

We are IntechOpen, the world's leading publisher of Open Access books Built by scientists, for scientists

6,900

Open access books available

186,000

International authors and editors

200M

Downloads

Our authors are among the

154

Countries delivered to

TOP 1%

most cited scientists

12.2%

Contributors from top 500 universities



WEB OF SCIENCE™

Selection of our books indexed in the Book Citation Index
in Web of Science™ Core Collection (BKCI)

Interested in publishing with us?
Contact book.department@intechopen.com

Numbers displayed above are based on latest data collected.
For more information visit www.intechopen.com



Ultrasound Modality in the Evaluation and Management of Gallbladder Polyps

*Haithem Zaafour, Meryam Mesbahi, Nizar Khedhiri,
Wassim Riahi, Mouna Cherif, Dhafer Haddad
and Anis Ben Maamer*

Abstract

Gallbladder polyps (GBP) are defined as developed masses inside the wall of the gallbladder; most of them (90%) are nontumor lesions. Abdominal ultrasound is the main and the first line radiological modality for their diagnosis and their risk lamination. We conducted a 12 year retrospective study between 2009 and 2020, which included patients who had preoperative transabdominal ultrasonography showing gallbladder polyps and had undergone cholecystectomy, and for whom postoperative pathology results were available, as well as patients who had at least one polyp discovered on the histopathological exam and who were not determined preoperatively. A total of 70 patients were identified. Preoperative diagnosis of vesicular polyp by ultrasound was carried in 82.9% of patients. The number of ultrasounds performed per person was 1.2 ± 0.47 . The polyps' size in mm was on average 6.14 ± 2.6 with extremes between 3 and 13 mm. On anatomopathological examination, a polyp was objectified in 33.3% of cases. In our series, abdominal ultrasound had a low sensitivity at 36.4%. We aim to provide the accuracy of abdominal ultrasound for the diagnosis of GBP, as a low-cost modality, and to evaluate the concordance of preoperative ultrasound imaging with postoperative pathology.

Keywords: gallbladder polyps, abdominal ultrasound, sensitivity, cholecystectomy, management

1. Introduction

Gallbladder polyps (GBP) are defined as developed masses inside the wall of the gallbladder; most of them (90%) are nontumor lesions [1]. They have been firstly classified in 1976 as benign tumors, pseudotumors, and malignant tumors [2].

Abdominal ultrasound is the main and the first line radiological modality for their diagnosis and their risk lamination [3]. It has been proven in the literature, the superiority of ultrasound by comparing it to other imaging techniques such as CT scan [4].

Ultrasound diagnosis of GBP is founded on two criteria—the lack of posterior acoustic shadow and immobility when changing the patient's position [1, 5].

Transabdominal ultrasound represents also an essential modality for the follow-up of GBP [6].

Nowadays, plenty of radiological modalities, such as transabdominal ultrasonography, endoscopic ultrasonography, magnetic resonance imaging (MRI), CT scan, or PET-CT have been employed for the diagnosis of GBP [7].

GBP are potentially malignant lesions so that it is mandatory to be precise whether the polyp is a high or low risk of malignancy and to lead undoubtedly to their perfect management [8].

We aim to provide the accuracy of abdominal ultrasound for the diagnosis of GBP, as a low-cost modality, and to evaluate the concordance of preoperative ultrasound imaging with postoperative pathology.

2. Methods

We conducted a 12 year retrospective study between 2009 and 2020, which included patients who had preoperative transabdominal ultrasonography showing gallbladder polyps and had undergone cholecystectomy, and for whom postoperative pathology results were available, as well as patients who had at least one polyp discovered on the histopathological exam and who were not determined preoperatively.

Epidemiological, clinical, morphological, and ultrasound data were then collected, as well as data from anatomy pathology interventions and reports.

3. Results

A total of 70 patients were identified. The sex ratio (male:female) was 0.34. The average age was 53.4 years with extremes ranging from 28 to 78 years. A total of 35 patients had a medical history, such as high blood pressure (25.7%), dyslipidemia (11.4%), and diabetes (8.6%). A total of 45 patients had a surgical history. The ASA score was 1 in 62.9%, 2 in 34.3%, and 3 in 2.9%.

Abdominal ultrasound was performed in all patients.

Preoperative diagnosis of vesicular polyp by ultrasound was carried in 82.9% of patients. Either due to symptoms in 68.6% of cases—right hypochondrium pain (48.4%), liver colic (35.5%), vomiting (9.7%) or fortuitous discovery in 8.6% of cases during an abdominal ultrasound for other pathology, or systematically in 5.7% of cases (four cases) as part of the preoperative assessment of an umbilical hernia.

In 17.1% of cases, the polyp was discovered perioperatively.

The number of ultrasounds performed per person was 1.2 ± 0.47 .

Characteristics	
Age (years)	53.4
Symptoms, (%)	68.8%
Diabetes mellitus	8.6%
Size of gallbladder polyp (mm)	6.14 ± 2.6
No. of polyps per patient	1.59 ± 0.79
Coexistin ggallstones	4

Table 1.
Demographic and clinical characteristics of the study population.

The number of gallbladder polyps per patient was 1.59 ± 0.79 .

The polyps' size in mm was on average 6.14 ± 2.6 with extremes between 3 and 13 mm. Gallbladder polyp and gallbladder stones were found in four patients (**Table 1**).

Other additional tests were performed: abdominal CT scan in 17.1% of cases, MRI in 5.7% of cases, upper endoscopy in 14.3% of cases, especially before gastric pain.

The surgical indication was retained especially when there were symptomatic polyps whatever the size, which was in 67.6% of cases.

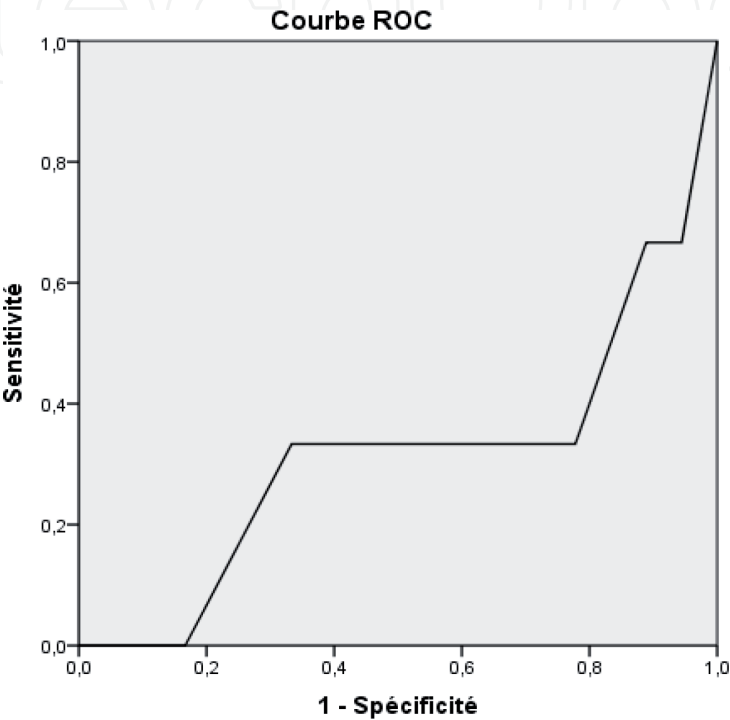


Figure 1.
 Correlation between the size of the polyp on the abdominal ultrasound and the presence of polyp on the piece of cholecystectomy.

Positive if >=	Sensibility	Specificity
2.00	1000	1000
3.35	667	944
3.85	667	889
4.25	333	778
4.75	333	722
5.25	333	611
5.75	333	556
7.00	333	333
8.25	000	167
9.75	000	111
12.00	000	056
14.00	000	000

Table 2.
 Sensibility and specificity of the abdominal ultrasound in function of the size of the polyp.

Cholecystectomy was performed by laparoscopy in 82.9% of cases.

On anatomopathological examination, a polyp was objectified in 33.3% of cases. The average size was 8.83 ± 10.8 mm. Dysplasia was found in 72.7% of all polyps.

In 22.7% of cases, cholesterosis was noted.

In our series, abdominal ultrasound had a low sensitivity at 36.4%.

Using the ROC curve (**Figure 1**) to study the correlation between the size of the polyp on the abdominal ultrasound and the presence of polyp on the piece of cholecystectomy, we found that the area under the curve was 0.315, which corresponds to a low discriminating power.

The study of the coordinates of the curve showed that a size of 7 mm would have the best specificity and sensitivity (**Table 2**).

4. Discussion

This cohort study is based on the effectiveness of transabdominal ultrasound on the detection of GBP.

GBP is the frequent vesicular lesions, which are found frequently on abdominal ultrasonography [8]. Asymptomatic GBP is present in 5% of adults [9].

The abdominal ultrasonography presents the first line radiological means for the diagnosis of gallbladder diseases and the perfect examination for diagnosing polyps [4, 8]. Considering that it has the lower cost-effectiveness, convenient accessibility, the lack of radiation, and because of its higher sensitivity 93% and specificity 95.3% [8–10].

On the ultrasound, GBP appears as an elevated, immobile lesion of the wall, it has a posterior acoustic shadow, and it appears as a sessile lesion [11, 12].

Despite the routine use of ultrasound, it seems that its positive predictive value in diagnosing polyps is still low [13].

It can present some limitations because it is operator-dependent [14], and it can provide errors in the determination of polyps, their numbers, and their size [8].

As an example, a gallstone can be easily mistaken for a polyp on ultrasonography [15], as it can be only identified on ultrasound if it measures over 5 mm [15].

Many hypotheses have been studied to explain the poor sensitivity of ultrasound in determining true polyps, Kratzer proposed in this case, that the initial diagnosis of a polyp might be incorrect [7]. As seen in the Cochrane review that the cause of false diagnoses by ultrasound was generally a result of misinterpretation of gallstones as polyps [10].

However, Ostapenko [13] has concluded that seven patients of 34 with GBP did not have a detectable polyp, supporting the argument that the initial diagnosis was a false positive.

In our series, ultrasound had a sensitivity of 36.4%. Several factors could explain this result. Since ultrasound is a dependent operator examination, gall bladder stones, especially those of small size, could be taken on account of a polyp. The polyp's migration to the bile ducts could be another explanation and would probably be the cause of the hepatic colic. The absence of polyp on the histological examination could also be explained by the manipulation of the gallbladder during cholecystectomy.

In case of diagnostic difficulties, and mainly when malignancy is suspected, other complementary investigations can be more helpful [14, 16, 17] presenting by:

Contrast-enhanced sonography: which is an ultrasound enhanced by the injection of a medium non-irradiating ultrasonic contrast (microbubbles), is more specific in the study of vascularity, showing hyper-echoic contrast during the arterial phase and iso-echoic images during the venous phase. So, it is more

useful to identify gallbladder polyps of multiple stones and from other polypoid lesions [9, 14].

Magnetic resonance imaging (MRI): It is a particular modality used in the differentiation between gallbladder polyps from other polypoid lesions, especially adenomyomatosis [14].

Positron emission tomography (PET): It is used to evaluate the malignancy diagnosis in polyps rising more than 10 mm by hypermetabolism [14].

Endoscopic ultrasound (EUS): It is determined to be better than ultrasound, it is the best modality in diagnosing gallbladder polyps [15], especially when there is suspicion of regional lymph nodes, providing the staging of polypoid lesions [14, 15].

Conventional ultrasound is sufficient to investigate GBP compared to other modalities, however, it has been proven in some studies that endoscopic ultrasound is more specific and exact, especially in the differentiation between true and pseudopolyps [11].

Guo [8] confirmed the accuracy of ultrasound for polyps diagnosis which was 78.8% in their work, and its accuracy for differentiation between benign and malignant polyps, which was confirmed in the Cochrane review [10]. Our results are in line with these cohort studies.

On ultrasonography, the polyp echogenicity is used to distinguish between true, pseudopolyps, and gallstones [18].

Its main role is to identify prematurely the progression of polyps to malignant carcinomas [13]. Polyps size is considered the main indicator of potential malignancy [16].

According to the guidelines, an arbitrary cut-off of 10 mm is confirmed to indicate cholecystectomy, which is justified by the increased incidence of gallbladder carcinoma in the polyps rising sharply from 10 mm and upwards [11, 16, 18, 19].

Polyps can cause symptoms and the relationship between symptoms and risk of malignancy is still controversial according to the literature, so cholecystectomy is wisely indicated when GBP are symptomatic [11].

Many factors that influence the therapeutic strategy of GBP were studied, including mainly the polyp size on radiological findings [18].

Referring to the literature (recent guidelines by the ESGAR group), the main factors that determine malignancy included primarily—the size greater than 10 mm, the sessile morphology, the presence of symptoms, the age 50 years and older, the Indian ethnicity, and the associated primary sclerosing cholangitis (**Figure 2**) [14, 18, 20].

Several retrospective studies showed controversial results about factors influencing malignancy and indicating cholecystectomy, which are—concomitant gallstones, elevated CA 19-9 marker, rapid polyp growth, and the number of polyps [14, 18, 20].

Gallbladder polyps are generally diagnosed and monitored by ultrasonography which is debated in the literature, discussing its accuracy [16]. Some studies confirmed its failure for the diagnosis, seen the absence of polyps at numerous histological examinations [16].

Several series have studied the correlation between ultrasound findings and histopathology results, concluded significant conjunction for the size determination between both modalities [15].

Elmasry [16] showed a significant number of gallbladder polyps that were not seen at histological examination postcholecystectomy, with an incidence of 16.4% of all histological results. This can be explained that polyps may be destroyed by the mechanical action of the gallbladder wall [7].

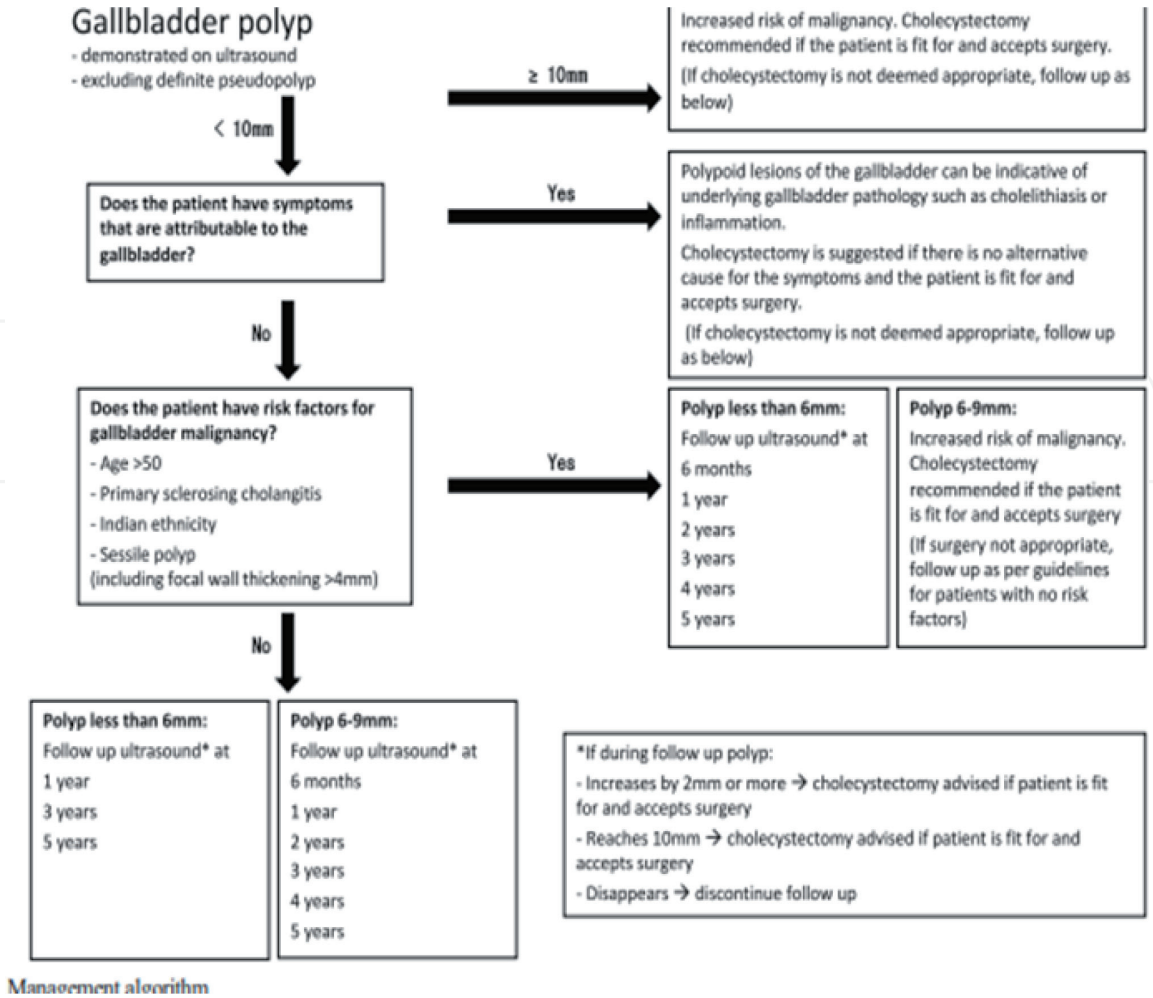


Figure 2.
 Management algorithm for gallbladder polyps [11].

Nonresected GBP which are smaller than 10 mm are recommended to be followed up regularly with serial ultrasound imagery [15], every 6 months–1 year for those under 5 mm, every 3–6 months for those with a dimension of 5–10 mm [1].

Follow-up strategy of GBP is not yet based on any consensus on the size of polyps, neither on its frequency or duration. Recently, the guidelines of ESGAR states recommend that polyps of 6–9 mm should be supervised prudently than polyps of less than 6 mm [18]. So that the measurement of polyps size is mandatory during the follow up of GBP—it was found that 6.9% of polyps increased their size during the monitoring period [12].

It has been proven that there was no evidence data published to define the increasing size of the polyps during surveillance, which may be an indicator for cholecystectomy [2].

5. Conclusion

Preoperative diagnosis of GBP distinguishing malignant from benign lesions is challenging. Literature has highlighted the accuracy of ultrasound as the key modality for GBP detection.

It is used to be the gold standard, seeing it has relatively low-cost, low-risk, and widely available techniques. However, many studies discussed its ineffectiveness in polyp diagnosis, despite its major role in European guidelines. Leading to the essential role of other modalities such as magnetic resonance imaging, and endoscopic

ultrasound. In the upcoming, studies should investigate more on the utility of these newer imaging techniques to enhance a new multimodal strategy to gallbladder polyp investigation.

IntechOpen

IntechOpen

Author details

Haithem Zaafour^{*}, Meryam Mesbahi, Nizar Khedhiri, Wassim Riahi,
Mouna Cherif, Dhafer Haddad and Anis Ben Maamer
Department of General Surgery, Habib Thameur Hospital, Tunis, Tunisia

^{*}Address all correspondence to: zaafouri.haithem@hotmail.fr

IntechOpen

© 2021 The Author(s). Licensee IntechOpen. This chapter is distributed under the terms of the Creative Commons Attribution License (<http://creativecommons.org/licenses/by/3.0>), which permits unrestricted use, distribution, and reproduction in any medium, provided the original work is properly cited. 

References

- [1] Pirraci DA. Evaluation and Ultrasound Follow-up of Gallbladder Polyps. *Webmed Central Radiology*. 2013;**4**(6):WMC004297
- [2] Morera-Ocón FJ, Ballestín-Vicente J, Calatayud-Blas AM, Cataldo de Tursi-Rispoli L, Bernal-Sprekelsen JC. Surgical indications in gallbladder polyps *Cirugía Española*. 2013;**91**(5): 324-330
- [3] Choi TW. Risk stratification of gallbladder polyps larger than 10 mm using high-resolution ultrasonography and texture analysis. *European Radiology*. 2018;**28**(1):196-205
- [4] Liu L-N, Xu H-X, Lu M-D, Xie X-Y, Wang W-P, Hu B, et al. Contrast-enhanced ultrasound in the diagnosis of gallbladder diseases: A multi-center experience. *PLoS One*. 2012;**7**(10):13
- [5] Bae JS. Quantitative contrast-enhanced US helps differentiating neoplastic vs non-neoplastic gallbladder polyps. *European Radiology*. 2019;**29**(7):3772-3781
- [6] Martin E, Gill R, Debru E. Diagnostic accuracy of transabdominal ultrasonography for gallbladder polyps: Systematic review. *Canadian Journal of Surgery*. 2018;**61**(3):200-207
- [7] Kratzer W, Haenle MM, Voegtle A, Mason RA, Akinli AS, Hirschbuehl K, et al. Ultrasonographically detected gallbladder polyps: A reason for concern? A seven-year follow-up study. *BMC Gastroenterology*. 2008;**8**:41-49
- [8] Guo J, Wu G, Zhou Z. Polypoid lesions of the gallbladder: report of 160 cases with special reference to diagnosis and treatment in China. *International Journal of Clinical and Experimental Pathology*. 2015;**8**(9):11569-11578
- [9] Yuan Z. Is contrast-enhanced ultrasound superior to computed tomography for differential diagnosis of gallbladder polyps? A cross-sectional study. *Frontiers in Oncology*. 2021;**11**:12
- [10] Sarah ZW, Mark PL, Marcello DM, Joost Ph D, Kurinchi SG, Cornelis Jhm van L. et al. Transabdominal ultrasound and endoscopic ultrasound for diagnosis of gallbladder polyps (review). *Cochrane Database of Systematic Reviews*. 2018;**8**(8):CD012233
- [11] Wiles R. Management and follow-up of gallbladder polyps. *European Radiology*. 2017;**27**(9):3856-3866.
- [12] Rafaelsen SR, Otto PO, Pedersen MRV. Long-term ultrasound follow-up in patients with small gallbladder polyps. *Danish Medical Journal*. 2020;**67**(10):1-7
- [13] Ostapenko A, Liechty S, Kim M, Kleiner D. Accuracy of ultrasound in diagnosing gallbladder polyps at a community hospital. *JSLs*. 2020;**24**(4):1-5
- [14] Valibouze C. The management of gallbladder polyps. *Journal of Visceral Surgery* 2020;**157**(5):410-417
- [15] Andrén-Sandberg Å. Diagnosis and management of gallbladder polyps. *North American Journal of Medicine and Science*. 2012;**4**(5):10
- [16] Elmasry MM, Mracs M. The risk of malignancy in ultrasound detected gallbladder polyps: A systematic review. *International Journal of Surgery*. 2016;**33**:28-35
- [17] Babu BI, Dennison AR, Garcea G. Management and diagnosis of gallbladder polyps: A systematic review. *Langenbeck's Archives of Surgery*. 2015;**400**(4):455-62

[18] McCain RS, Diamond A, Jones C, Coleman HG. Current practices and future prospects for the management of gallbladder polyps: A topical review. *World Journal of Gastroenterology*. 2018;**24**(26):2844-2852

[19] Jeong Y, Kim JH, Chae HD, Park SJ, Bae JS, Joo I, et al. Deep learning-based decision support system for the diagnosis of neoplastic gallbladder polyps on ultrasonography: Preliminary results. *Scientific Reports* 2020;**10**(1): 1-10

[20] Sun Y, Yang Z, Lan X, Tan H. Neoplastic polyps in gallbladder: A retrospective study to determine risk factors and treatment strategy for gallbladder polyps. *Hepatobiliary Surgery and Nutrition*. 2019;**8**(3):9