

We are IntechOpen, the world's leading publisher of Open Access books Built by scientists, for scientists

6,900

Open access books available

186,000

International authors and editors

200M

Downloads

Our authors are among the

154

Countries delivered to

TOP 1%

most cited scientists

12.2%

Contributors from top 500 universities



WEB OF SCIENCE™

Selection of our books indexed in the Book Citation Index
in Web of Science™ Core Collection (BKCI)

Interested in publishing with us?
Contact book.department@intechopen.com

Numbers displayed above are based on latest data collected.
For more information visit www.intechopen.com



Adaptive Optics Imaging Technique in Diabetic Retinopathy

*Florian Baltă, Irina Elena Cristescu
and Ioana Teodora Tofolean*

Abstract

Adaptive optics ophthalmoscopy opened a new era in the medical retina field. The possibility of obtaining high-resolution retinal images of photoreceptors and retinal vessels addresses new perspectives in retinal physiology and pathophysiology. The overwhelming incidence of diabetes in the global population justifies the need to develop and refine methods of diagnosing early retinal changes, in order to preserve vision and avoid complications. The current grading of diabetic retinopathy is based on clinical changes only. Nevertheless, imaging tools such as optical coherence tomography and optical coherence tomography angiography are also used for screening of this pathology. The corroboration of the information provided by these imaging methods may lay the foundations for a new approach to the definition and diagnosis of diabetic retinopathy.

Keywords: diabetic retinopathy, retinal imaging, adaptive optics ophthalmoscopy, wall-to-lumen ratio, cone mosaic, rtx1™

1. Introduction: Adaptive optics in retinal imaging

The principle of adaptive optics (AO) belongs to Babcock since 1953. Fifteen years afterward, the technique started to be used in military setups. Its main purpose was obtaining good satellite surveillance images, even in unfavorable meteorological situations. In 1970, the Soviet and American military managed the real-time correction of atmospheric turbulences when studying laser sources and stars [1, 2]. In 1996, the first AO ophthalmoscope allowed *in vivo* imaging of the human retina, compensating for static and dynamic aberrations of the optical system of the human eye. AO technology has three main components: a Hartmann-Shack sensor, to measure distortion, a deformable mirror to compensate for the distortion, and a control system to calculate the required compensation.

AO has been allowing *in vivo* studies of human retinal photoreceptors mosaic and vessels at a two-micron transversal resolution. As it is lessening the effect of optical aberrations on any measurement, it can be combined with almost any imaging device. AO imaging at histological resolution of the retina opened new perspectives toward early detection, monitoring, and treatment of retinal diseases. The devices above are allowing noninvasive *in vivo* imaging of retinal structures:

- retinal nerve fiber layers; axons of ganglion cells can be studied with AO scanning laser ophthalmoscopy (AOSLO) [3, 4], AO optical coherence tomography (AOOCT) [5], and with AO flood illumination ophthalmoscopy [6];

- ganglion cells, although large in size, they have a low signal-to-noise ratio and a low intrinsic contrast. They were visualized in monkeys using intrinsic two-photon excitation fluorescence and AOSLO [7] and in humans using AOOCT [8];
- bipolar cells could not be visualized using any AO system, as they lack intrinsic contrast and scatter to be seen by reflectance;
- Henle fibers were visible with AOSLO, but in pathological cases only. In a study that included four family members with Best vitelliform macular dystrophy, the inner retinal layers changed their orientation because of the large subretinal lesions, thus producing sufficient scatter to reveal their structure;
- photoreceptors have been the most studied microscopic retinal structures, being the first neuron of the human visual pathway. Both cones and rods could be assessed using AO imaging techniques [9]. Advances in AO ophthalmoscopy led to substantial refinement in the ability to assess these cells, to the point where recording and analyzing clear mosaics of photoreceptors across of the macular region become possible;
- retinal pigment epithelium (RPE) was visualized in patients with age-related degeneration, in which RPE was obvious due to the photoreceptors degeneration, fact confirmed by optical coherence tomography (OCT) scans as well [10]. Moreover, AOSLO dark field showed RPE cell mosaic in a subject with no eye disease [11];
- lamina cribrosa—morphological changes were noticed in glaucomatous patients using flood illumination AO retinal camera [12], AOOCT [13], and AOSLO [10];
- retinal vasculature.

The following section focuses on an overview of AO retinal imaging methods, namely AO flood illumination imaging, adaptive optics scanning laser ophthalmoscopy, and adaptive optics optical coherence tomography.

1.1 AO flood illumination imaging

AO flood illumination imaging was obtained by coupling a wave front sensor and a deformable mirror to a high-magnification fundus camera, thus providing some of the first organized studies of retinal photoreceptors [14]. This is the principle of the AO rtx1 camera (Imagine Eyes, Orsay, France), which has been extensively used in the study of retinal photoreceptors [15–17] and vasculature [18, 19]. Compared with the other two devices, its axial resolution is smaller ($\sim 300\ \mu\text{m}$) [10]. However, an important advantage of this type of imaging is the speed at which the entire retinal image is acquired (a few milliseconds). Thus, with a CCD camera, 40 retinal images are taken in 4 s, which are to be further processed by specialized software in order to deliver a final image [20]. One single image is minimally influenced by eye movement, and the system is capable of providing very high frame rates with high sensitivity [21].

1.2 AO scanning laser ophthalmoscopy

AO scanning laser ophthalmoscope provides a higher contrast relative to AO flood illumination by recording scattered light from a focused beam across the

retinal surface through confocality. A pinhole conjugated to the focal retinal plane removes beams of light whose origin is outside the point spread function. By modifying the pinhole size, different transversal and axial resolutions of the system can be obtained, allowing imaging of the retinal structures (nerve fiber layers, photoreceptors, blood vessels). Its accuracy is increased by the AO constituent. In addition to this, continuous scanning allows the study of larger areas at a superior rate relative to conventional fundus imaging [22]. AOSLO is being used in high-resolution imaging, eye-tracking, laser modulations setups, psychophysics and electrophysiology studies [23].

1.3 AO optical coherence tomography

OCT started to be used as a retinal imaging tool in 1991, while the association of AO technology with the OCT was first introduced more than 10 years ago [24]. An advantage of the AO OCT is its ability to adjust images in all three coordinates (both axial and lateral) and to offer great visualization of individual cells because of its outstanding axial resolution. Axial resolution increases with the bandwidth of the imaging coherent light source [23]. Time-domain OCT might reach an axial resolution of 2–3 μm , whereas spectral-domain OCT an axial resolution between 2.1 and 2.5 μm [25]. Nevertheless, individual cells cannot be visualized because of low acquisition speed and low lateral resolution ($>15 \mu\text{m}$). Swept source OCT has a higher acquisition speed, but with an axial resolution of 5.3 μm and a lateral one of 20 μm . Lateral resolution is influenced by the eye's aberrations effect on focal spot size. After coupling AO with OCT imaging, the lateral resolution of the system reached 2–3 μm [26], and 3D imaging of retinal structures (RPE, ganglion cells, lamina cribrosa, nerve fiber layer) was achieved [27].

2. Diabetic retinopathy and adaptive optics

Diabetic retinopathy (DR) is a microvascular complication of diabetes mellitus (DM), representing one of the leading causes of vision loss and blindness worldwide [28]. Its early diagnosis is necessary to preserve vision and avoid its complications.

Staging of diabetic retinopathy is currently performed according to clinical changes only. Given the fact that patients with DR can be asymptomatic for a very long period of time, even in very advanced stages of the disease, regular screening of diabetic patients and appropriate treatment are strongly recommended [29]. Besides clinical examination, the new emerging imaging methods provide valuable information and lay the foundations of a new approach in the definition and diagnosis of diabetic retinopathy.

The accepted pathophysiological mechanisms of vision loss entail both retinal microvascular and neuronal damage [30–34]. Therefore, some authors [35] suggest diabetic retinal disease to be a more appropriate term for retinal changes in diabetes mellitus than diabetic retinopathy, as it encompasses both retinal vasculopathy and neuropathy. Moreover, it appears that retinal diabetic neuropathy (neuronal degeneration of the internal retinal layers) precedes retinal vasculopathy [36].

Diabetic patients without DR are proven by full-field electroretinography (ERG) and multifocal ERG studies to have retinal functional alterations [37], as well as ionic transport changes at photoreceptors' level [38, 39]. In addition to this, given that the retina and the cerebral cortex have the same embryological origin, it can be speculated that the retinal functional alterations may be connected with neurocognitive deficits in diabetic patients [40]. In this context, the study of photoreceptors

and retinal vessels can lead to the identification of new biomarkers that are able to mirror retinal alterations induced by DM.

Adaptive optics retinal camera is able to detect early diabetes-induced retinal changes, often before any documentable sign can be traced using other retinal imaging techniques, thus shedding new light on the pathophysiology of microvascular and neuronal changes in DR.

Microaneurysms are considered to be the first visible clinical signs, while the loss of pericytes seems to be the first histological microvascular alteration [41]. Microvascular clinical findings in DR encompass intraretinal hemorrhages, microaneurysms, venous caliber abnormalities, intraretinal microvascular abnormalities (IRMA), lipid exudates, cotton-wool spots, and retinal neovascularization [42]. Among these, microaneurysms [43], microscopic hemorrhages [43–45], hard exudates [46, 47], edematous cyst walls [45], and modified arteriolar structures [48–50] were already morphologically characterized using adaptive optics images (**Figures 1** and 2). Offering a fine documentation of retinal lesions, AO imaging technique might become an important instrument for early diagnosis and progression monitorization of DR [51].

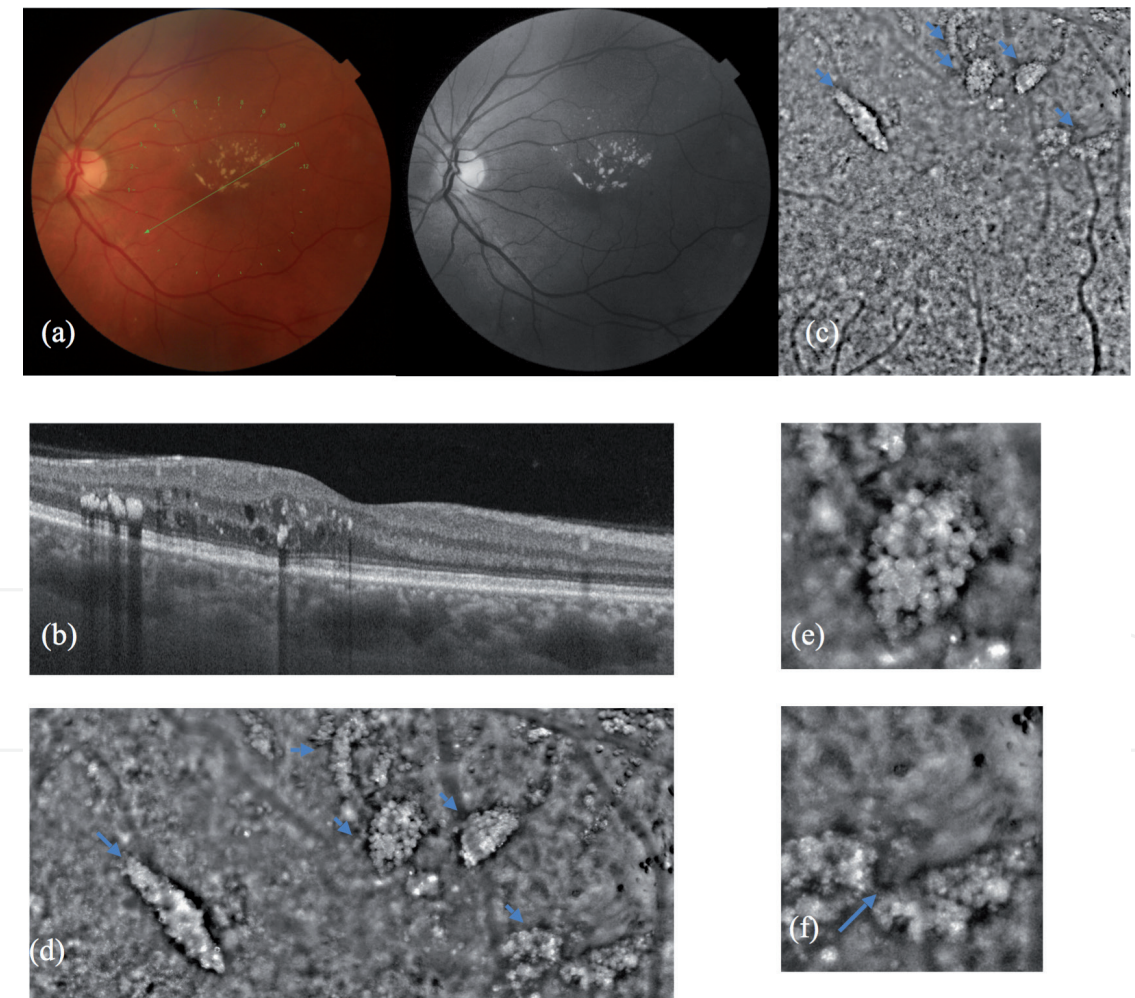


Figure 1. (a) Color fundus photo and red free photo of a patient with hard exudates and retinal edema. (b) Optical coherence tomography corresponding to the green line in (a) shows hard exudates in the middle retinal layers. (c) Adaptive optics imaging cone mosaic; small arrows indicate the hard exudates. (d) Magnification of the upper part in (c), in which besides the hard exudates (small arrows), edema blurring the retinal image can be noticed. (e) Magnification of (d), detail of a hard exudate showing foci of hyper- and hypo-reflectivity. (f) Magnification of (d), detail of two hard exudates and retinal edema; the cystic spaces have a sharp demarcation line indicated by the big arrow. (Reproduced from [46]. Copyright by the ©Romanian Society of Ophthalmology.)

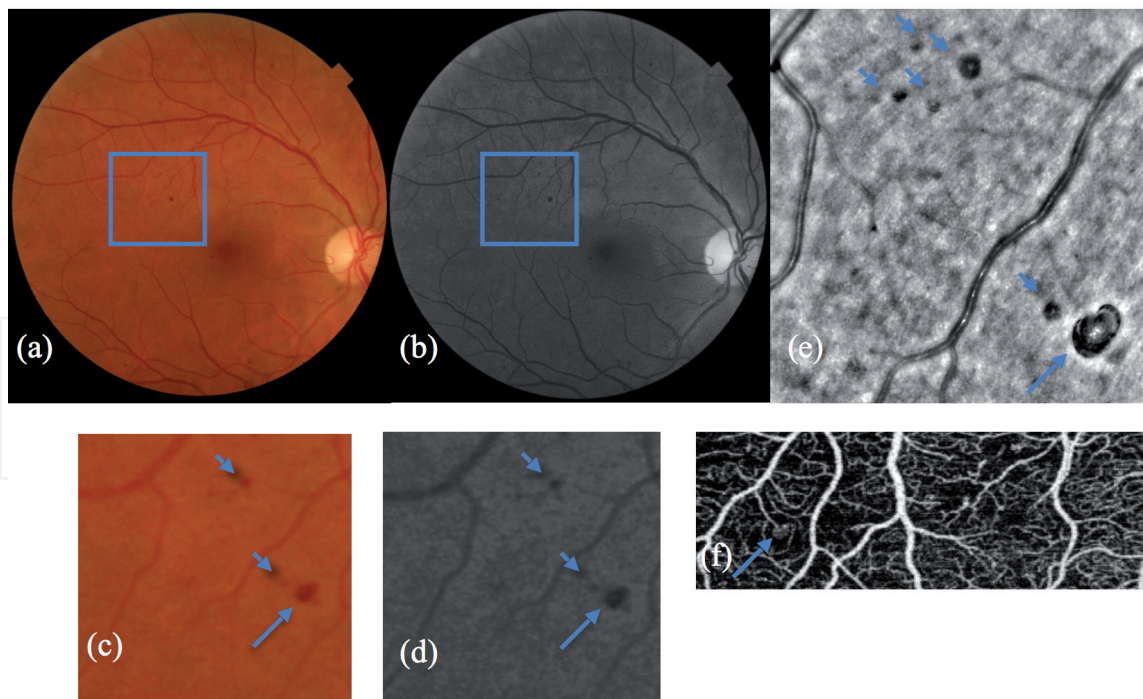


Figure 2.
 (a) and (b) Color fundus photo and red free photo of a patient with microaneurysms and hemorrhages.
 (c) and (d) Larger magnification of the area delimited in the previous photos, (a) and (b). The big arrow indicates a microaneurysm and the arrowheads show hemorrhages. (e) Adaptive optics image corresponding to (c) and (d). The black lesion with inner hyper-reflectivity marked by a big arrow is a microaneurysm. The black lesions marked by small arrows are retinal hemorrhages. (f) OCT angiography revealed only one lesion from the ones above which is the microaneurysm. (Reproduced from [46]. Copyright by the ©Romanian Society of Ophthalmology.)

2.1 Imaging the cone mosaic in diabetic retinopathy

Biological systems are characterized by symmetrical spatial arrangements as in hexagonal systems. These structures can have equal angles and sides. Even when they are not clearly delimited [52], Voronoi diagrams can generate the limits between elements, taking the starting points as generators. It is known that the regular hexagon is the maximum-sided polygon that could be used to cover a plane without overlaps. The immediate advantage of this organization is the maximization of number of neighbors of each element and the consequent optimization of cell signaling, resolution, and isotropy (photoreceptors, retinal neurons).

2.1.1 Cone parameters

2.1.1.1 Photoreceptor density

The density of photoreceptors is usually assessed by dividing the number of detected cones by the analyzed area. This method implies a normal distribution within the analyzed area and will underestimate the density if this area overlaps over regions for which no data are available. These limitations motivate the need for Voronoi local density analysis [53]. The density of photoreceptors can be expressed in metric (cones/mm²) or angular (cones/degree) units. The value of the antero-posterior axis can influence the values expressed in metric units. At a certain eccentricity, the distance from the fovea may be different depending on the antero-posterior axis. For example, an eccentricity of 2° corresponds to a distance between 0.53 and 0.64 mm from the fovea, given an axis of 22–26 mm. As the axis gets longer, the retinal area increases and the cones density gets lower when expressed in metric units [54].

2.1.1.2 Cone spacing

This indicator is useful to be used in conjunction with photoreceptor density. It considers only the closest photoreceptor for each cone detected in the region of interest, regardless of the measured distance [17]. This can lead to high values for isolated cells. On the other hand, it has been shown that the distance between photoreceptors is less sensitive to subsampling (compared to cones) and to the correlation with a certain pathology. Thus, photoreceptor spacing overestimates the overall health of the photoreceptor mosaic (e.g., a mosaic with sporadic photoreceptor losses may have normal distances between photoreceptors, but in the presence of an abnormal density). In conclusion, in order to correctly depict a mosaic, all biomarkers should be considered [55].

2.1.1.3 Voronoi diagrams

Given a finite set of two or more points in an Euclidean plane, we associate all locations of that plane with the nearest element of the set. The result is a tessellation of the plane in a series of regions associated with the elements of the set of points. This tiling is called the Voronoi diagram generated by the set of points, while the regions that make up the Voronoi diagram are called Voronoi polygons [56]. Li and collaborators showed that less than 30% of Voronoi polygons are non-hexagonal in the vicinity of the fovea and that their percentage increases to 50–60% at higher eccentricities [57]. Cones at higher eccentricities are unevenly distributed and protect the visual system from perceiving a distorted signal [58].

AO ophthalmoscopy is an accessible tool for clinicians to visualize the human retina *in vivo* [59, 60]. Cones parameters have been analyzed in healthy, adult population [15, 61, 62] and correlated to several factors (age, gender, refractive error, antero-posterior axis, race, ethnicity). These studies showed a variability of photoreceptor densities in normal population [15, 63], which makes it difficult to detect small variabilities of this parameter in comparative studies. The inclusion of all photoreceptor parameters (distance from the nearest photoreceptor and Voronoi diagrams—with the analysis of their spatial arrangement) in study protocols promises to provide more conclusive results [17]. Nevertheless, the first measurements of cone density come from the postmortem histological analysis of the human retina [64]. It has been shown that in the center of the fovea, there is a density of 199,000 cells/mm², which decreases to about 20,000 cells/mm² to 1 mm from the center of the fovea.

2.1.2 Cone parameters in diabetic retinopathy

AO ophthalmoscopy has been used to assess the parafoveal cone parameters in diabetic patients (type I or type II diabetes) and controls in various studies (**Figure 3**) [16, 17, 48, 66, 67].

Lombardo et al. [17] studied the differences between cone parameters at 1.5 degrees eccentricity in patients diagnosed with DM I without DR or with nonproliferative DR and in healthy subjects. Their results showed that cone density was higher in the control group as compared with the study group, on both vertical and horizontal meridians. Another study [47, 68] showed that cone density was 10% lower in type I diabetic subjects with no DR than in controls. Moreover, cone densities were also investigated in type II diabetic patients with or without DR and in healthy subjects, at 0 and 2 degrees eccentricity [16]. The results showed a positive correlation of the extent of cone loss on AO imaging with DR severity in




Figure 3.
 Examples of regions of interest (red square) at 2, 3, and 4 degrees nasally analyzed in a control subject (a) and in a diabetic patient (b). (Reproduced from [65]. Copyright by the ©Romanian Society of Ophthalmology.)

type II diabetic patients. On the other hand, Tan and collaborators [69] found no cone densities differences at 7 degrees eccentricity between patients with DM I and healthy subjects, probably due to the short duration of diabetes in the study group.

In addition to this, cone spacing was found to significantly increase in diabetic patients, when compared with healthy controls [70]. Results show lessening of hexagonal mosaics of cones (Voronoi 6 tiles) with increased severity of DR.

The horizontal meridian was proved to have a higher average cone density than the vertical one in both controls and type I diabetic patients with no DR [47, 68]. However, the asymmetry was higher in the control group. Another study reported this pattern in normal subjects [15]. This asymmetry, also called “horizontal–vertical anisotropy,” could be related to the way we are using our vision. When reading, the horizontal meridian is more in demand than the vertical one. Psychophysical studies have shown a higher contrast sensitivity and spatial resolution of the horizontal meridian as compared with the vertical one at a given eccentricity [71]. Further studies including more subjects are needed to describe the cone parameters in diabetic and age-matched volunteers.

2.2 Imaging the retinal microvasculature in diabetic retinopathy

Retinal microcirculation is a network of arterioles, capillaries, and venules with diameters that do not exceed 150 μm , whose main function is to assure and regulate an optimal tissue perfusion [72]. Microcirculation alterations, also called microangiopathy, lead to organ damage and clinical events in patients with DM.

A microvascular network is assessed from a structural and functional point of view, taking into consideration both its topology and geometric abnormalities [73].




Figure 4. Image of the retinal artery of a patient with diabetes mellitus, with visualization of the walls (short arrow) and lumen (long arrow), employing AO detect artery software.

The retinal vascular branching model is similar to a fractal, having a complex pattern of distribution, where each part has similar features to the main structure. DR is associated with a decreased fractal dimension, which is probably correlated with the shortcoming of the retinal circulation [74]. The network geometry is appreciated using the length and the diameters of the vessels, by calculating different derived parameters.

Vascular-addressing diseases encounter different patterns of vascular remodeling. The inward eutrophic remodeling, seen in stages 1 and 2 of essential hypertension, is characterized by a reduced lumen diameter, with consecutive rearrangement of the surrounding smooth muscle cells, but without a marked growth response [75]. The media-to-lumen ratio is increased due to reduced lumen diameter and external diameter of the wall and due to increased media thickness, with minimum changes in the total amount of wall tissue. All these result in decreased vasodilation potential of the vessel and altered arteriolar distensibility [76, 77]. In contrast, the hypertrophic remodeling, found in diabetes mellitus and in long-standing, severe and secondary hypertension, exhibits a significant growth response with vascular smooth muscle cell hypertrophy or hyperplasia [78, 79]. This leads to the increase of both media-to-lumen ratio and the media cross-sectional area of the vessel [80].

The bedside morphological assessment of human retinal microcirculation is not facile, the gold standard being the media-to-lumen ratio evaluated by wire or pressure micromyography on bioptic samples [81]. Recently, noninvasive techniques for the evaluation of retinal arterioles prove rather good agreement with micromyographic measurements, in particular scanning laser Doppler flowmetry and adaptive optics [81, 82]. Preliminary data suggest that AO has a substantial advantage over Doppler flowmetry, having a better correlation with the gold standard, but invasive procedure [81].

Adaptive optics ophthalmoscopy uses a cutting-edge technique, visualizing the retinal arterioles lumen as a bright band, while the walls correspond to the darker neighboring regions (**Figure 4**). The wall thickness of the blood vessels depends on the vessels' size, with large lumens requiring thicker walls. The AO-related vascular parameters of interest are:

- wall thickness (WT);
- lumen diameter (LD);
- vessel diameter (VD—the algebraic sum between the thickness of the arterioles' walls and the lumen diameter);

- wall-to-lumen ratio (WLR—the ratio between the wall thickness and the lumen diameter);
- the cross-sectional area of the vascular wall (WCSA—the calculation is based on the lumen diameter and vessel diameter values).

Zaleska-Żmijewska et al. [48] found statistically significant differences between the control group and the prediabetic group with respect to LD and to WLR. Furthermore, the same scientific team demonstrated that WLR, WCSA, and the average WT exhibit significant differences between the control group and type II diabetic patients [70]. An AOSLO study confirms that retinal arterial WT is significantly greater in patients with type 2 diabetes than in controls [83].

When it comes to DM type I, the average capillary LD proved to be significantly narrower in eyes with nonproliferative diabetic retinopathy and type I DM, when compared with healthy subjects ($6.27 \pm 1.63 \mu\text{m}$ versus $7.31 \pm 1.59 \mu\text{m}$, $p = 0.002$) [50]. When investigating the retinal microcirculation changes in type I and II diabetic patients without retinopathy, among all studied parameters, only WLR was significantly different between the control group and each group of diabetic patients taken individually, while no statistically significant differences were found between the two diabetic groups [47, 68].

New data characterize retinal arterioles according to DR classification, showing that LD, WT, and WLR significantly correlate with the stage of DR [84]. AO was even used to establish the effects of a multinutrient complex on retinal microvasculature in diabetic patients. After 3 months of food supplements administration, WLR, WT, and WCSA had significantly decreased, when compared with initial observations [85].

AO proved its potential to detect retinal microvascular changes in prediabetic subjects and diabetic patients, as well as to reveal differences between the diabetic groups. Providing useful information about the topological and geometrical features of the retinal microvasculature from early onset of diabetic disease, AO has a promising role in the future, providing valuable prognostic, diagnostic, and therapy-related information in diabetic retinopathy.

Conflict of interest

The authors declare no conflict of interest.

IntechOpen

Author details

Florian Baltă^{1,2,3}, Irina Elena Cristescu^{3*} and Ioana Teodora Tofolean^{1,2}

1 “Carol Davila” University of Medicine and Pharmacy, Bucharest, Romania

2 Emergency Eye Hospital, Bucharest, Romania

3 “Retina” Clinic, Bucharest, Romania

*Address all correspondence to: cristescu.irina@gmail.com

IntechOpen

© 2021 The Author(s). Licensee IntechOpen. This chapter is distributed under the terms of the Creative Commons Attribution License (<http://creativecommons.org/licenses/by/3.0>), which permits unrestricted use, distribution, and reproduction in any medium, provided the original work is properly cited. 

References

- [1] Hardy J. Adaptive optics—A progress review. *Proceedings of SPIE on Active and Adaptive Optical Systems*. 1991; **1542**:2-17
- [2] Park JH, Kong L, Zhou Y, Cui M. Large-field-of-view imaging by multi-pupil adaptive optics. *Nature Methods*. 2017; **14**(6):581-583
- [3] Takayama K, Ooto S, Hangai M, Arakawa N, Oshima S, Shibata N, et al. High-resolution imaging of the retinal nerve fiber layer in normal eyes using adaptive optics scanning laser ophthalmoscopy. *PLoS One*. 2012; **7**(3):e33158
- [4] Takayama K, Ooto S, Hangai M, Ueda-Arakawa N, Yoshida S, Akagi T, et al. High-resolution imaging of retinal nerve fiber bundles in glaucoma using adaptive optics scanning laser ophthalmoscopy. *American Journal of Ophthalmology*. 2013; **155**(5):870-881
- [5] Choi SS, Zawadzki RJ, Keltner JL, Werner JS. Changes in cellular structures revealed by ultra-high resolution retinal imaging in optic neuropathies. *Investigative Ophthalmology & Visual Science*. 2008; **49**(5):2103-2119
- [6] Ramaswamy G, Lombardo M, Devaney N. Registration of adaptive optics corrected retinal nerve fiber layer (RNFL) images. *Biomedical Optics Express*. 2014; **5**(6):1941-1951
- [7] Hunter JJ, Masella B, Dubra A, Sharma R, Yin L, Merigan WH, et al. Images of photoreceptors in living primate eyes using adaptive optics two-photon ophthalmoscopy. *Biomedical Optics Express*. 2010; **2**(1):139-148
- [8] Liu T, Jung H, Liu J, Droettboom M, Tam J. Noninvasive near infrared autofluorescence imaging of retinal pigment epithelial cells in the human retina using adaptive optics. *Biomedical Optics Express*. 2017; **8**(10):4348-4360
- [9] Doble N, Choi SS, Codona JL, Christou J, Enoch JM, Williams DR. In vivo imaging of the human rod photoreceptor mosaic. *Optics Letters*. 2011; **36**(1):31-33
- [10] Zhang B, Li N, Kang J, He Y, Chen XM. Adaptive optics scanning laser ophthalmoscopy in fundus imaging, a review and update. *International Journal of Ophthalmology*. 2017; **10**(11):1751-1758
- [11] Scoles D, Sulai YN, Dubra A. In vivo dark-field imaging of the retinal pigment epithelium cell mosaic. *Biomedical Optics Express*. 2013; **4**(9):1710-1723
- [12] Zwillinger S, Paques M, Safran B, Baudouin C. In vivo characterization of lamina cribrosa pore morphology in primary open-angle glaucoma. *Journal Français d'Ophtalmologie*. 2016; **39**(3):265-271
- [13] Dong ZM, Wollstein G, Wang B, Schuman JS. Adaptive optics optical coherence tomography in glaucoma. *Progress in Retinal and Eye Research*. 2017; **57**:76-88
- [14] Liang J, Williams DR, Miller DT. Supernormal vision and high-resolution retinal imaging through adaptive optics. *Journal of the Optical Society of America. A, Optics, Image Science, and Vision*. 1997; **14**(11):2884-2892
- [15] Legras R, Gaudric A, Woog K. Distribution of cone density, spacing and arrangement in adult healthy retinas with adaptive optics flood illumination. *PLoS One*. 2018; **13**(1):e0191141
- [16] Soliman MK, Sadiq MA, Agarwal A, Sarwar S, Hassan M, Hanout M, et al.

High-resolution imaging of parafoveal cones in different stages of diabetic retinopathy using adaptive optics fundus camera. *PLoS One*. 2016;**11**(4): e0152788

[17] Lombardo M, Parravano M, Serrao S, Ziccardi L, Giannini D, Lombardo G. Investigation of adaptive optics imaging biomarkers for detecting pathological changes of the cone mosaic in patients with type 1 diabetes mellitus. *PLoS One*. 2016;**11**(3):e0151380

[18] Koch E, Rosenbaum D, Brolly A, Sahel JA, Chaumet-Riffaud P, Girerd X, et al. Morphometric analysis of small arteries in the human retina using adaptive optics imaging: Relationship with blood pressure and focal vascular changes. *Journal of Hypertension*. 2014;**32**(4):890-898

[19] Lermé N, Rossant F, Bloch I, Paques M, Koch E, editors. *Coupled Parallel Snakes for Segmenting Healthy and Pathological Retinal Arteries in Adaptive Optics Images*. Cham: Springer International Publishing; 2014

[20] Tumahai P, Moureaux C, Meillat M, Debellemann G, Flores M, Delbosc B, et al. High-resolution imaging of photoreceptors in healthy human eyes using an adaptive optics retinal camera. *Eye (London, England)*. 2018;**32**(11): 1723-1730

[21] Bedggood P, Metha A. Optical imaging of human cone photoreceptors directly following the capture of light. *PLoS One*. 2013;**8**(11):e79251

[22] Roorda A, Romero-Borja F, Donnelly Iii WJ, Queener H, Hebert TJ, Campbell MCW. Adaptive optics scanning laser ophthalmoscopy. *Optics Express*. 2002;**10**(9):405-412

[23] Godara P, Dubis AM, Roorda A, Duncan JL, Carroll J. Adaptive optics retinal imaging: Emerging clinical

applications. *Optometry and Vision Science*. 2010;**87**(12):930-941

[24] Zhang Y, Rha J, Jonnal R, Miller D. Adaptive optics parallel spectral domain optical coherence tomography for imaging the living retina. *Optics Express*. 2005;**13**(12):4792-4811

[25] Kolb JP, Pfeiffer T, Eibl M, Hakert H, Huber R. High-resolution retinal swept source optical coherence tomography with an ultra-wideband Fourier-domain mode-locked laser at MHz A-scan rates. *Biomedical Optics Express*. 2018;**9**(1): 120-130

[26] Jonnal RS, Kocaoglu OP, Zawadzki RJ, Liu Z, Miller DT, Werner JS. A review of adaptive optics optical coherence tomography: Technical advances, scientific applications, and the future. *Investigative Ophthalmology and Visual Science*. 2016;**57**(9):OCT51-OCT68

[27] Pircher M, Zawadzki RJ. Review of adaptive optics OCT (AO-OCT): Principles and applications for retinal imaging [invited]. *Biomedical Optics Express*. 2017;**8**(5):2536-2562

[28] Nentwich MM, Ulbig MW. Diabetic retinopathy—ocular complications of diabetes mellitus. *World Journal of Diabetes*. 2015;**6**(3):489-499

[29] Wong TY, Sun J, Kawasaki R, Ruamviboonsuk P, Gupta N, Lansingh VC, et al. Guidelines on diabetic eye care: The international council of ophthalmology recommendations for screening, follow-up, referral, and treatment based on resource settings. *Ophthalmology*. 2018;**125**(10):1608-1622

[30] Fletcher EL, Phipps JA, Wilkinson-Berka JL. Dysfunction of retinal neurons and glia during diabetes. *Clinical & Experimental Optometry*. 2005;**88**(3):132-145

- [31] Ding J, Wong TY. Current epidemiology of diabetic retinopathy and diabetic macular edema. *Current Diabetes Reports*. 2012;**12**(4):346-354
- [32] Yau JW, Rogers SL, Kawasaki R, Lamoureux EL, Kowalski JW, Bek T, et al. Global prevalence and major risk factors of diabetic retinopathy. *Diabetes Care*. 2012;**35**(3):556-564
- [33] Stem MS, Gardner TW. Neurodegeneration in the pathogenesis of diabetic retinopathy: Molecular mechanisms and therapeutic implications. *Current Medicinal Chemistry*. 2013;**20**(26):3241-3250
- [34] Nian S, Lo ACY, Mi Y, Ren K, Yang D. Neurovascular unit in diabetic retinopathy: Pathophysiological roles and potential therapeutical targets. *Eye and Vision*. 2021;**8**(1):15
- [35] Abràmoff MD, Lavin PT, Birch M, Shah N, Folk JC. Pivotal trial of an autonomous AI-based diagnostic system for detection of diabetic retinopathy in primary care offices. *npj Digital Medicine*. 2018;**1**(1):39
- [36] Sohn EH, van Dijk HW, Jiao C, Kok PH, Jeong W, Demirkaya N, et al. Retinal neurodegeneration may precede microvascular changes characteristic of diabetic retinopathy in diabetes mellitus. *Proceedings of the National Academy of Sciences of the United States of America*. 2016;**113**(19):E2655-E2664
- [37] Tyrberg M, Lindblad U, Melander A, Lövestam-Adrian M, Ponjavic V, Andréasson S. Electrophysiological studies in newly onset type 2 diabetes without visible vascular retinopathy. *Documenta Ophthalmologica*. 2011;**123**(3):193-198
- [38] Kern TS, Berkowitz BA. Photoreceptors in diabetic retinopathy. *Journal of Diabetes Investigation*. 2015;**6**(4):371-380
- [39] Calderon GD, Juarez OH, Hernandez GE, Punzo SM, De la Cruz ZD. Oxidative stress and diabetic retinopathy: Development and treatment. *Eye (London, England)*. 2017;**31**(8):1122-1130
- [40] Kodl CT, Seaquist ER. Cognitive dysfunction and diabetes mellitus. *Endocrine Reviews*. 2008;**29**(4):494-511
- [41] Friedenwald J, Day R. The vascular lesions of diabetic retinopathy. *Bulletin of the Johns Hopkins Hospital*. 1950;**86**(4):253-254
- [42] Duh EJ, Sun JK, Stitt AW. Diabetic retinopathy: Current understanding, mechanisms, and treatment strategies. *JCI Insight*. 2017;**2**(14):e93751
- [43] Paques M, Meimon S, Rossant F, Rosenbaum D, Mrejen S, Sennlaub F, et al. Adaptive optics ophthalmoscopy: Application to age-related macular degeneration and vascular diseases. *Progress in Retinal and Eye Research*. 2018;**66**:1-16
- [44] Lombardo M, Parravano M, Lombardo G, Varano M, Boccassini B, Stirpe M, et al. Adaptive optics imaging of parafoveal cones in type 1 diabetes. *Retina*. 2014;**34**(3):546-557
- [45] Bek T. Fine structure in diabetic retinopathy lesions as observed by adaptive optics imaging. A qualitative study. *Acta Ophthalmologica*. 2014;**92**(8):753-758
- [46] Cristescu I-E, Ochinciuc R, Balta F, Zagrean L. High-resolution imaging of diabetic retinopathy lesions using an adaptive optics retinal camera. *Romanian Journal of Ophthalmology*. 2019;**63**(1):29-34
- [47] Cristescu IE. Diabetic retinopathy evaluation through high resolution imaging techniques. Bucharest: "Carol Davila" University of Medicine and Pharmacy; 2019

- [48] Zaleska-Żmijewska A, Piatkiewicz P, Smigielska B, Sokolowska-Oracz A, Wawrzyniak ZM, Romaniuk D, et al. Retinal photoreceptors and microvascular changes in prediabetes measured with adaptive optics (rtx1): A case-control study. *Journal Diabetes Research*. 2017;**2017**:4174292
- [49] Rosenbaum D, Mattina A, Koch E, Rossant F, Gallo A, Kachenoura N, et al. Effects of age, blood pressure and antihypertensive treatments on retinal arterioles remodeling assessed by adaptive optics. *Journal of Hypertension*. 2016;**34**(6):1115-1122
- [50] Lombardo M, Parravano M, Serrao S, Ducoli P, Stirpe M, Lombardo G. Analysis of retinal capillaries in patients with type 1 diabetes and nonproliferative diabetic retinopathy using adaptive optics imaging. *Retina*. 2013;**33**(8):1630-1639
- [51] Loganadane P, Delbosc B, Saleh M. Short-term progression of diabetic hard exudates monitored with high-resolution camera. *Ophthalmic Research*. 2019;**61**(1):3-9
- [52] da Fontoura CL, Rocha F, Araújo de Lima SM. Characterizing polygonality in biological structures. *Physical Review E*. 2006;**73**(1):011913
- [53] Costa Lda F, Bonci DM, Saito CA, Rocha FA, Silveira LC, Ventura DF. Voronoi analysis uncovers relationship between mosaics of normally placed and displaced amacrine cells in the thraira retina. *Neuroinformatics*. 2007;**5**(1):59-78
- [54] Obata R, Yanagi Y. Quantitative analysis of cone photoreceptor distribution and its relationship with axial length, age, and early age-related macular degeneration. *PLoS One*. 2014;**9**(3):e91873
- [55] Garrioch R, Langlo C, Dubis AM, Cooper RF, Dubra A, Carroll J. Repeatability of in vivo parafoveal cone density and spacing measurements. *Optometry and Vision Science*. 2012;**89**(5):632-643
- [56] Okabe A, Boots B, Sugihara K, Spatial Tessellations: Concepts and Applications of Voronoi Diagrams. J. Wiley and Sons, Chichester, New York, Brisbane, Toronto and Singapore: Wiley Series in Probability and Mathematical Statistics; 1992
- [57] Li KY, Roorda A. Automated identification of cone photoreceptors in adaptive optics retinal images. *Journal of the Optical Society of America. A, Optics, Image Science, and Vision*. 2007;**24**(5):1358-1363
- [58] Williams DR, Collier R. Consequences of spatial sampling by a human photoreceptor mosaic. *Science*. 1983;**221**(4608):385-387
- [59] Burns SA, Elsner AE, Sapoznik KA, Warner RL, Gast TJ. Adaptive optics imaging of the human retina. *Progress in Retinal and Eye Research*. 2019;**68**:1-30
- [60] Paques M, Meimon S, Grieve K, Rossant F. Adaptive Optics for In-Vivo Exploration of Human Retinal Structures. Munich, Germany: SPIE Optical Metrology; 2017.
- [61] Park SP, Chung JK, Greenstein V, Tsang SH, Chang S. A study of factors affecting the human cone photoreceptor density measured by adaptive optics scanning laser ophthalmoscope. *Experimental Eye Research*. 2013;**108**:1-9
- [62] Chui TY, Song H, Burns SA. Individual variations in human cone photoreceptor packing density: Variations with refractive error. *Investigative Ophthalmology & Visual Science*. 2008;**49**(10):4679-4687
- [63] Lombardo M, Serrao S, Devaney N, Parravano M, Lombardo G. Adaptive

optics technology for high-resolution retinal imaging. *Sensors (Basel)*. 2012;**13**(1):334-366

[64] Curcio CA, Sloan KR, Kalina RE, Hendrickson AE. Human photoreceptor topography. *Journal of Comparative Neurology*. 1990;**292**(4):497-523

[65] Cristescu IE et al. Cone photoreceptor density in type I diabetic patients measured with an adaptive optics retinal camera. *Romanian Journal of Ophthalmology*. 2019;**63**(2):153-160

[66] Sawides L, de Castro A, Burns SA. The organization of the cone photoreceptor mosaic measured in the living human retina. *Vision Research*. 2017;**132**:34-44

[67] Lammer J, Prager SG, Cheney MC, Ahmed A, Radwan SH, Burns SA, et al. Cone photoreceptor irregularity on adaptive optics scanning laser ophthalmoscopy correlates with severity of diabetic retinopathy and macular edema. *Investigative Ophthalmology and Visual Science*. 2016;**57**(15):6624-6632

[68] Cristescu IE, Zagrean L, Balta F, Branisteanu DC. Retinal microcirculation investigation in type I and II diabetic patients without retinopathy using an adaptive optics retinal camera. *Acta Endocrinologica (Bucharest)*. 2019;**15**(4):417-422

[69] Tan W, Wright T, Rajendran D, Garcia-Sanchez Y, Finkelberg L, Ksilak M, et al. Cone-photoreceptor density in adolescents with type 1 diabetes. *Investigative Ophthalmology and Visual Science*. 2015;**56**(11):6339-6343

[70] Zaleska-Żmijewska A, Wawrzyniak ZM, Dąbrowska A, Szaflik JP. Adaptive optics (rtx1) high-resolution imaging of photoreceptors and retinal arteries in patients with diabetic retinopathy. *Journal Diabetes Research*. 2019;**2019**:9548324

[71] Fuller S, Rodriguez RZ, Carrasco M. Apparent contrast differs across the vertical meridian: Visual and attentional factors. *Journal of Vision*. 2008;**8**(1):1-16

[72] Smits MM, Tonneijck L, Muskiet MH, Hoekstra T, Kramer MH, Diamant M, et al. GLP-1-based therapies have no microvascular effects in type 2 diabetes mellitus: An acute and 12-week randomized, double-blind, Placebo-Controlled Trial. *Arteriosclerosis, Thrombosis, and Vascular Biology*. 2016;**36**(10):2125-2132

[73] Yu PK, Balaratnasingam C, Cringle SJ, McAllister IL, Provis J, Yu DY. Microstructure and network organization of the microvasculature in the human macula. *Investigative Ophthalmology & Visual Science*. 2010;**51**(12):6735-6743

[74] Huang F, Dashtbozorg B, Zhang J, Bekkers E, Abbasi-Sureshjani S, Berendschot TT, et al. Reliability of using retinal vascular fractal dimension as a biomarker in the diabetic retinopathy detection. *Journal of Ophthalmology*. 2016;**2016**:6259047

[75] Rizzoni D, Agabiti RE. Small artery remodeling in hypertension and diabetes. *Current Hypertension Reports*. 2006;**8**(1):90-95

[76] Laurent S, Boutouyrie P. The structural factor of hypertension: Large and small artery alterations. *Circulation Research*. 2015;**116**(6):1007-1021

[77] Gliemann L, Buess R, Nyberg M, Hoppeler H, Odriozola A, Thaning P, et al. Capillary growth, ultrastructure remodelling and exercise training in skeletal muscle of essential hypertensive patients. *Acta Physiologica (Oxford, England)*. 2015;**214**(2):210-220

[78] Schiffrin EL. Remodeling of resistance arteries in essential hypertension and effects of

antihypertensive treatment. *American Journal of Hypertension*. 2004;**17** (12 Pt 1):1192-1200

[79] Izzard AS, Rizzoni D, Agabiti-Rosei E, Heagerty AM. Small artery structure and hypertension: Adaptive changes and target organ damage. *Journal of Hypertension*. 2005;**23**(2):247-250

[80] Rizzoni D, Porteri E, Guelfi D, Muiesan ML, Valentini U, Cimino A, et al. Structural alterations in subcutaneous small arteries of normotensive and hypertensive patients with non-insulin-dependent diabetes mellitus. *Circulation*. 2001;**103**(9): 1238-1244

[81] De Ciuceis C, Caletti S, Coschignano MA, Rossini C, Duse S, Docchio F, et al. [OP.8C.03] comparison between three non-invasive techniques of evaluation microvascular morphology vs. the gold-standard locally invasive micromyography. Preliminary data. *Journal of Hypertension*. 2017;**35**:e90

[82] Viridis A, Savoia C, Grassi G, Lembo G, Vecchione C, Seravalle G, et al. Evaluation of microvascular structure in humans: A 'state-of-the-art' document of the working group on macrovascular and microvascular alterations of the Italian society of arterial hypertension. *Journal of Hypertension*. 2014;**32**(11):2120-2129, discussion 9

[83] Arichika S, Uji A, Murakami T, Suzuma K, Gotoh N, Yoshimura N. Correlation of retinal arterial wall thickness with atherosclerosis predictors in type 2 diabetes without clinical retinopathy. *The British Journal of Ophthalmology*. 2017;**101**(1):69-74

[84] Ueno Y, Iwase T, Goto K, Tomita R, Ra E, Yamamoto K, et al. Association of changes of retinal vessels diameter with ocular blood flow in eyes with diabetic retinopathy. *Scientific Reports*. 2021;**11**(1):4653

[85] Baltă F, Cristescu IE, Mirescu AE, Baltă G, Tofolean IT. Effect of a multinutrient complex on retinal microcirculation in diabetic patients investigated using an adaptive optics retinal camera. *Acta Endocrinologica (Bucharest)*. 2020;**16**(4):389-395