

# We are IntechOpen, the world's leading publisher of Open Access books Built by scientists, for scientists

6,900

Open access books available

186,000

International authors and editors

200M

Downloads

Our authors are among the

154

Countries delivered to

TOP 1%

most cited scientists

12.2%

Contributors from top 500 universities



WEB OF SCIENCE™

Selection of our books indexed in the Book Citation Index  
in Web of Science™ Core Collection (BKCI)

Interested in publishing with us?  
Contact [book.department@intechopen.com](mailto:book.department@intechopen.com)

Numbers displayed above are based on latest data collected.  
For more information visit [www.intechopen.com](http://www.intechopen.com)



# Types of Skin Grafts

*Verónica Olvera-Cortés*

## Abstract

Skin grafting is a useful technique that has been used for a very long time for achieving closure of wounds when it cannot occur in a natural conventional manner. There are different types of grafts according to their origin, thickness and form. There are 3 main types of grafts that are used to cover wounds: Split-thickness skin grafts, full-thickness skin grafts and composite grafts. Each of them has specific indication and has a unique technique for harvesting. If the graft is not taken care of properly its survival can be compromised and necrosis of the graft can occur. Even though complications may present, skin grafting is still considered a practical approach to repair many type of wounds.

**Keywords:** Graft, Skin, Non melanoma skin cancer, surgery, treatment

## 1. Introduction

A skin graft is a piece of skin of variable thickness without any vascular connection, separated from the donor site, and afterwards transposed over the recipient site which is to be repaired [1].

This technique was used initially in India about 2.500–3.000 years ago by Tilemaker Caste. It was later rediscovered in the XIX century and was the most used technique during World War I and II. And in 1823 Buenger was the first to describe a successful intervention by transferring skin from the buttock to the nose [1]. It is a basic technique and an option of reconstruction after a tumor resection, in case of ulcers and burned patients [1].

Skin graft execution is simpler than most skin flaps and can be performed in almost any wound with a vascularized bed. One of the great advantages of skin grafts is that they are very variable in size and shape to allow wound closure of wound defects of different sizes. There are many sites that can be donor sites making it easier for the skin to match.

## 2. Indications

Wound closure should always follow the principles of the reconstructive ladder, which directs the surgeon to use the least complex method of closure to achieve an ideal cosmetic result [2].

Often a graft may be used when healing of a full thickness wound by second intention, a primary closure, or utilization of a local flap are not feasible options [3].

In some instances, grafts can be used in combination with linear repairs or flaps for skin reconstruction surgery. In addition, skin grafts can be used for shallow defects, or in a patient with multiple morbidities who cannot tolerate a more complex or multi-stage repair [4].

3. Classification

There are many ways in which skin grafts can be classified, based on their origin, thickness, composition, time in which they are performed, geometry and if it meshed or not (**Table 1**).

According to their origin, skin grafts can be divided in 3: Autografts, allografts and xenografts.

Autografts are taken from the patient’s own skin, and they are the most common used skin grafts.

Allografts come from another person’s skin. And xenografts are derived from another species, other than human skin, for example porcine grafts. Both allografts and xenografts are used in chronic wounds or burn wounds. Their utility comes from their ability to stimulate wound healing, provide protection and achieve debridement [3].

In terms of thickness, they are distinguished as: Split-thickness skin grafts and full-thickness skin grafts [1] and composite grafts.

Split-thickness skin grafts are composed by epidermis and a variable thickness of dermis. They can be subdivided in 3 [1]:

- Thin: 0.15–0.25 mm
- Intermediate: 0.3–0.4 mm
- Thick: 0.5–0.6 mm

Full-thickness skin grafts are composed of epidermis and dermis with skin appendages [1].

The amount of dermis in the skin graft determines many properties of the graft, such as resistance to pressure and shear forces, shrinkage, sensitivity and esthetic results. In other words, the thicker the graft the better mechanical, functional and aesthetic properties, but also this means that the neo and revascularization of the graft will be more difficult.

If the graft includes other tissue besides skin it is a composite graft. Composite grafts are made by two different tisular structures, skin and cartilage most of the cases [1].

According to the moment in time in which the graft is realized [1]:

Character	Types
Origin	1. Autograft 2. Allograft 3. Xenograft
Thickness	1. Split thickness 2. Full thickness 3. Composite
Time	1. Immediate 2. Differed
Expansion	1. Sheet graft 2. Meshed graft

**Table 1.**  
*Classification of skin grafts.*

**Immediate:** Realized just after the resection of the tumor. To repair the loss of substance.

**Differed:** The graft is performed in a second intervention, in order to have the confirmation of clean margins. This approach is justified for aggressive tumors and tumor relapse, to obtain granulation tissue when the surgery is extensive in depth and/or width, and exceptionally when hemostasis of the recipient site cannot be achieved [1].

Another way to classify skin grafts is based if a technique is used to expand the graft itself. If the skin graft is directly applied onto the defect without further treatment this is called an unmeshed or sheet graft [5].

A mesh graft is when multiple slits are made on the graft. Usually this is made with a mechanical mesher and it is common to apply this on split-thickness skin grafts. Meek graft is a skin graft that is cut in stripes, equal in length and width. It used a cork plate and a machine with rotating blades. Punch grafts are obtained using a punch, which allows to obtain multiple full-thickness skin grafts, it is a useful technique to cover large wound areas.

#### 4. Physiology

The survival of skin grafts is a complex process that involves different phases. In order to understand them it is necessary to remember how the skin is irrigated.

Skin consists of 2 basic layers, the epidermis and dermis. The dermis is divided into a papillary and reticular layer. Within the dermis resides the skin's neurovascular supply. The subcutaneous tissue beneath the skin contains the superficial fascia and subcutaneous fat [6].

The skin vasculature consists of a deep dermal/subcutaneous plexus and a superficial plexus [6]. Both plexi are connected via communicating vessels. The superficial plexus can be found in the reticular dermis, near its junction with the papillary dermis. The deep plexus, located in the subcutaneous tissue, consists of an extensive venous plexus, capable of holding large quantities of blood and an accompanying artery. The deep plexus supplies vessels to the pilosebaceous units and the superficial plexus. Arteriovenous anastomoses also exist in the region [6, 7]. The superficial plexus originates vascular loops within the papillary dermis. Nutrients diffuse into the epidermis because no vessels cross the dermal-epidermal junction. Venous and lymphatic systems exist in a similar arrangement [6].

Unlike flaps, grafts depend on the ingrowth of capillaries from the recipient site for their ultimate survival [8].

For the first 24–48 hours, the graft initially derives oxygen and nutrients from the underlying bed by diffusion (plasmatic diffusion or imbibition). The graft can increase in weight by up to 40%. During imbibition, the graft and the wound bed are held together via a layer of fibrin. The fibrin is eventually replaced by granulation tissue [2, 3, 8].

The second phase, inosculation, is defined by an anastomosis of the preexistent vessels of the graft and the wound base. This phase occurs during the second and third postoperative days [3].

For graft-take to occur, the recipient site must be capable of producing capillary buds. Since capillary outgrowth is needed both to produce granulation tissue and to nourish a skin graft, areas that granulate well (muscle and deep fascia), accept grafts readily. Other surfaces, such as tendon denuded of its fascia covering, exposed bone, or cartilage, are incapable of producing granulation tissue and, therefore, are unable to nourish a skin graft [9].

Also the skin graft must remain in close approximation to the recipient bed during the phase of capillary ingrowth. The presence of air, serum, or fluid between the graft and recipient bed creates a barrier through which the capillaries cannot grow fast enough to prevent necrosis of the graft [9].

Revascularization involves the growth, proliferation, and connection of vessels from the recipient base and sidewalls. The rate of revascularization is dependent on the thickness of the graft and the vascularity of the recipient bed. As a general rule, the thinner the skin graft, the faster it establishes a blood supply [9].

Within 4 to 7 days, full circulation has been restored to the graft. Restoration of lymphatic circulation also occurs within 7 days. Reinnervation of the graft begins approximately 2 to 4 weeks after grafting; however, full sensation may require several months or even years to return to normal [8].

## **5. Technique**

### **5.1 Split-thickness skin grafts (STSG)**

STSG are indicated for large defects (>5 cm), slow- or nonhealing chronic wounds, or as a temporary cover when monitoring a wound bed for potential cancer recurrence [3, 10].

This type of skin graft is useful when the definitive reconstruction of a wound is delayed, either for surveillance of an aggressive cancer or when granulation tissue is needed on the bed of the recipient site.

Donor site selection is based on the size of the graft needed to cover the wound, the patient's ability to care for the donor site and how the donor site wound would affect the patient's daily activities (walk, sit, sleep). Taking all this in consideration the medial and lateral thighs are most used for donor site. Also it is practical to consider donor sites that can be hidden under clothing, such as the medial or lateral upper arm, abdomen, back and buttocks. Donor sites that offer large flat surfaces also facilitate the harvesting of STSGs [11].

Once the donor area has been selected, it should be shaved of all hair to aid in the harvesting and handling of the skin graft [8].

The donor site should be prepared and draped in the normal sterile fashion and local anesthesia may be infiltrated [4]. If the graft requirement is significant, saline may be infiltrated instead of local anesthesia to make the graft harvesting easier.

STSG may be harvested using a dermatome or the freehand technique, depending on the size of graft needed and location of the recipient site [3].

There are many electric dermatomes available (e.g. Davol, Padgett, Zimmer), all of them with adjustable graft width and thickness.

After marking the dimensions of the graft (mark the skin graft 15–20% larger than needed and thus allow for shrinkage), the skin is lubricated with sterile ointment. The assistant surgeon should keep the skin flat and stretched by counter-tension [12].

The dermatome is held at a 30° to 45° angle, and advanced, from proximal to distal, while traction is maintained on the skin. Toothless forceps are used to prevent the graft from getting snared, and the dermatome is lifted away while still engaged [10–12].

After the STSG is obtained it is transferred to a sterile-saline soaked gauze to keep it moist. Attention must be paid in order not to confuse the dermal and epidermal surface when handling the skin graft. A useful tip is to remember that the dermal surface glistens more than the epidermal side and also the edges of the graft will curve to the dermal surface.



Meshing the STSG allows the graft to cover a wound that is larger in dimensions than the unmeshed STSG. Meshing increases the coverage area by 25–35% and also increases the flexibility of the graft so it can be used over mobile surfaces such as joints [4].

It also provides fenestrations in the skin graft that allow the egress of fluid from the wound bed, which minimizes the chance of seroma or hematoma formation and subsequent graft failure. Mechanical meshing of grafts is recommended when they are being used to cover defects >8 cm in diameter or when extensive serosanguineous drainage is anticipated [4].

Meshing can be accomplished in a variety of ways, but the most common and efficient method is to use a hand-powered mechanical mesher to produce multiple uniform slits in a skin graft, approximately 0.05 inches apart. The skin to be meshed is placed on a carrier with the dermis side up and spread over the carrier. The graft is then passed through the mesher. It is then covered with moist saline gauze. Split thickness grafts can be meshed to obtain expansion from 1:1 upto 1:4. In case of paucity of donor site and large recipient area the graft can be meshed to achieve expansion of 1:9. The survival of such widely meshed graft can be improved by covering it with 1:3 meshed allograft. This method is called sandwich grafting. Xenograft can also be used for this purpose. The disadvantages of meshing include suboptimal cosmesis and delay in ultimate closure of the grafted site [2, 8].

The donor site should be temporarily covered with gauze soaked in 1% lidocaine with epinephrine while attention is quickly turned back to the graft. The epinephrine in the solution promotes hemostasis in this acute, abrasion-like donor site [4].

The recipient site must be prepared before the placement of the STSG. Since there must be close contact between the skin graft and wound bed, a good hemostasis should be done in order to prevent hematoma formation. If the wound bed has granulated tissue all the fibrinous debris have to be removed.

When the STSG is placed over the recipient site sometimes it needs to be cut to fit the size of the wound. After the graft is trimmed it has to be attached to initiate contact between the graft and the wound bed. In order to achieve this a tie-over dressing is used. First apply an antibiotic impregnated gauze on the graft, after a foam dressing or sponge is put over the gauze, put single sutures around the defect and leave long tails of the sutures, this long tails will be tied over the dressing or sponge.

Attention is subsequently turned to the donor site, which is best treated as a superficial abrasion. Further hemostasis is usually not necessary. A moist occlusive dressing is applied, making use of antibiotic ointment or petrolatum and a nonadherent dressing such as polymer film [4].

The donor site presents important drainage during the first 48 hrs, this is a normal process and it is important to inform the patient. In order to avoid fluid collection the dressing can be punctured at the site to allow drainage or the dressing can be changed more frequently.

In the postoperative period the most important part is to minimize all physical activity. Since any abrupt or strong movement may affect the graft, shearing forces can be created and the graft itself may be damaged or bleeding from the wound bed can occur. Separation of the graft from the recipient site compromises its vascularization and eventually its survival. This is why the patient is advised to elevate the intervened area and restrict all physical efforts.

The manipulation of the dressings should be kept at minimum in order to avoid contamination or involuntary movement that may disrupt the process of revascularization of the graft, which takes about 3 to 5 days.

After wound healing is achieved it is important to advise the patient to avoid sunshine and to use sun-blocking agents to prevent hyperpigmentation, use a greasy ointment to reduce dryness and itching [12].

The advantages of using this type of skin graft are: Very easy and fast harvesting, provides good color match in most cases, they may be obtained from any area of the body, provides skin for large defects [12].

The disadvantages of this type of grafts are: Graft contraction and hyper-pigmentation (Split thickness grafts will contract 10–20% immediately after harvest and up to 20–50% over time), fixation may be inadequate, leading to shearing and wound dehiscence, cannot be used on exposed tendon, nerves, cartilage, or bone, development of hematoma or seroma may lead to poor vascularization of the graft, in case of wound infection, skin graft may turn necrotic within 24 h [2, 12].

## **5.2 Full-thickness skin grafts (FTSG)**

FTSG are very useful in dermatologic surgery, especially after the removal of a skin cancer, areas that are conducive to FTSG include nasal ala and tip, helix, medial canthus, lower eyelid, digits, and extremities. FTSG should be limited to less than 5 cm [3].

In order to maximize cosmesis, various factors must be taken into account when choosing a site to harvest, including photodamage, color, existing adnexal structures (hair), and the appearance of the donor site scar. Donor skin should be devoid of malignant lesions or any changes that might later be confused for recurrence of malignancy. Commonly used sites for FTSG are: pre- and postauricular regions, creases of the upper eyelids, nasolabial folds, supraclavicular region, lateral neck, antecubital fossa, and groin [3, 8].

Once the appropriate donor site has been chosen, anesthetized, cleansed, and prepared for harvest, a template of the defect is made by using gauze, cardboard labels, or foil from suture packaging. The template is then transposed to the donor site.

The skin graft will contract at the recipient site, for this reason it is important to make the template 10–20% bigger in order to avoid distortion of the anatomy of the area that was intervened. When eyelid defects are closed using a skin graft the template needs to be oversized more so that ectropion will not develop.

Full thickness grafts should be harvested at the level just deep to the dermis, not down to fascia, as the graft will need to be thinned [2]. Once the graft is obtained, all the subcutaneous tissue must be removed using curved iris scissors. Remove the adherent fat by putting the graft under tension. Roll the graft over your forefinger and pull it down with your middle finger and thumb [12]. The goal is to expose the dermis. Since any remaining fat will obstruct the imbibition phase.

Remoistening the graft periodically with sterile saline or local anesthetic during the defatting procedure is recommended to prevent desiccation [11].

Before placing a skin graft, the recipient site must be clean and not actively bleeding [8].

After placing the graft in the recipient site it needs to be fixated with sutures. Optimal suturing technique is with the needle entering the graft first, 2–3 mm from the edge, and then exiting in the adjacent recipient site skin and subsequently tied with 3–4 throws of a square knot. Distance between sutures is usually 3–4 mm [4] (**Figures 1 and 2**).

It is important to place sutures sufficiently deep such that both the papillary and reticular dermis of the graft and recipient site are directly aligned with each other. Suturing that is too superficial apposes only the papillary dermis, leaving a dead space in the deeper reticular dermis which tends to retract more than the superficial papillary dermis. This increases the risk of both hematoma formation and a depressed, more visible scar. Excessively superficial suturing has also been implicated as a potential etiology of graft pin-cushioning [4].

Bolsters are used to stabilize and protect the graft and to provide a uniform pressure dressing to the grafted area. Bolster materials include saline-soaked dental rolls, saline-soaked gauze, and mineral oil-soaked cotton balls. The bolsters should have a nonstick surface and should be fitted to the size of the graft. They are secured with simple interrupted sutures using 4–0 silk are placed in pairs directly across from one another 2–3 mm from the graft margins. Bolsters are left in place for 5 to 7 days [3, 10].

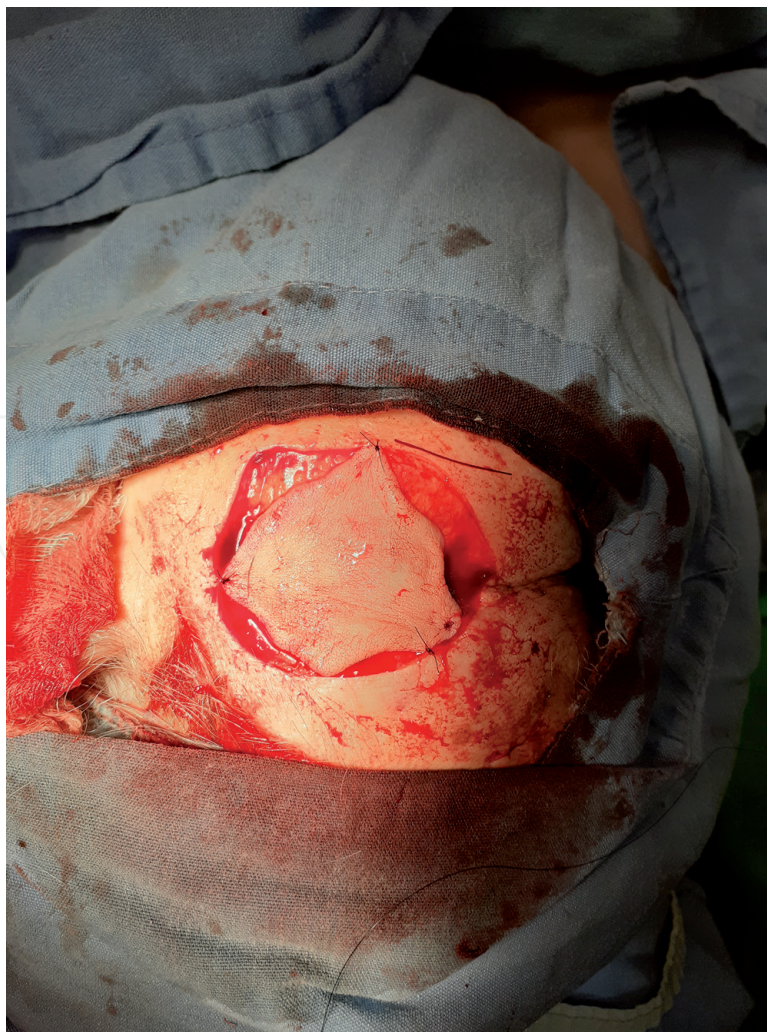The donor site is repaired later after the graft has been placed as it is important to allow nutrient diffusion to the graft to begin [3].

During the postoperative period the use of antibiotic ointment is recommended for the recipient and donor site in order to avoid infection. Also the dressing in the recipient site has to be checked every day for one week and every 2 to 3 days at the donor site. Both areas have to be cleaned with saline solution. The sutures can be removed after 7–8 days.

Development of pink color during 3 to 7 days signals neovascularization and successful graft take. Over the ensuing 1 to 2 months, pink color diminishes, but the graft may remain lighter than surrounding skin (**Figures 3 and 4**) [10].

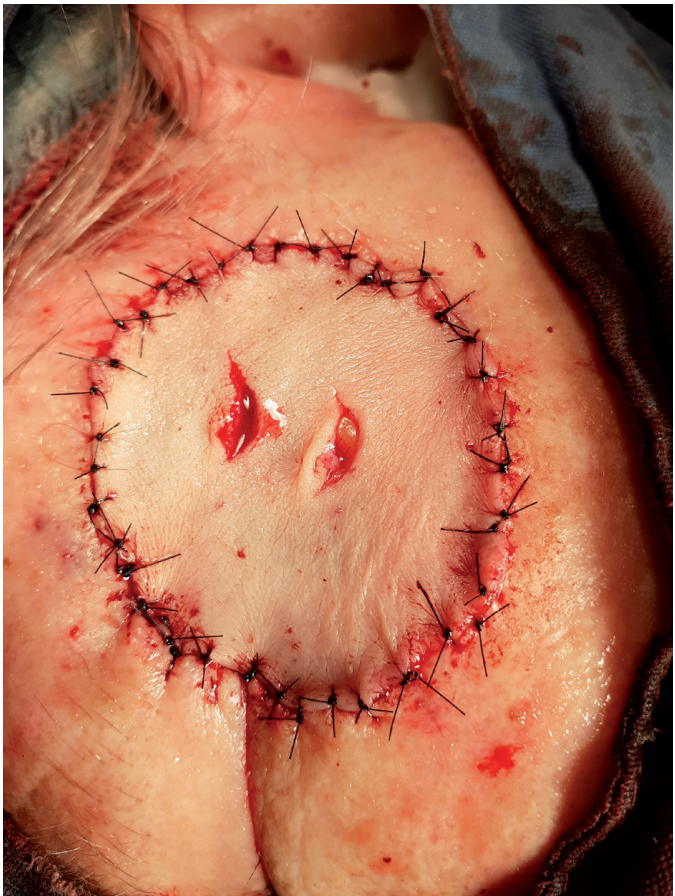The advantages of this technique are: easy and rapid harvesting, provides excellent color match and adequate thickness of the skin, a small scar remains after skin harvesting and primary closure of the donor site [12].

The disadvantages of this type of grafts are: limited size of skin for harvesting, donor site will require STSG when primary closure is not possible [12].

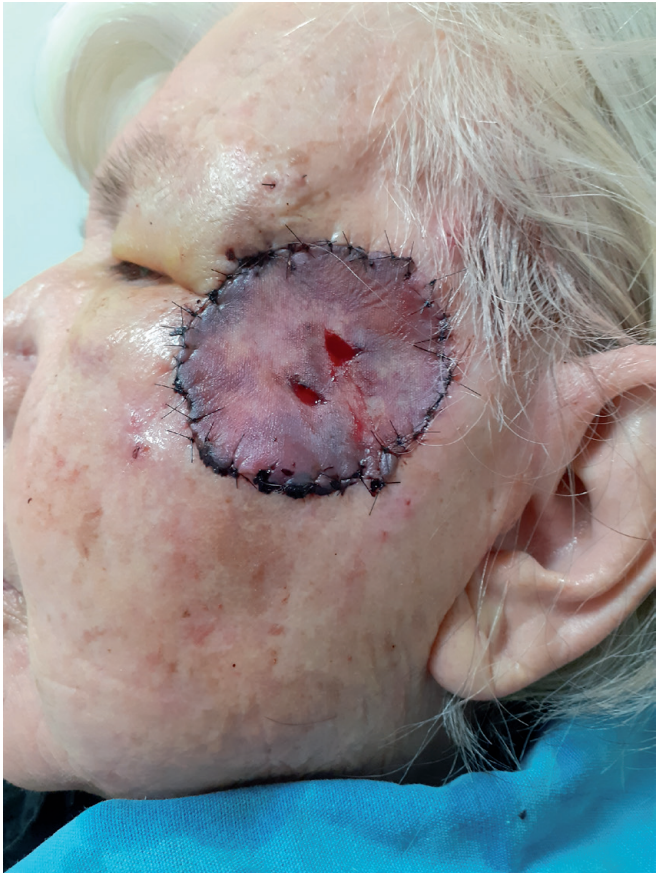

**Figure 1.**  
*Initial attachment of the Full-skin graft.*

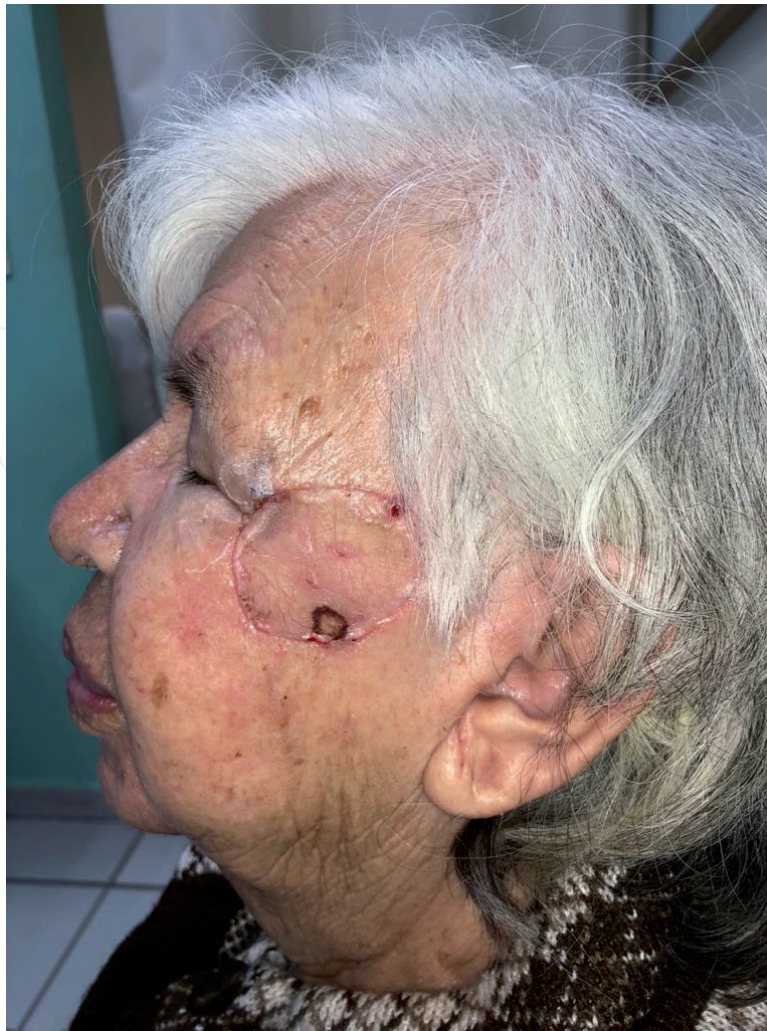



**Figure 2.**  
*Complete placement of sutures attaching the FSG.*



**Figure 3.**  
*Full-skin graft appearance after removing the bolster (48 hrs),*



**Figure 4.**  
*Full-skin graft appearance at one month after the surgery.*

### 5.3 Composite grafts

This type of graft consists of two different type of tissues. Mostly cartilage with or without subcutaneous tissue and the overlying skin. Because they offer support and structure composite grafts are used to repair full-thickness defects of the nasal ala and helical rim. The size of the defect for this type of graft is 1 cm or less.

They can also be used to fill partial-thickness defects that extend too deeply for a full-thickness skin graft to heal without leaving a concavity or contraction of the free margin [13].

The metabolic needs of composite grafts differ from the needs of skin grafts, the former have greater demands and needs rapid revascularization in order to survive. The blood flow formed by the anastomoses between the wound bed and composite graft can extend only to a small portion beyond the margin of the graft. Portions of the graft that are beyond 1 cm from the vessel anastomoses is at risk of not receiving appropriate blood flow and is at risk of necrosis.

Its survival depends on passive diffusion of oxygen and nutrients through the perichondrium from adjacent vascularized tissue. The vascularity of the recipient bed is also a consideration. The nasal ala is generally well supplied with blood vessels and can usually support composite grafts [13].

Because the cartilage in these grafts carries with it the skin that will cover the cutaneous portion of the defect, the donor site should be chosen so that the texture, color, and nature of appendages match as best as possible the features of the recipient site [13].



The ear exhibits a wide range of thicknesses, curvatures, and appendage-type structures [13]. Composite auricular grafts harvested from the helical crus are particularly useful, because they provide thin skin that is tightly adherent to the underlying cartilage. The graft affords structural support and resembles fine nasal skin being reconstructed [10].

First, the recipient site is measured and the donor site marked such that the composite graft will be approximately 5–10% larger than the defect. This oversizing will compensate for the natural shrinkage of the graft that occurs during healing [13].

Once the donor site has been closed, the graft is prepared. Using a pair of curved iris scissors, the skin is trimmed from the wings to expose the underlying cartilage. The remaining cartilaginous pegs should frame the lateral aspects of the graft [13]. A hemostat or scissors may be used to undermine pockets on each side of the defect. These pockets should run parallel to the alar or helical rim and should only be deep enough to accommodate the cartilaginous pegs of the composite graft. And the cartilaginous pegs are gently inserted into these pockets so that the graft interlocks with its recipient bed [13].

The graft is secured in place with a single layer of suture through skin and perichondrium, minimizing sutures passing through cartilage. Limiting sutures and graft trauma facilitates robust vessel ingrowth [10].

Antibiotic-impregnated gauze should be placed in the patient's nostril to stabilize the alar rim. A pressure dressing or bolster should be used to stabilize the graft [13].

In the postoperative period, the intranasal gauze needs to stay for 24–48 hrs and then removed so that the wound can be cleaned. Any activity that may elevate the patient's blood pressure has to be avoided. The sutures can be removed after 7 days.

Composite grafts change their color during the following days after the procedure. At first the graft will be pallid because of the lack of blood flow. After 6 hrs it changes color to lightly pink, representing the beginning of the vessel anastomoses. The next 24–48 hrs the graft becomes blue because of venous congestion that follows, and will remain like this for a week, until venous drainage begins. Later it will become pink and this indicates adequate blood flow and graft survival. The pink color will increase in the next days reaching a red color as the healing process continues. After 2 to 6 months later the red color will disappear. The final tone can be achieved after 1 or 2 years.

## **6. Complications**

All types of grafts can present complications that may compromise its survival.

Complete or partial graft failure is the primary complication seen with FTSGs. Causes for failure include hematoma, graft-bed contact disruption, infection, smoking, and excessive electrocoagulation of the wound base [8].

If the skin graft develops necrosis it should not be debrided, the necrotic tissue serves as a natural dressing that allows new skin formation under it. There can be some contour alterations made by the healing process, specially on the nose (elevation), that can improve by themselves in a period of 6 months, if after that period the alterations remain dermabrasion or intralesional steroids can be used.

The acute complications of STSG are the same of those presented by FTSG (hematoma, seroma, graft movement). Long term complications of STSG are related to skin graft contraction that may distort free margins, impair function, develop graft fragility or alter the final aesthetic result.

If infection of the graft is suspected or developed a skin culture needs to be performed and proper antibiotics should be given.

In composite grafts short-term potential complications, include bleeding, infection, and necrosis of the graft. This last complication presents initially as a yellowish whiteness that remains and then is followed by the appearance of a black eschar.

Should the graft become necrotic, the eschar should not be debrided. The necrosis may only be superficial, with the underlying dermis and cartilage still viable [13].

Long term complications of composite grafts are consequence of an inappropriate anchorage of the graft to the recipient site, trauma or extreme contractural forces, all of which can cause displacement or deformation of the graft.

## 7. Conclusions


Since their initial use almost 3.000 years ago skin grafts have been a very useful option for wound repair. Whether it is due to an ulcer, burn or surgery, wound closure can be accomplished via skin grafts in any of their modalities. Skin grafts offer a very useful alternative for reconstruction that can be applied to almost any site of the body. It is imperative to select an adequate donor site to offer the best match possible. The process and technique of each type of graft is easy to perform. And with the correct sterile and surgical technique the possibility of complications is minimized. This type of wound management should not be considered as a last resort, since their advantages outweigh the disadvantages.

## Author details

Verónica Olvera-Cortés  
Instituto Mexicano del Seguro Social, Ciudad de México, Mexico

\*Address all correspondence to: [dra.veronica.olvera@gmail.com](mailto:dra.veronica.olvera@gmail.com)

## IntechOpen

© 2021 The Author(s). Licensee IntechOpen. This chapter is distributed under the terms of the Creative Commons Attribution License (<http://creativecommons.org/licenses/by/3.0>), which permits unrestricted use, distribution, and reproduction in any medium, provided the original work is properly cited. 



## References

- [1] Blatière V. Injertos cutáneos: injertos de piel de grosor variable y total. *EMC Dermatología*. 2021;55(1):1-17.
- [2] Jensen AR, Klein MB, Ver Halen JP, Wright AS, Horvath KD. Skin Flaps and Grafts: A Primer for the National Technical Skills Curriculum Advanced Tissue-Handling Module. *J Surg Educ*. 2008;65(3):191-199.
- [3] Leal-Khoury SM and Grummer SE. Skin Grafting. In: Nouri K. *Mohs Micrographic Surgery*. 1st ed. Springer-Verlag London. 2012. p. 433-442.
- [4] Acosta AE, Aasi SZ, MacNeal RJ, Messingham MJ, Arpey CJ. Skin Grafting. In: Robinson JK, Hanke CW, Siegel DM, Fratila A. *Surgery of the Skin: Procedural Dermatology*. 3rd ed. Saunders Publishing. 2015. p.306-323.
- [5] Hierner R, Degreef H, Vranckx JJ, Garmyn M, Massagé P, Van Brussel M. Skin grafting and wound healing—the “dermato-plastic team approach”. *Clin Dermatol*. 2005;23:343-352.
- [6] Losquadro WD. Anatomy of the Skin and the Pathogenesis of Nonmelanoma Skin Cancer. *Facial Plast Surg Clin N Am*. 2017;25:283-289.
- [7] Ablove RH, Howell RM. The Physiology And Technique Of Skin Grafting. *Hand Clin*. 1997;13(2):163-173.
- [8] Adams DC, Ramsey ML. Grafts in Dermatologic Surgery: Review and Update on Full- and Split-Thickness Skin Grafts, Free Cartilage Grafts, and Composite Grafts. *Dermatol Surg*. 2005;31:1055-1067.
- [9] Lyons RJ. Promoting healing of skin flaps and grafts. *AORN Journal*. 1982;35(6):1174-1176.
- [10] Brenner MJ, Moyer JS. Skin and Composite Grafting Techniques in Facial Reconstruction for Skin Cancer. *Facial Plast Surg Clin N Am*. 2017;25:347-363.
- [11] Zhang AY, Meine JG. Flaps and Grafts Reconstruction. *Dermatol Clin*. 2011;29:217-230.
- [12] Erovic BM, Lercher P. Skin Graft Harvesting. In: Erovic BM, Lercher P. *Manual of Head and Neck Reconstruction Using Regional and Free Flaps*. 1st ed. Springer-Verlag Wien. 2015. p. 53-60.
- [13] Adams C, Ratner D. Composite and free cartilage grafting. *Dermatol Clin*. 2005;23:129-140.