

# We are IntechOpen, the world's leading publisher of Open Access books Built by scientists, for scientists

6,900

Open access books available

186,000

International authors and editors

200M

Downloads

Our authors are among the

154

Countries delivered to

TOP 1%

most cited scientists

12.2%

Contributors from top 500 universities



WEB OF SCIENCE™

Selection of our books indexed in the Book Citation Index  
in Web of Science™ Core Collection (BKCI)

Interested in publishing with us?  
Contact [book.department@intechopen.com](mailto:book.department@intechopen.com)

Numbers displayed above are based on latest data collected.  
For more information visit [www.intechopen.com](http://www.intechopen.com)



# Intraoperative Ultrasound in Colorectal Surgery

*Sinziana Ionescu*

## Abstract

Intraoperative ultrasound (IOUS) in colorectal surgery can be used both in benign and in malignant lesions. In benign cases, such as Crohn's disease and diverticulitis, it can orient toward the extension of the surgical intervention. In malignant cases, such as colorectal cancer with liver metastases, IOUS/CE-IOUS (contrast-enhanced) improved the intraoperative management of liver metastases by dictating the resection margins in relation to the tumor extension. The IOUS method allows for exact tumor location, intestinal wall visualization, and malignant tumor penetration. The IOUS revealed the tumor and its margin in rectal lesions, making the sphincter-sparing operation easier to perform. In patients with small polyps and early colon and rectum cancers, IOUS works well as a one-of-a-kind intraoperative localization technique. In comparison with IOUS, CE-IOUS offered better detection and resection guidance. Intraoperative ultrasound enables surgeons to easily localize small, non-palpable lesions of the large bowel. Furthermore, it can determine even the aggressive potential of these lesions with high precision.

**Keywords:** colorectal, intraoperative ultrasound, laparoscopic ultrasound, colorectal surgery, robotic ultrasound

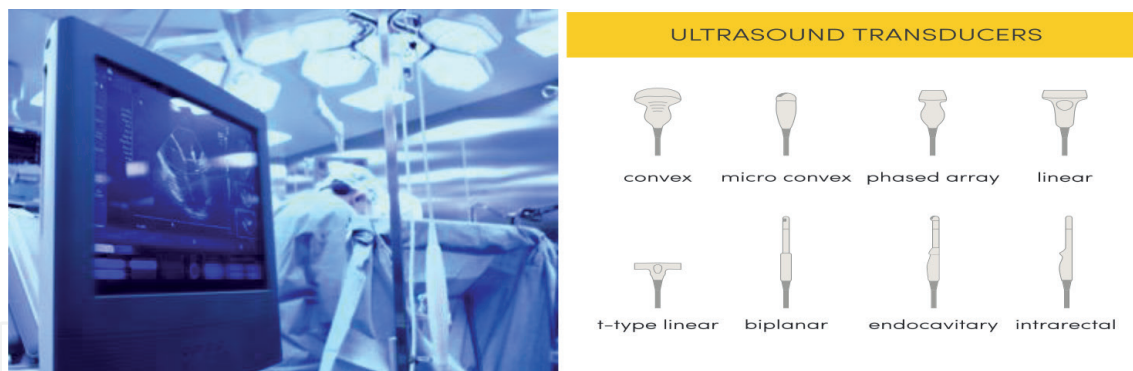
## 1. Introduction

Intraoperative ultrasound is a complex and highly interactive imaging study field that is one of the ultrasonography's fastest growing fields. Intraoperative ultrasound has a wide spectrum of uses, which are expanding all the time.

Intraoperative ultrasound is used effectively in neurosurgery to operate on the brain and spinal cord, and it is mostly used in intra-abdominal surgery to operate on the liver, biliary tract, and pancreas.

Intraoperative vascular surgical disease assessment and intraoperative ultrasound imaging can also guide endarterectomy interventions. In patients with colorectal liver metastases, liver resections with negative margins increase survival (CRLM).

Intraoperative ultrasound (IOUS) is a useful tool that provides information about liver lesions, allowing surgeons to adjust their surgical technique to ensure total removal and, as a result, increase disease-free survival (DFS). Another important use of intraoperative ultrasound in colorectal surgery is to localize lesions at the level of the colon and of the rectum in order to properly adjust the extension of the resection (**Figure 1**).



**Figure 1.**  
*Intraoperative monitor of ultrasound and various types of ultrasound probes.*

## 2. General characteristics of intraoperative ultrasound

### 2.1 Intraoperative ultrasound in open surgery

Intraoperative ultrasonography (IOUS), according to Machi and coauthors [1] can provide a wide range of diagnostic information that would otherwise be unavailable or unavailable, as well as a guide or help with various surgical procedures in real time. With the technical development of the proper equipment, IOUS is currently used in a wide variety of surgical interventions, such as hepato-biliary, pancreatic, endocrine, cardiovascular, and neurologic surgeries. Among its numerous advantages, we underline safety, quickness, accuracy, and versatility. Therefore, IOUS is a valuable technique that surgeons are recommended to master to improve intraoperative decision-making. Furthermore increasing the attention for details, ultrasound Doppler allows the user to visualize blood flow and can assess the blood supply in and near the area of interest, thus avoiding injury to important vessels during dissection, as found by Vapenstad and collab [2]. Various intraoperative transducers are available for use, as mentioned by Marcal and team [3] in abdominal surgery: Linear array, curvilinear array, and phased array IOUS transducers are made available by different vendors. One of the most important criteria is that the probe fits snugly into the surgical incision and can be easily maneuvered in a narrow operative space. Higher-frequency transducers, in comparison with lower frequency transducers, can produce higher-resolution images.

Due to the faster attenuation, as the wave passes through the tissue, high-frequency echography waves have a mild tissue penetration. Moreover, from a didactic perspective, the operating room is a place in which the surgeon (more than in the case of other specialties) has a favorable environment to learn operative ultrasound use and interpretation, since the surgeon is already familiar with the anatomical structures that have to be examined during the procedure.

### 2.2 Laparoscopic ultrasound

Laparoscopic ultrasound is a relatively new method in point of surgical sonography, whose arrival can be attributed to the need for the development of specialized transducers that could fit through conventional laparoscopic trocars. The quality, reliability, and ease of use of such units have evolved quickly, so that laparoscopic ultrasonography became routine. One of the advantages of this procedure is that it helps the surgeon to peer into the tissues being operated on, compensating for the inability to palpate those tissues physically.

As a result, not only did it help to replicate open surgery, but it also helped to improve existing laparoscopic surgical techniques. The monitoring of the tips of ultrasound (US) laparoscopes presents several particular challenges.

Instead of a camera, an ultrasound laparoscope's tip has an ultrasound array.

As a result, computer vision tracking methods cannot be used to detect the tip using the image from the laparoscope. The control levers on the laparoscope handle can be used to adjust the tip of the probe.

In contrast to endoscopes, which are rigid throughout, and the tip's pose can be calculated solely by tracking the handle, ultrasound laparoscopes require an additional sensor installed on the tip to obtain the pose, as defined in Chinmay's work [4].

An ultrasound array is located at the tip of the considered ultrasound laparoscope.

The probe's tip is movable, and the surgeon operating the laparoscope may use the control levers to adjust the tip's trajectory even further.

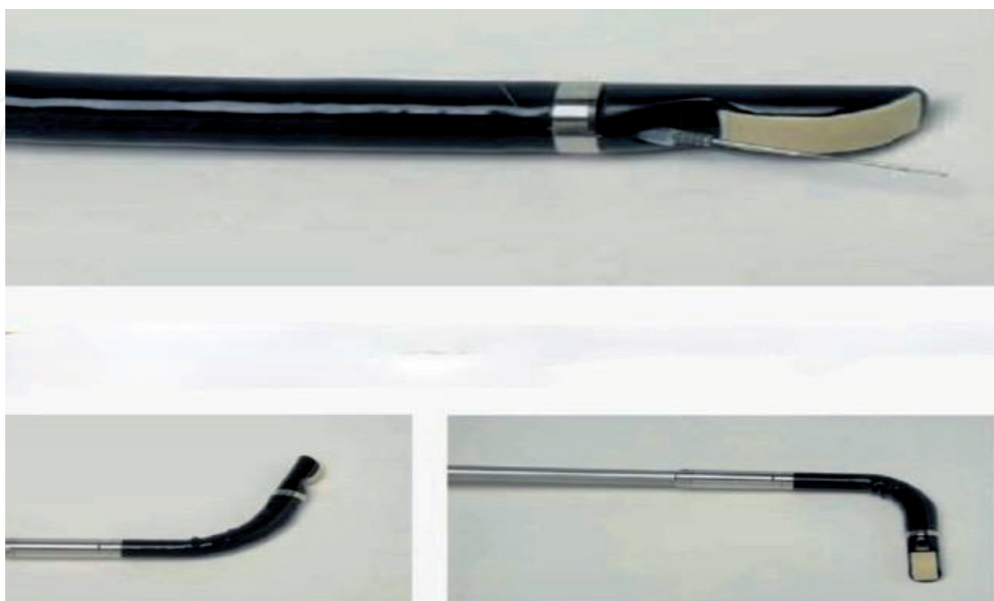These levers are attached to the laparoscope's tip.

The movement of the laparoscope tip is usually regulated by two levers.

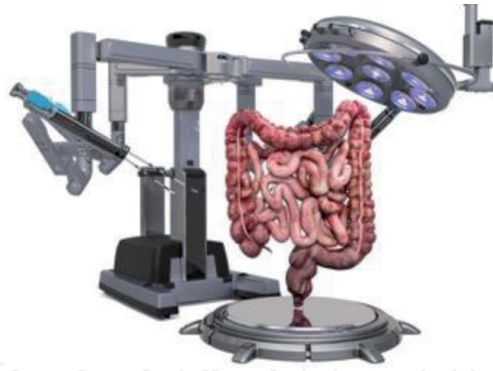The laparoscope tip may be relocated in a hemispheric space inside the patient's body using them (**Figure 2**).

Alecu and coauthors [5] came to the following conclusions in a report on the efficiency of visualization and the general benefits of laparoscopic ultrasonography in abdominal surgery:

1. Diagnostic laparoscopy and intraoperative contact ultrasonography are combined in laparoscopic ultrasonography;
2. laparoscopic ultrasound is a simple and effective examination procedure;
3. laparoscopic ultrasonography is the technique of choice for intraoperative CBD exploration;
4. laparoscopic ultrasonography may improve abdominal malignancy exploration, resulting in a more accurate diagnosis.



**Figure 2.**  
(a-c) A laparoscopic probe has a needle biopsy enhancement (a, above) and two lower images (b, c) showing the flexibility of the tip of the probe.



**Figure 3.**  
*A surgical robot and the schematic approach to the colorectal area.*

### 2.3 Robotic ultrasound

The combination of an ultrasound imaging technique with a robotic device in medical procedures is known as the Robots' ultrasound process (RUS).

Robots are often suitable for ultrasound integration because of their unquestionable capacity for high precision, dexterity, and repeatability.

Despite the fact that the field is still relatively new, it has already developed a slew of robotic systems for use in dozens of medical procedures, such as the one by Priester and collab [6].

Consider the following example: the use of robotic ultrasound in partial nephrectomy with a robot.

According to Di Cosmo and coauthors [7], using a robotic ultrasound probe during partial nephrectomy enables the surgeon to optimize tumor detection with maximum autonomy while also benefiting from the robot's precision and articulation during this crucial phase of the procedure.

Furthermore, ultrasound can help to reduce the time spent in ischemia (IT).

The benefits of nephron-sparing surgery over radical nephrectomy are identified using a pool of data that shows oncological and survival equivalence.

As robot-assisted partial nephrectomy (RAPN) techniques evolved, the use of different instruments to aid the surgeon in identifying masses and their vascular network became more sophisticated.

The authors of this study [7] investigated the current use of intraoperative ultrasound as an operative tool to enhance the localization of small renal masses during RAPN (**Figure 3**).

## 3. Several applications of intraoperative ultrasound in general surgery

In abdominal surgery, intraoperative ultrasound is a popular form of diagnosis.

Not only does it detect focal lesions, but it also eliminates perfusion and elasticity analyses with color-coded Doppler sonography, contrast-enhanced ultrasound, and elastography, all of which allow for highly sensitive and precise diagnostics, especially in oncological surgery, as described in an article by Hackl and team [8]. Another study looked at the staging possibilities offered by intraoperative ultrasound as was the case of Oba and coauthors [9]. Intraoperative assessment needed to appreciate the extent and location of Crohn's disease has not been standardized and currently involves a mixture of surgeons' experience, tactile feedback, and macroscopic appearance. In a study titled "Assessing the Feasibility and Safety of Using Intraoperative Ultrasound in Ileocolic Crohn's Disease—The IUSS CROHN



Study,” Celentano and team [10] devised a strategy for a thorough intraoperative ultrasound scan of the small bowel to overcome this variability. This feasibility study mentioned above demonstrated the safety of intraoperative ultrasound and allowed the development of a standardized protocol for the intraoperative ultrasound.

## **4. Intraoperative ultrasound in colorectal surgery**

### **4.1 Early and precise detection of liver metastases with consecutive treatment: Resection, RFA, cryosurgery**

According to Walker and collab [11], up to two-thirds of colorectal cancer (CRC) patients develop colorectal liver metastases (CRLMs), with one-quarter of patients having synchronous metastases.

Surgical resection for CRLM provides the best chance of a successful outcome.

Computerized tomography and magnetic resonance imaging are often used to stage CRC prior to surgery.

Intraoperative ultrasound (IOUS) and contrast-enhanced IOUS (CE-IOUS) scans have been shown to detect additional metastases not visible on preoperative imaging.

Colorectal surgeons do not commonly use IOUS during primary resection for CRC.

The confident use of IOUS/CE-IOUS after primary resection of CRC can aid decision-making by giving the most sensitive type of liver staging, even when compared to magnetic resonance imaging. This is especially significant in the age of laparoscopic procedures, as the colorectal surgeon loses the ability to palpate the liver and its lesions.

The use of IOUS/CE-IOUS by colorectal surgeons has been hampered by a number of factors.

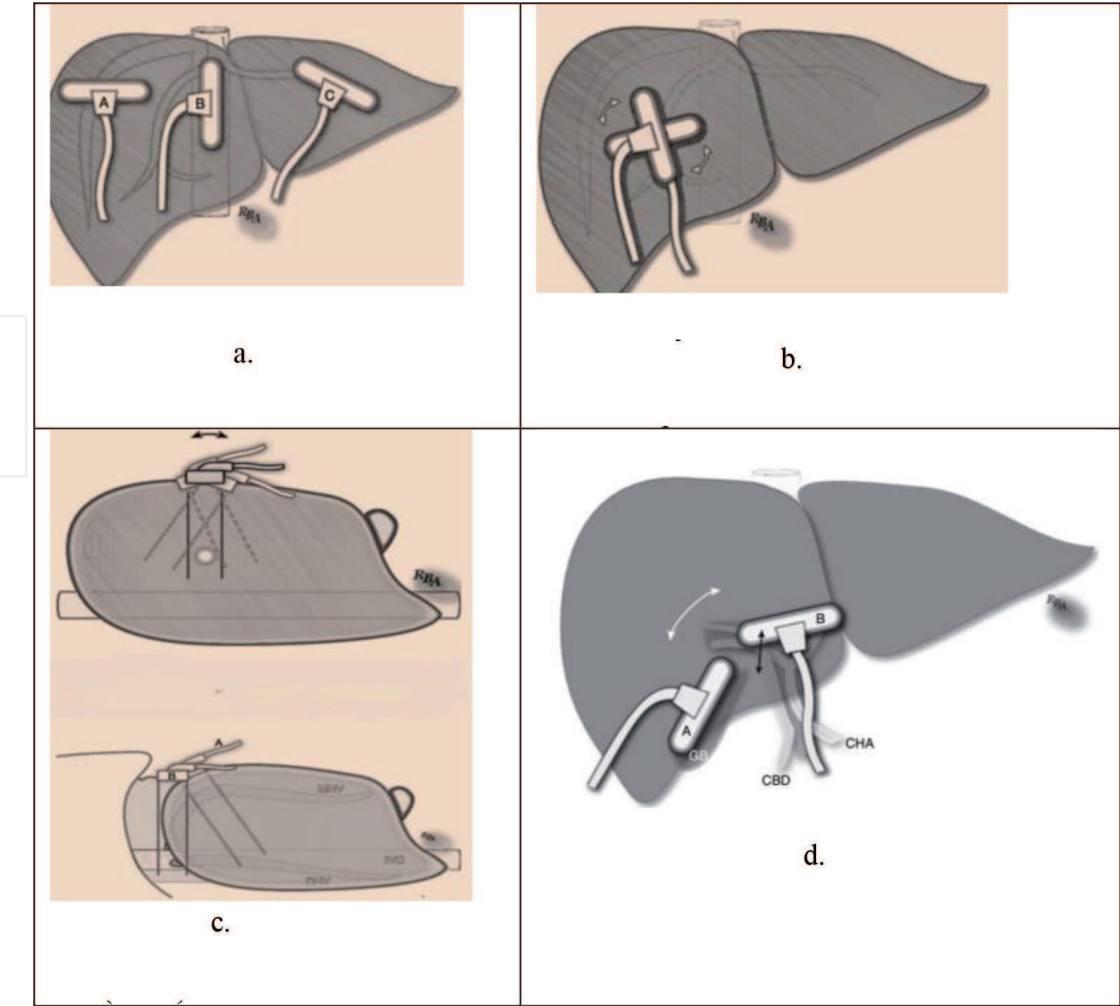
Time constraints, familiarity with procedures, a perceived learning curve, cost effects, and numerous limitations of the modality due to operator variations are just a few of them.

Incorporating IOUS into colorectal surgeons’ basic training and subsequent research into the potential benefits of IOUS/CE-IOUS could theoretically lower these barriers, allowing for more widespread use of IOUS during primary resection for CRC. In a research performed by Desolneux and coauthors [12], the central idea was to determine the clinical utility (CU) of contrast-enhanced intraoperative ultrasound (CE-IOUS) using sulfur hexafluoride microbubbles during CRLM surgery. The conclusion was that although the primary endpoint was not met for one protocol violation, secondary endpoints indicate that CE-IOUS has an intermediate added value for surgeons treating CRLMs (**Figure 4**).

### **4.2 Localization of colorectal tumors**

In a study published by Greif and collab [13] with the goal of determining the accuracy of intraoperative ultrasound (IOUS) as a localizing technique for colorectal resections and its impact on surgical management, it was discovered that IOUS can be used as a sole method of intraoperative localization and provide additional information in patients with small polyps and early cancers of the colon and rectum.

Furthermore, a study by Luck and team [14] discovered that in an *in vitro* setting, a direct ultrasound of the colon utilizing a high-frequency surgical probe gave accurate pictures of neoplastic tumors. This method may play a part in the



**Figure 4.**  
(a) Standard intraoperative transducer position for liver scanning. (b) Rotational transducer movement, the probe is rotated clockwise or counterclockwise on a fixed point, in order to see in two planes. (c) Rocking/tilting the transducer without (above) or with (down) saline immersion. (d) Positions of the probe in order to look at the biliary tree—Main divisions.

intraoperative location of lesions and assessment of colorectal cancer. Furthermore, the same research adds to the overall picture by stating that excellent ultrasound images were obtained, particularly when the colonic lumen was filled with saline.

This technique found and correctly located all lesions, as well as several impalpable synchronous polyps.

The remains of a malignant polyp not evident with intraoperative colonoscopy were discovered by specimen ultrasound in two specimens.

The image's clarity allowed for cancer staging.

The benefit of using laparoscopic high-resolution ultrasonography in conjunction with color power Doppler to locate colonic polyp lesions during a laparoscopic colon resection, as stated by Panaro and coauthors [15], is that intraoperative colonoscopy is avoided.

Intraoperative colon ultrasonography can pinpoint colonic polyp lesions that are not visible during laparoscopy, and it is a quick and painless alternative to other imaging techniques.

### 4.3 Guidance of the technique of quadratus lumborum block for postoperative pain management in colorectal surgery

In an article authored by Deng [16], it was underlined that laparoscopic ultrasound can be used for guiding the injection site in quadratus lumborum block

(QLB) for pain management. The study looked at 74 patients who were scheduled for laparoscopic colorectal surgery and were divided into two classes at random.

Following surgery, patients were given a single dose of QLB or TAPB administered bilaterally using ultrasound guidance.

Twenty-microliter of 0.375% ropivacaine was injected into each hand.

All patients were given sufentanil as a patient-controlled intravenous analgesia (PCIA), and the results showed that the QLB is a more powerful postoperative analgesia than the TAPB in patients undergoing laparoscopic colorectal surgery because it decreases sufentanil intake.

#### **4.4 Doppler assessment of flow and vessel division**

As early as 1980, studies evaluating colonic blood flow through intraoperative Doppler ultrasound showed that laser Doppler flowmetry represents a potentially very interesting non-invasive, continuous method for the quantitative study of human intestinal blood flow, such as the one performed by Ahn and team [17]. In parallel to the study on humans and completing the general picture with valuable information regarding blood flow, a study by Kashiwagi and collab [18] will be further described. In order to determine the minimal threshold of tissue blood flow (TBF) for safe colonic anastomosis, an experiment was performed in dogs: The wound healing process of anastomotic sites was correlated with varying degrees of TBF, measured by laser Doppler velocimetry (LDV). The conclusion of the above-mentioned study was in terms of TBF, if the LDV value at the anastomotic site is at least 1.0, equivalent to about 30% of the TBF of the intact colonic wall, then the anastomosis is considered healthy and dehiscence is unlikely.

In a study presented by Seike and coauthors [19], colonic blood flow at the proximal site of the anastomosis was measured by laser Doppler flowmetry in 96 patients with the rectum and sigmoid colon cancer while clamping IMA or LCA, and the conclusion of the research that looked at which point of ligature would be optimal was that colonic blood flow at the proximal site of the anastomosis was crucial. Patients who undergo ultralow anterior resection and have a high reduction by IMA clamping need various intraoperative efforts to avoid ischemia at the stage of the anastomosis.

According to another study reported by Hallbook [20], laser Doppler flowmetry was used to measure transmural colonic blood flow before the formation of a plain ( $n = 16$ ) or pouch ( $n = 14$ ) anastomosis during the surgery. Before dissecting the bowel, the vascular supply was recorded at two locations: one near to the intended bowel end and another 8 cm away.

After dissection and, where possible, pouch creation, but before the anastomosis was completed, a second recording was made at the same sites.

Following bowel dissection, blood flow levels at the site intended for the anastomosis were substantially reduced in the end-to-end anastomosis community.

Following bowel dissection and pouch building, blood supply levels at the site of the anastomosis were comparable in the pouch community (side-to-end anastomosis).

Unaffected blood supply at the pouch anastomosis site can be a beneficial factor for anastomotic healing, according to the findings.

Furthermore, when it comes to the small bowel partner of an anastomosis, such as the ileocolic anastomosis after right hemicolectomy or the confection of a small bowel J pouch, blood flow supply must be assessed.

This can now be done more accurately with the aid of an ICG quantitative flow technique, but laser Doppler can still be used for orientation, as demonstrated in a study published by Johansson and coauthors [21]. The precision of the blood



flow evaluation by Doppler is such that one can look at the sutureline blood flow in colonic anastomoses, to compare the impact of a mechanical versus a manual anastomosis on the blood supply to the anastomosed area, as was emphasized by Chung and team [22].

#### **4.5 Ultrasound elastography to detect fibrotic bowel strictures in Crohn's disease**

Another study conducted by Chen [23] looked at the distinction of intestinal fibrosis from inflammation in Crohn's disease (CD)-associated strictures, as presented by Vestito [24] in a systematic review with meta-analysis to assess whether ultrasound elastography can have a diagnostic role in detecting fibrotic bowel strictures in patients with Crohn's disease. The study included consecutive CD patients with ileal/ileocolonic strictures who had shear wave elastography (SWE) within 1 week of surgical resection.

The grade and severity of both fibrosis and inflammation in the resected bowel specimen were compared to the SWE of the stenotic bowel wall.

One of the key points of this study was that SWE is a viable and effective method for detecting intestinal fibrosis in CD patients.

Combining SWE and bowel vascularization on traditional ultrasound after validation could be used to direct a management strategy in CD patients by identifying the form of intestinal stricture.

### **5. Conclusion**

This chapter explores the general advantages of intraoperative ultrasound in improving the outcome of the surgical diagnosis, staging, and patient outcome. Specifically, intraoperative colorectal ultrasound can be used both at the level of the primary tumor, as at the level of the lymph nodes, and at the level of the secondary determinations, especially liver metastases.

#### **Conflict of interest**

The author declares no conflict of interest.

IntechOpen

## Author details

Sinziana Ionescu<sup>1,2</sup>

1 Bucharest Oncology Institute, Bucharest, Romania

2 “Carol Davila” University of Medicine and Pharmacy, Bucharest, Romania

\*Address all correspondence to: [sinzianaionescu30@gmail.com](mailto:sinzianaionescu30@gmail.com)

## IntechOpen

© 2021 The Author(s). Licensee IntechOpen. This chapter is distributed under the terms of the Creative Commons Attribution License (<http://creativecommons.org/licenses/by/3.0>), which permits unrestricted use, distribution, and reproduction in any medium, provided the original work is properly cited. 

## References

- [1] Machi J, Oishi AJ, Furumoto NL, Oishi RH. Intraoperative ultrasound. *The Surgical Clinics of North America*. 2004;**84**(4):1085-1111. DOI: 10.1016/j.suc.2004.04.001
- [2] Våpenstad C, Rethy A, Langø T, et al. Laparoscopic ultrasound: A survey of its current and future use, requirements, and integration with navigation technology. *Surgical Endoscopy*. 2010;**24**:2944-2953. DOI: 10.1007/s00464-010-1135-6
- [3] Marcal LP, Patnana M, Bhosale P, Bedi DG. Intraoperative abdominal ultrasound in oncologic imaging. *World Journal of Radiology*. 2013;**5**(3):51-60. DOI: 10.4329/wjrv.5.i3.51
- [4] file:///Users/ionescusinziana/Downloads/SAMANT\_Chinmay\_2019\_ED269.pdf
- [5] Alecu L, Lungu C, Pascu A, Costan I, Corodeanu G, Deacu A, et al. Ecografia intraoperatorie în chirurgia laparoscopică [Intraoperative ultrasonography during laparoscopic surgery]. *Chirurgia*. 2000;**95**(6):557-564
- [6] Priester AM, Natarajan S, Culjat MO. Robotic ultrasound systems in medicine. *IEEE Transactions on Ultrasonics, Ferroelectrics, and Frequency Control*. 2013;**60**(3):507-523. DOI: 10.1109/TUFFC.2013.2593
- [7] Di Cosmo G, Verzotti E, Silvestri T, Lissiani A, Knez R, Pavan N, et al. Intraoperative ultrasound in robot-assisted partial nephrectomy: State of the art. *Archivio Italiano di Urologia, Andrologia*. 2018;**90**(3):195-198. DOI: 10.4081/aiua.2018.3.195
- [8] Hackl C, Bitterer F, Platz Batista da Silva N, Jung EM, Schlitt HJ. Intraoperative ultrasound in visceral surgery. *Chirurg*. 2020;**91**(6):474-480. DOI: 10.1007/s00104-020-01142-6
- [9] Oba A, Inoue Y, Ono Y, Ishizuka N, Arakaki M, Sato T, et al. Staging laparoscopy for pancreatic cancer using intraoperative ultrasonography and fluorescence imaging: The SLING trial. *The British Journal of Surgery*. 2021;**108**(2):115-118. DOI: 10.1093/bjs/znaa111
- [10] Celentano V, Beable R, Ball C, Flashman KG, Reeve R, Fogg C, et al. Feasibility of intraoperative ultrasound of the small bowel during Crohn's disease surgery. *Techniques in Coloproctology*. 2020;**24**(9):965-969. DOI: 10.1007/s10151-020-02268-9
- [11] Walker TLJ, Bamford R, Finch-Jones M. Intraoperative ultrasound for the colorectal surgeon: Current trends and barriers. *ANZ Journal of Surgery*. 2017;**87**(9):671-676. DOI: 10.1111/ans.14124
- [12] Desolneux G, Isambert M, Mathoulin-Pelissier S, Dupré A, Rivoire M, Cattena V, et al. Contrast-enhanced intra-operative ultrasound as a clinical decision making tool during surgery for colorectal liver metastases: The ULIS study. *European Journal of Surgical Oncology*. 2019;**45**(7):1212-1218. DOI: 10.1016/j.ejso.2019.03.002
- [13] Greif F, Aranovich D, Hananel N, Knizhnik M, Belenky A. Intraoperative ultrasound in colorectal surgery. *Journal of Clinical Ultrasound*. 2009;**37**(7):375-379. DOI: 10.1002/jcu.20600
- [14] Luck A, Copley J, Hewett P. Ultrasound of colonic neoplasia. *Surgical Endoscopy*. 2000;**14**:185-188. DOI: 10.1007/s004649900097
- [15] Panaro F, Casaccia M, Cavaliere D, Torelli P. Laparoscopic colon resection with intraoperative polyp localisation with high resolution ultrasonography coupled with colour power Doppler. *Postgraduate Medical Journal*.

2003;**79**(935):533-534. DOI: 10.1136/pmj.79.935.533

[16] Deng W, Long X, Li M, Li C, Guo L, Xu G, et al. Quadratus lumborum block versus transversus abdominis plane block for postoperative pain management after laparoscopic colorectal surgery: A randomized controlled trial. *Medicine*. 2019;**98**(52):e18448. DOI: 10.1097/MD.00000000000018448

[17] Ahn H, Lindhagen J, Lundgren O. Measurement of colonic blood flow with laser Doppler flowmetry. *Scandinavian Journal of Gastroenterology*. 1986;**21**(7):871-880. DOI: 10.3109/00365528609011132

[18] Kashiwagi H. The lower limit of tissue blood flow for safe colonic anastomosis: An experimental study using laser Doppler velocimetry. *Surgery Today*. 1993;**23**(5):430-438. DOI: 10.1007/BF00309502

[19] Seike K, Koda K, Saito N, et al. Laser Doppler assessment of the influence of division at the root of the inferior mesenteric artery on anastomotic blood flow in rectosigmoid cancer surgery. *International Journal of Colorectal Disease*. 2007;**22**:689-697. DOI: 10.1007/s00384-006-0221-7

[20] Hallböök O, Johansson K, Sjö Dahl R. Laser Doppler blood flow measurement in rectal resection for carcinoma—Comparison between the straight and colonic J pouch reconstruction. *British Journal of Surgery*. 1996;**83**(3):389-392. DOI: 10.1002/bjs.1800830330

[21] Johansson K, Ahn H, Lindhagen J. Intraoperative assessment of blood flow and tissue viability in small-bowel ischemia by laser Doppler flowmetry. *Acta Chirurgica Scandinavica*. 1989;**155**(6-7):341-346

[22] Chung RS. Blood flow in colonic anastomoses. Effect of stapling and

suturing. *Annals of Surgery*.

1987;**206**(3):335-339. DOI: 10.1097/00000658-198709000-00011

[23] Chen YJ, Mao R, Li XH, Cao QH, Chen ZH, Liu BX, et al. Real-time shear wave ultrasound elastography differentiates fibrotic from inflammatory strictures in patients with Crohn's disease. *Inflammatory Bowel Diseases*. 2018;**24**(10):2183-2190. DOI: 10.1093/ibd/izy115

[24] Vestito A, Marasco G, Maconi G, Festi D, Bazzoli F, Zagari RM. Role of ultrasound elastography in the detection of fibrotic bowel strictures in patients with Crohn's disease: Systematic review and meta-analysis. *Ultraschall in der Medizin*. 2019;**40**(5):646-654. DOI: 10.1055/a-0865-1842