

We are IntechOpen, the world's leading publisher of Open Access books Built by scientists, for scientists

6,900

Open access books available

185,000

International authors and editors

200M

Downloads

Our authors are among the

154

Countries delivered to

TOP 1%

most cited scientists

12.2%

Contributors from top 500 universities



WEB OF SCIENCE™

Selection of our books indexed in the Book Citation Index
in Web of Science™ Core Collection (BKCI)

Interested in publishing with us?
Contact book.department@intechopen.com

Numbers displayed above are based on latest data collected.
For more information visit www.intechopen.com



Testicular Histopathology and Spermatogenesis in Mice with Scrotal Heat Stress

Thuan Dang-Cong and Tung Nguyen-Thanh

Abstract

Chronic heat stress-induced testicular damage and function therefore adversely affect their reproduction. Some research shows that heat stress has a negative effect on histopathological features of testicular tissue structure and spermatogenesis. An animal model was used to evaluate the effect of heat stress on testicular histology changes and spermatogenesis. The mouse model of heat stress was established by submerged in a pre-warmed incubator. The testes' tissue was fixed and stained with hematoxylin-eosin (H&E) for quantitative analysis of histopathological alterations and spermatogenesis according to Johnson scoring system. Mice exposed to heat stress exhibited degenerated and disorganized features of spermatogenic epithelium and reduced spermatogenic cells. Heat stress exposure shows a significantly reduced Johnson score compared to the control condition. The percentage of high Johnsen score points was decreased in heat-stress exposure mice, while the ratio of low Johnsen score points was gradually increased. This chapter describes a mouse model for studying the male reproductive system and applies the Johnsen scores system to assess testicular histopathology in the seminiferous tubule cross-section. Collectively, this chapter indicated a negative impact of heat stress on mouse spermatogenesis as well as the human reproductive system.

Keywords: Chronic heat stress, testicular tissue, Johnson scoring system, spermatogenesis

1. Introduction

High environmental temperatures affect the functionality of many biological systems in the human body, such as the circulatory system, integumentary system, and respiratory system, with consequences on male reproductive activity [1].

The testes' temperatures of the most numerous species of mammal are often lower than body temperature to accommodate normal spermatogenesis [2]. An increase in testicular and epididymal temperatures in men and other mammals leads to reduced sperm output, decreased sperm motility, and increases the percentage of sperm with abnormal morphology [3]. Increases in testicular temperature may be detrimental to spermatogenesis and ultimately cause problems infertility [4, 5]. Elevation of scrotal temperature interrupts spermatogenesis, resulting in reduced the number and motility of spermatozoa, fertilization ability of the surviving sperm, and poor fertilization-embryo [4, 6].

A high-temperature environment, although it may be within the physiological limits, still hurts sperm quality. The optimal testicular temperature for spermatogenesis is from 2 to 4°C lower than the body temperature. Each 1°C increase in testicular temperature leads to a 14% decrease in spermatogenesis [7]. Recently, research by Gong et al. showed that high ambient temperature drastically reduces sperm motility through decreased mitochondrial activity and ATP synthesis [8]. Heat-stressed testicular tissue leads to apoptosis via mitochondrial pathways or DNA damage. Besides, damaged sperm in the vas deferens DNA fracture under the influence of high ambient temperature can lead to male infertility [9]. Therefore, heat-stressed is a high-risk factor affecting the testicular structure and reducing sperm quality.

Scrotal heat stress increases oxidation, resulting in disrupted thermoregulation of the testicle such as reduction of production antioxidant enzymes and production of heat shock proteins, increase in apoptosis and cell death [10]. Heat stress reduces the ability to regulate the temperature of the scrotum, causes oxidative stress, thus causing cellular reactions including mitochondrial dysfunction, increases the reactive oxygen species (ROS), and reduces the production of anti-ROS enzymes [6]. Scrotal heat stress causes a variety of mechanisms that occur in the testes including oxidative stress response, heat shock response, cell cycle checkpoints, DNA repair, apoptosis, and cell death [5, 11]. Scrotal heat stress interrupts spermatogenesis in male mice [5]. Spermatogonial germ cells are also influenced by heat stress, resulting in the elimination and absence of them in the seminiferous tubules, Sertoli and Leydig cells are degenerated [6].

Spermatogenesis is associated with many factors, including environmental temperatures that can cause cell and molecular changes, affecting gene expression that disrupts sperm production, resulting in reduced reproductive health [12]. Germinal cells are variably sensitive to high temperatures [1]. Significant apoptotic loss of germ cells after testicular heat stress may occur either through intrinsic or extrinsic pathways [13]. Cells in the testis of mammals are affected by heat stress principally primary spermatocytes and early spermatids [14]. The testes of the mice in the Heat stress group showed degenerative changes with spermatogenic arrest in most of the seminiferous ducts [15]. DNA fragmentation in sperm was observed in the testicular tissue exposed to heat stress [16]. The biomechanism of sperm DNA damage involves various types of oxidative reactions, DNA repair errors in the late stages of spermatogenesis, and functional abnormalities that reduce the protective ability of Sertoli cells leading to increased DNA fragmented sperms [17].

Many factors contribute to increasing testicular temperature. These factors can be grouped according to habits, lifestyles [18, 19], occupational factors that must be exposed to high temperatures for long periods [20, 21], and climate change [22]. Depending on the situation, the testicles may experience transient or prolonged heat stress with varying intensity. The effects of high ambient temperature on male fertility tend to accumulate with repeated exposure over a while [7, 18].

Mice are animal models commonly used in biomedical research, because they are easy to handle, cost-effective, and have similarities in thermostats such as a human. Several studies have used experimental mouse models to assess environmental stress on testicular structure and spermatogenesis. Previous research has shown that germ cell death can be induced in response to scrotal temperature exposure in mice [23, 24]. However, the animal model for heat stress study is not yet well established.

The aim of this chapter is to describe a mouse model for investigating the testicular histomorphometric change in response to testicular heat stress and discuss the negative effect of chronic scrotal heat stress on the human male reproductive system.

2. Method to generate a mouse model for testicular heat stress

2.1 Mouse model for testicular heat stress

Swiss mature male mice have 8–10 weeks old (20–23 g) were kept in an animal facility at a controlled temperature ($25 \pm 1^\circ\text{C}$) and illuminated (12 h light–12 h dark), and with free access to food and water.

The mouse model was established to study the effect of scrotal heat stress on spermatogenesis and male fertility. The lower body (including the scrotum) of the mouse was soaked in a thermally controlled water bath (heat exposure at 37°C , 40°C , or 43°C) 2 times a day 10 minutes apart, every 10 minutes, lasting for 5 consecutive weeks, 6 days a week. Control mice were treated in the same way, but in water bath maintained at room temperature. After having the bath, mice were dried and examined for any injury or redness to the scrotal skin before being returned to their cages. Mice were kept in different cages and had free access to water and food. All animals are cared for under identical environmental conditions and monitored their general health.

2.2 Tissue processing and hematoxylin–eosin staining

After completing the heat exposure experiment after 5 weeks, all mice was sacrificed under anesthesia. Their testis tissue were harvested for histological morphometric analysis. The testicular specimens were individually immersed into 4% buffered formaldehyde and dehydrated with graded concentrations of ethyl alcohols at room temperature. The testicular specimens were then embedded into paraffin. The paraffin blocks were cut thinly with a thickness of $5\text{ }\mu\text{m}$ and transferred into gelatinized slides. The sections were deparaffinized with xylene and then rehydrated through a descending series of ethanol and water. Slides were stained with hematoxylin and eosin (H&E) and observed under a light microscope for histopathological analysis.

2.3 Johnsen’s mean testicular biopsy score count

Testicular histological damage and spermatogenesis were assessed using Johnsen’s mean testicular biopsy score under light microscopy [25]. Thirty tubules

Score	Description
10	Complete spermatogenesis with many spermatozoa. Germinal epithelium organized in a regular thickness leaving an open lumen.
9	Many spermatozoa are present but germinal epithelium disorganized with marked sloughing or obliteration of lumen.
8	Only a few spermatozoa are present in the section.
7	No spermatozoa but many spermatids present.
6	No spermatozoa and only a few spermatids are present.
5	No spermatozoa, no spermatids but several or many spermatocytes present.
4	Only few spermatocytes and no spermatids or spermatozoa are present.
3	Spermatogonia are the only germ cells present.
2	No germ cells but Sertoli cells present.
1	No cells in the tubular section

Table 1.
Histological classification of seminiferous tubular cross-sections according to the Johnsen scoring system [25].

for each testis were graded and each tubule was given a score from 1 to 10 based on the presence or absence of germ cell types in the testicular seminiferous tubules such as spermatozoa, spermatids, spermatocyte, spermatogonia, germ cells, and Sertoli cells to evaluate histology. A higher Johnsen's score indicates a better status of spermatogenesis, while a lower score refers to more severe dysfunction. A score of 1 means no epithelial maturation is considered for the tubules with complete inactivity while a score of 10 means full epithelial maturation is considered for the tubules with maximum activity (**Table 1**).

3. The impact of heat stress on spermatogenesis

3.1 An overview of the spermatogenesis

Mammalian spermatogenesis is a complex system within structurally well-designed seminiferous tubules of the testes (**Figure 1a**). Germ cells develop in a spatially organized fashion from the basal membrane to the lumen. During the process of spermatogenesis, primary spermatocytes were differentiated from diploid spermatogonia (Spermatogonial stem cells). Primary spermatocytes undergo to the first meiotic division to generate two secondary spermatocytes. Each secondary spermatocytes go through the second meiosis division to produce haploid daughter spermatids. Spermatid transforms into spermatozoa by the process of metamorphosis (spermiogenesis). Finally, mature sperm were released from the seminiferous epithelium into the tubular lumen. In humans, the spermatogenesis process takes approximately 70 days [26, 28].

3.2 Spermatogenesis complications in mice with heat stress-induced

Globally, animal models have commonly been used to address a variety of biomedical research including, from basic science to immunology and infectious disease, oncology, and behavior or therapies. Laboratory mice are genetically heterogeneous and have been developed to be the powerhouse for biomedical research [29]. Animal models, especially the mouse model was investigated for the study of human infertility or spermatogenesis [30], effects of testes hyperthermia [10], cisplatin-induced testicular injury [31].

Healthy mice without heat stress show the complete process of spermatogenesis in which progenitor spermatogonia develop into mature spermatozoa in the seminiferous tubules (**Figure 1b**). The germinal epithelium including of cells at different stages of spermatogenic development (spermatogonia, primary spermatocytes, secondary spermatocytes, spermatids, and spermatozoa) located in invaginations or in dilations between of Sertoli cells (**Figure 1c**). Meanwhile, the heat-stress exposed mice exhibited degenerated and disorganized features of spermatogenic epithelium and reduced spermatogenic cell numbers (**Figure 1d and e**).

3.3 Evaluation on changes of testicular histology and spermatogenesis in mice exposed to heat stress

Johnsen's score evaluation system was used in several studies to assess testicular histology, a relatively complete scoring system with a full level of testicular histological scores given a score of 10 to 1 with a decrease in the number of cells in the lumen of the spermatogenesis [25]. This quantitative histological grading system is reliable, easily obtained and simple to prognosis for reproductive capacity in men [32, 33]. Johnsen's score is also a histopathological predictor of semen quality after a

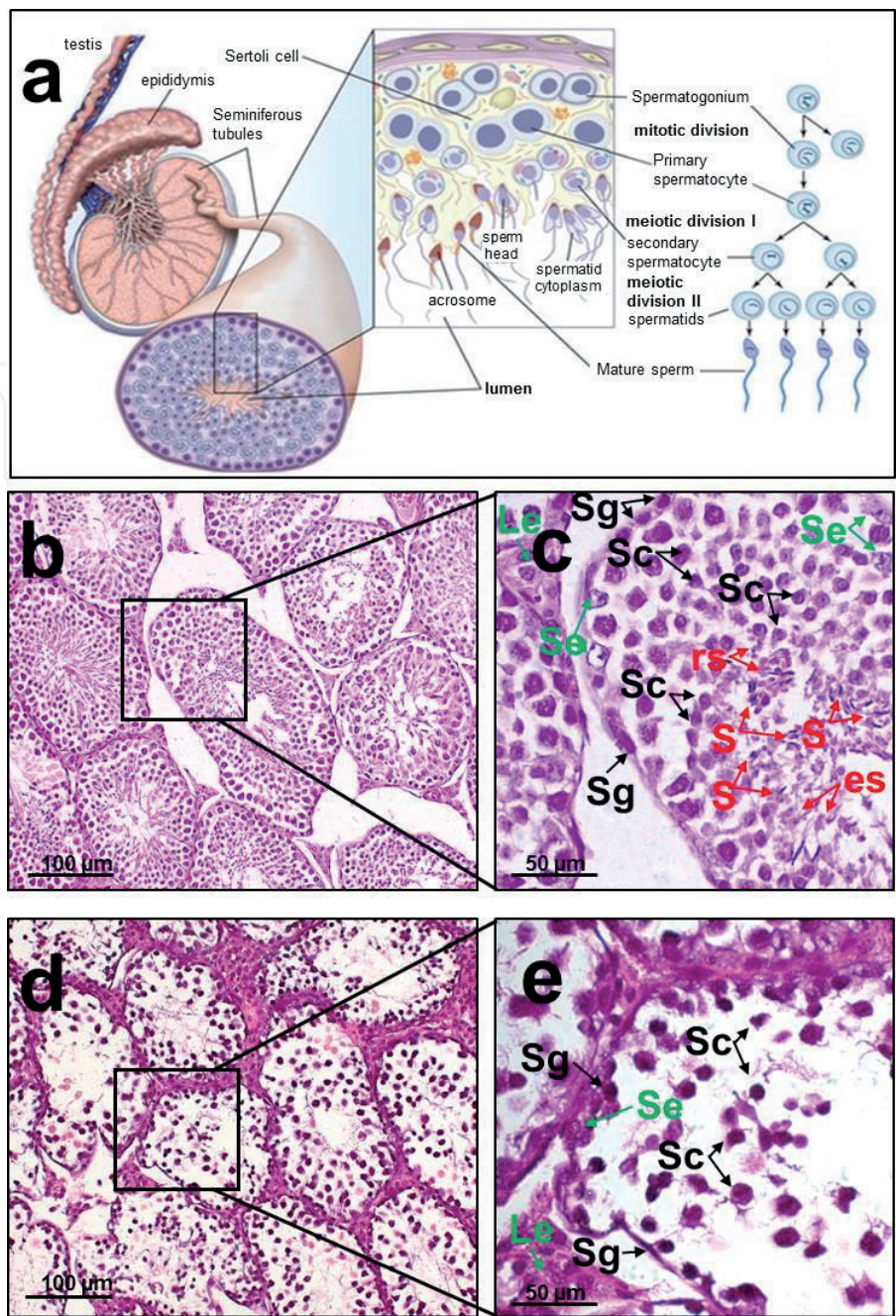


Figure 1.
Anatomy of healthy adult seminiferous tubules [26] and spermatogenesis in healthy and heat-stress exposed mice [27]. (a) Spermatogenesis takes place in the seminiferous tubules of adult testes. The magnification of a seminiferous tubule wedge highlights various cell types created in the differentiation of primordial germ cells to mature sperm. (b) Testicular structure in controlled male mice. (c) Complete spermatogenesis occurs in the seminiferous tubules. (d) Testicular structure in heat-stress exposed male mice. (e) Spermatogenesis arrest occurs in the seminiferous tubules from heat-stress exposed mice; Le: Leydig cells, Se: Sertoli cells, Sg: spermatogonia, Sc: spermatocytes, rs: round spermatids, es: elongating spermatids, S: spermatozoa.

number of treatment indications in male infertility patients to analyze and determine positive prognostic values that help improve fertility [33].

Tung et al. applied the criteria formulated by Johnsen to assess murine testicular histopathology affected by scrotal heat stress [27]. Results showed that Johnsen's score was significantly reduced in the heat stress groups compared with those in the control group, increasing the possibility of infertility in male mice. The seminiferous tubules were graded (1 to 10) according to a reduction in the number and density of germ cells from the lumen of seminiferous tubules. Standardization of Johnsen scores in the seminiferous tubule cross-sections of control and heat exposed group mice stained with hematoxylin–eosin was shown in **Figure 2**.

Johnsen scores 8, 9, and 10 indicate spermatogenesis with a few to many spermatozoa present in a section of seminiferous tubular (**Figure 2a–c**). Scores 6 and 7 indicate seminiferous tubular with no spermatozoa, but spermatids present (**Figure 2d and e**). Seminiferous tubular with no spermatozoa, no spermatids, but spermatocyte present is evaluated as scores 4 and 5 (**Figure 2g and f**). Seminiferous tubular with only spermatogonia as germ cells presence is evaluated as score 3 (**Figure 2h**), meanwhile tubular with no germ cells but Sertoli cells present is given a score 2 (**Figure 2i**). Seminiferous tubular with complete absence of cells in the seminiferous tubules is evaluated as score 1 (**Figure 2j**) [27].

3.4 The effect of heat stress on male reproduction

Genital heat stress has been known as a risk factor for male infertility. However, the exact mechanism causing impaired spermatogenesis is still unclear. Testicular histology after thermal exposure had changed such as decreased epithelial thickness, the appearance of cellular debris, fragmented cells, and absence of sperm and spermatocytes [34, 35]. The impact of prolonged heat stress negatively affects sperm quality and quantity, testicular structure with disruption of the surrounding epithelium [34]. In addition, scrotal heat stress reduces testicular weight, mitochondrial degeneration, dilatation of the smooth endoplasmic reticulum and Leydig cells lose the function of supporting stem cells [13]. Findings from this study support that the testicular structure was disorganized germinal epithelium with marked sloughing or obliteration of lumen; spermatogenesis was interrupted with the absence of many types of sperm cells in male mice after chronic scrotal heat stress exposed for 5 weeks.

The elevated testicular temperature in mammals leads to impair spermatogenesis, germ cells incur damage, decreased sperm motility, and increases the percentage of sperm with an abnormal morphology [3, 36, 37]. Paul et al. also showed the effect of heat stress on testicular function and decreased fertility in mice [38]. In addition, heat stress increases free radicals and oxidative stress resulting in apoptosis of germ cells and increased sperm DNA fracture, loss of sperm integrity [39, 40].

There are many factors that can increase testicular temperature. These factors that affect male fertility can be grouped according to habits, lifestyles [18, 19], occupational factors that must be exposed to high temperatures for long periods [20, 21], and climate change [22]. Depending on the situation, the testicles may experience transient or prolonged heat stress with varying intensity. The effects of high ambient temperature on male fertility tend to accumulate with repeated exposure over a while [7, 18].

Heat-stressed has a direct impact on work performance by increasing the risk of illness and work-related injuries. When workers are exposed to high temperatures, their bodies are unable to activate compensation regimes or recover from stressful working days that put their health in danger [41]. Boni et al. demonstrated high ambient temperature as a serious threat to reproductive function in animals and humans. Comparing parameters between the control group and the group workers exposed to heat were within the limits of normozoosperm range, there was a serious decline in semen parameters [21]. The bakers exposed to high ambient temperature have high infertility rates as shown in Al-Otaibi's study [20]. There was another large-scale epidemiological study at the Danish infertility clinic in which subjects underwent sperm examinations or infertility treatments, and obtained information on occupational exposure. It was found that the groups of workers exposed to textile dyes and lead, noise, cadmium, and mercury were all potentially infertile [42]. Similarly, Hamerezaee et al. have drawn the same results about the effects of temperature stress on semen quality when studied on workers of the steel industry

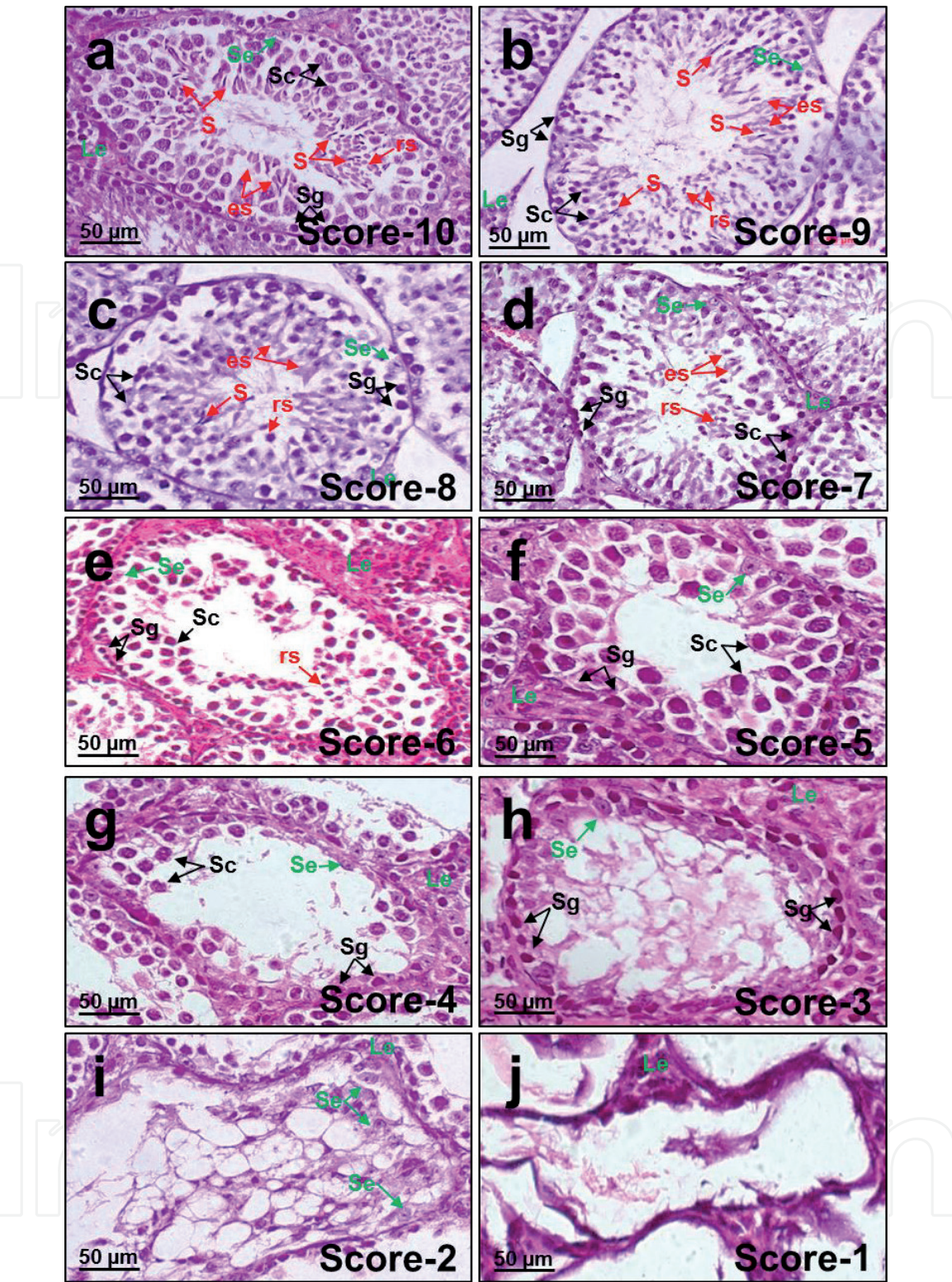


Figure 2.
Standardization of Johnsen scores in the seminiferous tubule cross-sections of control and heat exposed group mice stained with hematoxylin-eosin [27]. (a) Johnsen score 10. (b) Johnsen score 9. (c) Johnsen score 8. (d) Johnsen score 7. (e) Johnsen score 6. (f) Johnsen score 5. (g) Johnsen score 4. (h) Johnsen score 3. (i) Johnsen score 2. (j) Johnsen score 1. Le: Leydig cells, Se: Sertoli cells, Sg: spermatogonia, Sc: spermatocytes, rs: round spermatids, es: elongating spermatids, S: spermatozoa.

in Iran. The semen quality of the workers is lower than the normal limit and significantly lower than the control group [43]. Another three-year study conducted in a fertility clinic in New Orleans found that men working in buildings without air conditioning during summertime would reduce their sperm quality. Their semen samples had a significantly lower sperm concentration, number of sperms per ejaculation, and a lower percentage of sperm motility when compared those figures

in summer to other seasons of the year [44]. In contrast, a study in the ceramic industry has reported that workers exposed to high temperatures had no significant difference on semen analyses except for the sperm velocity [45].

In conclusion, this chapter shows the evidence for negative effects on histopathological alterations and spermatogenesis arrest following chronic scrotal heat stress. This chapter also characterizes an animal model for studying the male reproductive system and standardized Johnsen scores system to assess murine testicular histopathology in the seminiferous tubule cross-sections.

Acknowledgements

The study was supported by the Hue university-level research projects in science and technology (DHH 2019-2104-88).

Author details

Thuan Dang-Cong¹ and Tung Nguyen-Thanh^{2,3*}


¹ Department of Histology, Embryology, Pathology, and Forensic, Hue University of Medicine and Pharmacy, Hue University, Hue, Vietnam

² Faculty of Basic Science, Hue University of Medicine and Pharmacy, Hue University, Hue, Vietnam

³ Institute of Biomedicine, Hue University of Medicine and Pharmacy, Hue University, Hue, Vietnam

*Address all correspondence to: nttung@huemed-univ.edu.vn;
nguyenthanhtung@hueuni.edu.vn

IntechOpen

© 2021 The Author(s). Licensee IntechOpen. This chapter is distributed under the terms of the Creative Commons Attribution License (<http://creativecommons.org/licenses/by/3.0>), which permits unrestricted use, distribution, and reproduction in any medium, provided the original work is properly cited. 

References

- [1] Boni R: **Heat stress, a serious threat to reproductive function in animals and humans.** *Molecular Reproduction and Development* 2019, **86**.
- [2] Rockett JC, Mapp FL, Garges JB, Luft JC, Mori C, Dix DJ: **Effects of hyperthermia on spermatogenesis, apoptosis, gene expression, and fertility in adult male mice.** *Biology of reproduction* 2001, **65**(1):229-239.
- [3] Abdelhamid MHM, Walschaerts M, Ahmad G, Mieusset R, Bujan L, Hamdi S: **Mild experimental increase in testis and epididymis temperature in men: effects on sperm morphology according to spermatogenesis stages.** *Translational andrology and urology* 2019, **8**(6):651-665.
- [4] Shadmehr S, Fatemi Tabatabaei SR, Hosseinfar S, Tabandeh MR, Amiri A: **Attenuation of heat stress-induced spermatogenesis complications by betaine in mice.** *Theriogenology* 2018, **106**:117-126.
- [5] Lin C, Shin DG, Park SG, Chu SB, Gwon LW, Lee JG, Yon JM, Baek IJ, Nam SY: **Curcumin dose-dependently improves spermatogenic disorders induced by scrotal heat stress in mice.** *Food & function* 2015, **6**(12):3770-3777.
- [6] Rasooli A, Taha Jalali M, Nouri M, Mohammadian B, Barati F: **Effects of chronic heat stress on testicular structures, serum testosterone and cortisol concentrations in developing lambs.** *Animal reproduction science* 2010, **117**(1-2):55-59.
- [7] Durairajanayagam D, Agarwal A, Ong C: **Causes, effects and molecular mechanisms of testicular heat stress.** *Reproductive BioMedicine Online* 2015, **30**(1):14-27.
- [8] Gong Y, Guo H, Zhang Z, Zhou H, Zhao R, He B: **Heat Stress Reduces Sperm Motility via Activation of Glycogen Synthase Kinase-3 α and Inhibition of Mitochondrial Protein Import.** *Front Physiol* 2017, **8**:718-718.
- [9] Kim B, Park K, Rhee K: **Heat stress response of male germ cells.** *Cellular and molecular life sciences : CMLS* 2013, **70**(15):2623-2636.
- [10] Kumar Roy V, Marak TR, Gurusubramanian G: **Alleviating effect of Mallotus roxburghianus in heat-induced testicular dysfunction in Wistar rats.** *Pharmaceutical biology* 2016, **54**(5):905-918.
- [11] Zhang MH, Shi ZD, Yu JC, Zhang YP, Wang LG, Qiu Y: **Scrotal heat stress causes sperm chromatin damage and cysteinyl aspartate-specific proteinases 3 changes in fertile men.** *Journal of assisted reproduction and genetics* 2015, **32**(5):747-755.
- [12] Cammack KM, Antoniou E, Hearne L, Lamberson WR: **Testicular gene expression in male mice divergent for fertility after heat stress.** *Theriogenology* 2009, **71**(4):651-661.
- [13] Durairajanayagam D, Agarwal A, Ong C: **Causes, effects and molecular mechanisms of testicular heat stress.** *Reproductive biomedicine online* 2015, **30**(1):14-27.
- [14] Setchell B: **The effect of heat on the testes of mammals.** *Anim Reprod International Symposium on Animal Biology of Reproduction* 2006, **3**:81-91.
- [15] Mohajeri D, Kaffashi Elahi R: **Effects of Nigella sativa on heat-induced testis damage in mouse.** *Bratislavske lekarske listy* 2015, **116**(4):264-269.
- [16] Hamilton TRDS, Siqueira AFP, de Castro LS, Mendes CM, Delgado JdC, de Assis PM, Mesquita LP, Maiorka PC,

Nichi M, Goissis MD *et al*: **Effect of Heat Stress on Sperm DNA: Protamine Assessment in Ram Spermatozoa and Testicle.** *Oxid Med Cell Longev* 2018, 2018:5413056-5413056.

[17] Tesarik J, Mendoza-Tesarik R, Mendoza C: **Sperm nuclear DNA damage: update on the mechanism, diagnosis and treatment.** *Reproductive biomedicine online* 2006, 12(6):715-721.

[18] Durairajanayagam D: **Lifestyle causes of male infertility.** *Arab J Urol* 2018, 16(1):10-20.

[19] Garolla A, Torino M, Sartini B, Cosci I, Patassini C, Carraro U, Foresta C: **Seminal and molecular evidence that sauna exposure affects human spermatogenesis.** *Human reproduction (Oxford, England)* 2013, 28(4): 877-885.

[20] Al-Otaibi ST: **Male infertility among bakers associated with exposure to high environmental temperature at the workplace.** *Journal of Taibah University Medical Sciences* 2018, 13(2):103-107.

[21] Boni R: **Heat stress, a serious threat to reproductive function in animals and humans.** *Molecular Reproduction and Development* 2019, 86(10):1307-1323.

[22] Sinawat S: **The environmental impact on male fertility.** *Journal of the Medical Association of Thailand = Chotmaihet thangkaet* 2000, 83(8):880-885.

[23] Rakesh V, Stallings JD, Reifman J: **A virtual rat for simulating environmental and exertional heat stress.** *J Appl Physiol (1985)* 2014, 117(11):1278-1286.

[24] Paul C, Teng S, Saunders PT: **A single, mild, transient scrotal heat stress causes hypoxia and oxidative stress in mouse testes, which induces**

germ cell death. *Biology of reproduction* 2009, 80(5):913-919.

[25] Johnsen SG: **Testicular biopsy score count--a method for registration of spermatogenesis in human testes: normal values and results in 335 hypogonadal males.** *Hormones* 1970, 1(1):2-25.

[26] Schilit S: **Uncovering Novel Cytogenetic and Molecular Etiologies for Male Infertility.** 2019.

[27] Tung NT, Phuoc DV, Thuan DC, Tam LM, Quoc Huy NV: **Assessment of testis histopathological changes and spermatogenesis in male mice exposed to chronic scrotal heat stress.** *J Anim Behav Biometeorol* 2020, 8:174-180.

[28] Hunter D, Anand-Ivell R, Danner S, Ivell R: **Models of in vitro spermatogenesis.** *Spermatogenesis* 2012, 2(1):32-43.

[29] Barre-Sinoussi F, Montagutelli X: **Animal models are essential to biological research: issues and perspectives.** *Future science OA* 2015, 1(4):FSO63.

[30] Jamsai D, O'Bryan MK: **Mouse models in male fertility research.** *Asian journal of andrology* 2011, 13(1):139-151.

[31] Whirledge SD, Garcia JM, Smith RG, Lamb DJ: **Ghrelin partially protects against cisplatin-induced male murine gonadal toxicity in a GHSR-1a-dependent manner.** *Biology of reproduction* 2015, 92(3):76.

[32] Dohle GR, Elzanaty S, van Casteren NJ: **Testicular biopsy: clinical practice and interpretation.** *Asian journal of andrology* 2012, 14(1):88-93.

[33] Teixeira TA, Pariz JR, Dutra RT, Saldiva PH, Costa E, Hallak J: **Cut-off values of the Johnsen score and Copenhagen index as**

histopathological prognostic factors for postoperative semen quality in selected infertile patients undergoing microsurgical correction of bilateral subclinical varicocele. *Translational andrology and urology* 2019, 8(4): 346-355.

[34] Setchell BP: **The effects of heat on the testes of mammals.** *Animal Reproduction* 2006, vol. 3: no. 2.

[35] Gao J, Zuo Y, So KH, Yeung WS, Ng EH, Lee KF: **Electroacupuncture enhances spermatogenesis in rats after scrotal heat treatment.** *Spermatogenesis* 2012, 2(1):53-62.

[36] Kanter M, Aktas C, Erboga M: **Heat stress decreases testicular germ cell proliferation and increases apoptosis in short term: an immunohistochemical and ultrastructural study.** *Toxicology and industrial health* 2013, 29(2):99-113.

[37] Shiraishi K, Matsuyama H, Takihara H: **Pathophysiology of varicocele in male infertility in the era of assisted reproductive technology.** *International journal of urology : official journal of the Japanese Urological Association* 2012, 19(6):538-550.

[38] Paul C, Murray AA, Spears N, Saunders PT: **A single, mild, transient scrotal heat stress causes DNA damage, subfertility and impairs formation of blastocysts in mice.** *Reproduction* 2008, 136(1):73-84.

[39] Shiraishi K, Takihara H, Matsuyama H: **Elevated scrotal temperature, but not varicocele grade, reflects testicular oxidative stress-mediated apoptosis.** *World journal of urology* 2010, 28(3):359-364.

[40] Nash S, Rahman MS: **Short-term heat stress impairs testicular functions in the American oyster, *Crassostrea virginica*: Molecular mechanisms and induction of oxidative stress and apoptosis in**

spermatogenic cells. *Molecular reproduction and development* 2019, 86(10):1444-1458.

[41] Momen MN, Ananian FB, Fahmy IM, Mostafa T: **Effect of high environmental temperature on semen parameters among fertile men.** *fertility and sterility* 2010, 93(6):1884-1886.

[42] Rachootin P, Olsen J: **The risk of infertility and delayed conception associated with exposures in the Danish workplace.** *Journal of Occupational and Environmental Medicine* 1983, 25(5):394-402.

[43] Hamerezaee M, Dehghan SF, Golbabaee F, Fathi A, Barzegar L, Heidarnejad N: **Assessment of Semen Quality among Workers Exposed to Heat Stress: A Cross-Sectional Study in a Steel Industry.** *Safety and health at work* 2018, 9(2):232-235.

[44] Levine RJ, Bordson BL, Mathew RM, Brown MH, Stanley JM, Starr TB: **Deterioration of semen quality during summer in New Orleans.** *Fertility and Sterility* 1988, 49(5):900-907.

[45] Figa-Talamanca I, Dell'Orco V, Pupi A, Dondero F, Gandini L, Lenzi A, Lombardo F, Scavalli P, Mancini G: **Fertility and semen quality of workers exposed to high temperatures in the ceramics industry.** *Reproductive Toxicology* 1992, 6(6):517-523.