

We are IntechOpen, the world's leading publisher of Open Access books Built by scientists, for scientists

6,900

Open access books available

185,000

International authors and editors

200M

Downloads

Our authors are among the

154

Countries delivered to

TOP 1%

most cited scientists

12.2%

Contributors from top 500 universities



WEB OF SCIENCE™

Selection of our books indexed in the Book Citation Index
in Web of Science™ Core Collection (BKCI)

Interested in publishing with us?
Contact book.department@intechopen.com

Numbers displayed above are based on latest data collected.
For more information visit www.intechopen.com



An Overview of the Biochemical and Histopathological Effects of Insecticides

Haci Ahmet Deveci, Gökhan Nur, Ayla Deveci, Inan Kaya, Müge Mavioglu Kaya, Abdulsamed Kükürt, Volkan Gelen, Ömer Faruk Başer and Mahmut Karapehlivan

Abstract

The number of studies on insecticides, which constitute an important class of pesticides, is increasing day by day. These chemicals used in the fight against pests in the field of agriculture; It is also used to fight mosquitoes and insects in homes, gardens and rural areas. Excessive use of insecticides has adversely affected many beneficial organisms besides target organisms. As a result of the negative effects of insecticides on non-target organisms, the normal balance of nature has been disturbed and this has led to the decline of some living species in the world. In many studies from the past to the present, it has been shown that these insecticides have negative effects on the environment, human and animal health. Some of these chemicals, which have many benefits in the fight against agricultural pests, have been banned due to their harmful effects on non-target organisms as a result of excessive use. Today, however, these chemicals are still used intensively against agricultural pests, threatening non-target organisms and human health. For this reason, in this book chapter we have prepared, the negative effects of insecticides on living things are examined by reviewing biochemical and histopathological studies.

Keywords: Pesticide, insecticide, oxidative stress parameters, histopathology changes

1. Introduction

The rapid and uncontrolled increase in the world population brings along the need for nutrition and food. Today, the failure to provide agricultural products at the level to meet the increase in world population causes problems of nutritional and food needs. In order to meet the nutritional and food needs, it is important to produce agricultural products with low cost and high quality and efficiency. In the production of agricultural products, losses of up to 65% may occur in products due to some pests and diseases. For this reason, producers use different methods to increase the yield in agricultural areas and to prolong the durability of foodstuffs. One of these methods is the chemical control method, which is carried out under the name of agricultural control, which increases product productivity in the agricultural field. In fact, the basis of this method is the use of pesticides. In the global pesticides market, herbicides rank first among pesticides with a share of 47%. This

is followed by insecticides (29%), fungicides (19%) and other pesticides (5%). In Turkey, insecticides (47%) take the first place in the use of pesticides, which is followed by herbicides (24%), fungicides (16%) and other pesticides (13%) [1, 2].

Pesticides, which are chemical and biological substances used in the fight against pests, are widely used for protective purposes against internal and external parasites in veterinary medicine and agricultural control. Pesticides are substances that are frequently used to obtain more products in the control of insects that damage agricultural products and various vectors that are the cause of disease [3, 4].

Pesticides are widely used in the field of agriculture to control pests. In addition to agricultural purposes, pesticides are also utilized in the fight against mosquitoes and weeds in houses, gardens and rural areas. However, pesticides which remain the same in the soil for a long-time cause water, soil and air pollution and ruin the ecological balance. The most important harmful effects of pesticides are that they enter the body through the food chain and cause acute and chronic poisoning in humans and animals. In addition, it has been reported that pesticide degradation products cause damage to biological systems as a result of accumulation in tissues and organs over time [5–7].

Pesticides are classified in different ways according to their formulation forms, the chemical structure of their active substances and the pest group they are used in. The most widely used classification is the classification made based on the pest group they are used in. Insecticide (insecticide), fungicide (fungicide), herbicide (weed killer), acaricide (spider killer), bactericide (bactericide), rodenticide (rodenticide), nematocide (nematode killer), aphicide (aphid killer), and algicide (algae killer) can be given as examples to the pesticides in this classification. Among them, herbicides, insecticides, and fungicides are the most widely used and studied in the world [8, 9].

Knowing the types of insecticides, their chemical structures, and their harmful effects on the environment and living things will guide the studies that can prevent the damage of these substances. This study, presented in line with this information, it is aimed to explain the biochemical and histopathological effects of insecticides on the organism by considering them with current articles.

2. Classification of insecticides

Insects are one of the factors that threaten our health in the environments we live in. In addition to its psychological effects such as disgust in humans, it leads to the spreading of diseases such as plague, jaundice, and typhoid. Apart from these,

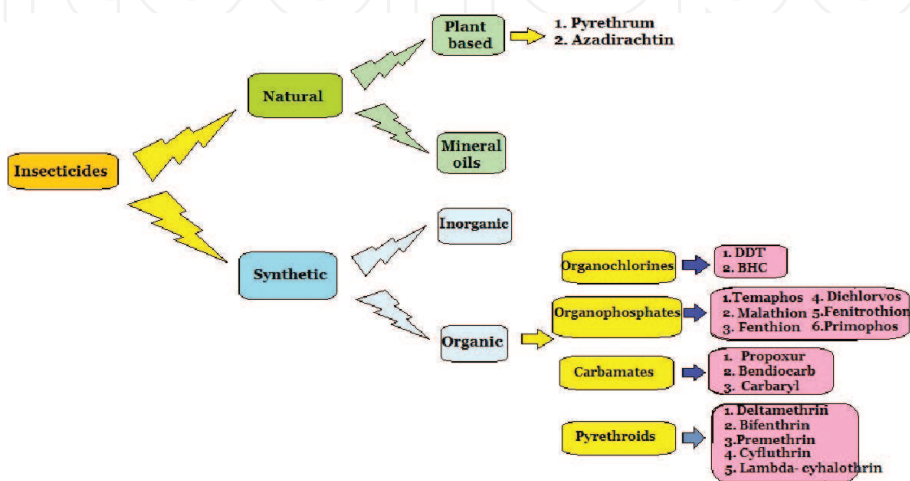


Figure 1.
Classification of insecticides [10].

insect bites can cause complaints such as itching, skin peeling, and pain in humans. Pesticides used to kill insects in many living areas such as agriculture, livestock farming, houses and workplaces are called as ‘insecticide’. Insecticides are the second most widely used pesticide type in the world after herbicides [1, 9]. Insecticides are generally classified as in **Figure 1** [10].

3. Bioaccumulation of insecticides and their transfer in the food chain

As from the middle of the twentieth century, human health and the natural environment have begun to be adversely affected upon the excessive use of pesticides, including insecticides. These substances, which are used against insects that

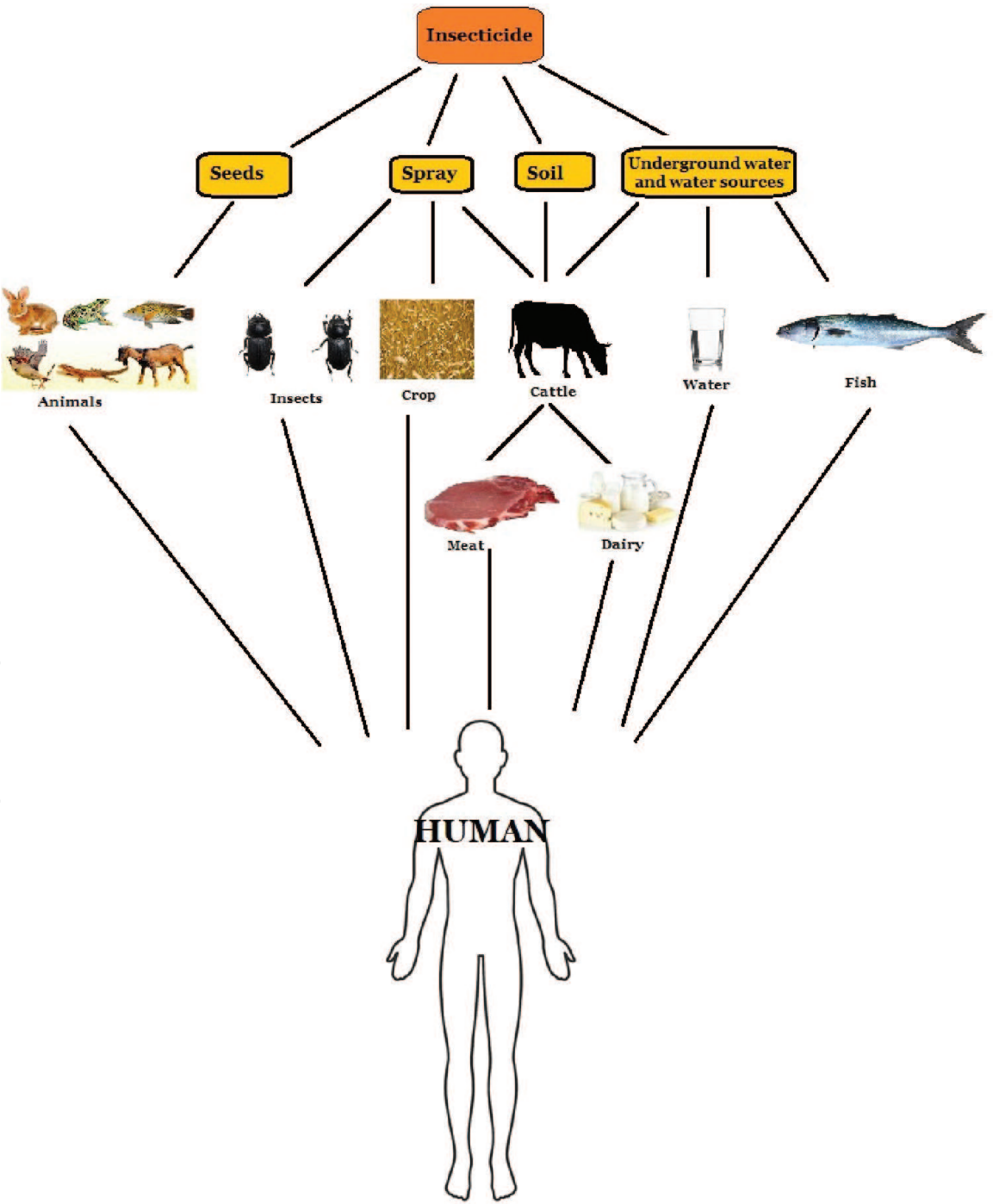


Figure 2.
Bioaccumulation of insecticide residues in the food chain [9].

harm agricultural products in the beginning, have indeed brought about significant increases in the quality and quantity of agricultural products. Insecticides, which serve to protect agricultural products by destroying unwanted insects, have provided great benefits for both the environment and public health by also controlling pathogenic vectors. However, as a result of excessive use of these substances to obtain better quality and more products later on, many unexpected harmful effects have been experienced. These substances remain intact for a long time in water, soil, fruits and vegetables and cause environmental pollution. Since insecticides applied to agricultural products can remain intact for a long time, they can reach the food chain by mixing with soil and water, and then passing through plants and animals [11–13]. These pollutants enter through the skin, gills, and digestive systems of aquatic organisms and begin to accumulate in the organs of these living creatures. These pollutants entering the body are metabolized and excreted with the help of body fluids. If they cannot be excreted from the body, they accumulate in tissues with high fat content and may remain in these tissues for many years [13, 14]. The accumulation increases exponentially when small aquatic organisms carrying insecticide residues are eaten by larger aquatic organisms and plants with insecticide residues are eaten by animals. Thus, the residue level in humans, who are in the last link of the food chain, becomes much higher and concentrated [11, 12]. The bioaccumulation of pesticide residues in the food chain is shown in **Figure 2** [9].

4. Action mechanisms of insecticides

The nervous system of insects is developed and it has characteristics similar to the nervous system of mammals. Therefore, insecticides do not have species-specific selective effects, and all mammals, including humans, are extremely sensitive to the toxic effects of insecticides. Selective action between insects and mammals is usually the result of differences in detoxification mechanisms or differential interactions in their target structures. Insecticides cause more acute poisoning in non-target organisms compared to the other pesticides [8]. The effects of insecticides may vary depending on features such as their chemical formulations, amount and duration of application, temperature and pH of the environment etc. [13–15]. The continuous use of the same insecticide species in agricultural practices causes insect species to lose their sensitivity and become resistant to these insecticides over time. As a result, the need for continuous renewal has emerged due to the decreasing effectiveness of organophosphate, carbamate, organochlorine, and pyrethroid insecticides, and alternative new insecticides such as neonicotinoid insecticides have been developed [16, 17].

The majority of insecticides used today are neurotoxic substances and act by poisoning the nervous systems of target organisms [18, 19]. The action mechanism of organophosphate and carbamate insecticides is based on the inhibition of the acetylcholinesterase enzyme (AChE). Organophosphate insecticides or their active metabolites covalently bind to the hydroxyl group of serine in the active site of AChE with phosphate radicals and cause inhibition of the enzyme. Detoxification of organophosphates includes hydrolysis reaction catalyzed by A-esterases such as paraoxonase (PON) and stoichiometric binding reactions to B-esterases such as acetylcholinesterase, butyrylcholinesterase, and carboxylesterase in plasma [19–22]. Carbamate insecticides also involve “carbamylation” of the enzyme. The cholinergic syndrome that develops in acute poisonings caused by this group of insecticides is short-lived, since the enzyme’s reactivation time is short after carbamylation [23]. Organochlorine insecticides are effective on the central nervous system and

Insecticide Class	Example	Mechanism	Effect
Organophosphate	Diazinon Chlorpyrifos Mipafox	Inhibition of AChE	Cholinergic syndrome Peripheral axonopathy
Carbamate	Aldicarb Carbaryl	Inhibition of AChE	Cholinergic syndrome
Pyrethroid	Deltamethrin Allethrin	Prolonged opening of sodium Channels	Hyperexcitability
Organochlorine	DDT Lindane	Prolonged opening of sodium channel Inhibition of GABA- and voltage-dependent chloride channels	Hyperexcitability, tremors Seizures

Table 1.
Mechanisms and effects of neurotoxic insecticides in mammals [18].

their action mechanism may vary according to the structure of the insecticide. DDT (Dichlorodiphenyltrichloroethane) changes the permeability of sodium-potassium channels in the nerve membrane and causes excessive nerve stimulation by causing slow closure of sodium channels. In cyclodiene and lindane exposure, neurotransmitter release from synapses is affected. These compounds antagonize GABA (γ -aminobutyric acid) and cause depolarization and overstimulation in the postsynaptic membrane [23, 24]. Pyrethroid insecticides, on the other hand, change the properties of voltage-dependent sodium channels and cause prolonged opening of the channel. In this way, excessive excitation occurs in the central nervous system [18, 23]. **Table 1** shows the action mechanisms of insecticides [18]. In recent years, it has been reported that insecticides, in addition to these effects, increase the production of reactive oxygen species (ROS), thus causing an increase in oxidant molecules and a decrease in antioxidant molecules in the organism [5–7, 17, 19, 25, 26]. ROS formation rate and elimination work in balance. If it breaks down in favor of ROS, oxidative stress occurs. Due to oxidative stress, peroxidative damage to macromolecules and membranes of cells occurs in organisms. Moreover, their metabolic activities in cell components are impaired. Known to tissue and organ pathologies occur in the presence of oxidative stress in the organism [27–34].

5. Biochemical effects of insecticides

Pesticides are metabolized in the liver by cytochrome P450 enzyme systems, passing through the human body through the skin, respiration, and digestion. Pesticides stimulate lipid peroxidation in hepatic microsomes and cause a decrease in cytochrome P450 enzymes, glucose 6-phosphatase and pyrophosphatase activities [35]. Detoxification of organophosphate pesticides, including organophosphate insecticides, is provided by A-esterases such as paraoxonase (PON) and B-esterases such as acetylcholinesterase, butyrylcholinesterase, and carboxylesterase in plasma [19, 20]. In a study conducted on agricultural laborers who were exposed to pesticides for a long time, it has been observed that protein levels significantly reduced and aspartate aminotransferase (AST), alanine aminotransferase (ALT), alkaline phosphatase (ALP), and lactate dehydrogenase (LDH) activities significantly increased in these

people, compared to people who were not directly exposed to pesticides [36]. On the other hand, in a study conducted on pesticide sales people in the GAP Region, it was observed that AST and ALT activities increased, while ALP and LDH activities decreased in those who worked at pesticide sales locations for a long time [37].

In an experimental study in which the organophosphate insecticide diazinon was applied to rats for 4 weeks, it was reported that this insecticide caused significant changes in hematological and biochemical parameters. Accordingly, it was reported that serum biochemical parameters AST, ALT, ALP, LDH, creatine kinase (CK) activities, and urea, uric acid, and creatinine values of rats, to which diazinon was administered, significantly increased, compared to the control group [38]. It was reported that DDT administration to rats increased serum AST and ALT levels,

Insecticide Used	Experimental Model	Oxidative Stress Parameters	References
Chlorpyrifos	Fish	Increase in MDA, NO	[48]
Chlorpyrifos	Mice	Increase in TOC Decrease in TAC, PON	[19]
Chlorpyrifos	Rat	Increase in lipid peroxidation Decrease in TAC, GSH, GPx, SOD, CAT	[49]
Cypermethrin	Fish	Increase in MDA, SOD, CAT Decrease in GSH, GPx	[50]
Cypermethrin	Mice	Increase in lipid peroxidation (TBARS) Decrease in GST, SOD	[51]
Cypermethrin	Rat	Increase in MDA, CAT Decrease in GSH, GPx, SOD	[52]
Deltamethrin	Fish	Increase in MDA Decrease in CAT, SOD, GSH, GPx	[43]
Deltamethrin	Mice	Increase in MDA	[53]
Deltamethrin	Rat	Increase in MDA Decrease in GSH	[54]
Diazinon	Fish	Increase in MDA, CAT Decrease in SOD, TAC	[55]
Diazinon	Mice	Increase in MDA Decrease in GSH, SOD	[56]
Diazinon	Rat	Increase in MDA, NO Decrease in GSH, GPx, SOD, CAT, TAC	[38]
Dichlorvos	Fish	Increase in lipid peroxidation (TBARS) No significant changes in GST	[57]
Dichlorvos	Mice	Increase in MDA Decrease in CAT, SOD, GPx	[58]
Dichlorvos	Rat	Increase in MDA, NO Decrease in PON	[7]
Malathion	Fish	Increase in LPO, CAT, SOD, GST, GPx Decrease in GSH, TAO	[59]
Malathion	Mice	Increase in MDA Decrease in GSH, GPx, SOD, CAT	[60]
Malathion	Rat	Increase in MDA Decrease in GSH	[61]

Table 2.
The effects of insecticides on oxidative stress parameters in experimental animal models.

stimulated inflammation, and suppressed the immune system [39]. In another study conducted on rats with the carbamate insecticide carbofuran, it was observed that this insecticide increased cholesterol level and AST, ALT, LDH activities and decreased high-density lipoprotein (HDL) level and AChE activity in rat serum after 24-hour treatment [40]. In a study conducted on fish with the organochlorine insecticide lindane, it was reported that glucose increased and total protein decreased at low doses and increased at high doses [41]. In another study conducted on fish, it was stated that the pyrethroid insecticide deltamethrin increased the biochemical parameters cholesterol and glucose values and AST, ALT, ALP activities and decreased the total protein and albumin values [42].

Oxidative stress parameters are among the most important biochemical parameters affected by pesticides. Most environmental pollutants, including pesticides, have the ability to induce oxidative stress in almost all organisms, especially fish. Some studies with pesticide-treated fish revealed that pesticide treatment caused oxidative stress by increasing reactive oxygen species (ROS) in the cells and tissues of fish [43–45]. Oxidative stress negatively affects life of living creatures by causing genotoxic effects, lipid peroxidation and enzyme inhibitions. Lipid peroxidation, which occurs as a result of the toxic effects of pesticides, is an important indicator of oxidative stress and can be demonstrated by measuring malondialdehyde (MDA) levels [16, 46].

As in the other higher organisms, fish have important defense mechanisms to cope with oxidative stress. This defense mechanism, generally called as antioxidant, plays an important role in the survival of fish and in their adaptation to chemical stress. Antioxidant defense systems are composed of enzymatic components such as Paraoxonase (PON), superoxide dismutase (SOD), catalase (CAT), glutathione-S-transferase (GST), glutathione peroxidase (GPx), glutathione reductase (GR) and non-enzymatic components such as glutathione (GSH). SOD and CAT are important antioxidant enzymes that form the first defense mechanism against pesticides. GSH is also an important non-enzymatic antioxidant molecule that protects cells against the harmful effects of oxidative stress [16, 19, 46, 47].

Insecticides that contaminate aquatic systems not only cause toxic effects on fish but also adversely affect living creatures at higher trophic levels through the food chain and cause many negative situations in humans and animals. Insecticides cause significant changes on oxidative stress parameters in humans and animals as well as in fish. **Table 2** shows the effects of insecticides on oxidative stress parameters in experimental animal models.

6. Histopathological effects of insecticides

Pesticides have been widely used from past to present so that food production in the world is not affected by external factors. The most common use in the world is seen in the United States, and almost 15 billion dollars are spent annually for the pesticides [62, 63] and the most common of them is the herbicide glyphosate [62, 64]. Besides their use for sectoral beneficial results, they cause many metabolic disorders and lead to even death, especially due to their intake and absorption into the living body in various ways. OP compounds [65] are responsible for half of the deaths by inhibiting the acetylcholinesterase enzyme (AChE) in the central and autonomic nervous systems, lungs and neuromuscular junctions [62, 66, 67]. AChE inhibition increases cholinergic activity in both the central and peripheral nervous systems. Loss of consciousness, diarrhea, bronchospasm, paralysis and vomiting are the most typical symptoms of poisoning [62, 68], and death can occur as a result of respiratory failure [69, 70]. The toxicity of the substances taken into the organism, its chemical

structure, the human resources involved in the poisoning event and the quality of the institution providing medical support affect the mortality rate [71]. Almost half of the patients who are affected by pesticides and apply to the hospital are intubated due to their symptoms and receive ventilation support. Approximately 23–50% of patients in this condition die [72, 73]. The way to diagnose a significant part of the diseases and to obtain sufficient information about clinicopathological parameters is performed by assessing the samples taken from the organism in diseases or suspicious cases. In addition to determining the morphological characteristics of the tissues taken in this process, the role of scientists and especially the contributions of histopathologists in this field are undeniably important in evaluating and interpreting from different scientific dimensions also by using the latest developments in which science has evolved [74]. Histopathological changes are associated with complex biochemical and physiological responses to any stressor. Although histopathological parameters are not highly specific and do not provide quantitative information, they are popular biomarkers for environmental pollution [75]. The histopathological studies, one of the most promising areas for assessing animal health and response to different chemical species, include various studies that show generally cellular differences between control and pesticide-exposed animals [76]. Histopathological markers are considered very important in terms of showing the health status of the organism, together with other branches of science that provide data [77].

As a result of the intake, absorption and participation of pesticides in the systemic circulation and their effects on a cellular basis, the formation of biochemical and histopathological changes in tissue integrity and the emergence of negative symptoms are provided [7, 78–82]. The effects of environmental pollutants on fish tissues can also be determined by histopathological methods. Gills are especially important biomarkers as they are the first organ to encounter pollutants in the environment [13, 83]. In addition, the liver and kidneys are also target organs for the examination of histopathological and biochemical parameters [84]. In *Oncorhynchus mykiss*, as a result of application of clothianidin at different doses for 21 days, the histopathological state caused by this application in muscle, gill, brain and kidney tissues was examined and necrosis ranging from mild to severe in muscle tissue, atrophy and edema in myocytes, hyaline degeneration in muscle fibers and dissolution in connective tissue between myotomes were determined. In the gill tissue, primary and secondary lamella edema, secondary lamella fusion and hyperplasia, primary lamella hyperplasia, secondary lamella lifting, vasodilation, primary lamella thinning and secondary lamella shortening, and secondary lamella peculiar malformations were reported. Pericellular edema and necrosis, Purkinje cell degeneration, cell infiltration, congestion, gliosis, vascular dilatation and dystrophic changes were detected in the brain tissue. In kidney tissue, glomerular atrophy, decrease in hematopoietic tissue cells, tubular degeneration, and an increase in the number and spread of melanomacrophage centers depending on the increasing dose of clothianidin were observed [26].

The LC50 value (50% mortality) of malathion at the end of 96 hours in *Orthrias angorae* exposed to malathion administration was determined to be 3.0237 mg L^{-1} , and it was reported that the frequency of micronucleus formation in erythrocytes increased due to the increasing dose [85]. In a study with rainbow trout (*Oncorhynchus mykiss*) juveniles, the acute effects of maneb and carbaryl were examined and it was reported that edema and lamellar fusion, epithelial swelling and necrosis were observed in the gill lamellae of the fish [86]. In a study investigating the histopathological effects on the gill and kidney tissues of *Cyprinus carpio* as a result of acute application of deltamethrin, necrosis, spills, aneurysm, hemorrhages, edema, and hyperplasia were reported in the gills of fish [87]. Different doses of chlorpyrifos-based termifos pesticide were applied to *Clarias gariepinus*

(*African catfish*) fish for 5, 10 and 15 days. An increase in white blood cell counts and a decrease in erythrocyte counts and hematocrit levels were observed in fish [88]. In a study in which clothianidin, a neonicotinoid insecticide, was applied in rainbow trout for 7 and 21 days, it was reported that clothianidin caused hepatocellular degeneration, focal necrosis areas, sinusoidal dilatation and congestion, fibrous and vacuole formation, mild steatosis and pycnosis in the liver tissue, depending on the increasing dose [17].

In a study in which dichlorvos was administered in rats in a subacute manner [7], enlargement of Bowman's capsule, inflammatory cell infiltration, vascular occlusion, glomerular atrophy, and tubular degeneration areas were demonstrated in kidney tissue obtained from the substance-administered group. On the other hand, glomerular lobulation, tubular degeneration, separation in the basal lamina and inflammatory cell infiltration were observed in the group in which dichlorvos and vitamin E were administered. No significant decrease was observed in the severity and frequency of histological changes compared to the dichlorvos administered group (**Figure 3a–f**).

Carbon tetrachloride (CCl₄) is a fumigant used to kill insects in cereals and in a study examining the effects of green tea (*Camellia sinensis*) and parsley (*Petroselinum crispum*) diets against carbon tetrachloride hepatotoxicity in albino mice, liver degeneration, cellular infiltration, sinusoidal bleeding focuses, congestion and necrotic areas were observed in the CCl₄-administered group. No significant decrease in lesion severity and frequency was observed in the histopathological evaluation obtained from the groups using parsley and green tea separately with CCl₄ [89]. It was demonstrated that histopathological changes occurred in tissues at doses of 0.1 and 0.05 mg kg⁻¹ in mice exposed to deltamethrin. Degenerative and vascular changes in the liver, polymorphonuclear cell infiltration and focal necrosis

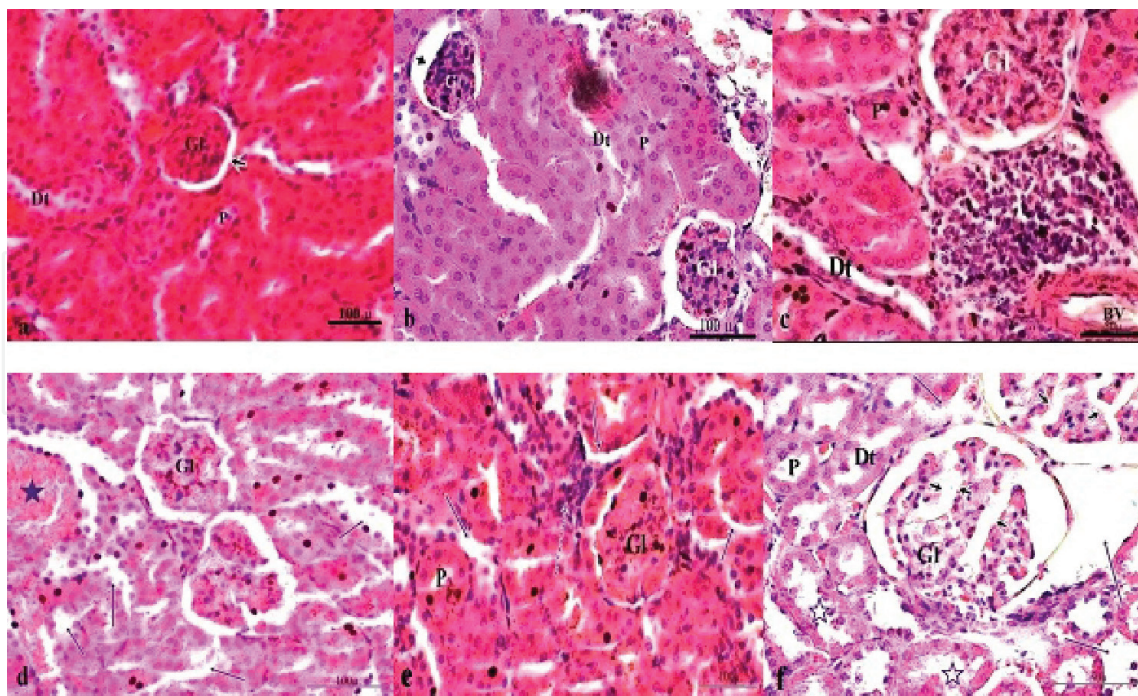


Figure 3.
 The effect of dichlorvos (5 mg/kg), corn oil (5 ml/kg) and vit-E (120 mg/kg) either separately or 1 h ago dichlorvos histology of renal section by using hematoxylin and eosin staining (H&E): (a) vit-E group; Gl: Glomeruli, P: Proximal tubule, Dt: Distal tubule, bowman capsule (arrow head), (b, c, d) Dichlorvos group; enlargement in bowman capsule and glomerular atrophy (arrow head), inflammatory cell infiltration (split arrows), BV: Blood vessel, vascular occlusion (asterisks), tubular degeneration (arrows), (e, f) Dichlorvos+vit-E; Gl: Separation in the basal lamina (arrows), tubular degeneration (asterisks), glomerular lobulation (arrow head), magnification: X 400, x 600, (bar: 50 μ , 100 μ) [7].

in hepatocytes were detected. Tubule degeneration and polymorphonuclear cell infiltration in the kidneys, and polymorphonuclear cell infiltration in the peribronchial and perivascular areas of the lungs were reported. Spermatogenic cell degeneration, tubule degeneration, and hyalinization in the seminiferous tubules were demonstrated in the testicles [90]. As a result of malathion application on *Channa punctatus*, the 96-hour LC50 value was determined to be 8.0 mg L^{-1} , sinusoidal dilatation and congestion were observed in the liver, and hypertrophy and pyknotic nuclei were detected in the hepatocytes. In the kidney, histopathological separation of the renal tubular epithelial layer from the basal membrane, vacuolization in the cytoplasm, renal tubule degeneration and necrosis, nuclear pyknosis and hypertrophy were reported in parallel with biochemically high creatinine, urea and BUN values. As the duration of exposure to malathion increased, damage to tissues increased in terms of severity and frequency [91].

7. Conclusion

Objective evaluation of biochemical markers is more practical than histological changes, and the formation of pathological damage in tissue occurs after the reflection of pesticide effects on biochemical parameters [92]. However, the results from histological evaluations alone do not necessarily indicate a direct effect of pesticides. In addition to the histopathological evaluation, examining other results and determining the source of the effects in the organism in this way will be accepted as a more accurate scientific approach. In response to the increasing human population on the planet we live in, the ever-increasing use of pesticides in order for agricultural production to meet this, and their presence at certain doses in food and the risk of mixing with the aquatic ecosystem is an important public health problem that will adversely affect the health of living creatures. Even exposure to pesticides in the above-mentioned amounts that are allowed to be taken into the body daily will cause accumulation in the body over a long period of time and, thus the changes primarily reflected in biochemical parameters, and, in the longer term, histopathological changes will occur due to increased tissue destruction. The oxidant/antioxidant balance in the organism may change in favor of oxidants as a result of external factors such as irregularity in physiological reactions or pesticide accumulation that may occur in the body. Thus, the changes occurring in cellular basis primarily provide outputs as a result of biochemical assessments, and when the damage reaches a textural dimension, histopathological results emerge following the changes in tissue integrity. The necessity of use of pesticides is an undeniable fact, considering the objectives it aims, but it is also known that there will be a decrease in pesticide use as a result of obtaining plant breeds, especially by making use of the developments in the field of biotechnology, that are more resistant to foreign factors such as insects, fungi, algae, weeds, bacteria, nematodes and rodents. In addition, more use of the biological control option against the factors that reduce the plant yield at a higher level will also produce beneficial results in terms of human health.



Author details

Haci Ahmet Deveci^{1*}, Gökhan Nur², Ayla Deveci³, Inan Kaya⁴,
Müge Mavioglu Kaya⁵, Abdulsamed Kükürt⁶, Volkan Gelen⁷,
Ömer Faruk Başer⁸ and Mahmut Karapehlivan⁸

1 Faculty of Health Sciences, Department of Nutrition and Dietetics, Gaziantep University, Gaziantep, Turkey

2 Faculty of Engineering and Natural Sciences, Department of Biomedical Engineering, Iskenderun Technical University, Hatay, Turkey

3 Vocational School of Technical Sciences, Kilis 7 Aralık University, Kilis, Turkey

4 Faculty of Science and Letters, Department of Biology, Kafkas University, Kars, Turkey

5 Faculty of Science and Letters, Department of Molecular Biology and Genetics, Kafkas University, Kars, Turkey

6 Faculty of Veterinary Medicine, Department of Biochemistry, Kafkas University, Kars, Turkey

7 Faculty of Veterinary Medicine, Department of Physiology, Kafkas University, Kars, Turkey

8 Faculty of Medicine, Department of Biochemistry, Kafkas University, Kars, Turkey

*Address all correspondence to: h.ahmet_deveci@hotmail.com

IntechOpen

© 2021 The Author(s). Licensee IntechOpen. This chapter is distributed under the terms of the Creative Commons Attribution License (<http://creativecommons.org/licenses/by/3.0>), which permits unrestricted use, distribution, and reproduction in any medium, provided the original work is properly cited. 

References

- [1] Akdoğan A, Divrikli U, Elçi L. Importance of pesticides and their effects on ecosystem. *Academic Food*. 2012; 1:125-132.
- [2] Kekillioğlu A, Bıçak Z. Investigation of pesticides and their effects on bees. *EJONS International Journal on Mathematic, Engineering and Natural Sciences*. 2020; 4(13):26-44.
- [3] Abdollahi M, Mostafalou S, Pournourmohammadi S, Shadnia S. Oxidative stress and cholinesterase inhibition in saliva and plasma of rats following subchronic exposure to malathion. *Comp. Biochem. Physiol. Part C*. 2004; 137: 29-34.
- [4] Ekebaş S, Çakır S, Ertuğrul O, Kence A. The detection of mutagenic activity of some chemicals (azamethypos, dichlorvos, methyl parathion, aflatoxin b1) by the smart test in drosophila melanogaster. *Turk. J. Vet. Anim. Sci*. 2000; 24(6):563-569.
- [5] Deveci HA, Karapehlivan M, Kaya I, Kükürt A, Alpay M. Protective effect of caffeic acid phenethyl ester against acute chlorpyrifos-ethyl poisoning. *Journal of Ankara University Faculty of Veterinary Medicine*. 2015; 62: 255-260.
- [6] Nur G, Husunet MT, Güler I, Deveci A, Koç E, Nur O, Kilic PA. The effect of caffeic acid phenethyl ester (CAPE) on hepatic histopathology and oxidative stress in rats treated with malathion. *Medicine Science*. 2018; 7(3): 604-609.
- [7] Nur G, Deveci HA, Koç E. Preservation of vitamin-E against nephrotoxic effect induced by subacute Dichlorvos application. *Fresenius Environmental Bulletin*. 2021; 30(7): 8651-8659.
- [8] Daş YK, Aksoy A. Pesticides. *Türkiye Klinikleri Veterinary Sciences- Pharmacology and Toxicology - Special Topics*. 2016; 2(2): 1-17.
- [9] Chawla P, Kaushika R, Swarajb VJS, Kumarb N. Organophosphorus pesticides residues in food and their colorimetric detection, *Environmental Nanotechnology, Monitoring & Management*, 2018; 10:292-307.
- [10] Hassaan MA, El Nemr A. Pesticides pollution: Classifications, human health impact, extraction and treatment techniques. *Egyptian Journal of Aquatic Research*. 2020; 46: 207-220.
- [11] Ceron JJ, Panizo CG, Montes A. Toxicological effects in rabbits induced by endosulfan, lindane and methylparathion representing agricultural by products contamination. *Bull. Environ. Contam. Toxicol.*, 1995; 54: 258-265.
- [12] Madej K, Kalenik TK, Piekoszewski W. Sample preparation and determination of pesticides in fat-containing foods. *Food Chemistry*. 2018; 269: 527-541.
- [13] Kayhan FE. Cycle of Insecticides in Nature and Effects on Aquatic Environment. *Selçuk University Faculty of Science Journal of Science*. 2020; 46(2): 29-40.
- [14] Buah-Kwofie A, Humphries MS, Pillay L. Bioaccumulation and risk assessment of organochlorine pesticides in fish from a global biodiversity hotspot: Simangaliso Wetland Park, South Africa. *Science of The Total Environment* 2018; 621: 273-281.
- [15] Kapsi M, Tsoutsis C, Paschalidou A, Albanis T. Environmental monitoring and risk assessment of pesticide residues in surface waters of the Louros River (N.W. Greece). *Science of The Total Environment*. 2019; 650: 2188-2198.

- [16] Fırat Ö, Aytekin T. Effect of neonicotinoid insecticide Thiamethoxam on oxidative stress parameters in *Oreochromis niloticus*. Journal of Balıkesir University Institute of Science and Technology, 2018; 20(2): 224-234.
- [17] Dogan D, Deveci HA, Nur G. Manifestation of oxidative stress and liver injury in clothionidin exposed *Oncorhynchus mykiss*. Toxicology Research, 2021a; 10 (3): 501-510. DOI: 10.1093/toxres/tfab027.
- [18] Costa LG, Giordano G, Guizzetti M, Vitalone A. Frontiers in Bioscience 2008; 13: 1240-1249.
- [19] Deveci HA, Karapehlivan M. Chlorpyrifos-induced parkinsonian model in mice: Behavior, histopathology and biochemistry. Pesticide Biochemistry and Physiology. 2018; 144: 36-41.
- [20] Eyer P, Szinicz L, Thiermann H, Worek F, Zilker T. Testing of antidotes for organophosphorus compounds: Experimental procedures and clinical reality. Toxicology. 2007; 233(1-3): 108-119.
- [21] Karalliedde LD, Edwards P, Marrs TC. Variables influencing the toxic response to organophosphates in humans. Food Chem Toxicol, 2003; 41:1-13
- [22] Demirdöğen BC. Organophosphate pesticide poisoning and the role of serum Paraoxonase 1 (PON1) enzyme in organophosphate metabolism. Turkish Hygiene Experimental Bio. Journal., 2010; 67(2): 97-112.
- [23] Ozkaya G, Çeliker A, Koçer-Giray B. Insecticide poisoning and evaluation of the situation in Turkey. Turkish Hygiene Experimental Bio. Journal., 2013; 70(2): 75-102.
- [24] Evangelista de Duffard AM, Duffard R. Behavioral toxicology, risk assessment, and chlorinated hydrocarbons. Environ Health Perspect, 1996; 104(2): 353-360.
- [25] Nur G, Deveci HA, Ersan Y, Merhan O, Nazli M, Nur O. Protective role of caffeic acid phenethyl ester against tetramethrine-induced toxicity in mice. Medicine Science. 2016; 5(4): 972-978.
- [26] Dogan D, Nur G, Deveci HA. Tissue-specific toxicity of clothianidin on rainbow trout (*Oncorhynchus mykiss*). Drug and Chemical Toxicology. 2021b; 1:1-11. DOI: 10.1080/01480545.2021.1892128.
- [27] Kükürt A, Kuru M, Karapehlivan M. Nitrik oksit, nitrik oksit sentaz ve dişi üreme sistemindeki rolleri. In: Evereklioğlu C, editor. Sağlık Bilimleri Alanında Akademik Çalışmalar-II, Gece Kitaplığı; 2020, p. 113-23.
- [28] Kükürt A. Doğal bir antioksidan olarak propolis tedavisinin koruyucu etkileri. In: Evereklioğlu C, editor. Sağlık Bilimlerinde Teori ve Araştırmalar II, Gece Kitaplığı; 2020, p. 501-15.
- [29] Kükürt A, Kuru M, Faruk Başer Ö, Karapehlivan M. Kisspeptin: Role in Female Infertility. In: Marsh C, editor. Reproductive Hormones, IntechOpen; 2020. <https://doi.org/10.5772/intechopen.94925>.
- [30] Başer ÖF, Kükürt A, Karapehlivan M. Oksidatif stresin azaltılmasında anjiyotensin dönüştürücü enzimin rolü. In: Evereklioğlu C, editor. Sağlık Bilimlerinde Teori ve Araştırmalar II, Gece Kitaplığı; 2020, p. 243-53.
- [31] Kuru M, Kükürt A, Oral H, Öğün M. Clinical Use of Progesterone and Its Relation to Oxidative Stress in Ruminants. In: Drevenšek G, editor. Sex Hormones in Neurodegenerative Processes and Diseases, InTechOpen; 2018, p. 303-27. <https://doi.org/10.5772/intechopen.73311>.

- [32] Gelen V, Kükürt A, Şengül E, Başer ÖF, Karapehlivan M. Can Polyphenols be Used as Anti-Inflammatory Agents against Covid-19 (SARS-CoV-2)-Induced Inflammation? [Online First], IntechOpen, DOI: 10.5772/intechopen.98684. Available from: <https://www.intechopen.com/online-first/77746>
- [33] Gelen V, Kükürt A, Şengül E. Role of the Renin-Angiotensin-Aldosterone System in Various Disease Processes: An Overview [Online First], IntechOpen, DOI: 10.5772/intechopen.97354. Available from: <https://www.intechopen.com/online-first/76612>
- [34] Kükürt A, Gelen V, Başer OF, Deveci HA, Karapehlivan M. Thiols: Role in Oxidative Stress-Related Disorders [Online First], IntechOpen, DOI: 10.5772/intechopen.96682. Available from: <https://www.intechopen.com/online-first/75841>
- [35] Kurutaş EB, Kılınç M. Effect of pesticides on biological systems. Archive Source Review Journal, 2003; 12:215-228
- [36] Çömelekoğlu Ü, Mazmancı B, Arpacı A. Examination of liver functions in agricultural workers exposed to the chronic effects of pesticides. Turk J Biol, 2000; 24: 461-466.
- [37] Mutlu F, Şimşek Z, Cici M. Investigation of cholinesterase inhibitors and liver enzyme levels in pesticide sales workers in the GAP Region. Harran Univ Veterinary Faculty Journal, 2017; 6 (1): 57-62.
- [38] Abdel-Daim MM, Abushouk AI, Alkhalf MI, Toraih EA, Fawzy MS, Ijaz H, Aleya L, Bungau SG. Antagonistic effects of *Spirulina platensis* on diazinon-induced hemato-biochemical alterations and oxidative stress in rats. Environmental Science and Pollution Research. 2018; 25:27463-27470.
- [39] Karamese M, Aydin H, Gelen V, Sengul E, Karamese SA. The antiinflammatory, anti-oxidant and protective effects of a probiotic mixture on organ toxicity in a rat model. Future Microbiol. 2020;15:401-12. <https://doi.org/10.2217/fmb-2020-0005>.
- [40] Jaiswal SK, Gupta VK, Siddiqi NJ, Pandey RS, Sharma Bechan. Hepatoprotective effect of *Citrus limon* fruit extract against Carbofuran induced toxicity in Wistar Rats. Chinese Journal of Biology. 2015; 1-10.doi. [org/10.1155/2015/686071](https://doi.org/10.1155/2015/686071).
- [41] Saravanan M, Prabhu Kumar K, Ramesh M. Haematological and biochemical responses of freshwater teleost fish *Cyprinus carpio* (Actinopterygii: Cypriniformes) during acute and chronic sublethal exposure to lindane. Pest Biochem Physiol. 2011; 100:206-211.
- [42] El-Sayed YS, Saad TT. Subacute intoxication of a deltamethrinbased preparation (Butox® 5% EC) in monosex Nile tilapia, *Oreochromis niloticus* L. Bas. Clinic Pharmacol Toxicol. 2007; 102:293-299.
- [43] Yonar, ME, Sakin F. Ameliorative effect of lycopene on antioxidant status in *Cyprinus carpio* during pyrethroid deltamethrin exposure. Pesticide Biochemistry and Physiology.2011; 99: 226-231.
- [44] Deveci HA, Unal S, Karapehlivan M, Ayata MK, Gaffaroğlu M, Kaya I, Yılmaz M. Effects of glyphosate (herbicide) on serum paraoxonase activity, high density lipoprotein, total antioxidant and oxidant levels in Kars Creek Transcaucasian Barbs (*Capoeta capoeta* [Guldenstaedt, 1773]). Fresenius Environmental Bulletin. 2017; 26(5), 3514-3518.
- [45] Nur G, Deveci HA. Histopathological and biochemical

- responses to the oxidative stress induced by glyphosate-based herbicides in the rainbow trout (*Oncorhynchus mykiss*). *Journal of Cellular Neuroscience and Oxidative Stress*. 2018; 10(1), 656-665.
- [46] Toroser D, Orr WC, Sohal RS. Carbonylation of mitochondrial proteins in *Drosophila melanogaster* during aging, *Biochemical and Biophysical Research Communications*. 2007; 363: 418-424.
- [47] Zirong X, Shijun B. Effects of waterborne Cd exposure on glutathione metabolism in Nile tilapia (*Oreochromis niloticus*) liver. *Ecotoxicology and Environmental Safety*. 2007; 67: 89-94.
- [48] Deveci HA, Kükürt A, Nur G, Kaya I. Effect of Chlorpyrifos-ethyl application on sialic acid, malondialdehyde and nitric oxide levels in *Cyprinus carpio* (L. 1758). *Kafkas University, Journal of Science Institute*. 2016; 9 (2): 46-51.
- [49] Kopjar N, Žunec S, Mendaš G, Micek V, Kašuba V, Mikolić A. Evaluation of chlorpyrifos toxicity through a 28-day study: cholinesterase activity, oxidative stress responses, parent compound/metabolite levels, and primary DNA damage in blood and brain tissue of adult male Wistar rats. *Chem Biol Interact*. 2018; 279:51-63.
- [50] Yonar ME. Protective Effect of Lycopene on oxidative stress and antioxidant status in *Cyprinus carpio* during Cypermethrin exposure. *Environmental Toxicology*. 2013; 28(11):609-616. doi: 10.1002/tox.20757
- [51] Al-Shaikh TM. Protective antioxidant effect of garlic against cypermethrin induced lung toxicity in adult male mice. *Biochemical and Histopathological studies Life Science Journal*. 2012; 9(4): 4017-4025.
- [52] Raina R, Verma PK, Pankaj NK, Kant V, Prawez S. Protective role of L-ascorbic acid against cypermethrin-induced oxidative stress and lipid peroxidation in Wistar rats. *Toxicological & Environmental Chemistry*. 2010; 92(5): 947-953.
- [53] Bagherpour H, Malekshah AK, Amiri FT, Azadbakht M. Protective effect of green tea extract on the deltamethrin-induced toxicity in mice testis: An experimental study. *International Journal of Reproductive BioMedicine*. 2019; 17: 337-348. doi. org/10.18502/ijrm.v17i5.4601.
- [54] Shivanoor SM, David M. Reversal of deltamethrin-induced oxidative damage in rat neural tissues by turmeric diet: Fourier transform-infrared and biochemical investigation. *Zoology the Journal of Basic & Applied Zoology*. 2016; 77:56-68.
- [55] Ali M, Mirvaghefi A, Asadi F. Effects of vitamin E, selenium and vitamin C on various biomarkers following oxidative stress caused by diazinon exposure in rainbow trout. *Ege J Fish Aqua Sci*. 2015; 32(3): 151-158. DOI: 10.12714/egejfas.2015.32.3.05.
- [56] El-Shenawy NS, El-Salmy F, Al-Eisa RA, El-Ahmary B. Amelioratory effect of vitamin E on organophosphorus insecticide diazinon-induced oxidative stress in mice liver. *Pesticide Biochemistry and Physiology*. 2010; 96:101-107. doi:10.1016/j.pestbp.2009.09.008.
- [57] Varó I, Navarro JC, Nunes B, Guilhermino L. Effects of dichlorvos aquaculture treatments on selected biomarkers of gilthead sea bream (*Sparus aurata* L.) fingerlings. *Aquaculture*. 2007; 266:87-96
- [58] Chaudhary B, Bist R. Protective manifestation of bacoside A and bromelain in terms of cholinesterases, gamma-amino butyric acid, serotonin level and stress proteins in the brain of dichlorvos-intoxicated mice. *Cell Stress Chaperones*. 2017; 22(3):371-376.

- [59] Ibrahim AT. Biochemical and histopathological response of *Oreochromis niloticus* to malathion hepatotoxicity. *J. Royal. Sci.* 2019; 1(1): 10-15.
- [60] Ali RI, Ibrahim MA. Malathion induced testicular toxicity and oxidative damage in male mice: the protective effect of curcumin. *Egypt J Forensic Sci.* 2018; 8(70):1-13 doi.org/10.1186/s41935-018-0099-x. Protective Effect of Lycopene on Oxidative Stress and Antioxidant Status in *Cyprinus carpio* during Cypermethrin Exposure
- [61] Mohammadzadeh L, Hosseinzadeh H, Abnous K, Razavi BM. Neuroprotective potential of crocin against malathion-induced motor deficit and neurochemical alterations in rats. *Environ Sci Pollut Res.* 2018; 25(5): 4904-4914.
- [62] Hulse EJ, Smith SH, Wallace WA, Dorward DA, Simpson AJ, Drummond G, Clutton RE, Eddleston M. Development of a histopathology scoring system for the pulmonary complications of organophosphorus insecticide poisoning in a pig model. *PLoS ONE.* 2020; 15(10): e0240563.
- [63] A look at fertilizer and pesticide use in the US New York, USA: gro-intelligence.com; 2018. Available from: <https://gro-intelligence.com/insights/articles/a-look-at-fertilizer-and-pesticide-use-in-the-us>.
- [64] Atwood D, Paisley-Jones C. Pesticides Industry Sales and Usage 2008-2012 Market Estimates. Washington, USA: Office of Pesticide Programs US Environmental Protection Agency, 2017.
- [65] Gunnell D, Eddleston M, Phillips MR, Konradsen F. The global distribution of fatal pesticide self-poisoning: Systematic review. *Bmc Public Health.* 2007; 7:357-373.
- [66] Patočka J, Kuča K, Jun D. Acetylcholinesterase and butyrylcholinesterase—important enzymes of human body. *Acta Medica (Hradec Kralove).* 2004; 47(4):215-228.
- [67] Fryer AD, Lein PJ, Howard AS, Yost BL, Beckles RA, Jett DA. Mechanisms of organophosphate insecticide-induced airway hyperreactivity. *American Journal of Physiology-Lung Cellular and Molecular Physiology.* 2004; 286(5):L963-L9L9.
- [68] Namba T. Poisoning due to organophosphate insecticides-acute and chronic manifestations. *American Journal of Medicine.* 1971; 50(4):475-492.
- [69] Chang C, Chuang M, Lee C, Hsieh M. Outcome of Organophosphate Poisoning with Acute Respiratory Failure: A 10-Year Study. *AJRCCM.* 2020; 201: A5354.
- [70] Banday TH, Tathineni B, Desai MS, Naik V. Predictors of Morbidity and Mortality in Organophosphorus Poisoning: A Case Study in Rural Hospital in Karnataka, India. *North American journal of Medical Sciences.* 2015; 7(6):259-265.
- [71] Eddleston M. Novel clinical toxicology and pharmacology of organophosphorus insecticide self-poisoning. *Annual review of pharmacology and toxicology.* 2019; 59:341-360.
- [72] Alahakoon C, Dassanayake TL, Gawarammana IB, Weerasinghe VS, Buckley NA. Differences between organophosphates in respiratory failure and lethality with poisoning post the 2011 bans in Sri Lanka. *Clinical Toxicology (Phila).* 2019; 466-470.
- [73] Muley A, Shah C, Lakhani J, Bapna M, Mehta J. To identify morbidity and mortality predictors in acute organophosphate poisoning. *Indian*

journal of critical care medicine:
peer-reviewed, official publication of
Indian Society of Critical Care
Medicine. 2014; 18(5):297-300.

[74] Doğan Ö. Standardization in the
process of histopathological diagnosis.
Aegean Pathology Journal. 2005; 2:8-28.

[75] Hinton DE, Lauren DJ. Liver
structural alterations accompanying
chronic toxicity: potential biomarkers of
exposure. In: McCartney JF, Shugart LR
(eds): Biomarkers of environmental
contamination (pp 15-57). Boca Raton,
FL: Lewis Publ., 1990.

[76] Niimi AJ. Review of biochemical
methods and other indicators to assess
fish health in aquatic ecosystems
containing toxic chemicals. J Great
Lakes Res. 1990; 16:529-541.

[77] Van der Oost R, Beyer J,
Vermeulen NP. Fish bioaccumulation
and biomarkers in environmental risk
assessment: a review. Environ Toxicol
Pharmacol. 2003; 13:57-149.

[78] Clasen B, Loro VL, Murussi CR,
Tiecher TL, Moraes B, Zanella R.
Bioaccumulation and oxidative stress
caused by pesticides in *Cyprinus carpio*
reared in a rice-fish system. Science of
The Total Environment. 2018;
626(1):737-743.

[79] Gaaied S, Oliveira M, Le Bihanic F,
Cachot J, Banni M. Gene expression
patterns and related enzymatic activities
of detoxification and oxidative stress
systems in zebrafish larvae exposed to
the 2,4-Dichlorophenoxyacetic acid
herbicide. Chemosphere. 2019;
224:289-297.

[80] Volschenka CM, Ikenak Y,
Yohannes YB, Nakayama SM,
Ishizuka M, Smith E, Van Vuren JMJ,
Greenfield R. Baseline bio-accumulation
concentrations and resulting oxidative
stress in *Synodontis zambezensis* after
an acute laboratory exposure to

4,4' - DDT. Pesticide Biochemistry and
Physiology. 2019; 156:44-55.

[81] Kaya I., Yilmaz M., Koç E.,
Deveci H.A., Ersan Y., Karapehlivan M.
Investigation of the serum total
antioxidant, oxidant and sialic acid
levels of *Cyprinus carpio* (l. 1758) treated
with tebuconazole (fungicide). Journal
of FisheriesSciences com. 2014; 8(3):
214-219.

[82] Kaya, I., Onen O., Kaya M.M,
Kükürt A., Deveci H.A,
Karapehlivan M. The effects of
organophosphorus pesticides on some
biochemical markers in Teleosts. In:
New Trends in Health Sciences.
Duran N. (ed.), Livre de Lyon. Lyon.
France. 2021; p. 213-227.

[83] Akbulut C, Kaymak G, Esmer HE,
Yön ND, Kayhan FE. Mechanisms of
oxidative stress induced by heavy metals
and pesticides in fish. Ege J Fish Aqua
Sci. 2014; 31(3):155-160.

[84] Akbulut C, Öztürk B,
Uzun A, Yon ND. Tribenuron methyl
exposure inhibits oogenesis in
zebrafish *Danio rerio* (Hamilton, 1822).
Indian Journal of Fisheries. 2017;
3:127-131.

[85] Gül S, Nur G, Kaya Ö.T, Kamber U,
Gürgegin B. Detection of micronuclei in
peripheral erythrocytes of *Orthrias*
angora (Steindachner, 1897) exposed to
malathion. Fresenius Environmental
Bulletin. 2007; 16(5):472-476.

[86] Boran H, Altinok I, Capkin E.
Histopathological changes induced by
maneb and carbaryl on some tissues of
rainbow trout, *Oncorhynchus mykiss*.
Tissue and Cell. 2010; 42(3):158-164.

[87] Cengiz EI. Gill and kidney
histopathology in the freshwater fish
Cyprinus carpio after acute exposure to
deltamethrin. Environmental
Toxicology and Pharmacology. 2006;
22(2):200-204.

[88] Nwani CD, Ugwu DO, Okeke OC, Onyishi GC, Ekeh FN, Atama C, Eneje LO. Toxicity of the chlorpyrifos-based pesticide Termifos: effects on behaviour and biochemical and haematological parameters of African catfish *Clarias gariepinus*. *African Journal of Aquatic Science*. 2013; 38(3):255-262.

[89] Guven A, Nur G, Deveci HA. Effect of Green tea (*Camellia sinensis* L.) and Parsley (*Petroselinum crispum*) Diets Against Carbon Tetrachloride Hepatotoxicity in Albino Mice. *Fresenius Environmental Bulletin*. 2019; 28(9):6521-6527.

[90] Tewari A, Banga HS, Gill JPS. Sublethal chronic effects of oral dietary exposure to deltamethrin in Swiss albino mice. *Toxicology and Industrial Health*. 2018; 34(6):1-10.

[91] Bharti S, Razool F. Analysis of the biochemical and histopathological impact of a mild dose of commercial malathion on *Channa punctatus* (Bloch) fish. *Toxicology Reports*. 2021; 8:443-455.

[92] Ewald G. Chronic measures of toxicant-induced effects on fish. *Ann Zool Fennici*. 1995; 32:311-316.