

We are IntechOpen, the world's leading publisher of Open Access books Built by scientists, for scientists

6,900

Open access books available

186,000

International authors and editors

200M

Downloads

Our authors are among the

154

Countries delivered to

TOP 1%

most cited scientists

12.2%

Contributors from top 500 universities



WEB OF SCIENCE™

Selection of our books indexed in the Book Citation Index
in Web of Science™ Core Collection (BKCI)

Interested in publishing with us?
Contact book.department@intechopen.com

Numbers displayed above are based on latest data collected.
For more information visit www.intechopen.com



Extra-Intestinal Features of Crohn's Disease

Monjur Ahmed

Abstract

Although Crohn's disease is a chronic inflammatory disease of the gastrointestinal tract, it can affect multiple organs behaving like a multisystem immune mediated disease. The dysregulated immune system in patients with Crohn's disease leads to uncontrolled inflammation which primarily affects the gastrointestinal tract but may also affect various extra-intestinal organs. With the increased incidence and prevalence of Crohn's disease, its extra-intestinal manifestations are increasingly being seen in our clinical practice. The musculoskeletal, mucocutaneous, ophthalmic, hepatobiliary, renal, cardiovascular and pulmonary manifestations of Crohn's disease have been reviewed in this chapter. Some of these extra-intestinal manifestations are due to systemic inflammation, some of them are due to malabsorption of nutrients and bile salts, and some due to medications given for the treatment of Crohn's disease. These extra-intestinal manifestations of Crohn's disease are seen in at least 25% of patients with Crohn's disease. Some of them correlate well with Crohn's disease activity but the rest of them have no relation to the activity of Crohn's disease. Although most of the time the extra-intestinal features are seen after the diagnosis of Crohn's disease, they can precede or follow the diagnosis of Crohn's disease. Management of these extra-intestinal manifestations varies as the ones associated with activity of Crohn's disease respond to remission of Crohn's disease whereas the ones not related to the activity of Crohn's disease require specific treatments for those conditions.

Keywords: extra-intestinal manifestations of Crohn's disease, musculoskeletal manifestations of Crohn's disease, mucocutaneous manifestations of Crohn's disease, ophthalmic manifestations of Crohn's disease, hepatobiliary, renal, cardiovascular and pulmonary manifestations of Crohn's disease

1. Introduction

Crohn's disease is an idiopathic chronic, relapsing inflammatory condition that mainly affects the gastrointestinal tract but can also involve extra-intestinal sites. As the incidence and prevalence of this disease is increasing, we are also seeing more and more extra-intestinal features of this disease [1, 2]. Crohn's disease and ulcerative colitis are the two main forms of inflammatory bowel diseases and both of them have extra-intestinal manifestations. In this chapter, we will be focusing on the extra-intestinal features of Crohn's disease.

The gastrointestinal tract plays an important role in immune regulation. The innate and adaptive immunity becomes dysregulated in Crohn's disease. This generally occurs in a genetically susceptible individual due to environmental factors

and altered gut microbiota. As the immune homeostasis is disrupted, uncontrolled inflammation occurs in the gut. The inflammatory process can become systemic and other organs can be involved as well. At least 25% of patients with Crohn's disease develop extra-intestinal manifestations [3]. Joints, bones and skin are most commonly involved. Other organs of involvement include muscles, eyes, oral mucosa, hepatobiliary system, kidneys and lungs [4]. Some of these manifestations correlate with disease activity and some of them have no correlation with disease activity. Most of the time joint, eye and skin involvement correlate with intestinal inflammatory disease activity. Active Crohn's disease can reduce fertility in women due to decreased ovarian reserve. This results in decreased anti-Mullerian hormone (AMH) level in the blood in women above age 30 years with active Crohn's colitis compared to healthy control women [5]. Patients' with Crohn's disease have significantly increased risk of developing anxiety and depression, particularly in the year after the initial diagnosis of Crohn's disease [6]. The pooled prevalence of anxiety and depression in Crohn's disease was found to be 31% and 24.4% respectively in a systematic review [7]. Extra-intestinal manifestations (EIMs) are more prevalent in patients with Crohn's colitis although these manifestations may precede the development of colitis, be synchronous with colitis, follow the diagnosis of Crohn's disease or persist even after colitis subsides. Patients with one EIM are at increased risk of developing another EIM. In fact, 25% of the patients have more than one EIM.

2. Musculoskeletal manifestations

As mentioned before musculoskeletal system involvement is common and these include arthralgia, arthritis, pseudoarthritis, hypertrophic osteoarthropathy, osteopenia, osteoporosis, aseptic necrosis of the hip and other joints, psoas abscess, osteomyelitis and sarcopenia. Peripheral arthralgia occurs in about 20% of patients with Crohn's disease and is strongly associated with Crohn's colitis [8]. About 15 to 20% patients with Crohn's disease develop arthritis [9]. Approximately 60 to 70% of arthritis is peripheral large joint arthritis. Knees, ankles, wrists, elbows and hips are most commonly affected. Oligoarticular arthritis affecting less than 5 joints is seen in 6% of patients with Crohn's disease, and polyarticular arthritis affecting 5 or more joints affects 4% of patients with Crohn's disease [10]. A minority of patients with Crohn's disease may develop symmetrical polyarthritis affecting proximal interphalangeal, metacarpophalangeal, and metatarsophalangeal joints similar to the presentation of rheumatoid arthritis. 1 to 6% of patients with Crohn's disease develop ankylosing spondylitis affecting the spine and sacroiliac joints. Patients with ankylosing spondylitis present with low back pain and gradually they develop spinal fusion over a period of time. As many as two-third of patients with Crohn's disease with ankylosing spondylitis are HLA-B27 positive [11]. Small joint polyarthritis and ankylosing spondylitis can flare up without any increased activity of Crohn's disease. Pseudoarthritis presenting as diffuse joint aches can occur following glucocorticoids withdrawal. Aseptic necrosis of joints (particularly hip joints) can occur in Crohn's disease due to hypercoagulable state and fibrin microclot formation occluding the epiphyseal capillaries [12]. Either short term high dose or long term corticosteroid therapy can also predispose the patients with Crohn's disease to aseptic necrosis of bone (i.e. cellular death of bone) which can cause severe pain and disability [13]. In one study, 2.1% of patients with inflammatory bowel disease had aseptic necrosis of the hip on computerized tomography [14]. Crohn's disease leads to low mineral density which is seen even at time of diagnosis. Proinflammatory cytokines like tumor necrosis factor, smoking, calcium

and vitamin D malabsorption and low body mass index (BMI) are contributing factors although use of glucocorticoids is the main risk factor [15, 16]. Osteopenia (T score – 1.0 to –2.49) and osteoporosis (T score – 2.5 and lower) are seen in 30 to 60% of patients with Crohn's disease. 60% of patients with Crohn's disease also develop sarcopenia that is strongly related to osteopenia and osteoporosis [17].

In a nutshell, the various manifestations are as follows:

- Arthritis
 - a. Large joint
 - 1. Polyarticular
 - 2. Oligoarticular
 - b. Symmetrical small joint
 - c. Ankylosing spondylitis
- Peripheral arthralgia
- Pseudoarthritis
- Hypertrophic osteoarthropathy
- Osteopenia, osteoporosis
- Sarcopenia
- Aseptic necrosis of the hip and other joints
- Psoas abscess
- Osteomyelitis

3. Mucocutaneous manifestations

Cutaneous manifestations occur in almost one third of patients with Crohn's disease. Erythema nodosum (EN) and pyoderma gangrenosum (PG) are the most common cutaneous lesions seen in Crohn's disease although these lesions can also be seen in other disorders [18]. EN appears as an erythematous subcutaneous tender nodule, most commonly seen on the pretibial region (**Figure 1**). In Crohn's disease, EN is more commonly seen in females than in males. It tends to occur during the first 2 years of clinical course and is associated with exacerbation of large joint arthritis and colitis, and generally improves with the treatment of Crohn's disease [19]. It is recommended not to biopsy EN because of risk of scar tissue formation.

PG generally presents as painful ulcers with sharply circumscribed and demarcated violaceous borders and crater-like holes at the necrotic yellowish base, most commonly seen on the extensor surface of the lower extremities but can occur anywhere on the body [20]. Sometimes PG can present tender nodules or pustules [21]. PG is a chronic debilitating skin disorder and is not associated with Crohn's

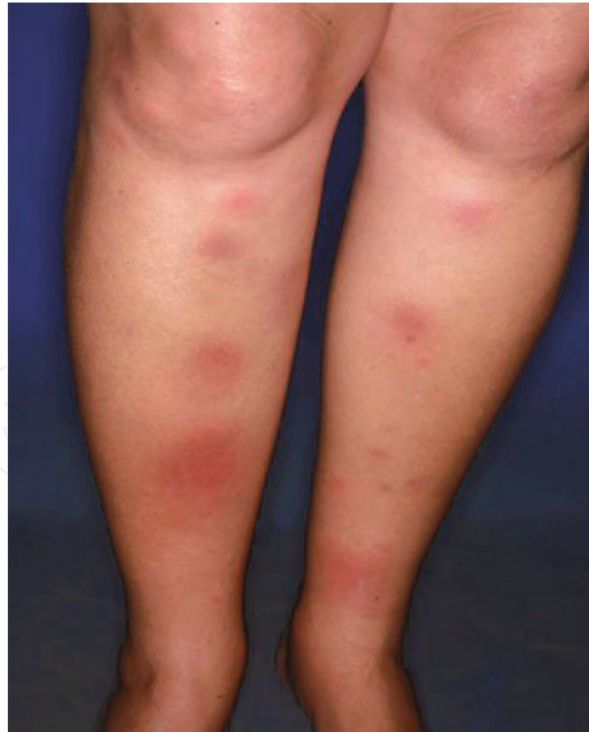

Figure 1.
Erythema nodosum.

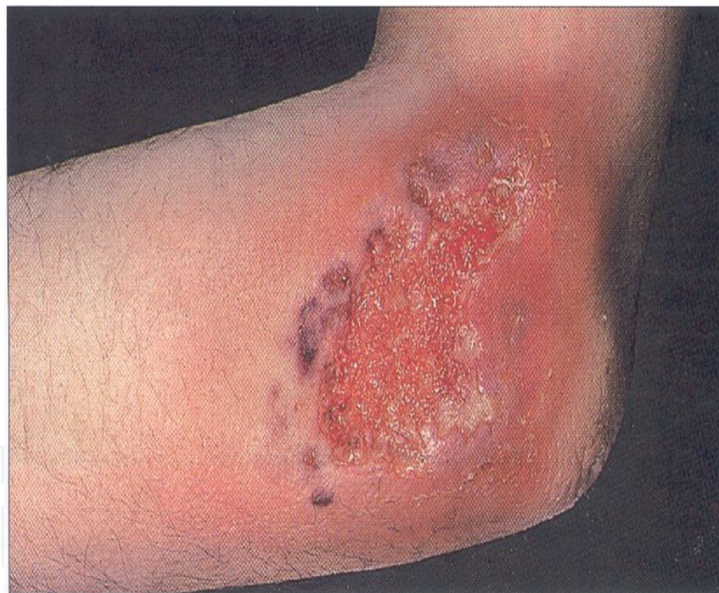

Figure 2.
Pyoderma gangrenosum.

disease activity. Histologically it is a neutrophilic dermatosis characterized by infiltration of neutrophils into the skin. Pathergy phenomenon (i.e. formation of large ulcers in response to minor trauma) is characteristic of PG. PG heals up with cribriform scars (**Figure 2**).

Sweet's syndrome (SS) is another neutrophilic dermatosis rarely associated with Crohn's disease. Patients present with painful erythematous or violaceous papular or nodular lesions on the face, neck or upper extremity with abrupt onset of fever and neutrophilic leukocytosis [22].

Oral mucosa can be affected in Crohn's disease. Lips are the most common sites of oral Crohn's disease [23]. Lips become swollen with vertical fissures due to

granulomatous involvement of the lips. Aphthous ulcers or stomatitis (AS) occurs in 20 to 30% of patients with Crohn's disease [24]. Pyostomatitis vegetans (PV) is another rare lesion associated with Crohn's disease. It is characterized by 'snail track' shaped flat yellowish ulcers in the oral and gingival mucosa [25].

Another rare cutaneous manifestation of Crohn's disease is metastatic Crohn's disease (MCD). It can present as papule, nodule, plaque or ulcer with a predilection for skin folds, external genitalia (penis, vulva), perineum, infra-mammary area, limbs and retroauricular area [26]. It is so called because of the presence of non-caseating granuloma (histologically identical to the primary intestinal lesion) in the skin that is remote from the gastrointestinal tract [27]. MCD can precede or develop simultaneously with intestinal Crohn's disease. No clear correlation is found between MCD and intestinal Crohn's disease activity [28].

The prevalence of psoriasis is 8 times higher in patients with Crohn's disease than that in the general population due to overlapping genetic and immunopathogenic mechanisms [29]. There is also increased incidence of epidermolysis bullosa acquisita and leucocytoclastic vasculitis in patients with Crohn's disease [30, 31]. Epidermolysis bullosa acquisita (EBA) appears as subepidermal blistering skin lesion over the extensor aspect of the body, particularly on trauma prone areas, and is associated with scarring, milia formation and skin fragility. EBA occurs due to autoimmunity to type VII collagen present at the dermoepidermal junction and is associated with symptomatic esophageal web formation [32]. Leucocytoclastic vasculitis (LCV) is another very rare dermatologic manifestation of Crohn's disease and presents as palpable purpura over the lower extremities and ankles [33]. EN, AS, PV, SS and LCV can be associated with increased intestinal inflammatory activity.

Dermatologic manifestations secondary to malabsorption of nutrients can occur. These include angular cheilitis due to riboflavin deficiency, purpura due to vitamin K deficiency and acrodermatitis enteropathica (AE) due to zinc deficiency. AE appears as eczematoid and psoriasiform patchy skin lesions on the extremities and peri-orificially. AE can also cause alopecia [34].

Patients with Crohn's disease are at increased risk of developing melanoma of the skin [35].

Certain skin lesions are due to the medications used to control Crohn's disease. Anti-tumor necrosis factor (TNF) agents can cause paradoxical psoriasiform rash over the palmar aspect of hands, planter aspects of feet, flexures and scalp in about 5% of patients [36]. Risk factors for developing this rash include female sex, obesity, smoking (active or past), short duration of disease and family history of inflammatory skin disease [37]. The pathogenesis of development of this anti-TNF-induced psoriasiform rash is exactly not known. But increased concentration of IL-17/IL-22 expressing Th17 cells and interferon (IFN)- γ -expressing Th1 cells are seen in the rash [36, 38]. IFN- α may also play a role in the formation of this rash. Normally TNF decreases the production of IFN- α by inhibiting the maturation of plasmacytoid dendritic cells. Anti-TNF therapy may lead to overproduction of IFN- α [39]. Increased concentration of IFN- α protein is found in anti-TNF associated psoriasiform rash. Another mechanism could be anti-TNF-induced patchy cutaneous immune suppression leading to the formation of psoriasiform rash [40].

Other non-psoriasiform skin lesions due to anti-TNF agents include local pruritic skin erythema at the site of infusion, eczematiform skin lesions, xerosis cutis, palmoplantar pustulosis, viral and bacterial infections of the skin [41]. Long et al found in a retrospective study that anti-TNF therapy may increase the risk of melanoma, and thiopurines may increase the risk of non-melanoma skin cancer (basal cell cancer, squamous cell cancer) [42]. The mucocutaneous manifestations are outlined in **Table 1**.

Mucocutaneous manifestations due to disease	Mucocutaneous manifestations due to malabsorption	Mucocutaneous manifestations due to medications
<ul style="list-style-type: none">• Erythema nodosum• Pyoderma gangrenosum• Sweet’s syndrome• Aphthous ulcers or stomatitis• Pyostomatitis vegetans• Granulomatous cheilitis• Metastatic Crohn’s disease• Epidermolysis bullosa acquisita• Leucocytoclastic vasculitis• increased risk of developing melanoma of the skin	<ul style="list-style-type: none">• angular cheilitis• Purpura• Acrodermatitis enteropathica	<ul style="list-style-type: none">• Paradoxical psoriasiform rash due to anti-TNF• local pruritic skin erythema at the site of infusion• Eczematiform skin lesions• Xerosis cutis• Palmoplantar pustulosis• Viral and bacterial infections of the skin• Increased risk of melanoma due to anti-TNF• Increased risk of non-melanoma skin cancer (basal cell cancer, squamous cell cancer) due to thiopurines

Table 1.
Mucocutaneous manifestations of Crohn’s disease.

4. Ophthalmic manifestations

Eyes can be involved in 12% of patients with Crohn’s disease [43]. Ocular involvement occurs more commonly in patients with colonic or ileocolonic Crohn’s disease than in patients with isolated small bowel Crohn’s disease [44]. Frequently, patients with ocular involvement also have peripheral large joint arthritis and EN. The common ophthalmic manifestations include episcleritis, scleritis, uveitis, non-specific follicular conjunctivitis and blepharitis [45]. Rarely, orbital myositis and optic neuritis can occur. Patients with episcleritis and scleritis present with red tender eyes. Patients with uveitis present with deep eye pain, red eyes with circumcorneal congestion, meiosis, headache, blurring of vision and photophobia. Patients with uveitis should be seen by an ophthalmologist emergently. Uveitis in patients with Crohn’s disease is generally bilateral, posterior, insidious in onset, chronic and 4 times more common in females than in males [46]. Patients with small bowel Crohn’s disease may also present with night blindness secondary to vitamin A malabsorption and deficiency. The ophthalmic manifestations are outlined in **Table 2**.

Ophthalmic manifestations due to disease	Ophthalmic manifestations due to malabsorption
<ul style="list-style-type: none">• Episcleritis (Figure 3)• Scleritis• Uveitis• Follicular conjunctivitis• Blepharitis• Orbital myositis• Optic neuritis	Night blindness due to vitamin A deficiency

Table 2.
Ophthalmic manifestations in Crohn’s disease.

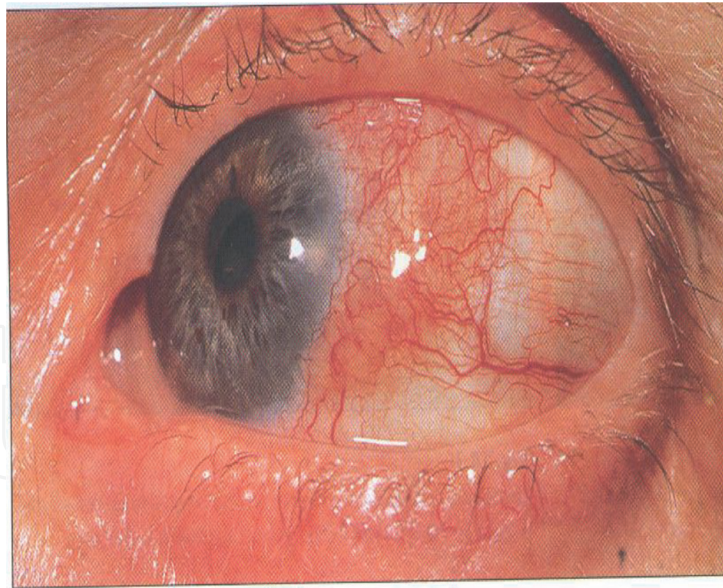

Figure 3.
Episcleritis.

5. Hepatobiliary manifestations

Crohn's disease can affect both liver and biliary tract. Some of the manifestations are directly related to the disease process and some are secondary to medications used in Crohn's disease. Non-alcoholic hepatic steatosis (NAHS) is the most frequent hepatobiliary manifestation that is secondary to intestinal inflammation and metabolic factors [47]. Sagami et al found in a retrospective study that patients with Crohn's disease and NAHS had higher rate of remission and longer surgery free interval [48]. About 2% of patients with Crohn's disease develop primary sclerosing cholangitis (PSC), and 5 to 10% of patients with PSC have Crohn's disease [49]. PSC is a progressive inflammatory, fibrosing and stricturing disease involving both intrahepatic and extrahepatic bile ducts in more than 80% of cases. In about 10% of cases, only intrahepatic bile ducts are involved and in less than 5% of cases, only extrahepatic bile ducts are involved. Patients with PSC remain asymptomatic for many years. They are generally detected by finding abnormal liver function test. When symptomatic, they generally present with itching jaundice, right upper quadrant pain, fever and chills. Magnetic resonance cholangiopancreatography (MRCP) rather than Endoscopic retrograde cholangiopancreatography (ERCP) is now considered as diagnostic test of choice as it is non-invasive, can reduce the risk of hospitalization by 10%, and can visualize the liver [50]. It shows 'stricturing and beading' appearance of both extra-hepatic and intra-hepatic bile ducts. Liver biopsy is not required if imaging studies are suggestive of PSC. Liver histology may show lymphocytic infiltrate of bile duct, bile ductopenia, and periductal concentric fibrosis giving 'onion skin' appearance but no histological appearance is pathognomonic of PSC. Patients with PSC are at increased (10–15%) risk of developing cholangiocarcinoma. But colon cancer risk does not seem to be increased in patients with PSC and Crohn's colitis [51]. Other hepatobiliary manifestations of Crohn's disease include cholelithiasis, granulomatous hepatitis, portal vein thrombosis and secondary amyloidosis [52–54]. Patients with Crohn's disease have 2 fold increased prevalence of gallstone formation than general population. According to Crohn's and colitis foundation of America, up to one third of patients with Crohn's disease may develop gallstones which could be cholesterol-rich stones or pigment stones. In Crohn's disease, gallbladder bile may get supersaturated with cholesterol (with or

Renal manifestations due to disease	Renal manifestations due to malabsorption	Renal manifestations due to medications
<ul style="list-style-type: none">• IgA nephropathy• Membranous glomeruloneohritis• Tubulointerstitial nephritis• Amyloidosis	<ul style="list-style-type: none">• Nephrolithiasis	<ul style="list-style-type: none">• Interstitial nephritis

Table 3.
Renal manifestations in Crohn’s disease.

without ileal disease/resection) leading to the formation of cholesterol-rich gallstones [55]. In patients with ileal disease/resection, bile acid malabsorption initially causes bile acid-induced diarrhea. Bile acid pool slowly decreases and it leads to cholesterol supersaturated bile and cholesterol-rich stone formation. Bile acid malabsorption also induces enterohepatic circulation of bilirubin and increases the rate of secretion of bilirubin into bile. This may help formation of pigment stone [56].

6. Renal manifestations

Renal and urinary tract involvement can occur rarely in Crohn’s disease. Nephrolithiasis, IgA nephropathy, membranous glomeruloneohritis, tubulointerstitial nephritis and amyloidosis are the most frequent involvement [57]. Calcium oxalate stone is formed in the kidneys and urinary tract because of hyperoxaluria. In extensive Crohn’s disease of small bowel or intestinal resection, malabsorbed free fatty acid binds calcium in the intestinal lumen to form calcium-fatty acid salts and thus free calcium becomes less available to bind oxalate in the intestinal lumen. Oxalate then binds with sodium to form sodium oxalate that is easily absorbed through the colonic mucosa resulting in hyperoxaluria [58]. Uric acid stones can also be formed in patients with diarrhea and/or intestinal neostomy, dehydration and hypemetabolic state [59]. Crohn’s disease is also associated with IgA nephropathy [60] and membranous glomerulonephritis [61]. Patients taking mesalamine can develop interstitial nephritis. But patients with Crohn’s disease (not taking mesalamine) can also develop primary chronic tubulointerstitial nephritis [62]. Secondary renal amyloidosis can be a late manifestation of Crohn’s disease [63]. The renal manifestations are outlined in **Table 3**.

7. Cardiovascular manifestations

Although different cardiovascular manifestations are seen in patients with Crohn’s disease, they are not due to traditional cardiovascular risk factors but secondary to chronic systemic inflammation [64]. The different cardiovascular manifestations include pericarditis, myocarditis, nonbacterial thrombotic endocarditis, congestive heart failure, arterial and venous thromboembolism. Among these pericarditis is the most common cardiovascular manifestation [65]. Myocarditis can be due to autoimmune mechanism secondary to exposure to autoantigen or mesalamine-induced [66]. Crohn’s disease can also be associated with non-bacterial thrombotic endocarditis (Libman-Sacks endocarditis) due to hypercoagulable state [67]. The chronic inflammatory state seen in Crohn’s disease may cause myocardial fibrosis due to abnormal collagen metabolism, microvascular endothelial dysfunction, vitamin and essential nutrient deficiencies and changes in nitric oxide

mediated vasodilation [68]. This may lead to chronic heart failure, atrial and ventricular arrhythmia and heart block. Acute heart failure can occur secondary to myopericarditis or myocardial infarction. Patients with Crohn's disease are at increased risk of developing both venous and arterial thromboembolism because of hypercoagulable state as active bowel inflammation leads to thrombocytosis, increased levels of factor V, factor VIII, fibrinogen and fibrinopeptide A, and deficiency of antithrombin III and free protein S in the blood. Other factors include prolonged bed rest, immobility, central venous catheter placement, use of corticosteroids and oral contraceptive pills, smoking and dehydration [69]. The cardiovascular manifestations are outlined as follows:

- Pericarditis
- Myocarditis
- Nonbacterial thrombotic endocarditis
- Increased risk of thromboembolism

8. Pulmonary manifestations

Patients with Crohn's disease can rarely develop subclinical inflammatory process in the lung parenchyma, tracheobronchial tree and pleura in the absence of pulmonary symptoms [70, 71]. Increased lymphocytic count in bronchoalveolar lavage (BAL) indicating lymphocytic alveolitis may suggest latent involvement of lungs in Crohn's disease [72]. Abnormal pulmonary function test (increased carbon monoxide transfer factor/TLCO) can be found in this asymptomatic group of patients without any abnormal imaging [73]. Lung involvement may correlate with bowel inflammation [74]. Other pulmonary manifestations seen in association with Crohn's disease are tracheobronchitis, bronchiectasis, bronchiolitis obliterans organizing pneumonia (BOOP), multiple pulmonary nodules (sterile necrobiotic nodules consisting of sterile aggregates of neutrophils with necrosis), pleuropericarditis, methotrexate-induced pneumonitis, interstitial lung disease and pulmonary eosinophilia due to sulfasalazine and mesalamine, and biologic agents related infections such as reactivation of pulmonary tuberculosis, development of pneumocystis carinii pneumonia and opportunistic fungal infections (aspergillosis, coccidiomycosis, histoplasmosis, nocardiosis) [75–84]. The pulmonary manifestations are outlined in **Table 4**.

Pulmonary manifestations due to disease	Pulmonary manifestations due to medications
<ul style="list-style-type: none">• Lymphocytic alveolitis• Tracheobronchitis• Bronchiectasis• Bronchiolitis obliterans organizing pneumonia• Multiple pulmonary nodules• Pleuropericarditis	<ul style="list-style-type: none">• Methotrexate-induced pneumonitis and interstitial lung disease• Pulmonary eosinophilia due to sulfasalazine and mesalamine• Reactivation of pulmonary tuberculosis, development of pneumocystis carinii pneumonia and opportunistic fungal infections (aspergillosis, coccidiomycosis, histoplasmosis, nocardiosis) due biologic agents

Table 4.
Pulmonary manifestations in Crohn's disease.

9. Conclusion

As Crohn's disease is a chronic systemic inflammatory disease, the inflammatory cascade can be seen in multiple organs. Many of the EIMs occur as a result of pro-inflammatory cytokines. Some of the EIMs do not correlate with intestinal inflammatory activity. Some of the EIMs may precede the gastrointestinal manifestations of Crohn's disease. Some of the EIMs are due to malabsorption of nutrients, vitamins and minerals. Some of the EIMs are due to autoantigens. Some of the EIMs are due to medications used for Crohn's disease.


Author details

Monjur Ahmed

Thomas Jefferson University, Philadelphia, Pennsylvania, USA

*Address all correspondence to: monjur.ahmed@jefferson.edu

IntechOpen

© 2021 The Author(s). Licensee IntechOpen. This chapter is distributed under the terms of the Creative Commons Attribution License (<http://creativecommons.org/licenses/by/3.0>), which permits unrestricted use, distribution, and reproduction in any medium, provided the original work is properly cited. 

References

- [1] Torres J, Mehandru S, Colombel JF, Peyrin-Biroulet L. Crohn's disease. *Lancet*. 2017 Apr 29; 389(10080): 1741-1755. doi: 10.1016/S0140-6736(16) 31711-1. Epub 2016 Dec 1. PMID: 27914655.
- [2] Veauthier B, Hornecker JR. Crohn's Disease: Diagnosis and Management. *Am Fam Physician*. 2018 Dec 1;98(11): 661-669. PMID: 30485038.
- [3] Ephgrave K. Extra-intestinal manifestations of Crohn's disease. *Surg Clin North Am*. 2007 Jun;87(3):673-680. doi: 10.1016/j.suc.2007.03.003. PMID: 17560419.
- [4] Levine JS, Burakoff R. Extraintestinal manifestations of inflammatory bowel disease. *Gastroenterol Hepatol (N Y)*. 2011 Apr;7(4):235-41. PMID: 21857821; PMCID: PMC3127025.
- [5] Fréour T, Miossec C, Bach-Ngohou K, Dejoie T, Flamant M, Maillard O, Denis MG, Barriere P, Bruley des Varannes S, Bourreille A, Masson D. Ovarian reserve in young women of reproductive age with Crohn's disease. *Inflamm Bowel Dis*. 2012 Aug;18(8): 1515-1522. doi: 10.1002/ibd.21872. Epub 2011 Sep 20. PMID: 21936034.
- [6] Kurina LM, Goldacre MJ, Yeates D, Gill LE. Depression and anxiety in people with inflammatory bowel disease. *J Epidemiol Community Health*. 2001 Oct;55(10):716-20. doi: 10.1136/ jech.55.10.716. PMID: 11553654; PMCID: PMC1731788.
- [7] Mikocka-Walus A, Knowles SR, Keefer L, Graff L. Controversies Revisited: A Systematic Review of the Comorbidity of Depression and Anxiety with Inflammatory Bowel Diseases. *Inflamm Bowel Dis*. 2016 Mar;22(3): 752-762. doi: 10.1097/ MIB.0000000000000620. PMID: 26841224.
- [8] Farmer RG, Hawk WA, Turnbull RB Jr. Clinical patterns in Crohn's disease: a statistical study of 615 cases. *Gastroenterology*. 1975 Apr;68(4 Pt 1): 627-635. PMID: 1123132.
- [9] Orchard TR. Management of arthritis in patients with inflammatory bowel disease. *Gastroenterol Hepatol (N Y)*. 2012 May;8(5):327-9. PMID: 22933865; PMCID: PMC3424429.
- [10] Orchard TR, Wordsworth BP, Jewell DP. Peripheral arthropathies in inflammatory bowel disease: their articular distribution and natural history. *Gut*. 1998 Mar;42(3):387-91. doi: 10.1136/gut.42.3.387. PMID: 9577346; PMCID: PMC1727027.
- [11] Jacques P, Mielants H, Coppieters K, De Vos M, Elewaut D. The intimate relationship between gut and joint in spondyloarthropathies. *Curr Opin Rheumatol*. 2007 Jul;19(4):353-357. doi: 10.1097/BOR.0b013e328133f59f. PMID: 17551365.
- [12] Khan A, Illiffe G, Houston DS, Bernstein CN. Osteonecrosis in a patient with Crohn's disease unrelated to corticosteroid use. *Can J Gastroenterol*. 2001 Nov;15(11):765-768. doi: 10.1155/ 2001/293059. PMID: 11727007.
- [13] Klingenstein G, Levy RN, Kornbluth A, Shah AK, Present DH. Inflammatory bowel disease related osteonecrosis: report of a large series with a review of the literature. *Aliment Pharmacol Ther*. 2005 Feb 1;21(3): 243-249. doi: 10.1111/ j.1365-2036.2005.02231.x. PMID: 15691298.
- [14] Rolston VS, Patel AV, Leach TJ, Li D, Karayev D, Williams C, Siddanthi ML, Targan SR, Weisman MH, McGovern DPB. Prevalence and Associations of Avascular Necrosis of the Hip in a Large

Well-characterized Cohort of Patients With Inflammatory Bowel Disease. *J Clin Rheumatol*. 2019 Jan;25(1):45-49. doi: 10.1097/RHU.0000000000000797. PMID: 29794876; PMCID: PMC6252167.

[15] Turk N, Cukovic-Cavka S, Korsic M, Turk Z, Vucelic B. Proinflammatory cytokines and receptor activator of nuclear factor kappaB-ligand/osteoprotegerin associated with bone deterioration in patients with Crohn's disease. *Eur J Gastroenterol Hepatol*. 2009 Feb;21(2):159-166. doi: 10.1097/MEG.0b013e3283200032. PMID: 19098682.

[16] Noble CL, McCullough J, Ho W, Lees CW, Nimmo E, Drummond H, Bear S, Hannan J, Millar C, Ralston SH, Satsangi J. Low body mass not vitamin D receptor polymorphisms predict osteoporosis in patients with inflammatory bowel disease. *Aliment Pharmacol Ther*. 2008 Apr 1;27(7):588-596. doi: 10.1111/j.1365-2036.2008.03599.x. Epub 2008 Jan 10. PMID: 18194505.

[17] Schneider SM, Al-Jaouni R, Filippi J, Wiroth JB, Zeanandin G, Arab K, Hébuterne X. Sarcopenia is prevalent in patients with Crohn's disease in clinical remission. *Inflamm Bowel Dis*. 2008 Nov;14(11):1562-1568. doi: 10.1002/ibd.20504. PMID: 18478564.

[18] Lebwohl M, Lebwohl O. Cutaneous manifestations of inflammatory bowel disease. *Inflamm Bowel Dis*. 1998 May;4(2):142-148. doi: 10.1002/ibd.3780040209. PMID: 9589299.

[19] Tavela Veloso F. Review article: skin complications associated with inflammatory bowel disease. *Aliment Pharmacol Ther*. 2004 Oct;20 Suppl 4:50-53. doi: 10.1111/j.1365-2036.2004.02055.x. PMID: 15352894.

[20] Yeh JE, Tsiaras WG. Intractable pyoderma gangrenosum in a Crohn's

disease patient on vedolizumab. *JAAD Case Rep*. 2017 Mar 9;3(2):110-112. doi: 10.1016/j.jdcr.2017.01.012. PMID: 28337471; PMCID: PMC5347515.

[21] Brooklyn T, Dunnill G, Probert C. Diagnosis and treatment of pyoderma gangrenosum. *BMJ*. 2006 Jul 22;333(7560):181-4. doi: 10.1136/bmj.333.7560.181. PMID: 16858047; PMCID: PMC1513476.

[22] Lima CDS, Pinto RDB, Góes HFO, Salles SAN, Vilar EAG, Lima CDS. Sweet's syndrome associated with Crohn's disease. *An Bras Dermatol*. 2017 Mar-Apr;92(2):263-265. doi: 10.1590/abd1806-4841.20175298. PMID: 28538894; PMCID: PMC5429120.

[23] Plauth M, Jenss H, Meyle J. Oral manifestations of Crohn's disease. An analysis of 79 cases. *J Clin Gastroenterol*. 1991 Feb;13(1):29-37. doi: 10.1097/00004836-199102000-00008. PMID: 2007740.

[24] Trikudanathan G, Venkatesh PG, Navaneethan U. Diagnosis and therapeutic management of extra-intestinal manifestations of inflammatory bowel disease. *Drugs*. 2012 Dec 24;72(18):2333-2349. doi: 10.2165/11638120-000000000-00000. PMID: 23181971.

[25] Huang BL, Chandra S, Shih DQ. Skin manifestations of inflammatory bowel disease. *Front Physiol*. 2012 Feb 6;3:13. doi: 10.3389/fphys.2012.00013. PMID: 22347192; PMCID: PMC3273725.

[26] Panackel C, John J, Krishnadas D, Vinayakumar KR. Metastatic Crohn's disease of external genitalia. *Indian J Dermatol*. 2008;53(3):146-8. doi: 10.4103/0019-5154.43207. PMID: 19882017; PMCID: PMC2763745.

[27] Palamaras I, El-Jabbour J, Pietropaolo N, Thomson P, Mann S, Robles W, Stevens HP. Metastatic Crohn's disease: a review. *J Eur Acad*

- Dermatol Venereol. 2008 Sep;22(9):1033-1043. doi: 10.1111/j.1468-3083.2008.02741.x. Epub 2008 Jun 19. PMID: 18573158.
- [28] Graham DB, Jager DL, Borum ML. Metastatic Crohn's disease of the face. *Dig Dis Sci*. 2006 Nov;51(11):2062-2063. doi: 10.1007/s10620-006-9533-2. Epub 2006 Sep 29. PMID: 17009111.
- [29] Fiorino G, Omodei PD. Psoriasis and Inflammatory Bowel Disease: Two Sides of the Same Coin? *J Crohns Colitis*. 2015 Sep;9(9):697-698. doi: 10.1093/ecco-jcc/jjv110. Epub 2015 Jun 15. PMID: 26079725.
- [30] Reddy H, Shipman AR, Wojnarowska F. Epidermolysis bullosa acquisita and inflammatory bowel disease: a review of the literature. *Clin Exp Dermatol*. 2013 Apr;38(3):225-229; quiz 229-30. doi: 10.1111/ced.12114. PMID: 23517353.
- [31] Tsiamoulos Z, Karamanolis G, Polymeros D, Triantafyllou K, Oikonomopoulos T. Leukocytoclastic vasculitis as an onset symptom of Crohn's disease. *Case Rep Gastroenterol*. 2008 Sep;2(3):410-4. doi: 10.1159/000161562. Epub 2008 Nov 14. PMID: 21897791; PMCID: PMC3166803.
- [32] Stewart MI, Woodley DT, Briggaman RA. Epidermolysis bullosa acquisita and associated symptomatic esophageal webs. *Arch Dermatol*. 1991 Mar;127(3):373-377. PMID: 1998368.
- [33] Buck M, Domic I, McDermott W, Nordstrom C, Dawan S, Virata A, Martin S, Hudson A, Milovanovic T, Nordin T. Leukocytoclastic vasculitis as a rare dermatologic manifestation of Crohn's disease mimicking cellulitis: a case report. *BMC Gastroenterol*. 2020 Jul 29;20(1):240. doi: 10.1186/s12876-020-01371-3. PMID: 32727390; PMCID: PMC7389435.
- [34] Krasovec M, Frenk E. Acrodermatitis enteropathica secondary to Crohn's disease. *Dermatology*. 1996; 193(4):361-363. doi: 10.1159/000246296. PMID: 8993972.
- [35] Kappelman MD, Farkas DK, Long MD, Erichsen R, Sandler RS, Sørensen HT, Baron JA. Risk of cancer in patients with inflammatory bowel diseases: a nationwide population-based cohort study with 30 years of follow-up evaluation. *Clin Gastroenterol Hepatol*. 2014 Feb;12(2):265-73.e1. doi: 10.1016/j.cgh.2013.03.034. Epub 2013 Apr 17. PMID: 23602821; PMCID: PMC4361949.
- [36] Cullen G, Kroshinsky D, Cheifetz AS, Korzenik JR. Psoriasis associated with anti-tumour necrosis factor therapy in inflammatory bowel disease: a new series and a review of 120 cases from the literature. *Aliment Pharmacol Ther*. 2011 Dec;34(11-12):1318-1327. doi: 10.1111/j.1365-2036.2011.04866.x. Epub 2011 Sep 29. PMID: 21957906.
- [37] Tillack C, Ehmann LM, Friedrich M, Laubender RP, Papay P, Vogelsang H, Stallhofer J, Beigel F, Bedynek A, Wetzke M, Maier H, Koburger M, Wagner J, Glas J, Diegelmann J, Koglin S, Dombrowski Y, Schaubert J, Wollenberg A, Brand S. Anti-TNF antibody-induced psoriasiform skin lesions in patients with inflammatory bowel disease are characterised by interferon- γ -expressing Th1 cells and IL-17A/IL-22-expressing Th17 cells and respond to anti-IL-12/IL-23 antibody treatment. *Gut*. 2014 Apr;63(4):567-77. doi: 10.1136/gutjnl-2012-302853. Epub 2013 Mar 6. PMID: 23468464.
- [38] Teunissen MB, Koomen CW, de Waal Malefyt R, Wierenga EA, Bos JD. Interleukin-17 and interferon-gamma synergize in the enhancement of proinflammatory cytokine production by human keratinocytes. *J Invest Dermatol*. 1998 Oct;111(4):645-649. doi: 10.1046/j.1523-1747.1998.00347.x. PMID: 9764847.
- [39] de Gannes GC, Ghoreishi M, Pope J, Russell A, Bell D, Adams S, Shojania K,

Martinka M, Dutz JP. Psoriasis and pustular dermatitis triggered by TNF- α inhibitors in patients with rheumatologic conditions. *Arch Dermatol*. 2007 Feb;143(2):223-231. doi: 10.1001/archderm.143.2.223. PMID: 17310002.

[40] Scaldaferri F, Petito V, Papa A, Cesarini M, Arena V, Lopetuso LR, Corbi M, Perino F, Caldarola G, Carbone A, Corazziari E, Sgambato A, Gasbarrini A, De Simone C. Anti-TNF- α -induced psoriasiform lesions in IBD: an abnormal immune activation or a 'patchy cutaneous' immune suppression? *Gut*. 2014 Apr;63(4):699-701. doi: 10.1136/gutjnl-2013-305478. Epub 2013 Nov 19. PMID: 24253935.

[41] Cleynen I, Van Moerkercke W, Billiet T, Vandecandelaere P, Vande Castele N, Breynaert C, Ballet V, Ferrante M, Noman M, Assche GV, Rutgeerts P, van den Oord JJ, Gils A, Segaeert S, Vermeire S. Characteristics of Skin Lesions Associated With Anti-Tumor Necrosis Factor Therapy in Patients With Inflammatory Bowel Disease: A Cohort Study. *Ann Intern Med*. 2016 Jan 5;164(1):10-22. doi: 10.7326/M15-0729. Epub 2015 Dec 8. PMID: 26641955.

[42] Long MD, Martin CF, Pipkin CA, Herfarth HH, Sandler RS, Kappelman MD. Risk of melanoma and nonmelanoma skin cancer among patients with inflammatory bowel disease. *Gastroenterology*. 2012 Aug;143(2):390-399.e1. doi: 10.1053/j.gastro.2012.05.004. Epub 2012 May 11. PMID: 22584081; PMCID: PMC4065572.

[43] Kalla R, Ventham NT, Satsangi J, Arnott ID. Crohn's disease. *BMJ*. 2014 Nov 19;349:g6670. doi: 10.1136/bmj.g6670. PMID: 25409896.

[44] Das KM. Relationship of extraintestinal involvements in inflammatory bowel disease: new

insights into autoimmune pathogenesis. *Dig Dis Sci*. 1999 Jan;44(1):1-13. doi: 10.1023/a:1026629528233. PMID: 9952216.

[45] Mintz R, Feller ER, Bahr RL, Shah SA. Ocular manifestations of inflammatory bowel disease. *Inflamm Bowel Dis*. 2004 Mar;10(2):135-139. doi: 10.1097/00054725-200403000-00012. PMID: 15168814.

[46] Lyons JL, Rosenbaum JT. Uveitis associated with inflammatory bowel disease compared with uveitis associated with spondyloarthropathy. *Arch Ophthalmol*. 1997 Jan;115(1):61-64. doi: 10.1001/archophth.1997.01100150063010. PMID: 9006426.

[47] Magrì S, Paduano D, Chicco F, Cingolani A, Farris C, Delogu G, Tumbarello F, Lai M, Melis A, Casula L, Fantini MC, Usai P. Nonalcoholic fatty liver disease in patients with inflammatory bowel disease: Beyond the natural history. *World J Gastroenterol*. 2019 Oct 7;25(37):5676-5686. doi: 10.3748/wjg.v25.i37.5676. PMID: 31602167; PMCID: PMC6785525.

[48] Sagami S, Ueno Y, Tanaka S, Fujita A, Hayashi R, Oka S, Hyogo H, Chayama K. Significance of non-alcoholic fatty liver disease in Crohn's disease: A retrospective cohort study. *Hepatol Res*. 2017 Aug;47(9):872-881. doi: 10.1111/hepr.12828. Epub 2016 Nov 28. PMID: 27737498.

[49] Levine JS, Burakoff R. Extraintestinal manifestations of inflammatory bowel disease. *Gastroenterol Hepatol (N Y)*. 2011 Apr;7(4):235-41. PMID: 21857821; PMCID: PMC3127025.

[50] Khoshpouri P, Habibabadi RR, Hazhirkarzar B, Ameli S, Ghadimi M, Ghasabeh MA, Menias CO, Kim A, Li Z, Kamel IR. Imaging Features of Primary Sclerosing Cholangitis: From Diagnosis

to Liver Transplant Follow-up.

Radiographics. 2019 Nov-Dec;39(7):
 1938-1964. doi: 10.1148/rg.2019180213.
 Epub 2019 Oct 18. PMID: 31626561.

[51] Braden B, Halliday J, Aryasingha S, Sharifi Y, Checchin D, Warren BF, Kitiyakara T, Travis SP, Chapman RW. Risk for colorectal neoplasia in patients with colonic Crohn's disease and concomitant primary sclerosing cholangitis. *Clin Gastroenterol Hepatol*. 2012 Mar;10(3):303-308. doi: 10.1016/j.cgh.2011.10.020. Epub 2011 Oct 28. PMID: 22037429.

[52] Patedakis Litvinov BI, Pathak AP. Granulomatous hepatitis in a patient with Crohn's disease and cholestasis. *BMJ Case Rep*. 2017 Sep 7;2017:bcr2017220988. doi: 10.1136/bcr-2017-220988. PMID: 28882937; PMCID: PMC5589046.

[53] Mathieu E, Fain O, Trinchet JC, Aourousseau MH, Stérin D, Thomas M. La thrombose porte: une complication exceptionnelle de la maladie de Crohn [Portal vein thrombosis: a rare complication of Crohn disease]. *Rev Med Interne*. 1994;15(9):589-92. French. doi: 10.1016/s0248-8663(05)82504-4. PMID: 7984838.

[54] Sharma P, Aguilar R, Siddiqui OA, Nader MA. Secondary systemic amyloidosis in inflammatory bowel disease: a nationwide analysis. *Ann Gastroenterol*. 2017;30(5):504-511. doi: 10.20524/aog.2017.0168. Epub 2017 Jun 14. PMID: 28845105; PMCID: PMC5566770.

[55] Lapidus A, Akerlund JE, Einarsson C. Gallbladder bile composition in patients with Crohn's disease. *World J Gastroenterol*. 2006 Jan 7;12(1):70-4. doi: 10.3748/wjg.v12.i1.70. PMID: 16440420; PMCID: PMC4077498.

[56] Brink MA, Slors JF, Keulemans YC, Mok KS, De Waart DR, Carey MC,

Groen AK, Tytgat GN. Enterohepatic cycling of bilirubin: a putative mechanism for pigment gallstone formation in ileal Crohn's disease. *Gastroenterology*. 1999 Jun;116(6):1420-1427. doi: 10.1016/s0016-5085(99)70507-x. PMID: 10348826.

[57] Corica D, Romano C. Renal Involvement in Inflammatory Bowel Diseases. *J Crohns Colitis*. 2016 Feb;10(2):226-235. doi: 10.1093/ecco-jcc/jjv138. Epub 2015 Jul 29. PMID: 26223844.

[58] Gaspar SR, Mendonça T, Oliveira P, Oliveira T, Dias J, Lopes T. Urolithiasis and crohn's disease. *Urol Ann*. 2016 Jul-Sep;8(3):297-304. doi: 10.4103/0974-7796.184879. PMID: 27453651; PMCID: PMC4944622.

[59] Cirillo M, Iudici M, Marcarelli F, Laudato M, Zincone F. La nefrolitiasi nelle malattie intestinali [Nephrolithiasis in patients with intestinal diseases]. *G Ital Nefrol*. 2008 Jan-Feb;25(1):42-8. Italian. PMID: 18264917.

[60] Choi JY, Yu CH, Jung HY, Jung MK, Kim YJ, Cho JH, Kim CD, Kim YL, Park SH. A case of rapidly progressive IgA nephropathy in a patient with exacerbation of Crohn's disease. *BMC Nephrol*. 2012 Aug 6;13:84. doi: 10.1186/1471-2369-13-84. PMID: 22866754; PMCID: PMC3724487.

[61] Díaz Rodríguez C, Granja E, Vázquez Martul E, Sacristán F, Moreno Fernández A, González Rivero C, del Río Romero D, Trinidad JC. Asociación de glomerulonefritis membranosa y enfermedad de Crohn [Association between membranous glomerulonephritis and Crohn's disease]. *Nefrologia*. 2004;24(4):368-71. Spanish. PMID: 15455498.

[62] Izzedine H, Simon J, Piette AM, Lucsko M, Baumelou A, Charitanski D, Kernaonnet E, Baglin AC, Deray G,

Beaufils H. Primary chronic interstitial nephritis in Crohn's disease. *Gastroenterology*. 2002 Nov;123(5):1436-1440. doi: 10.1053/gast.2002.36613. PMID: 12404216.

[63] Saitoh O, Kojima K, Teranishi T, Nakagawa K, Kayazawa M, Nanri M, Egashira Y, Hirata I, Katsu Ki KI. Renal amyloidosis as a late complication of Crohn's disease: a case report and review of the literature from Japan. *World J Gastroenterol*. 2000 Jun;6(3):461-464. doi: 10.3748/wjg.v6.i3.461. PMID: 11819631; PMCID: PMC4688785.

[64] Aarestrup J, Jess T, Kobylecki CJ, Nordestgaard BG, Allin KH. Cardiovascular Risk Profile Among Patients With Inflammatory Bowel Disease: A Population-based Study of More Than 100 000 Individuals. *J Crohns Colitis*. 2019 Mar 26;13(3):319-323. doi: 10.1093/ecco-jcc/jjy164. PMID: 30321330.

[65] Mitchell NE, Harrison N, Junga Z, Singla M. Heart Under Attack: Cardiac Manifestations of Inflammatory Bowel Disease. *Inflamm Bowel Dis*. 2018 Oct 12;24(11):2322-2326. doi: 10.1093/ibd/izy157. PMID: 29788235.

[66] Merceron O, Bailly C, Khalil A, Pontnau F, Hammoudi N, Dorent R, Michel PL. Mesalamine-induced myocarditis. *Cardiol Res Pract*. 2010 Sep 13;2010:930190. doi: 10.4061/2010/930190. PMID: 20871830; PMCID: PMC2943131.

[67] Uchida W, Mutsuga M, Ito H, Oshima H, Usui A. Nonbacterial Thrombotic Endocarditis Associated With Crohn Disease. *Ann Thorac Surg*. 2018 May;105(5):e199-e201. doi: 10.1016/j.athoracsur.2017.12.005. Epub 2018 Jan 3. PMID: 29305852.

[68] Hatoum OA, Binion DG, Otterson MF, Gutterman DD. Acquired microvascular dysfunction in inflammatory bowel disease: Loss of

nitric oxide-mediated vasodilation. *Gastroenterology*. 2003 Jul;125(1):58-69. doi: 10.1016/s0016-5085(03)00699-1. PMID: 12851871.

[69] Giannotta M, Tapete G, Emmi G, Silvestri E, Milla M. Thrombosis in inflammatory bowel diseases: what's the link? *Thromb J*. 2015 Apr 2;13:14. doi: 10.1186/s12959-015-0044-2. PMID: 25866483; PMCID: PMC4393581.

[70] Tagle M, Barriga J, Piñeiro A. Enfermedad de Crohn asociada a la lesión pulmonar focal [Crohn's disease associated with focal pulmonare lesion]. *Rev Gastroenterol Peru*. 2003 Oct-Dec; 23(4):293-6. Spanish. PMID: 14716424.

[71] Mikhaïlova ZF, Levchenko SV, Karagodina Iula, Barinov VV. [Pulmonary disorders in patients with chronic inflammatory bowel disease]. *Eksp Klin Gastroenterol*. 2011;(3):54-9. Russian. PMID: 21695953.

[72] Wallaert B, Colombel JF, Tonnel AB, Bonniere P, Cortot A, Paris JC, Voisin C. Evidence of lymphocyte alveolitis in Crohn's disease. *Chest*. 1985 Mar;87(3):363-367. doi: 10.1378/chest.87.3.363. PMID: 3971763.

[73] Mikhaïlova ZF, Parfenov AI, Ruchkina IN, Rogozina VA. [External respiratory function in patients with Crohn's disease]. *Eksp Klin Gastroenterol*. 2011;(2):82-5. Russian. PMID: 21560645.

[74] Tzanakis N, Bouros D, Samiou M, Panagou P, Mouzas J, Manousos O, Siafakas N. Lung function in patients with inflammatory bowel disease. *Respir Med*. 1998 Mar;92(3):516-522. doi: 10.1016/s0954-6111(98)90301-8. PMID: 9692115.

[75] Iwama T, Higuchi T, Imajo M, Akagawa S, Matsubara O, Mishima Y. Tracheo-bronchitis as a complication of Crohn's disease—a case report. *Jpn J Surg*. 1991 Jul;21(4):454-457. doi: 10.1007/BF02470975. PMID: 1960905.

- [76] Butland RJ, Cole P, Citron KM, Turner-Warwick M. Chronic bronchial suppuration and inflammatory bowel disease. *Q J Med.* 1981;50(197):63-75. PMID: 7267968.
- [77] Gil-Simón P, Barrio Andrés J, Atienza Sánchez R, Julián Gómez L, López Represa C, Caro-Patón A. Bronquiolititis obliterante con neumonía organizada y enfermedad de Crohn [Bronchiolitis obliterans organizing pneumonia and Crohn's disease]. *Rev Esp Enferm Dig.* 2008 Mar;100(3):175-7. Spanish. doi: 10.4321/s1130-01082008000300010. PMID: 18416645.
- [78] Golpe R, Mateos A, Pérez-Valcárcel J, Lapeña JA, García-Figueiras R, Blanco J. Multiple pulmonary nodules in a patient with Crohn's disease. *Respiration.* 2003 May-Jun;70(3):306-309. doi: 10.1159/000072015. PMID: 12915753.
- [79] Patwardhan RV, Heilpern RJ, Brewster AC, Darrah JJ. Pleuropericarditis: an extraintestinal complication of inflammatory bowel disease. Report of three cases and review of literature. *Arch Intern Med.* 1983 Jan;143(1):94-96. PMID: 6849612.
- [80] Sostman HD, Matthay RA, Putman CE, Smith GJ. Methotrexate-induced pneumonitis. *Medicine (Baltimore).* 1976 Sep;55(5):371-388. doi: 10.1097/00005792-197609000-00002. PMID: 957997.
- [81] Gupta A, Gulati S. Mesalamine induced eosinophilic pneumonia. *Respir Med Case Rep.* 2017 Apr 12;21:116-117. doi: 10.1016/j.rmcr.2017.04.010. PMID: 28458997; PMCID: PMC5397013.
- [82] Keane J, Gershon S, Wise RP, Mirabile-Levens E, Kasznica J, Schwieterman WD, Siegel JN, Braun MM. Tuberculosis associated with infliximab, a tumor necrosis factor alpha-neutralizing agent. *N Engl J Med.* 2001 Oct 11;345(15):1098-1104. doi: 10.1056/NEJMoa011110. PMID: 11596589.
- [83] Stratakos G, Kalomenidis I, Papas V, Malagari K, Kollintza A, Roussos C, Anagnostopoulou M, Paniara O, Zakynthinos S, Papiris SA. Cough and fever in a female with Crohn's disease receiving infliximab. *Eur Respir J.* 2005 Aug;26(2):354-357. doi: 10.1183/09031936.05.00005205. PMID: 16055885.
- [84] Colombel JF, Loftus EV Jr, Tremaine WJ, Egan LJ, Harmsen WS, Schleck CD, Zinsmeister AR, Sandborn WJ. The safety profile of infliximab in patients with Crohn's disease: the Mayo clinic experience in 500 patients. *Gastroenterology.* 2004 Jan;126(1):19-31. doi: 10.1053/j.gastro.2003.10.047. PMID: 14699483.