

We are IntechOpen, the world's leading publisher of Open Access books Built by scientists, for scientists

6,900

Open access books available

186,000

International authors and editors

200M

Downloads

Our authors are among the

154

Countries delivered to

TOP 1%

most cited scientists

12.2%

Contributors from top 500 universities



WEB OF SCIENCE™

Selection of our books indexed in the Book Citation Index
in Web of Science™ Core Collection (BKCI)

Interested in publishing with us?
Contact book.department@intechopen.com

Numbers displayed above are based on latest data collected.
For more information visit www.intechopen.com



Osseointegration of Dental Implants and Osteoporosis

*Sara Gibreel, Hasaan Gassim Mohamed,
Amartya Raj Suraj and Sukumaran Anil*

Abstract

Osteoporosis is a disease characterized by low bone mass and microarchitectural deterioration of bone tissue, leading to enhanced bone fragility and susceptibility to fractures. Osteoporosis also results in loss of bone mineral density throughout the body, including the maxilla and mandible. Successful osseointegration of dental implants is attributed to their ability to integrate well with bone. The influence of bone quality on dental implant osseointegration has been discussed in several studies, and higher rates of dental implant failure have been reported in patients with low bone quality and an inadequate bone volume. Osteoporosis represents a risk factor for osseointegration, and this relationship may be derived from the association of the disease with a deficiency in bone formation. This condition would compromise the healing capacity and the apposition of bone at the implant interface. Currently, there is no clear consensus regarding dental implant treatment in osteoporotic individuals. Studies have revealed contradictory reports regarding the success and failure of dental implants in patients with osteoporosis. Antiresorptive agents have been widely used to treat osteoporosis. Dental implant placement in patients on bisphosphonate therapy may trigger osteonecrosis of the bone. Hence, it is important to analyze factors that have to be taken into consideration prior to implant therapy in patients with osteoporosis and those undergoing treatment. This chapter outlines dental implant osseointegration under osteoporotic conditions. The possible effect of bisphosphonate therapy on dental implant survival will also be discussed based on the current literature.

Keywords: osteoporosis, osteopenia, bisphosphonates, osseointegration, implant, bone mineral density, risk factors

1. Introduction

Osteoporosis is a systemic skeletal disease that deteriorates bone mass and strength and affects the microarchitecture of bone, thus increasing bone turnover and bone fragility [1]. Osteoporosis is categorized into primary and secondary types. Primary osteoporosis is considered decreased bone density attributed to aging, post-menopausal conditions and idiopathic osteoporosis. Secondary osteoporosis occurs in patients with predisposing factors, such as other endocrinopathies and a history of using some drugs. Osteoporotic bone is characterized by a decreased thickness,

deranged trabecular structure, reduced mineral content, as well as an increased carbonate-to-phosphate ratio [2]. The reduction in osteoid formation is attributed to the absence of or a deficit in pre-osteoblast differentiation into osteoblasts or a reduction in the number of osteoprogenitor cells and defects in their proliferation and differentiation [3].

Dental implant placement has become a common and frequent option for tooth replacement. The success of dental implants largely depends on their osseointegration. Factors that interfere with osseointegration act as potential threats to implant survival. Osteoporosis is considered a questionable condition in dental implant placement since it affects the jaw bones, and bisphosphonates (BPs) are the first line of therapy [4–6]. Local and systemic factors can influence the osseointegration. The implant surface and the bone are the main interacting entities, and changes to these affect the healing and osseointegration of the implant. It is recognized that any compromise in the bone quality and quantity adversely affects the osseointegration. A microrough implant surface results in better osseointegration than a smooth implant surface. The relationship between osteoporosis and bone formation around implants is still unclear [7, 8]. Osteoporosis in the elderly, especially in postmenopausal women, is significantly correlated with tooth loss [9]. In fractures, delayed bone healing occurs due to low bone density, poor bone quality and osseous microstructural changes [10]. The endosseous implant healing mechanism is similar to that of bone fracture healing; hence, it is reasonable to assume that dental implant survival may be negatively affected by osteoporosis [11]. Animal studies have shown a relatively low rate of osseointegration in an osteoporotic environment [12, 13]. While most of these experimental studies were carried out on long bones rather than jaw bones, [14] studies of experimentally induced osteoporosis in the mandible failed to show a significant difference in peri-implant bone formation [15–18].

2. Pathophysiology of osteoporosis

Osteoporosis is a condition characterized by decreased bone mineral density and deteriorated bone microarchitecture and hence compromised bone quality. Osteoporosis can be classified into primary and secondary types. Primary osteoporosis can also be subclassified as type I and type II osteoporosis [17]. Type I osteoporosis occurs primarily due to the loss of trabecular bone, leading to distal forearm and vertebral body fractures. Type II osteoporosis is also known as senile osteoporosis and mainly occurs in men and women over the age of 70 years due to the loss of cortical and trabecular bone. Osteoporosis may also result from genetic and endocrine disorders, hypogonadal states, deficiencies, drug-induced and inflammatory states, and hematologic and neoplastic disorders as secondary causes. Estrogen deficiency is thought to be critical in the pathogenesis of postmenopausal osteoporosis. In the postmenopausal period, the bone structure changes due to estrogen deficiency, and osteoporosis can occur as a result of an imbalance in bone remodeling leading to enhanced bone resorption [3].

Osteoporosis leads to bone demineralization, which begins to manifest clinically in the fourth and fifth decades of life. Modifiable and nonmodifiable risk factors are responsible for osteoporosis [19]. Nonmodifiable risk factors include age, sex, genetic factors and early menopause, while modifiable risk factors include inadequate calcium consumption, lack of exercise, and behavioral factors, such as smoking and alcoholism. Other factors that can contribute to the development of osteoporosis

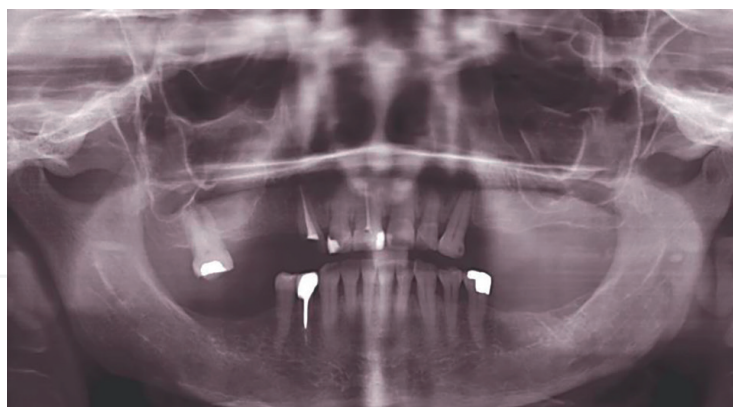


Figure 1.
Orthopantomogram of a 65-year-old patient with osteoporosis. Note the area of low bone density, alveolar bone loss and tooth loss.

include certain endocrine diseases, such as hyperparathyroidism, chronic renal and hepatic disease, malabsorption, and the use of certain drugs, such as oral glucocorticoids [18, 19].

The role of estrogen in the development of osteoporosis is well documented. Studies have shown that sex steroids, particularly estrogen, are important in developing peak bone mass and that estrogen deficiency is an important determinant of bone loss in both sexes [20, 21]. Estrogen can directly and/or indirectly affect osteoclasts, osteoblasts and osteocytes. It has been firmly established that these cells express functional estrogen receptors, [22] and studies have clearly demonstrated that estrogen can induce osteoclast apoptosis through the osteoclast-specific deletion of estrogen receptors. This can reduce osteoclast apoptosis and increase the osteoclast lifespan, which results in decreased trabecular bone mass (**Figure 1**) [23, 24]. Aging and estrogen deficiency may lead to an impairment in bone formation involving oxidative stress. Estrogen deficiency can also lead to a marked increase in NF- κ B activity in osteoblasts. In osteoporotic patients, estrogen treatment induces the expression of sclerostin, a potent inhibitor of bone formation [25]. As sclerostin is expressed by osteocytes, estrogen also affects osteocytes. Estrogen deficiency may enhance the rate of bone loss by stimulating the synthesis of several inflammatory cytokines that regulate osteoclast generation, such as IL-1, IL-2, IL-6, and prostaglandin E [26].

A recent study among Swedish women showed a previous history of fracture and low bone mineral density as important factors that can lead to an increased rate of hip and fragility fractures among them [27]. Another study conducted in the United States revealed that several factors, such as age, self-reported health, weight, height, self-reported physical activity, history of fracture after the age of 50, parental hip fracture, smoking, use of corticosteroids, and treated diabetes, may be early indicators of hip fractures [28]. Factors associated with an increased risk for osteoporosis in men include glucocorticoid treatment, hypogonadism, excessive alcohol consumption, anticonvulsant use, osteomalacia, severe hyperthyroidism, and bone marrow neoplasia [29].

3. Dental implants and osteoporosis

Osteoporosis causes a range of skeletal changes that may impact the feasibility of dental implant placement. Greater alveolar ridge resorption, altered trabecular

patterns in the anterior maxilla and posterior mandible, erosion of the inferior border of the mandible and increased resorption and thinning of the inferior mandibular cortical margin have been reported among osteoporotic individuals [30, 31]. Subjects with osteoporosis show a decreased number and thickness of trabecular plates as a characteristic feature of the disease. There have also been anecdotal reports that the incidence of maxillofacial fractures during the placement of endosseous implants is increased in patients with osteoporosis [32]. Additionally, bone changes evident on panoramic radiographs can be correlated with general osteoporosis, and dental radiography can serve as both a reliable indicator of bone loss in osteoporosis and a useful tool for diagnosing skeletal osteoporosis [33].

The osseointegration of an implant is a wound healing process that depends upon the quality, quantity, and healing capacity of the host bone and various other systemic conditions. Osseointegration is based on intimate bone-implant contact achieved during healing. Thus, any condition affecting bone quality or quantity or microarchitectural changes in bone structure, including a reduction in the cancellous bone volume and bone-implant contact, could theoretically have a negative impact on the survival and function of an endosseous implant [34]. There are relatively few absolute contraindications to rehabilitation with dental implants, including a recent myocardial infarction or cerebrovascular accident, history of valvular prosthesis placement, immune suppression, bleeding issues, active treatment of malignancy, drug abuse, psychiatric illness, and intravenous BP treatment [35]. Some relative contraindications and conditions that may unfavorably impact the outcomes of dental implant placement discussed in the literature include adolescence, aging, osteoporosis, smoking, diabetes, positive IL-1 genotype, human immunodeficiency virus infection, cardiovascular disease and hypothyroidism [36–38]. Controversy about the importance and effects of osteoporosis in dental therapy has continued [39].

In a study of implant placement in patients diagnosed with osteoporosis, Friberg et al. [40] found a success rate of 97% for the maxilla and 97.3% for the mandible on follow-up. Most studies have shown that it is feasible to place implants in subjects with osteoporosis, with success rates similar to those in healthy subjects, even in cases of poor bone quality during or after placement [4, 41–44].

4. Osteoporosis in implant Osseointegration

The osseointegration of an implant can be affected by the characteristics of the implant, the surgical procedure, and patient-dependent variables that can affect the quantity and quality of bone (**Table 1**). Osteoporosis, characterized by bone loss, microstructural alterations and a reduced bone regeneration capacity, has been considered a potential contraindication to or risk factor for dental implant placement. It has been established that osteoporosis affects the jaw in the same manner as other bones of the skeleton and thus may also alter the metabolic microenvironment of bone around the implant [56]. Bone is constantly metabolized throughout life by bone-resorbing osteoclasts and bone-forming osteoblasts. Osteocytes play an active role in modulating the process of bone metabolism through the lacunocanalicular system [57, 58]. Studies in osteoporotic animal models have shown altered osseointegration, especially in trabecular bone, which resulted in a significant reduction in bone-implant contact [59–61].

Elucidation of the role of osteocytes in peri-implant bone remodeling will help clarify the dynamics of bone metabolism following osseointegration. Since osteocytes

Author (year)	Study type/sample size	Follow-up period	Result/outcome
Becker et al. (2000) [45]	Retrospective case–control 49 cases, 49 controls, 5 osteoporosis, 7 osteoporosis	3.9 years	No association between dual-energy X-ray absorptiometry values or diagnosis of osteoporosis and implant loss
Friberg et al. (2001) [40]	Retrospective cohort 13 cases of osteoporosis	3.4 years	Successful implantation in osteoporosis provided adapted bone technique used and increased healing time allowed
von Wowern and Gotfredsen (2001) [46]	Retrospective cohort, 7 cases of osteoporosis, 11 controls	5 years	Mandibular osteoporosis a risk factor for peri-implant bone loss
Amorim et al. (2007) [47]	Retrospective case–control 19 cases of osteoporosis, 20 controls	9 months	No difference in implant survival between the two groups
Amorim et al. (2007) [47]	Prospective, 19 cases of osteoporosis, 20 controls	9 months	Failure in 1 (2.56%) case of osteoporosis, 0 controls
Alsaadi et al. (2008) [48]	Retrospective study, 187 total, 29 cases of osteoporosis	2 years	Failure in 0 cases of osteoporosis and 14 controls
Alsaadi et al. (2008) [49]	Retrospective, 19 cases of osteoporosis, 393 controls	2 years	Failure in 9 (13.24%) cases of osteoporosis and 92 (6.3%) controls
Holahan et al. (2008) [50]	Retrospective, 94 controls, 57 cases of osteopenia, 41 cases of osteoporosis	10 years	No difference between controls and cases; equal implant survival in all groups.
Dvorak et al. (2011) [51]	Cross-sectional, 46 cases of osteoporosis, 16 cases of osteopenia, 115 controls	6 ± 4 years	Failure in 6 (13%) cases of osteoporosis, 3 (18.75%) cases of osteopenia, and 15 (13%) controls
de Souza et al. (2013) [52]	Retrospective, 6 cases of osteoporosis, 186 controls	1 year	Failure in 12 (50%) cases of osteoporosis and 203 (29%) controls
Famili and Zavoral (2015) [53]	Case–control study, 30 patients	2 years	No difference: 100% survival
Siebert et al. (2015) [54]	Prospective study, 24 patients	1 year	100% implant survival
Temmerman et al. (2017) [55]	Prospective study, 48 patients	1 year	100% implant survival

Table 1.
Studies evaluating the outcome of dental implants among subjects with osteoporosis.

are the terminal cells of osteoblasts, understanding the relationship between osteocytes and implants will also shed light on the relationship between osteoblasts and implants in early bone formation. Research on the influence of estrogen deficiency and its treatment with alendronate and estrogen on bone density around osseointegrated implants in rats has shown that estrogen deprivation has a negative effect only on trabecular bone and that treatment with estrogen and alendronate can effectively prevent bone loss around osseointegrated implants [62]. Histological studies in humans have also shown the osseointegration of implants retrieved from osteoporotic individuals [63, 64]. A histological study that evaluated the bone-implant contact of

failed implants after retrieval showed no differences between implants originating from patients with and without osteoporosis [41]. The most important complication of implant placement in osteoporotic patients is bisphosphonate-related osteonecrosis of the jaw (BRONJ), that interferes with osseointegration. BPs act by inhibiting and inducing the apoptosis of osteoclasts, increasing collagen synthesis and inhibiting osteoblast proliferation. A systematic review showed that the placement of dental implants in osteoporotic patients who used oral BPs for less than five years did not develop BRONJ and that most adverse effects were related to the intravenous administration of BPs [65].

5. Dental implants and bisphosphonate therapy

Bisphosphonates are widely prescribed for the management of osteoporosis. They are pyrophosphate analogs containing a phosphate-carbon-phosphate bond, which is stable against chemical and enzymatic hydrolysis. BPs strongly bind to hydroxyapatite (HA) crystals and potentially inhibit osteoclast-mediated bone resorption while minimally inhibiting osteoblast activity [66]. BPs are used for increasing or maintaining bone mass and reducing excessive bone turnover [67]. By inhibiting osteoclast-mediated bone resorption, BPs contribute to an increase in bone mineral density as well as a decrease in the risk of fracture [68, 69]. Two routes of administration are commonly used: oral and intravenous. BPs act almost exclusively on bone when administered at physiological doses because of their specific affinity to bone; they are deposited both in newly formed bone and in proximity to osteoclasts. The half-life of BPs in the circulation is quite short, ranging from thirty minutes to two hours [70]. However, once incorporated into bone tissue, they can persist for up to 10 years, depending on the skeletal turnover time [71]. Oral BPs are commonly used in the treatment of osteoporosis, Paget's disease, and osteogenesis imperfecta, whereas intravenous BPs are used in the treatment of osteolytic tumors, hypercalcemia of malignancy, multiple myeloma, bone metastases from solid tumors, and other tumors [72, 73]. The most common oral BPs are alendronate (Fosamax), risedronate (Actonel), and ibandronate (Boniva).

There have been conflicting reports regarding installation of dental implants in patients undergoing bisphosphonate therapy [74, 75]. Experimental studies have shown a positive effect of BPs on peri-implant bone in experimental animals [76, 77]. Although some studies have reported that BPs have no effect on implant stability, [78] a few other reports have suggested that BPs may have a negative impact on osseointegration. Additionally, osseointegration failure has been reported in patients on BP therapy [79–81]. Current guidelines indicate that implant placement may be avoided if the patient has a serious bone disease or is on high doses of BPs. Osteoporotic patients on lower doses need to provide fully informed consent before proceeding with treatment, and patients with existing implants on BP therapy should be regularly monitored. Increased bone density around the implant may also occur. If bone pain or loss of integrity occurs, the superstructure should be removed, and the implant should be left submerged [82]. In such cases, bone surgery must be avoided because the bone is exceedingly dense, and avascular necrosis may occur (**Figure 2**).

The chances of developing osteonecrosis depend on the potency and duration of BP exposure [84–86]. BRONJ is a condition characterized by nonhealing exposed necrotic bone in the mandible or maxilla persisting for more than 8 weeks in a patient who has taken or is currently taking a BP and who has no history of radiation therapy of the

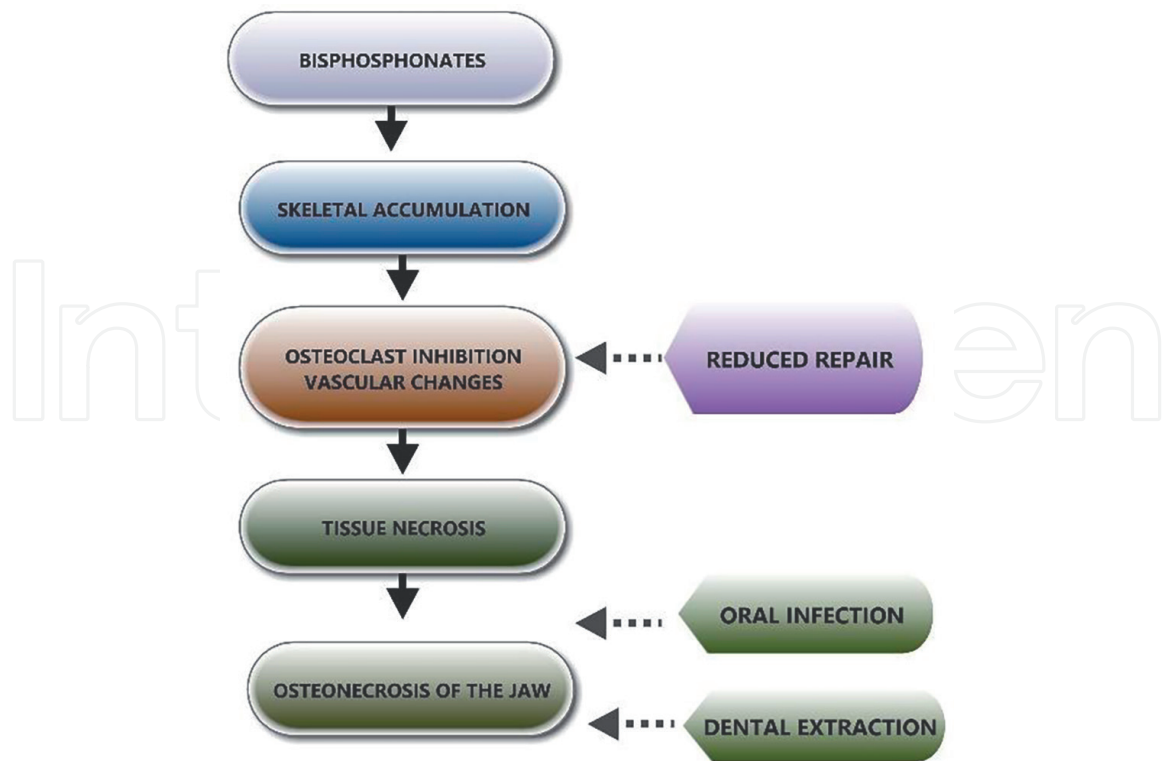


Figure 2.
Schematic diagram showing the possible mechanism of development of BP-associated osteonecrosis. BP, bisphosphonate (adapted and modified from Anil et al. [83]).

jaw [84, 87]. Incidents of osteonecrosis of the jaw have been reported in persons using BPs and undergoing invasive dental treatment procedures, including tooth extraction, dental implant placement, and surgical and nonsurgical periodontal treatment [88, 89]. Although BPs have been reported to cause oral mucosal alterations, the changes occurring in the jaw bone are of greater significance to the dentist [90, 91]. Osteonecrosis of the jaw is less often reported among patients who have received treatment with oral BPs at lower doses, used for osteoporosis, than among patients who have received treatment with higher doses, used for metastatic cancer. Even though the exact incidence of BRONJ is unknown, reports have estimated it to be approximately 1 in 10,000 for intravenous BPs. There is also an incomplete understanding of how BP therapy may affect tissue healing and the success rate of dental implantation [75, 80]. Advanced cases of BRONJ can lead to pathological fractures, especially in edentulous patients with long-standing oral implants [92].

6. Bisphosphonate-related osteonecrosis of the jaw

BPs alter the bone tissue metabolism by inhibiting bone resorption and reducing bone turnover. At the cellular level, BPs affect the recruitment of osteoclasts, their viability, the bioavailability of their progenitors, and their effect on bone. From a molecular point BPs have been proposed to modulate the function of osteoclasts by reacting with a surface receptor or with an intracellular enzyme [93]. BRONJ is defined as an area of exposed bone in the maxillofacial region that does not heal within 8 weeks in a patient who is receiving treatment with a BP. BRONJ develops secondary to the mechanisms of action of BPs in anti-osteoclastic and antiangiogenic

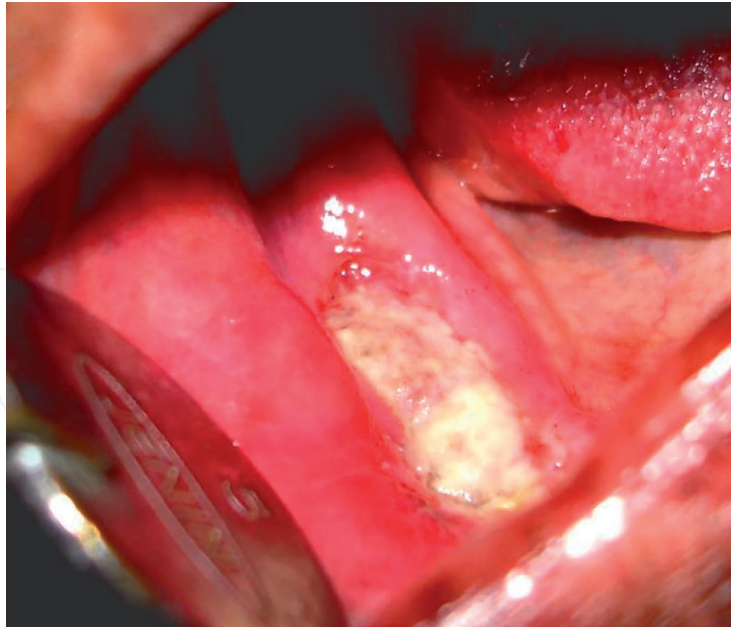


Figure 3.
BRONJ in a 63-year-old woman subsequent to extraction of mandibular molar. The patient was on intravenous zoledronate for 1 year (adapted and modified from Anil et al. [83]).

activities, which alter bone metabolism, inhibit bone resorption and reduce bone turnover. Additional signs and symptoms may include pain, swelling, paresthesia, suppuration, soft tissue ulceration, intra- or extraoral sinus tract formation, tooth loosening, and radiographic variability. These symptoms most commonly occur at sites of previous tooth extractions or other dental surgical interventions but may occur spontaneously. The exact role of BPs remains to be determined, and alterations in bone homeostasis coupled with odontogenic or surgical insult, or both, may be key to the development of osteonecrosis of the jaw [88, 93]. Cases of BRONJ are more common when frequent doses of intravenous BPs are used in treating malignancy than when oral BP regimens are used in treating osteoporosis [94].

The diagnosis of BRONJ is primarily based on the patient's history and the findings of a clinical examination. Most of the time, these patients have necrotic bone exposure ranging from a few millimeters to larger areas and can be asymptomatic for weeks, months, or years (**Figure 3**). The incidence of BRONJ is higher in the mandible than in the maxilla and in areas of thin mucosa overlying bony prominences, such as tori and the mylohyoid ridge. The management of BRONJ mainly comprises pain control measures, antibiotic therapy, mouth rinsing, BP discontinuation, hyperbaric chamber therapy, laser therapy, and surgical debridement [95, 96]. Assessments of markers of bone resorption, such as the serum C-terminal telopeptide of type I collagen; CTx or ITCP) test, can be used to assess the risk of developing BRONJ. Patients with a CTx level lower than 150 pg./mL should consider discontinuation of BP therapy for a period of 4–6 months.

7. Conclusion

Osteoporosis is a common skeletal disorder characterized by reduced bone mass and altered bone architecture, leading to an increase in bone fragility and the risk of fracture. This condition is associated with a decrease in bone quality and quantity,

which might affect dental implant osseointegration. The placement of dental implants in patients with osteoporosis is still debated because of the quality of the bone, which is a key factor that determines the success of dental implantation. Although osteoporosis is not considered a risk factor for dental implant failure, the initial implant stability can be influenced by both the local and skeletal bone density, and the healing time is prolonged in osteoporotic patients. While the risk of osteonecrosis of the jaw in patients on BPs is low, patients should be informed of this risk and sign a consent form including this specific point. Based on the available literature, it can be concluded that implants placed in patients with systemic osteoporosis did not present higher failure rates than those placed in patients without osteoporosis.

Conflict of interest

The authors declare no conflict of interest.

Author details

Sara Gibreel¹, Hasaan Gassim Mohamed², Amartya Raj Suraj¹
and Sukumaran Anil^{1,3*}

1 Department of Dentistry, Oral Health Institute, Hamad Medical Corporation,
Doha, Qatar

2 Dentistry Department, Primary Health Care Corporation, Doha, Qatar

3 College of Dental Medicine, Qatar University, Doha, Qatar

*Address all correspondence to: anil@graduate.hku.hk

IntechOpen

© 2021 The Author(s). Licensee IntechOpen. This chapter is distributed under the terms of the Creative Commons Attribution License (<http://creativecommons.org/licenses/by/3.0>), which permits unrestricted use, distribution, and reproduction in any medium, provided the original work is properly cited. 

References

- [1] Johnell O, Kanis JA: An estimate of the worldwide prevalence and disability associated with osteoporotic fractures. *Osteoporos Int* 2006, 17(12):1726-1733.
- [2] Gadeleta SJ, Boskey AL, Paschalis E, Carlson C, Menschik F, Baldini T, Peterson M, Rimnac CM: A physical, chemical, and mechanical study of lumbar vertebrae from normal, ovariectomized, and nandrolone decanoate-treated cynomolgus monkeys (*Macaca fascicularis*). *Bone* 2000, 27(4):541-550.
- [3] Feng X, McDonald JM: Disorders of bone remodeling. *Annu Rev Pathol* 2011, 6:121-145.
- [4] Li Y, He S, Hua Y, Hu J: Effect of osteoporosis on fixation of osseointegrated implants in rats. *J Biomed Mater Res B Appl Biomater* 2017, 105(8):2426-2432.
- [5] Basudan AM, Shaheen MY, Niazy AA, van den Beucken J, Jansen JA, Alghamdi HS: Histomorphometric Evaluation of Peri-Implant Bone Response to Intravenous Administration of Zoledronate (Zometa®) in an Osteoporotic Rat Model. *Materials (Basel)* 2020, 13(22).
- [6] Ozawa S, Ogawa T, Iida K, Sukotjo C, Hasegawa H, Nishimura RD, Nishimura I: Ovariectomy hinders the early stage of bone-implant integration: histomorphometric, biomechanical, and molecular analyses. *Bone* 2002, 30(1):137-143.
- [7] Chen H, Liu N, Xu X, Qu X, Lu E: Smoking, radiotherapy, diabetes and osteoporosis as risk factors for dental implant failure: a meta-analysis. *PLoS One* 2013, 8(8):e71955.
- [8] de Medeiros F, Kudo GAH, Leme BG, Saraiva PP, Verri FR, Honório HM, Pellizzer EP, Santiago Junior JF: Dental implants in patients with osteoporosis: a systematic review with meta-analysis. *Int J Oral Maxillofac Surg* 2018, 47(4):480-491.
- [9] Darcey J, Horner K, Walsh T, Southern H, Marjanovic EJ, Devlin H: Tooth loss and osteoporosis: to assess the association between osteoporosis status and tooth number. *British Dental Journal* 2013, 214(4):E10-E10.
- [10] Tarantino U, Cerocchi I, Scialdoni A, Saturnino L, Feola M, Celi M, Liuni FM, Iolascon G, Gasbarra E: Bone healing and osteoporosis. *Aging Clin Exp Res* 2011, 23(2 Suppl):62-64.
- [11] Marco F, Milena F, Gianluca G, Vittoria O: Peri-implant osteogenesis in health and osteoporosis. *Micron* 2005, 36(7-8):630-644.
- [12] Du Z, Chen J, Yan F, Xiao Y: Effects of Simvastatin on bone healing around titanium implants in osteoporotic rats. *Clinical Oral Implants Research* 2009, 20(2):145-150.
- [13] Dudeck J, Rehberg S, Bernhardt R, Schneiders W, Zierau O, Inderchand M, Goebbels J, Vollmer G, Fratzl P, Scharnweber D *et al*: Increased bone remodelling around titanium implants coated with chondroitin sulfate in ovariectomized rats. *Acta Biomater* 2014, 10(6):2855-2865.
- [14] Abtahi J, Agholme F, Sandberg O, Aspenberg P: Effect of local vs. systemic bisphosphonate delivery on dental implant fixation in a model of osteonecrosis of the jaw. *J Dent Res* 2013, 92(3):279-283.

- [15] Fujimoto T, Niimi A, Sawai T, Ueda M: Effects of steroid-induced osteoporosis on osseointegration of titanium implants. *Int J Oral Maxillofac Implants* 1998, 13(2):183-189.
- [16] Nasu M, Amano Y, Kurita A, Yosue T: Osseointegration in implant-embedded mandible in rats fed calcium-deficient diet: a radiological study. *Oral Dis* 1998, 4(2):84-89.
- [17] Tuck SP, Francis RM: Osteoporosis. *Postgraduate Medical Journal* 2002, 78(923):526-532.
- [18] Poole K, Compston J: Osteoporosis and its management. *British Medical Journal* 2006, 333(7581):1251.
- [19] Jeffcoat M: The association between osteoporosis and oral bone loss. *Journal of periodontology* 2005, 76(11-s):2125-2132.
- [20] Riggs B, Khosla S, Melton III L: Sex steroids and the construction and conservation of the adult skeleton. *Endocrine reviews* 2002, 23(3):279.
- [21] Vidal O, Lindberg M, Hollberg K, Baylink D, Andersson G, Lubahn D, Mohan S, Gustafsson J, Ohlsson C: Estrogen receptor specificity in the regulation of skeletal growth and maturation in male mice. *Proceedings of the National Academy of Sciences of the United States of America* 2000, 97(10):5474.
- [22] Weitzmann MN, Pacifici R: Estrogen deficiency and bone loss: an inflammatory tale. *J Clin Invest* 2006, 116(5):1186-1194.
- [23] Nakamura T, Imai Y, Matsumoto T, Sato S, Takeuchi K, Igarashi K, Harada Y, Azuma Y, Krust A, Yamamoto Y *et al*: Estrogen prevents bone loss via estrogen receptor alpha and induction of Fas ligand in osteoclasts. *Cell* 2007, 130(5):811-823.
- [24] Khosla S, Oursler MJ, Monroe DG: Estrogen and the skeleton. *Trends Endocrinol Metab* 2012, 23(11):576-581.
- [25] Mödder UI, Clowes JA, Hoey K, Peterson JM, McCready L, Oursler MJ, Riggs BL, Khosla S: Regulation of circulating sclerostin levels by sex steroids in women and in men. *J Bone Miner Res* 2011, 26(1):27-34.
- [26] Prestwood K, Pilbeam C, Burleson J, Woodiel F, Delmas P, Deftos L, Raisz L: The short-term effects of conjugated estrogen on bone turnover in older women. *Journal of Clinical Endocrinology & Metabolism* 1994, 79(2):366.
- [27] Albertsson D, Mellstrom D, Petersson C, Thulesius H, Eggertsen R: Hip and fragility fracture prediction by 4-item clinical risk score and mobile heel BMD: a women cohort study. *BMC Musculoskelet Disord* 2010, 11:55.
- [28] Robbins J, Aragaki AK, Kooperberg C, Watts N, Wactawski-Wende J, Jackson RD, LeBoff MS, Lewis CE, Chen Z, Stefanick ML *et al*: Factors associated with 5-year risk of hip fracture in postmenopausal women. *JAMA : the journal of the American Medical Association* 2007, 298(20):2389-2398.
- [29] Kelepouris N, Harper K, Gannon F, Kaplan F, Haddad J: Severe osteoporosis in men. *Annals of internal medicine* 1995, 123(6):452.
- [30] White SC, Rudolph DJ: Alterations of the trabecular pattern of the jaws in patients with osteoporosis. *Oral Surg Oral Med Oral Pathol Oral Radiol Endod* 1999, 88(5):628-635.
- [31] White SC: Oral radiographic predictors of osteoporosis.

Dentomaxillofac Radiol 2002, 31(2):84-92.

[32] Barbu HM, Comaneanu RM, Andreescu CF, Mijiritsky E, Nita T, Lorean A: Dental Implant Placement in Patients With Osteoporosis. Journal of Craniofacial Surgery 2015, 26(6).

[33] Devlin H, Horner K: Diagnosis of osteoporosis in oral health care. Journal of Oral Rehabilitation 2008, 35(2):152-157.

[34] Qi MC, Zhou XQ, Hu J, Du ZJ, Yang JH, Liu M, Li XM: Oestrogen replacement therapy promotes bone healing around dental implants in osteoporotic rats. Int J Oral Maxillofac Surg 2004, 33(3):279-285.

[35] Hwang D, Wang HL: Medical contraindications to implant therapy: part I: absolute contraindications. Implant Dent 2006, 15(4):353-360.

[36] Op Heij DG, Opdebeeck H, van Steenberghe D, Quirynen M: Age as compromising factor for implant insertion. Periodontol 2000 2003, 33:172-184.

[37] Hwang D, Wang HL: Medical contraindications to implant therapy: Part II: Relative contraindications. Implant Dent 2007, 16(1):13-23.

[38] Alsaadi G, Quirynen M, Komárek A, Van Steenberghe D: Impact of local and systemic factors on the incidence of oral implant failures, up to abutment connection. Journal of clinical periodontology 2007, 34(7):610-617.

[39] Tenenbaum HC, Shelemay A, Girard B, Zohar R, Fritz PC: Bisphosphonates and periodontics: potential applications for regulation of bone mass in the periodontium and other therapeutic/diagnostic uses. J Periodontol 2002, 73(7):813-822.

[40] Friberg B, Ekestubbe A, Mellström D, Sennerby L: Brånemark implants and osteoporosis: a clinical exploratory study. Clin Implant Dent Relat Res 2001, 3(1):50-56.

[41] Shibli JA, Aguiar KC, Melo L, d'Avila S, Zenóbio EG, Faveri M, Iezzi G, Piattelli A: Histological comparison between implants retrieved from patients with and without osteoporosis. Int J Oral Maxillofac Surg 2008, 37(4):321-327.

[42] Liu Y, Hu J, Liu B, Jiang X, Li Y: The effect of osteoprotegerin on implant osseointegration in ovariectomized rats. Arch Med Sci 2017, 13(2):489-495.

[43] Shibli JA, Aguiar KC, Melo L, Ferrari DS, D'Avila S, Iezzi G, Piattelli A: Histologic analysis of human peri-implant bone in type 1 osteoporosis. J Oral Implantol 2008, 34(1):12-16.

[44] Wagner F, Schuder K, Hof M, Heuberger S, Seemann R, Dvorak G: Does osteoporosis influence the marginal peri-implant bone level in female patients? A cross-sectional study in a matched collective. Clin Implant Dent Relat Res 2017, 19(4):616-623.

[45] Becker W, Hujoel PP, Becker BE, Willingham H: Osteoporosis and implant failure: an exploratory case-control study. J Periodontol 2000, 71(4):625-631.

[46] von Wowern N, Gotfredsen K: Implant-supported overdentures, a prevention of bone loss in edentulous mandibles? A 5-year follow-up study. Clin Oral Implants Res 2001, 12(1):19-25.

[47] Amorim MA, Takayama L, Jorgetti V, Pereira RM: Comparative study of axial and femoral bone mineral density and parameters of mandibular bone quality in patients receiving dental implants. Osteoporos Int 2007, 18(5):703-709.

- [48] Alsaadi G, Quirynen M, Komarek A, van Steenberghe D: Impact of local and systemic factors on the incidence of late oral implant loss. *Clin Oral Implants Res* 2008, 19(7):670-676.
- [49] Alsaadi G, Quirynen M, Michiles K, Teughels W, Komárek A, van Steenberghe D: Impact of local and systemic factors on the incidence of failures up to abutment connection with modified surface oral implants. *Journal of clinical periodontology* 2008, 35(1):51-57.
- [50] Holahan CM, Koka S, Kennel KA, Weaver AL, Assad DA, Regennitter FJ, Kademani D: Effect of osteoporotic status on the survival of titanium dental implants. *Int J Oral Maxillofac Implants* 2008, 23(5):905-910.
- [51] Dvorak G, Arnhart C, Heuberger S, Huber CD, Watzek G, Gruber R: Peri-implantitis and late implant failures in postmenopausal women: a cross-sectional study. *Journal of clinical periodontology* 2011, 38(10):950-955.
- [52] de Souza JG, Neto AR, Filho GS, Dalago HR, de Souza Júnior JM, Bianchini MA: Impact of local and systemic factors on additional peri-implant bone loss. *Quintessence Int* 2013, 44(5):415-424.
- [53] Famili P, Zavoral JM: Low Skeletal Bone Mineral Density Does Not Affect Dental Implants. *J Oral Implantol* 2015, 41(5):550-553.
- [54] Siebert T, Jurkovic R, Stelova D, Strecha J: Immediate Implant Placement in a Patient With Osteoporosis Undergoing Bisphosphonate Therapy: 1-Year Preliminary Prospective Study. *J Oral Implantol* 2015, 41 Spec No:360-365.
- [55] Temmerman A, Rasmusson L, Kübler A, Thor A, Quirynen M: An open, prospective, non-randomized, controlled, multicentre study to evaluate the clinical outcome of implant treatment in women over 60 years of age with osteoporosis/osteopenia: 1-year results. *Clin Oral Implants Res* 2017, 28(1):95-102.
- [56] de Souza Faloni AP, Schoenmaker T, Azari A, Katchburian E, Cerri PS, de Vries TJ, Everts V: Jaw and long bone marrows have a different osteoclastogenic potential. *Calcif Tissue Int* 2011, 88(1):63-74.
- [57] Bonewald LF: The amazing osteocyte. *J Bone Miner Res* 2011, 26(2):229-238.
- [58] Gowen LC, Petersen DN, Mansolf AL, Qi H, Stock JL, Tkalcevic GT, Simmons HA, Crawford DT, Chidsey-Frink KL, Ke HZ *et al*: Targeted disruption of the osteoblast/osteocyte factor 45 gene (OF45) results in increased bone formation and bone mass. *J Biol Chem* 2003, 278(3):1998-2007.
- [59] Alghamdi HS, van den Beucken JJ, Jansen JA: Osteoporotic rat models for evaluation of osseointegration of bone implants. *Tissue Eng Part C Methods* 2014, 20(6):493-505.
- [60] Korn P, Kramer I, Schlottig F, Tödtman N, Eckelt U, Bürki A, Ferguson SJ, Kautz A, Schnabelrauch M, Range U *et al*: Systemic sclerostin antibody treatment increases osseointegration and biomechanical competence of zoledronic-acid-coated dental implants in a rat osteoporosis model. *Eur Cell Mater* 2019, 37: 333-346.
- [61] Duarte PM, César Neto JB, Gonçalves PF, Sallum EA, Nociti j F: Estrogen deficiency affects bone healing around titanium implants: a histometric

study in rats. *Implant Dent* 2003, 12(4):340-346.

[62] Giro G, Gonçalves D, Sakakura CE, Pereira RM, Marcantonio Júnior E, Orrico SR: Influence of estrogen deficiency and its treatment with alendronate and estrogen on bone density around osseointegrated implants: radiographic study in female rats. *Oral Surg Oral Med Oral Pathol Oral Radiol Endod* 2008, 105(2):162-167.

[63] de Melo L, Piattelli A, Lezzi G, d'Avila S, Zenóbio EG, Shibli JA: Human histologic evaluation of a six-year-old threaded implant retrieved from a subject with osteoporosis. *J Contemp Dent Pract* 2008, 9(3):99-105.

[64] Shibli JA, Grande PA, d'Avila S, Iezzi G, Piattelli A: Evaluation of human bone around a dental implant retrieved from a subject with osteoporosis. *Gen Dent* 2008, 56(1):64-67.

[65] Madrid C, Sanz M: What impact do systemically administrated bisphosphonates have on oral implant therapy? A systematic review. *Clin Oral Implants Res* 2009, 20 Suppl 4:87-95.

[66] Peter B, Gauthier O, Laib S, Bujoli B, Guicheux J, Janvier P, van Lenthe GH, Muller R, Zambelli PY, Bouler JM *et al*: Local delivery of bisphosphonate from coated orthopedic implants increases implants mechanical stability in osteoporotic rats. *Journal of biomedical materials research Part A* 2006, 76(1):133-143.

[67] Greenspan S, Harris S, Bone H, Miller P, Orwoll E, Watts N, Rosen C: Bisphosphonates: safety and efficacy in the treatment and prevention of osteoporosis. *American Family Physician* 2000, 61(9):2731-2736.

[68] Fleisch HA: Bisphosphonates: preclinical aspects and use in osteoporosis. *Ann Med* 1997, 29(1):55-62.

[69] Russell RG, Rogers MJ, Frith JC, Luckman SP, Coxon FP, Benford HL, Croucher PI, Shipman C, Fleisch HA: The pharmacology of bisphosphonates and new insights into their mechanisms of action. *J Bone Miner Res* 1999, 14:53-65.

[70] Sparidans RW, Twiss IM, Talbot S: Bisphosphonates in bone diseases. *Pharm World Sci* 1998, 20(5):206-213.

[71] Drake MT, Clarke BL, Khosla S: Bisphosphonates: mechanism of action and role in clinical practice. *Mayo Clinic proceedings* 2008, 83(9):1032-1045.

[72] Coleman R: Risks and benefits of bisphosphonates. *Br J Cancer* 2008, 98(11):1736-1740.

[73] Greenspan S, Harris S, Bone H, Miller P, Orwoll E, Watts N, Rosen C: Bisphosphonates: safety and efficacy in the treatment and prevention of osteoporosis. *Am Fam Physician* 2000, 61(9):2731-2736.

[74] Goss A, Bartold M, Sambrook P, Hawker P: The nature and frequency of bisphosphonate-associated osteonecrosis of the jaws in dental implant patients: a South Australian case series. *J Oral Maxillofac Surg* 2010, 68(2):337-343.

[75] Javed F, Almas K: Osseointegration of dental implants in patients undergoing bisphosphonate treatment: a literature review. *J Periodontol* 2010, 81(4):479-484.

[76] Stadelmann V, Gauthier O, Terrier A, Bouler J, Pioletti D, Nantes F: Implants delivering bisphosphonate locally increase periprosthetic bone density in

an osteoporotic sheep model. A pilot study. *Eur Cell Mater* 2008, 16:10-16.

[77] Yildiz A, Esen E, Kürkçü M, Damlar I, Daglıoğlu K, Akova T: Effect of zoledronic acid on osseointegration of titanium implants: an experimental study in an ovariectomized rabbit model. *J Oral Maxillofac Surg* 2010, 68(3):515-523.

[78] Shabestari GO, Shayesteh YS, Khojasteh A, Alikhasi M, Moslemi N, Aminian A, Masaali R, Eslami B, Treister NS: Implant placement in patients with oral bisphosphonate therapy: a case series. *Clin Implant Dent Relat Res* 2010, 12(3):175-180.

[79] Starck W, Epker B: Failure of osseointegrated dental implants after diphosphonate therapy for osteoporosis: a case report. *Int J Oral Maxillofac Implants* 1995, 10(1):74-78.

[80] Kasai T, Pogrel MA, Hossaini M: The prognosis for dental implants placed in patients taking oral bisphosphonates. *J Calif Dent Assoc* 2009, 37(1):39-42.

[81] Shirota T, Nakamura A, Matsui Y, Hatori M, Nakamura M, Shintani S: Bisphosphonate-related osteonecrosis of the jaw around dental implants in the maxilla: report of a case. *Clin Oral Implants Res* 2009, 20(12):1402-1408.

[82] Serra M, Llorca C, Donat F: Oral implants in patients receiving bisphosphonates: a review and update. *Med Oral Patol Oral Cir Bucal* 2008, 13:E755-E760.

[83] Anil S, Preethanath RS, AlMoharib HS, Kamath KP, Anand PS: Impact of osteoporosis and its treatment on oral health. *Am J Med Sci* 2013, 346(5):396-401.

[84] Bagan J, Scully C, Sabater V, Jimenez Y: Osteonecrosis of the jaws in patients treated with intravenous bisphosphonates (BRONJ): A concise update. *Oral Oncol* 2009, 45(7):551-554.

[85] Kawahara M, Kuroshima S, Sawase T: Clinical considerations for medication-related osteonecrosis of the jaw: a comprehensive literature review. *Int J Implant Dent* 2021, 7(1):47.

[86] Rupel K, Ottaviani G, Gobbo M, Contardo L, Tirelli G, Vescovi P, Di Lenarda R, Biasotto M: A systematic review of therapeutical approaches in bisphosphonates-related osteonecrosis of the jaw (BRONJ). *Oral Oncol* 2014, 50(11):1049-1057.

[87] Hoff AO, Toth BB, Altundag K, Johnson MM, Warneke CL, Hu M, Nooka A, Sayegh G, Guarneri V, Desrouleaux K *et al*: Frequency and risk factors associated with osteonecrosis of the jaw in cancer patients treated with intravenous bisphosphonates. *J Bone Miner Res* 2008, 23(6):826-836.

[88] Marx RE: Pamidronate (Aredia) and zoledronate (Zometa) induced avascular necrosis of the jaws: a growing epidemic. *J Oral Maxillofac Surg* 2003, 61(9):1115-1117.

[89] Ficarra G, Beninati F, Rubino I, Vannucchi A, Longo G, Tonelli P, Pini Prato G: Osteonecrosis of the jaws in periodontal patients with a history of bisphosphonates treatment. *Journal of clinical periodontology* 2005, 32(11):1123-1128.

[90] Gonzalez-Moles MA, Bagan-Sebastian JV: Alendronate-related oral mucosa ulcerations. *J Oral Pathol Med* 2000, 29(10):514-518.

[91] Demerjian N, Bolla G, Spreux A: Severe oral ulcerations induced by

alendronate. Clin Rheumatol 1999, 18(4):349-350.

[92] Pogrel M: Bisphosphonates and bone necrosis. J Oral Maxillofac Surg 2004, 62(3):391-392.

[93] Ruggiero SL, Mehrotra B, Rosenberg TJ, Engroff SL: Osteonecrosis of the jaws associated with the use of bisphosphonates: a review of 63 cases. J Oral Maxillofac Surg 2004, 62(5):527-534.

[94] Bamias A, Kastritis E, Bamia C, Moulopoulos LA, Melakopoulos I, Bozas G, Koutsoukou V, Gika D, Anagnostopoulos A, Papadimitriou C *et al*: Osteonecrosis of the jaw in cancer after treatment with bisphosphonates: incidence and risk factors. J Clin Oncol 2005, 23(34):8580-8587.

[95] Vescovi P, Merigo E, Manfredi M, Meleti M, Fornaini C, Bonanini M, Rocca JP, Nammour S: Nd:YAG laser biostimulation in the treatment of bisphosphonate-associated osteonecrosis of the jaw: clinical experience in 28 cases. Photomed Laser Surg 2008, 26(1):37-46.

[96] Magopoulos C, Karakinaris G, Telioudis Z, Vahtsevanos K, Dimitrakopoulos I, Antoniadis K, Delaroudis S: Osteonecrosis of the jaws due to bisphosphonate use. A review of 60 cases and treatment proposals. Am J Otolaryngol 2007, 28(3):158-163.