

We are IntechOpen, the world's leading publisher of Open Access books Built by scientists, for scientists

6,900

Open access books available

185,000

International authors and editors

200M

Downloads

Our authors are among the

154

Countries delivered to

TOP 1%

most cited scientists

12.2%

Contributors from top 500 universities



WEB OF SCIENCE™

Selection of our books indexed in the Book Citation Index
in Web of Science™ Core Collection (BKCI)

Interested in publishing with us?
Contact book.department@intechopen.com

Numbers displayed above are based on latest data collected.
For more information visit www.intechopen.com



Management of Hunner Lesion in Interstitial Cystitis/Bladder Pain Syndrome Patients

Kwang Jin Ko and Kyu-Sung Lee

Abstract

Interstitial cystitis/bladder pain syndrome (IC/BPS) is a chronic condition characterized by chronic pelvic pain related to the bladder. One phenotype of IC/BPS is the Hunner lesion type IC/BPS. Hunner lesion exhibits typical features such as mucosal ulceration, fibrosis, and severe inflammation. The tissue surrounding the Hunner lesion may show lymphoplasmacytic infiltrates, and mast cells are increased in the lamina propria. In this chapter, we discuss intravesical treatment, endoscopic treatment, and partial cystectomy with augmentation cystoplasty for the management of Hunner lesion in IC/BPS patients.

Keywords: Bladder pain syndrome, Endoscopic treatment, Hunner lesion, Interstitial cystitis, Intravesical treatment

1. Introduction

Interstitial cystitis/bladder pain syndrome (IC/BPS) is a condition characterized by chronic pelvic pain, pressure or discomfort perceived to be related to the urinary bladder and is accompanied by other urinary symptoms in the absence of confusable diseases [1]. Interstitial cystitis was first described by Skene in 1887, and its definition has changed over the past 100 years. Guy Hunner was the first to identify the characteristic cystoscopic findings associated with bladder pain that were initially called Hunner's ulcers. However, these cystoscopic findings are not characteristic of an ulcer and instead due to a severe inflammatory lesion; therefore, the term ulcer is no longer used. IC/BPS is divided into the Hunner type interstitial cystitis with Hunner lesion and bladder pain syndrome (BPS) without Hunner lesion [2]. Hunner type IC/BPS cystitis has characteristic endoscopic findings and distinct inflammatory histopathology, whereas BPS lacks both the endoscopic and histopathology findings. The Hunner lesion is described as a "circumscribed, red-denuded mucosal lesion with small vessels radiating toward a central scar, with fibrin deposit or coagulum" and a "velvet red patch that looks like carcinoma in situ" (Figure 1) [1].

During cystoscopic examination, it is crucially important to watch the bladder mucosa from the early phase of bladder filling, because Hunner lesions might be obscured shortly after bladder distension. Recent research has revealed significant differences in the demographics, clinical presentation, bladder pathology, urinary marker profiles, and treatment responses between patients with IC/BPS with

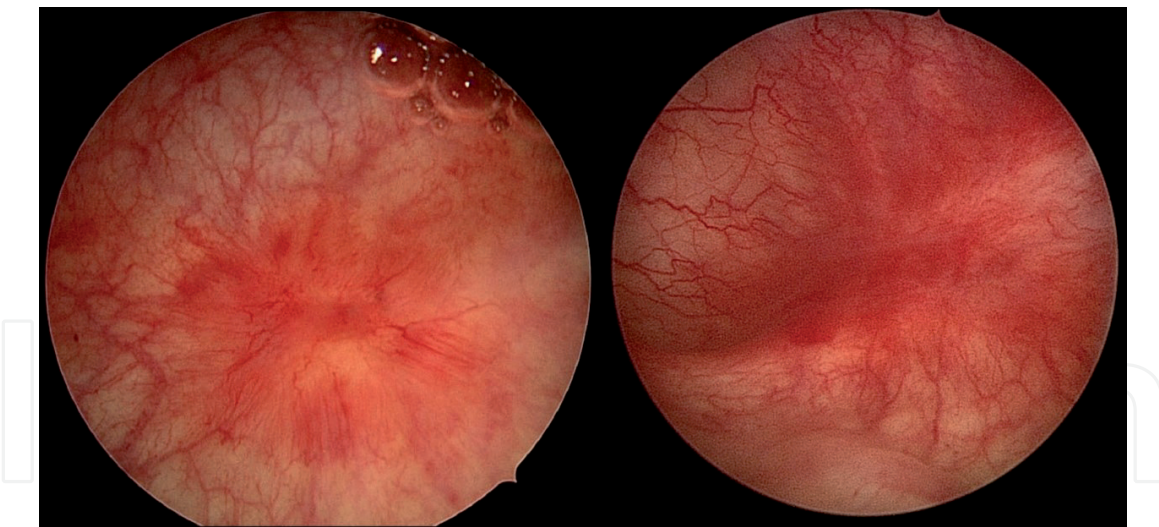


Figure 1.
Cystoscopic findings of Hunner lesion.

Hunner lesion and those without Hunner lesion. IC/BPS with Hunner lesions is a distinct inflammatory disorder characterized by epithelial denudation and frequent clonal expansion of infiltrating B cells, in association with biological processes involved in immune responses and infectious disease [3]. IC/BPS without Hunner lesions, however, rarely show histological changes and retain a preserved urothelium. IC/BPS with Hunner lesion has an incidence of up to 7% among IC/BPS patients and is categorized as a separate disease from non-Hunner IC/BPS [2, 4, 5]. In this chapter, we discuss intravesical treatment and endoscopic treatment of the Hunner lesion type IC/BPS.

2. Intravesical treatment

2.1 Dimethyl sulfoxide

Intravesical instillation of dimethyl sulfoxide (DMSO) was approved by the FDA in 1978 as a treatment method for IC/BPS. The mechanism of action of DMSO may involve anti-inflammatory effects, nerve blockade, smooth muscle relaxation, and collagen inhibition [6]. In the American Urological Association (AUA) guidelines, intravesical DMSO may be used for symptoms refractory to conservative measures or as initial treatment to address severe symptoms as second-line treatment [7]. In contrast, the EAU guideline does not recommend the use of DMSO because of insufficient evidence. A review by Cochrane also reported that the evidence for treating IC/BPS with intravesical DMSO is limited [6]. In 1988, Perez-Marrero et al. [8] published a trial with 33 patients and found that the proportion of patients with subjective symptom improvement was 53% among DMSO-injected patients compared with 18% in the placebo group. Since then, several single-arm studies have been reported, and most studies have confirmed the 61–95% of therapeutic effect of DMSO in patients who did not respond to medication or hydrodistension.

A multicenter, randomized, placebo-controlled trial examining DMSO compared with placebo in 96 patients was recently published in Japan in 2021 [9]. The mean O’Leary-Sant Interstitial Cystitis Symptom Index (ICSI) score at week 12 decreased by –5.2 in the DMSO group compared with a decrease by –3.4 in the placebo group, with a statistically significant difference between the groups. Although the O’Leary-Sant Interstitial Cystitis Problem Index (ICPI), number of frequency,

mean voided volume, and maximum voided volume showed significant improvement in the DMSO group compared with placebo group, there was no significant difference in the pain score between the two groups at 12 weeks. In this study, Hunner lesions were confirmed by cystoscopy at baseline in 86% of all patients. The authors speculated that the high incidence of Hunner lesions may have contributed to the clinical efficacy of DMSO. Although it was a small study, another study compared the efficacy of DMSO treatment between patients with and without Hunner lesion, and DMSO intravesical instillation showed a significant therapeutic effect only in IC/BPS patients with Hunner lesion. These findings suggest that IC/BPS with Hunner lesion and IC/BPS without Hunner lesion have different characteristics, and intravesical DMSO treatment with strong anti-inflammatory effects may play a greater role in Hunner lesion type IC/BPS.

2.2 Hyaluronic acid

Hyaluronic acid (HA) is a component of the glycosaminoglycan (GAG) layer of the bladder and is used to repair the GAG layer. A previous study synthesis in an inflammatory model of IC/BPS indicated that the mechanism of action involves modulation of urothelial permeability and stimulation of GAG [10]. HA is used at a concentration of 0.8% for intravesical instillation treatment for IC/BPS. In a previous study in which intravesical HA was administered for 4 weeks with monthly instillation for 6 months in patients with refractory IC/BPS, the response rate at 12 weeks was 71% and was maintained well until 20 weeks. In a study comparing HA and heparin intravesical instillation after hydrodistension, the therapeutic effect of severe IC/BPS patients was maintained longer in patients who received HA instillation than those who received heparin.

2.3 Chondroitin sulfate

Chondroitin sulfate (CS) is a glycoprotein and a component of the GAG layer of bladder mucosa. Commercially available CS products include iAluRil (Juno, AK), Uracyst (Galen, UK), and Uropol (Galen). Nickel et al. [11] performed a multicenter, randomized, double-blind study in which 20 ml of 2% CS or an inactive control solution were injected weekly for 8 weeks for female patients with IC/BPS. The proportion of patients with moderate or marked improvement at 11 weeks was 38.0% in the CS group and 31.3% in the control group; CS treatment in IC/BPS patients showed minor improvements in IC/BPS-related symptom and pain. In another recent report, intravesical CS was found to be superior to intravesical HA in terms of frequency, nocturia and ICPI in patients with BPS/IC during the 6 months of follow-up [12]. In refractory IC/BPS patients, the combination of 1.6% HA and 2.0% CS maintained improvement in symptoms for up to 3 years, indicating that the combination treatment might be more effective than the monotherapy [13].

3. Transurethral surgical ablation

3.1 Symptom control

If a Hunner lesion is confirmed by cystoscopy, transurethral surgical treatment should be performed. In 1971, Kerr et al. [14] first performed transurethral resection on a female patient with Hunner lesion who reported symptom relief for 1 year. In 2000, Peeker et al. [15] reported that 40% of patients who underwent transurethral resection of Hunner lesion had symptomatic improvement; the

remission rate was 34.5%, and patients remained in remission for 3 years after resection. In addition, Lee et al. [16] reported that combined hydrodistension and transurethral resection treatment increased bladder capacity and reduced the frequency of micturition and pain. Although the transurethral ablation methods, such as fulguration, coagulation, or resection of Hunner lesion, differ according to various studies, the pain visual analogue scale (VAS) significantly improved after transurethral ablation.

We performed a prospective, observational study of 72 patients with IC/BPS with Hunner lesion who underwent transurethral ablation and followed patients for 3 years [17]. At one month after surgery, the mean number of frequency and mean number of urgency episodes decreased sharply to 5.5 times and 9.4 times, respectively. Over the 12-month follow-up period, the number of frequency, urgency and VAS pain score increased compared with immediately after primary ablation treatment; however, these indices were all significantly better, even after 12 months.

3.2 Characteristics of recurrence

As the extent of Hunner lesion increases, the patient's pain and urinary symptoms tend to become more severe. The ICSI and ICPI and the maximum bladder capacity are significantly associated with the extent of Hunner lesion [18]. Nevertheless, it seems unlikely that patients with multiple Hunner lesion or a wider extent of Hunner lesion are more likely to show recurrence. Akiyama et al. [18] performed hydrodistension with fulguration for Hunner lesion and evaluated the outcome according to the extent of Hunner lesion; the authors found that the extent of Hunner lesion did not predict the need for repeat hydrodistension/fulguration. In our previous study, we were also unable to identify predictive factors related to recurrence. Lower maximal cystometric capacity [odds ratio (OR) 1.01, 95% CI 1.001–1.013; $P = 0.017$] was the only predictive factor related to early recurrence within 12 months, but sex, presence of previous hydrodistension, and number of Hunner lesions did not affect early recurrence [17]. Han et al. [19] also examined the recurrence pattern and predictors of Hunner lesion; the number of Hunner lesions had no effect on recurrence and only the Pelvic Pain and Urgency/Frequency Patient Symptom Scale (PUF) bother score (OR 1.142, 95% CI 1.016–1.284, $P = 0.026$) was a predictor related to recurrence of Hunner lesion. A PUF bother score greater than or equal to 7.5 was identified as the predictive cut-off value for recurrence, with a ROC area of 0.690 (sensitivity: 67.9%, specificity: 62.5%). In summary, the predictors of Hunner lesion recurrence have not yet been clearly identified; recurrence or progression does not appear to be faster in patients with multiple Hunner lesions and severe symptoms at the time of initial diagnosis.

One study evaluated the recurrence patterns of Hunner lesion after transurethral ablation and showed that 21.8% of Hunner lesions recurred in the previous ablation site, 18.8% recurred in a de novo site, and 59.4% recurred in both previous and de novo sites [19]. We analyzed the recurrence pattern through prospectively collected data of IC/BPS patients with Hunner lesion who underwent transurethral ablation (data not yet published). In our cases, Hunner lesion recurred in 120 of 210 patients with a median follow-up of 32 months. Among patients with a first recurrence, the proportion of patients with recurrence at the previous ablation site was 50.8% ($n = 61$), while 6.7% ($n = 8$) had recurrence of a new lesion, and 42.5% ($n = 51$) had recurrence at both previous and new sites. Overall, 90% of patients had recurrence around the previous ablation site, and less than 7% showed recurrence at a new site. Endoscopic treatment for Hunner lesion shows good efficacy in alleviating symptoms for a specific period of time after the procedure, but ultimately does not prevent Hunner lesion recurrence. This is considered a natural course of IC/BPS with

Hunner lesion disease with the characteristics of pancystitis. To prevent recurrence, the role of postoperative medication or intravesical treatment should be investigated. A recent pilot study reported that hydrodistension with fulguration of Hunner lesion plus maintenance DMSO therapy prolonged the recurrence-free time in patients with IC/BPS with Hunner lesion [20].

3.3 Does repeat treatment reduce recurrence?

One question regarding the recurrence of Hunner lesions is whether endoscopic treatment helps to suppress recurrence. However, current research indicates this may not be the case. In a 30-month prospective study of IC/BPS with Hunner lesion treatment naïve patients, the median recurrence-free time after the first endoscopic ablation of Hunner lesion was 12.0 ± 1.6 months (95% CI; 8.9–15.1). After the second endoscopic ablation, the median recurrence-free time was 18.0 ± 5.1 months (95% CI; 8.0–28.0), which was slightly increased, but the difference was not statistically significant ($p = 0.15$) [17]. Nevertheless, if Hunner lesion recurs, repeat ablation should be performed. Repeated endoscopic ablation does not lower the recurrence rate, but it is the only way to significantly reduce pain and improve quality of life in a less invasive manner.

3.4 Which endoscopic treatment, transurethral resection or coagulation, can further reduce recurrence?

Prominent ulcerations are observed in the histology of Hunner lesion, which may be covered by fibrin mixed with inflammatory cells, in particular neutrophils. The lesions are often wedge-shaped and involve the superficial part of the lamina propria, often extending into the muscularis mucosae. Thus, deep biopsies including bladder muscle are required, since the disease process involves superficial as well as deeper layers of the bladder wall [4]. Many symptoms and findings in IC/BPS with Hunner lesion may be ascribed to the release of mast cell–derived factors. Mast cells are often observed near nerves, and functional evidence suggests innervation of these cells. As a hypothesis that has been accepted so far, transurethral ablation might be the removal of intramural nerve endings engaged in the inflammatory process [21–23].

Whether transurethral resection of Hunner lesion is capable of disease control compared with coagulation/fulguration and prevents recurrence of Hunner lesion is an important question. A randomized controlled study was conducted to compare the therapeutic effect between transurethral resection and coagulation of Hunner lesion in 126 patients with IC/BPS [24]. The primary endpoint was the difference in recurrence-free time between the two surgical methods, and the secondary outcomes were voiding symptoms, pain level, and risk factors for recurrence. The median duration of follow-up was 11.0 months. There were no differences in the recurrence-free time between the treatment groups: 12.2 months (95% confidence interval [CI], 11.1–17.6) for the transurethral resection group and 11.5 months (95% CI, 9.03–16.1; $p = 0.735$) for the transurethral coagulation group. In addition, after both procedures, the mean daytime frequency, nocturia, urgency episodes, ICSI, ICPI, PUF symptom scale, and VAS for pain all improved significantly compared with baseline; however, there were no differences between the groups over 12 months. The type of surgery, age, number of Hunner lesions, and maximal cystometric capacity were not associated with the risk of recurrence. In safety analysis, in cases treated with transurethral resection, the incidence of bladder injury was 7.9%, which was slightly higher than that among patients treated with coagulation, which was 3.4%. Our findings did not suggest that one procedure was

superior to the other with regard to delaying recurrence. The choice of treatment did not affect the recurrence rate and produced comparable results, which may be because the ultimate peripheral denervation acted as the same thermal effect in both treatments.

3.5 Is it helpful to perform concurrent hydrodistension before transurethral ablation?

Some studies have suggested that concurrent hydrodistension with transurethral ablation may be helpful for symptom improvement [16, 18, 25]. However, the simultaneous performance of hydrodistension causes difficulties in complete removal of the Hunner lesion. Hydrodistension obscures the boundaries of the Hunner lesion, which are clearly identified through cystoscopy, and bleeding related to hydrodistension interferes with the field of surgical view. We believe that good efficacy can be maintained only with transurethral resection or coagulation of Hunner lesion without hydrodistension.

3.6 Technique of transurethral coagulation and resection of Hunner lesion

To coagulate or resect the Hunner lesion, the most important first step is to demarcate the lesion with the cautery before full bladder distension. Complete coagulation of the inside Hunner lesion of the boundary should then be performed. If starting from the inside of the lesion and working outward, reactive erythema spreads outward and obscures the original boundary of the lesion. In the case of transurethral resection, it is effective to use a bipolar loop. During the resection, resection should be performed as deeply as possible to the muscle layer using a cutting current. However, bladder damage can easily occur because the bladder wall of Hunner lesion is thin and friable. To prevent bladder injury, the quantity of irrigation fluid should be kept constant through suction attached to the outer sheath. Using this approach, the risk of bladder damage can be reduced by preventing the overdistension of bladder. Nevertheless, when it is difficult to complete resect the Hunner lesion or when the surgeon does not have extensive experience for transurethral resection, transurethral coagulation alone may be enough to control Hunner lesions.

4. Reconstructive surgery

Partial or complete cystectomy, augmentation cystoplasty, and urinary diversion are options indicated by the AUA and East Asian guidelines when all other therapies have failed [1, 7]. Rossberger et al. [26] found that reconstructive surgery resulted in the resolution of symptoms in 94% of patients with refractory IC/BPS with Hunner lesion. Patients with IC/BPS with Hunner lesion had a significantly smaller bladder capacity and benefited from reconstructive surgery compared with patients without Hunner lesion. We retrospectively analyzed 40 patients who underwent augmentation ileocystoplasty with supratrigonal cystectomy in patients with refractory IC/BPS with Hunner lesion [27]. After augmentation with supratrigonal cystectomy, significantly decreased pain and frequency and significantly increased bladder capacity were observed. Treatment failure was defined as the persistence of symptoms after surgery or a less than 30% reduction in ICSI from baseline, which accounted for 20% (8/40) of patients. Two of the patients had recurrent Hunner lesion around the bladder neck and additional endoscopic ablation was performed, while the remaining patients maintained oral medication [27].

There may be concerns about major complications after reconstructive surgery; however, most complications were minor and managed conservatively. Although six patients had vesicoureteral reflux after surgery, there was no deterioration of the upper urinary tract, so no additional treatment was required. Five patients received intermittent catheterization because they were unable to void after surgery, but the discomfort of catheterization was not considered a significant problem due to improvement in pain [27].

5. Conclusion

Although there is no definite treatment for IC/BPS, endoscopic treatment can be considered for Hunner lesion type IC/BPS. To confirm the presence of Hunner lesion, cystoscopy should be performed in patients with suspected IC/BPS. When performing cystoscopy, the bladder should not be inflated too much to prevent false-positive findings or bleeding due to mucosal fissure and to accurately diagnose Hunner lesion. Various intravesical therapies, including HA, CS, and DMSO, have been used for IC/BPS and are more effective in terms of anti-inflammatory effects and GAG layer replenishment in patients with Hunner lesion than patients without Hunner lesion. Overall, endoscopic ablation for Hunner lesion is an effective and minimally invasive treatment for patients with Hunner lesion type IC/BPS; this treatment strategy significantly reduces pain and improves voiding symptoms. Mucosal cracks that occur during hydrodistension are not real Hunner lesion, and we do not recommend performing hydrodistension first during endoscopic ablation. Repeated ablation does not suppress recurrence but does not reduce the therapeutic efficacy. There are various methods for endoscopic ablation; the main methods are coagulation or resection of Hunner lesion, and both are good treatment modalities to relieve the symptoms of Hunner lesion IC/BPS and improve quality of life. IC/BPS with Hunner lesion is a progressive disease, and it is necessary to establish a treatment protocol such as adjuvant intravesical treatment to reduce the risk of recurrence after transurethral ablation.

Author details

Kwang Jin Ko¹ and Kyu-Sung Lee^{1,2*}

¹ Department of Urology, Samsung Medical Center, Sungkyunkwan University School of Medicine, Seoul, Republic of Korea

² Research Institute for Future Medicine Samsung Medical Center, Seoul, Korea

*Address all correspondence to: ksleedr@skku.edu

IntechOpen

© 2021 The Author(s). Licensee IntechOpen. This chapter is distributed under the terms of the Creative Commons Attribution License (<http://creativecommons.org/licenses/by/3.0>), which permits unrestricted use, distribution, and reproduction in any medium, provided the original work is properly cited. 

References

- [1] Homma Y, Akiyama Y, Tomoe H, et al. Clinical guidelines for interstitial cystitis/bladder pain syndrome. *Int J Urol* 2020;27:578-89.
- [2] Whitmore KE, Fall M, Sengiku A, Tomoe H, Logadottir Y, Kim YH. Hunner lesion versus non-Hunner lesion interstitial cystitis/bladder pain syndrome. *Int J Urol* 2019;26 Suppl 1:26-34.
- [3] Maeda D, Akiyama Y, Morikawa T, et al. Hunner-Type (Classic) Interstitial Cystitis: A Distinct Inflammatory Disorder Characterized by Pancystitis, with Frequent Expansion of Clonal B-Cells and Epithelial Denudation. *PLoS One* 2015;10:e0143316.
- [4] Fall M, Nordling J, Cervigni M, et al. Hunner lesion disease differs in diagnosis, treatment and outcome from bladder pain syndrome: an ESSIC working group report. *Scand J Urol* 2020;54:91-8.
- [5] Lai HH, Pickersgill NA, Vetter JM. Hunner Lesion Phenotype in Interstitial Cystitis/Bladder Pain Syndrome: A Systematic Review and Meta-Analysis. *J Urol* 2020;204:518-23.
- [6] Rawls WF, Cox L, Rovner ES. Dimethyl sulfoxide (DMSO) as intravesical therapy for interstitial cystitis/bladder pain syndrome: A review. *Neurourol Urodyn* 2017;36:1677-84.
- [7] Hanno PM, Erickson D, Moldwin R, Faraday MM. Diagnosis and treatment of interstitial cystitis/bladder pain syndrome: AUA guideline amendment. *J Urol* 2015;193:1545-53.
- [8] Perez-Marrero R, Emerson LE, Feltis JT. A controlled study of dimethyl sulfoxide in interstitial cystitis. *J Urol* 1988;140:36-9.
- [9] Yoshimura N, Homma Y, Tomoe H, et al. Efficacy and safety of intravesical instillation of KRP-116D (50% dimethyl sulfoxide solution) for interstitial cystitis/bladder pain syndrome in Japanese patients: A multicenter, randomized, double-blind, placebo-controlled, clinical study. *Int J Urol* 2021;28:545-53.
- [10] Rooney P, Srivastava A, Watson L, Quinlan LR, Pandit A. Hyaluronic acid decreases IL-6 and IL-8 secretion and permeability in an inflammatory model of interstitial cystitis. *Acta Biomater* 2015;19:66-75.
- [11] Nickel JC, Hanno P, Kumar K, Thomas H. Second multicenter, randomized, double-blind, parallel-group evaluation of effectiveness and safety of intravesical sodium chondroitin sulfate compared with inactive vehicle control in subjects with interstitial cystitis/bladder pain syndrome. *Urology* 2012;79:1220-4.
- [12] Gülpınar Ö, Esen B, Kayış A, Gökçe M, Süer E. Clinical comparison of intravesical hyaluronic acid and chondroitin sulfate therapies in the treatment of bladder pain syndrome/interstitial cystitis. *Neurourol Urodyn* 2018;37:257-62.
- [13] Cervigni M, Natale F, Nasta L, Mako A. Intravesical hyaluronic acid and chondroitin sulphate for bladder pain syndrome/interstitial cystitis: long-term treatment results. *Int Urogynecol J* 2012;23:1187-92.
- [14] Kerr WS, Jr. Interstitial cystitis: treatment by transurethral resection. *J Urol* 1971;105:664-6.
- [15] Peeker R, Aldenborg F, Fall M. Complete transurethral resection of ulcers in classic interstitial cystitis. *Int Urogynecol J Pelvic Floor Dysfunct* 2000;11:290-5.
- [16] Lee ES, Lee SW, Lee KW, Kim JM, Kim YH, Kim ME. Effect of

transurethral resection with hydrodistention for the treatment of ulcerative interstitial cystitis. *Korean J Urol* 2013;54:682-8.

[17] Ko KJ, Chung H, Suh YS, Lee SW, Kim TH, Lee KS. Therapeutic effects of endoscopic ablation in patients with Hunner type interstitial cystitis. *BJU Int* 2018;121:659-66.

[18] Akiyama Y, Niimi A, Nomiya A, et al. Extent of Hunner lesions: The relationships with symptom severity and clinical parameters in Hunner type interstitial cystitis patients. *Neurourol Urodyn* 2018;37:1441-7.

[19] Han JY, Shin JH, Choo MS. Patterns and predictors of Hunner lesion recurrence in patients with interstitial cystitis. *Neurourol Urodyn* 2019;38:1392-8.

[20] Otsuka A, Suzuki T, Matsushita Y, et al. Therapeutic Endoscopic Treatment Plus Maintenance Dimethyl Sulfoxide Therapy Prolongs Recurrence-Free Time in Patients With Hunner Type Interstitial Cystitis: A Pilot Study. *Int Neurourol J* 2019;23:327-33.

[21] Kim HJ. Update on the Pathology and Diagnosis of Interstitial Cystitis/Bladder Pain Syndrome: A Review. *Int Neurourol J* 2016;20:13-7.

[22] Fall M. Conservative management of chronic interstitial cystitis: transcutaneous electrical nerve stimulation and transurethral resection. *J Urol* 1985;133:774-8.

[23] Newson B, Dahlström A, Enerbäck L, Ahlman H. Suggestive evidence for a direct innervation of mucosal mast cells. *Neuroscience* 1983;10:565-70.

[24] Ko KJ, Cho WJ, Lee YS, Choi J, Byun HJ, Lee KS. Comparison of the Efficacy Between Transurethral Coagulation and Transurethral

Resection of Hunner Lesion in Interstitial Cystitis/Bladder Pain Syndrome Patients: A Prospective Randomized Controlled Trial. *Eur Urol* 2020;77:644-51.

[25] Chennamsetty A, Khourdaji I, Goike J, Killinger KA, Girdler B, Peters KM. Electrosurgical management of Hunner ulcers in a referral center's interstitial cystitis population. *Urology* 2015;85:74-8.

[26] Rössberger J, Fall M, Jonsson O, Peeker R. Long-term results of reconstructive surgery in patients with bladder pain syndrome/interstitial cystitis: subtyping is imperative. *Urology* 2007;70:638-42.

[27] Kim HJ, Lee JS, Cho WJ, et al. Efficacy and safety of augmentation ileocystoplasty combined with supratrigonal cystectomy for the treatment of refractory bladder pain syndrome/interstitial cystitis with Hunner's lesion. *Int J Urol* 2014;21 Suppl 1:69-73.