

We are IntechOpen, the world's leading publisher of Open Access books Built by scientists, for scientists

6,900

Open access books available

186,000

International authors and editors

200M

Downloads

Our authors are among the

154

Countries delivered to

TOP 1%

most cited scientists

12.2%

Contributors from top 500 universities



WEB OF SCIENCE™

Selection of our books indexed in the Book Citation Index
in Web of Science™ Core Collection (BKCI)

Interested in publishing with us?
Contact book.department@intechopen.com

Numbers displayed above are based on latest data collected.
For more information visit www.intechopen.com



Ureteric Injury in Gynecology Surgery

Rama Garg

Abstract

It is the most serious and trouble-some complication of pelvic surgery and common reason for medico-legal action by the patient. It can be unilateral or bilateral. Lowest 3 cm of ureter is usually injured. 75% of injuries result from gynecological operations - 3/4th during abdominal and 1/4th during vaginal operations. As most injuries can be diagnosed intraoperatively, systematic assessment of urinary tract integrity should be part of the surgical plan. Intraoperative cystoscopy using either flexible or rigid instruments can aid in the diagnosis or exclusion of urinary tract injury. Identification of the mechanism of injury and its location guides immediate or delayed repair. Mobilization should be sufficient to allow a tension-free closure. Tissue interposition is typically recommended. Common sites for ureteral injury are found beneath the uterine vessels near the cardinal ligament and beneath the infundibulopelvic ligament and the tunnel of Wertheim. Successful ureteral repair relies on careful mobilization, wide spatulation, use of fine absorbable suture (4-0, 5-0), and temporary stenting. Postoperative signs and symptoms of ureteral injury may include unilateral flank pain, fever, prolonged ileus, and abdominal or pelvic fluid collection (urinoma).

Keywords: Ureteric, Injury, Gynecology, Surgery, Prevention, Ureteroureterostomy

1. Introduction

Involuntary continuous leakage of urine after gynecological surgery comes as a bolt from blue to the patient and may cause suffering many times more than her previous disease. It is the most serious and trouble-some complication of pelvic surgery and common reason for medico-legal action by the patient [1].

2. Incidence

It can be unilateral or bilateral [1–6].

Abd. Hysterectomy	→	0.5%-1.0%
Vaginal Hysterectomy	→	0.1%
Adnexectomy	→	0.1%
Extensive Hysterectomy	→	1-2%
Laparoscopy associated ureteral injury	→	0.3-0.4%

Lowest 3 cm of ureter is usually injured.
75% of injuries from gynecological operations.

- 3/4 during abdominal operations.
- 1/4 during vaginal operations.

3. Type/Mechanism

- Crushing from misapplication of clamp [1–6].
- ligation with suture.
- transection – partial or complete.
- angulation with secondary obstruction - partial or complete.
- ischemia from stripping of blood supply from the wall of ureter.
- resection
- Cauterization – electrical, thermal, laser and stapler injuries in laparoscopic surgery.

4. Surgical anatomy and anatomical locations

- At or below the infundibulopelvic ligament (**Figures 1–5**) [1–6].
- Along the course of ureter on the lateral pelvic side wall just above the uterosacral ligament.
- Where the ureter passes beneath the uterine vessels.
- Beyond the uterine vessels as the ureter passes through the tunnel in the cardinal ligament and turns anteriorly and medially to enter the bladder.
- Intramural portion of ureter when it traverses the bladder wall.
- Devascularization especially in the lower 1/3rd.

5. Association with gynecological surgery

- Most common site - pelvic brim near the infundibulopelvic ligament where it is crossed by common iliac artery, is more prone to injury due to adhesions especially in endometriosis and malignancy (**Figures 4 and 5**) [1–6]
- Most common procedure - Total abdominal hysterectomy
- Most common type of injury - obstruction

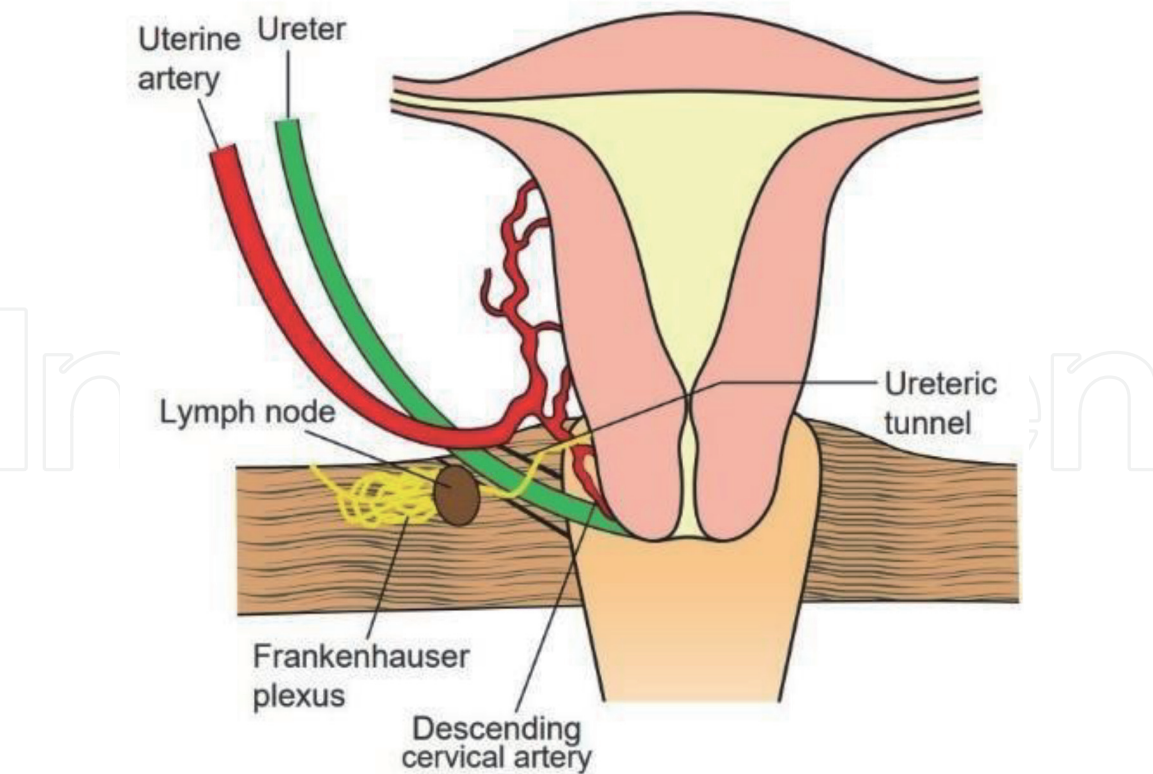


Figure 1.
Structures in the cardinal ligament—descending cervical branch of the uterine artery, ureter in the ureteric tunnel, lymph node and Frankenhauser plexus. Taken from [1].

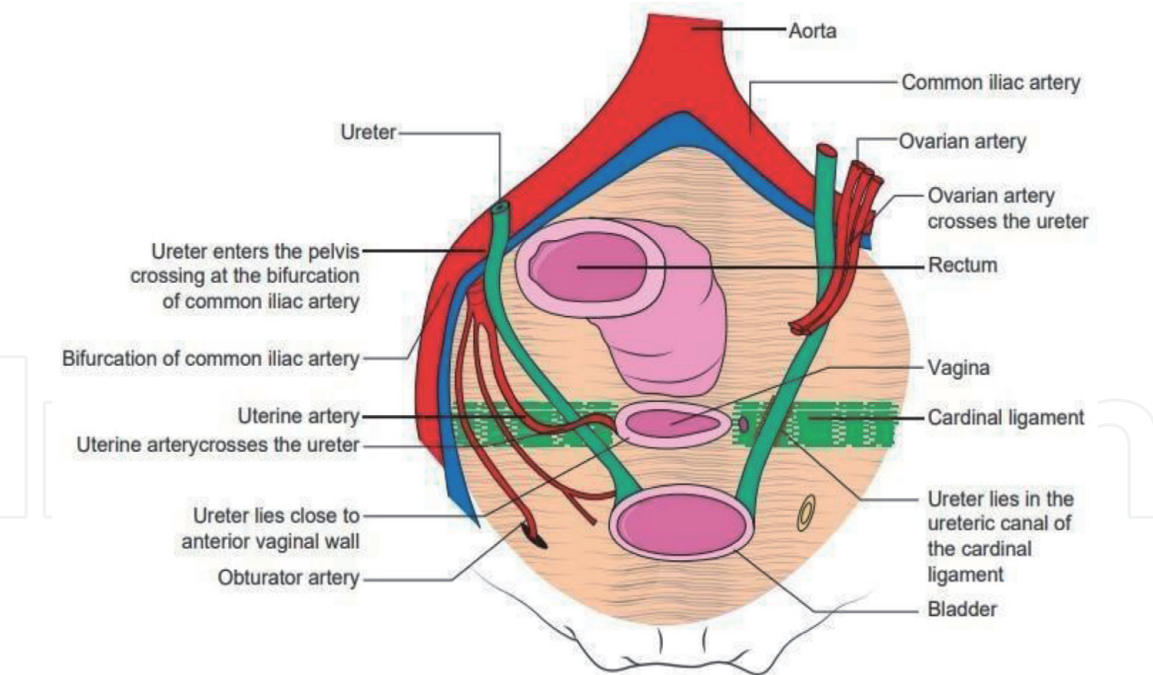


Figure 2.
Course of pelvic ureters. Taken from [1].

- Most common activity - attempts to achieve hemostasis.
- Most common time of diagnosis-None: 50-50 split between intraoperative and post-operative.
- Most common long term sequelae – None, however patient may need for repeat surgery.

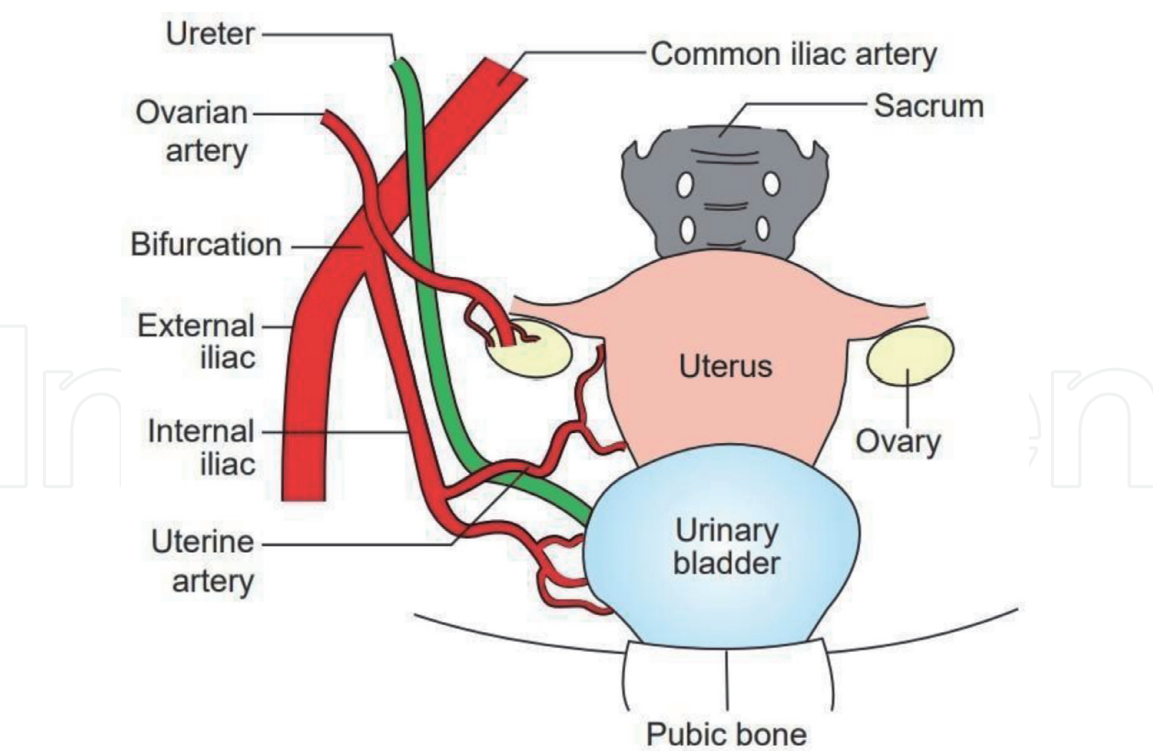


Figure 3.
Relations of the pelvic ureter. It crosses the bifurcation of vessels and then crosses under the uterine artery to enter the ureteric tunnel. Taken from [1].

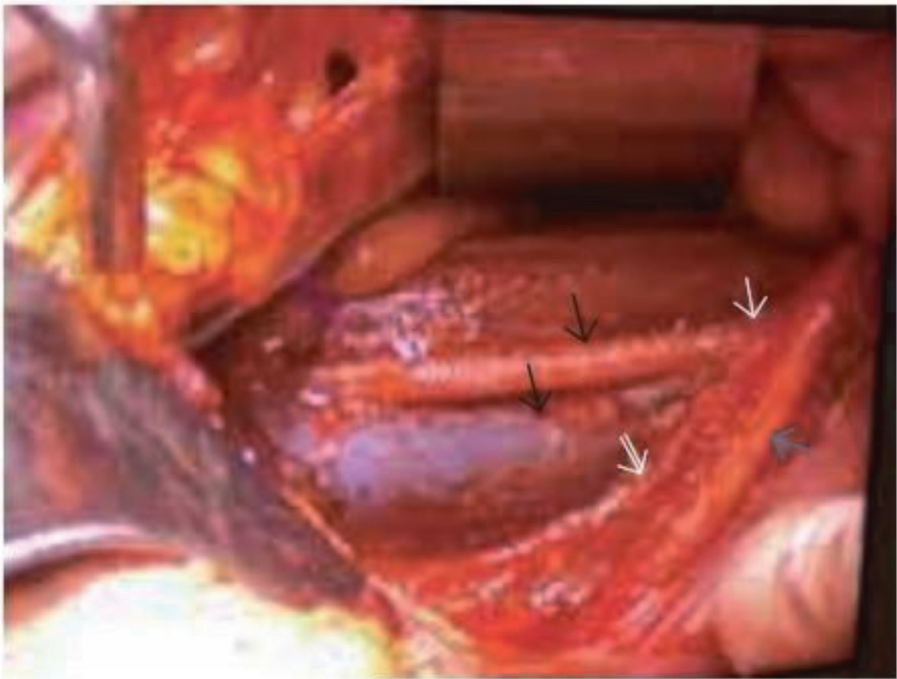


Figure 4.
Pelvic lymphadenectomy. The external iliac artery (black arrow), vein (black double arrow), bifurcation of common iliac artery (white arrow) and internal iliac artery (white double arrow). The ureter is seen crossing the common iliac at its bifurcation (blue arrow). Taken from [1].

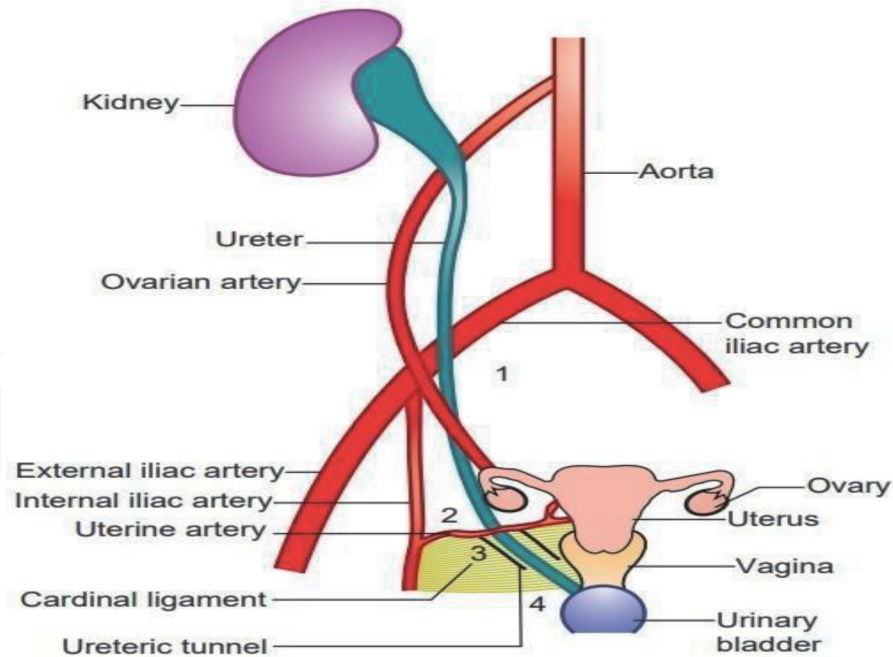


Figure 5.
 Various points at which ureter is prone to injury in gynaecological surgery. (1) At the pelvic brim, while clamping the ovarian vessels. (2) In the broad ligament while clamping the uterine vessels. (3) In the ureteric tunnel in cardinal ligament. (4) At the vault of the vagina before it enters the bladder. Taken from [1].

6. Sequelae

- Spontaneous resolution and healing when injury is mild [1–6].
- Post hydronephrotic renal atrophy with complete ligation of a ureter.
 - If no sepsis → asymptomatic kidney atrophy.
 - If sepsis → becomes evident immediately.
- Secondary stenosis and kidney damage.
 - Ureteral necrosis with urinary extravasation
 - Ureterovaginal fistula
 - Urinoma
 - retroperitoneal abscess
 - urinary ascites (URINOMA)
 - peritonitis
- Uraemia due to bilateral ureteric obstruction → flank pain, unexplained or persistent fever with or without chills, BUN and creatinine levels rise.

- Anuria for first 24-48 hours.
 - In first week → Atrophy of distal nephrons.
 - In second week → Atrophy of cortical region.
 - Renal Biopsy → Protein casts in Bowman's space are pathognomonic of obstruction.

7. Prevention

- Primary prevention [1-6]
- Secondary prevention
- Tertiary prevention

7.1 Primary prevention

Prevention of injury before it occurs. As most injuries can be diagnosed intraoperatively, systematic assessment of urinary tract integrity should be part of the surgical plan.

Never cut/clamp /suture/apply energy before proper identification of ureter. always remember to preserve the blood supply of ureter. inadvertent injury if suspected though not confirmed (blunt trauma/devascularization/ lateral damage due to thermal energy), ureteric stenting/catheterisation is to be done. always be proactive to involve the urogynaecologist at the earliest stage before, during or after surgery.

1. Careful evaluation of patient's gynecological disease and recognition of risk to the ureter with the surgical procedure is of foremost importance.
2. Preoperative excretory urogram- is mandatory in high-risk cases.
3. Ureteral catheterization by cystostomy or cystoscopically where ureter is at high risk, may be done (**Figure 6**).
4. Adequate incision and proper exposure are most helpful.
5. Ureter must not be hidden in the operator's subconscious mind - Never cut or clamp anything in and around ureter unless ureter is defined and stay outside the adventitial sheath when dissecting the ureter. Avoid energy sources near ureter especially monopolar cautery. Harmonic energy use is best near ureter next to cold scissors.
6. Before clamping infundibulopelvic ligament - surgeon must identify the ureter, lift the infundibulopelvic ligament and only then apply the clamp. First clamp should be lowest and lateral and second clamp above and medial.

7.3 rules after skeletonization of uterine vessels

- Place the lowest clamp first.

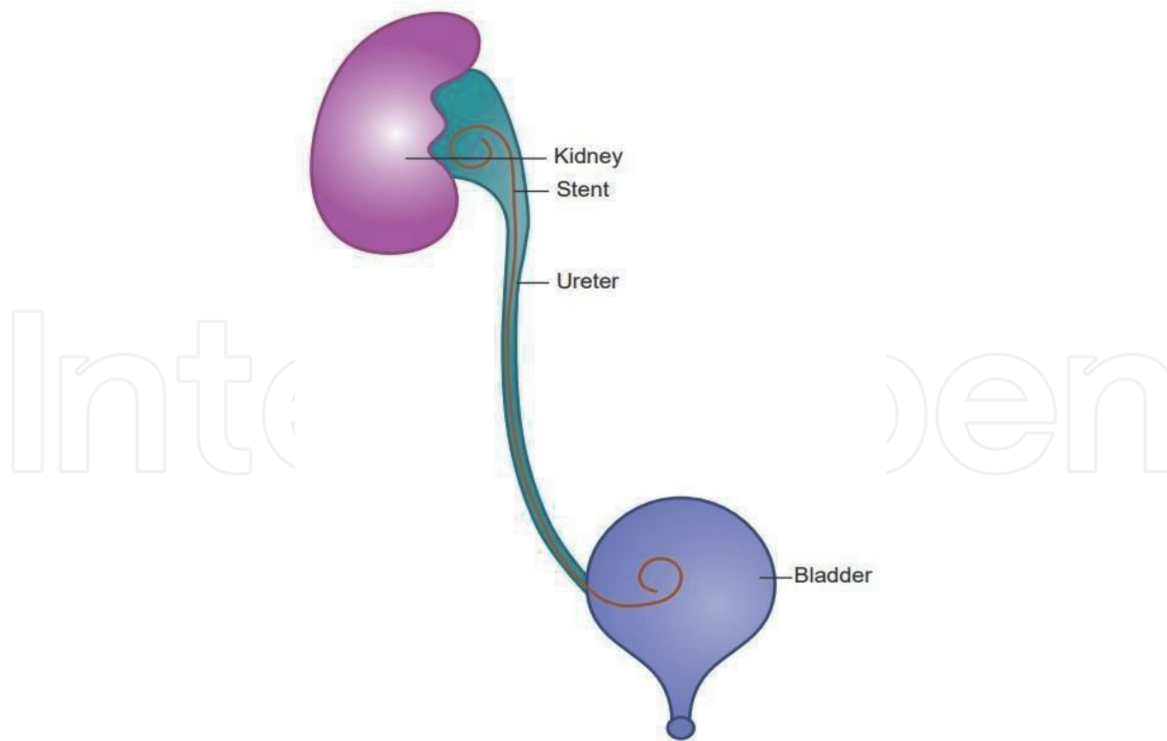


Figure 6.
 Double pigtail stent placed in the ureter for management of crush injury or after repair of transection. Taken from [1].

- Place it at right angle to uterus.
 - Place it at the level of internal os.
 - Ligation of uterine vessels should be medial to ureter so that ureteric branch of uterine artery can be preserved.
8. Dissection of bladder from upper vagina both inferiorly and laterally is required before excising cervix from vaginal vault.
 9. Paracervical and paravaginal clamps or sutures should be as close as possible to cervix.
 10. To support the vault with uterosacral ligament sutures should not be placed high or more laterally on side wall otherwise ureter may get kinked or ligated.
 11. Carefully reperitonise the pelvis or one may leave reperitonisation.
 12. To control the intraoperative bleeding best is to apply pressure with a pack or stick sponge or finger.
 13. During vaginal hysterectomy
 - vesico-uterine space must be dissected adequately to allow displacement of ureters away from the clamp by downward traction on cervix and countertraction upward beneath the bladder.
 - Small-small bits of paracervical and parametrial tissues should be clamped, cut, and ligated.

- Double clamping of cardinal ligaments and uterine vessels should be avoided as lateral clamp will come close to the ureter.

14. Perform a supracervical hysterectomy during caesarean section or extend the hysterotomy incision caudally to cervix.

15. During laparoscopic surgery:

- If ureters are not visualized, retroperitoneal dissection should be done to decrease the incidence of complications (**Figure 4**). Visualization under Invisible near infrared (NIR) light after intravenous. or retrograde injection of ICG (Indigo carmine) dye is very useful if needed but it is expensive.
- In tubal sterilization - Fallopian tubes should be taken away from pelvic wall before electrocoagulation.
- In LAVH - if stapler application in cardinal and uterosacral ligament is not safe, then this part of operation should be done vaginally.

Note: Kinking is functionally similar to obstruction till it is undone. Be careful when clamping or suturing the uterosacral ligament and during reperitonisation.

7.2 Secondary prevention

Recognition of injury during operation so that immediate repair can be done. (**Figure 6–12**)

Intraoperative cystoscopy using either flexible or rigid instruments can aid in the diagnosis or exclusion of urinary tract injury. Identification of the mechanism of injury and its location guides immediate or delayed repair.

Evaluation of ureter should be done before operative procedure is terminated by:

- Inspection of peristaltic activity.
- Palpation, mobilization
- Dissection by reflecting peritoneum.
- Ureteral catheterization. (**Figure 6**)
- I/V chromogen test
- 2.5-5ml of indigo carmine 0.8% / Methylene Blue - within 3-5 minutes spurt from each ureteric orifice is there. If takes longer time - I/V fluids or diuretics are given.
- If no spurting, ureter should be explored along its course to point out the site of obstruction or injury.
- If transection is partial or complete - dye will leak into operative field.
- If ligation by suture/kinking is complete - No dye will leak in operative field and there will be proximal dilatation of ureter which will increase progressively.

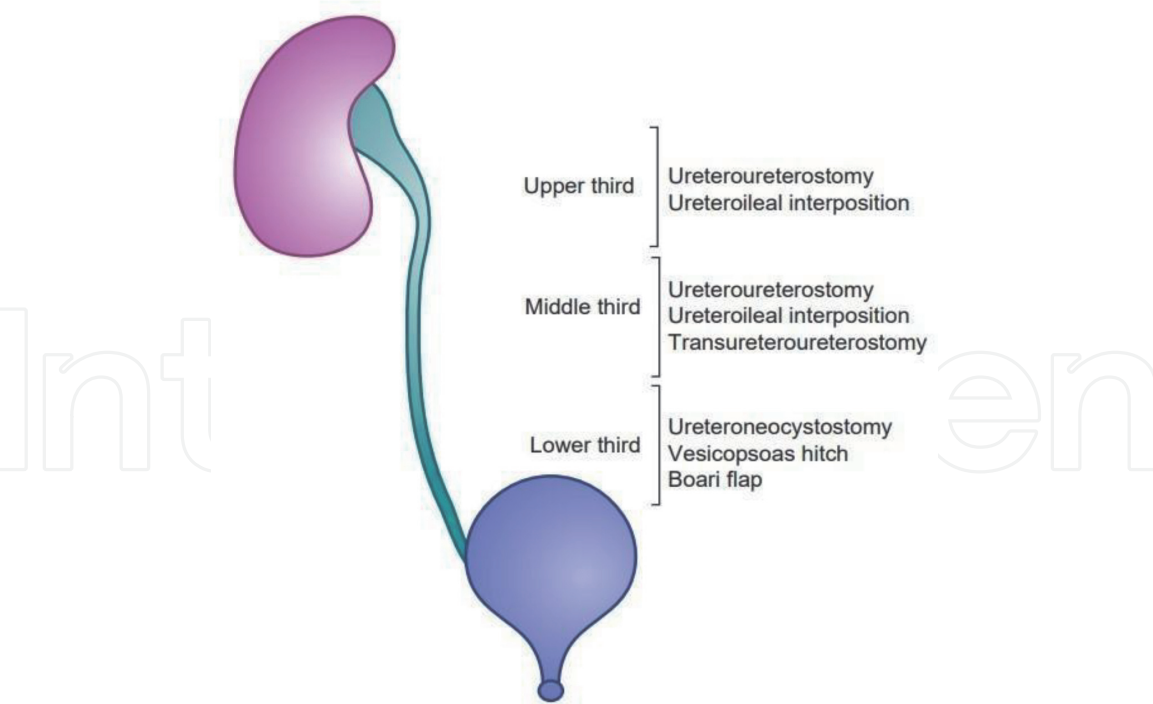


Figure 7.
Management of transection of the ureter depends on the level at which ureter is transected, that is, in the upper third, middle third or lower third. Taken from [1].

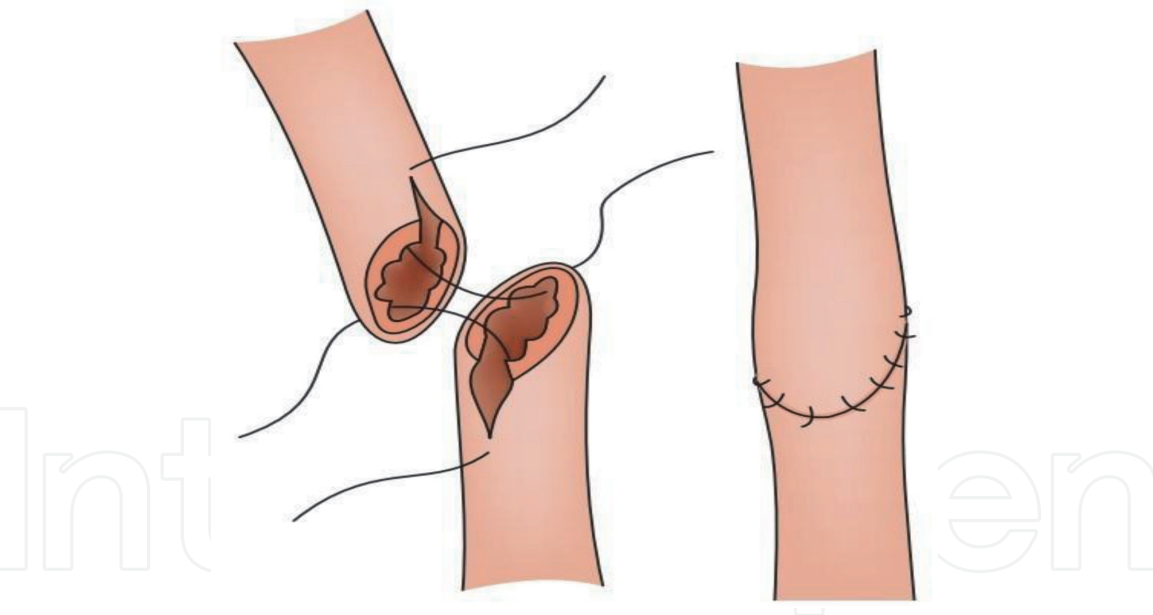


Figure 8.
Diagrammatic representation of ureteroureterostomy. The ends are spatulated and sutured. Taken from [1].

- If ligation by suture/kinking incomplete - - No dye will leak in operative field and there will be proximal dilatation of ureter that will decrease slowly and slowly.
- Intraoperative cystoscopy: Urine efflux from the ureteric orifice may be absent or slow on intraoperative cystoscopy. Almost 90% of ureteric injuries are diagnosed by cystoscopy. Partial obstruction and thermal injuries may be missed.

Note: if peristalsis seen, most probably injury is not there. but it cannot rule out ischaemic injury which will manifest postoperatively only and may manifest after

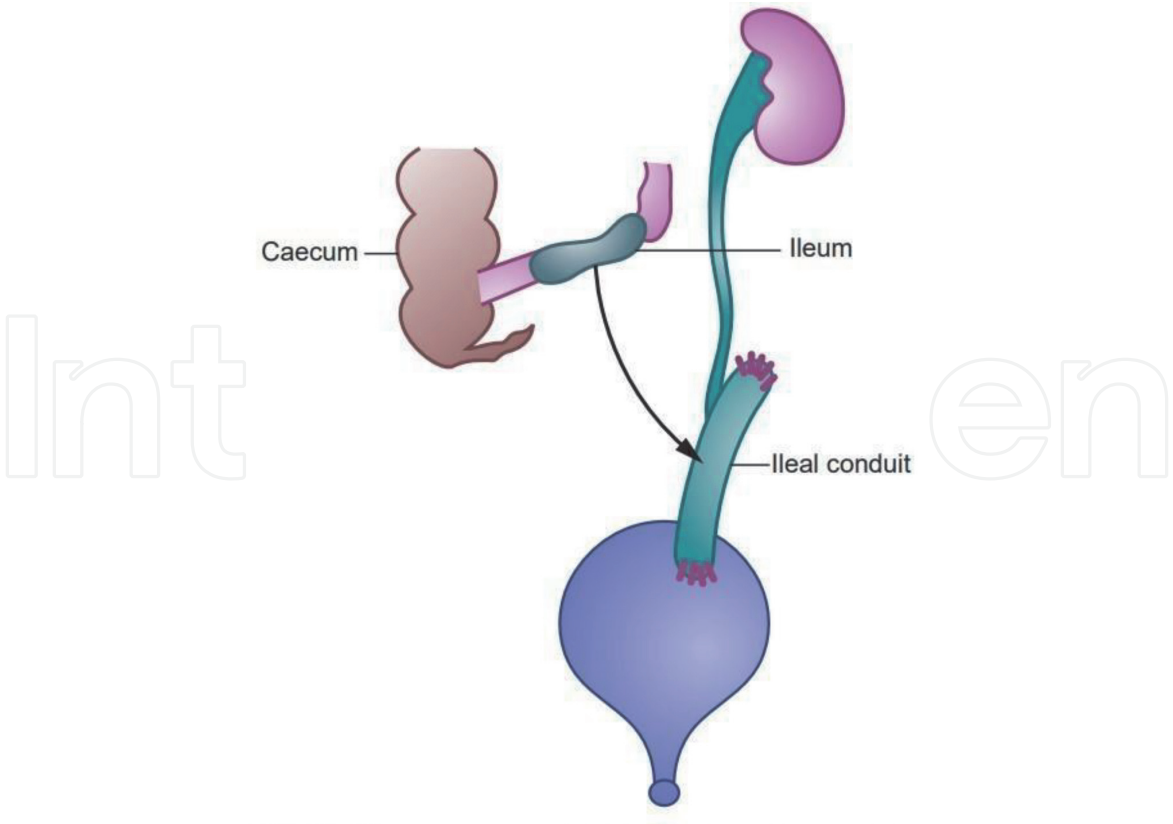


Figure 9. Transposition of the ileum is performed when the lower segment is not long enough to implant into the bladder without tension. A distal segment of the ileum is cut and attached to the ureter at the upper end and implanted into the bladder at the lower end. Taken from [1].

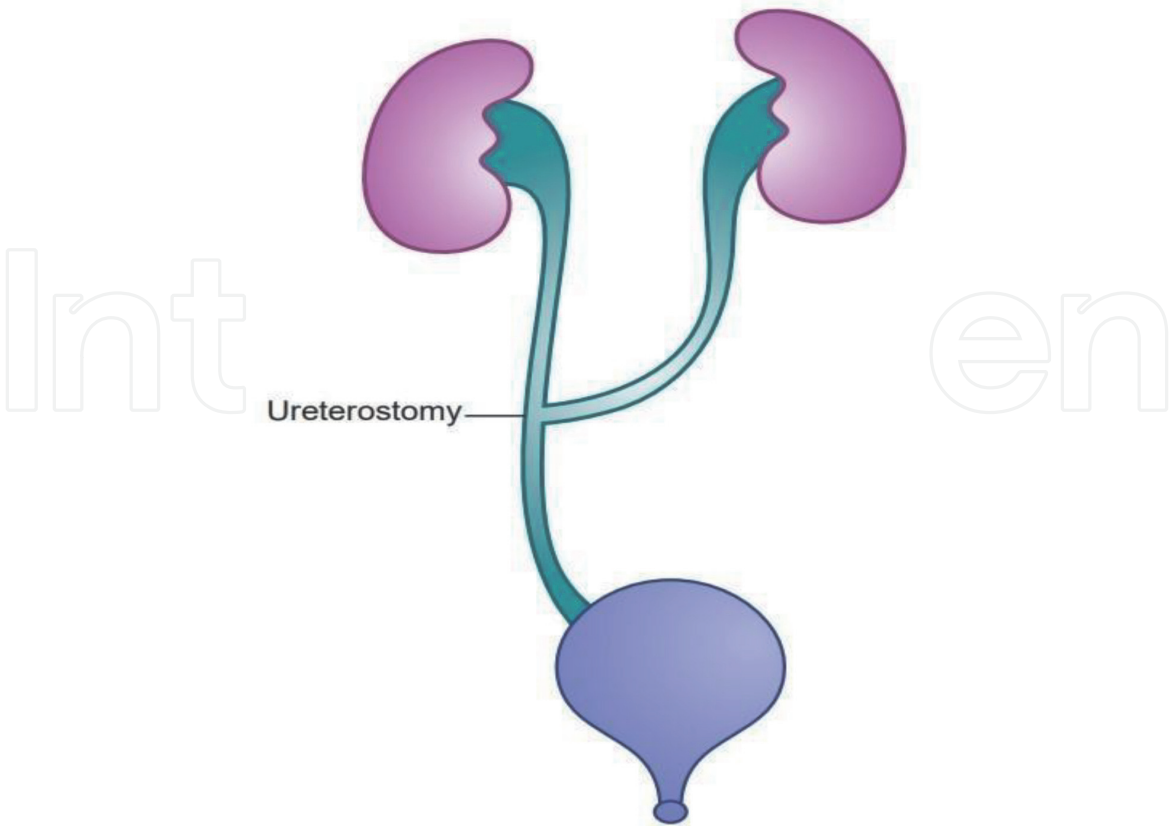


Figure 10. Transureteroureterostomy—when the length of the lower segment of the ureter is not adequate, the cut end is anastomosed to the ureter on the opposite side. Taken from [1].

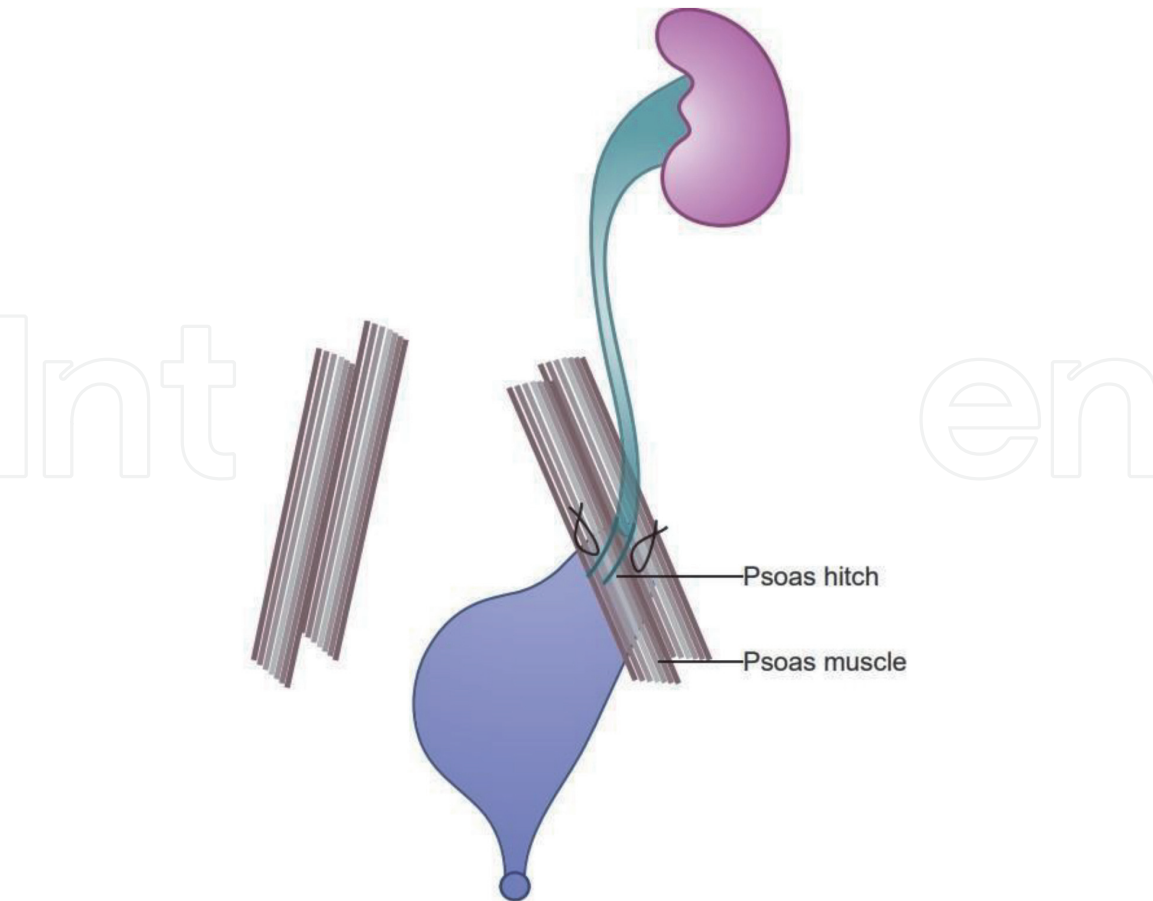


Figure 11.
A bladder flap (boari flap) shaped into a tube and the lower end of the ureter is attached to this to provide extra length and prevent tension. Taken from [1].

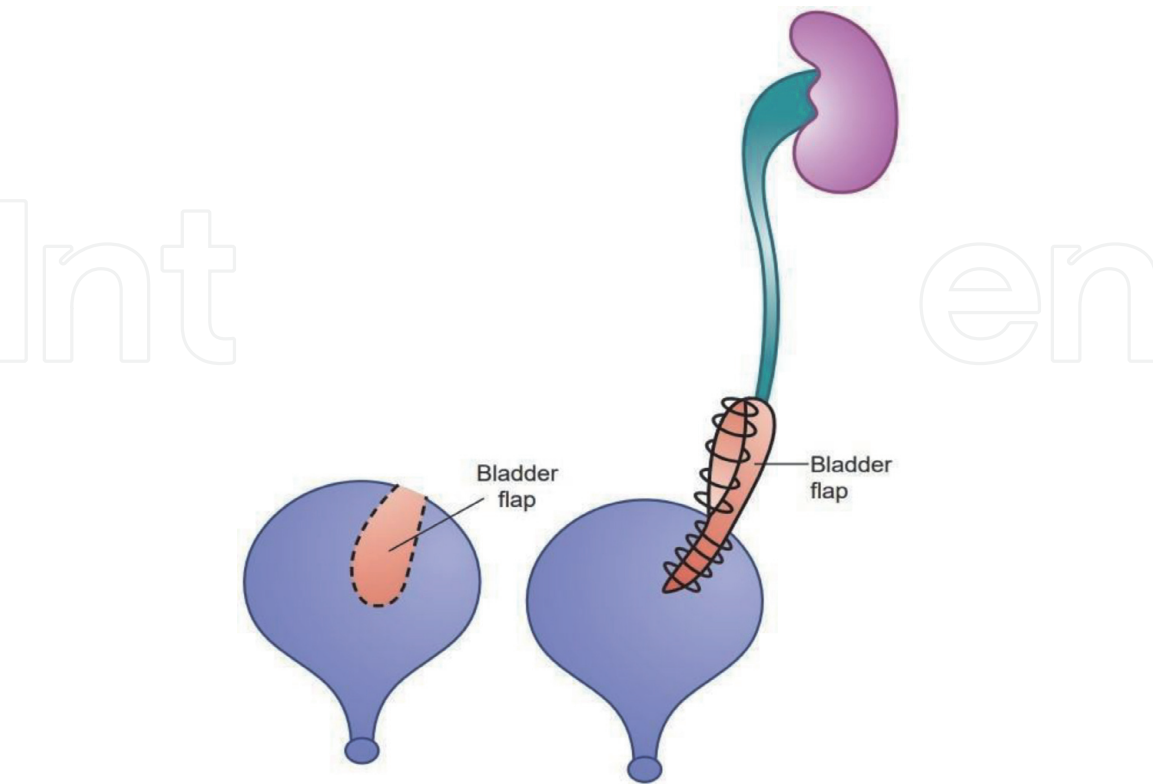


Figure 12.
Psoas hitch procedure, the bladder is pulled up and stiched to the psoas muscle to prevent tension after ureteroneocystostomy. Taken from [1].

7-10 days. so, if inadvertent injury is suspected though not confirmed, ureteric stenting/catheterisation is to be done, to prevent further complications.

- Surgical procedures as per need are to be done as given under tertiary prevention depending on individual factors like site of injury, extent of damage and integrity of opposite ureter provided patient's condition allows. If unfit, temporary measures like closed drainage/PCN are taken till general condition is fit i.e., within 48-72 hours or later after 6-8 weeks.

7.3 Tertiary prevention

Recognition of injury as early as possible in postoperative phase (**Figures 6–12**)

Signs/Symptoms of patient: STORMY POSTOPERATIVE PERIOD

- flank pain
- cost-vertebral tenderness
- persistent ileus
- lower abdominal mass/ ascites- Paracentesis to be done for urea level.
- unexplained fever with/without chills
- unexplained hematuria
- oliguria
- watery discharge from vagina.

8. Diagnosis

- USG may show unilateral or bilateral hydroureter or hydroureteronephrosis/ urinary ascites [1–6].
- Excretory urogram
- IV Indigo carmine test
- Pyridium/ Methylene blue test
- 3 swab tests with Methylene blue
- Cystoscopy with passage of retrograde ureteral stent, if possible, should be done.
- Comparison of pre and postoperative creatinine level.

9. Treatment depends upon

- Site of injury (distance from bladder) [1–6]
- Integrity of opposite ureter.

- Loss of length
- Time of Dx:
 - recognized during surgery.
 - unrecognized during surgery

9.1 General guidelines for management of ureteral injuries

This depends on the type and timing of presentation, the site of injury and the patient’s condition. Immediate treatment is to relieve obstruction and stop leakage of urine. Definitive surgery for women with intraperitoneal or extraperitoneal leakage or obstruction, this should be undertaken as soon as the patient is stable and ready. Management of transaction and thermal injuries is the same as of intraoperatively diagnosed injuries. Very small fistulas may close with stenting. For large fistulas and when urine leaks despite stenting, surgery is required (Figure 7).

9.2 Principles

Mobilization should be sufficient to allow a tension-free closure. Tissue interposition is typically recommended. Common sites for ureteral injury are found beneath the uterine vessels near the cardinal ligament and beneath the infundibulopelvic ligament and the tunnel of Wertheim. Successful ureteral repair relies on careful mobilization, wide spatulation, use of fine absorbable suture (4-0, 5-0), and temporary stenting.

• Crushing/ Angulation/Ligation	• Deligation, assessment of vitality and stent placement (Figure 6)
• Partial Transection	• Primary repair over ureteral stent
• Total Transection	• Uncomplicated/ Complicated (when a segment of ureter is/has to be cut due to extensive damage)
Upper & middle third	<ul style="list-style-type: none">• Ureteroureterostomy over the stent. (Figure 8).• Ureteroileal interposition/ Uretero-entero-neocystostomy - when an ileal segment is interposed between the two cut ends of the ureter or between the ureter and the bladder (Figure 9)• Transureteroureterostomy (Figure 10) -done occasionally only these days.• Boari flap is also used for extensive midureteral injuries. Boari bladder flap is fashioned with bladder wall; ureter is tunnelled in and attached to the flap. (Figure 12)
Lower third	<ul style="list-style-type: none">• Uretero- neocystostomy over ureteral stent (Figure 11) Ureteroneocystostomy is reimplantation of ureter into the bladder.• Psoas hitch/ Vesico-psoas (Figure 11) In vesico-psoas hitch, the bladder is mobilized and fixed to the psoas muscle to relieve tension (psoas hitch) after uretero-neocystostomy.• Boari bladder flap (Figure 12)
• Thermal injury - Not rare	• Dealt as above depending upon various factors as above. The damaged part must be resected.

9.2.1 Injury recognized during surgery

- Clamp and ligature should be removed immediately (Figures 8–12).

- Simple pelvic closed drainage should be done.
- Intubate the ureter for 7 days by means of cystoscopy/cystotomy and retrograde catheterization of ureter with
 - Infant feeding tube - No.5
 - J-shaped stent is preferable. (**Figure 6**)
- If ureter is discovered to be cut or if extensive damage after clamping or ligation - Injury to lower third is most common
 - Injury to ureter < 4-5cm of ureterovesical junction
 - If 3–4 cm proximal to ureterovesical junction → Ureteroureterostomy is needed.
 - If within 2 cm of ureterovesical junction → Ureteroneocystostomy is required.
 - If above two cannot be done without tension → Vesicopsoas hitch is the procedure required.
 - Injury to ureter > 4-5cm of ureterovesical junction/at brim
 - Bladder flap (Boari) (**Figure 12**)
 - Uretero-ureteral anastomosis (**Figure 8**)
 - Transperitoneal anastomosis to opposite ureter (**Figure 10**). Rarely done these days
 - Small intestine can be used as a conduit for the lower ureter-ileal conduit (**Figure 9**)
 - Skin ureterostomy

9.2.2 Injuries unrecognized during surgery

- Immediate ureteral catheterization and bypass the obstruction— should be left for 14 days or longer.
- If catheterization not possible:
 - Diagnosed within 48-72 hours of surgery- immediate ureteral repair should be done.

If diagnosis is made late or if extensive devascularization and injury are likely to occur e.g., after extensive hysterectomy, or extensive retroperitoneal fibrosis, cellulitis and induration is expected in patients with poor medical condition -PCN (Percutaneous Nephrostomy) preferably under ultrasound is required and definitive surgery can be planned 6-8 weeks later.

10. Videos

<https://medicallearninghub.com/course/ureteric-safety-in-complex-gynecology-surgeries#>

11. Conclusions

Sound knowledge of ureteral anatomy is critical to the avoidance of injury. In the event that the ureter is damaged during gynecologic surgery, intraoperative diagnosis allows for immediate repair in most cases. For this reason, intraoperative confirmation of ureteral integrity should be routine, whether the surgical approach is transvaginal or transabdominal through the open, laparoscopic, or robot-assisted approach. The ureter may be assessed visually, by palpation, or cystoscopically. Identification of the mechanism of injury and its location guides immediate or delayed repair. With proper recognition and therapy, ureteral function can be restored, and renal function maintained.

Acknowledgements

I am extremely grateful to my family for always being there to support me. I want to thank my parents who always believed in me. I would especially like to thank my children for constantly motivating me to work harder and my granddaughter for constantly cheering me up.

Funding

No.

Conflict of interest

The author declares no conflict of interest.

Thanks

Thank you very much Er Sidharth Garg (M Eng Electrical and Computer) for formatting the paper and making all the necessary edits to achieve its desired structure and Dr. Muskaan Bharti MBBS Intern for editing the chapter.

IntechOpen

IntechOpen

Author details

Rama Garg
Adesh Institute of Medical Sciences and Research, Adesh University, Bathinda,
Punjab, India

*Address all correspondence to: drramagarg@gmail.com

IntechOpen

© 2021 The Author(s). Licensee IntechOpen. This chapter is distributed under the terms of the Creative Commons Attribution License (<http://creativecommons.org/licenses/by/3.0>), which permits unrestricted use, distribution, and reproduction in any medium, provided the original work is properly cited. 

References

- [1] Seshadri L. Essentials of Gynaecology. 2 ed. Wolters Kluwer Health (India); 2019. 11,12,386-393 p. ISBN-13: 978-93-5129-698-0 www.wolterskluwerindia.co.in
- [2] Victoria L. Handa, Linda Van Le. Te Linde's Operative Gynecology. 12th ed. Wolters Kluwer; 2020. 460-462,461f,633-649,649f p. Indian Reprint ISBN-13: 978-93-89702-84-2. Original ISBN-13: 9781496386441
- [3] Marcus E. Setchell, John H. Shepherd, Christopher N. Hudson. Shaw's Textbook of Operative Gynaecology. 7th ed. Elsevier India; 2013. 17, 372,383-389 p. ISBN: 978-81-312-1160-1
- [4] Kumar S, editor. Howkins & Bourne, Shaw's Textbook of Gynecology 17th ed. ELSEVIER; 2019. 23-25,377-384 p. ISBN: 978-81-312-5411-0. e-Book ISBN: 978-81-312-5412-7
- [5] Kumar P, Malhotra N, editors. JEFFCOATE'S PRINCIPLES OF GYNAECOLOGY. 7th International ed. Jaypee Brothers Medical Publishers (P) Ltd 2008. 41,263-268,778 p. ISBN: 978-81-8448-288-1 Visit our website: www.jaypeebrothers.com
- [6] Konar H, editor. DC Dutta's Textbook of Gynecology. 7th ed. Jaypee Brothers Medical Publishers (P) Ltd; 2016. 11-12,345,349-51 p. ISBN 978-93-85891-59-5 www.jaypeebrothers.com