We are IntechOpen, the world's leading publisher of Open Access books Built by scientists, for scientists

6,900
Open access books available

185,000
International authors and editors

200M
Downloads

Our authors are among the

154
Countries delivered to

TOP 1%
most cited scientists

12.2%
Contributors from top 500 universities

WEB OF SCIENCE™

Selection of our books indexed in the Book Citation Index in Web of Science™ Core Collection (BKCI)

Interested in publishing with us?
Contact book.department@intechopen.com

Numbers displayed above are based on latest data collected.
For more information visit www.intechopen.com

Chapter

Transposition of Great Arteries

Rita Prasad Verma

Abstract

TGA is the commonest complex congenital cyanotic cardiac anomaly occurring during the first week of life. It is characterized by the unusual anomaly of ventriculoarterial discordance, with the aorta (A) originating from the right ventricle (RV) and the pulmonary artery (PA) from the left ventricle (LV). In the common Dextro form (DTGA), A is abnormally located to the right, anterior, and inferior of PA. The anatomic configuration results in the lethal hemodynamic pattern of 2 independent and parallel running circulatory circuits, which mandates creating a conduit to ensure the mixing of oxygenated and deoxygenated blood for survival. In the rare Levo form (LTGA), the aorta is placed anterior and to the left of PA with ventricular inversion. TGA is well tolerated in the fetus and is challenging to diagnose by fetal echocardiography unless the outflow tracts are specifically visualized. Postnatally the typical findings of murmur and cyanosis vary according to the associated cardiac defects and the degree of intercirculatory mixing. The arterial switch operation (ASO), which involves establishing ventriculoarterial concordance, is the standard surgical repair of D-TGA and has replaced the atrial switch procedures due to its superior long-term outcomes. The Rastelli procedure is used for complex DTGA cases. DTGA has a 90% mortality rate in the first year of life if untreated, while over 95% survive for 5 to 25 years after surgery. Post-surgical course may be complicated and require surgical revisions. The long-term outcome is associated with normal or mild to moderate neurodevelopmental disabilities, depending upon the type, complexity, and course of the disease. Expert follow-up of the patients into adulthood is an integral part of the management of TGA for best outcomes.

Keywords: Dextro-transposition of great arteries, Ventriculoarterial discordance, Ventriculoatrial discordance, Levo-transposition of great arteries, Arterial switch operation, Atrial switch operation

1. Introduction

Transposition of the great arteries (TGA) is a critical complex congenital cyanotic cardiac disorder, characterized by the unique anomaly of ventriculoarterial discordance of major vessels. In the common type, the aorta (Ao) arises abnormally from the right ventricle (RV) and the pulmonary artery (PA) from the left ventricle (LV), leading to a lethal hemodynamic pattern of 2 independent circulations, running parallel to each other. This condition mandates a conduit that will ensure the mixing of blood between the two vascular circuits for survival. An open ductus arteriosus (DA) and, to some extent, patent foramen

ovale (PFO) serve this purpose during the initial hours of postnatal life. As the DA closes physiologically after birth, the condition becomes critical and requires the emergent reopening of the ductus or creating an atrial shunt to maintain the intercirculatory mixing of blood. TGA can result in acute cardiorespiratory decompensation and death within the first 48 hours of life if the diagnosis is missed. Early palliation followed by surgical repair, which involves physiological correction with the atrial switch or anatomic correction with arterial switch, has dramatically increased the survival rate of TGA to more than 90% from a universally fatal disease.

TGA is classified as Dextro (D-TGA) and Levo transpositions (L-TGA), based on Ao's relationship with PA in the anomalous heart. As LTGA is extremely rare, DTGA is discussed here, with the former referred to for comparison.

2. Epidemiology

TGA is the second most common congenital cyanotic heart defect (CCHD) and the commonest one occurring during the 1st week of life [1]. According to an estimation, about 1153 infants are born with TGA annually in the USA. The prevalence is assessed to be 2.3–4.7 per 10,000 live births [2, 3]. TGA accounts for approximately 3 percent of all congenital heart disease (CHD) disorders and almost 20 percent of all cyanotic CHD defects [2]. Overall, the incidence of DTGA is 5–10% of all CHDs, whereas that of LTGA is <1%, and 0.02 to 0.07 per 1000 live births. About 90% of the cases present as an isolated defect and the disorder is rarely associated with extracardiac anomalies. The occurrence of non-cardiac congenital lesions in TGA at <10% is significantly lower than those in other CHDs [4]. DTGA is not associated with any identifiable syndromes or genetic abnormality. It is notable that 80 percent of the patients with DiGeorge syndrome display 22q11 deletion and conotruncal lesions, but they rarely suffer from DTGA [5]. TGA in family members is uncommon, and the prevalence of CHD in the siblings of affected babies is not different from the general population at 0.3 percent [6]. TGA has a documented association with maternal diabetes mellitus, and it is more common in males to females in a 3:1 ratio in the DTGA form. The pathogenesis is multifactorial, and a combination of genetic and environmental factors is believed to play a role.

3. Embryology

While the exact embryology is undefined, TGA is hypothesized to be secondary to a developmental aberration in the morphogenesis of the bilateral sub arterial conus. During the first month of fetal life, the subaortic conus and sub pulmonary conus, which represent the preliminary great arteries, are normally positioned above the right ventricle. At approximately 30 to 34 days of fetal life, the subaortic CONUS is resorbed, and the aortic valve migrates inferiorly and posteriorly into the left ventricle. The sub pulmonary conus does not resorb, and the pulmonary valve retains its association with the right ventricle [7]. In D-TGA, the sub pulmonary CONUS is resorbed abnormally, and the pulmonary valve migrates posteriorly. Simultaneously, the unresorbed subaortic conus forces the aortic valve to move anteriorly and get engaged with the morphologic right ventricle. The origin and course of the coronary arteries vary and are determined by the movement of the subaortic conus [8].

4. Anatomy

Under normal conditions, Ao originates from the LV and is situated posteroinferior and to the right of the main pulmonary artery (**Figure 1**). In DTGA, Ao arises from the right ventricle (RV) and is positioned anteroinferior and to the right of PA, which is connected to the LV (**Figure 2**) [7]. The atria are normally positioned with atrial situs solitus, which is associated with atrioventricular concordance, d-looping of the ventricles, and ventriculo-arterial discordance. The aortic valve is anteroinferior and to the pulmonary valve's right instead of being posteroinferior and right as in normal conditions. The pulmonary and systemic circulations run independent of and parallel to each other with no mixing of the oxygenated and deoxygenated blood. In LTGA, the Ao is anterior, and to the left of PA, and the ventricles are inverted with atrioventricular discordance. The morphological RV is positioned to the left and the morphological LV to the right with Ao originating from the RV and PA from LV (**Figure 3**). The blood is pumped into the systemic circuit via RV and the pulmonary circuit via LV in this form. The systemic and pulmonary circulations are not impaired, and a shunt is not needed to mix blood. The two types of TGA are, therefore, hemodynamically different entities. In DTGA, with complete transposition and atrioventricular concordance, the lifesaving communication between the two parallel circulations is achieved interarterially via PDA, which connects the Ao with PA, or intra atrially via atrial septal defect (ASD) or PFO. Ventricular septal defect (VSD) is present in about 50% of the cases and provides another source of mixing between the oxygenated blood in the pulmonary circuit and deoxygenated blood in the systemic circuit.

Anatomically, DTGA may occur as an isolated defect (simple) or in combination with other cardiac lesions (complex). The commonest anomaly found in DTGA is VSD, often associated with other cardiac lesions, such as pulmonic valve stenosis

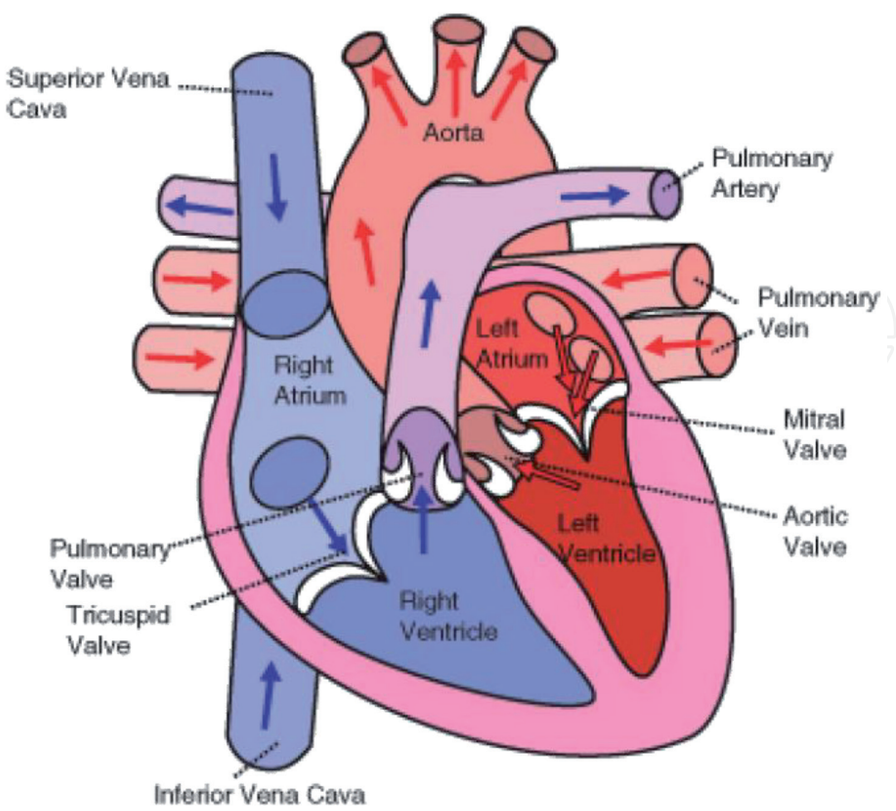

Figure 1.
Normal heart.

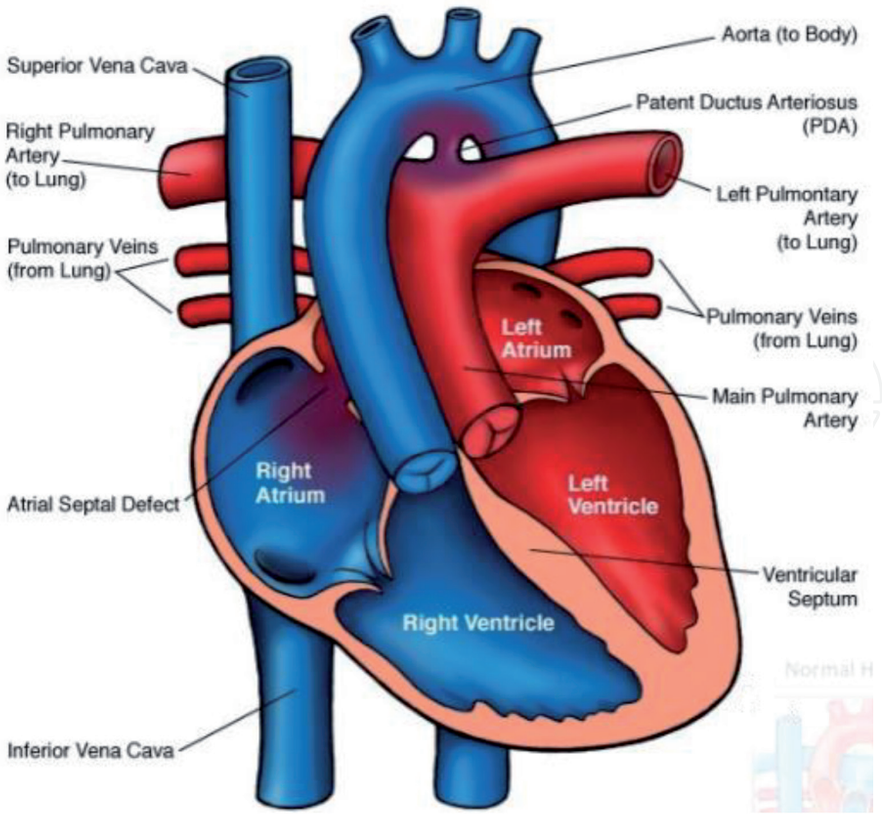

Figure 2.
Anatomy of heart in DTGA.

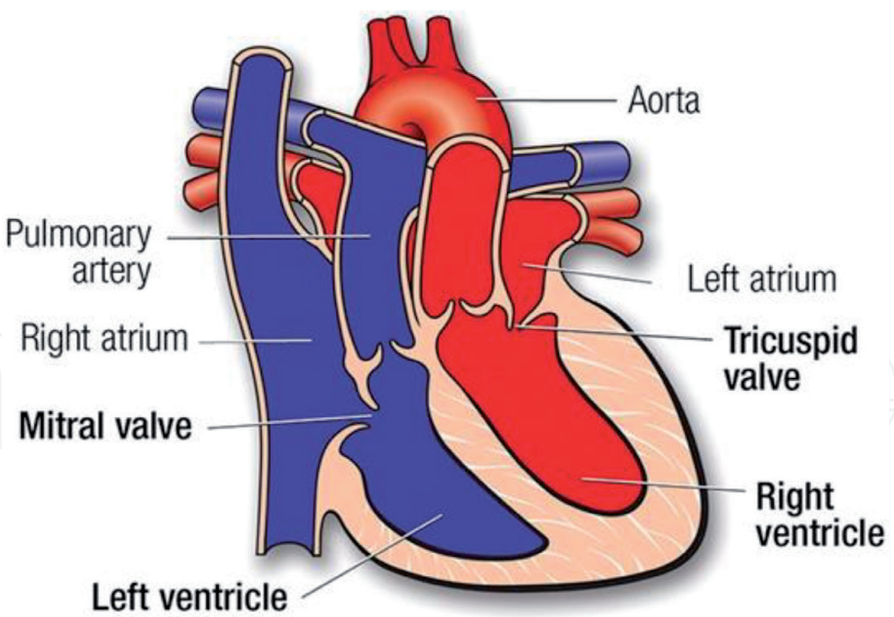

Figure 3.
Anatomy of heart in LTGA.

(PS) or atresia, overriding atrioventricular valves, coarctation of the aorta (COA), and aortic interruption [6–8]. The second most common defect in DTGA is left ventricular outflow tract obstruction (LVOO), detected in approximately 25% of the cases [9, 10]. LVOO may be anatomic or dynamic. If the interventricular septum is intact, the high pressure in RV, which may be at times equal to the systemic blood pressure, forces the ventricular septum to bulge into the LV cavity and thus creates a

dynamic outflow obstruction. The dynamic obstruction is resolved when a conduit is formed between the two parallel circulations, either medically by reopening the DA with PGE1 or surgically by creating an atrial septal defect (ASD) by balloon septostomy. Other cardiac structural anomalies seen in DTGA involve atrioventricular valves, such as overriding valves or the straddling tricuspid valve [11].

In LTGA the defect is congenitally corrected with atrioventricular discordance. Ventricles are inverted, and A arises from RV and PA from LV [7]. Despite transposition of the great arteries, deoxygenated blood is pumped into the lungs, while oxygenated blood circulates to the rest of the body. With this anomaly, therefore, a shunt is not needed. Anatomically, the aortic valve is anterior and to the left of the pulmonary valve. LTGA is associated more often with other cardiac anomalies, the common ones being VSD at 60–70%, PS at 30–50%, tricuspid regurgitation (TR) at 30% and dextrocardia at <1%.

The coronary arteries are anatomically abnormal in about 33% of the patients with TGA [12]. The commonly reported anomalies are the left circumflex coronary originating from the right coronary artery in 22%, single right artery in 9.5%, single left coronary artery in 3%, or inverted coronary arteries in 3% of the cases. Their course towards their destination may be shortened and unusual, such as passing between the two great arteries. There may be multiple coronary ostia arising from the sinus of Valsalva [12].

5. Hemodynamics and pathophysiology

In DTGA, the deoxygenated blood coming from the superior and inferior vena cava normally drain into the right atrium (RA). From there, it passes over to the right ventricle (RV), then enters the systemic circulation via the abnormally connected Ao, and finally returns to the RA through the vena cava (**Figure 4**). The oxygenated blood in the pulmonary circuit enters the left ventricle (LV) via the left atrium (LA), is pumped into the abnormally connected pulmonary artery, and returns back to the LA via pulmonary veins. This circulatory pattern is incompatible with life and requires mandatory mixing between the two parallel circulations, which is achieved intracardiacally via the PFO, ASD or a VSD; or extracardiacally with a patent DA or other vascular channel of the bronchopulmonary collateral circulation.

DTGA is well tolerated by the fetus as the intercirculatory mixing of blood is maintained by the open fosa ovalis and patent DA. Hemodynamically, during the.

intrauterine life, the major part of the oxygen-rich blood coming from the umbilical vein enters the right atrium and passes across the fossa ovalis into the LV, from where it enters the pulmonary artery and eventually the systemic circulation via the open DA. The vascular resistance in the placental system is comparatively lower to that in pulmonary capillaries and thereby facilitates the right-to-left blood flow through the DA into the aorta. After birth, the volume of intercirculatory mixing decides the severity of hypoxemia, which is optimized by balancing the effective pulmonary and systemic blood flows [7, 8]. The effective systemic blood flow is defined as the volume of oxygenated pulmonary venous return reaching the systemic capillary bed, and the effective pulmonary blood flow, the systemic venous return entering the pulmonary capillary system via the intracardiac and extracardiac shunts. To be most efficient, the shunting of blood must be bidirectional, occurring during both systole and diastole. Being a lower pressure system, this happens better at the atrial level. The interventricular and extracardiac shunt flow may be unidirectional as they function in a high-pressure system across high-pressure gradient. Keeping the shunt bidirectional and balanced is important, as a preferential shunting to either side will lead to clinical deterioration.

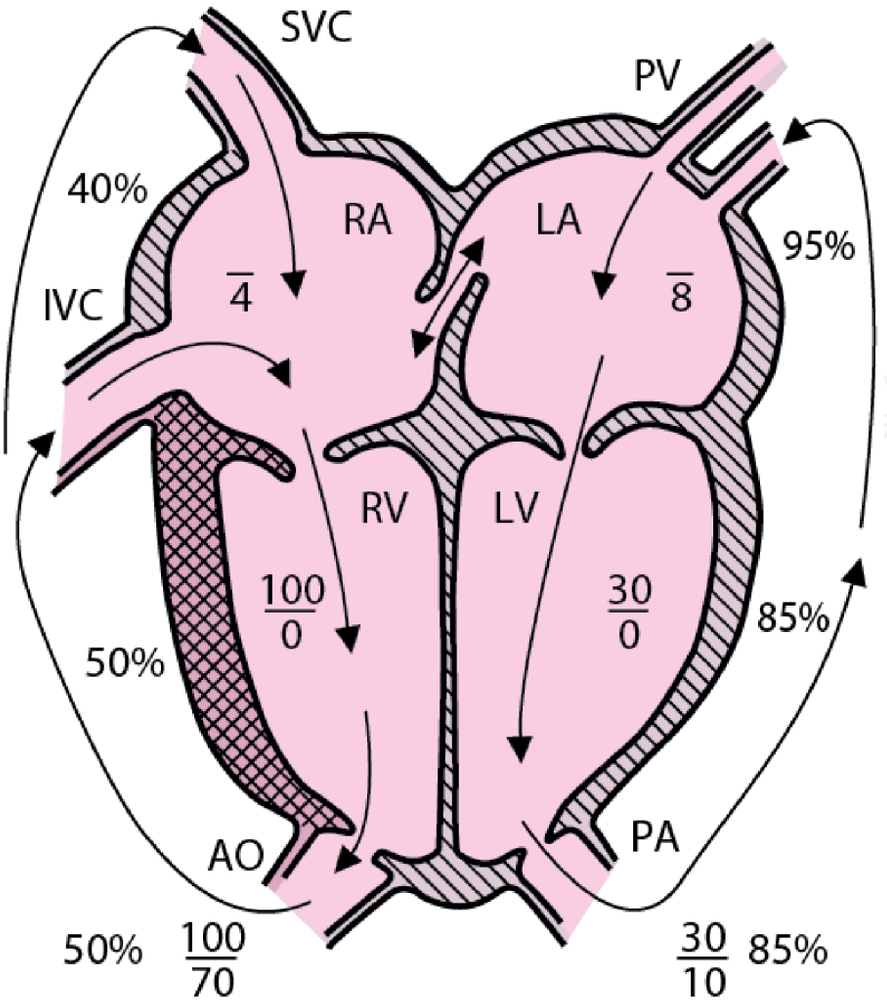

Figure 4.
Hemodynamics in DTGA (curtsey MSD manual).

6. Clinical presentation

Infants with TGA are generally born at term and are normally developed [7, 8, 13]. They may be asymptomatic initially and develop variable cyanosis and respiratory distress shortly after birth. Most patients present with mild shallow tachypnea, which may not be associated with significant retractions. The neonates appear comfortable compared to the degree of cyanosis. Cyanosis is "fixed" and does not respond to oxygen supplementation, resulting in a failed hyperoxia test. If DTGA is uncomplicated, there may not be any murmur. The cases complicated with VSD, PS, and LVOO present with murmurs specific to the lesions. On auscultation, S1 may be loud and single with no audible P2 sound.

The cyanosis in DTGA varies from mild to severe. The degree of mixing between the deoxygenated and oxygenated blood and the presence of other cardiac anomalies determine the severity of cyanosis [7, 8, 13]. If associated with restrictive PFO or ASD, intact ventricular septum or very small VSD severe cyanosis during the newborn period may be noted, which is initially modified by the presence of a patent DA. If a VSD is present, the mixing is better, and the oxygen desaturation not significant; hence the lesion may be detected by a failed pulse oximetry screening at birth. Infants with large VSDs may have no cyanosis or mild cyanosis only when crying or straining. These infants develop CCF over the first month of life. If DA is open and pulmonary vascular pressure low, cyanosis is less intense as the shunting across DA is from left to right. If associated with both VSD and LVOO cyanosis at

birth is extreme, the severity depending upon the degree of diminution of pulmonary blood flow due to left ventricular outflow tract obstruction. DTGA associated with VSD and progressively advancing pulmonary vascular obstructive disease is an uncommon variety and presents with progressive cyanosis despite early palliative procedure and absence of CCF. If DTGA is associated with an intact ventricular septum and PDA along with one of the following: pulmonary hypertension, coarctation of the aorta, or interrupted aortic arch, the infant may have higher postductal oxygen saturations than the preductal, as the better-saturated blood flows into the descending aorta via right-to-left ductal shunting. This sometimes presents as differential cyanosis.

About 80% of infants born with TGA are asymptomatic for the first 24–48 hours of life since the DA is open [13]. After discharge, as the DA closes, such babies return with acute cardiorespiratory decompensation with hypoxemia and severe metabolic acidosis due to tissue hypoperfusion. The universal application of the pre-discharge Congenital Cyanotic heart disease pulse oximetry screening test, recommended by the AAP has significantly improved the chances of a timely diagnosis of TGA in neonates, and such situations are now minimized. In some cases, the presentation may be delayed by days or even weeks, but most are revealed within the neonatal period. If untreated, about 30 percent of TGA cases will die in the first week, 50 percent in the first month, and almost 90 percent within the first year of life.

7. Diagnosis

Antenatal diagnosis of TGA by fetal echocardiography has improved since the visualization of outflow tracts to evaluate the major arteries' relationship is regularly performed. Postnatally, any baby failing the CCHD test or presenting with tachypnea and cyanosis that does not improve with 100% oxygen supplementation should raise the suspicion of a shunting cardiac lesion. A Hyperoxia test confirms the fixed shunting and differentiates between cardiac and pulmonary etiology of hypoxia [13].

Echocardiography with Doppler Study is confirmatory. The procedure should include evaluating atrioventricular and ventricular arterial connections and the presence of other anatomical cardiac anomalies, including those of coronary arteries. In D-TGA, two-dimensional echocardiography in the subcostal view demonstrates a great artery arising from the posteriorly situated left ventricle and bifurcating into left and right pulmonary arteries, while in the short-axis or parasagittal view, the aorta is visualized coming out anteriorly from the right ventricle [7, 8, 13, 14]. The atrial evaluation is important to confirm the presence of FO or ASD and the degree of interatrial flow, which determines the critical intercirculatory mixing. The presence of a VSD assures mixing but suggests the possibility of aortic arch anomalies. Complex TGA with VSD and coarctation have worse surgical outcomes and mortality. The presence of patent DA and the degree and direction of shunting blood are important information to obtain. Coronary artery anatomy and its variations must be ascertained via echocardiography, angiography or cardiac magnetic resonance imaging (MRI) prior to surgery. Atrioventricular valvular anomalies and chordae tendineae's relationship with interventricular septum and ventricles are other important features to evaluate before surgery.

Electrocardiography in TGA is generally normal with right-axis deviation and right ventricular hypertrophy. Biventricular hypertrophy may be noted if DTGA is complicated with large VSD, PDA, PS, or LVOO. Chest radiography may show normal or slightly increased heart size or the typical "egg on a string" appearance with

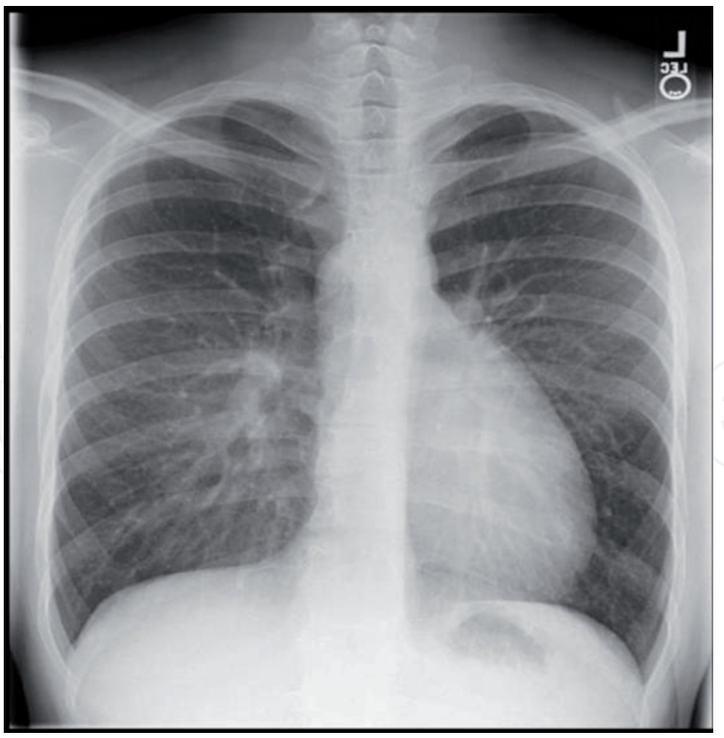

Figure 5.
Chest radiograph in DTHA showing "egg on string appearance".

a narrow mediastinum, created by the anteroposterior positioning of the aorta and pulmonary artery and by involuted thymus (**Figure 5**) [7, 8, 13, 14]. The pulmonary vascular markings may be normal or increased. In the presence of a large VSD or straddling tricuspid valve, the pulmonary flow is increased, and cardiomegaly with congestive heart failure may supervene soon after birth. Cardiac catheterization (CC) and coronary angiography should be done to determine the origin, anatomy, and course of CA, espy if the echocardiography fails to visualize it well before surgery. CC is also used for performing balloon septostomy as a palliative measure to establish mixing of blood.

The conditions which should be clinically differentiated from DTAG are other cyanotic congenital cardiac defects, such as double-outlet right ventricle with malposed great arteries; tricuspid atresia; pulmonary atresia with an intact ventricular septum or with VSD; Tetralogy of Fallot with absent pulmonary valve, pulmonary atresia or severe pulmonary valve stenosis; TAPVR and truncus arteriosus.

8. Management

8.1 Medical management

Once the diagnosis is confirmed after a though evaluation, the focus should be on cardiorespiratory stabilization and adequate systemic oxygenation by ensuring optimum mixing of blood. As the first step, DA's patency is maintained with continuous intravenous PGE1 infusion, which is followed by balloon atrial septostomy (BAS, Rashkind procedure) [15, 16]. The presence of a significantly lower preductal oxygen saturation (SaO2) than the post ductal suggests inadequate atrial shunting and mixing of blood and indicates CC and BAS [17]. BAS is used to increase the atrial level shunt. The procedure can be performed at the bedside under echocardiographic guidance or in the catheterization laboratory under fluoroscopy

and echocardiography. It involves accessing the heart via the umbilical or femoral vein and then inserting a deflated balloon across the atrial septum into LA. The balloon is then inflated and pulled back across the septum. The procedure is repeated, and follow-up echocardiography and clinical hemodynamic assessment are done to ensure the formation of an effective ASD and optimum intracardiac mixing.

Intravenous fluid and bicarbonate should be given to correct metabolic acidosis, and pulmonary support should be provided as and if indicated. Congestive heart failure should be treated if present. Appropriate nutrition is an essential part of the management.

8.2 Surgical management and procedures

Surgery is undertaken within the first 1–2 weeks of life. The infants' clinical status and hemodynamics determines the timing. Surgery is generally undertaken after the palliation procedures, but in selected cases, such as DTGA with intact ventricular septum and restrictive foramen ovale with severe metabolic acidosis may be performed without, and within the first few days of life [18]. The arterial switch operation (ASO, Jatene procedure) is the standard surgical procedure for DTGA. ASO has reduced the mortality in DTGA from almost 90% in unoperated infants to <5% in those who undergo surgery [19–21]. The perioperative mortality with ASO in simple DTGA is <1%, while it is 4% in those with complex DTGA. Reportedly a delay of ASO beyond three days after birth may be associated with increased morbidity and health care costs. Other surgical options in DTDA are the Mustard, Senning, and Rastelli procedures. The surgical procedures are selected according to the complexity of DTGA as follows:

a. Simple DTGA with intact VS and no other cardiac anomalies: ASO is the preferred surgery and is performed within the first month of life for the LV to be able to sustain the systemic pressure circulation. In this procedure, the two great arteries are transected and translocated to the opposite root, thus reestablishing the ventriculoarterial concordance. In addition, the coronary arteries are mobilized and reimplanted into the neo-aortic roots with the formation of buttons around them. If coronary arterial reimplantation or mobilization is not possible, the atrial switch operation, known as the Mustard or Senning procedures, may be undertaken. In this operation, the oxygen-rich blood is redirected to RV and Ao, and the oxygen-poor blood to the LV and PA via a two-way interatrial baffle, created by the patient's own tissue or synthetic material. The atrial switch is less preferred due to its late complications. It may be used for palliation in selected complex cases of LTGA.

b. DTGA with VSD: ASO and VSD closure are performed.

c. D-TGA with VSD and LVOO due to pulmonary stenosis (PS): The Rastelli procedure is the standard surgery, and ASO can be done with or without relieving the LVOO obstruction. The decision about choosing one procedure over the other depends on the size of VSD, the severity, and type of LVOO, the status of neo aortic, i.e., pulmonary valve, and the anatomy of coronary arteries. The objective and considerations are to minimize the recurrence risk of LVOO (i.e., PS) or future repeat surgeries and to optimize the pulmonary valve functions. Both ASO and Rastelli procedures involve an arterial switch following which the LV functions as the systemic ventricle and the RV as the pulmonary ventricle [14, 17]. The principle is to redirect the ventricular outflows. Rastelli procedure is undertaken in patients of D-TGA with a large VSD and significant

LVOO. In this procedure, the LV outflow tract obstruction is baffled through the VSD, thus closing it, and the oxygenated blood from the left ventricle is directed into the aorta. A valved conduit is placed between RV and PA, and the deoxygenated blood from the right ventricle enters the PA via the conduit. The Rastelli procedure with a perioperative mortality of <5 percent generally provides better and more durable relief of LVOT obstruction than ASO but has more postoperative complications.

d. TGA with VSD and pulmonary arterial vascular disease: This is a rare type in which surgery may not be beneficial as PA hypertension is progressive. Palliation may be an option in some cases.

8.3 Complications of surgery

Complications may occur in 5 to 25 percent of patients who undergo ASO; the commonest one that will need reintervention is pulmonary artery stenosis [22–26]. If the right ventricular pressure becomes close to systemic levels or if the lung perfusion scan is abnormal catheter-based dilation and stent placement may be performed. Other less common complications include coronary artery insufficiency, neo-aortic root dilation, and neo-aortic regurgitation. With the Rastelli procedure, complications such as conduit stenosis needing replacement, atrial and ventricular arrhythmias, and right and left ventricular failure are reported. Complications of the atrial switch include right ventricular failure, arrhythmias, and baffle-related sequelae [20, 23, 24].

9. Prognosis of TGA

With the introduction of palliation followed by cardiac surgical procedures, the outcome of TGA has changed from a universally fatal disease to a long-term survival rate of over 90% [20]. Patients who undergo ASO have the best long-term survival and the lowest morbidity, and the best functional outcome compared to other surgical procedures. ASO is reported to have a > 95 percent survival at 15 to 25 years post-discharge, whereas survival in the Mustard atrial switch procedure is approximately 80 percent at 20 years and 75 percent at 25 years. [25] In the Rastelli procedure, 10-year survival rates are reported to be 80 to 94 percent [22]. Perioperative mortality is greater in patients with complex DTGA compared to those with simple DTGA. Progressive congestive heart failure and sudden death are the commonest causes of death. The clinical risk factors for mortality in TGA are prematurity, low birth weight, single coronary artery, aortic arch obstruction, and RV hypoplasia. Ninety-three percent of the ASO recipients are reported to be free from long-term cardiovascular complications, such as arrhythmia, cerebrovascular accident, heart failure-related hospitalization. Their cardiorespiratory exercise capability is at 91 percent of normal, while those who undergo atrial switch procedures 75 percent [26]. VSD repair, residual right-sided obstructive lesions, and decreased left ventricular function are the risk factors for poor exercise performance. Those who undergo Mustard or Senning operations are more likely to suffer from arrhythmia and right heart failure.

Neurodevelopmental impairment is common in babies after ASO [27–33]. Surgery at postnatal age > 2 weeks and the presence of VSD are documented to be associated with reduced perioperative brain growth and poor language performance scores at 18 months of age, respectively [15]. In one study, at 16 years of age, 65 percent of the ASO recipients required special education, occupational therapy,

psychotherapy, and counseling; and about 20 percent suffered from attention deficit hyperactivity disorder and poor global psychosocial function scores [28]. The occurrence of seizures in the postoperative period is independently associated with lower neuropsychological scores. In another prospective study performed on 45 children with DTGA, the neurodevelopmental testing at age four to six years revealed the scores to be normal for cognition, language, and verbal working memory but lower for inhibition control, cognitive flexibility, social cognition, and executive function, when compared with controls [29, 30]. Neurodevelopmental outcomes are modified by the timing of diagnosis (prenatal versus postnatal), the severity of hypoxemia in the newborn period, the timing of surgery, associated cardiac defects, perioperative complications, necrotizing enterocolitis, and the need for extracorporeal membrane oxygenation. Brain MRI may be abnormal in 20–50% of cases who undergo surgery and demonstrate focal ischemic changes, white matter changes, volume loss, and periventricular leukomalacia [32, 33].

10. Long term outcomes in adult survivors

In the adult survivors of DTGA who undergo atrial switch procedure, RV failure and TR are common as the morphological RV functionally supports the high-pressure systemic circulation instead of the physiological low-pressure pulmonary circulation as it is supposed to [34]. More common long term complications are cardiac arrhythmias, which can result in sudden death due to atrial flutter. In the longer living survivors, sinus node dysfunction with the eventual need for pacemaker placement has been noted. In the adult survivors of ASO recipients, pulmonary arterial stenosis and distortion, neoaortic root dilatation, and aortic regurgitation are the reported complications.

In the patients with LTGA, the congenitally corrected transposition, the systemic high-pressure circulation is supported by the morphological RV and a weak tricuspid valve. In these patients, TR is common which progressively worsens with age, eventually leading to RV failure. Additional surgical interventions may be required if RV dilatation or dysfunction appear. Almost 90% of cases of LTGA are associated with other cardiac defects, such as VSD (70–80%), PA (30–60%), mitral valve anomalies (straddling valve, additional cusps, dysplasia, 55%), and TR (90%). Rhythm disorders, like heart block or atrial arrhythmias, are common in them. Some of these patients may eventually require cardiac transplantation. Appropriate follow-up with periodic hemodynamic and functional assessment is an integral part of these patients' subsequent specialized management for best outcomes [35].

11. Conclusion

TGA is a complex congenital cyanotic cardiac anomaly characterized by ventriculoarterial or ventriculoatrial discordance. DTGA is the commonest cyanotic heart disease occurring during the first week of life. Advancements in early diagnostic measures, medical management, and surgical procedures have increased this former universally fatal disease's survival rate to over 90%. The post-surgical course is complicated by cardiac anatomic, hemodynamic, and rhythm disorders, which may require meticulous follow-up and additional surgical interventions, including cardiac transplants in some cases with LGTA. Long term outcome may be associated with normal to mild neurodevelopmental disabilities depending upon the type, complexity, and course of the disease. Expert follow-up of the patients into adulthood is essential for the best outcomes.

IntechOpen

IntechOpen

Author details

Rita Prasad Verma
Nassau University Medical Center, East Meadow, NY, USA

*Address all correspondence to: rverma2@numc.edu

IntechOpen

© 2021 The Author(s). Licensee IntechOpen. This chapter is distributed under the terms of the Creative Commons Attribution License (http://creativecommons.org/licenses/by/3.0), which permits unrestricted use, distribution, and reproduction in any medium, provided the original work is properly cited.

References

[1] Mai CT, Isenburg JL, Canfield MA, et al. for the National Birth Defects Prevention Network. National population-based estimates for major birth defects, 2010-2014. Birth Defects Res 2019; 1– 16. https://doi.org/10.1002/bdr2.1589.

[2] Centers for Disease Control and Prevention (CDC). Improved national prevalence estimates for 18 selected major birth defects--United States, 1999-2001. MMWR Morb Mortal Wkly Rep 2006; 54:1301.

[3] Reller MD, Strickland MJ, Riehle-Colarusso T, et al. Prevalence of congenital heart defects in metropolitan Atlanta, 1998-2005. J Pediatr 2008; 153:807.

[4] Tennstedt C, Chaoui R, Körner H, Dietel M. Spectrum of congenital heart defects and extracardiac malformations associated with chromosomal abnormalities: results of a seven year necropsy study. Heart 1999; 82:34.

[5] Momma K. Cardiovascular anomalies associated with chromosome 22q11.2 deletion syndrome. Am J Cardiol 2010; 105:1617.

[6] Becker TA, Van Amber R, Moller JH, Pierpont ME. Occurrence of cardiac malformations in relatives of children with transposition of the great arteries. Am J Med Genet 1996; 66:28.

[7] Fulton DR, Fyler DC. D-Transposition of the Great Arteries. In: Nadas' Pediatric Cardiology, 2nd ed, Keane JF, Lock JE, Fyler DC (Eds), Saunders Elsevier, Philadelphia, PA 2006. p.645.

[8] Wernovsky G. Transposition of the Great Arteries. In: Moss and Adams' Heart Disease in Infants, Children, and Adolescents: Including the Fetus and Young Adult, 7th ed, Allen HD, Shaddy RE, Driscoll DJ, Feltes TF (Eds), Wolters Kluwer Health/Lipincott Williams & Wilkins, Philadelphia, PA 2008. p.1039.

[9] Moene RJ, Oppenheimer-Dekker A, Bartelings MM. Anatomic obstruction of the right ventricular outflow tract in transposition of the great arteries. Am J Cardiol 1983; 51:1701.

[10] Kirklin JW, Barratt-Boyes BG. Complete Transposition of the Great Arteries. In: Cardiac Surgery, Kirklin JW, Barratt-Boyes BG (Eds), Churchill Livingston, New York 1993. p.1383.

[11] Deal BJ, Chin AJ, Sanders SP, et al. Subxiphoid two-dimensional echocardiographic identification of tricuspid valve abnormalities in transposition of the great arteries with ventricular septal defect. Am J Cardiol 1985; 55:1146.

[12] Wernovsky G, Sanders SP. Coronary artery anatomy and transposition of the great arteries. Coron Artery Dis 1993; 4:148.

[13] Rao PS. Diagnosis and management of cyanotic congenital heart disease: part I. Indian J Pediatr. 2009 Jan. 76 (1):57-70.

[14] Rao PS. Management of Congenital Heart Disease: State of the Art—Part II—Cyanotic Heart Defects. Children (Basel). 2019 Apr; 6(4): 54. doi: 10.3390/children6040054

[15] Beitzke A, Suppan CH. Use of prostaglandin E2 in management of transposition of great arteries before balloon atrial septostomy. Br Heart J. 1983;49(4):341-344. doi:10.1136/hrt.49.4.341

[16] Hiremath G, Natarajan G, Math D, Aggarwal S. Impact of balloon atrial

septostomy in neonates with transposition of great arteries. J Perinatol. 2011 Jul;31(7):494-499.

[17] Rao PS. Transposition of the Great Arteries in the Neonate. Neonatology today Newsletter. 2010 August. Volume 5. Issue 8

[18] Nevvazhay T, Chernogrivov A, Biryukov E, Biktasheva L, Karchevskaya K, Sulejmanov S, Kalinicheva J, Artemiev N. Arterial switch in the first hours of life: no need for Rashkind septostomy? Eur J Cardioth Surg. 2012 Sep;42(3):520-523.

[19] Lim JM, Porayette P, Marini D, et al. Associations Between Age at Arterial Switch Operation, Brain Growth, and Development in Infants With Transposition of the Great Arteries. Circulation 2019; 139:2728.

[20] Hutter PA, Kreb DL, Mantel SF, et al. Twenty-five years' experience with the arterial switch operation. J Thorac Cardiovasc Surg 2002; 124:790.

[21] Anderson BR, Ciarleglio AJ, Hayes DA, et al. Earlier arterial switch operation improves outcomes and reduces costs for neonates with transposition of the great arteries. J Am Coll Cardiol 2014; 63:481.

[22] Hazekamp MG, Gomez AA, Koolbergen DR, et al. Surgery for transposition of the great arteries, ventricular septal defect and left ventricular outflow tract obstruction: European Congenital Heart Surgeons Association multicentre study. Eur J Cardiothorac Surg 2010; 38:699.

[23] Jatene AD, Fontes VF, Paulista PP, et al. Anatomic correction of transposition of the great vessels. J Thorac Cardiovasc Surg 1976; 72:364.

[24] Prêtre R, Tamisier D, Bonhoeffer P, et al. Results of the arterial switch operation in neonates with transposed great arteries. Lancet 2001; 357:1826.

[25] Khairy P, Clair M, Fernandes SM, et al. Cardiovascular outcomes after the arterial switch operation for D-transposition of the great arteries. Circulation 2013; 127:331.

[26] Kuebler JD, Chen MH, Alexander ME, Rhodes J. Exercise Performance in Patients with D-Loop Transposition of the Great Arteries After Arterial Switch Operation: Long-Term Outcomes and Longitudinal Assessment. Pediatr Cardiol 2016; 37:283.

[27] Karl TR, Hall S, Ford G, et al. Arterial switch with full-flow cardiopulmonary bypass and limited circulatory arrest: neurodevelopmental outcome. J Thorac Cardiovasc Surg 2004; 127:213.

[28] Hövels-Gürich HH, Seghaye MC, Schnitker R, et al. Long-term neurodevelopmental outcomes in school-aged children after neonatal arterial switch operation. J Thorac Cardiovasc Surg 2002; 124:448.

[29] Culbert EL , Ashburn DA, Cullen-Dean G, Joseph JA, Williams WG, Blackstone EH, McCrindle BW, Congenital Heart Surgeons Society. Quality of life of children after repair of transposition of the great arteries. Circulation. 2003 Aug 19;108 (7):857-862.

[30] Neufeld RE, Clark BG, Robertson CM, et al. Five-year neurocognitive and health outcomes after the neonatal arterial switch operation. J Thorac Cardiovasc Surg 2008; 136:1413.

[31] McGrath E, Wypij D, Rappaport LA, et al. Prediction of IQ and achievement at age 8 years from neurodevelopmental status at age 1 year in children with D-transposition of the great arteries. Pediatrics 2004; 114:e572.

[32] Bellinger DC, Wypij D, Rivkin MJ, et al. Adolescents with d-transposition

of the great arteries corrected with the arterial switch procedure: neuropsychological assessment and structural brain imaging. Circulation 2011; 124:1361.

[33] DeMaso DR, Labella M, Taylor GA, et al. Psychiatric disorders and function in adolescents with d-transposition of the great arteries. J Pediatr 2014; 165:760.

[34] Breinholt JP , Sheba John Management of the Adult with Arterial Switch. Methodist Debakey Cardiovasc J. Apr-Jun 2019;15(2):133-137. doi: 10.14797/mdcj-15-2-133.

[35] Safi LM, Bhatt AB. Update on the Management of Adults With Arterial Switch Procedure for Transposition of the Great Arteries. Curr Treat Options Cardiovasc Med. 2017 Jan;19(1):4. doi: 10.1007/s11936-017-0505