

# We are IntechOpen, the world's leading publisher of Open Access books Built by scientists, for scientists

6,900

Open access books available

185,000

International authors and editors

200M

Downloads

Our authors are among the

154

Countries delivered to

TOP 1%

most cited scientists

12.2%

Contributors from top 500 universities



WEB OF SCIENCE™

Selection of our books indexed in the Book Citation Index  
in Web of Science™ Core Collection (BKCI)

Interested in publishing with us?  
Contact [book.department@intechopen.com](mailto:book.department@intechopen.com)

Numbers displayed above are based on latest data collected.  
For more information visit [www.intechopen.com](http://www.intechopen.com)





# The Physiology of Tear Film

*Abraham Kayal*

## Abstract

The precorneal tear film is a thin layer, about 2–5.5  $\mu\text{m}$  thick, which overlays the corneal and conjunctival epithelium. It functions to lubricate and protect the corneal and eyelid interface from environmental and immunological factors as well as provide an optical medium. The tear film is depicted as a three-layered structure: lipid, aqueous, and mucous layers. Within each layer possesses a different composition which dictates its function. In common between the three layers are their homeostatic process of evaporation and drainage. Any dysfunction in either of the layers can result in Dry Eye Syndrome (DES). The composition, regulation, and pathology of tear film will be discussed in this chapter.

**Keywords:** Physiology, tear film, meibomian glands, lacrimal glands, conjunctival goblet cells, blink reflex

## 1. Introduction

The precorneal tear film is traditionally described as a structure made of three layers which make up a thickness of 2–5.5  $\mu\text{m}$  [1]. The thickness of the tear film was a controversial topic, with many attempts to measure the full thickness through different imaging modalities. However, recent publications such as the DEWS II Tear Film state that ultrahigh resolution Optical Coherence Tomography (OCT) has recently resolved the debate over the tear film thickness. Furthermore, the tear film is now regarded as a complex blended two-layer structure comprising of an outer lipid layer and an inner muco-aqueous layer [1, 2]. However, to better understand the precorneal tear film, the traditional approach will be taken in this review. The three tear film layers serve to not only protect and provide nutrition to the cornea, but also act as the first refractive surface for light entering the eye. Of the three layers, the largest is the middle aqueous. (e.g. **Table 1**).

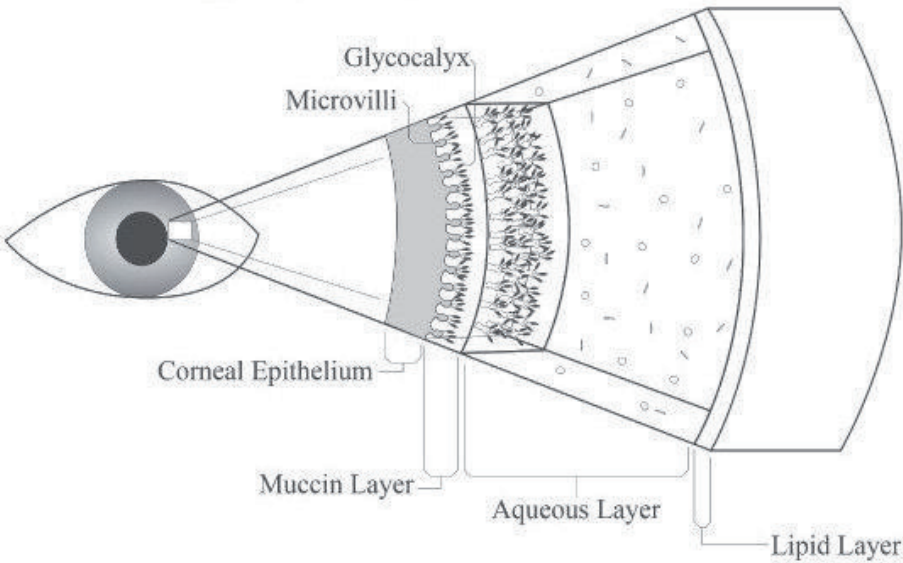
## 2. The layers of tear film

Traditionally, the tear film has been described as a three-layered structure composed of the deep mucinous, middle aqueous, and superficial lipid layers (e.g. **Figure 1**). All three layers overlay the corneal and conjunctival epithelium, forming a full thickness of 2–5.5  $\mu\text{m}$  [1]. Generally, the functions of the tear film are to lubricate the corneal and eyelid interface, form a protective covering and a smooth optical surface at the air-eye interface, and provide an antibacterial medium for the cornea and conjunctiva. The tear film also acts as the main oxygen supply to the corneal epithelium and functions as a temporary depository for instilling topical therapeutic drugs. (e.g. **Figure 1**).



	Origin	Composition	Function
Mucin Layer	<ul style="list-style-type: none"><li>• Corneal and Conjunctival epithelial cells (Glycocalyx)</li><li>• Conjunctival goblet cells &amp; Glands of Manz (Mucous)</li></ul>	<ul style="list-style-type: none"><li>• Glycoprotein</li><li>• Mucin</li></ul>	<ul style="list-style-type: none"><li>• Converts corneal epithelium to a hydrophilic surface for aqueous to hydrate.</li><li>• Decreases corneal surface tension.</li></ul>
Aqueous Layer	<ul style="list-style-type: none"><li>• Lacrimal glands</li><li>• Corneal epithelial cells</li><li>• Conjunctival epithelial cells</li></ul>	<ul style="list-style-type: none"><li>• Water</li><li>• Oxygen</li><li>• Lysozymes, Lactoferrin, Betalysin, Immunoglobins</li><li>• VEGF</li><li>• Electrolytes</li></ul>	<ul style="list-style-type: none"><li>• Barrier to infection</li><li>• Flushes debris</li><li>• Wound healing</li><li>• Provides energy for corneal metabolism</li><li>• Corneal hydration</li></ul>
Lipid Layer	<ul style="list-style-type: none"><li>• Meibomian glands</li></ul>	<ul style="list-style-type: none"><li>• Cholesterol esters</li><li>• Waxes</li></ul>	<ul style="list-style-type: none"><li>• Delays evaporation</li><li>• Lowers surface tension</li><li>• Provides optically smooth surface</li></ul>

**Table 1.**  
*Overview of the origin, composition, and function of the tear film layers.*



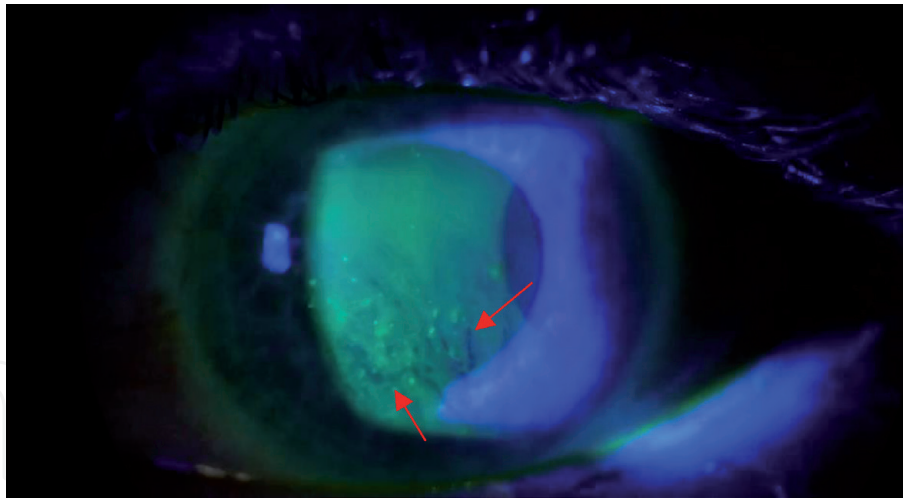
**Figure 1.**  
*Traditional 3-layered composition of tear film. Available via license: Creative commons attribution 4.0 international.*

2.1 The mucinous layer

Most posteriorly sits the mucinous layer which has a thickness of 0.5  $\mu\text{m}$ . It is composed of a mucin dominant gel formed by 2 layers: the glycocalyx and mucous layers. Posteriorly, the glycocalyx layer sits on the microvilli of the superficial corneal epithelium and is produced by the corneal and conjunctival epithelial cells [1, 2].

Overlying the glycocalyx layer is the mucous “blanket,” a thick layer produced by the conjunctival goblet cells and the glands of Manz, lying in the crypts of Henle and in the bulbar conjunctiva, respectively [3]. This mucous layer is made of many gel-forming mucins and most significant of the mucin is MUC5-AC. Several studies





**Figure 2.**  
 TBUT with fluorescein dye tear break up (red arrow). Taken with permission from Kenny Chan [5].

have linked MUC5-AC decrease to DES. The function of the mucin is to transform the corneal surface into a hydrophilic surface [1, 2]. This transformation results in a reduction in corneal surface tension and provides the cornea with tear film stability, allowing the adhesion of the overlying aqueous layer, preventing the formation of dry spots. This decrease in surface tension also serves to lubricate and cushion the eye during all movements [3].

In order to test the integrity of the mucinous layer, the Tear Break-up Time (TBUT) test can be done. This test is used to assess for evaporative dry eye disease from the deficiency of mucin [4]. It is carried out by first instilling fluorescein into the patient's tear film. Afterwards, a cobalt blue illumination is shown onto the effected eye to observe the time elapsed between the last blink and the appearance of the first dry spot in the tear film (e.g. **Figure 2**). A TBUT of under 10 seconds is abnormal, indicating a problem with the mucinous layer's ability to form a hydrophilic layer [4].

Other abnormalities can occur which affect this layer include Vitamin A deficiency, Ocular Cicatricial Pemphigoid, Stevens-Johnsons Syndrome, and Alkali burns [6]. All mentioned conditions lead to the destruction of goblet cells with consequent loss of mucin production. As a result, a rapid breakdown of tear film occurs, even with adequate volume of aqueous layer.

## 2.2 The aqueous layer

The middle aqueous layer forms the largest part of the tear film thickness, at 2–6  $\mu\text{m}$  [1]. Its main functions are to supply oxygen to the corneal epithelium, provide a protective layer against bacteria, and provide a healing media through VEGF. The aqueous layer is produced by the secretions of the lacrimal gland apparatus and its accessory glands. The aqueous layer can be secreted via reflex secretions or via its basal source. The reflex secretions are secreted by the main lacrimal gland whereas the basal source of the aqueous is secreted from the accessory lacrimal glands of Krause and Wolfring [7].

Unlike the mucinous layer, the release of aqueous is mediated by various methods: the autonomic nervous system, hormones, and psychological factors. The autonomic nervous system activates the lacrimal reflex through the sensory innervations at the corneal and conjunctival unmyelinated C-type fibers which form the subepithelial plexus at the superficial cornea [8]. The stimulation of the sensory nerves causes the parasympathetic system to increase the aqueous secretion



and vasodilate the blood vessels supplying the lacrimal gland. Although the sympathetic nervous system plays a role in tear lacrimal aqueous secretion, the parasympathetic system predominates this reflex [8].

Androgens also play a role in the mediation of aqueous secretion from the lacrimal gland. Reduced serum androgen levels in women with altered endocrine states, such as women after menopause, ovariectomy, and during oral contraceptive use have been observed to have primary lacrimal deficiency, despite their variable estrogen levels. However, men who take anti-androgen therapy do not show signs of any change to tear secretion, suggesting that the androgen effect of the lacrimal gland may be sex specific [8]. Moreover, emotional expression also controls the secretion of aqueous from the lacrimal gland. The exact mechanism is currently unknown, and further research is needed to understand the neurobiology of human emotional crying [2, 8].

The aqueous layer is composed of 98% water, with the remaining 2% made up of Sodium, Potassium (6x that of plasma), Chloride, Bicarbonate, Calcium, Amino Acids, Oxygen, and VEGF (**Table 2**) [7]. The proteins found in the aqueous layer plays a significant role, as it supplies the cornea with a rich source of bactericidal enzymes. High in number of lysozymes, lactoferrin, betalysin, and immunoglobins, the aqueous layer provides a barrier to infection for the eye. The Immunoglobins, mostly IgA, are derived from the lymphoid tissue in the lacrimal gland stroma. Furthermore, the VEGF found in the aqueous provides the cornea with a source for healing [7, 9].

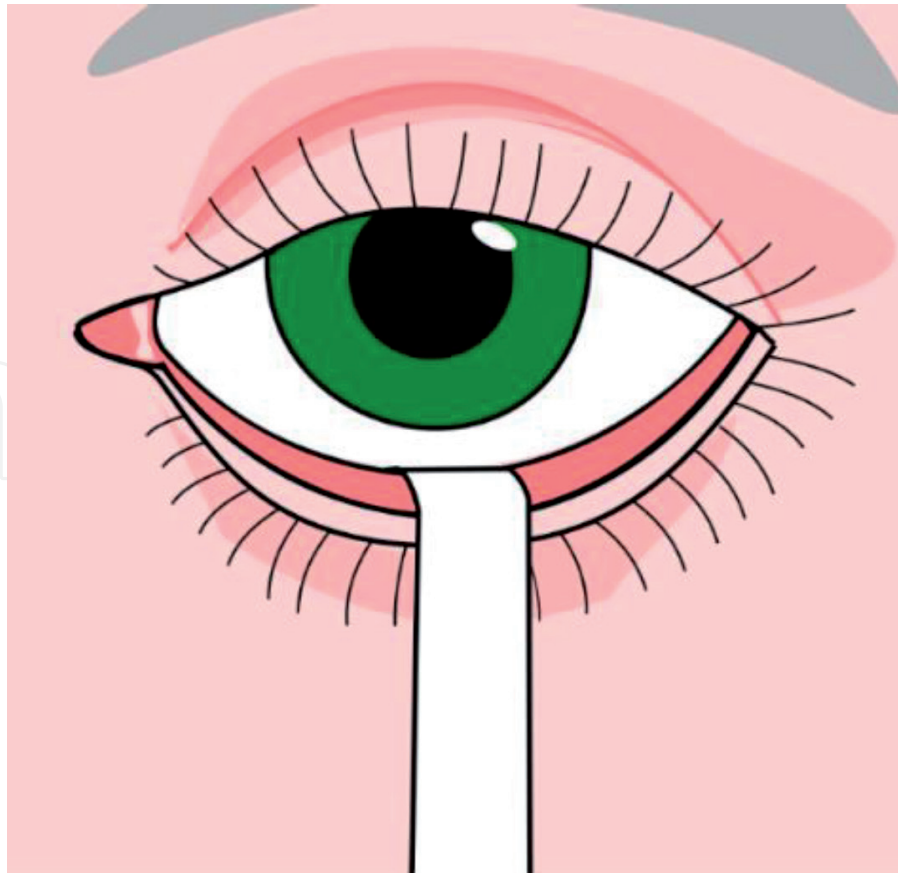
Due to the cornea's requirements to achieve transparency, there is no blood supply within its structure. Nevertheless, oxygen is needed for the corneal epithelium's aerobic metabolism. This oxygen is derived mainly from the aqueous layer of the tear film when the eyes are open and minorly from the conjunctival blood vessels when the eyes are closed. When the eyes are open, the tear film possesses a saturation of 155 mmHg of Oxygen which makes up 70% of ATP production at the corneal epithelium. The last 30% occurs when the eyes are closed, with the saturation of oxygen from the conjunctival blood vessels being 55 mmHg. If the individual is a contact lens wearer, the pO<sub>2</sub> drops to around 15 mmHg when eyes are closed [9, 10]. Moreover, the aqueous layer smooths irregularities in the corneal surface providing an optical function.

To test the caliber of the aqueous layer, the Schirmer test can be performed. The Schirmer test is done using a special filter paper which is 5 mm wide and 35 mm long with the bent end placed between the palpebral conjunctiva of the lower eyelid and the bulbar conjunctiva of the eye. The eye is then closed for 5 minutes and the absorption of the fluid into the filter paper is measured in millimeters. The test can be done with or without the use of anesthetics (e.g. **Figure 3**) [11]. To evaluate the baseline secretions of the lacrimal gland, the test is done using anaesthetics, whereas the evaluation of reflex secretions along with baseline secretions is done without the use of anaesthetics. An individual with normal aqueous tear

Sodium	134–170 mmol/l
Potassium	20–40 mmol/l
Chloride	130 mmol/l
Bicarbonate	26 mmol/l
Calcium	0.61 mmol/l
Amino Acids	50 mg/l
Urea	4–7 mmol/l

**Table 2.**  
*Electrolytes and proteins making up 2% of aqueous [7].*





**Figure 3.**  
*Schirmer test. Available via license: Creative commons attribution-share alike 3.0 Unported.*

production will have a reading of >15 mm after 5 minutes. Mild–moderate reduction of aqueous production is a reading from 5 to 14 mm after 5 minutes, and severe dryness is a reading of less than 5 mm [11, 12].

A deficiency of the aqueous layer is responsible for about 20% of cases of DES [11]. Such deficiency can be a result of advanced age, Sjogrens syndrome, Keratoconjunctivitis Sicca, familial dysautonomia, and side-effects of common ocular surgeries such as LASIK, PRK, and phacoemulsification [13, 14].

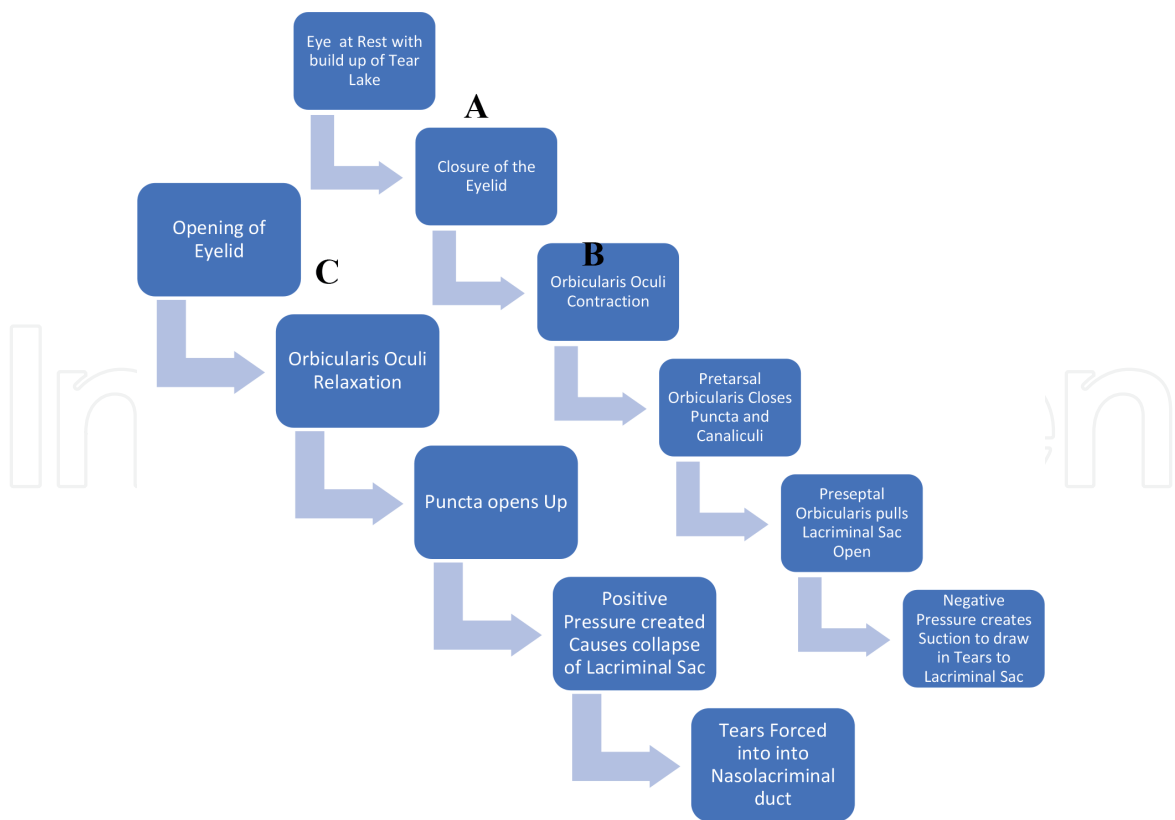
### 2.3 The lipid layer

The lipid layer is the most significant layer in terms of DES. Alterations of its thickness and composition are associated with DES. The lipid layer is the outermost layer of the precorneal tear film and is the thinnest at 0.04  $\mu\text{m}$ . The lipids within this layer are secreted from mainly the meibomian glands, with minor contribution from the Moll and Zeiss glands located in the eyelids [1, 13, 15].

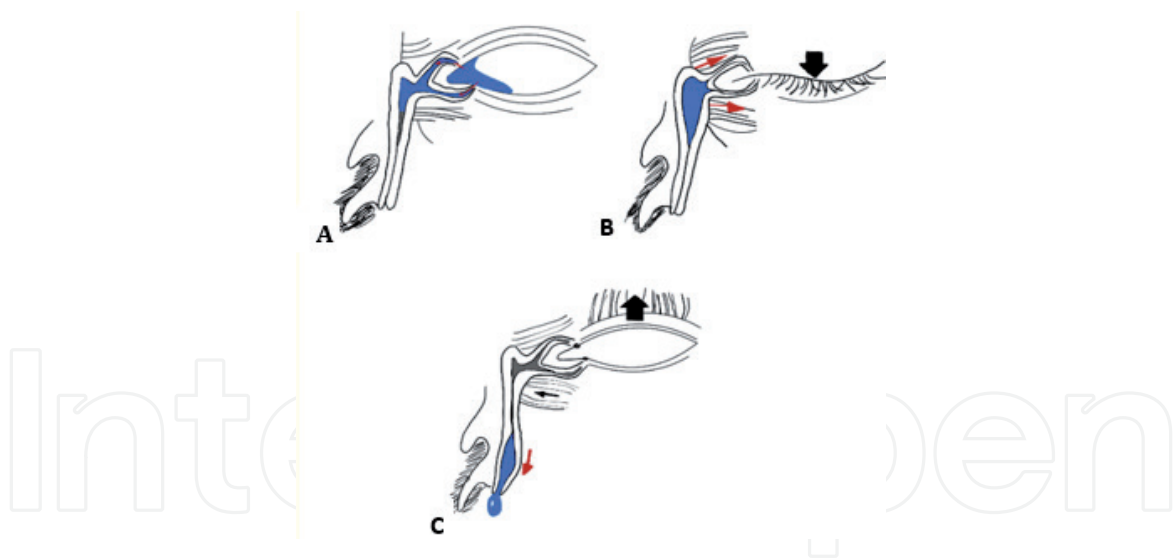
The lipid layer is composed of mostly cholesteryl esters and waxes, with the rest of its composition made up of diesters, fatty acids, cholesterol, and triacylglycerol. The main function of this layer is to prevent the rapid evaporation of tears, followed by the prevention of spillage of tears at the lid margin [16, 17]. This prevention is achieved by the formation of a water-tight seal with the closure of the lids. Furthermore, the lipid layer functions as a clear optical medium.

Deficiency of the lipid layer occurs with meibomian gland dysfunction (MGD). Of cases of dry eye, MGD makes up 60% of cases of DES [13]. With the dysfunction of the meibomian gland, the thickness of the lipid layer is decreased, leading to rapid evaporation of tears and spillage of tear film over the lid margin, ending in eye dryness. To individuals with DES, this spillage can give the false sensation





**Figure 4.**  
Lacrimal pump mechanism corresponding with *Figure 5*.



**Figure 5.**  
Illustration of Lacrimal pump. (A) Pump at resting state. (B) Closure of eyelid. (C) Opening of eyelid.

of excessive watering as opposed to dryness. Other conditions effecting the meibomian glands are infections from *Staphylococcus aureus* and other bacteria which produce cholesterol esterase and fatty wax esterase capable of hydrolyzing the meibomian lipids and forming “froths” at the lid margin [18].

Non-invasive tests including interferometry, meibography, and meibometry are carried out to detect abnormalities in the lipid layer and meibomian gland. However, meibometry is the only test which measures the basal lipid production volume of the meibomian glands [17, 19, 20]. The test is done with the use of an 8-mm wide loop of translucent plastic tape and a “Laser Meibometer” which measures the optical density of the tape. Before beginning the test, the optical density



of the plastic tape is measured with the laser meibometer as a control. While the patient is gazing upwards with their lower lid pulled downwards, the loop is then pushed against the lid margin with a pressure of 0 mmHg for 3 seconds and is set aside for 3 minutes to evaporate any tear fluid contaminants. Afterwards, the laser meibometer is used to measure the “casual” or basal lipid level. This measurement is calculated as (C-B) where C is the casual reading and B is the reading from the untouched tape [20].

### 3. Balance of tear film

The dynamics of the precorneal tear film are balanced through drainage and evaporation. The drainage of the tear film is regulated by neural reflexes, as opposed to evaporation which depends on the blink rate, temperature, humidity, and air velocity [21].

The drainage of the tear film is maintained by the lacrimal portion of the orbicularis muscle with blinking and is termed the “lacrimal pump mechanism” [22, 23]. This mechanism is controlled mainly by the closure and opening of the eyelids by the orbicularis oculi muscle, in turn effecting the pressure on the lacrimal sac as seen below (e.g. **Figures 3 and 4**):

### 4. Conclusion


The integrity of the tear film layer plays a significant role in the development of dry eye. Although extremely thin, the precorneal tear film holds a significant role in protecting the eye from environmental contamination and local or systemic pathology. Any alteration to the composition of each layer of tear film will drastically affect the function of that layer, and in turn compromise the health of the cornea.

### Author details

Abraham Kayal  
Institute of Ophthalmology, University College of London, London,  
United Kingdom

\*Address all correspondence to: [abraham.kayal@gmail.com](mailto:abraham.kayal@gmail.com)

### IntechOpen

© 2021 The Author(s). Licensee IntechOpen. This chapter is distributed under the terms of the Creative Commons Attribution License (<http://creativecommons.org/licenses/by/3.0>), which permits unrestricted use, distribution, and reproduction in any medium, provided the original work is properly cited. 



## References

- [1] Willcox MDP, Argüeso P, Georgiev GA, Holopainen JM, Laurie GW, Millar TJ, Papas EB, Rolland JP, Schmidt TA, Stahl U, Suarez T, Subbaraman LN, Uçakhan OO, MDk, Jones L; TFOS DEWS II Tear Film Report. *Ocul Surf.* 2017 July; 15(3): 366-403. doi:10.1016/j.jtos.2017.03.006
- [2] Davidson HJ, Kuonen VJ. The tear film and ocular mucins. *Vet Ophthalmol.* 2004 Mar-Apr;7(2):71-7. doi: 10.1111/j.1463-5224.2004.00325.x. PMID: 14982585; PMCID: PMC7169288.
- [3] TRB Chemedica International. The mucus layer. [Internet] 2016. Available from: <https://vismed.trbchemedica.co.uk/business-professionals/understanding-the-tear-film/the-mucus-layer> [Accessed 03-04-2021].
- [4] University of Iowa. *Tear breakup time (TBUT)*. [Internet] 2021 Available from: <https://webeye.ophth.uiowa.edu/eyeforum/atlas/pages/TBUT/index.htm> [Accessed 14 April 2021].
- [5] Kenny Chan, Tear Film Break Up Time, (2016) Available from: [https://www.youtube.com/watch?v=p91NY\\_CuImY](https://www.youtube.com/watch?v=p91NY_CuImY), (accessed: 27/04/2021)
- [6] Hodges, Robin R, and Darlene A Dartt. "Tear film mucins: front line defenders of the ocular surface; comparison with airway and gastrointestinal tract mucins." *Experimental eye research* vol. 117 (2013): 62-78. doi:10.1016/j.exer.2013.07.027
- [7] TRB Chemedica International. The aqueous layer. [Internet] 2016. Available from: <https://vismed.trbchemedica.co.uk/business-professionals/understanding-the-tear-film/the-aqueous-layer> [Accessed 03-04-2021].
- [8] Dartt, Darlene A. "Neural regulation of lacrimal gland secretory processes: relevance in dry eye diseases." *Progress in retinal and eye research* vol. 28,3 (2009): 155-177. doi:10.1016/j.preteyeres.2009.04.003
- [9] Neil J. Friedman, MD, Peter K. Kaiser, MD and William B. Trattler, MD. *Review of Ophthalmology*, 3rd Edition; 2018 p. 191. ISBN: 9780323390569
- [10] National Research Council (US) Working Group on Contact Lens Use Under Adverse Conditions; Ebert Flattau P, editor. *Considerations in Contact Lens Use Under Adverse Conditions: Proceedings of a Symposium*. Washington (DC): National Academies Press (US); 1991. *Environmental Gases and Contact Lens Wear*. Available from: <https://www.ncbi.nlm.nih.gov/books/NBK234120/>
- [11] Eyedocs. *Schirmer's Test*. [online] 2021 Available from: <https://www.eyedocs.co.uk/ophthalmology-articles/cornea/505-schirmers-test> [Accessed 01-04-2021].
- [12] Brott NR, Ronquillo Y. Schirmer Test. [Updated 2020 Jun 9]. In: StatPearls [Internet]. Treasure Island (FL): StatPearls Publishing; 2021 Jan-. Available from: <https://www.ncbi.nlm.nih.gov/books/NBK559159/>
- [13] Lukasz Cwiklik, Tear film lipid layer: A molecular level view, *Biochimica et Biophysica Acta (BBA) - Biomembranes*, Volume 1858, Issue 10, 2016, Pages 2421-2430, ISSN 0005-2736, <https://doi.org/10.1016/j.bbamem.2016.02.020>.
- [14] Finis D, Schrader S, Geerling G. Meibom-Drüsen-Dysfunktion [Meibomian gland dysfunction]. *Klin Monbl Augenheilkd.* 2012 May;229(5):506-13. German.



doi: 10.1055/s-0031-1299533. Epub 2012 May 16. PMID: 22592341.

s1542-0124(12)70013-7. PMID: 17075649.

[15] Kels BD, Grzybowski A, Grant-Kels JM. Human ocular anatomy. *Clin Dermatol*. 2015 Mar-Apr;33(2):140-146. doi: 10.1016/j.clindermatol.2014.10.006. PMID: 25704934.

[23] Tear flow dynamics in the human nasolacrimal ducts--a pilot study using dynamic magnetic resonance imaging. Amrith S, Goh PS, Wang SC. *Graefes Arch Clin Exp Ophthalmol*. 2005 Feb; 243(2):127-131.

[16] TRB Chemedica International. The lipid layer. [Internet] 2016. Available from: <https://vismed.trbchemedica.co.uk/business-professionals/understanding-the-tear-film/the-lipid-layer> [Accessed 04-04-2021].

[17] Bron AJ, Tiffany JM, Gouveia SM, Yokoi N, Voon LW. Functional aspects of the tear film lipid layer. *Exp Eye Res*. 2004 Mar;78(3):347-360. doi: 10.1016/j.exer.2003.09.019. PMID: 15106912.

[18] Poonam Mudgil; Antimicrobial Role of Human Meibomian Lipids at the Ocular Surface. *Invest. Ophthalmol. Vis. Sci*. 2014;55(11):7272-7277. doi: <https://doi.org/10.1167/iovs.14-15512>.

[19] Yokoi N, Komuro A. Non-invasive methods of assessing the tear film. *Exp Eye Res*. 2004 Mar;78(3):399-407. doi: 10.1016/j.exer.2003.09.020. PMID: 15106919.

[20] Wise, Ryan J et al. "Meibography: A review of techniques and technologies." *Saudi journal of ophthalmology : official journal of the Saudi Ophthalmological Society* vol. 26,4 (2012): 349-356. doi:10.1016/j.sjopt.2012.08.007

[21] Mathers W. Evaporation from the ocular surface. *Exp Eye Res*. 2004 Mar;78(3):389-394. doi: 10.1016/s0014-4835(03)00199-4. PMID: 15106917.

[22] Paulsen FP, Schaudig U, Thale AB. Drainage of tears: impact on the ocular surface and lacrimal system. *Ocul Surf*. 2003 Oct;1(4):180-191. doi: 10.1016/