

We are IntechOpen, the world's leading publisher of Open Access books Built by scientists, for scientists

6,900

Open access books available

186,000

International authors and editors

200M

Downloads

Our authors are among the

154

Countries delivered to

TOP 1%

most cited scientists

12.2%

Contributors from top 500 universities



WEB OF SCIENCE™

Selection of our books indexed in the Book Citation Index
in Web of Science™ Core Collection (BKCI)

Interested in publishing with us?
Contact book.department@intechopen.com

Numbers displayed above are based on latest data collected.
For more information visit www.intechopen.com



Minimally Invasive Approaches in the Thoracic Surgery

Güntüğ Batıhan and Kenan Can Ceylan

Abstract

Minimally invasive techniques in thoracic surgery have made great progress over the past 20 years and are still evolving. Many surgical procedures performed with large thoracotomy incisions in the past can now be performed with much smaller incisions. With many studies, the advantages of minimally invasive surgery have been clearly seen, and thus its use has become widespread worldwide. Today, minimally invasive surgical methods have become the first choice in the diagnosis and treatment of lung, pleural and mediastinal pathologies. Minimally invasive approaches in thoracic surgery include many different techniques and applications. In this chapter, current minimally invasive techniques in thoracic surgery are discussed and important points are emphasized in the light of the current literature.

Keywords: Lobectomy, minimally invasive surgery, robotic surgery, video-assisted thoracic surgery

1. Introduction

Minimally invasive surgical approaches have become widely used in chest surgery as they are applied in every area of medicine. With the use of smaller incisions and modern instruments, patient comfort has increased, and hospital stays have been shortened.

Due to the rigid structure of the thorax, ventilation of the lung, and the presence of large vascular structures in the mediastinum, it has not been easy to adapt minimally invasive methods to thoracic surgery. While initially limited to simple biopsy procedures and wedge resections, nowadays, extended lung resections can be performed with minimally invasive surgery.

Advantages of thoracoscopic lobectomy compared to thoracotomy include less postoperative pain, better pulmonary function, early recovery, shorter hospitalization have shown by many studies, and Video-assisted thoracic surgery (VATS) has become established as a gold standard treatment method for patients with early-stage lung cancer [1–6].

2. Brief history of lung resections

In human history, wars, traumas and infections have created the necessity for surgical interventions and provoked its development. Lung resection performed by Rolandus in a patient with pulmonary herniation due to trauma in 1499 has taken its place as the first case in the literature. Similarly, Nicholas Tulp surgically treated

a patient with herniated lung due to chest trauma. The surgical method he applied was “ligatured it and cut it off with scissors: it weighed three ounces” [7].

Frederik Ruysch (1638–1731) described a case of traumatic lung herniation. He ligated the herniated lung and preformed serial dressing changes until the necrotic lung sloughed off [8].

The first case of resection for a lung tumor was reported in 1861 by Jules Emil Pean. He performed lung resection by suturing the pleura to the lung and, removing it with galvanic current cautery [9].

Lung resections performed until the beginning of the 20th century were based on cutting a portion of the lobe by ligaturing. In 1927 Whittemore presented his exteriorization lobectomy. In this procedure, the lung was firmly sutured to the muscles of the chest wall with deep stitches and the wound closed as tightly as possible. The main logic here is to make the tissue sloughed off by creating gangrene in the part of the lung to be removed [10].

One-staged lobectomy was firstly described by Brunn in 1927. He performed lobectomy in patients with bronchiectasis and used the technique of hilar clamping, ligation, and suturing with phrenicotomy to keep the diaphragm immobile. He also completely closed the pleural cavity and chest wall and used an intercostal catheter for drainage [8, 11, 12].

In the following years, the importance of anatomical dissection of hilar structures was understood and individual ligation and suturing of the anatomical structures were performed in lung resections.

Adapting the innovations in technology to surgical treatment methods started a new era in thoracic surgery.

Lewis et al. reported 100 consecutive VATS lobectomy in 1992. He stapled the hilar structures without individual dissection. The use of this technique has raised suspicion in the surgical community against VATS, and individual isolation and ligation of the hilar structures have continued [13].

The technique of anterior-to-posterior isolation and ligation of the hilar structures was firstly described by McKenna [14]. This approach has been adopted and successfully applied by many surgeons. Even if the port numbers changed, the basic approach remained as the anterior to posterior dissection and division of the hilar structures separately (**Figures 1 and 2**).

Many studies conducted in the following years showed the superiority of VATS over thoracotomy in postoperative pain, drainage time, length of hospital stay and postoperative complications [14–16].

With the increasing experience, many thoracic surgery procedures and advanced lung resections can be successfully performed with VATS today. Although

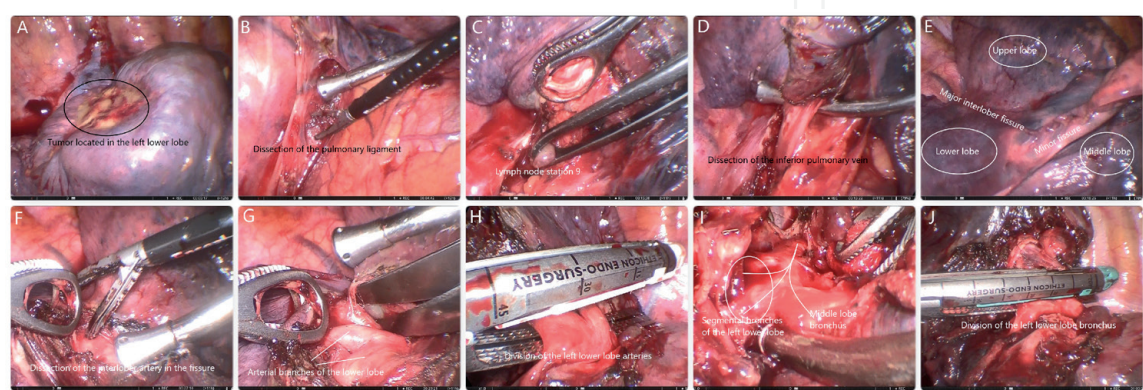


Figure 1. VATS right lower lobectomy was performed for the lung cancer located in the right lower lobe. Intraoperative photographs of important steps were collaged.

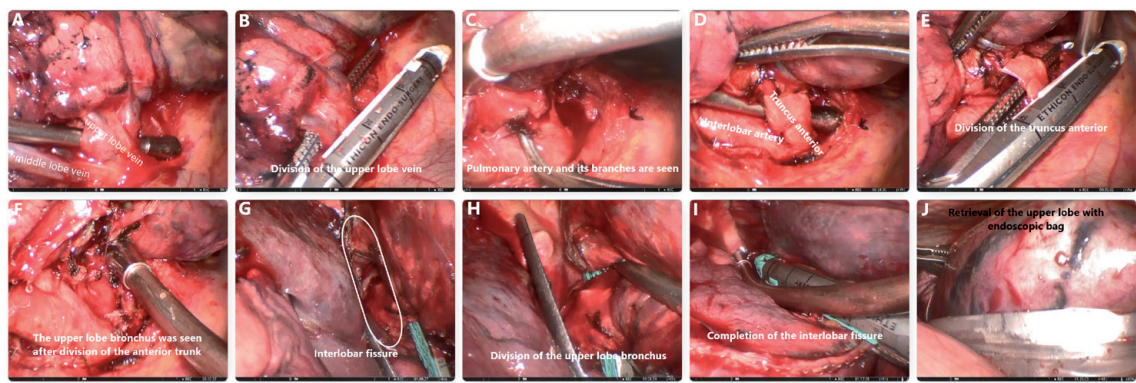


Figure 2.
VATS right upper lobectomy was performed for the lung cancer located in the right upper lobe. Intraoperative photographs of important steps were collaged.

the basic approach remains the same, different techniques have emerged over time in videothoroscopic surgery. Below, we have tried to summarize different approaches under the heading of surgical techniques.

3. Surgical technique

Due to the nature of thoracic surgery, its relationship with anesthesiologists is more advanced than other surgical specialties. The single-lung ventilation, which may be accomplished with either double-lumen endobronchial tubes or with single-lumen tubes and bronchial blockers, is often required. Placement of a thoracic epidural catheter for postoperative pain control is essential. Therefore, the presence of an experienced anesthesiologist is of great importance for the intraoperative and postoperative process to go smoothly.

The patient is positioned in full lateral decubitus position with slight flexion of the table at the level of the mid-chest, which allows slight splaying of the ribs to

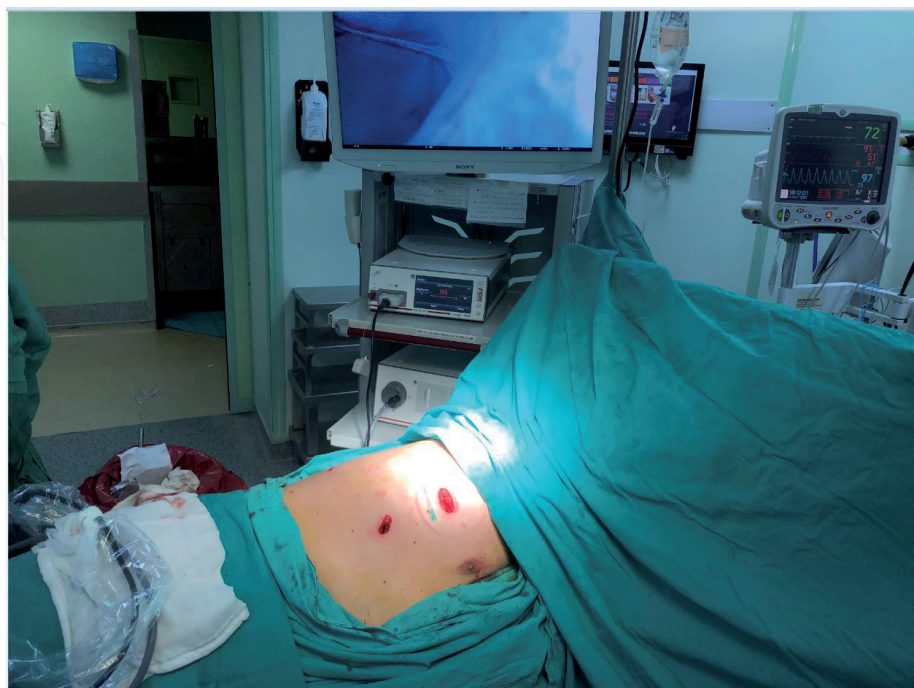

Figure 3.
Patient and camera position during VATS.

improve exposure in the absence of rib spreading. The operator and assistant stand at the front of the patient and the monitor is positioned at the back (**Figure 3**).

Endoscopic instruments like endostaplers, endograspers and dissectors, endoscopic bag and energy devices should be readily available. The number of ports varies depending on the instruments available, the experience of the team and the surgeon's personal preference.

3.1 3-port VATS

In this technique, a 1.5 cm camera port along the midaxillary line is located in the 7th or 8th intercostal space in the midaxillary line. The main access (utility) port was usually placed in the anterior axillary line 4th intercostal space for an upper lobectomy or 5th intercostal space for a lower lobectomy. The posterior port is placed at the level of seventh or eighth intercostal space along the posterior axillary line (**Figure 4**).

The posterior port provides an ideal angle for endoscopic staplers and vascular structures can be divided without difficulty. In addition, when necessary, the camera is moved to the posterior port to make a better exploration and a safe dissection of the hilar structures in the posterior [15, 16].

3.2 2-port VATS

Although there are different variations in this technique in terms of the placement of the camera port, in our clinic, we prefer the middle or anterior axillary

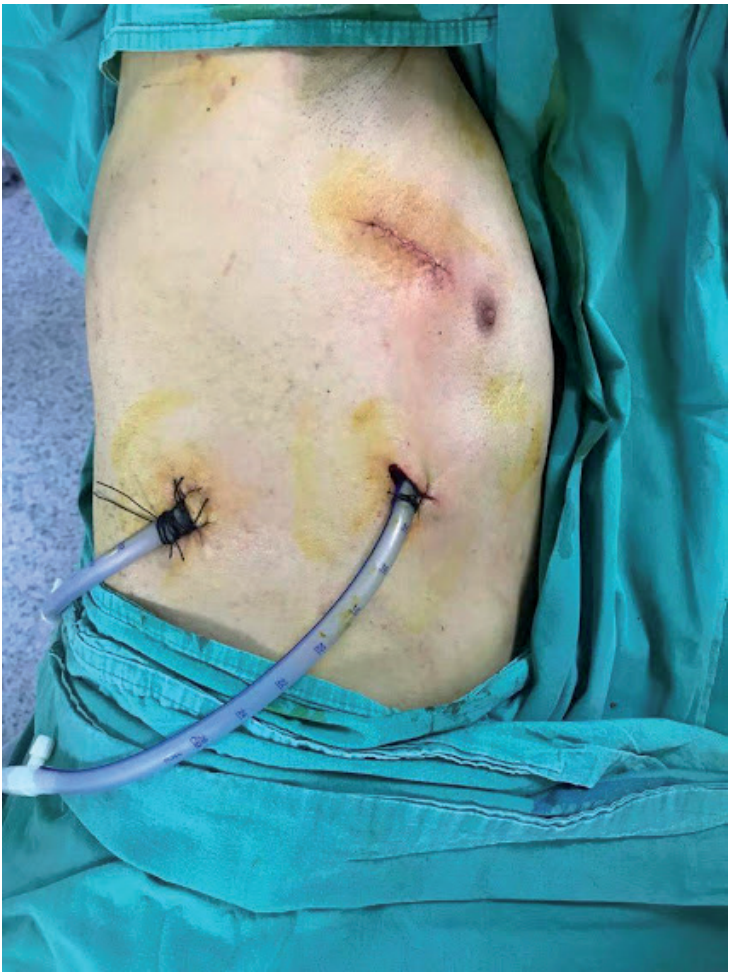

Figure 4.
Incisions in the 3-port VATS technique.

line 7–8. intercostal space. The location of the utility port is similar to the 3-port technique (**Figure 5**).

Due to the lack of a posterior port in this technique appropriate retraction maneuvers must be done to ensure safe dissection. The use of more than one instrument through the anterior port opening to compensate for the absence of the posterior port is not recommended due to the risks of intercostal nerve injury and long-term postoperative pain.

3.3 Uniportal VATS

Surgeons have always been attracted by the notion that surgical procedures can be performed through a single incision. Three-port and bi-portal VATS lobectomy is well established and have been preferred by many thoracic surgeons however with increasing experience, the search for a less invasive technique continued.

Uniportal VATS is firstly described by Dr. Gaetano Rocco in 2004 for minor thoracic procedures include pleural biopsies, sympathectomies, debridements of early-stage empyema. In this study, Rocco stated that wedge resections can be performed successfully as in the classical three-port technique and emphasized the superiority of uniportal surgery [17].

The first uniportal VATS lobectomy was reported by Gonzalez-Rivas in 2011. In the following years, Gonzales demonstrated that even the most complex lung resections can be performed with uniportal VATS successfully and safely. Uniportal VATS has become preferred by many surgeons due to its advantages, such as causing less tissue damage and providing direct vision [18, 19].

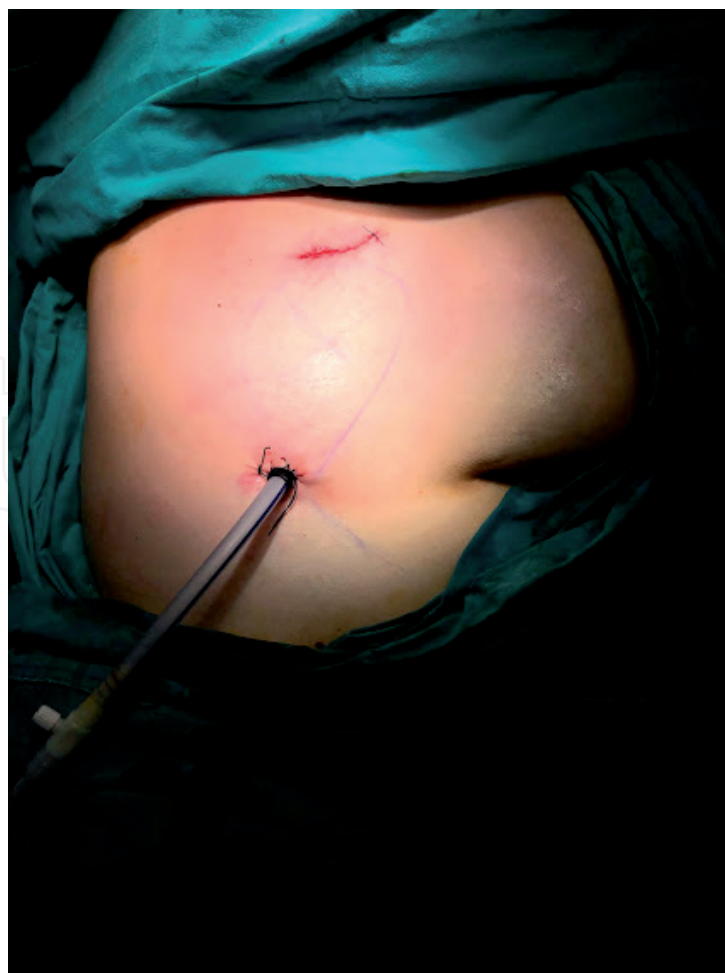

Figure 5.
Incisions in the 2-port VATS technique.

3–5 cm uniport incision is placed in the 5th intercostal in the anterior axillary line. A 5 mm diameter 30° video-thoracoscope is inserted through the same incision. Thus, the assistant and the surgeon share the same vision of direction. Although this is beneficial in terms of team cooperation, the working environment of the surgeon is somewhat limited.

3.4 Needlescopic VATS

As the name suggests, Needlescopic VATS is a minimally invasive surgical procedure performed by keeping port incisions as small as possible. The term of “needlescopic”, which was first defined for laparoscopy, was later used for VATS [20–22]. General acceptance is that port incisions in needlescopic VATS are smaller than 3 mm and therefore, the essentials of this approach are appropriate equipment and instruments. Using this approach, diagnostic procedures, pneumothorax operations and sympathectomies have been successfully performed. This technique can also be used for lung resections by making a utility incision in addition to the needlescopic ports. Ko HJ et al. reported the results of 75 patients who underwent uniportal and needlescopic VATS anatomic resection and defined needlescopic approach as a bridge between multiport and uniportal thoracic surgery [23, 24].

During the past 15 years at our center, approximately 800 patients have undergone VATS lobectomy. Each of the approaches detailed above has been applied in our clinic, and as a result, the 3-port approach has been adopted more heavily. Our experience has shown that the posterior port provides a very suitable angle for hilar dissection and stapler use, and significantly reduces the operation time. In addition, the lung can be retracted with the grasper used from the posterior port and the operator can work with two hands. Whichever approach is used in VATS, the important thing is to complete the learning curve and to expand the patient scale that can benefit from VATS by increasing experience in the approach used.

With the increasing experience, the patient group with a history of locally advanced lung cancer or neoadjuvant therapy can also benefit from minimally invasive surgery and extended lung resections can be performed successfully.

4. Robot-assisted thoracic surgery (RATS)

The adaptation of the robotic system to the thorax has opened new horizons for thoracic surgeons. Features superior to VATS can be summarized as follows [25–27]:

1. Filtration of physiologic hand tremor
2. Ten times magnification and the 3D high definition camera
3. Thanks to the robotic arms that offer articulation it is easier to perform complex surgical maneuvers, comfortable reach to the narrow spaces.
4. By offering the surgeon an ergonomic position, it reduces the risk of muscle fatigue during the operation.

However, despite all these features, its use has not become widespread due to its high cost, long installation and lack of tactile feedback, but undoubtedly, all surgical procedures will evolve towards robotization in the near future.

5. Diagnostic performance of VATS in thoracic pathologies

Minimally invasive surgical methods have become a good alternative for patients who cannot be diagnosed with non-invasive diagnostic methods. VATS is successfully applied for diagnostic purposes in sampling of mediastinal lymph nodes, undiagnosed mediastinal masses, and parenchymal lesions [28–30].

EBUS-TBNA is a safe and feasible procedure for the diagnosis of mediastinal lymph nodes. However, in mediastinal pathologies, especially in cases where large tissue sampling is required, it is not always possible to diagnose with EBUS. VATS is feasible for mediastinal lymph nodes and tumors with a sensitivity of 100%. VATS is an appropriate method for sampling 5th and 6th station lymph nodes in lung cancer staging, which cannot be reached by either EBUS or mediastinoscopy. Contrary to the alternative methods that can be used for sampling the lymph nodes in this region, VATS can be used to evaluate the thoracic cavity and the T factor of the tumor simultaneously.

VATS is a successful method in the diagnosis of parenchymal nodules as well as mediastinal pathologies. Although non-surgical methods include CT-guided percutaneous needle aspiration and transbronchial biopsy are the first choice in the diagnosis of small pulmonary nodules, the success rate of these methods is low in lesions below 1 cm and subsolid nodules.

Although it is a safe and feasible method, it can be difficult to detect small and subsolid nodules with VATS because of the lack of tactile feedback and of bimanual palpation. Various pre-operative and perioperative marking techniques were described in the literature to facilitate intraoperative detection of small-sized or subsolid nodules [30–32].

Methylene blue, metal wire, micro coil or Technetium-99 can be used for marking the parenchymal nodules [30–33]. Because it is effective, easy to apply and inexpensive, we prefer preoperative CT-guided injection of methylene blue to marking the pulmonary nodules in our clinic. However, an experienced interventional radiologist who has good communication with the surgical team is required for the successful application of this technique.

6. VATS resection in the treatment of lung cancer

The application of VATS lobectomy in the surgical treatment of lung cancer has a history of approximately 30 years. Lewis et al. published the first VATS lobectomy series in the literature, involving 3 patients with lung cancer in 1992. [13]. In 1999, a series of 400 cases were published by the same author [34]. However, the surgical technique used in these studies was far from the modern VATS lobectomy, which involves the dissection of hilar structures separately.

McKenna Jr. described the first VATS lobectomy that forms the basis of today's practice, which includes anatomic dissections with individual ligation of the vessels and bronchi. He and his colleagues reported 1100 cases with NSCLC who underwent VATS lobectomy [14]. Many studies demonstrating the superiority of VATS over thoracotomy followed this study, which presented a short hospital stay, low mortality and morbidity rates.

In the following years, uniportal VATS lobectomy was described by Gonzalez-Rivas. He presented the results of 102 patients who underwent uniportal VATS lobectomy in 2013. In this study mean surgical time was 154.1 ± 46 minutes and the median duration time of a chest tube was 2 days and the median length of hospital stay was 3 days [18, 19]. In the following years, Gonzales Rivas shared his experiences showing that the uniportal approach can also be used successfully

in extended lung resections include bronchial sleeve, vascular sleeve, or double sleeve resections [35].

As discussed, the postoperative results of VATS compared to open lobectomy have been confirmed in the various studies. Inexperienced centers, VATS lobectomy is successfully applied not only in the early stage but also in the surgical treatment of locally advanced lung cancer.

7. Conclusions

Minimally invasive surgical approaches have become the preferred choice in many diagnostic and therapeutic surgical interventions in today’s thoracic surgery.

However, patient safety should always be prioritized in the selection of the surgical method. Intraoperative complications, especially for major lung resections, carry a high risk of morbidity and mortality. Therefore, it is very important for the surgeon to complete the learning curve in minimally invasive surgery.

It is an indisputable fact that technology directly affects surgical techniques and equipment therefore, as long as technological developments continue, minimally invasive approaches will keep up its evolution.

Conflict of interest

The authors declare no conflict of interest.

Acronyms and abbreviations

CT	Computed tomography
EBUS	Endobronchial ultrasound
EUS	Endoscopic ultrasound
MRI	Magnetic resonance imaging
NSCLC	Non-small cell lung cancer
PET	Positron emission tomography
VATS	Video-assisted thoracic surgery

Author details

Güntuğ Batıhan* and Kenan Can Ceylan
University of Health Sciences Turkey, Dr. Suat Seren Chest Diseases and Chest Surgery Training and Research Center, İzmir, Turkey

*Address all correspondence to: gbatihan@hotmail.com

IntechOpen

© 2021 The Author(s). Licensee IntechOpen. This chapter is distributed under the terms of the Creative Commons Attribution License (<http://creativecommons.org/licenses/by/3.0>), which permits unrestricted use, distribution, and reproduction in any medium, provided the original work is properly cited. 

References

- [1] Reddy RV. The advantages of VATS: a systematic review. *Thorax* 2005;60:238.
- [2] Villamizar NR, Darrabie MD, Burfeind WR, et al. Thoracoscopic lobectomy is associated with lower morbidity compared with thoracotomy. *J Thorac Cardiovasc Surg* 2009;138: 419-25.
- [3] Paul S, Altorki NK, Sheng S, et al. Thoracoscopic lobectomy is associated with lower morbidity than open lobectomy: a propensity-matched analysis from the STS database. *J Thorac Cardiovasc Surg* 2010;139:366-78.
- [4] Petersen RP, Pham D, Burfeind WR, et al. Thoracoscopic lobectomy facilitates the delivery of chemotherapy after resection for lung cancer. *Ann Thorac Surg* 2007;83:1245-9; discussion 1250.
- [5] Swanson SJ, Meyers BF, Gunnarsson CL, et al. Video-assisted thoracoscopic lobectomy is less costly and morbid than open lobectomy: a retrospective multiinstitutional database analysis. *Ann Thorac Surg* 2012;93:1027-32.
- [6] Ng CS, Whelan RL, Lacy AM, et al. Is minimal access surgery for cancer associated with immunologic benefits? *World J Surg* 2005;29:975-81.
- [7] Paget S. The surgery of the chest. Bristol, England: John Wright & Co.; 1896.
- [8] Kittle CF. The history of lobectomy and segmentectomy including sleeve resection. *Chest Surg Clin N Am* 2000;10:105-130.
- [9] Chang JHAPTSENMaTANYs-VBH, 1991. 25-29. Print.
- [10] Whittemore W. The treatment of such cases of chronic suppurative bronchiectasis as are limited to one lobe of the lung. *Ann Surg* 1927;86:219-226.
- [11] Smith A. Development of lung surgery in the United Kingdom. *Thorax* 1982;37:161-168.
- [12] Nissen R. Development of total pneumonectomy. *Am J Surg* 1949;78:816-820.
- [13] Lewis RJ, Caccavale RJ, Sisler GE, et al. One hundred consecutive patients undergoing video-assisted thoracic operations. *Ann Thorac Surg* 1992;54: 421-426.
- [14] McKenna RJ. Lobectomy by video-assisted thoracic surgery with mediastinal node sampling for lung cancer. *J Thorac Cardiovasc Surg* 1994;107:879-882.
- [15] Sihoe AD, Yim AP. Video-assisted pulmonary resections. In: Patterson FG, Cooper JD, Deslauriers J. eds. *Thoracic Surgery* (3rd Edition). Philadelphia: Elsevier, 2008:970-88.
- [16] Sihoe AD. The Evolution of VATS Lobectomy. In: Cardoso P. eds. *Topics in Thoracic Surgery*. Rijeka: Intech, 2011:181-210.
- [17] Rocco G, Khalil M, Jutley R. Uniportal video-assisted thoracoscopic surgery wedge lung biopsy in the diagnosis of interstitial lung diseases. *J Thorac Cardiovasc Surg* 2005;129: 947-8.
- [18] Gonzalez D, Paradela M, Garcia J, et al. Single-port video-assisted thoracoscopic lobectomy. *Interact Cardiovasc Thorac Surg* 2011;12:514-5.
- [19] Gonzalez-Rivas D, Paradela M, Fernandez R, et al. Uniportal video-assisted thoracoscopic lobectomy: two years of experience. *Ann Thorac Surg* 2013;95:426-32.

- [20] Sihoe AD, Hsin MK, Yu PS. Needlescopic video-assisted thoracic surgery pleurodesis for primary pneumothorax. *Multimed Man Cardiothorac Surg*. 2014 Jun 25;2014:mmu012.
- [21] Kim TS, Kim KH, An CH, Kim JS. Single center experiences of needlescopic grasper assisted single incision laparoscopic cholecystectomy for gallbladder benign disease: comparison with conventional 3-port laparoscopic cholecystectomy. *Ann Surg Treat Res*. 2016;91:233-8.
- [22] Inoue S, Kajiwarra M, Teishima J, Matsubara A. Needlescopic assisted laparoendoscopic single-site adrenalectomy. *Asian J Surg*. 2016;39:6-11.
- [23] Chen JS, Hsu HH, Kuo SW, Tsai PR, Chen RJ, Lee JM, Lee YC. Needlescopic versus conventional video-assisted thoracic surgery for primary spontaneous pneumothorax: a comparative study. *Ann Thorac Surg*. 2003 Apr;75(4):1080-5.
- [24] Ko HJ, Chiang XH, Yang SM, Yang MC. Needlescopic-assisted thoracoscopic pulmonary anatomical lobectomy and segmentectomy for lung cancer: a bridge between multiportal and uniportal thoracoscopic surgery. *Surg Today*. 2019 Jan;49(1):49-55.
- [25] Augustin F, Bodner J. Robotic-assisted thoracic surgery: a helpful tool or just another expensive gadget? *J Thorac Dis* 2017;9(9):2881-2883.
- [26] Veronesi G. Robotic surgery for the treatment of early-stage lung cancer. *Curr Opin Oncol* 2013;25:107-14.
- [27] Augustin F, Bodner J, Maier H, et al. Robotic-assisted minimally invasive vs. thoracoscopic lung lobectomy: comparison of perioperative results in a learning curve setting. *Langenbecks Arch Surg* 2013;398:895-901.
- [28] Howington JA. The role of VATS for staging and diagnosis in patients with non-small cell lung cancer. *Semin Thorac Cardiovasc Surg*. 2007 Fall;19(3):212-6. doi: 10.1053/j.semtcvs.2007.07.007.
- [29] Simon C. Y. Chow, Calvin S. H. Ng. Recent developments in video-assisted thoracoscopic surgery for pulmonary nodule management. *J Thorac Dis* 2016;8(Suppl 6):S509-S516
- [30] Chang AC, Yee J, Orringer MB, Iannettoni MD. Diagnostic thoracoscopic lung biopsy: an outpatient experience. *Ann Thorac Surg*. 2002 Dec;74(6):1942-6; discussion 1946-7.
- [31] Ciriaco P, Negri G, Puglisi A, Nicoletti R, Del Maschio A, Zannini P. Video-assisted thoracoscopic surgery for pulmonary nodules: rationale for preoperative computed tomography-guided hookwire localization. *Eur J Cardiothorac Surg*. 2004 Mar;25(3):429-33.
- [32] Lenglinger FX, Schwarz CD, Artmann W. Localization of pulmonary nodules before thoracoscopic surgery: value of percutaneous staining with methylene blue. *AJR Am J Roentgenol*. 1994 Aug;163(2):297-300.
- [33] Martins FK, Oliveira GA, da Silva TK, Bello RM, Coelho JC, Gelatti A, Lewgoy J, Pasa MB. Nodule marking strategies: cost-benefit. *J Vis Surg* 2018;4:220
- [34] Lewis RJ, Caccavale RJ, Bocage JP, Widmann MD. Video-assisted thoracic surgical non-rib spreading simultaneously stapled lobectomy: a more patient-friendly oncologic resection. *Chest*. 1999 Oct;116(4):1119-24.
- [35] Gonzalez-Rivas D, Fieira E, Delgado M, de la Torre M, Mendez L, Fernandez R. Uniportal video-assisted thoracoscopic sleeve lobectomy and other complex resections. *J Thorac Dis*. 2014;6(Suppl 6):S674-S681.