

We are IntechOpen, the world's leading publisher of Open Access books Built by scientists, for scientists

6,900

Open access books available

186,000

International authors and editors

200M

Downloads

Our authors are among the

154

Countries delivered to

TOP 1%

most cited scientists

12.2%

Contributors from top 500 universities



WEB OF SCIENCE™

Selection of our books indexed in the Book Citation Index
in Web of Science™ Core Collection (BKCI)

Interested in publishing with us?
Contact book.department@intechopen.com

Numbers displayed above are based on latest data collected.
For more information visit www.intechopen.com



Robotic Myomectomy: Until Achieving Reproductive Success, Step by Step

Radamés Rivas López

Abstract

Surgeons who practice robotic surgery in benign gynecological conditions agree that in some cases, blood loss and transfusions are reduced, the time of hospital stay and of reintegration to daily activities is less, although commonly in the first cases of each surgeon surgical time may be longer than laparoscopic surgery depending on the learning curve of each. As in any other surgical technique, it is important that the surgeon is trained and certified in accordance with the guidelines that each hospital institution indicates for the practice of robotic surgery and is constantly updated through the tools provided by robotic surgery to ensure the correct use of this technology and always maintain the skill looking for the safety of the patient at all times. Uterine fibroids, are the most common benign tumors that appear in women of reproductive age. Depending on their location, number and size, the symptoms they produce vary in frequency and severity. Robotic myomectomy has shown that with a surgical team that operates frequently, it is superior to conventional laparoscopic myomectomy, even in the area of cost/benefit. Robotic myomectomy is an accessible, efficient and flattering pathway for patients with fibroids who want a pregnancy.

Keywords: leiomyoma, robotic surgery, myomectomy, infertility, myoma, fibroids, fertility

1. Introduction

Minimally invasive surgery is at the forefront of technology and robotic surgery is part of this new development.

This review includes the main gynecological surgeries that greatly benefit from the use of this robotic technology, such as: hysterectomy, myomectomy, tubal recanalization, sacrocolpopexy, endometriosis, and transabdominal cerclage.

Likewise, the advantages and disadvantages of this technology are analyzed, as well as the influence of the type of training and learning curve for this type of surgical approach.

Laparoscopic surgery has evolved rapidly in various specialties, in the area of gynecology, robot-assisted surgery is used in different procedures, mainly in hysterectomy for benign diseases and myomectomy, also in cases of tubal recanalization, lymphadenectomy, endometriosis and sacrocolpopexy.

Robot-assisted surgery managed to develop technical advances that surpass laparoscopic surgery such as:

Vision in third dimension (3D)

High visual definition on the console

Movements of the forceps similar to those of the doctor's hand

Better ergonomic position during surgery that avoids fatigue.

Surgeons who practice robotic surgery in benign gynecological conditions agree that in some cases, blood loss and transfusions are reduced, the time of hospital stay and of reintegration to daily activities is less, although commonly in the first cases of each surgeon surgical time may be longer than laparoscopic surgery depending on the learning curve of each.

There are different opinions regarding the advantages and disadvantages that robotic surgery offers vs. laparoscopic surgery in benign gynecological conditions, which is why the advantages of this system and/or surgical approach should be known as in any other type of surgery, as well as the potential risks inherent in all surgery and notify the patient through an informed consent before the intervention.

As in any other surgical technique, it is important that the surgeon is trained and certified in accordance with the guidelines that each hospital institution indicates for the practice of robotic surgery and is constantly updated through the tools provided by robotic surgery to ensure the correct use of this technology and always maintain the skill looking for the safety of the patient at all times.

2. Fundamental principles to consider

Uterine fibroids, also known as fibroids or leiomyomas, are the most common benign tumors that appear in women of reproductive age. Depending on their location, number and size, the symptoms they produce vary in frequency and severity. There is scientific evidence that fibroids interfere with sperm migration, oocyte transport and embryo implantation due to endometrial inflammation or vascular alterations that they produce. Approximately 5 to 10% of infertile women have fibroids and their presence is the only abnormal factor found in up to 4% of them [1]. At present, in women of reproductive age with gestational desire and presence of fibroids, myomectomy is probably the treatment of choice.

Technology continues to evolve and expand conservative treatment options for women who desire fertility preservation. There are some techniques for this, such as: uterine artery embolization, high-frequency ultrasound guided by magnetic resonance imaging, and radiofrequency ablation. However, myomectomy remains the gold standard for women with infertility who suffer from uterine myomatosis and wish to become pregnant later [2].

The relationship between fibroids and fertility continues to be debated, especially with regard to intramural fibroids. It is generally accepted that submucosal fibroids decrease fertility and that subserous fibroids have little or no influence in this regard [3]. However, according to some reports, intramural fibroids that do not affect the cavity are also associated with unfavorable reproductive outcomes. Analysis of prospective and retrospective studies shows that intramural fibroids that do not distort the cavity have a significant adverse effect on live birth rates in women undergoing in vitro fertilization [4].

The impact of intramural fibroids that do not distort the endometrial cavity has been a point of constant controversy, especially when choosing the most appropriate therapeutic strategy, and as occurred in our study, intramural fibroids were the ones that were found more frequently in patients, without However, it is important to take into account the live birth rate and not only the postoperative pregnancy rate, since fibroids can be associated with an unfavorable obstetric outcome.

A meta-analysis carried out by Sunkara and Rikhrad years later indicated that the presence of intramural fibroids that do not distort the cavity is associated with an adverse outcome in women undergoing treatment of In Vitro Fertilization (IVF), it is mentioned that the live newborn rate in patients with fibroids is 21% lower than in women without fibroids [3, 4].

Those intramural fibroids that do not affect the cavity, the size of the same is still a point of debate, it is generally taken as a cut-off point for myomectomy those intramural fibroids that do not affect the cavity but are greater than or equal to 4 cm [5, 6]. As occurred in our group of patients, all intramural fibroids were at least 4 or more centimeters tall. In these cases, the route of choice for the surgical approach is preferably by minimally invasive surgery.

The surgical route of choice depends on two fundamental factors: the fibroid itself, its location, its number, size and the experience of the surgical team. Submucosal fibroids are treated hysteroscopically, while intramural and subserous fibroids can be treated laparoscopically, robotically, abdominally, or vaginally. Whenever possible, the route of choice should be through minimal access surgery, since there is a solid scientific basis in which it is shown that with the robotic laparoscopic, conventional laparoscopic or vaginal approach, there is less intraoperative blood loss, a lower rate of adhesions, less postoperative morbidity, and fewer days of hospitalization than with open myomectomy [7]. It should be noted that a recent study reported a faster return of patients to their work and/or daily activities after a myomectomy for minimally invasive surgery [8].

In this same sense, robotic myomectomy has shown that with a surgical team that operates frequently, it is superior to conventional laparoscopic myomectomy, even in the area of cost/benefit [9]. And it is that if you have a team made up of anesthesiologists, surgeons, nurses and doctors who regularly perform this type of robotic approach, efficiency, economy, shorter surgical times are achieved and the results are effective and at a reasonable cost. Even as Wu mentions, more studies are needed to determine which patients would benefit greatly from a robotic approach, both in terms of patient outcomes and cost-effectiveness [10].

Takmaz et al. It compared symptom severity and health quality outcomes for women who underwent laparoscopic and robotic myomectomy. Finding that both laparoscopic and robotic myomectomy provides significant reductions in the severity of fibroid-associated symptoms and a significant improvement in quality of life 1 year after surgery. The rate of improvement was comparable for both procedures [11].

However despite the evidence that minimally invasive surgery is preferable to laparotomy, most myomectomies are still performed by laparotomy. Robotic surgery was introduced to eliminate or improve some of the difficulties associated with laparoscopic surgery. We know that a myomectomy is a surgery that requires suturing in several planes, in different directions and with different cancellations, where it was planned that the characteristics of a surgical robot that would help to carry out this work would be of great value. Robotic myomectomy has now been shown to be efficient and safe by a vast bibliography, its results are similar to laparoscopic surgery, although the robotic procedure is associated with a higher cost. The introduction of robotic surgery has expanded the indications for minimally invasive myomectomy to more complex cases that were previously performed using laparotomy. Despite everything, and as Lonnerfors points out, no randomized, prospective and controlled trials have been published that compare the different approaches to a myomectomy in order to make an analysis and from there derive the best recommendations based on the evidence [12].

There are two meta-analyses that can be cited, the first by Lavazzo et al. The premise was to demonstrate that robot-assisted myomectomy was an equally safe and effective treatment option as laparoscopy and open surgery for uterine

myomatosis. It was found that regarding the comparison between the robotic and laparoscopic technique, no significant differences were found between both types of surgery. Concluding that the minimally invasive approach has the advantage of less blood loss, less need for transfusion and shorter hospital stay. Suggesting that long-term outcomes required clarification, including pain control, fertility, and postoperative pregnancy rates, as well as possible recurrence rates [13].

Two years later, Wang et al. They carried out a new meta-analysis on our subject and concluded that compared to the laparoscopic and abdominal approaches, robotic surgery is significantly associated with: lower indices of complications, lower conversion rate of the procedure and less operative bleeding [14].

The results in functional terms after performing a myomectomy by any approach is to achieve the birth of a healthy baby. In Mexico, the first successful report on a robot-assisted myomectomy was made by our surgical team [14]. However, in this area there are not such drastic conclusions about the approach in favor of one or another technique according to the superiority of its reproductive results and the absence of randomized studies that compare the different surgical approaches in this regard. However Jayakumaran in a comparative analysis of the role of robot-assisted laparoscopy in the field of reproductive surgery the reported advantages and limitations of the use of robotics in reproductive surgeries such as myomectomy, among others. He found that robotic assistance in reproductive surgery presented decreased blood loss, less postoperative pain, a shorter hospital stay, and a faster convalescence, while reproductive outcomes were similar in the other approaches. He likewise found that robotic surgery was as safe and effective as conventional laparoscopy, representing a totally reasonable alternative to the abdominal approach. He suggesting that procedures that are technically challenging with the Conventional laparoscopy could be performed with robotic assistance due to its advantages of better visualization and Endowrist™ movements (similar to the wrist of the human hand) that allow for precise suturing. This helps to overcome the limitations of laparoscopy, especially in complicated procedures, and can shorten the learning curve of minimally invasive surgery. Thus justifying the controlled and randomized studies that compare the short and long-term results to strengthen the role of robotic surgery in the field of reproductive surgery [15].

Regarding efficiency with good results, fundamental characteristics in surgical procedures, there is the question that up to what number of fibroids would it be possible to remove by minimally invasive surgery?(16), particularly in robotic surgery. Kim et al. They demonstrated that it is feasible to perform a robotic myomectomy in patients with up to 20 fibroids, preserving efficiency and good postoperative results, being even a faster procedure than the open myomectomy with which it was compared in the study [16, 17].

3. Robotic myomectomy: step by step

The first step is to have a good imaging diagnosis, with magnetic resonance imaging the ideal study at this time for this as shown in **Figure 1**. This must be interpreted correctly by the surgeon, since it is the GPS to achieve success in terms of removing the number of fibroids and planning the hysterotomy.

The second step is planning regarding the configuration of robotic ports for successful intraoperative development, taking into account the following philosophy:

In robotic myomectomy, if the objective is below the umbilical scar, we can place the robotic lens at the umbilical level. But if the objective is at the umbilical level or above it, then we need an adequate working distance of between 7 and 10 cm, depending on the case to be able to develop our work well and then the lens must be at that distance level as shown in **Figure 2**.

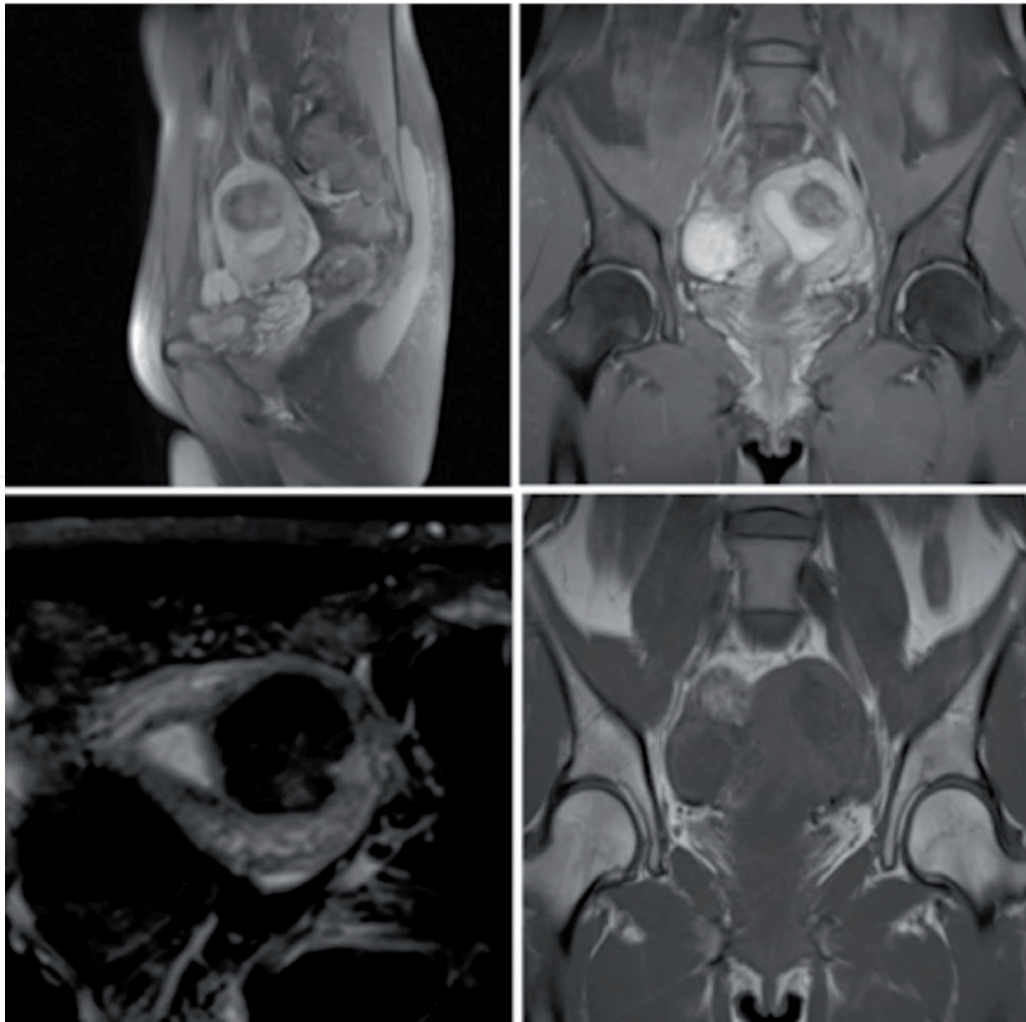


Figure 1.
Protocol magnetic resonance imaging for fibroids localization.

Finally the development of the surgery step by step is as follows:

1. Infiltration of the myometrium with dilute vasopressin. As shown in **Figure 3**.
2. Incision of the myometrium with scissors or monopolar hook in arm 1 using the monopolar energy judiciously and without excess (maximum 35 Watts). As shown in **Figure 4**.
3. Traction and countertraction technique until complete enucleation of the myoma, using a tenaculum for greater efficiency. As shown in **Figure 5**.
4. The myometrium is observed and the intact endometrial dome is observed in the center, and we do not recommend using it as much as possible as it dries and necrotic the myometrial tissue. As shown in **Figure 6**.
5. The closure of the myometrium is in three planes with preferably barbed suture that reduces operative times and reduces bleeding. As shown in **Figure 7**.
6. After the repaired uterus, hemostasis is verified. As shown in **Figure 8**.
7. At the end of the uterine suture, the robot was undocked and the fibroid was extracted by using of contained electrical or not electric morcellation. As shown in **Figure 9**.

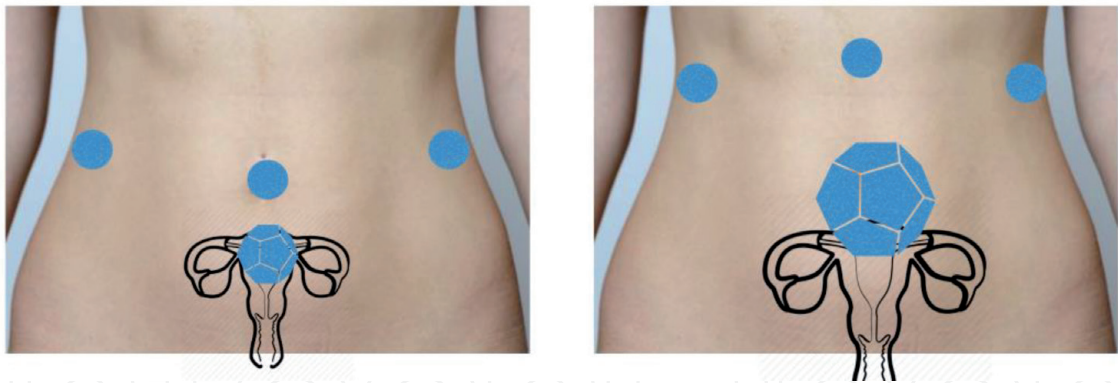


Figure 2.
Port placement configuration.

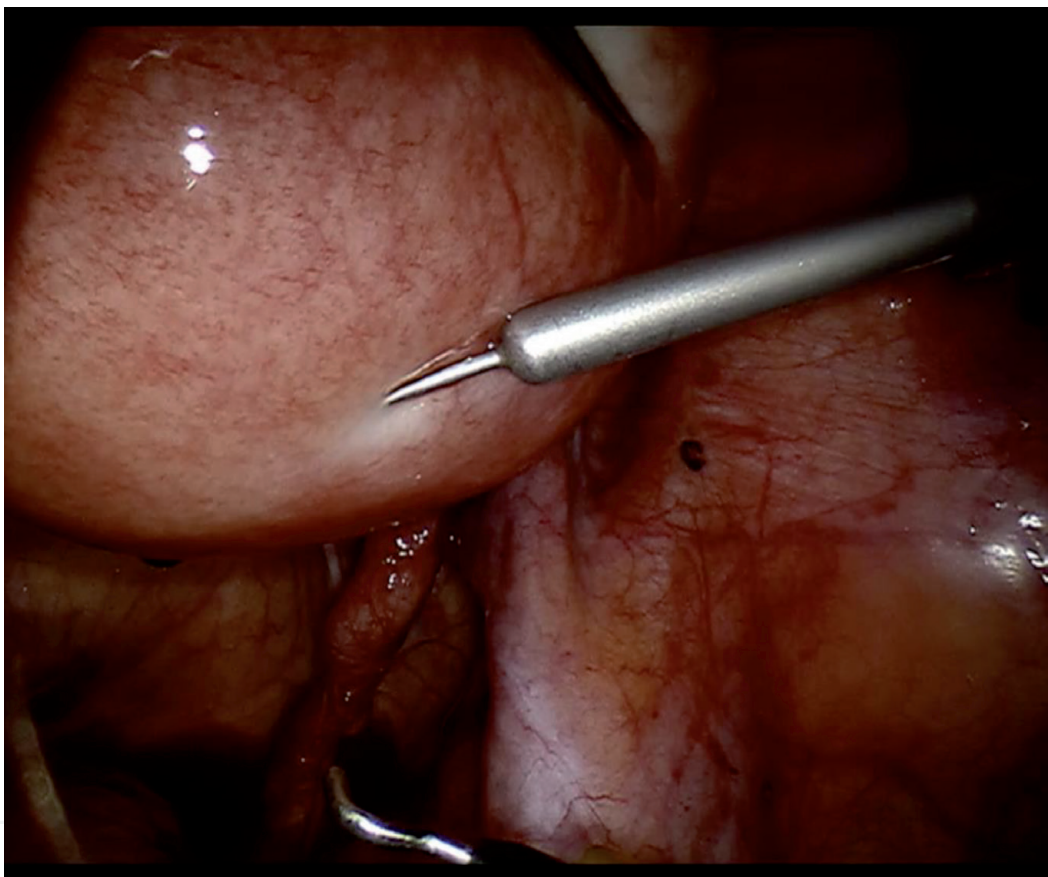


Figure 3.
Infiltration of the myometrium.

In our country there has been a good acceptance for the use of this platform in cases of myomectomies including the birth at the end of babies without the fear of a major complication such as uterine rupture. Thus showing that robotic myomectomy is an accessible, efficient and flattering pathway for patients with fibroids who want a pregnancy.

We must point out that our group performs robotic myomectomies with only two arms apart from the robot chamber, and we believe that it is essential to maintain a controlled cost in the operative processes without skimping on good results. The vast majority of the aforementioned and currently available studies have performed robotic-assisted laparoscopic myomectomies with four arms, that is, a central port for the camera and three robotic ports plus the necessary accessories, which is usually at least one. More. That gives you certain operative advantages but in most cases few cosmetic advantages and if it is to invade as little as possible

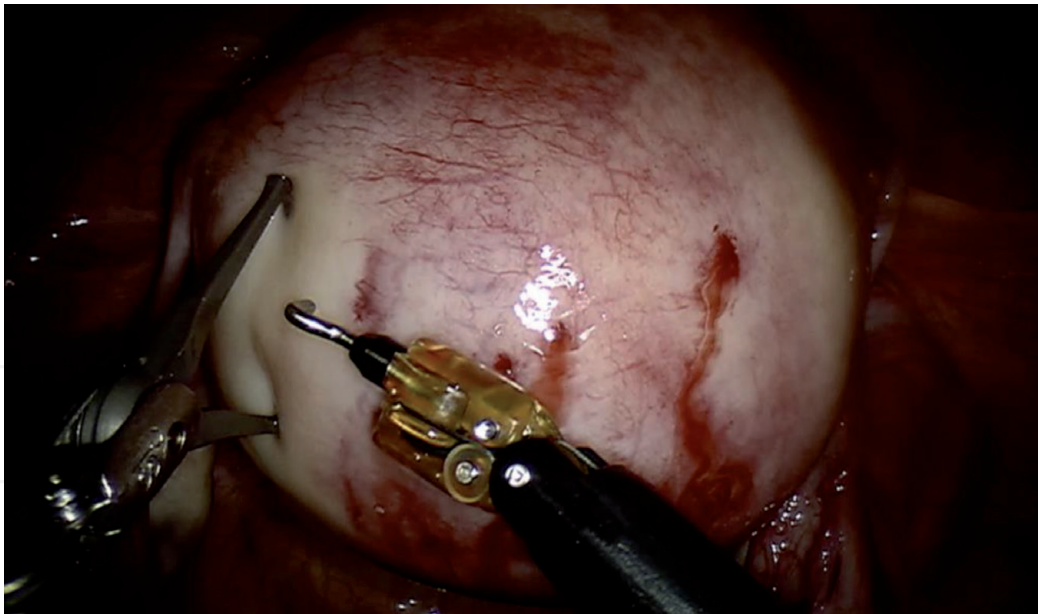


Figure 4.
Incision of the myometrium.

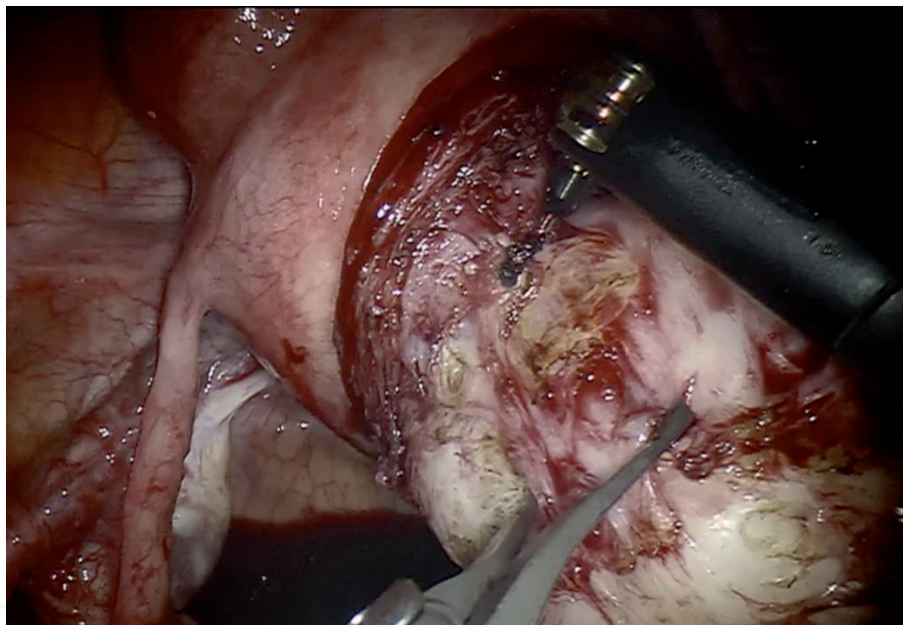


Figure 5.
Myoma enucleation.

it would be prudent to use as few ports as possible. This challenges even more any surgical plan, but provides greater esthetics, less invasion with cost containment for the benefit of all, patient, hospital and third-party payers if applicable, which is in the end what is sought, good results with minimal access.

Finally we do the following historical reflection:

1. A robot must not harm a human being or, because of its inaction, let a human being suffer harm.
2. A robot must obey orders given by a human being, except when these orders are in opposition to the first law.
3. A robot must protect its own existence, until this protection is not in conflict with the first or second laws.

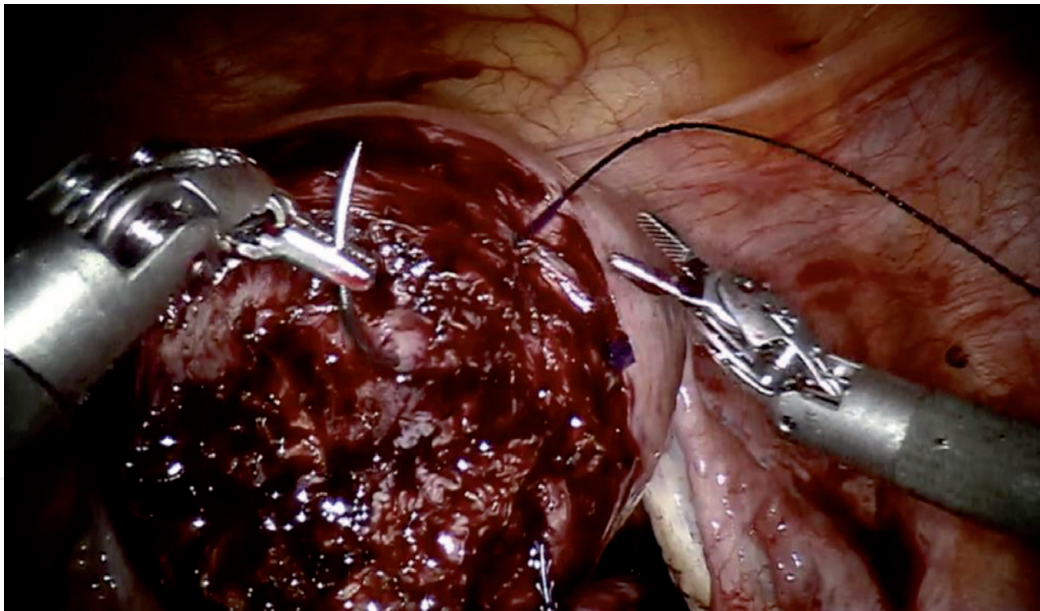


Figure 6.
Intact endometrial dome and less use of energy.

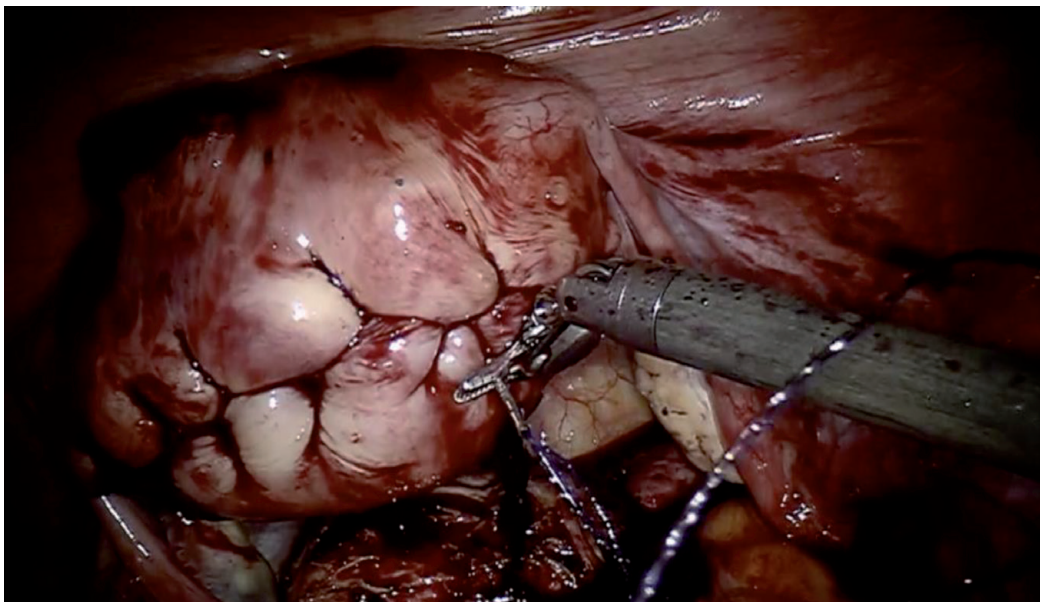


Figure 7.
Total myometrium closure.

The above is an excerpt from Isaac Asimov's futuristic novel: *Me, a robot* written in 1950 and showing how human beings have always maintained a special interest in the robotic theme [18]. What awaits us in the future? we will know soon.

4. Conclusion

Technology continues to evolve and expand conservative treatment options for women who desire fertility preservation. Whenever possible, the route of choice should be through minimal access surgery, since there is a solid scientific basis in which it is shown that with the robotic laparoscopic there is less intraoperative blood loss, a lower rate of adhesions, less postoperative morbidity, fewer days of hospitalization and a faster return of patients to their work and/or daily activities.

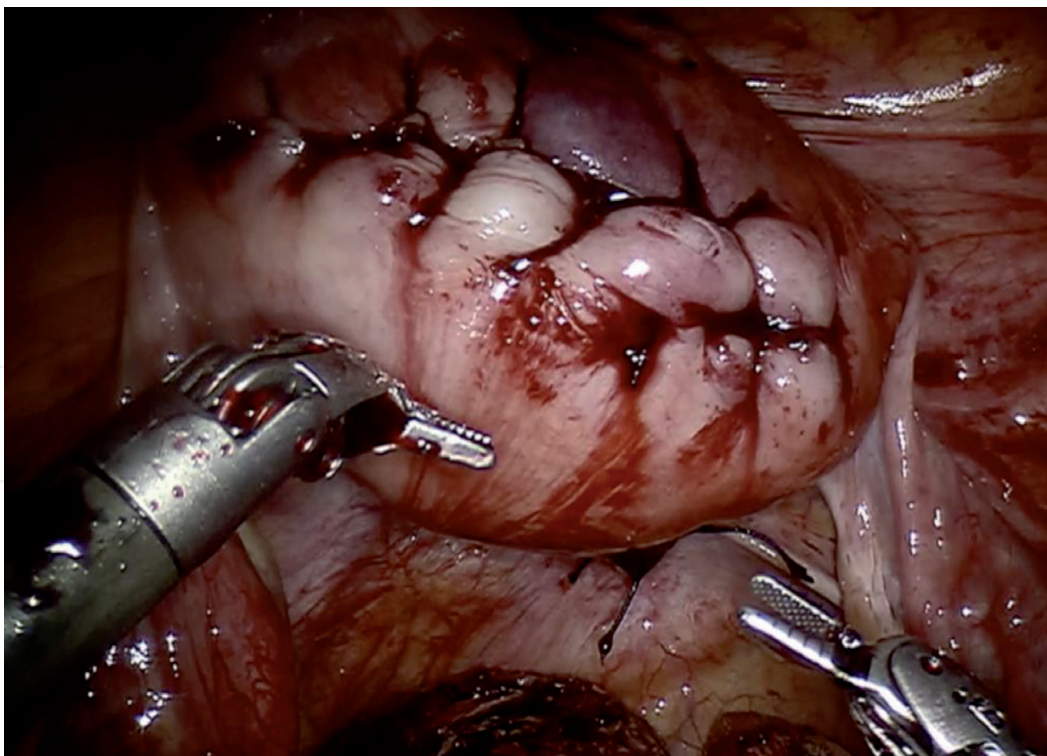


Figure 8.
Verify hemostasis.

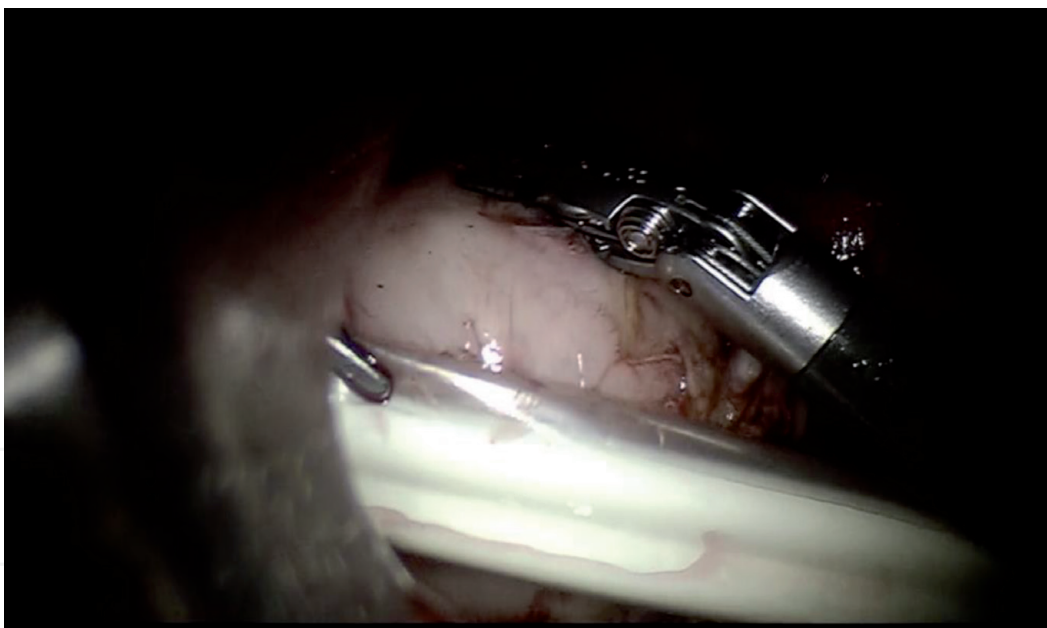


Figure 9.
Contained morcelation.

IntechOpen

IntechOpen

Author details

Radamés Rivas López

The Mexican Association of Robotic Surgery and Center of Robotic Surgery,
Reproductive Medicine Women's Clinic Ángeles Pedregal Hospital,
México City, México

*Address all correspondence to: radamesrl@hotmail.com

IntechOpen

© 2021 The Author(s). Licensee IntechOpen. This chapter is distributed under the terms of the Creative Commons Attribution License (<http://creativecommons.org/licenses/by/3.0>), which permits unrestricted use, distribution, and reproduction in any medium, provided the original work is properly cited. 

References

- [1] Khaund A, Lumsden MA. Impact of fibroids on reproductive function. *Best Pract Res Clin Obstet Gynaecol* 2008;22(4): 749e60.
- [2] Gobern JM, Rosemeyer CJ, Barter JF, Steren AJ. Comparison of robotic, laparoscopic, and abdominal myomectomy in a community hospital. *JSLs*. 2013;17(1):116-120.
- [3] Cook H, Ezzati M, Segars JH, et al. The impact of uterine leiomyomas on reproductive outcomes. *Minerva Ginecol* 2010 Jun;62(3):225e36.
- [4] Sunkara SK, Khairy M, El-Toukhy T, et al. The effect of intramural fibroids without uterine cavity involvement on the outcome of IVF treatment: a systematic review and meta-analysis. *Hum Reprod* 2010;25:418e29.
- [5] Rikhray K, Tan J, Taskin O, Albert AY, Yong P, Bedaiwy MA. The Impact of Noncavity-Distorting Intramural Fibroids on Live Birth Rate in *In Vitro* Fertilization Cycles: A Systematic Review and Meta-Analysis. *J Womens Health (Larchmt)*. 2020;29(2): 210-219.
- [6] Pritts EA, ParkerWH, Olive DL. Fibroids and infertility: and updated systematic review of the evidence. *Fertil Steril* 2009; 91:1215-1223
- [7] Galliano D, Bellver J, Días-García C, simón C, pedllicer A. ART and uterine pathology: how relevant is the maternal side for implantation? *Hum Repd Update* 2015; 21 (1):13-38
- [8] Gingold JA, Gueye NA, Falcone T. Minimally Invasive Approaches to Myoma Management. *J Minim Invasive Gynecol*. 2018;25(2):237-250.
- [9] Laughlin-Tommaso SK, Lu D, Thomas L, et al. Short-term quality of life after myomectomy for uterine fibroids from the COMPARE-UF Fibroid Registry. *Am J Obstet Gynecol*. 2020;222(4):345.e1-345.e22.
- [10] Wu CZ, Klebanoff JS, Tyan P, Moawad GN. Review of strategies and factors to maximize cost-effectiveness of robotic hysterectomies and myomectomies in benign gynecological disease. *J Robot Surg*. 2019;13(5): 635-642.
- [11] Takmaz O, Ozbasli E, Gundogan S, et al. Symptoms and Health Quality After Laparoscopic and Robotic Myomectomy. *JSLs*. 2018;22(4):e2018.00030.
- [12] Lonnerfors C. Robot-assisted myomectomy. *Best Pract Res Clin Obstet Gynaecol*. 2018;46:113-119.
- [13] Iavazzo C, Mamais I, Gkegkes ID. Robotic assisted vs laparoscopic and/or open myomectomy: systematic review and meta-analysis of the clinical evidence. *Arch Gynecol Obstet*. 2016;294(1):5-17.
- [14] Wang T, Tang H, Xie Z, Deng S. Robotic-assisted vs. laparoscopic and abdominal myomectomy for treatment of uterine fibroids: a meta-analysis. *Minim Invasive Ther Allied Technol*. 2018;27(5):249-264.
- [15] Rivas-López R, 1 Durón-Padilla R, 2 Romero-Hernández S, 3 Audifred-Salomón J, 4 Hernández-Denis JA. Miomectomía laparoscópica asistida por robot y embarazo. Reporte de caso. *Ginecol Obstet Mex*. 2016;84(3): 194-200
- [16] Jayakumaran J, Patel SD, Gangrade BK, Narasimhulu DM, Pandian SR, Silva C. Robotic-assisted laparoscopy in reproductive surgery: a contemporary review. *J Robot Surg*. 2017;11(2):97-109.

[17] Hyunkyung Kim, et al. Robot-assisted laparoscopic myomectomy, *Obstet Gynecol Sci* 2018;61(1):135-141

[18] Asimov I. (1950). *I, Robot*. Garden City, N.Y: Doubleday.

IntechOpen

IntechOpen