

We are IntechOpen, the world's leading publisher of Open Access books Built by scientists, for scientists

6,900

Open access books available

186,000

International authors and editors

200M

Downloads

Our authors are among the

154

Countries delivered to

TOP 1%

most cited scientists

12.2%

Contributors from top 500 universities



WEB OF SCIENCE™

Selection of our books indexed in the Book Citation Index
in Web of Science™ Core Collection (BKCI)

Interested in publishing with us?
Contact book.department@intechopen.com

Numbers displayed above are based on latest data collected.
For more information visit www.intechopen.com



Lupus Nephritis: Renal Biopsy Guiding the Clinician

Rosa Marlene Viero and Daniela Cristina dos Santos

Abstract

Systemic lupus erythematosus is a chronic autoimmune disease that affects mostly women. The kidneys are involved in 50% of patients causing a high degree of disease morbidity and mortality with poor prognosis. Early diagnosis of lupus nephritis with prompt therapy correlates with a better outcome. The renal biopsy provides important informations to clinicians to monitor the patients. The patterns of glomerular lesion, degree of activity and chronicity of the disease and extent of lesions to the tubulointerstitial and vascular compartments are fundamental information for the clinician to decide the most appropriate treatment. In order to correlate the kidney disease with clinical manifestations and patient outcome the glomerular lesions are classified according to International Society of Nephrology and Renal Pathology Society Classification (ISN/RPS). The definition of active and chronic lesions was introduced by studies conducted at National Institute of Health (NIH). The ISN/RPS classification and NIH indices have recently been revised by a series of retrospective validation studies to improve and minimize the controversial aspects.

Keywords: Systemic lupus erithematosus, lupus nephritis, renal biopsy, ISN/RPS classification, NIH activity and chronicity indices, patients management, prognosis

1. Introduction

Systemic lupus erythematosus (SLE) is a chronic multisystem autoimmune disease that frequently involve kidneys in women. The development of the disease is related to exposure to environmental factors in individuals with genetic predisposition. It is characterized by loss of tolerance against nuclear autoantigens, lymphoproliferation, polyclonal autoantibody production, immune complex disease and multiorgan tissue inflammation [1]. The affected organs include skin, joints, heart, lungs, kidneys, central nervous system and serous membranes. The disease involves a sequence of manifestations such as arthritis, serositis, chronic fatigue, skin rashes, glomerulonephritis, neurological involvement and hematological abnormalities [2]. SLE is the most frequent cause of secondary glomerular disease [3–5]. Lupus nephritis (LN) as a disease usually develops early in the clinical course of SLE in up to 50% of patients. The development of effective diagnostic tests and the introduction of new therapies has shown an improvement in the survival of patients with SLE. However, SLE patients still have a higher risk of death than the general population, especially patients with LN. Lupus glomerulonephritis with intense activity requires greater immunosuppression with increased risk of death from opportunistic infections. On the other hand, long-term treatment with high-dose

of corticosteroids is a risk factor for coronary atherosclerosis and cardiovascular disease [1, 6]. Glomerular immune complexes can activate complement and engage leukocyte Fc receptors to initiate renal inflammation and injury [1]. LN has very pleomorphic clinical and morphologic expressions. Clinical findings range from asymptomatic hematuria and proteinuria to nephrotic syndrome or rapidly progressive renal failure [7].

2. Renal biopsy

The renal biopsy is the gold standard for the diagnosis of LN, providing important information to the clinician for the management of the patients [7–9]. A diagnosis of SLE is based on clinical systemic features and serologic tests attending the American College of Rheumatology (ACR) criteria for SLE [10]. However, it is not uncommon that the renal biopsy shows morphologic expressions that is very suspicious or conclusive of LN before extrarenal manifestations are evident [11]. The renal biopsy provides an important information about the morphology and severity of the lesions, their classification, grades of activity and chronicity of the disease. With the appearance of any signs or symptoms of kidney disease such as hematuria, proteinuria, nephrotic syndrome or renal insufficiency the renal biopsy should be performed. Repeat kidney biopsies should also be done for clinical indications due to SLE flare, persistent proteinuria or declining renal function. The role of the renal biopsy in diagnosis, treatment, management, and follow-up of LN is critical, although to predict the outcome has been a matter of controversy [1, 7, 8]. Considering the importance of the biopsy making the treatment decision and determining the prognosis, it is essential to assess renal histopathology with high accuracy [9, 12, 13]. LN can affect all compartments of the kidney including glomeruli, tubules, interstitium and blood vessels. The analysis of the renal lesions is based on light microscopy (LM) associated with the immunofluorescence (IF) and electron microscopy (EM) findings [11].

3. Glomerular, tubulointerstitial and vascular lesions

The glomeruli are the most affected compartment in the LN. The initial injury is related to immune deposits in the mesangium and/or capillary loops. Large subendothelial deposits can be easily seen by LM. The distribution of deposits in the mesangium and/or glomerular capillaries defines the morphological pattern of the disease and consequently clinical manifestations. Some cases have only mesangial deposits, and others have deposits in the mesangium and in the capillary loops. Deposits in the capillary loops can be intramembranous, subendothelial (between endothelial cells and glomerular basement membrane) or subepithelial (between podocytes and glomerular basement membrane). Large subendothelial deposits characterize the wire loops and determine intense thickening of the glomerular basement membrane with occlusion of capillary loops (**Figure 1**). Immune deposits with complement activation determines an inflammatory reaction with proliferation of resident cells and exudation of mononuclear cells and polymorphonuclear neutrophils. Mesangial deposits stimulate proliferation of mesangial cells and deposition of mesangial matrix. Subendothelial deposits in capillary loops stimulate endothelial proliferation, and subepithelial deposits determines thickening of the GBM without significant cellular proliferation. Capillary involvement by the inflammatory response may result in segmental glomerular necrosis and adjacent cellular crescents. Prolonged glomerular injury result in segmental and/or global

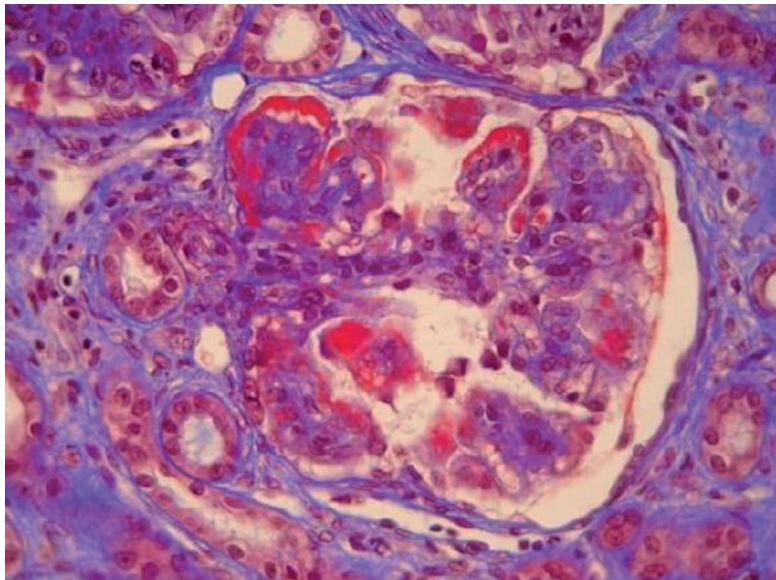


Figure 1.
Glomerulus with intense global hypercellularity and subendothelial hyaline deposits in peripheral capillary loops (wire loops). Masson trichrome 400x.

scarring. The IF staining is variable. IgG is the most frequent immunoglobulin (**Figure 2**), usually associated with deposits of C1q and C3. IgM and IgA deposits may also be present. Fibrin deposits are frequent in areas of necrosis and in association with active crescents. The IF staining is called the full house when there is deposition of the three immunoglobulins, C1q and C3. This staining pattern is very useful for diagnosing LN. The EM confirms the IF findings showing since small mesangial electron dense deposits to large and abundant deposits in the mesangium with extension to capillary loops. Immune deposits limited to the mesangium are associated with mild clinical signs and symptoms. The presence of deposits in the capillary loops, especially in the subendothelial space, is related to more harmful forms of the disease. Anti-dsDNA and anti-C1q antibodies correlate with

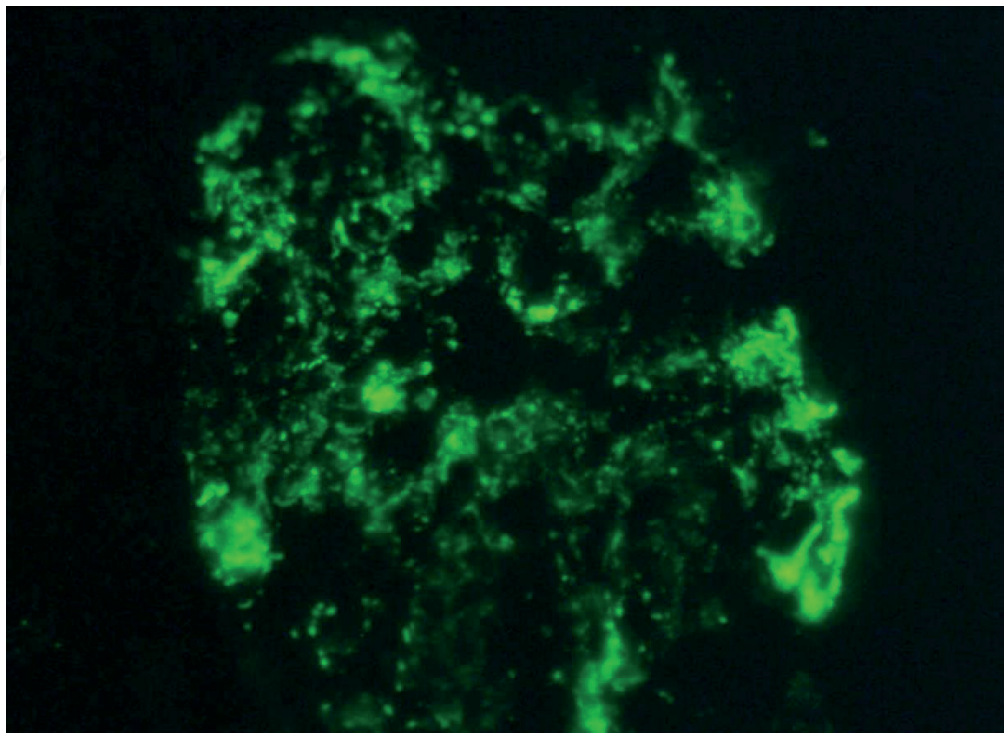


Figure 2.
Granular deposits of IgG in the mesangium and capillary loops. IF-400x.

subendothelial deposits that stimulate endothelial proliferation and glomerular necrosis. The most severe form of LN are cases of diffuse proliferative nephritis that show voluminous subendothelial deposits with high correlation with disease activity. Furthermore, during the course of the disease, LN can undergo transformations. Purely mesangial injuries can evolve to more severe mesangioendothelial proliferative disease with damage of capillary loops. After treatment, severe LN with endothelial proliferation can turn into mesangial proliferative lesion [7, 11].

Tubulointerstitial lesions are found in all types of glomerular lesions, although is more frequent in the most severe forms of proliferative LN. The lesions result from the autoimmune inflammatory activity of the disease and/or prolonged periods of proteinuria [11]. The acute phase is characterized by edema and inflammatory infiltrate with a predominance of mononuclear cells. Immune deposits are detected by IF and EM mainly in the tubular basement membrane and peritubular capillaries in 50% of the patients (**Figure 3**). Immunoglobulins are associated with complement components C1q and C3 in most cases. There was no correlation between prevalence of deposits and the severity of interstitial inflammation, suggesting that the immune complexes are not involved in the pathogenesis of interstitial nephritis in SLE [11, 14]. The predominance of T lymphocytes, CD4 or CD8, with frequent presence of monocytes and NK cells suggests cellular immunity. While several mechanisms may play an initial role, interstitial T cells and monocytes may be important determinants of pathogenesis of interstitial nephritis, and monocytes may be the major factor in the chronic injury and progression of LN [15]. On the other hand, nephrotic proteinuria also induces changes in the tubular cells due to active and excessive resorption of filtered proteins and lipoproteins by the proximal tubules [11]. After a prolonged period of damage, tubular atrophy and interstitial fibrosis characterize the chronic phase of the disease. Active and severe tubulointerstitial injury is most common in severe diffuse proliferative LN. The severity of interstitial inflammation correlated with the degree of renal insufficiency and was an accurate prognostic indicator of progressive deterioration of renal function. Many studies have shown an association between tubulointerstitial damage and a poor renal outcome in LN and in order to avoid progression to end

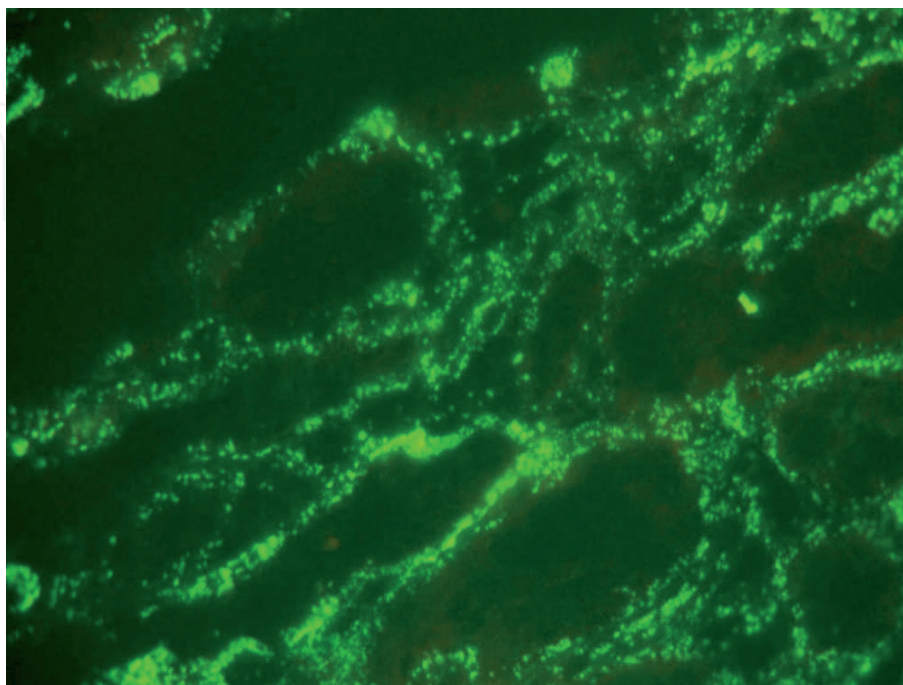


Figure 3.
Granular deposits of C1q in tubular basement membrane and peritubular spaces. IF-400x.

stage renal disease some studies suggest an early intervention before the development of interstitial fibrosis [15–18].

A variety of vascular lesions are encountered in renal biopsies of patients with SLE: uncomplicated vascular immune deposits, noninflammatory necrotizing vasculopathy, true renal vasculitis, thrombotic microangiopathy and arteriosclerosis. The interlobular arteries and arterioles are the most involved vessels [11, 19–21]. Large study with 285 patients with LN found vascular lesion in 79 (27.7%): 9.47% with noninflammatory necrotizing vasculopathy, 8.42% with thrombotic microangiopathy, 7.02% with arteriosclerosis and 2.81% with true vasculitis [20]. Wu *et al* [21] studying 341 patients with LN found 81.8% of vascular injury, including 74.19% of uncomplicated vascular immune deposits, 24.5% of arteriosclerosis, 17.59% of thrombotic microangiopathy, 3.81% of noninflammatory necrotizing vasculopathy and 0.59% of true vasculitis. The inclusion of cases of uncomplicated vascular immune deposits explains the higher incidence of vascular lesions in this study. Uncomplicated vascular immune deposits are the most common lesion and do not significantly affect prognosis. This type of injury shows deposits of immunoglobulins and complement in the small arteries and arterioles, without any inflammatory process and impairment of vascular lumen. The noninflammatory necrotizing vasculopathy determines severe vascular narrowing by abundant eosinophilic material constituted by immune deposits, plasma proteins and fibrin insudation in the vessel wall. There are also degenerative changes and loss of endothelial cells and myocytes. This is a form of vascular lesion associated to more severe forms of glomerular lesion, and is less common than uncomplicated vascular immune deposits. The necrotizing vasculopathy has a poor prognosis with a high degree of disease progression. A true renal vasculitis, with inflammatory infiltrate and necrosis of the vascular wall, is the least common vascular lesion in the LN. This kind of lesion is very severe with an ominous prognosis and need an aggressive immunosuppressive therapy. The thrombotic microangiopathy is characterized by myointimal proliferation of the small vessels, with a pattern of “onion skin”, that complicates with thrombosis. In patients with SLE this vascular lesion occurs in association with hemolytic-uremic syndrome, antiphospholipid syndrome and malignant hypertension. Arteriosclerosis is a degenerative non-immunological vascular lesion characterized by fibrous thickening of the intima of the arteries without necrosis, proliferation or thrombosis. This lesion is common in LN due to the high prevalence of risk factors for arteriosclerosis in lupus patients such as hypertension, hyperlipidemia and prolonged use of corticosteroids. Vascular lesion can occur in any type of glomerular injury, but they are more frequent in the more active glomerulitis with mesangial and glomerular capillaries involvement [11, 19, 21]. Renal vascular lesions, specially of the necrotizing, vasculitic or thrombotic type adversely affects renal outcome with a higher rate of progression to renal failure [11, 19–21]. At the time of renal biopsy, patients with vascular lesion had higher levels of serum creatinine than patients without vascular lesion (2.2 mg/dl vs. 1.2 mg/dl). The probability of a kidney survival at 5 and 10 years was 74.3% and 58.0% in patients with vascular lesion, compared with 89.6% and 85.9% in patients without vascular lesion, respectively [20].

4. International Society of Nephrology and Renal Pathology Society Classification (2003)

The classifications of LN are based on glomerular morphologic lesions in different classes of LN and aim to identify patients at risk of progressing to chronic renal failure.

The morphological changes are based mainly under LM, although the combined analysis of IF and EM provide more effective study. The original World Health Organization (WHO) classification, formulated in 1974, defined 5 classes: Classes I-Normal glomeruli, II-Pure Mesangial Proliferation, III-Focal and segmental proliferative GN (<50% of glomeruli), IV-Diffuse Proliferative GN (≥50% of glomeruli) and V-Membranous GN. In 1995, the WHO classification was modified by the inclusion of subclasses emphasizing active and chronic lesions. However, the introduction of many subclasses has made it difficult to apply in practice. The subclasses of the membranous form of LN (class V) with proliferative lesions of class III (Vc) and class IV (Vd) were very controversial. The class V with additional proliferative features (Vc and Vd) showed a worse prognosis than pure class V, demonstrating that the prognosis was related to proliferative lesions and not to class V. These subcategories were eliminated, and instead, such complex lesions should be diagnosed as association of class V with classes III or IV [11]. The WHO classification has more recently evolved into the 2003 International Society of Nephrology and Renal Pathology Society classification (ISN/RPS) [22] (**Table 1**). The ISN/RPS nomenclature described only the immune-complex LN, not addressing other lesions such as thrombotic microangiopathy and podocytopathies. The ISN/RPS system classifies LN on the basis of where immune complexes accumulate in glomeruli, the presence or absence of mesangial or endocapillary proliferation, the overall extent of glomerular involvement (focal or diffuse; global or segmental) and whether glomerular injury is active (inflammatory) or chronic (sclerotic).

The schema ISN/RPS retains the major criteria of WHO classification with a revision and/or inclusion of pathologic details for each class. The “normal”category of the class I of WHO was eliminated, being replaced by the presence of mesangial deposits by IF and/or EM with normal LM. Class II besides deposits by IF or EM presents mesangial proliferation by LM. Classes III and IV present both mesangial and capillary deposits with endocapillary proliferation, and are separated based on the percentage of glomeruli affected by active and chronic lesions. The most

Classes	Type of Lesion
Class I-Mesangial LN	Normal LM, deposits IF or EM
Class II-Mesangial Proliferative LN	Mesangial hipercellularity and immune deposits by IF or EM
Class III-Focal LN III (A)-active lesions III (A/C)-active and chronic lesions III (C)-chronic lesions	< 50% glomeruli affected by segmental or global endo and/or extracapillary proliferation, subendothelial deposits, necrosis and crescents. Active and chronic lesions.
Class IV-Diffuse LN IV-S (A) or IV-G (A)-active lesions IV-S (A/C) or IV-G (A/C)-active and chronic lesions IV-S (C) or IV-G (C)-glomerular scars	≥50% glomeruli affected by segmental or global endo and/or extracapillary proliferation, subendothelial deposits, necrosis and crescents. Active and chronic lesions.
Class V-Membranous LN	Subepithelial deposits with thickening of GBM
Class VI-Advanced sclerosing LN	90% sclerosed glomeruli. Absence of residual activity.

Table 1.
International Society of Nephrology and Renal Pathology Society Classification of lupus Nephritis-2003 (ISN/RPS).

controversial aspect was the introduction of a subdivision of class IV based on whether the lesions are predominantly segmental or global [23]. Previous studies have suggested that a subgroup of LN with severe segmental lesions involving most of the glomeruli, may have a different pathogenesis than the global proliferative lesions of class III or IV. These severe segmental lesions often had necrosis and crescents, similar to pauci-immune necrotizing and crescentic GN. About 20% of patients with apparent necrotizing and crescentic LN, with rare or absent subendothelial deposits and without significant endocapillary proliferation, have positive ANCA suggesting a coexistence of LN and ANCA-associated necrotizing and crescentic GN [24]. Features of activity and chronicity was clearly delineated in the subcategories of class III and IV. Class IV has a higher risk of progression to chronic renal failure and large subendothelial deposits, necrosis and crescents have a worse prognosis. Due to the higher frequency of biopsied patients with more aggressive kidney injury, most series show a higher percentage of class IV [11]. The class VI was defined with glomerular sclerosis $\geq 90\%$ of glomeruli without residual activity. Severe tubular atrophy, interstitial fibrosis, inflammation, and arteriosclerosis usually accompany the glomerular sclerosis. Chronic lesions, such as segmental or global sclerosis, are interpreted as sequelae of previous more aggressive lesions in the current classification. Thus, a segmentally sclerosing lesion producing an adhesion to Bowman's capsule, most likely represents an organization of a lesion with endothelial proliferation and/or necrosis and crescents, and should be interpreted as a chronic lesion of class III or IV. Globally sclerosed glomeruli can be particularly challenging, because ischemic collapse of the glomerular tuft with collagenous material in Bowman's space occur with aging and benign nephrosclerosis. This kind of lesion overlaps with sclerosed glomerulus with a fibrous crescent after an inflammatory process. Excess cells in the collagenous area, evidence of proliferative injury in the glomerular tuft with adhesion to the retracted and lamellate Bowman's capsule can help distinguish sclerosis due to LN from other causes of sclerosis [8].

Therefore, immune complex formation in the mesangium causes class I and II lesions, subendothelial deposits causes classes III and IV and subepithelial deposits occur in class V lesions.

5. Activity and chronicity indices

It has been known that immunosuppressive therapy is capable of reducing the amount of immune deposits and the degree of inflammatory process in the kidney. However, reduction of histological activity was not always accompanied by clinical improvement and, on the other hand, active lesions on the biopsy may be associated with a silent clinical presentation. These findings demonstrate the importance of renal biopsy in monitoring patients. Investigators have attempted to analyze renal biopsy specimens of LN with respect to active and chronic features as predictors of outcome and guides to therapy. Active lesions are potentially treatable and only the most severe ones become chronic, whereas chronic lesions represent irreversible damage with great impact in the outcome [25]. The concept of activity and chronicity indices was adopted in the studies of National Institutes of Health (NIH) (Table 2). According to this system, the activity (AI) and chronicity indices (CI) are graded on a scale of 0 to 24 and 0 to 12, respectively, by calculating the sum of individual scores (0 to 3+). In a group of patients with diffuse proliferative disease (Class IV), Austin *et al* [25] found that AI is moderately predictive of outcome, with 60% 10-year survival with AI greater than 12. Another study [26] showed 40% of impairment of renal function in 4 years with AI > 12 compared to 7% in the group with AI < 12. The CI was more predictive of renal outcome than

Indices	Grades
Activity Index (0–24)	
Endocapillary hypercellularity	0 absent
Subendothelial deposits	1+ <25% of glomeruli
Necrosis	2+ 25–50% of glomeruli (x2)
Cellular crescents	3+ >50% of glomeruli (x2)
Leukocyte infiltration	0 absent
Interstitial inflammation	1+ mild
	2+ moderate
	3+ severe
Chronicity Index (0–12)	
Glomerular sclerosis	0 absent
Fibrous crescents	1+ <25% of glomeruli
	2+ 25–50% of glomeruli
	3+ >50% of glomeruli
Tubular atrophy	0 absent
Interstitial fibrosis	1+ mild
	2+ moderate
	3+ severe

Table 2.
Activity and chronicity indices of lupus nephritis according to National Institutes of Health (NIH).

AI, demonstrating a 100% 10-year survival with CI ≤ 1 , 68% with CI of 2 or 3 and 32% with CI ≥ 4 . Although individual activity scores do not show predictive value for disease progression, all the scores of CI were individually predictive of renal failure, particularly tubular atrophy [25]. A combination of different scores also shows impact on the prognosis. There are a high risk of doubled creatinine with a combination of two scores, such as more than 50% of cellular crescents and moderate to severe interstitial fibrosis. Patients with severe disease treated with aggressive immunosuppression showed that AI > 7 and CI > 3 have a high risk of progression [27]. More than 50% of crescents are a very ominous morphological finding, but even with $<50\%$ of crescents but combined with moderate or severe fibrosis the risk of doubled creatinine is high specially in black patients [28].

Renal biopsy does not adequately predict the progression of long-term lesions due to disagreement between signs of clinical and histological activity of the disease. Patients in clinical remission show in repeated biopsies evidence of active inflammatory process. On the other hand, in the absence of histological activity, cases of patients with persistent clinical signs are described. Thus, studies have suggested that serial biopsies during maintenance therapy may help in patient monitoring [7]. Alsuwaida *et al* [29] when analyzing a second renal biopsy at the end of the maintenance therapy, demonstrated that persistence of glomerular hypercellularity and interstitial inflammation presented a higher risk of doubling serum creatinine. Patients with an activity index greater than 2 in the second biopsy showed worse renal survival at 10 years and regarding the chronicity index there was a trend for better renal survival with a CI lower than 3.

6. Clinical findings and management

In order to prevent CKD, all patients with SLE should be evaluated for kidney involvement at initial diagnosis and at follow-up. Assessment of patients with suspected LN are greatly facilitated through information obtained by renal biopsy,

and early diagnosis with response to therapy is correlated with better outcome [7, 9]. The heterogeneous morphological aspects of the disease is accompanied by a variable clinical findings. The different classes of LN guide clinicians in making the most appropriate therapeutic decision. A purely mesangial disease sparing the peripheral glomerular capillaries (classes I and II) usually have a mild disease with low levels of proteinuria and normal renal function. The prognosis is excellent and the patients require only conservative treatment. In many patients it is a stable lesion that may persist for years. However, it can undergo transformation to a more severe injury with increased levels of proteinuria and reduced kidney function [7]. LN with capillary loops injuries (classes III and IV) that shows more endocapillary proliferation, necrosis and crescents, with a coexistence of active and chronic lesions, have more aggressive disease. Tubular and interstitial lesions are nearly universal in diffuse proliferative LN and parallel the distribution of the glomerular lesions. Vascular lesions also occur most frequently in the diffuse proliferative group. The clinical manifestations are represented by high levels of proteinuria with or without nephrotic syndrome and active urinary sediment. In class III renal insufficiency is uncommon and the prognosis is variable. In a small percentage of patients there is poor outcome which results from progression of class III to class IV. The diffuse proliferative LN (class IV) have the most severe and active clinical renal presentation, with nephrotic syndrome in up 50% of the patients and various degrees of renal insufficiency in greater than 50% of the patients [30, 31]. It is a consensus that class IV has a worse prognosis. The proliferative classes with more severe active lesions (III and IV) are treated with potent immunosuppression [1, 8]. Some investigators proposed that class IV-S is pathogenetically distinct and has worse long-term outcome than class IV-G, suggesting important prognostic differences [23]. LN class IV-G has predominantly subendothelial deposits and endocapillary proliferation and patients with class IV-S much higher rate of segmental fibrinoid necrosis [32]. Segmental and global glomerulosclerosis are the consequence of active necrotizing lesions with crescent formation. The prognostic significance of class IV-S versus IV-G has been analyzed in other studies and no significant differences in outcome were demonstrated [32–34].

All patients with class V LN have proteinuria and 59–70% have the nephrotic syndrome. Renal insufficiency is uncommon. Patients with class V are more likely to present with renal disease before other systemic features of lupus are apparent. When a membranous lesion is associated with the active or chronic lesions of class III or IV, both diagnoses are to be reported. Patients with membranous LN (class V) may be managed conservatively with antiproteinuric therapy when proteinuria is subnephrotic or with immunosuppression with nephrotic proteinuria [7]. Patients with class VI lupus nephritis have severe renal insufficiency and require only supportive treatment and/or kidney replacement therapy [7].

7. Controversial aspects of ISN/RPS classification and NIH activity and chronicity indices

The classification of INS/RPS was proposed to standardize and emphasize the most relevant lesions to guide the treatment of LN. Recently, several retrospective validation studies concerning the utility of the classification were performed. These studies have highlighted the limitations of the classification and of the activity and chronicity indices. In these reports, the main weaknesses of the classification include: 1. Tubulointerstitial and vascular lesions not included in the system; 2. No correlation between the lesions with long-term outcome; 3. Poor interobserver reproducibility of both active and chronic lesions [12, 13, 32–35].

Tubulointerstitial and vascular lesions correlated closely with clinical disease activity and renal outcome in many studies [14, 19–21]. It is necessary at least to mention these lesions in the diagnosis of the biopsy report.

The classification of LN, especially classes IV-G and IV-S, and the activity and chronicity indexes have not shown a satisfactory correlation with the long-term outcome of the disease [1, 7, 8, 13]. After treatment induction and even during the maintenance phase, the inflammatory process may persist and go unnoticed clinically. Some authors recommend repeating the renal biopsy after treatment to better assess the response to treatment and predict the course of the disease [1, 7, 8, 29]. There is also a poor reproducibility among pathologists to apply these criteria that limits their application in practice [1, 36, 37]. It is a consensus that the classification of LN as well as the criteria of activity and chronicity of the disease should be reviewed [1, 7, 8, 36, 37].

8. Conclusions

In conclusion, the precise identification of key glomerular, tubulointerstitial and vascular lesions remain incompletely understood in terms of pathogenesis and prognostic effect. The ISN/RPS classification improved the knowledge of different patterns of LN lesions, and validation studies have shown new emerging morphological data to be further investigated and included in the classification [8, 12, 35]. Most nephrologists find an assessment of activity and chronicity

Biopsy Report
ID: RPS, caucasian, female with 38 years-old
History: Patient with erythema and scaling in the face, lymphocitopenia, anemia, proteinuria of 2g/24h, microhematuria, serum creatinine of 1,8 mg/dl. Anti-dsDNA>200 UI, ANA 1/1600.
Renal biopsy
Macroscopy: 3 fragments of renal biopsy measuring each 1cm long. One fragment fixated in Duboscq-Brazil was sent to LM, 1 frozen fragment was sent to IF using anti-IgG, IgA, IgM, C1q, C3, Fibrin, κ and λ conjugates, 1 fixated in glutaraldehyde 2,5% sent to EM.
Light Microscopy: Renal biopsy showing the cortical with 30 glomeruli, all with large size and mesangioendothelial heavy hypercellularity and moderate exsudate of polymorphonuclear neutrophils; some peripheral capillary loops show bulky hyaline deposits obliterating capillary lumens (wire loops). In 6 glomeruli there are small segments fibrinoid necrosis, nuclear debris and fibrin deposits, with overlying small cellular crescents. Two glomeruli are globally sclerosed surrounded by tubular atrophy and mild interstitial fibrosis. There is also a heavy interstitial edema and inflammatory infiltrate of mononuclear cells with degenerative changes of tubules. The vessels are unremarkable.
Immunofluorescence: Presence of diffuse granular deposits in the mesangium and capillary loops of IgG (3/3+), IgA (2/3+), IgM (1/3+), C1q (3/3+), C3 (2/3+), Fibrin (2/3+), κ and λ (2/3+). There were deposits in the tubular basement membrane and peritubular capillaries of IgG and C1q (2/3+). There were no deposits in the vessels.
Electron microscopy: Presence of mesangial, subendothelial and tubular basement membrane electron-dense deposits.
Renal biopsy diagnosis: Lupus nephritis characterized by diffuse proliferative glomerulonephritis with 20% of segmental necrosis, 20% of cellular crescents and 6,6% of global glomerular sclerosis. Intense lymphomononuclear tubulointerstitial nephritis with focal tubular atrophy and interstitial fibrosis. Normal vessels.
ISN/RPS classification: Class IV-G (A/C)
NIH Activity and Chronicity Indices:
Activity: subendothelial deposits 2+, glomerular hypercellularity 3+, exsudate of neutrophils 2+, necrosis 2+, cellular crescents 2+, interstitial inflammatory infiltrate 3+. Total = 14
Chronicity: glomerular sclerosis 1+, tubular atrophy 1+, interstitial fibrosis 1+. Total =3

Box 1.
Biopsy Report Interpretation of Lupus Nephritis

indices useful, and the biopsy reports should include routinely, with a detailed description of the types of active and chronic lesions and proportion of glomeruli affected (**Figures 1–3** and **Box 1**). Despite these unresolved controversies, active lesions versus chronic lesions, in addition to class of LN, influence response to therapy. The ISN/RPS recently presented a consensus report from a meeting of an international nephropathology working group in 2016. Briefly, they proposed new definitions for mesangial hypercellularity and different patterns of crescents; endocapillary proliferation was replaced by endocapillary hypercellularity, the IV-S and IV-G subclasses were eliminated, and active and chronic designations of class III and IV were replaced by the activity and chronicity indices that should be applied to all classes. In order to improve the LN classification, further studies will be carried out to validate the new proposal [38].

Acknowledgements

We thank our professors, the Department of Pathology and the Botucatu Medical School for all the learning that allowed this work.

Conflict of interest

The authors declare no conflict of interest.

Author details

Rosa Marlene Viero* and Daniela Cristina dos Santos
Department of Pathology, Botucatu Medical School, UNESP, Botucatu, SP, Brazil

*Address all correspondence to: rosa.viero@unesp.br

IntechOpen

© 2021 The Author(s). Licensee IntechOpen. This chapter is distributed under the terms of the Creative Commons Attribution License (<http://creativecommons.org/licenses/by/3.0>), which permits unrestricted use, distribution, and reproduction in any medium, provided the original work is properly cited. 

References

- [1] Parikh SV, Almaani S, Brodsky S, Rovin BH. Update on Lupus Nephritis: Core Curriculum 2020. *AJKD* 2020; 76 (2): 265-281.
- [2] Worrall JG, Snaith ML, Batchelor JR, Isenberg DA. SLE: a rheumatological view. Analysis of the clinical features, serology and immunogenetics of 100 SLE patients during long-term follow-up. *Q J Med* 1990; 74 (275): 319-330.
- [3] Malafronte P, Mastroianni-Kirsztajn G, Betônico G, Romão Jr JE, Alves MAR, Carvalho MF, Viera Neto OM, Cadaval RAM, Bérigamo RR, Woronik V, Sens YAS, Marrocos MSM, Barros RT. Paulista registry of glomerulonephritis: 5-year data report. *Nephrol Dial Transplant* 2006; 21: 3098-3105.
- [4] Rivera F, Lopez-Gomez JM, Perez-Garcia R. Spanish Registry of Glomerulonephritis. Frequency of renal pathology in Spain 1994-1999. *Nephrol Dial Transplant* 2002; 17: 1594-1602.
- [5] Li LS, Liu ZH. Epidemiologic data of renal diseases from a single unit in China: analysis based on 13,519 renal biopsies. *Kidney Int* 2004; 66: 920-923.
- [6] Borchers AT, Keen CL, Shoenfeld Y, Gershwin ME. Surviving the butterfly and the wolf: mortality trends in systemic lupus erythematosus. *Autoimmunity Reviews* 2004; 3:423-453.
- [7] Almaani S, Meara A, Rovin BH. Update on Lupus Nephritis. *Clin J Am Soc Nephrol* 2017; 12 (5): 825-835.
- [8] Giannico G, Fogo AB. Lupus Nephritis: Is the Kidney Biopsy Currently Necessary in the Management of Lupus Nephritis? *Clin J Am Soc Nephrol* 2013; 8: 138-145.
- [9] Satish S, Deka P, Shetty MS. A clinico-pathological study of lupus nephritis based on the International Society of Nephrology-Renal Pathology Society 2003 classification system. *J Lab Phys* 2017; 9 (3): 149-155.
- [10] Tan EM, Cohen AS, Fries JF, Masi AT, McShane DJ, Rothfield NF, Schaller JG, Talal N, Winchester RJ. The 1982 revised criteria for the classification of systemic lupus erythematosus. *Arthritis Rheum* 1982; 25 (11): 1271-1277.
- [11] D'Agati VD, Stokes MB. Renal disease in systemic lupus erythematosus, mixed connective tissue disease, Sjögren syndrome, and rheumatoid arthritis. In: Jennette JC, Olson JL, Silva FG, D'Agati VD, editors. *Hepinstall's Pathology of Kidney*. 7th Ed. Philadelphia-PA, USA: Wolters Kluwer; 2015. p. 559-656.
- [12] Dasari S, Chakraborty A, Truong L, Mohan C. A Systematic Review of Interpathologist Agreement in Histologic Classification of Lupus Nephritis. *Kidney Int Rep* 2019; 4: 1420-1425.
- [13] Sada KE, Makino H. Usefulness of ISN/RPS Classification of Lupus Nephritis. *J Korean Med Sci* 2009; 24 (Suppl 1): S7-10.
- [14] Park MH, D'Agati VD, Appel GB, Pirani CL. Tubulointerstitial disease in lupus nephritis: relationship to immune deposits, interstitial inflammation, glomerular changes, renal function, and prognosis. *Nephron* 1986; 44: 309-319.
- [15] Alexopoulos E, Seron D, Hartley RB, Cameron JS. Lupus nephritis: correlation of interstitial cells with glomerular function. *Kidney Int* 1990; 37 (1): 100-109.

- [16] Broder A, Mowrey WB, Khan HN, Jovanovic B, Londono-jimenez A, Izmirly P, Putterman C. Tubulo interstitial Damage Predicts End Stage Renal Disease in Lupus Nephritis with Preserved to Moderately Impaired Renal Function: a Retrospective Cohort Study. *Semin Arthritis Rheum* 2018; 47(4): 545-551.
- [17] Clark MR, Trotter K, Chang A. The pathogenesis and therapeutic implications of tubulointerstitial inflammation in human lupus nephritis. *Semin Nephrol* 2015; 35(5): 455-464.
- [18] Jimenez AL, Mowrey WB, Putterman C, Buyon J, Goilav B, Broder A. Tubulointerstitial Damage in Lupus Nephritis: A Comparison of the Factors Associated with Tubulo interstitial Inflammation and Renal Scarring. *Arthritis Rheumatol.* 2018; 70(11): 1801-1806.
- [19] Appel GB, Pirani CL, D'Agati V: Renal vascular complications of systemic lupus erythematosus. *J Am Soc Nephrol* 1994; 4: 1499-1515.
- [20] Banfi G, Bertani T, Boeri V, Faraggiana T, Mazzucco G, Monga G, Sacchi G. Renal vascular lesions as a marker of poor prognosis in patients with lupus nephritis. Gruppo Italiano per lo Studio della Nefrite Lupica (GISNEL). *Am J Kidney Dis* 1991; 18 (2): 240-248.
- [21] Wu LH, Yu F, Tan Y, Qu Z, Chen MH, Wang SX, Liu G, Zhao MH. Inclusion of renal vascular lesions in the 2003 ISN/RPS system for classifying lupus nephritis improves renal outcome predictions. *Kidney Int* 2013; 83: 715-723.
- [22] Weening JJ, D'Agati VD, Schwartz MM, Seshan SV, Alpers CE, Appel GB, Balow JE, Bruijn JA, Cook T, Ferrario F, Fogo AB, Ginzler EM, Hebert L, Hill G, Hill P, Jennette JC, Kong NC, Lesavre P, Lockshin M, Looi LM, Makino H, Moura LA, Nagata M. The Classification of Glomerulonephritis in Systemic Lupus Erythematosus Revisited. *J Am Soc Nephrol* 2004; 15: 241-250.
- [23] Najafi CC, Korbet SM, Lewis EJ, Schwartz MM, Reichlin M, Evans J; Lupus Nephritis Collaborative Study Group: Significance of histologic patterns of glomerular injury upon long-term prognosis in severe lupus glomerulonephritis. *Kidney Int* 2001; 59: 2156-2163.
- [24] Nasr SH, D'Agati VD, Park HR, Serman PL, Goyzueta JD, Dressler RM, Hazlett SM, Pursell RN, Caputo C, Markowitz GS: Necrotizing and crescentic lupus nephritis with antineutrophil cytoplasmic antibody seropositivity. *Clin J Am Soc Nephrol* 2008; 3: 682-690.
- [25] Austin III HA, Muenz LR, Joyce KM, Antonovych TA, Kullick ME, Klippel JH, Decker JL, Balow JE. Prognostic factors in lupus nephritis. Contribution of renal histologic data. *Am J Med* 1983; 75 (3):382-391.
- [26] Austin III HA, Muenz LR, Joyce KM, Antonovych TT, Balow JE. Diffuse proliferative lupus nephritis: identification of specific pathologic features affecting renal outcome. *Kidney Int* 1984; 25 (4): 689-695.
- [27] Austin III HA, Boumpas DT, Vaughan EM, Balow JE. Predicting renal outcomes in severe lupus nephritis: contributions of clinical and histological data. *Kidney Int* 1994; 45 (2): 544-550.
- [28] Austin III HA, Boumpas DT, Vaughan EM, Balow. High-risk features of lupus nephritis: importance of race and clinical and histological factors in 166 patients. *Nephrol Dial Transplant* 1995; 10: 1620-1628.
- [29] Alsuwaida A, Husain S, Alghonaim M, AlOudah N, Alwakeel J,

- ullah A, Kfoury H: Strategy for second kidney biopsy in patients with lupus nephritis. *Nephrol Dial Transplant* 2012; 27: 1472-1478.
- [30] Appel GB, Silva FG, Pirani CL, Meltzer JI, Estes D. renal involvement in systemic lupus erithematosus (SLE): a study of 56 patients emphasizing histologic classification. *Medicine (Baltimore)* 1978; 57: 371.
- [31] Baldwin DS, Gluck MC, Lowenstein J, Gallo GR. Lupus nephritis: clinical course as related to morphologic forms and their transitions. *Am J Med* 1977; 62:12-30.
- [32] Hill GS, Delahousse M, Nochy D, Bariety J. Class IV-S versus class IV-G lupus nephritis: clinical and morphologic differences suggesting different pathogenesis. *Kidney Int* 2005; 68: 2288-2297.
- [33] Mittal B, Hurwitz S, Rennke H, Singh AK: New subcategories of class IV lupus nephritis: Are there clinical, histologic, and outcome differences? *Am J Kidney Dis* 2004; 44: 1050-1059.
- [34] Yu F, Tan Y, Wu LH, Zhu SN, Liu G, Zhao MH: Class IV-G and IV-S lupus nephritis in Chinese patients: A large cohort study from a single center. *Lupus* 2009; 18: 1073-1081.
- [35] Mubarak M, Nasri H. ISN/RPS 2003 classification of lupus nephritis: time to take a look on the achievements and limitations of the schema. *J Nephropathol.* 2014; 3(3): 87-90.
- [36] Schwartz MM, Lan SP, Bernstein J, Hill GS, Holley K, Lewis EJ. Role of pathology indices in the management of severe lupus glomerulonephritis. *Lupus Nephritis Collaborative Study Group. Kidney Int* 1992; 42 (3): 743-748.
- [37] Schwartz MM, Lan SP, Bernstein J, Hill GS, Holley K, Lewis EJ. Irreproducibility of the activity and chronicity indices limits their utility in the management of lupus nephritis. *Lupus Nephritis Collaborative Study Group. Am J Kidney Dis* 1993; 21 (4): 374-377.
- [38] Bajema IM, Wilhelmus S, Alpers CE, Bruijn JA, Colvin RB, Cook HT, D'Agati VD, Ferrario F, Haas M, Jennette JC, Joh K, Nast CC, Noël LH, Rijnink EC, Roberts ISD, Seshan SV, Sethi S, Fogo AB. Revision of the International Society of Nephrology/ Renal Pathology Society classification for lupus nephritis: clarification of definitions, and modified National Institutes of Health activity and chronicity indices. *Kidney Int* 2018; 93, 789-796.