

We are IntechOpen, the world's leading publisher of Open Access books Built by scientists, for scientists

6,900

Open access books available

185,000

International authors and editors

200M

Downloads

Our authors are among the

154

Countries delivered to

TOP 1%

most cited scientists

12.2%

Contributors from top 500 universities



WEB OF SCIENCE™

Selection of our books indexed in the Book Citation Index
in Web of Science™ Core Collection (BKCI)

Interested in publishing with us?
Contact book.department@intechopen.com

Numbers displayed above are based on latest data collected.
For more information visit www.intechopen.com



Medical Therapy of Giant Cell Tumor of Bone

*Raquel Lopes-Brás, Isabel Fernandes, Sandra Casimiro
and Luís Costa*

Abstract

Giant cell tumor of bone (GCTB) is mostly a benign disease of the bone, although with high local recurrence rate and potential for metastatic spread, namely to the lungs. It is also a locally aggressive tumor, associated with severe morbidity and functional impairment due to bone destruction. Treatment is therefore required and should be offered at an early stage to allow complete resection, minimizing functional sequelae and local recurrence. Surgical resection is the mainstay of treatment, often followed by intralesional adjuvant therapy. GCTB has a particular biology, in which RANKL represents a key factor in tumor pathogenesis, thus making this molecule a valuable therapeutic target. Monthly administration of denosumab, a fully human monoclonal antibody directed against RANKL, has been studied in several clinical trials and shown a high rate of local control with favorable safety profile. In this chapter, current medical management, ongoing studies, and future directions in GCTB will be discussed.

Keywords: denosumab, giant cell tumor of bone, RANKL, sarcoma, sarcomatoid transformation

1. Introduction

Giant cell tumor of bone (GCTB) is a primary tumor of bone usually arising in the meta-epiphysis of long bones, although potentially also occur in other parts of the skeleton, such as the spine or pelvis [1]. GCTB more often affects young patients in the second to fourth decades of life [1, 2] and those living in urban (rather than rural) areas [3]. It is also associated with Paget's disease [4]. The condition presents with localized pain, tenderness to touch, palpable mass, and decreased range of motion, as well as mechanical pain and joint swelling in patients with presentation near joints [5]. Rarely, it may present with pathological fracture [4].

GCTB is mostly a benign disease, but local recurrence rates are high and there is a small risk of metastatic spread, namely to the lungs [1, 6]. Risk factors for pulmonary metastases include young age, Enneking stage 3, local recurrence, and axial disease, but not treatment modality [6, 7]. Pulmonary metastases most often appear three to four years after initial diagnosis and rarely are the cause of death [8]. However, when GCTB metastasizes, mortality rate rises to 14–25% [8, 9].

Despite being a rare event, GCTB can also undergo malignant sarcomatoid transformation [10]. In these cases, malignant GCTB can present with three histologic subtypes: osteosarcoma, fibrosarcoma, or undifferentiated pleomorphic

sarcoma. This usually occurs following multiple recurrent lesions (e.g. Paget's disease) and/or radiation therapy [5].

Multicentric GCTB is another rare form of tumor presentation, characterized by two or more distant lesions of histologically confirmed disease [11]. These lesions can present as synchronous (more common) or metachronous. Although multicentric GCTB appears to have demographic differences (patients are young and more commonly female), disease behavior – including local recurrence rates, pulmonary metastases pattern, and malignant transformation – seems to be similar to solitary GCTB [11].

Radiologically, GCTB presents as an osteolytic lesion with characteristic radiolucent and geographic (well-circumscribed) appearance and fading cortical bone, rarely showing periosteal reaction. GCTBs are usually eccentric masses in the epiphyseal region extending to subchondral bone (sclerotic metaphyseal margin) [5, 12].

Besides a high degree of suspicion in radiological exams (plain films, computed tomography [CT], and magnetic resonance imaging [MRI]), GCTB diagnosis must be histologically confirmed by core-needle or open biopsy [5]. Still, plain radiographs, CT scan, and MRI are useful for diagnosis and local staging. MRI is often performed to delineate neoplasm extent, namely soft tissue extension. Additionally, bone scintigraphy helps ruling out other asymptomatic bone lesions and chest CT scan should be performed to exclude lung involvement and guide treatment.

Based on radiological findings and according to Enneking and later Campanacci grading systems, GCTB can be classified in three grades [7, 13]:

- Grade I (latent): well-defined margin (thin rim of mature bone) and intact cortex (not deformed).
- Grade II (active): relatively well-defined margins but no radiopaque rim; cortex is thinned and moderately expanded. Grade II lesions with fracture are graded separately.
- Grade II (aggressive): indistinct borders and cortex destruction, suggesting rapid and permeated growth.

This surgical staging system allows preoperative planning. Post-operatively, GCTB can also be graded based on histological features in grade 1 (typical), grade 2 (aggressive), or grade 3 (malignant) [14].

Due to lack of long-term follow-up data, GCTB prognosis is not well established to date [15]. However, the overall prognosis of benign GCTB is generally favorable. Recurrence rates are estimated at 25% [15] and can be as high as 50% after curettage alone [16]. Systemic treatment with bisphosphonates or denosumab seems to lower these figures [17]. Although secondary lung involvement is rare in benign GCTB and very uncommonly the cause of death, mortality rate is higher in these patients (14–25%) [8, 9, 18]. Regarding malignant GCTB (either primary or secondary), overall survival at 5 years is about 85% and poorest in older patients and those with distant disease at diagnosis, according to a Surveillance, Epidemiology and End Results (SEER) study involving 117 cases of malignant GCTB [19]. Smaller studies may indicate worse survival rates [20].

2. GCTB biology and pathogenesis

2.1 Histopathology

GCTB is histologically characterized by diffuse growth of receptor activator of nuclear factor kappa-B ligand (RANKL)-positive, round-to-oval polygonal or

elongated mononuclear stromal cells, RANK-positive mononuclear cells of myeloid lineage, and RANK-positive osteoclast-like giant cells, reflecting a physiopathology intimately linked to the RANKL/RANK pathway [17, 21, 22] (**Figure 1**). Small areas of osteoid matrix deposition, woven bone, and occasionally new bone are also observed in about 50% of GCTB samples, with different studies reporting an incidence between 22 and 52% [23].

The characteristic giant cells in GCTB are osteoclastic in nature [24–28] and represent the reactive component responsible for GCTB aggressive lytic behavior, leading to GCTB designation as osteoclastoma. These cells express RANK but not RANKL [26]. Profiling studies have shown that giant cells in GCTB are the result of CD33+ pre-osteoclast fusion that further fuse with CD14+ mononuclear cells [27] and express tartrate-resistant acid phosphatase (TRAP) and vitronectin receptor, osteoclast markers, being capable of lacunar resorption [29].

However, in GCTB neoplastic cells are ovoid stromal cells, displaying markers of mesenchymal stem cells derived from the osteoblast lineage, but minimal expression of fully differentiated osteoblasts, like osteocalcin, alkaline phosphatase, osteoprotegerin (OPG), and TRAIL [29–33]. Twist-mediated downregulation of RUNX2, a major osteogenic regulator, has been shown to interrupt osteoblastic differentiation and depress osteoblast lineage markers in GCTB [34].

GCTB stromal cells express high levels of RANKL [27] and also produce other osteoclastogenic cytokines, like interleukin (IL)-1, -6, -11, and -17, tumor necrosis factor- α (TNF- α), and macrophage colony-stimulating factor (M-CSF), through which osteoclast differentiation is stimulated from precursor cells [26]. Other characteristics supporting their neoplastic nature include dominance, increased proliferative potential, abundance of genetic alterations, and expression of more differentiation markers than multinucleated giant cells [22]. GCTBs are polyclonal in nature, with inconsistent chromosomal changes and telomere associations occurring in up to 72% of cases, although lacking prognostic value [35–38]. Mononuclear stromal cell-exclusive mutation p.G34W (or p.G34L, p.G34M, p.G34R, or p.G34V in a small sub-set of cases) in the *H3F3A* gene, encoding histone 3.3 (H3.3) variant implicated in epigenetic reprogramming and memory, has been identified as GCTB-specific driver mutation [30].

Because G34W mutations occur more frequently than chromosomal abnormalities and can be causative risk factors for chromosomal structural remodeling in DNA synthesis, it has been hypothesized that this driver mutation causes chromosomal instability and defects, contributing to pleiotropic effects on cell cycle-related expression, immature osteoblastic differentiation, and chemokines, cytokines, and

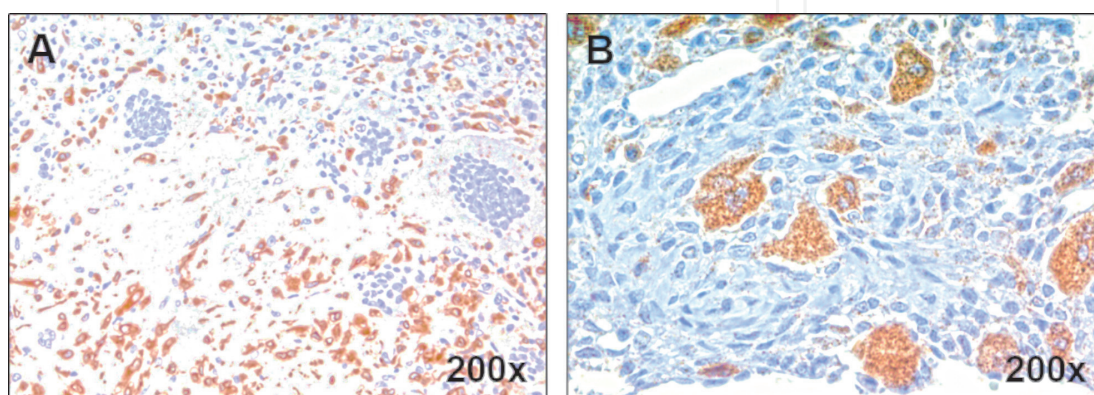


Figure 1.
 Representative images of RANKL (A) and RANK (B) immunohistochemistry in formalin-fixed and paraffin-embedded GCTB samples. (unpublished data).

surface markers expression [22, 37]. Additionally, mutations in cyclin D1, p53, and MET have been linked to malignant transformation and GCTB recurrence [22].

Biologically, Wnt/ β -catenin and transforming growth factor beta (TGF- β) signaling pathways mediate the exacerbated proliferation of stromal cells in GCTB. β -catenin, cyclin D1, and p21 have been shown to be overexpressed in the nuclei of GCTB stromal cells [39]. Additionally, one study showed that protease activated receptor-1 (PAR-1) is also upregulated in GCTB downstream of TGF- β , via Smad3 and Smad4 [40]. In the study, PAR-1 knockout in GCTB stromal cells inhibited tumor growth, angiogenesis, and osteoclastogenesis *in vitro* and PAR-1 inhibition suppressed tumor growth and giant cell formation *in vivo*.

2.2 Physiopathology

GCTB physiopathology is not entirely understood, but there is compelling evidence that RANKL overexpression by mononuclear stromal cells plays a key role and elicits transformation of monocytic pre-osteoclast to osteoclast cells, ultimately resulting in osteolysis observed in these tumors [22, 41–43] (**Figure 2**). Accordingly, preclinical models have shown that OPG, a soluble decoy receptor for RANKL, inhibits monocyte activation and osteoclast differentiation [44].

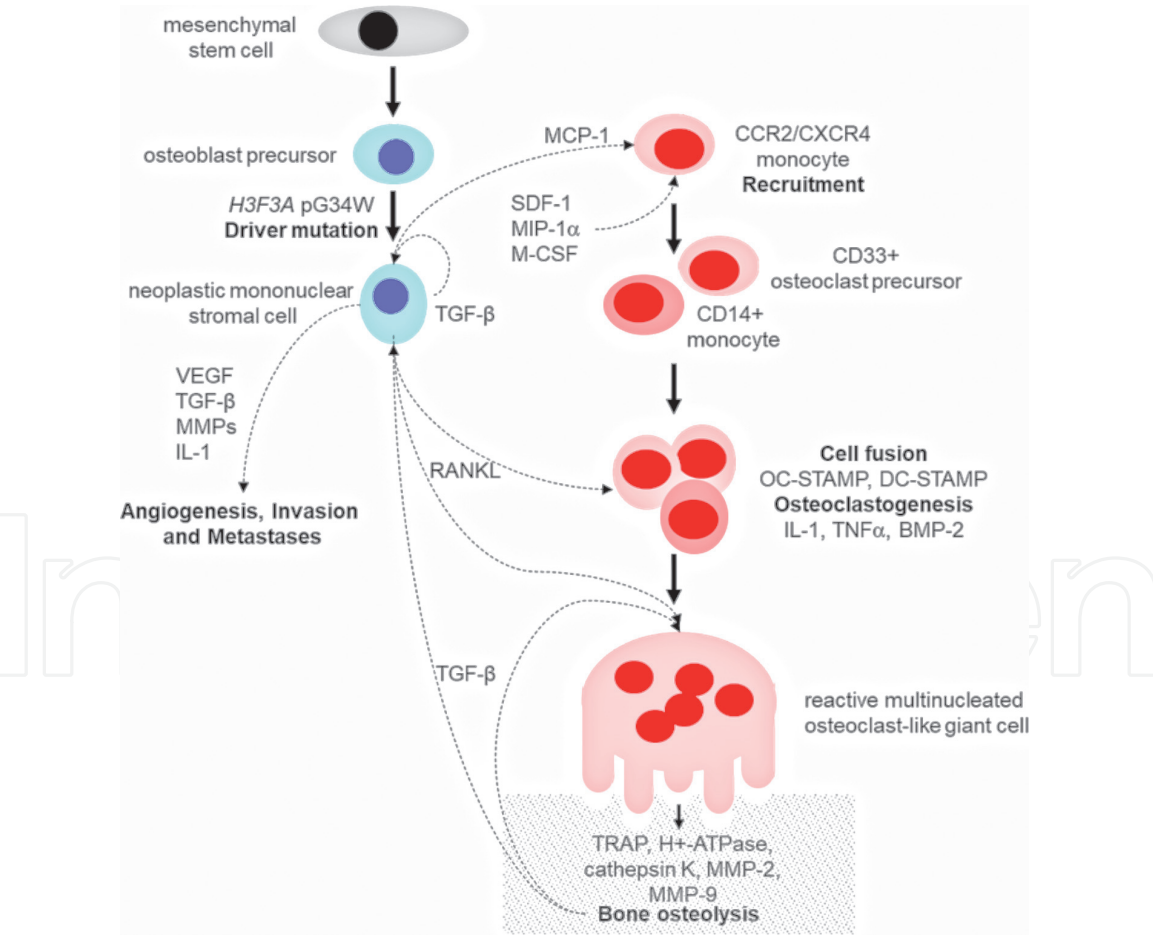


Figure 2. Simplified scheme of GCTB physiopathology. BMP-2, bone morphogenetic protein 2; CCR2, C-C chemokine receptor type 2; CXCR4, C-X-C chemokine receptor type 4; DC-STAMP, dendritic cell-specific transmembrane protein; IL-1, interleukin 1; MCP-1, monocyte chemoattractant protein-1; M-CSF, macrophage colony-stimulating factor; MIP-1 α , macrophage inflammatory protein 1-alpha; MMPs, matrix metalloproteases; OC-STAMP, osteoclast stimulatory transmembrane protein; RANKL, receptor activator of nuclear factor kappa-B ligand; SDF-1, stromal cell-derived factor 1; TGF- β , transforming growth factor beta; TNF α , tumor necrosis factor alpha; TRAP, tartrate-resistant acid phosphatase; VEGF, vascular endothelial growth factor.

In GCTB, stromal cell-derived monocyte chemoattractant protein-1 (MCP-1/CCL2) recruits bone marrow-derived CCR2/CXCR4-expressing monocytic osteoclast precursors from peripheral blood [45, 46]. Other soluble factors within GCTB microenvironment are chemotactic for myelomonocytic cells, including stromal cell-derived factor 1 (SDF-1/CXCL12), macrophage inflammatory protein 1-alpha (MIP-1 α /CCL3), and M-CSF1 [26, 47]. Osteoclast precursors localized at GCTB microenvironment differentiate into active, bone resorbing, osteoclasts.

Different pre-clinical studies have shown that GCTB stromal cells with circulating mononuclear cells co-culture induces differentiation of osteolytic giant cells [41–43]. For differentiation to occur, RANKL expression in stromal cells is regulated by CCAAT/enhancer-binding protein beta (C/EBP β), found to be overexpressed in GCTB [48], and also by parathyroid hormone-related peptide (PTHrP) in an autocrine manner [49]. Next, RANKL-induced cell fusion is co-stimulated by M-CSF and IL-34 [26] and enhanced by specific transmembrane proteins overexpressed in GCTB [50] and coupling components, like insulin-like growth factors (IGF) I and II [51].

RANK pathway activation in giant cells leads to up-regulation of nuclear factor of activated T cells c1 (NFATc1), an auto-regulated key transcription factor responsible for regulating expression of important genes involved in bone resorption, like cathepsin K or β 3-integrin [52]. Cathepsin K is involved in initial steps of bone resorption, degrading collagen type I and remodeling the bone matrix, allowing migration. As bone resorption starts, TGF- β entrapped in bone matrix is activated by matrix metalloproteinases (MMPs), stimulating giant cell migration [46], which is mediated by α v β 3 integrin attachment to the bone matrix [53].

MMPs have an important role in GCTB physiopathology. Apart from the above-mentioned role in giant cell migration via TGF- β activation, MMPs influence other major aspects within the tumor microenvironment, like angiogenesis, invasion, and metastatic development. MMP-2 and MMP-9 are key in all these processes [22]. In GCTB, the extracellular matrix metalloproteinase inducer (EMMPRIN) is responsible for inducing MMP expression. Higher EMMPRIN expression at multinuclear osteoclast-like giant cells has been observed in stage III GCTB, probably regulated by RANKL from stromal-like tumor cells [54].

As previously mentioned, metastases are extremely rare in GCTB and there are no clues on molecular or physiopathological events related with GCTB metastization to date.

2.3 Tumor markers

Pathophysiology of GCTB progression remains unclear and prognostic factors, treatment targets, and predictive biomarkers represent unmet needs.

Histologically, ambiguous giant cell-rich lesions – including benign GCTB, chondroblastoma, aneurysmal bone cyst, central giant cell granuloma of the jaw, and malignant giant cell-rich osteosarcoma – are often found, especially as small biopsy or curettage specimens [22]. In these cases, *H3F3A* gene p.G34W mutation can be used in the differential diagnosis, as it is almost GCTB-exclusive [30, 55]. Approximately 90% of GCTBs display the p.G34W mutation, with minor subsets (<2%) displaying p.G34L, p.G34M, p.G34R, or p.G34V variants. *H3F3B* p.K36M is the *H3.3* mutation found in the vast majority (90–95%) of chondroblastomas [30].

H3.3 p.G34W mutant-specific immunohistochemistry (IHC; clone RM263, commercially available) is a highly sensitive and specific surrogate marker of *H3F3A* p.G34W mutation in GCTB [56–58], being useful for practical diagnosis in primary [58] or recurrent, metastatic, and secondary malignant GCTB [59]. Although denosumab therapy may decrease p.G34W expression [22], evidence

shows that spindle cells and cells in and around immature bone in denosumab-treated GCTBs are H3.3 p.G34W-positive by IHC, with H3F3A mutations consistently detected in corresponding samples [56, 58, 60, 61], which may predict relapse risk [55].

Although rare, malignant GCTB may occur, and studies suggest that p.G34W mutation is preserved [55]. One report, however, showed loss of one *H3F3A* allele (probably the mutant allele) in GCTB malignant component, leading to negative p. G34W IHC [62].

p63, a member of the p53 family of transcription factors, has also been studied as biomarker in GCTB diagnosis. p63 immunostaining has been used in diagnosis of head and neck squamous cell carcinoma, prostate adenocarcinoma (negative for p63 in opposition to p63-positive benign prostatic tissue) [63], and poorly differentiated squamous cell carcinoma [64]. p63 has also been shown to be highly expressed in GCTB mononuclear neoplastic cells [65–67], but its usefulness is still to be determined. A meta-analysis of eight different studies including 335 GCTB patients showed that p63 is a helpful marker for GCTB diagnosis in critically ill patients, although it cannot be recommended as a single definitive diagnostic marker [68].

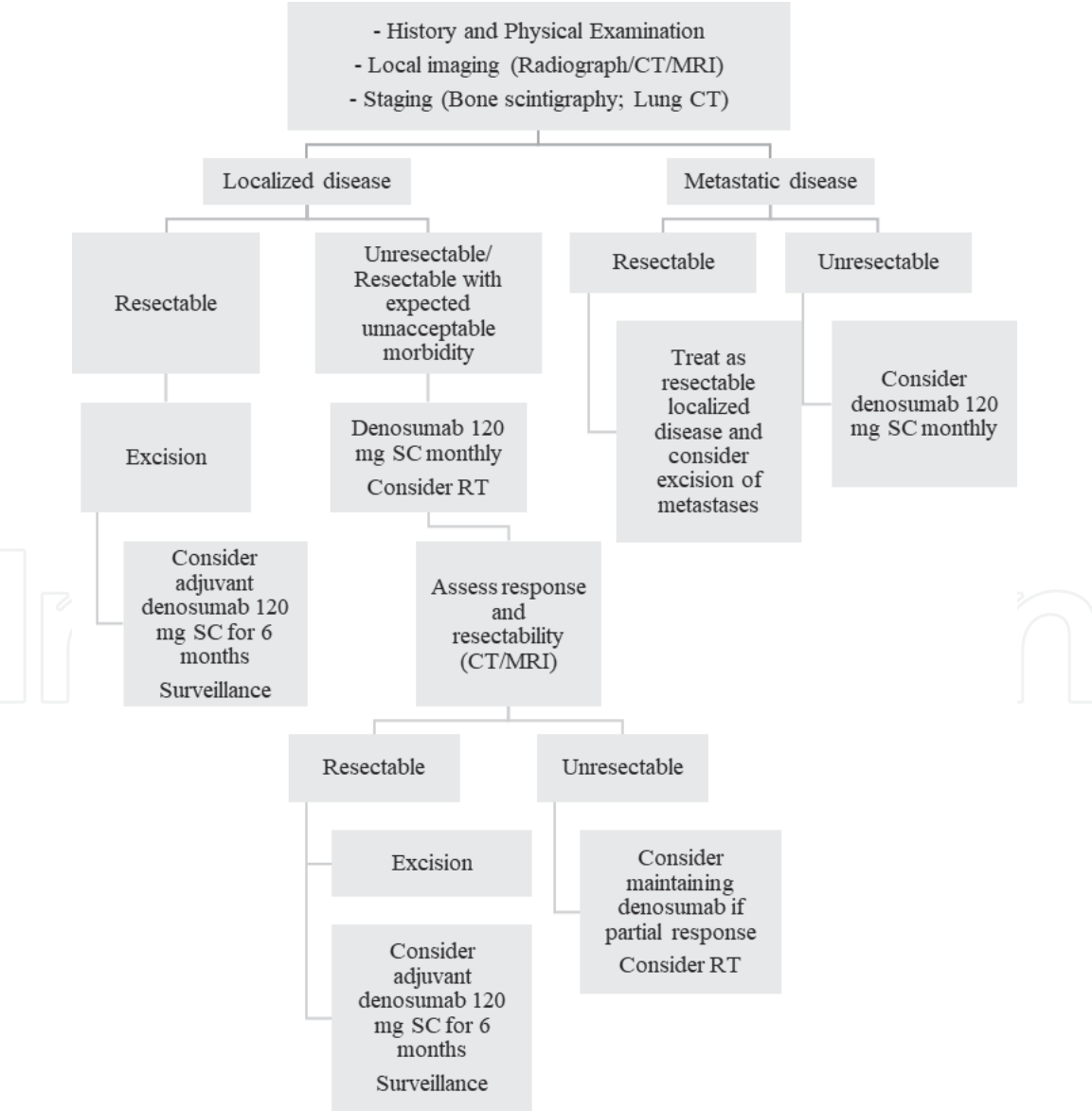


Figure 3. Flowchart of GCTB treatment. Adapted from NCCN guidelines – Bone cancer [73]. CT, computerized tomography; MRI, magnetic resonance imaging; RT, radiation therapy; SC, subcutaneous.

Finally, it has been suggested that high RANKL, IL-6, TNF α , SDF-1, and MCP-1 expression may help predict GCTB metastatic potential and prognosis, warranting further studies [69].

3. Treatment overview

Treatment options for localized GCTB include *en bloc* resection or curettage with or without local adjuvants, like phenol, liquid nitrogen, or polymethylmethacrylate [70]. Radiation therapy (RT) can also be used as an alternative to surgery for local control, with 5-year local control rates of 80% [71]. However, RT is associated with risk of malignant transformation into high-grade sarcoma, making surgery the preferred option when possible. Contrarily to palliative care in irresectable or distant disease, systemic neoadjuvant or adjuvant therapy with the RANKL-binding fully human monoclonal antibody denosumab is still not established [70, 72]. A treatment algorithm is depicted in **Figure 3**.

4. Medical therapy

4.1 Denosumab

Denosumab is a fully human monoclonal antibody (IgG2) that binds with high affinity and specificity to RANKL [74], thereby inhibiting osteoclast-mediated osteolysis. Given GCTB pathophysiology and its association to RANKL/RANK pathway, denosumab has proven effective in this disease.

In patients with resectable GCTB, adjuvant denosumab at a 120 mg dosage administered subcutaneously every 28 days, with additional loading doses on days 8 and 15 on the first month, during 6 months after complete resection has been approved by both the Food and Drug Administration and European Medicines Agency [72, 75, 76]. However, this treatment is still debated. Studies supporting its use in the adjuvant setting are scarce and mostly rely in level IV evidence. Conversely, evidence from a systematic review by Luengo-Alonso [72] favored adjuvant denosumab, which showed a positive histological and clinical (pain relief) response. In patients with unresectable GCTB (either primary or recurrent) or when complete excision is possible but post-surgical severe morbidity and functional impairment is expected, neoadjuvant denosumab should be started (same dosing scheme as above) and response to treatment evaluated. Should the patient respond to denosumab and surgery be feasible with acceptable morbidity, then complete excision and possibly adjuvant denosumab for six months should be considered. On the other hand, the optimal denosumab duration is still debatable when treatment response is suboptimal or in cases of sacral or spinal GCTB, multiple lesions (including pulmonary metastases), or patient's clinical ineligibility for surgery. Denosumab should be considered until progression or unacceptable toxicity (e.g., osteonecrosis of the jaw), provided at least partial response is achieved.

4.2 Bisphosphonates

Bisphosphonates inhibit osteoclast-mediated bone resorption and are used in cancer patients, especially in bone metastases setting. In GCTB patients, denosumab is the preferred systemic treatment option. However, evidence regarding the use of adjuvant denosumab is not consistent and some studies show lack of benefit in local recurrence rates [77, 78]. Bisphosphonates, like zoledronic acid (ZA), can be an

option in the adjuvant setting. A recent meta-analysis of case-control studies showed that the use of adjuvant bisphosphonates in patients submitted to intralesional curettage may decrease local recurrence rates, independently of Campanacci staging [79]. In patients undergoing wide resection, bisphosphonates seem to have no benefit in local recurrence. A phase II non-randomized clinical trial of adjuvant ZA after extensive curettage in GCTB patients showed that ZA failed to prevent local recurrence [80]. Another phase II multicentric, randomized, open-label clinical trial showed no benefit with adjuvant ZA, although the study was terminated earlier due to poor accrual [81]. The use of adjuvant bisphosphonates should be evaluated on a case-by-case basis. In unresectable or metastatic GCTB, clinical studies addressing the use of bisphosphonates are also scarce. Overall, the role of bisphosphonates in the treatment of patients with GCTB remains to be clearly defined.

4.3 Chemotherapy/systemic cytotoxic agents/interferon

Chemotherapy agents and interferon- α have also been used to treat GCTB, as reported in case reports and small series, but results were poor and there are no clinical trials to guide their use. Anecdotal small retrospective case series and case reports have documented the use of doxorubicin [82, 83], cyclophosphamide [84], cisplatin plus doxorubicin [85], combination therapy with vincristine, doxorubicin, cyclophosphamide and actinomycin-D, followed by high-dose methotrexate and vincristine [86], interferon alpha 2a [87] and interferon alpha 2b [88], with mixed results.

5. Conclusions and future directions

GCTB is a primary and mostly benign tumor of bone usually arising in the meta-epiphysis of long bones and more often affecting young patients. Despite its frequent benign nature, local recurrence rate is high and there is a non-negligible risk of distant metastatization, namely to the lungs. Therefore, treatment should provide the best chance of curative outcome with minimal functional sequelae and quality of life impairment.

The main pillar of treatment is surgery, but systemic therapy has a role in adjuvant and palliative settings. Regarding GCTB pathophysiology, RANKL/RANK pathway is central to tumor development and denosumab, a monoclonal antibody against RANKL, is the most studied and most effective systemic therapy for the disease. Its use is particularly established in the palliative setting, i.e., in cases of unresectable disease, patient ineligibility for surgery, or lung involvement. Although less studied, bisphosphonates can also be an option. However, their role in GCTB medical management needs to be better clarified.

GCTB rare nature, particularly malignant GCTB, hampers the development of clinical trials to investigate new drugs for second-line treatment and establish the optimal treatment sequence (neo- vs. adjuvant denosumab or adjuvant denosumab vs. after recurrence, etc.). Currently, one clinical trial (NCT04255576) is studying the use of JMT103, a novel fully human IgG4 monoclonal antibody against RANKL, in GCTB [89]. Another clinical trial (NCT03449108) is using a different approach to address bone tumors, including GCTB [90], by studying the use of LN-145-S1, or autologous tumor infiltrating lymphocytes, in treatment-refractory or relapsed disease. As discussed above, mutations in cyclin D1, p53, and MET have been associated with GCTB malignant transformation and recurrence. This raises the hypothesis that cyclin-dependent kinase (CDK) inhibitors (e.g., ribociclib,

palbociclib) and MET inhibitors (e.g., crizotinib) may be useful in this disease. Although these therapies have been approved in other tumors (CDK inhibitors in breast cancer and crizotinib in lung cancer), no studies are in place in GCTB yet. Another promising target is MMPs, specially MMP-2 and MMP-9, that play an important role in GCTB physiopathology, namely regarding tumor microenvironment, angiogenesis, invasion, and metastatic development. Preclinical studies in breast cancer used ML115, a bone-seeking MMP inhibitor, to prevent bone metastases [91], with promising results. Although still far from use in the clinical practice, this could be another potential therapy worth studying in GCTB. Several other clinical trials continue to investigate the use of denosumab, bisphosphonates, and local therapy (surgery/RT) [92–97].

Acknowledgements

We thank Joana Cavaco Silva for her contribution as a medical writer. Authors acknowledge Joana Cavaco Silva for manuscript revision.

Conflict of interest

The authors declare no conflict of interest.

Nomenclature

BMP-2	Bone morphogenetic protein 2
CCR2	C-C chemokine receptor type 2
CXCR4	C-X-C chemokine receptor type 4
C/EBP β	CCAAT/enhancer binding protein beta
CT	Computerized tomography
CDK	Cyclin-kinase inhibitors
DC-STAMP	Dendritic cell-specific transmembrane protein
EMMPRIN	Extracellular matrix metalloproteinase inducer
FFPE	Formalin-Fixed Paraffin-Embedded
GCTB	Giant cell tumor of the bone
H3.3	Histone 3.3
IgG	Immunoglobulin G
IHC	Immunohistochemistry
IGF	Insulin-like growth factor
IL-1	Interleukin 1
M-CSF	Macrophage colony-stimulating factor
MIP-1 α	Macrophage inflammatory protein 1-alpha;
MRI	Magnetic resonance imaging
MMP	Matrix metalloprotease
MCP-1	Monocyte chemoattractant protein-1
NFATc1	Nuclear factor of activated T cells c1
OC-STAMP	Osteoclast stimulatory transmembrane protein
PTHrP	Parathyroid hormone related peptide
RT	Radiation therapy
RANKL	Receptor activator of nuclear factor kappa-B ligand
RUNX2	Runt-related transcription factor 2
SC	Subcutaneous

SDF-1	Stromal cell-derived factor 1
TRAP	Tartrate-resistant acid phosphatase
TRAIL	TNF-related apoptosis inducing ligand
TGF- β	Transforming growth factor beta
TNF- α	Tumor necrosis factor-alpha
VEGF	Vascular endothelial growth factor
ZA	Zoledronic acid

Author details

Raquel Lopes-Brás^{1*}, Isabel Fernandes^{1,2}, Sandra Casimiro² and Luís Costa^{1,2*}

1 Medical Oncology Department, Hospital de Santa Maria, Centro Hospitalar
Universitário Lisboa Norte, Lisbon, Portugal

2 LCosta Lab, Instituto de Medicina Molecular – João Lobo Antunes, Faculdade de
Medicina da Universidade de Lisboa, Lisbon, Portugal

*Address all correspondence to: raquellopesbras@gmail.com and
luiscosta.oncology@gmail.com

IntechOpen

© 2021 The Author(s). Licensee IntechOpen. This chapter is distributed under the terms of the Creative Commons Attribution License (<http://creativecommons.org/licenses/by/3.0>), which permits unrestricted use, distribution, and reproduction in any medium, provided the original work is properly cited. 

References

- [1] Athanasou NA, Bansal M, Forsyth R, Reid RP, Sapi Z. Giant cell tumour of bone. In: Fletcher C, Bridge J, Hogendoorn P, Mertens F, editors. WHO classification of tumours of soft tissue and bone. 4th ed. Lyon: International Agency for Research on Cancer (IARC); 2013. p. 321-4.
- [2] Liede A, Bach BA, Stryker S, Hernandez RK, Sobocki P, Bennett B, et al. Regional variation and challenges in estimating the incidence of giant cell tumor of bone. *The Journal of bone and joint surgery American volume*. 2014;96(23):1999-2007.
- [3] Larsson SE, Lorentzon R, Boquist L. Giant-cell tumor of bone. A demographic, clinical, and histopathological study of all cases recorded in the Swedish Cancer Registry for the years 1958 through 1968. *The Journal of bone and joint surgery American volume*. 1975;57(2):167-173.
- [4] Goldenberg RR, Campbell CJ, Bonfiglio M. Giant-cell tumor of bone. An analysis of two hundred and eighteen cases. *The Journal of bone and joint surgery American volume*. 1970;52(4):619-664.
- [5] Amanatullah DF, Clark TR, Lopez MJ, Borys D, Tamurian RM. Giant cell tumor of bone. *Orthopedics*. 2014;37(2):112-120.
- [6] Chan CM, Adler Z, Reith JD, Gibbs CP, Jr. Risk factors for pulmonary metastases from giant cell tumor of bone. *The Journal of bone and joint surgery American volume*. 2015;97(5):420-428.
- [7] Enneking WF. A system of staging musculoskeletal neoplasms. *Clinical orthopaedics and related research*. 1986(204):9-24.
- [8] Siebenrock KA, Unni KK, Rock MG. Giant-cell tumour of bone metastasising to the lungs. A long-term follow-up. *The Journal of bone and joint surgery British volume*. 1998;80(1):43-47.
- [9] Rock MG, Pritchard DJ, Unni KK. Metastases from histologically benign giant-cell tumor of bone. *The Journal of bone and joint surgery American volume*. 1984;66(2):269-274.
- [10] Gong L, Liu W, Sun X, Sajdik C, Tian X, Niu X, et al. Histological and clinical characteristics of malignant giant cell tumor of bone. *Virchows Archiv: an international journal of pathology*. 2012;460(3):327-334.
- [11] Hoch B, Inwards C, Sundaram M, Rosenberg AE. Multicentric giant cell tumor of bone. Clinicopathologic analysis of thirty cases. *The Journal of bone and joint surgery American volume*. 2006;88(9):1998-2008.
- [12] Sobti A, Agrawal P, Agarwala S, Agarwal M. Giant Cell Tumor of Bone - An Overview. *Arch Bone Jt Surg*. 2016;4(1):2-9.
- [13] Campanacci M, Baldini N, Boriani S, Sudanese A. Giant-cell tumor of bone. *JBJS*. 1987;69(1).
- [14] Jaffe HL. Giant cell tumor of bone: Its pathologic appearance, grading, supposed variants and treatment. *Arch Pathol*. 1940;30:993-1031.
- [15] Palmerini E, Picci P, Reichardt P, Downey G. Malignancy in Giant Cell Tumor of Bone: A Review of the Literature. *Technology in cancer research & treatment*. 2019;18:1533033819840000.
- [16] Hu P, Zhao L, Zhang H, Yu X, Wang Z, Ye Z, et al. Recurrence Rates and Risk Factors for Primary Giant Cell Tumors around the Knee: A Multicentre Retrospective Study in China. *Scientific reports*. 2016;6:36332.

- [17] Lipplaa A, Dijkstra S, Gelderblom H. Challenges of denosumab in giant cell tumor of bone, and other giant cell-rich tumors of bone. *Current opinion in oncology*. 2019;31(4):329-335.
- [18] Tubbs WS, Brown LR, Beabout JW, Rock MG, Unni KK. Benign giant-cell tumor of bone with pulmonary metastases: clinical findings and radiologic appearance of metastases in 13 cases. *AJR American journal of roentgenology*. 1992;158(2):331-334.
- [19] Beebe-Dimmer JL, Cetin K, Fryzek JP, Schuetze SM, Schwartz K. The epidemiology of malignant giant cell tumors of bone: an analysis of data from the Surveillance, Epidemiology and End Results Program (1975-2004). *Rare Tumors*. 2009;1(2):e52-e.
- [20] Rock MG, Sim FH, Unni KK, Witrak GA, Frassica FJ, Schray MF, et al. Secondary malignant giant-cell tumor of bone. Clinicopathological assessment of nineteen patients. *The Journal of bone and joint surgery American volume*. 1986;68(7):1073-1079.
- [21] Kuhn J, Sapra A. Osteoclastoma. *StatPearls*. Treasure Island (FL)2020.
- [22] Noh BJ, Park YK. Giant cell tumor of bone: updated molecular pathogenesis and tumor biology. *Human pathology*. 2018;81:1-8.
- [23] Branstetter DG, Nelson SD, Manivel JC, Blay JY, Chawla S, Thomas DM, et al. Denosumab induces tumor reduction and bone formation in patients with giant-cell tumor of bone. *Clinical cancer research: an official journal of the American Association for Cancer Research*. 2012;18(16):4415-4424.
- [24] Maggiani F, Forsyth R, Hogendoorn PC, Krenacs T, Athanasou NA. The immunophenotype of osteoclasts and macrophage polykaryons. *J Clin Pathol*. 2011;64(8):701-705.
- [25] Doussis IA, Puddle B, Athanasou NA. Immunophenotype of multinucleated and mononuclear cells in giant cell lesions of bone and soft tissue. *J Clin Pathol*. 1992;45(5):398-404.
- [26] Atkins GJ, Haynes DR, Graves SE, Evdokiou A, Hay S, Bouralexis S, et al. Expression of osteoclast differentiation signals by stromal elements of giant cell tumors. *Journal of bone and mineral research: the official journal of the American Society for Bone and Mineral Research*. 2000;15(4):640-649.
- [27] Forsyth RG, De Boeck G, Baelde JJ, Taminiau AH, Uyttendaele D, Roels H, et al. CD33+ CD14- phenotype is characteristic of multinuclear osteoclast-like cells in giant cell tumor of bone. *Journal of bone and mineral research: the official journal of the American Society for Bone and Mineral Research*. 2009;24(1):70-77.
- [28] Goldring SR, Roelke MS, Petrisson KK, Bhan AK. Human giant cell tumors of bone identification and characterization of cell types. *J Clin Invest*. 1987;79(2):483-491.
- [29] Lau YS, Sabokbar A, Gibbons CL, Giele H, Athanasou N. Phenotypic and molecular studies of giant-cell tumors of bone and soft tissue. *Human pathology*. 2005;36(9):945-954.
- [30] Behjati S, Tarpey PS, Presneau N, Scheipl S, Pillay N, Van Loo P, et al. Distinct H3F3A and H3F3B driver mutations define chondroblastoma and giant cell tumor of bone. *Nat Genet*. 2013;45(12):1479-1482.
- [31] Wulling M, Delling G, Kaiser E. The origin of the neoplastic stromal cell in giant cell tumor of bone. *Human pathology*. 2003;34(10):983-993.
- [32] Huang L, Teng XY, Cheng YY, Lee KM, Kumta SM. Expression of preosteoblast markers and Cbfa-1 and Osterix gene transcripts in stromal

tumour cells of giant cell tumour of bone. *Bone*. 2004;34(3):393-401.

[33] Murata A, Fujita T, Kawahara N, Tsuchiya H, Tomita K. Osteoblast lineage properties in giant cell tumors of bone. *J Orthop Sci*. 2005;10(6):581-588.

[34] Singh S, Mak IW, Cowan RW, Turcotte R, Singh G, Ghert M. The role of TWIST as a regulator in giant cell tumor of bone. *J Cell Biochem*. 2011;112(9):2287-2295.

[35] Gorunova L, Vult von Steyern F, Storlazzi CT, Bjerkehaugen B, Folleras G, Heim S, et al. Cytogenetic analysis of 101 giant cell tumors of bone: nonrandom patterns of telomeric associations and other structural aberrations. *Genes Chromosomes Cancer*. 2009;48(7):583-602.

[36] Horvai AE, Kramer MJ, Garcia JJ, O'Donnell RJ. Distribution and prognostic significance of human telomerase reverse transcriptase (hTERT) expression in giant-cell tumor of bone. *Mod Pathol*. 2008;21(4):423-430.

[37] Schwartz HS, Butler MG, Jenkins RB, Miller DA, Moses HL. Telomeric associations and consistent growth factor overexpression detected in giant cell tumor of bone. *Cancer Genet Cytogenet*. 1991;56(2):263-276.

[38] Schwartz HS, Eskew JD, Butler MG. Clonality studies in giant cell tumor of bone. *J Orthop Res*. 2002;20(2):387-390.

[39] Matsubayashi S, Nakashima M, Kumagai K, Egashira M, Naruke Y, Kondo H, et al. Immunohistochemical analyses of beta-catenin and cyclin D1 expression in giant cell tumor of bone (GCTB): a possible role of Wnt pathway in GCTB tumorigenesis. *Pathol Res Pract*. 2009;205(9):626-633.

[40] Wang T, Jiao J, Zhang H, Zhou W, Li Z, Han S, et al. TGF-beta induced

PAR-1 expression promotes tumor progression and osteoclast differentiation in giant cell tumor of bone. *Int J Cancer*. 2017;141(8):1630-1642.

[41] Joyner CJ, Quinn JM, Triffitt JT, Owen ME, Athanasou NA. Phenotypic characterisation of mononuclear and multinucleated cells of giant cell tumour of bone. *Bone Miner*. 1992;16(1):37-48.

[42] Miyamoto N, Higuchi Y, Tajima M, Ito M, Tsurudome M, Nishio M, et al. Spindle-shaped cells derived from giant-cell tumor of bone support differentiation of blood monocytes to osteoclast-like cells. *J Orthop Res*. 2000;18(4):647-654.

[43] Roux S, Quinn J, Pichaud F, Orcel P, Chastre E, Jullienne A, et al. Human cord blood monocytes undergo terminal osteoclast differentiation in vitro in the presence of culture medium conditioned by giant cell tumor of bone. *J Cell Physiol*. 1996;168(3):489-498.

[44] Atkins GJ, Bouralexis S, Haynes DR, Graves SE, Geary SM, Evdokiou A, et al. Osteoprotegerin inhibits osteoclast formation and bone resorbing activity in giant cell tumors of bone. *Bone*. 2001;28(4):370-377.

[45] Zheng MH, Fan Y, Smith A, Wysocki S, Papadimitriou JM, Wood DJ. Gene expression of monocyte chemoattractant protein-1 in giant cell tumors of bone osteoclastoma: possible involvement in CD68+ macrophage-like cell migration. *J Cell Biochem*. 1998;70(1):121-129.

[46] Yu Q, Stamenkovic I. Cell surface-localized matrix metalloproteinase-9 proteolytically activates TGF-beta and promotes tumor invasion and angiogenesis. *Genes Dev*. 2000;14(2):163-176.

[47] Liao TS, Yurgelun MB, Chang SS, Zhang HZ, Murakami K, Blaine TA,

- et al. Recruitment of osteoclast precursors by stromal cell derived factor-1 (SDF-1) in giant cell tumor of bone. *J Orthop Res*. 2005;23(1):203-209.
- [48] Ng PK, Tsui SK, Lau CP, Wong CH, Wong WH, Huang L, et al. CCAAT/enhancer binding protein beta is up-regulated in giant cell tumor of bone and regulates RANKL expression. *J Cell Biochem*. 2010;110(2):438-446.
- [49] Mak IW, Turcotte RE, Ghert M. Parathyroid hormone-related protein (PTHrP) modulates adhesion, migration and invasion in bone tumor cells. *Bone*. 2013;55(1):198-207.
- [50] Miyamoto H, Suzuki T, Miyauchi Y, Iwasaki R, Kobayashi T, Sato Y, et al. Osteoclast stimulatory transmembrane protein and dendritic cell-specific transmembrane protein cooperatively modulate cell-cell fusion to form osteoclasts and foreign body giant cells. *Journal of bone and mineral research: the official journal of the American Society for Bone and Mineral Research*. 2012;27(6):1289-1297.
- [51] Hemingway F, Taylor R, Knowles HJ, Athanasou NA. RANKL-independent human osteoclast formation with APRIL, BAFF, NGF, IGF I and IGF II. *Bone*. 2011;48(4):938-944.
- [52] Gohda J, Akiyama T, Koga T, Takayanagi H, Tanaka S, Inoue J. RANK-mediated amplification of TRAF6 signaling leads to NFATc1 induction during osteoclastogenesis. *EMBO J*. 2005;24(4):790-799.
- [53] Pilkington MF, Sims SM, Dixon SJ. Transforming growth factor-beta induces osteoclast ruffling and chemotaxis: potential role in osteoclast recruitment. *Journal of bone and mineral research: the official journal of the American Society for Bone and Mineral Research*. 2001;16(7):1237-1247.
- [54] Si AI, Huang L, Xu J, Kumta SM, Wood D, Zheng MH. Expression and localization of extracellular matrix metalloproteinase inducer in giant cell tumor of bone. *J Cell Biochem*. 2003;89(6):1154-1163.
- [55] Yamamoto H, Ishihara S, Toda Y, Oda Y. Histone H3.3 mutation in giant cell tumor of bone: an update in pathology. *Med Mol Morphol*. 2020;53(1):1-6.
- [56] Yamamoto H, Iwasaki T, Yamada Y, Matsumoto Y, Otsuka H, Yoshimoto M, et al. Diagnostic utility of histone H3.3 G34W, G34R, and G34V mutant-specific antibodies for giant cell tumors of bone. *Human pathology*. 2018;73:41-50.
- [57] Amary F, Berisha F, Ye H, Gupta M, Gutteridge A, Baumhoer D, et al. H3F3A (Histone 3.3) G34W Immunohistochemistry: A Reliable Marker Defining Benign and Malignant Giant Cell Tumor of Bone. *Am J Surg Pathol*. 2017;41(8):1059-1068.
- [58] Luke J, von Baer A, Schreiber J, Lubbehusen C, Breining T, Mellert K, et al. H3F3A mutation in giant cell tumour of the bone is detected by immunohistochemistry using a monoclonal antibody against the G34W mutated site of the histone H3.3 variant. *Histopathology*. 2017;71(1):125-133.
- [59] Tsukamoto Y, Futani H, Kihara T, Watanabe T, Kumanishi S, Matsuo S, et al. An extremely rare case of primary malignancy in giant cell tumor of bone, arising in the right femur and harboring H3F3A mutation. *Pathol Res Pract*. 2018;214(9):1504-1509.
- [60] Kato I, Furuya M, Matsuo K, Kawabata Y, Tanaka R, Ohashi K. Giant cell tumours of bone treated with denosumab: histological, immunohistochemical and H3F3A mutation analyses. *Histopathology*. 2018;72(6):914-922.

- [61] Girolami I, Mancini I, Simoni A, Baldi GG, Simi L, Campanacci D, et al. Denosumab treated giant cell tumour of bone: a morphological, immunohistochemical and molecular analysis of a series. *J Clin Pathol*. 2016; 69(3):240-247.
- [62] Yoshida KI, Nakano Y, Honda-Kitahara M, Wakai S, Motoi T, Ogura K, et al. Absence of H3F3A mutation in a subset of malignant giant cell tumor of bone. *Mod Pathol*. 2019;32(12): 1751-1761.
- [63] Shiran MS, Tan GC, Sabariah AR, Rampal L, Phang KS. p63 as a complimentary basal cell specific marker to high molecular weight-cytokeratin in distinguishing prostatic carcinoma from benign prostatic lesions. *Med J Malaysia*. 2007;62(1):36-39.
- [64] Zhang H, Liu J, Cagle PT, Allen TC, Laga AC, Zander DS. Distinction of pulmonary small cell carcinoma from poorly differentiated squamous cell carcinoma: an immunohistochemical approach. *Mod Pathol*. 2005;18(1): 111-118.
- [65] Shooshtarizadeh T, Rahimi M, Movahedinia S. P63 expression as a biomarker discriminating giant cell tumor of bone from other giant cell-rich bone lesions. *Pathol Res Pract*. 2016;212(10):876-879.
- [66] Yanagisawa M, Kakizaki H, Okada K, Torigoe T, Kusumi T. p63 as a prognostic marker for giant cell tumor of bone. *Ups J Med Sci*. 2013;118(1): 23-28.
- [67] Lee CH, Espinosa I, Jensen KC, Subramanian S, Zhu SX, Varma S, et al. Gene expression profiling identifies p63 as a diagnostic marker for giant cell tumor of the bone. *Mod Pathol*. 2008;21(5):531-539.
- [68] Wan Z, Lee CW, Yuan S, Lee OK. Can p63 serve as a biomarker for diagnosing giant cell tumor of bone? A systematic review and meta-analysis. *Sao Paulo Med J*. 2020;138(5):393-399.
- [69] Muheremu A, Niu X. Pulmonary metastasis of giant cell tumor of bones. *World J Surg Oncol*. 2014;12:261.
- [70] Casali PG, Bielack S, Abecassis N, Aro HT, Bauer S, Biagini R, et al. Bone sarcomas: ESMO-PaedCan-EURACAN Clinical Practice Guidelines for diagnosis, treatment and follow-up. *Annals of Oncology*. 2018;29:iv79-iv95.
- [71] Shi W, Indelicato DJ, Reith J, Smith KB, Morris CG, Scarborough MT, et al. Radiotherapy in the management of giant cell tumor of bone. *American journal of clinical oncology*. 2013;36(5): 505-508.
- [72] Luengo-Alonso G, Mellado-Romero M, Shemesh S, Ramos-Pascua L, Pretell-Mazzini J. Denosumab treatment for giant-cell tumor of bone: a systematic review of the literature. *Archives of orthopaedic and trauma surgery*. 2019; 139(10):1339-1349.
- [73] National Comprehensive Cancer Network (NCCN). Bone Cancer (Version 1.2021) 2021 [Available from: https://www.nccn.org/professionals/physician_gls/pdf/bone.pdf].
- [74] Bekker PJ, Holloway DL, Rasmussen AS, Murphy R, Martin SW, Leese PT, et al. A single-dose placebo-controlled study of AMG 162, a fully human monoclonal antibody to RANKL, in postmenopausal women. *Journal of bone and mineral research: the official journal of the American Society for Bone and Mineral Research*. 2004;19(7): 1059-1066.
- [75] Chawla S, Henshaw R, Seeger L, Choy E, Blay JY, Ferrari S, et al. Safety and efficacy of denosumab for adults and skeletally mature adolescents with giant cell tumour of bone: interim analysis of an open-label, parallel-

group, phase 2 study. *The Lancet Oncology*. 2013;14(9):901-908.

[76] Xgeva - Summary of Product Characteristics: European Medicines Agency; 2011 [updated 2016. Available from: https://www.ema.europa.eu/en/documents/product-information/xgeva-par-product-information_en.pdf.

[77] Müller DA, Beltrami G, Scoccianti G, Campanacci DA, Franchi A, Capanna R. Risks and benefits of combining denosumab and surgery in giant cell tumor of bone-a case series. *World J Surg Oncol*. 2016;14(1):281.

[78] Errani C, Tsukamoto S, Leone G, Righi A, Akahane M, Tanaka Y, et al. Denosumab May Increase the Risk of Local Recurrence in Patients with Giant-Cell Tumor of Bone Treated with Curettage. *The Journal of bone and joint surgery American volume*. 2018;100(6):496-504.

[79] Shi M, Chen L, Wang Y, Wang W, Zhang Y, Yan S. Effect of bisphosphonates on local recurrence of giant cell tumor of bone: a meta-analysis. *Cancer Manag Res*. 2019;11:669-680.

[80] Gouin F, Rochwerger AR, Di Marco A, Rosset P, Bonneville P, Fiorenza F, et al. Adjuvant treatment with zoledronic acid after extensive curettage for giant cell tumours of bone. *European Journal of Cancer*. 2014;50(14):2425-2431.

[81] Lipplaa A, Kroep JR, van der Heijden L, Jutte PC, Hogendoorn PCW, Dijkstra S, et al. Adjuvant Zoledronic Acid in High-Risk Giant Cell Tumor of Bone: A Multicenter Randomized Phase II Trial. *The oncologist*. 2019;24(7):889-e421.

[82] Dominkus M, Ruggieri P, Bertoni F, Briccoli A, Picci P, Rocca M, et al. Histologically verified lung metastases in benign giant cell tumours—14 cases

from a single institution. *Int Orthop*. 2006;30(6):499-504.

[83] Yamamoto M, Fukushima T, Sakamoto S, Tomonaga M. Giant cell tumor of the sphenoid bone: long-term follow-up of two cases after chemotherapy. *Surgical neurology*. 1998;49(5):547-552.

[84] Osaka S, Toriyama M, Taira K, Sano S, Saotome K. Analysis of giant cell tumor of bone with pulmonary metastases. *Clinical orthopaedics and related research*. 1997(335):253-261.

[85] Stewart DJ, Belanger R, Benjamin RS. Prolonged disease-free survival following surgical debulking and high-dose cisplatin/doxorubicin in a patient with bulky metastases from giant cell tumor of bone refractory to "standard" chemotherapy. *American journal of clinical oncology*. 1995;18(2):144-148.

[86] Mella O, Dahl O, Bang G, Engedal H, Gøthlin J, Lunde OD. Chemotherapy of a malignant, metastasizing giant-cell tumor of bone: report of an unusual case and the response to combination chemotherapy. *Cancer*. 1982;50(2):207-211.

[87] Kaiser U, Neumann K, Havemann K. Generalised giant-cell tumour of bone: successful treatment of pulmonary metastases with interferon alpha, a case report. *Journal of cancer research and clinical oncology*. 1993;119(5):301-303.

[88] Wei F, Liu X, Liu Z, Jiang L, Dang G, Ma Q, et al. Interferon alfa-2b for recurrent and metastatic giant cell tumor of the spine: report of two cases. *Spine*. 2010;35(24):E1418-E1422.

[89] Efficacy and Safety of JMT103 in Patients With Giant Cell Tumor of Bone.

[90] LN-145 or LN-145-S1 in Treating Patients With Relapsed or Refractory

Ovarian Cancer, Anaplastic Thyroid Cancer, Osteosarcoma, or Other Bone and Soft Tissue Sarcomas.

[91] Tauro M, Lynch CC. Bone seeking matrix metalloproteinase-2 (MMP-2) inhibitors can prevent bone metastatic breast cancer. *Annals of Oncology*. 2019;30:iii60-iii1.

[92] Long-term Safety Follow-up of Subjects With Giant Cell Tumor of Bone Treated With Denosumab in Study 20062004.

[93] Safety and Efficacy of Post-operative Denosumab Strategy for Giant Cell Tumor of Bone Treatment in China.

[94] Study of XGEVA® (Denosumab) in Chinese Adults and Skeletally Mature Adolescents With Giant Cell Tumor of the Bone.

[95] Safety and Efficacy Study of Denosumab in Patients With Recurrent or Unresectable Giant Cell Tumor of Bone.

[96] Local Bisphosphonate Effect on Recurrence Rate in Extremity Giant Cell Tumor of Bone.

[97] Giant Cell Tumor of the Extremities Treated With Surgery and/or Medical Treatment.