

# We are IntechOpen, the world's leading publisher of Open Access books Built by scientists, for scientists

6,900

Open access books available

186,000

International authors and editors

200M

Downloads

Our authors are among the

154

Countries delivered to

TOP 1%

most cited scientists

12.2%

Contributors from top 500 universities



WEB OF SCIENCE™

Selection of our books indexed in the Book Citation Index  
in Web of Science™ Core Collection (BKCI)

Interested in publishing with us?  
Contact [book.department@intechopen.com](mailto:book.department@intechopen.com)

Numbers displayed above are based on latest data collected.  
For more information visit [www.intechopen.com](http://www.intechopen.com)



# Potency of SARS-CoV-2 on Ocular Tissues

*Saliha Durak, Hande Eda Sutova, Abuzer Alp Yetisgin,  
Ozlem Kutlu and Sibel Cetinel*

## Abstract

The current COVID-19 pandemic has affected more than 100 million people and resulted in morbidity and mortality around the world. Even though the disease caused by SARS-CoV-2 is characterized by respiratory tract involvement, previous and recent data also indicates ocular manifestation. Not surprisingly, cell entry point of the virus, ACE2 receptor, is widely expressed in ocular tissues ranging from conjunctiva to retina. Despite the sensibility of ocular tissues, the sophisticated defense mechanism of the eye might eliminate viral transmission. Nevertheless, the potential of systemic transmission through the nasolacrimal duct may not be eliminated. In the case of ocular involvement, the disease outcomes might be as treatable as conjunctivitis or as serious as retinal degeneration and the treatment regimen vary accordingly. Within these contingencies, our aim with this chapter is to shed light on molecular bases of SARS-CoV-2 infection, systemic invasiveness following ocular transmission, manifestation and permanent effects on ocular tissues.

**Keywords:** COVID-19, SARS-CoV-2, conjunctivitis, conjunctiva, retina, ACE2, TMPRSS2

## 1. Introduction

Coronaviruses are enveloped, positive-sense RNA viruses belonging to the subfamily Coronavirinae in the family Coronaviridae and cause serious respiratory ailments in humans [1]. In the last 20 years, three different types of coronavirus, including Middle-East respiratory syndrome coronavirus (MERS-CoV), severe acute respiratory syndrome coronavirus (SARS-CoV) and SARS-CoV-2, respectively, have caused severe respiratory tract infections and fatal outbreaks. SARS-CoV-2 emerged in Wuhan, China in December 2019 and has rapidly become an international health emergency [2]. In March 2020, the World Health Organization (WHO) has declared novel coronavirus disease 2019 (COVID-19) pandemic.

SARS-CoV-2 uses the angiotensin-converting enzyme 2 (ACE2) receptor for viral entry, as in SARS-CoV [3]. One of the major structural proteins, the glycoprotein Spike (S) of the SARS-CoV-2 binds to surface receptor (ACE2) of the host cell and mediates viral entry. S protein is composed of two domains; S1 domain contains receptor-binding region, while S2 domain manages viral fusion with the membrane of the host cell. Host transmembrane protease serine type 2 (TMPRSS2) cleaves the S protein into S1 and S2 domains upon virus binding to ACE2 [3–5]. SARS-CoV-2 receptor binding and fusion of viral membrane and cell membrane initiate viral infection.

ACE2 protein is expressed in a variety of human organs and tissues, including ocular tissues ranging from conjunctiva to retina [6, 7]. Understanding the transmission paths of SARS-CoV-2 is crucial to prevent the viral spread. Current studies show that SARS-CoV-2 could be transmitted via direct contact or aerosol droplets. Ocular surfaces are possible viral entry and infection sites, or gateway for spread of the virus to the respiratory system [8, 9]. Although ocular symptoms are rare in COVID-19 patients, manifestations affecting the ocular surfaces such as conjunctivitis, epiphora, chemosis [10, 11], retinal hemorrhages, central retinal vein occlusion (CRVO), ischemia [12–15] as well as blurred vision and vision loss [16, 17] have been reported.

This chapter focuses on the presence and the effects of cellular receptors of SARS-CoV-2 on ocular tissues, evaluates the potential ocular transmission through the eyes, and discusses the short and long-term effects and manifestations of the virus on ocular surfaces at the molecular level.

## **2. ACE2 and TMPRSS2 expression profiles in ocular tissues**

In 2020, various cases of positive conjunctival swabs and conjunctivitis were reported as COVID-19 symptoms. Therefore, several researchers have investigated the ocular surfaces as a potential infection route for SARS-CoV-2 [18, 19]. To this end, intensive research focused on the presence of ACE2 and TMPRSS2 receptors in various ocular tissues since both receptors play important roles in the entry of SARS-CoV-2 to the host cells [20, 21].

ACE2 is an important component of Renin-Angiotensin System (RAS). The circulatory RAS is composed of certain enzymes and active-inactive peptides and plays crucial roles in human body including the regulation of blood pressure, fluid volumes and electrolyte homeostasis [22–27]. These regulations are controlled through the digestion of Angiotensinogen by Renin to generate Angiotensin I and transformation of Angiotensin I to the active form Angiotensin II by angiotensin-converting enzyme (ACE). Recently, Renin and ACE independent generation of Angiotensin II has also been reported [27]. In addition to the circulatory system, RAS is also found locally in some tissues and two separate research groups, Fischer-Ferraro *et al.* and Ganten *et al.* discovered the first clues on local RAS and its tissue-specific roles in 1971 [28, 29]. To date, local RAS has been reported in various organs such as brain, heart, intestine, kidney, and the eye [30, 31]. The presence of RAS in the eye suggested its involvement in various ocular diseases such as age-related macular degeneration (AMD), diabetic retinopathy, and glaucoma [22].

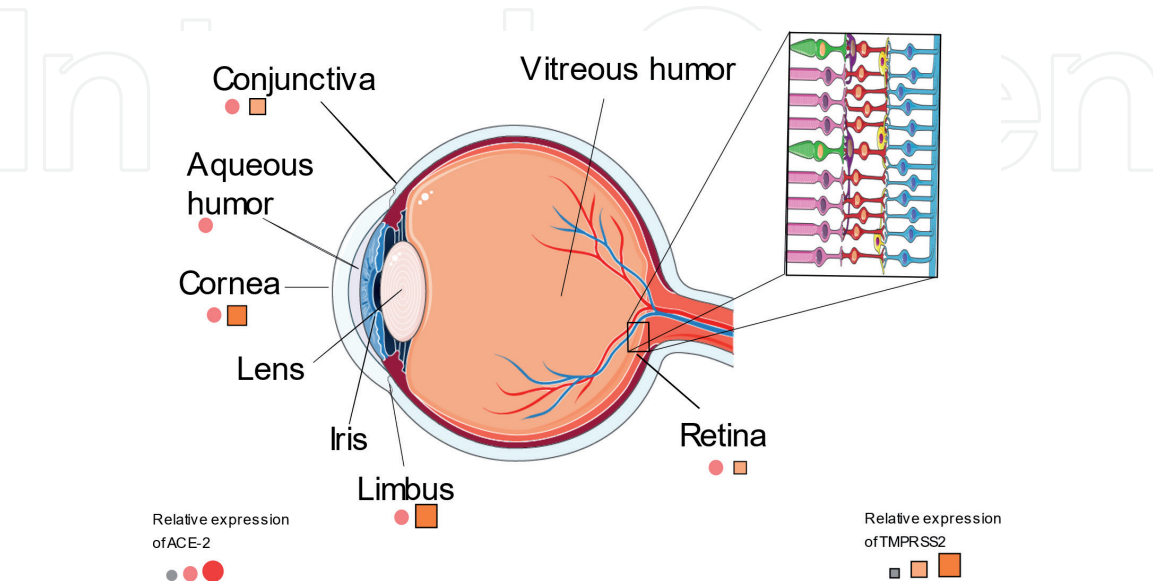
ACE2 is a carboxypeptidase found in circulatory system and in some tissues and regulates RAS negatively by cleaving angiotensin II [21]. This carboxypeptidase is structurally similar to angiotensin converting enzyme (ACE) with a 42% sequence similarity [32]. ACE2 was first discovered and cloned in 2000 as a counter-regulator of ACE, which generates Angiotensin (1–7) by cleaving a single residue from Angiotensin II or Angiotensin (1–9) by removing single residue from Angiotensin I [32–35]. In the eye, ACE2 expression has been demonstrated in a wide variety of ocular tissues, including aqueous humor, retina, corneal epithelium, conjunctival epithelium, and limbal epithelium [6, 7, 22]. ACE2 is found to decrease intraocular pressure (IOP) upon activation with chemical inducers [36].

In addition to ACE2, recent studies showed that TMPRSS2 receptor was also contributing to the cell entry of SARS-CoV-2 by cleaving the spike protein after its' binding to ACE2 receptor [6, 37, 38]. TMPRSS2 is one of the serine proteases, involved in various physiological and pathological processes, including protein catabolism, blood coagulation and tissue rearrangement [39, 40]. As a homologous to enterokinase, the

function of TMPRSS2 is suggested to be similar to enterokinase that cleaves acidic pro-peptide from trypsinogen to generate active enzyme. However, exact physiological functions of TMPRSS2 are still not clear [40, 41]. Many ocular surfaces express TMPRSS2 receptor such as conjunctiva and corneal stroma [42].

Due to the important roles of ACE2 and TMPRSS2 in SARS-CoV-2 infection, their individual and co-expression in ocular tissues is investigated [43]. In an early study, local ACE2 expression in rodent retina was evaluated by using immunoblotting, immunohistochemistry analyses and mRNA levels. Expression of ACE2 was broadly localized in the inner nuclear layer and photoreceptors of rodent retinas [44]. Similarly, TMPRSS2 expression was also shown in the retina [45]. One of the most comprehensive studies on this subject was the investigation of coronavirus-2 (CoV-2) tropism in ocular tissues [6]. Here, co-expression of ACE2 receptor and TMPRSS2 protease was shown in human adult conjunctival, limbal and corneal epithelium but not in embryonic and fetal ocular tissues [6]. On the other hand, comparative RNA expression levels of ACE2 and TMPRSS2 in various tissues suggested ACE2 being the limiting factor for infection because TMPRSS2 expression showed a broader tissue distribution [46]. Similarly, expression of ACE2 and TMPRSS2 in post-mortem eyes of non-diabetic and diabetic retinopathy specimens revealed significantly strong expression of ACE2 in corneal and conjunctival epithelium while broad expression of TMPRSS2 in all ocular surfaces [42]. A comparable expression pattern with post-mortem eyes was found in five surgical conjunctival specimens as well, only with higher ACE2 staining intensity in the surgical specimen [42].

Co-expression profile of ACE2 and TMPRSS2 genes shows some contradicting expression profiles between human primary conjunctival and pterygium cells and different cell lines including ARPE-19, HUVEC, HaCaT, HepG2, and A549 [37]. For instance, persistent expression of ACE2 and TMPRSS were observed in conjunctival and pterygium cells of some patients, which was concluded not to be enough for SARS-CoV-2 cell entry [37]. In contrast, a significantly higher gene expression of TMPRSS2 and a lower but notable ACE2 gene expression in studied ocular (ARPE-19, HUVEC) and lung cell (A549) lines were observed [37]. Investigation of healthy and diseased conjunctival samples for mRNA expression levels of ACE2 and TMPRSS2, and ACE2 protein expression by immunostaining revealed ACE2 expression in conjunctival samples [47]. However, protein



**Figure 1.** Representative schematic of the relative expression profile of ACE2 and TMPRSS2 in ocular surfaces. (This schematic was created using Servier Medical Art templates, which are licensed under a Creative Commons Attribution 3.0 Unported License; <https://smart.servier.com>).



expression of ACE2 and other SARS-CoV-2 mediators of cell entry found not significant enough for the infection [47]. On the other hand, the expression of ACE2 and TMPRSS2 in ocular epithelium such as corneal epithelial cells, conjunctival epithelial cells and corneal endothelial cells is also reported. Herein, co-expression of ACE2 and TMPRSS2 in corneal epithelium and endothelium suggested the susceptibility of cornea for a potential SARS-CoV-2 infection site (**Figure 1**) [48].

### **3. Potential systemic invasiveness of SARS-CoV-2 following ocular transmission**

The three human coronaviruses, SARS-CoV, MERS-CoV, and SARS-CoV-2 are highly infectious compared to HCoV-229-E, HCoV-NL63, HCoV-OV43, and HCoV-HKU1, which infect upper respiratory tract with mild symptoms. On the other hand, SARS-CoV, MERS-CoV, and SARS-CoV-2 cause severe lower respiratory tract infection, which then leads to pneumonia [49]. The transmission mechanism of SARS-CoV and SARS-CoV-2 are similar in many aspects. These viruses could be transmitted with direct contact, droplet, or aerosolized particle contact with the eye surface, nose, and mouth [9]. SARS-CoV and SARS-CoV-2 are genetically similar as well. However, the number of patients infected with SARS-CoV-2 is hundreds of times higher, indicating a significantly higher transmission rate compared to SARS-CoV and MERS-CoV [50]. It's also recently shown that the rate of SARS-CoV-2 replication in conjunctiva is higher than SARS-CoV and MERS-CoV [51].

Potency of viral infections are mainly affected by the virus invasiveness, receptor repertoire of the host cell membrane, and the immune system response. The first step for the viral invasion is the binding of the virus to the host cell by its receptors [52]. Glycoproteins and spike proteins are well-known proteins for all coronaviruses that bind to the receptor of the host cell and trigger the viral entry. The spike proteins are encoded in  $\beta$ -coronaviruses and today, it has been known that SARS-CoV-2 spike protein has the receptor-binding domain, mediating the interaction with the host cell membrane receptor, ACE2 [53].

The eye is an organ representing a large surface area and could be easily exposed to external pathogenic factors. The large surface area of the eye is a potential landing zone for viral particles [54]. Importantly, the expression of TMPRSS2, CD147, ACE2, and CTSL proteins in ocular tissues indicate their potential as SARS-CoV-2 entry route [55–57]. Confirmed expression of ACE2 and TMPRSS2 in conjunctival and corneal tissues [46] suggest conjunctiva and cornea as ocular regions for SARS-CoV-2 entry [8, 49].

Ocular exposure may lead to systemic transmission of the SARS-CoV-2 virus via two pathways. In first pathway, cornea, conjunctiva, lacrimal gland, meibomian glands could be directly exposed to the infection. Particularly, the conjunctival tissue could be easily infected via droplets or a close contact with infected individuals and contaminated hands. Due to its potency as an entry site of viruses, conjunctiva is accepted as an important pathway for infection of the respiratory viruses [52]. In second pathway, virus in tear can migrate through the nasolacrimal duct and infect the nasal or gastrointestinal epithelium [9].

SARS-CoV-2 may indirectly enhance the possibility of ocular complications as well. For instance, the cytokine storm, vascular endothelial dysfunction, and hypercoagulability may lead to not only retinal microangiopathic changes but also congestion of the central retinal vessels, or micro-vascularization of the optic nerve head [14, 58, 59]. It has been also reported that SARS-CoV-2 led to paracentral

acute middle maculopathy and acute macular neuro-retinopathy [60, 61]. In May 2020, retinal changes in 12 adult COVID-19 patients were analyzed by using optical coherence tomography (OCT). Hyper-reflective lesions were observed at the ganglion cell level and interestingly, inner plexiform layers were found more prominently at the papillomacular bundle in both eyes [14]. A 40-year-old man diagnosed with SARS-CoV-2 infection reported that he had right calf pain and blurred vision in both eyes. His ophthalmic exam revealed retinal vein occlusion (RVO) on both eyes, indicating COVID-19 as a potential cause for RVO [12].

On the other hand, the viral infection can occur at the upper respiratory tract and viruses can migrate to the nasolacrimal duct and to the conjunctiva, resulting in viral conjunctivitis [62]. Furthermore, SARS-CoV-2 infection via the conjunctival tissues may also occur in non-human primates that the SARS-CoV-2 inoculation has been shown to cause mild COVID-19 in rhesus macaques [63].

### 3.1 Natural ocular defense mechanisms

The eye has natural anatomical and physiological protection mechanisms that prevent the entry of large amounts of virus-loaded particles to the ocular surface [64]. The eye has three defense mechanisms against different types of microorganisms and toxic substances. These are; mechanical, immunological, and anatomical defense mechanisms which are critical to recognize and eliminate the pathogens from the ocular surface for eye protection [65].

**Mechanical defense** system is composed of eyelids, eyelashes, corneal epithelium containing tight intercellular junctions, and conjunctival mucosa. Corneal epithelial cells also protect the ocular surface by secreting cytokines and causing immune defense activation against the viral invasion [65]. Eyelid protects the eye surface against any mechanical injury. When the eyelids and lashes are closed, the eye is also protected from any exposure of pathogens and other foreign molecules such as dust, dirt, and any other debris [66].

**Anatomical defense system** is based on the barriers of anterior and posterior segments of the eye. The drugs administered to the eye are extensively drained by the precorneal barriers present in the anterior segment (around 90%) and tears migrate through the nasolacrimal duct [67]. Aqueous humor is secreted by the ciliary body and the flow direction of the aqueous humor is towards the cornea, which is an opposite direction of topically administered drug. The aqueous humor can be a limiting factor for the drugs to show therapeutic effects. Sclera presents at the posterior segment of the eye and protects the eye from the exogenous substances. Surface charge, physicochemical properties, and molecular radius are the parameters affecting the drug permeability across sclera. The drug with greater molecular radius and lipophilicity can lead to inhibition of permeation across sclera [67]. On the other hand, the pathogens are also cleaned from the ocular surface with the lacrimal drainage system. However, this physical self-cleaning system may cause SARS-CoV-2 infection via the migration of infected tears throughout the nasolacrimal drainage system and this passage can function as an alternative entry route of the virus from ocular surface to the respiratory tract [68].

**Immune defense** at the ocular surface is important for preservation of the eye. Particularly, cornea has a variety of defense mechanisms; classified as native, nonspecific, and acquired immunological defenses.

Innate immunity is the first line of defense mechanism in corneal infection; presents at birth and provides a nonspecific defense system [65]. This system can function in case of viral load and pathogenesis. Innate immune response is given at first encounter with the pathogen and can vary between different pathogens. For instance, among SARS-CoV viruses, the replication of the SARS-CoV-2 has been

more extensive in the bronchus than SARS-CoV and the higher plasma concentrations of proinflammatory cytokines have been observed in the SARS-CoV-2-infected patients [9].

Tears, corneal nerves, epithelium, keratocytes, polymorphonuclear cells and some cytokines are other cellular and molecular elements for protection of cornea against microorganisms. The first function of tears is to keep the cornea not to be dried. Tears clean the foreign particles from the ocular surface and transports anti-microbial proteins lactoferrin, lysozyme, lipocalin, and beta-lysine to prevent the infections. In addition to these proteins, immunoglobulins protect the cornea from infections [65]. Lactoferrin is able to inhibit the binding of SARS-CoV-2 to ACE2, and IgA shows an effective immune response against different types of microorganisms [65, 69]. For instance, secreted IgA protects the corneal epithelium by binding to bacteria and prevents it from attaching to epithelium. Besides, IgG has the ability to bind bacteria and neutralize some viruses.

Corneal epithelial cells activate immune response by secreting cytokines to preserve the eye against microbial invasion. They store IL-1 $\alpha$  to release it passively, when the trauma or any foreign agent stimulates the membrane. Keratocytes synthesize IL-6 and defensins as a defense mechanism. IL-6 and IL-1 show a synergetic effect against microbial activity. Defensin has antimicrobial activity in ocular infections and induce epithelial healing. It is also found in neutrophils located in conjunctiva. Corneal nerves send sensory information and therefore control the reflexive movements for protection of the eye. Furthermore, several other eye complements, composed of a variety of effectors and regulatory proteins activating each other to produce biologically active molecules, such as opsonins, enzymes and chemotaxins [65].

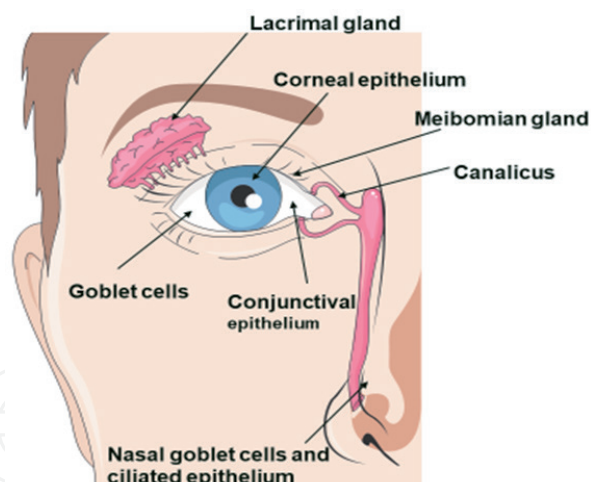
There are early and late defense stages of relevant innate and acquired immune responses. The immediate immune response takes minutes to several hours against microbial infection. When the innate immunity is unable to fight against the microorganisms or their antigens, acquired immunity can control microbial replication. Langerhans cells, antigen-presenting cells of the cornea, recognize the foreign antigen and can respond within 24–48 hours [65]. They recognize, process and present the antigens with MHC class II molecules, which are present on their surface. When they recognize an antigenic foreign molecule, they process the antigen and transport it to the surface by MHC molecules both class I and class II. The presentation of peptides by MHC molecules activates T cells and T-cell receptors, which then lead to the binding of MHC molecules to each other. If the MHC II molecule presents the antigen, then CD4 helper T cells kill the pathogen by secretion of cytokines that activates the other effector cells such as macrophages [65].

### **3.2 Nasolacrimal duct can play a role in SARS-CoV-2 systemic transmission**

The human tear ducts consist of the upper and lower lacrimal canaliculus, lacrimal sac, and nasolacrimal duct (**Figure 2**) [70]. The nasolacrimal system functions as a bridge between the ocular surface mucosa and upper respiratory tract for migration of the viruses with the help of tears to the inferior meatus of the nose. It allows the virus to move from the ocular surface to the respiratory tract throughout the nasolacrimal duct [52, 71]. The fluid may be taken up by the conjunctiva, sclera, or cornea but the highest percent of the liquid is drained into the nasopharyngeal space. Additionally, the epithelial lining of the lacrimal duct can absorb the tear fluid, which allows immunizing agents to be drained to nasal tissue [72].

In addition to the above-mentioned functions of nasolacrimal duct, it has a role in nonspecific immune defense. Nasolacrimal duct protects against dacryocystitis; thus, the epithelial cells produce a variety of antimicrobial substances, such as





**Figure 2.**

*Representative schematic of ocular surface and tear ducts (This schematic was created using Servier Medical Art templates, which are licensed under a Creative Commons Attribution 3.0 Unported License; <https://smart.servier.com>).*

lysozyme and lactoferrin. In case of an infection or an inflammatory dacryocystitis, antimicrobial peptides human inducible beta defensins 2 and 3 are produced. Moreover, the secretory products of the mucus component mucins (MUC1, MUC2, MUC4, MUC5AC, MUC5B, and MUC7) are produced by goblet and epithelial cells. Mucins preserve mucosal surfaces against pathogenic substances. It has been observed that MUC5B protects the patient against the SARS-CoV-2. There is a lower allelic frequency of the MUC5B genetic variant in the COVID-19 patient's body compared the healthy people, which is related to a higher level of MUC5B expression [73]. On the other hand, the expression of MUC1 and the soluble mucin MUC5AC were observed in cells that also express ACE2, indicating that the mucins may function in entry and transmission of the SARS-CoV-2 [46, 74]. However, it was revealed that the increased levels of secreted MUC1 and MUC5AC in the sputum cleaned from the trachea of COVID-19 patients [75]. The epithelium present in the nasolacrimal duct produces TFF peptides TFF1 and TFF3. The efferent tear ducts also contain lymphocytes and other defense cells that function in adaptive immune mechanisms [70].

Nasolacrimal duct has common entry receptors for some respiratory viruses. For instance, the glycoproteins of host epithelial cell, carrying terminal sialic acid (SA), are distributed through the ocular tissue and the respiratory tract through the lacrimal passage. Thus, the patient becomes infected with pneumonia [71].  $\alpha$ 2-6-linked SA is significantly abundant in trachea and nasal mucosa, while  $\alpha$ 2-3-linked SA are more prominent in ocular tissues and the lower respiratory tract tissues [72]. There are several reports hypothesized that the exposure of the ocular surface to SARS-CoV-2 may lead to infection, because of the drainage of the virus particles via the nasolacrimal duct [76]. Siedlecki *et al.* has shown that SARS-CoV-2 can infect the ocular surface by migrating into the respiratory tract with the help of tears through the nasolacrimal duct [77]. Supporting to this, the highest expression level of SARS-CoV-2 entry factors was shown in nasal epithelial cells (clusters of goblet cells and ciliated cells), among all cells present in the respiratory tree [46]. Unlike all these infection routes, SARS-CoV-2 infection may also possible with the hematogenous spread from the lacrimal gland [8].

Consequently, the human eye has three roles in coronavirus infection. Firstly, it is one of the target organs for coronavirus infection. Secondly, the conjunctiva can function as a transporter for human coronavirus to enter the respiratory tract.



SARS-CoV-2 can reach to nasal mucosa with nasolacrimal epithelium, gastrointestinal tract, and systemic circulation by leaving the conjunctivitis [19]. Thirdly, conjunctival secretions and tears can function to spread human coronavirus [52].

4. SARS-CoV-2 related ocular manifestations

4.1 Ocular surface manifestations

Since ocular surfaces hold the potential for SARS-CoV-2 transmission, clinical research focusing the COVID-19-associated ocular symptoms have attracted great attention. Even though, the incidence of SARS-CoV-2 infection through ocular surfaces is low, ocular manifestations are various. Dry eyes, epiphora, hyperemia were the most prevalent symptoms in COVID-19 patients, while chemosis, photophobia and conjunctivitis are barely seen. Other reported ocular surface symptoms were conjunctival congestion, conjunctival secretions, foreign body sensations, blurred vision, itching/irritation, ocular pain, and eye redness. The prevalence of SARS-CoV-2 and profiling ocular symptoms related to COVID-19 are summarized in Table 1 by including 2660 patients from 43 independent studies [10–14, 16, 17, 59–61, 69, 78–108].

In a large study, including 535 patients, 5.0% of the patients (27 patients) displayed conjunctival congestion. Conjunctival congestion was in fact, the first symptom in four patients, which explains that ocular manifestations may be observed in early times of SARS-CoV-2 infection. However, SARS-CoV-2 nucleic acid could not be identified in ocular swabs. Other ocular manifestations were dry eye, blurred vision, foreign body sensation, tearing, itching, ocular pain and photophobia. Conjunctival congestion has lasted for  $5.9 \pm 4.5$  days among the patients and ofloxacin, tobramycin and ganciclovir eye drops were supplied for

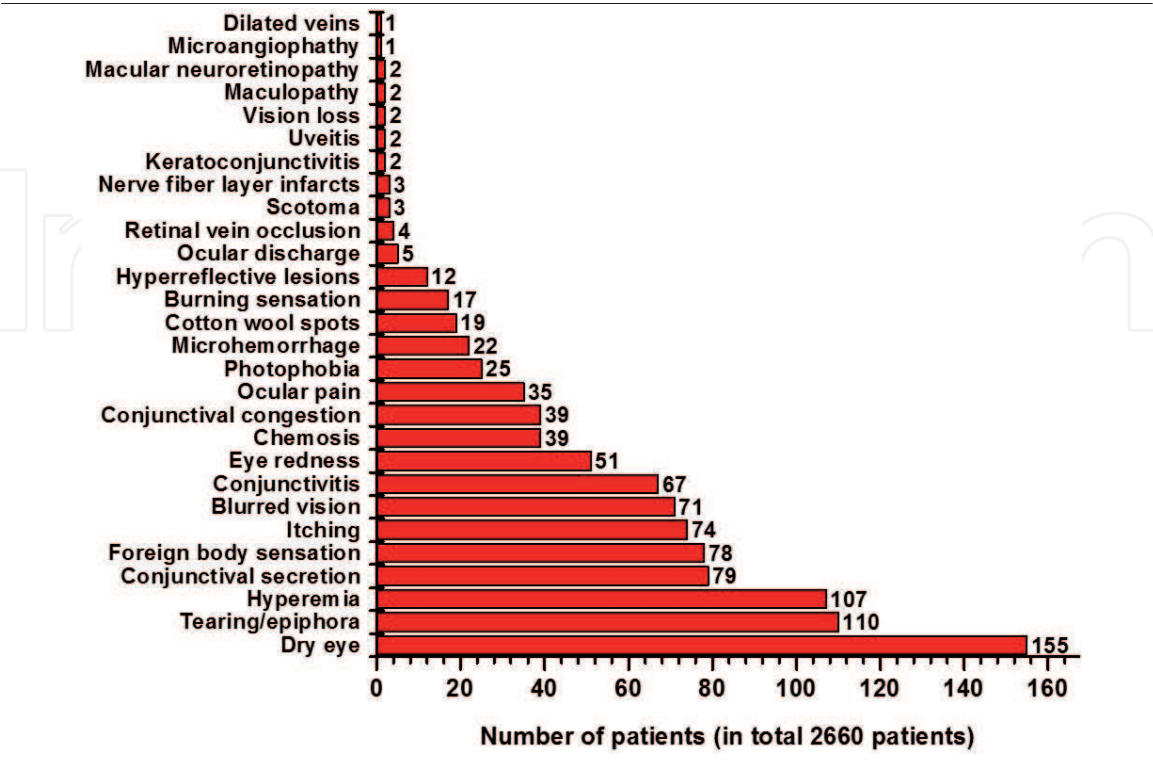


Table 1. The number of ocular findings observed in a total of 2660 patients with COVID-19 [10–14, 16, 17, 59–61, 69, 78–108].

treatment. Conjunctival congestion was a more widespread symptom in patients with frequent hand-eye contact [10].

In some studies, the presence of SARS-CoV-2 viral RNA on the ocular surfaces was confirmed. In February 2020, a study including 30 COVID-19 patients has declared SARS-CoV-2 nucleic acid in tear, conjunctival secretion as well as in sputum samples in one patient with conjunctivitis at the third day of the disease. The presence of the virus in the eye allowed speculation that transmission with the aerosols could be possible. However, this was one of the early studies and at that time there was not enough information about the transmission routes of virus [104]. In another study, involving 72 COVID-19 patients, conjunctivitis was detected in two patients (2.8%) and SARS-CoV-2 nucleic acid was identified in ocular discharges of one patient [106]. Detection of virus RNA in the eye suggests that the ocular pathway may be a gateway for viral transmission. In a case study, SARS-CoV-2 RNA was detected on the ocular swab of a woman with conjunctivitis at the third day of the COVID-19 diagnosis. Conjunctival samples were continuously taken on a daily basis and viral RNA was detected, despite in a decreasing curve for 21 days. However, the viral RNA became observable again 5 days after it became unobservable in the ocular swabs. To understand the presence of viral replication in the conjunctiva, researchers have inoculated the first positive viral RNA samples in Vero E6 cells and 5 days later, they have observed cytopathic effect and confirmed viral replication by RT-PCR with RNA purified from Vero E6 cell growth media [83].

On the other hand, SARS-CoV-2 viral RNA was also present in some patients without conjunctivitis. Viral RNA was detected in ocular swabs in two patients among 33 COVID-19 patients (6.1%) without any ocular manifestation [19]. In another study, including 121 patients diagnosed with COVID-19, ocular manifestations such as itching, tearing, redness, foreign body sensation and discharge were obtained in only eight patients (6.6%). Ocular swab was positive for SARS-CoV-2 RNA in one of them and in two patients without ocular manifestations [107]. The presence of SARS-CoV-2 on normal ocular surfaces may indicate that both symptomatic and asymptomatic ocular surface contact also has a risk of virus transmission.

There are several cases, where ocular manifestations were reported as the first presenting manifestation of COVID-19. A 65-year-old patient applied to ophthalmology department with a complaint of burning sensation and discharge for the last two days was diagnosed with conjunctivitis. After 2 days, the patient was admitted to the hospital with symptoms associated with COVID-19 and SARS-CoV-2 infection was confirmed with positive RT-PCR results of the nasopharyngeal and conjunctival swabs as well as computed tomography (CT) scanning of the lungs [88]. In a study, 12 out of 38 COVID-19 patients (31.6%) presented ocular symptoms, including conjunctivitis, hyperemia, epiphora, chemosis and increased secretions. SARS-CoV-2 nucleic acid was detected in conjunctival swabs of two patients. In these patients, conjunctivitis was the first symptom in one patient [11]. The occurrence of ocular symptoms primarily suggests that ocular surface is the potential transmission site of the virus in these patients.

Conjunctivitis could be seen in both early and late stages in the course of COVID-19. In February 2020, bilateral conjunctivitis, including redness, tearing and foreign body sensation was observed 13 days after the onset of the disease in a COVID-19 patient. Although the presence of SARS-CoV-2 nucleic acid was less in the nasopharyngeal and sputum swabs, it was confirmed in conjunctival swabs by RT-PCR at days 13, 14 and 17 in a gradually decreasing manner. Ribavirin eye drops helped the treatment of the symptoms and the RT-PCR test from ocular swabs turned negative on day 19 [82]. In a COVID-19 patient at intensive care unit, ocular symptoms started on the 17th day of the disease with conjunctival hyperemia and

clear secretions and pseudomembranous. On the 19th day, hemorrhagic conjunctivitis was defined, however, SARS-CoV-2 RNA was not detectable in the patient's conjunctival and tear samples. Azithromycin eyedrop and dexamethasone were used for treatment and ocular manifestations were started to decrease from day 21 [95]. Conjunctivitis, seen in the middle and late phases of the COVID-19, may have developed due to systemic viral infection or auto-inflammatory and autoimmune responses. Considering the nasolacrimal duct forms a connection between the eye and the respiratory tract; it is likely that the virus in the respiratory tract may subsequently infect the eye. The fact that ACE2 receptor is expressed predominantly in the respiratory tract than epithelial cells in the eye surface confirms this theory.

In the first study where keratoconjunctivitis was reported as the main symptom of COVID-19, virus was detected in ocular swabs with much lower titers than respiratory swabs. The corneal findings in this case involved pseudodendrite, subepithelial infiltrate and multiple epithelial defects spreading through the cornea [81]. The first case of COVID-19 related acute anterior uveitis associated with acute follicular conjunctivitis and conjunctival hyperemia was reported in Italy. Acute anterior uveitis was characterized by bilateral eye redness lasting two weeks, unilateral photophobia, lacrimation, miosis, aqueous humour flare and anterior lens opacity causing blurred vision [16].

The low rate of ocular symptoms seen in patients with COVID-19 may be due to the under diagnosis. Particularly, for the diagnosis of conjunctivitis, an ophthalmologist is required. Otherwise, disease can be unnoticed and treated silently during systemic COVID-19 treatment regimen. Besides, since the ocular inoculation of SARS-CoV-2 cannot be fully elucidated, sampling time in the course of disease may also be a factor affecting detection of the presence of the virus on ocular surfaces. Since the virus may have been eliminated by ocular defense mechanisms or may have already entered the respiratory tract, the duration time of the virus on ocular surfaces may be very short. The sensitivity threshold of RT-PCR, which is the conventional method used to confirm the presence of the virus, may also cause false negative results. However, in order to declare that conjunctivitis occurs due to SARS-CoV-2 infection, virus detection through ocular swabs is mandatory since conjunctivitis may be of different viral, bacterial and allergic origin in patients with COVID-19. It should also be taken into account that ocular manifestations may be the only symptoms of the COVID-19.

#### **4.2 Retinal findings in patients with COVID-19**

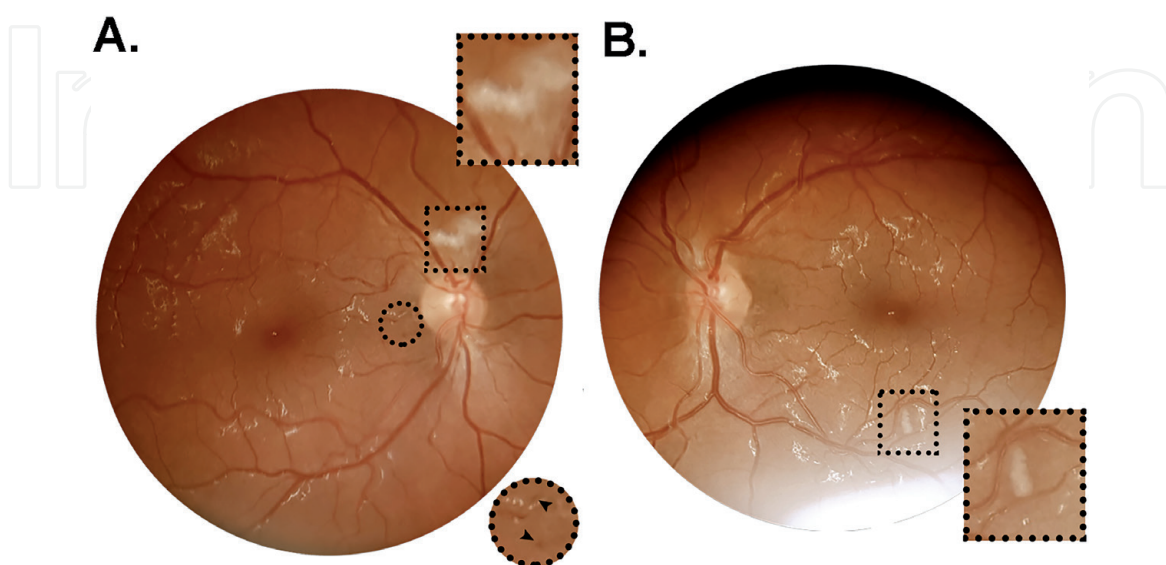
In viral infections, the cytopathic effect of the viral agent on retinal cells or damage to the retinal vasculature are common pathological findings of the retina. Systemic damage caused by SARS-CoV-2 made it necessary to enlighten additional viral involvement sites in addition to the respiratory system. Presence of ACE2 in aqueous humor [7] and retina [15] has allowed researchers to raise query on the possible injury caused by COVID-19 in the posterior part of the eye.

The first report published in May 2020 declaring COVID-19 related retinal alterations has paved the way for further studies. Retinal cotton wool spots and microhemorrhages in four patients as well as hyperreflective lesions at ganglion cell layer and inner plexiform layer in 12 patients was reported. Of the 12 patients, three had high blood pressure, one had diabetes and one had dyslipidemia. Examination was performed on 11–33 days after the onset of COVID-19 symptoms using optical coherence tomography (OCT). Intraocular inflammation was not noticed in any of the patients, however the presence of SARS-CoV-2 in the intraocular fluids was not tested in this study [14]. Similarly, in another study, 10 out of 18 intensive care unit patients had retinal abnormalities characterized by cotton wool spots, flame-shaped



hemorrhages, peripheral retinal hemorrhages, macular hemorrhages, retinal pigment epithelium hyperplasia and choroidal naevus. Nine of them had a history of diabetes and 12 of them had high blood pressure [96]. In another study of 25 patients, 3 patients (12%) displayed retinal changes including microhemorrhages, flame-shaped hemorrhage and nerve fiber layer infarcts (**Figure 3**). Retinal examinations were performed at 12–59 days after the onset of symptoms and only one patient had a medical history of hypertension. Another patient had hypotension, severe anemia, kidney and peripheral nervous system damage, which may explain microhemorrhages and nerve fiber layer infarcts [89]. These findings suggest that retinal alterations may occur depending on the patients' medical histories, yet it may also be due to the cytokine storm, which is developed as a result of immune response induced by COVID-19 and reaches to the retina by passing through the blood retina barrier.

In the fundus examination of a COVID-19 patient who was admitted to the hospital with the complaint of scotoma and decreased vision in one eye, fern-like retinal whitening, hyperreflective inner layers, increased venular tortuosity and retinal hemorrhages were found in the right eye and the patient was diagnosed with impending central retinal vein occlusion (iCRVO). After 10 days of treatment with steroids, patient's retinal changes and blood flow in central retinal vein almost returned to normal [87]. The iCRVO in this patient is thought to be due to the systemic response of COVID-19, as it can be treated with steroid therapy and the patient has no risk-bearing medical history. In the examination of a patient with lower leg pain and blurred vision in addition to common COVID-19 symptoms, deep venous thrombosis in the leg, bilateral CRVO, intraretinal hemorrhages, optic disk swelling, and cotton wool spots were detected. After 2 weeks of anticoagulant treatment, the patient's complaints returned to normal [12]. Similar to this, vascular occlusions may occur in the cases of hypertension, obesity and high cholesterol. In another study, bilateral cotton wool spots were detected on fundus examination during the late stage of COVID-19 in one patient, suffering an arcuate visual field defect in one eye. It was the first study to report COVID-19 induced vision loss. Retinal microvascular ischemia in the superficial plexus, which corresponded to the arcuate scotoma was detected by optical coherence tomography (OCT) angiography



**Figure 3.**  
 Retinal photograph of a patient with COVID-19. (A) Nerve fiber layer infarct above the optic nerve head, and microhemorrhages in the papillomacular bundle close to the optic disc was present in the right eye. (B) Nerve fiber layer infarcts at the inferior temporal vascular arcade, approximately 1.5-disc diameters inferior to the macula was present in the left eye. Reproduced from Reference [89] (CC BY 4.0).



[17]. These retinal changes can be related to microangiopathy and ischemia that are characterized in different anatomic parts in COVID-19 pathogenesis [109, 110].

In a study involving 54 COVID-19 patients, 15 patients had dilated veins, tortuous vessels was observed in seven patients, retinal hemorrhages in five patients, cotton wools spots in four patients and drusen in six patients were reported during fundus examination. Both mean artery diameters for severe cases and mean vein diameters for severe or non-severe cases were significantly higher in 54 COVID-19 patients, compared to 133 unexposed subjects [13]. Retinal vessel diameters and retinal circulation are parallel to the systemic circulation. Alterations in the retinal vessels can provide an insight into alterations in other organs. Enlargement of the vessels can be explained by the increased blood supply and effect of inflammatory mediators together with the inflammatory response to COVID-19 or a direct effect of the SARS-CoV-2 to endothelium. Moreover, two patients with COVID-19 had paracentral acute middle maculopathy and acute macular neuroretinopathy accompanied by scotoma [60]. In another study, scotoma, acute vision loss and several retinal hemorrhages related with acute macular neuroretinopathy and paracentral acute middle maculopathy were reported in one patient [61]. It has been reported that paracentral acute middle maculopathy is associated with the reduced blood supply to intermediate, deep, superficial capillary plexuses and acute macular neuroretinopathy is associated with the reduced blood supply to deep capillary plexus [111].

Venous thromboembolism is also a reported condition in COVID-19 patients; however, it is not known whether this is caused by the direct effect of the virus or the inflammatory response of the COVID-19. Cotton wool spots are characterized by disruption of axoplasmic flow in nerve tissue layer due to microvascular occlusion, and retina is extremely sensitive to ischemic events in the body. Considering the thrombotic conditions caused in COVID-19 patients, it can be thought that cotton wool spots in the retina are a result of the occlusion of terminal retinal arterioles.

The fact that the SARS-CoV-2 affects the central nervous system [112, 113] and the presence of its nucleic acid in retina [114] suggests that as a part of central nervous system, retina may be directly affected by the virus. Considering that the effect of SARS-CoV-2 on the central nervous system also effects the vital organ brain, non-invasive retinal examinations could be a prediction of the scope of COVID-19 in other organs like brain and heart, which has been implemented before for different diseases such as stroke, Alzheimer disease, multiple sclerosis and Parkinson disease [115].

In some studies, there was no link between retinal findings and ocular surface changes suggesting that retinal findings may be a marker of systemic alterations, and thus the importance of fundus examination should not be underestimated even in patients without any ocular complaints during the COVID-19 pandemic.

### **4.3 COVID-19 related expected long-term effects on eye**

Ocular manifestations of COVID-19 range from redness to acute anterior uveitis on the anterior segment of the eye and from microhemorrhages to retinal microvascular ischemia on the retina. Some of these manifestations may cause vision loss and blurred vision.

Retinal changes such as damage of retinal cells or retinal vasculature may be the precursor of a long-term retinal disease. When the peripapillary vascular impairment is compared between the control group and patients recovered from COVID-19, lower radial peripapillary capillary plexus perfusion density and reduced blood supply to peripapillary retinal nerve fiber layer were present in

post COVID-19 patients [98]. Older and systemic hypertensive patients were more prone to this microvascular damage. The radial peripapillary capillary plexus is very important for function of the retinal ganglion cells and axons and it is related to nerve fiber layer thickness and visual field loss in glaucoma [116]. Decrease in radial peripapillary capillary plexus density and nerve fiber layer thinning have been characterized in patients with early stage of glaucoma [117, 118]. Besides, it is more prominent in patients with glaucoma for more than ten years than in patients with glaucoma less than ten years [119]. However, whether the peripapillary capillary changes in patients with COVID-19 are reversible will be seen in further studies. Although these patients are at risk of developing glaucoma in the future, it should be kept in mind that there are several effective physiological parameters for disease development.

Looking at MERS and SARS outbreaks, it is difficult to predict the long-term ocular effect of COVID-19, due to the insufficient ocular findings and limited number of patients. Although different mechanisms cause the ocular effects of coronaviruses in animals, studies in animal models and understanding these mechanisms could give an idea about the long-term ocular effects of coronavirus in humans. Investigation of the effect of the coronavirus-related immune responses in retinal disease using experimental coronavirus retinopathy (ECOR) model indicated that levels of some cytokine molecules (TNF- $\alpha$ , TNF receptors) and signaling molecules (nitric oxide) increased in mice infected with murine coronavirus (mouse hepatitis virus) [120]. It was stated that TNF- $\alpha$  induction of nitric oxide may cause retina degeneration and loss of photoreceptor cells. In addition to that, following the primary immune response to virus, increased TNF receptor molecules and T cell reactivity may trigger autoimmunity.

The RAS system and its component ACE2 have important regulatory functions in the eye. ACE2 activation is known to reduce intraocular pressure [36]. Decreased expression of ACE2 to prevent viral spread can lead to misbalance of ACE-Angiotensin II/ACE-Angiotensin (1–7) balance, increase in intraocular pressure, vasoconstriction [61] and subsequently cause glaucoma. Hypothetically, in the light of this information, it is difficult to say that COVID-19 can cause a medium- or long-term serious ocular diseases such as glaucoma. However, ocular follow-up of COVID-19 patients with retinal symptoms may present whether these assumptions are justified as well as may benefit understanding virus tropism and immune responses to the virus.

## 5. Conclusion

With the emergence of SARS-CoV-2 in December 2019, the reporting of ocular symptoms observed in COVID-19 patients attracted many researchers and numerous publications were published in a short time to clarify the interaction between SARS-CoV-2 and the eye. Despite the fact that ocular symptoms present a low prevalence relative to respiratory and systemic symptoms, there is strong evidence for the ocular transmission of the SARS-CoV-2. The eye surfaces are one of the primary infection sites for SARS-CoV-2 and conjunctival secretions and tears can cause systemic spread of the virus. Additionally, the virus can use the ocular surfaces as a gateway to the respiratory tract.

Revealing the relationship between coronaviruses and the eye is of great importance in the diagnosis, treatment and infection control in both present and potential viral infections. Although many studies are investigating the ocular tropism of respiratory viruses, ocular transmission routes should be better understood in order to develop novel treatment methods such as antiviral agents that can be used in

ocular treatments against RNA viruses. Besides, non-invasive retinal examinations can be evaluated as a reflection of the patients' current systemic thrombotic condition and can be used in long-term patient follow-up related to COVID-19.

Considering that the first or only symptom of the COVID-19 may be conjunctivitis and virus can spread via tears even from asymptomatic patients, ophthalmologists and healthcare professionals should be aware of the risk and take necessary precautionary measures.

### **Conflict of interest**

The authors declare no conflict of interest.

### **Author details**

Saliha Durak<sup>1,2</sup>, Hande Eda Sutova<sup>1,2</sup>, Abuzer Alp Yetisgin<sup>1,3</sup>, Ozlem Kutlu<sup>1</sup> and Sibel Cetinel<sup>1\*</sup>

1 Nanotechnology Research and Application Center (SUNUM), Sabanci University, Istanbul, Turkey

2 Faculty of Engineering and Natural Sciences, Molecular Biology, Genetics and Bioengineering Program, Sabanci University, Istanbul, Turkey

3 Faculty of Engineering and Natural Sciences, Materials Science and Nano-Engineering Program, Sabanci University, Istanbul, Turkey

\*Address all correspondence to: cetinel@sabanciuniv.edu

### **IntechOpen**

© 2021 The Author(s). Licensee IntechOpen. This chapter is distributed under the terms of the Creative Commons Attribution License (<http://creativecommons.org/licenses/by/3.0>), which permits unrestricted use, distribution, and reproduction in any medium, provided the original work is properly cited. 

## References

- [1] Masters PS. The molecular biology of coronaviruses. *Adv Virus Res.* 2006;66:193-292.
- [2] Zhu N, Zhang D, Wang W, Li X, Yang B, Song J, et al. A Novel Coronavirus from Patients with Pneumonia in China, 2019. *New England Journal of Medicine.* 2020;382(8):727-33.
- [3] Hoffmann M, Kleine-Weber H, Schroeder S, Krüger N, Herrler T, Erichsen S, et al. SARS-CoV-2 Cell Entry Depends on ACE2 and TMPRSS2 and Is Blocked by a Clinically Proven Protease Inhibitor. *Cell.* 2020.
- [4] Tang T, Bidon M, Jaimes JA, Whittaker GR, Daniel S. *Coronavirus* membrane fusion mechanism offers a potential target for antiviral development. *Antiviral Research.* 2020;178:104792.
- [5] Walls AC, Park Y-J, Tortorici MA, Wall A, McGuire AT, Veesler D. Structure, Function, and Antigenicity of the SARS-CoV-2 Spike Glycoprotein. *Cell.* 2020;181(2):281-92.e6.
- [6] Collin J, Queen R, Zerti D, Dorgau B, Georgiou M, Djidrovski I, et al. Co-expression of SARS-CoV-2 entry genes in the superficial adult human conjunctival, limbal and corneal epithelium suggests an additional route of entry via the ocular surface. *The Ocular Surface.* 2020.
- [7] Holappa M, Valjakka J, Vaajanen A. Angiotensin(1-7) and ACE2, "The Hot Spots" of Renin-Angiotensin System, Detected in the Human Aqueous Humor. *Open Ophthalmol J.* 2015;9:28-32.
- [8] Ho D, Low R, Tong L, Gupta V, Veeraraghavan A, Agrawal R. COVID-19 and the Ocular Surface: A Review of Transmission and Manifestations. *Ocular Immunology and Inflammation.* 2020;28(5):726-34.
- [9] Barnett BP, Wahlin K, Krawczyk M, Spencer D, Welsbie D, Afshari N, et al. Potential of Ocular Transmission of SARS-CoV-2: A Review. *Vision.* 2020;4(3):40.
- [10] Chen L, Deng C, Chen X, Zhang X, Chen B, Yu H, et al. Ocular manifestations and clinical characteristics of 535 cases of COVID-19 in Wuhan, China: a cross-sectional study. *Acta Ophthalmologica.* 2020;98(8):e951-e9.
- [11] Wu P, Duan F, Luo C, Liu Q, Qu X, Liang L, et al. Characteristics of Ocular Findings of Patients With Coronavirus Disease 2019 (COVID-19) in Hubei Province, China. *JAMA Ophthalmol.* 2020;138(5):575-8.
- [12] Gaba WH, Ahmed D, Al Nuaimi RK, Dhanhani AA, Eatamadi H. Bilateral Central Retinal Vein Occlusion in a 40-Year-Old Man with Severe Coronavirus Disease 2019 (COVID-19) Pneumonia. *Am J Case Rep.* 2020;21:e927691-e.
- [13] Invernizzi A, Torre A, Parrulli S, Zicarelli F, Schiuma M, Colombo V, et al. Retinal findings in patients with COVID-19: Results from the SERPICO-19 study. *EClinicalMedicine.* 2020;27:100550.
- [14] Marinho PM, Marcos AAA, Romano AC, Nascimento H, Belfort R. Retinal findings in patients with COVID-19. *The Lancet.* 2020;395(10237):1610.
- [15] Senanayake Pd, Drazba J, Shadrach K, Milsted A, Rungger-Brandle E, Nishiyama K, et al. Angiotensin II and Its Receptor Subtypes in the Human Retina. *Investigative Ophthalmology & Visual Science.* 2007;48(7):3301-11.



- [16] Mazzotta C, Giancipoli E. Anterior Acute Uveitis Report in a SARS-CoV-2 Patient Managed with Adjunctive Topical Antiseptic Prophylaxis Preventing 2019-nCoV Spread Through the Ocular Surface Route. *Int Med Case Rep J*. 2020;13:513-20.
- [17] Gonzalez-Lopez JJ, Felix Espinar B, Ye-Zhu C. Symptomatic Retinal Microangiopathy in a Patient with Coronavirus Disease 2019 (COVID-19): Single Case Report. *Ocular Immunology and Inflammation*. 2020;1-3.
- [18] Leonardi A, Rosani U, Brun P. Ocular Surface Expression of SARS-CoV-2 Receptors. *Ocul Immunol Inflamm*. 2020;28(5):735-8.
- [19] Xie H-T, Jiang S-Y, Xu K-K, Liu X, Xu B, Wang L, et al. SARS-CoV-2 in the ocular surface of COVID-19 patients. *Eye and Vision*. 2020;7(1):23.
- [20] Aiello F, Gallo Afflitto G, Mancino R, Li JO, Cesareo M, Giannini C, et al. Coronavirus disease 2019 (SARS-CoV-2) and colonization of ocular tissues and secretions: a systematic review. *Eye (Lond)*. 2020;34(7):1206-11.
- [21] Hikmet F, Mear L, Edvinsson A, Micke P, Uhlen M, Lindskog C. The protein expression profile of ACE2 in human tissues. *Mol Syst Biol*. 2020;16(7):e9610.
- [22] Choudhary R, Kapoor MS, Singh A, Bodakhe SH. Therapeutic targets of renin-angiotensin system in ocular disorders. *J Curr Ophthalmol*. 2017;29(1):7-16.
- [23] Holappa M, Vapaatalo H, Vaajanen A. Many Faces of Renin-angiotensin System - Focus on Eye. *Open Ophthalmol J*. 2017;11:122-42.
- [24] Medina-Enriquez MM, Lopez-Leon S, Carlos-Escalante JA, Aponte-Torres Z, Cuapio A, Wegman-Ostrosky T. ACE2: the molecular doorway to SARS-CoV-2. *Cell Biosci*. 2020;10(1):148.
- [25] Mirabito Colafella KM, Bovee DM, Danser AHJ. The renin-angiotensin-aldosterone system and its therapeutic targets. *Exp Eye Res*. 2019;186:107680.
- [26] Paz Ocaranza M, Riquelme JA, Garcia L, Jalil JE, Chiong M, Santos RAS, et al. Counter-regulatory renin-angiotensin system in cardiovascular disease. *Nat Rev Cardiol*. 2020;17(2):116-29.
- [27] Oakes JM, Fuchs RM, Gardner JD, Lazartigues E, Yue X. Nicotine and the renin-angiotensin system. *American Journal of Physiology-Regulatory, Integrative and Comparative Physiology*. 2018;315(5):R895-R906.
- [28] Fischer-Ferraro C, Nahmod VE, Goldstein DJ, Finkielman S. Angiotensin and renin in rat and dog brain. *J Exp Med*. 1971;133(2):353-61.
- [29] Ganten D, Marquez-Julio A, Granger P, Hayduk K, Karsunky KP, Boucher R, et al. Renin in dog brain. *Am J Physiol*. 1971;221(6):1733-7.
- [30] Wagner J, Jan Danser AH, Derkx FH, de Jong TV, Paul M, Mullins JJ, et al. Demonstration of renin mRNA, angiotensinogen mRNA, and angiotensin converting enzyme mRNA expression in the human eye: evidence for an intraocular renin-angiotensin system. *Br J Ophthalmol*. 1996;80(2):159-63.
- [31] Holappa M, Vapaatalo H, Vaajanen A. Local ocular renin-angiotensin-aldosterone system: any connection with intraocular pressure? A comprehensive review. *Ann Med*. 2020;52(5):191-206.
- [32] Luhtala S, Vaajanen A, Oksala O, Valjakka J, Vapaatalo H. Activities of angiotensin-converting enzymes ACE1

- and ACE2 and inhibition by bioactive peptides in porcine ocular tissues. *J Ocul Pharmacol Ther.* 2009;25(1):23-8.
- [33] Tipnis SR, Hooper NM, Hyde R, Karran E, Christie G, Turner AJ. A human homolog of angiotensin-converting enzyme. Cloning and functional expression as a captopril-insensitive carboxypeptidase. *J Biol Chem.* 2000;275(43):33238-43.
- [34] Imai Y, Kuba K, Penninger JM. The discovery of angiotensin-converting enzyme 2 and its role in acute lung injury in mice. *Exp Physiol.* 2008;93(5):543-8.
- [35] Chhabra KH, Chodavarapu H, Lazartigues E. Angiotensin converting enzyme 2: a new important player in the regulation of glycemia. *IUBMB Life.* 2013;65(9):731-8.
- [36] Foureaux G, Nogueira BS, Coutinho DC, Raizada MK, Nogueira JC, Ferreira AJ. Activation of endogenous angiotensin converting enzyme 2 prevents early injuries induced by hyperglycemia in rat retina. *Braz J Med Biol Res.* 2015;48(12):1109-14.
- [37] Ma D, Chen CB, Jhanji V, Xu C, Yuan XL, Liang JJ, et al. Expression of SARS-CoV-2 receptor ACE2 and TMPRSS2 in human primary conjunctival and pterygium cell lines and in mouse cornea. *Eye (Lond).* 2020;34(7):1212-9.
- [38] Rahman N, Basharat Z, Yousuf M, Castaldo G, Rastrelli L, Khan H. Virtual Screening of Natural Products against Type II Transmembrane Serine Protease (TMPRSS2), the Priming Agent of Coronavirus 2 (SARS-CoV-2). *Molecules.* 2020;25(10).
- [39] Szabo R, Bugge TH. Type II transmembrane serine proteases in development and disease. *Int J Biochem Cell Biol.* 2008;40(6-7):1297-316.
- [40] Vaarala MH, Porvari KS, Kellokumpu S, Kyllönen AP, Vihko PT. Expression of transmembrane serine protease TMPRSS2 in mouse and human tissues. *J Pathol.* 2001;193(1):134-40.
- [41] Antalis TM, Bugge TH, Wu Q. Membrane-anchored serine proteases in health and disease. *Prog Mol Biol Transl Sci.* 2011;99:1-50.
- [42] Zhou L, Xu Z, Castiglione GM, Soiberman US, Eberhart CG, Duh EJ. ACE2 and TMPRSS2 are expressed on the human ocular surface, suggesting susceptibility to SARS-CoV-2 infection. *Ocul Surf.* 2020;18(4):537-44.
- [43] Zhang BN, Wang Q, Liu T, Dou SQ, Qi X, Jiang H, et al. A special on epidemic prevention and control: analysis on expression of 2019-nCoV related ACE2 and TMPRSS2 in eye tissues. *Zhonghua Yan Ke Za Zhi.* 2020;56(6):438-46.
- [44] Tikellis C, Johnston CI, Forbes JM, Burns WC, Thomas MC, Lew RA, et al. Identification of angiotensin converting enzyme 2 in the rodent retina. *Current Eye Research.* 2004;29(6):419-27.
- [45] Schnichels S, Rohrbach JM, Bayyoud T, Thaler S, Ziemssen F, Hurst J. Can SARS-CoV-2 infect the eye? An overview of the receptor status in ocular tissue. *Der Ophthalmologe.* 2021;118(1):81-4.
- [46] Sungnak W, Huang N, Bécavin C, Berg M, Queen R, Litvinukova M, et al. SARS-CoV-2 entry factors are highly expressed in nasal epithelial cells together with innate immune genes. *Nature Medicine.* 2020;26(5):681-7.
- [47] Lange C, Wolf J, Auw-Haedrich C, Schlecht A, Boneva S, Lapp T, et al. Expression of the COVID-19 receptor ACE2 in the human conjunctiva. *J Med Virol.* 2020;92(10):2081-6.

- [48] Roehrich H, Yuan C, Hou JH. Immunohistochemical Study of SARS-CoV-2 Viral Entry Factors in the Cornea and Ocular Surface. *Cornea*. 2020;39(12):1556-62.
- [49] Ocansey S, Abu EK, Abraham CH, Owusu-Ansah A, Boadi-Kusi SB, Ilechie AA, et al. Ocular Symptoms of SARS-CoV-2: Indication of Possible Ocular Transmission or Viral Shedding. *Ocul Immunol Inflamm*. 2020;28(8):1269-79.
- [50] Chen Y, Liu Q, Guo D. Emerging coronaviruses: Genome structure, replication, and pathogenesis. *J Med Virol*. 2020;92(4):418-23.
- [51] Hui KPY, Cheung M-C, Perera RAPM, Ng K-C, Bui CHT, Ho JCW, et al. Tropism, replication competence, and innate immune responses of the coronavirus SARS-CoV-2 in human respiratory tract and conjunctiva: an analysis in ex-vivo and in-vitro cultures. *The Lancet Respiratory Medicine*. 2020;8(7):687-95.
- [52] Sun C-B, Wang Y-Y, Liu G-H, Liu Z. Role of the Eye in Transmitting Human Coronavirus: What We Know and What We Do Not Know. *Front Public Health*. 2020;8:155-.
- [53] Yang Y, Peng F, Wang R, Yange M, Guan K, Jiang T, et al. The deadly coronaviruses: The 2003 SARS pandemic and the 2020 novel coronavirus epidemic in China. *J Autoimmun*. 2020;109:102434.
- [54] Coroneo MT. The eye as the discrete but defensible portal of coronavirus infection. *The ocular surface*. 2020:S1542-0124(20)30089-6.
- [55] Huet E, Vallée B, Delbé J, Mourah S, Prulière-Escabasse V, Tremouillères M, et al. EMMPRIN modulates epithelial barrier function through a MMP-mediated occludin cleavage: implications in dry eye disease. *Am J Pathol*. 2011;179(3):1278-86.
- [56] Kitazawa K, Hikichi T, Nakamura T, Mitsunaga K, Tanaka A, Nakamura M, et al. OVOL2 Maintains the Transcriptional Program of Human Corneal Epithelium by Suppressing Epithelial-to-Mesenchymal Transition. *Cell Rep*. 2016;15(6):1359-68.
- [57] Redzic JS, Armstrong GS, Isern NG, Jones DN, Kieft JS, Eisenmesser EZ. The retinal specific CD147 Ig0 domain: from molecular structure to biological activity. *J Mol Biol*. 2011;411(1):68-82.
- [58] Karampelas M, Dalamaga M, Karampela I. Does COVID-19 Involve the Retina? *Ophthalmology and Therapy*. 2020;9(4):693-5.
- [59] Landecho MF, Yuste JR, Gándara E, Sunsundegui P, Quiroga J, Alcaide AB, et al. COVID-19 retinal microangiopathy as an in vivo biomarker of systemic vascular disease? *Journal of Internal Medicine*. 2021;289(1):116-20.
- [60] Virgo J, Mohamed M. Paracentral acute middle maculopathy and acute macular neuroretinopathy following SARS-CoV-2 infection. *Eye (Lond)*. 2020;34(12):2352-3.
- [61] Gascon P, Briantais A, Bertrand E, Ramtohl P, Comet A, Beylerian M, et al. Covid-19-Associated Retinopathy: A Case Report. *Ocular Immunology and Inflammation*. 2020;28(8):1293-7.
- [62] Brandão-de-Resende C, Diniz-Filho A, de Almeida Brito F, Vasconcelos-Santos DV. SARS-CoV-2 and COVID-19 for the ophthalmologist. *Clinical & Experimental Ophthalmology*. n/a(n/a).
- [63] Deng W, Bao L, Gao H, Xiang Z, Qu Y, Song Z, et al. Ocular conjunctival inoculation of SARS-CoV-2 can cause mild COVID-19 in rhesus macaques.



Nature Communications.  
 2020;11(1):4400.

[64] Zimmerman K, Kearns F, Tzekov R. Natural protection of ocular surface from viral infections - A hypothesis. *Med Hypotheses*. 2020;143:110082.

[65] Akpek EK, Gottsch JD. Immune defense at the ocular surface. *Eye*. 2003;17(8):949-56.

[66] Maurizio Rolando M, Manfred Zierhut, MD. *The Ocular Surface and Tear Film and Their Dysfunction in Dry Eye Disease*. 2001.

[67] Cholkar K, Dasari SR, Pal D, Mitra AK. Eye: anatomy, physiology and barriers to drug delivery. *Ocular Transporters and Receptors* 2013. p. 1-36.

[68] Napoli PE, Nioi M, d'Aloja E, Fossarello M. The Ocular Surface and the Coronavirus Disease 2019: Does a Dual 'Ocular Route' Exist? *Journal of clinical medicine*. 2020;9(5):1269.

[69] Güemes-Villahoz N, Burgos-Blasco B, Arribi-Vilela A, Arriola-Villalobos P, Rico-Luna CM, Cuiña-Sardiña R, et al. Detecting SARS-CoV-2 RNA in conjunctival secretions: Is it a valuable diagnostic method of COVID-19? *Journal of Medical Virology*. 2021;93(1):383-8.

[70] Paulsen F, Garreis F, Schicht M, Bräuer L, Ali MJ, Sel S. [Anatomy and physiology of the nasolacrimal ducts]. *Hno*. 2016;64(6):354-66.

[71] Chen X, Yu H, Mei T, Chen B, Chen L, Li S, et al. SARS-CoV-2 on the ocular surface: is it truly a novel transmission route? *Br J Ophthalmol*. 2020.

[72] Belser JA, Rota PA, Tumpey TM. Ocular tropism of respiratory viruses. *Microbiol Mol Biol Rev*. 2013;77(1):144-56.

[73] van Moorsel CH, van der Vis JJ, Benschop C, Ruven HJ, Quanjel M, Grutters JC. The MUC5B promotor polymorphism associates with severe Covid-19. *medRxiv*. 2020.

[74] Smith JCS, Erin L., Girish VY, Monet Lou, John KMS, Jason M. Cigarette smoke triggers the expansion of a subpopulation of respiratory epithelial cells that express the SARS-CoV-2 receptor ACE2. 2020.

[75] Lu W, Liu X, Wang T, Liu F, Zhu A, Lin Y, et al. Elevated MUC1 and MUC5AC mucin protein levels in airway mucus of critical ill COVID-19 patients. *J Med Virol*. 2021;93(2):582-4.

[76] Qing H, Li Z, Yang Z, Shi M, Huang Z, Song J, et al. The possibility of COVID-19 transmission from eye to nose. *Acta Ophthalmol*. 2020;98(3):e388.

[77] Siedlecki J, Brantl V, Schworm B, Mayer WJ, Gerhardt M, Michalakakis S, et al. COVID-19: Ophthalmological Aspects of the SARS-CoV 2 Global Pandemic. *Klin Monbl Augenheilkd*. 2020;237(5):675-80.

[78] Abrishami M, Tohidinezhad F, Daneshvar R, Omidtabrizi A, Amini M, Sedaghat A, et al. Ocular Manifestations of Hospitalized Patients with COVID-19 in Northeast of Iran. *Ocul Immunol Inflamm*. 2020;28(5):739-44.

[79] Acharya S, Diamond M, Anwar S, Glaser A, Tyagi P. Unique case of central retinal artery occlusion secondary to COVID-19 disease. *IDCases*. 2020;21:e00867.

[80] Benito-Pascual B, Gegundez JA, Diaz-Valle D, Arriola-Villalobos P, Carreno E, Culebras E, et al. Panuveitis and Optic Neuritis as a Possible Initial Presentation of the Novel Coronavirus Disease 2019 (COVID-19). *Ocul Immunol Inflamm*. 2020;28(6):922-5.



- [81] Cheema M, Aghazadeh H, Nazarali S, Ting A, Hodges J, McFarlane A, et al. Keratoconjunctivitis as the initial medical presentation of the novel coronavirus disease 2019 (COVID-19). *Can J Ophthalmol*. 2020;55(4):e125-e9.
- [82] Chen L, Liu M, Zhang Z, Qiao K, Huang T, Chen M, et al. Ocular manifestations of a hospitalised patient with confirmed 2019 novel coronavirus disease. *Br J Ophthalmol*. 2020;104(6):748-51.
- [83] Colavita F, Lapa D, Carletti F, Lalle E, Bordi L, Marsella P, et al. SARS-CoV-2 Isolation From Ocular Secretions of a Patient With COVID-19 in Italy With Prolonged Viral RNA Detection. *Annals of internal medicine*. 2020;173(3):242-3.
- [84] Guan W-j, Ni Z-y, Hu Y, Liang W-h, Ou C-q, He J-x, et al. Clinical Characteristics of Coronavirus Disease 2019 in China. *New England Journal of Medicine*. 2020;382(18):1708-20.
- [85] Guo D, Xia J, Wang Y, Zhang X, Shen Y, Tong JP. Relapsing viral keratoconjunctivitis in COVID-19: a case report. *Virol J*. 2020;17(1):97.
- [86] Hong N, Yu W, Xia J, Shen Y, Yap M, Han W. Evaluation of ocular symptoms and tropism of SARS-CoV-2 in patients confirmed with COVID-19. *Acta Ophthalmologica*. 2020;98(5):e649-e55.
- [87] Invernizzi A, Pellegrini M, Messenio D, Cereda M, Olivieri P, Brambilla AM, et al. Impending Central Retinal Vein Occlusion in a Patient with Coronavirus Disease 2019 (COVID-19). *Ocular Immunology and Inflammation*. 2020;28(8):1290-2.
- [88] Khavandi S, Tabibzadeh E, Naderan M, Shoar S. *Corona* virus disease-19 (COVID-19) presenting as conjunctivitis: atypically high-risk during a pandemic. *Cont Lens Anterior Eye*. 2020;43(3):211-2.
- [89] Lani-Louzada R, Ramos CdVF, Cordeiro RM, Sadun AA. Retinal changes in COVID-19 hospitalized cases. *PLoS One*. 2020;15(12):e0243346.
- [90] Liang L, Wu P. There may be virus in conjunctival secretion of patients with COVID-19. *Acta Ophthalmologica*. 2020;98(3):223-.
- [91] Lim LW, Tan GS, Yong V, Anderson DE, Lye DC, Young B, et al. Acute Onset of Bilateral Follicular Conjunctivitis in two Patients with Confirmed SARS-CoV-2 Infections. *Ocul Immunol Inflamm*. 2020;28(8):1280-4.
- [92] Mahmut A, Boz AAE, Çınar BK, Çelik E, Yuvacı İs. Concomitant Ocular Diseases in Patients with SARS-CoV-2 Infection. *Sakarya Tıp Dergisi*.11(1): 137-41.
- [93] Marquezan MC, Marquezam JP, Nascimento H, Chalita MR, de Freitas D, Belfort R. Conjunctivitis Related to not Severe COVID-19: A Case Report. *Ocular Immunology and Inflammation*. 2020:1-3.
- [94] Meduri A, Oliverio GW, Mancuso G, Giuffrida A, Guarneri C, Venanzi Rullo E, et al. Ocular surface manifestation of COVID-19 and tear film analysis. *Scientific Reports*. 2020;10(1):20178.
- [95] Navel V, Chiambaretta F, Dutheil F. Haemorrhagic conjunctivitis with pseudomembranous related to SARS-CoV-2. *American Journal of Ophthalmology Case Reports*. 2020;19:100735.
- [96] Pereira LA, Soares LCM, Nascimento PA, Cirillo LRN, Sakuma HT, Veiga GLd, et al. Retinal

findings in hospitalised patients with severe COVID-19. *British Journal of Ophthalmology*. 2020;bjophthalmol-2020-317576.

[97] Pirraglia MP, Ceccarelli G, Cerini A, Visioli G, d'Ettorre G, Mastroianni CM, et al. Retinal involvement and ocular findings in COVID-19 pneumonia patients. *Scientific Reports*. 2020;10(1):17419.

[98] Savastano A, Crincoli E, Savastano MC, Younis S, Gambini G, Vico U, et al. Peripapillary Retinal Vascular Involvement in Early Post-COVID-19 Patients. *Journal of clinical medicine*. 2020;9.

[99] Scalinci SZ, Trovato Battagliola E. Conjunctivitis can be the only presenting sign and symptom of COVID-19. *IDCases*. 2020;20:e00774.

[100] Seah I, Agrawal R. Can the Coronavirus Disease 2019 (COVID-19) Affect the Eyes? A Review of Coronaviruses and Ocular Implications in Humans and Animals. *Ocular immunology and inflammation*. 2020;28(3):391-5.

[101] Sheth J, Narayanan R, Goyal J, Goyal V. Retinal vein occlusion in COVID-19: A novel entity. *Indian Journal of Ophthalmology*. 2020;68(10):2291-3.

[102] Valente P, Iarossi G, Federici M, Petroni S, Palma P, Cotugno N, et al. Ocular manifestations and viral shedding in tears of pediatric patients with coronavirus disease 2019: a preliminary report. *Journal of American Association for Pediatric Ophthalmology and Strabismus*. 2020;24(4):212-5.

[103] Wu P, Liang L, Chen C, Nie S. A child confirmed COVID-19 with only symptoms of conjunctivitis and eyelid dermatitis. *Graefes Arch Clin Exp Ophthalmol*. 2020;258(7):1565-6.

[104] Xia J, Tong J, Liu M, Shen Y, Guo D. Evaluation of coronavirus in tears and conjunctival secretions of patients with SARS-CoV-2 infection. *Journal of Medical Virology*. 2020;92(6):589-94.

[105] Ye Y, Song Y, Yan M, Hu C, Chen X, Yu J, et al. Novel coronavirus pneumonia combined with conjunctivitis: three cases report. *Chin J Exp Ophthalmol*. 2020;38(03):242-4.

[106] Zhang X, Chen X, Chen L, Deng C, Zou X, Liu W, et al. The evidence of SARS-CoV-2 infection on ocular surface. *The Ocular Surface*. 2020;18(3):360-2.

[107] Zhou Y, Duan C, Zeng Y, Tong Y, Nie Y, Yang Y, et al. Ocular Findings and Proportion with Conjunctival SARS-COV-2 in COVID-19 Patients. *Ophthalmology*. 2020;127(7):982-3.

[108] Zhou Y, Zeng Y, Tong Y, Chen C. Ophthalmologic evidence against the interpersonal transmission of 2019 novel coronavirus through conjunctiva. *medRxiv*; 2020.

[109] Danzi GB, Loffi M, Galeazzi G, Gherbesi E. Acute pulmonary embolism and COVID-19 pneumonia: a random association? *Eur Heart J*. 2020;41(19):1858.

[110] Iba T, Levy JH, Levi M, Connors JM, Thachil J. Coagulopathy of Coronavirus Disease 2019. *Critical Care Medicine*. 2020;48(9):1358-64.

[111] Chen Y-C, Chen S-N. Microvascular change in acute macular neuroretinopathy by using optical coherence tomography angiography. *Taiwan journal of ophthalmology*. 2019;9(2):118.

[112] Pryce-Roberts A, Talaei M, Robertson N. Neurological complications of COVID-19: a preliminary review. *Journal of Neurology*. 2020:1.

- [113] Paniz-Mondolfi A, Bryce C, Grimes Z, Gordon RE, Reidy J, Lednicky J, et al. Central nervous system involvement by severe acute respiratory syndrome coronavirus-2 (SARS-CoV-2). *Journal of medical virology*. 2020;92(7):699-702.
- [114] Casagrande M, Fitzek A, Püschel K, Aleshcheva G, Schultheiss H-P, Berneking L, et al. Detection of SARS-CoV-2 in Human Retinal Biopsies of Deceased COVID-19 Patients. *Ocular Immunology and Inflammation*. 2020:1-5.
- [115] London A, Benhar I, Schwartz M. The retina as a window to the brain—from eye research to CNS disorders. *Nature Reviews Neurology*. 2013;9(1):44.
- [116] Mammo Z, Heisler M, Balaratnasingam C, Lee S, Yu D-Y, Mackenzie P, et al. Quantitative Optical Coherence Tomography Angiography of Radial Peripapillary Capillaries in Glaucoma, Glaucoma Suspect, and Normal Eyes. *American Journal of Ophthalmology*. 2016;170:41-9.
- [117] Mansoori T, Sivaswamy J, Gamalapati JS, Balakrishna N. Radial peripapillary capillary density measurement using optical coherence tomography angiography in early glaucoma. *Journal of glaucoma*. 2017;26(5):438-43.
- [118] Jia Y, Simonett JM, Wang J, Hua X, Liu L, Hwang TS, et al. Wide-Field OCT Angiography Investigation of the Relationship Between Radial Peripapillary Capillary Plexus Density and Nerve Fiber Layer Thickness. *Investigative Ophthalmology & Visual Science*. 2017;58(12):5188-94.
- [119] Sefic S, Kasumovic A, Matoc I, Halimic T, Voloder B, Muhamedagic L, et al. Assessment of Perfused Peripapillary Capillaries and Peripapillary Capillary Density Maps in Glaucoma Patients. *Med Arch*. 2020;74(4):275-8.
- [120] Hooper LC, Chin MS, Detrick B, Hooks JJ. Retinal degeneration in experimental coronavirus retinopathy (ECOR) is associated with increased TNF- $\alpha$ , soluble TNFR2 and altered TNF- $\alpha$  signaling. *Journal of Neuroimmunology*. 2005;166(1):65-74.