

# We are IntechOpen, the world's leading publisher of Open Access books Built by scientists, for scientists

6,900

Open access books available

186,000

International authors and editors

200M

Downloads

Our authors are among the

154

Countries delivered to

TOP 1%

most cited scientists

12.2%

Contributors from top 500 universities



WEB OF SCIENCE™

Selection of our books indexed in the Book Citation Index  
in Web of Science™ Core Collection (BKCI)

Interested in publishing with us?  
Contact [book.department@intechopen.com](mailto:book.department@intechopen.com)

Numbers displayed above are based on latest data collected.  
For more information visit [www.intechopen.com](http://www.intechopen.com)



# Thoracoabdominal Compartment Syndrome

*Abdulaziz Shaher*

## Abstract

As we advance our knowledge in understanding abdominal compartment syndrome, it is worth going back to revisit our basic embryologic development of the main determinant of the abdominal and thoracic cavities, i.e., the diaphragm. The abdominal and thoracic cavities used to be one cavity at some stage of the embryonic life — “intraembryonic coelom” — before the “septum transversum” — diaphragmatic origin — divided it into two cavities. Therefore, if a condition develops that will impair the diaphragm from separating the cavities, leading to the possibility of pressures to transmit from one cavity to another, this becomes relevant as abdominal compartment syndrome. Diaphragmatic eventration is a congenital developmental defect in the muscular portion of the diaphragm with preserved attachments to the sternum, ribs, and dorsolumbar spine, leading to a semi-membranous diaphragm that anatomically separates the two cavities, but not physiologically. In the case of high abdominal pressure, the pressure will transmit to the thoracic cavity, causing derangement in both the anatomy and physiology. This was reported and named “Thoracoabdominal Compartment Syndrome”.

**Keywords:** Thoracoabdominal Compartment Syndrome, eventration, diaphragmatic paralysis, abdominal compartment syndrome

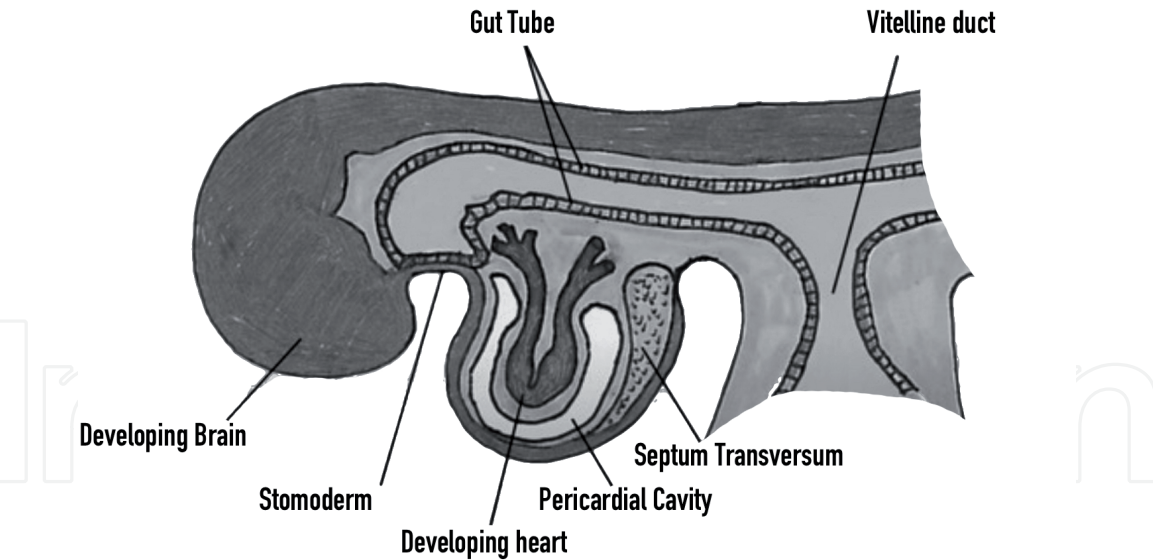
## 1. Introduction

The diaphragm is formed from a number of composite origins in the embryo. The most important is the “septum transversum”, which is a thick mass of cranial mesenchyme that gives rise to parts of the thoracic diaphragm. Without dwelling into more details, the septum transversum merges with mesoderm surrounding the esophagus, the growing pleura and peritoneum (‘pleuroperitoneal folds’) and the growing muscles of the abdominal wall. The septum transversum gives rise to the central tendon, while the pleuroperitoneal fold and abdominal wall muscles give rise to the muscular posterolateral parts.

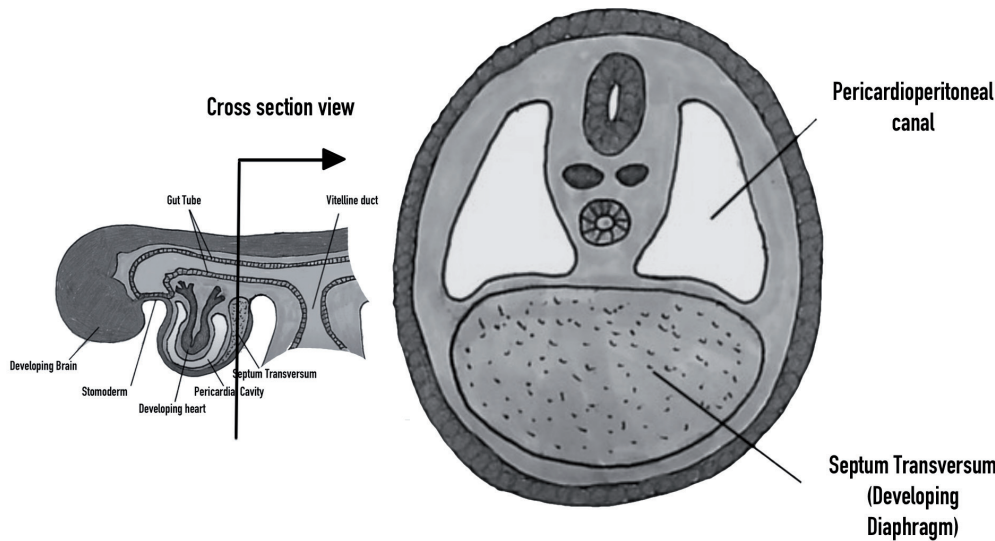
**Figures 1** and **2** show a brief introduction on the embryogenic development of the diaphragm and the truncal cavities.

The incidence of fetal breathing increases at up to about 30 weeks of gestation. Once the fetal breathing movements are characterized by a fluent downward movement of the diaphragm, outward displacement of the abdomen and inward displacement of the thorax occur [1].

After birth, the movement of the diaphragm accounts for the majority of the change in intrathoracic volume during quiet inspiration until it reaches 75% in adulthood. The diaphragmatic fibers attach around the inferior aspect of the



**Figure 1.**  
*Sagittal View of the embryo at 8 weeks, showing the early development of septum transversum.*



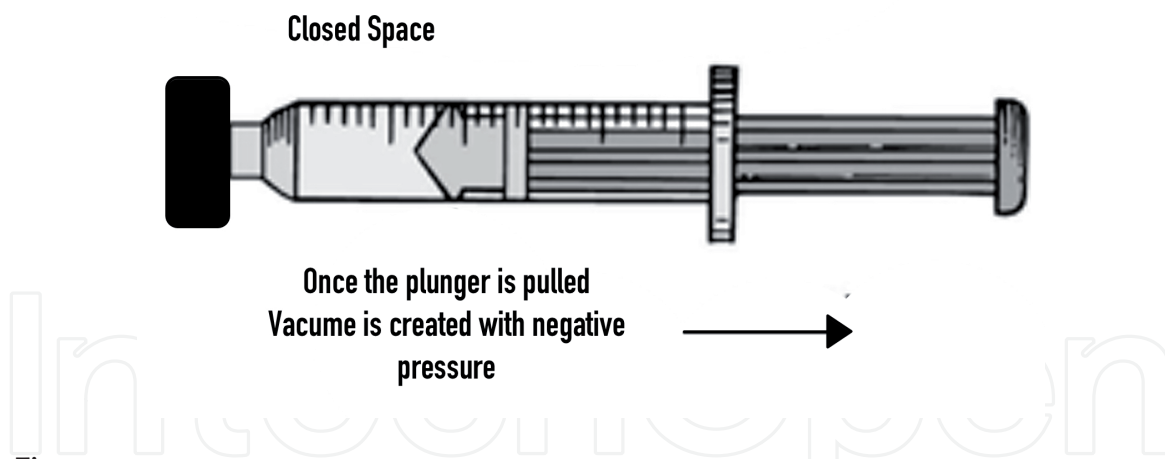
**Figure 2.**  
*Cross sectional view at the level of the septum transversum (Drawn by the author).*

thoracic cage, arching over the liver and contracting downward (inspiration) and relaxing upwards (expiration), exactly like a piston. The movement distance can be up to 7 cm with deep inspiration, and as a result, it is the main determinant of abdominal pressure, along with the abdominal wall muscles and fat [2].

For example, during vomiting and eructation, intra-abdominal pressure is increased by contraction of the costal fibers, but the crural fibers remain relaxed, allowing material to pass from the stomach into the esophagus [2].

The maximum transdiaphragmatic pressure ( $P_{dimax}$ ) reflects the diaphragmatic function and force. To measure  $P_{dimax}$  (the difference between intra-abdominal and intrathoracic pressures), pressure transducers are placed through the external nares to the stomach (to approximate intra-abdominal pressure) and in the esophagus (to approximate intrathoracic pressure). However, this technique is not commonly utilized.

Measuring pleural pressure is essential in ventilated patients in the Intensive Care Unit who have Acute Respiratory Distress Syndrome (ARDS). Accurate measurement of the ventilator parameters is required to assure safe and effective ventilation for already injured lungs.



**Figure 3.**  
*Creating the negative pressure by syringe plunger simulating the action of the diaphragm.*

The diaphragm behaves very much like the plunger of a syringe; inspiration contracts the diaphragmatic fibers, pulling the diaphragm downwards and decreasing the pressure (negative value below atmospheric pressure) in the thoracic cavity. This activity allows air to flow to the chest (**Figure 3**).

## 2. Diaphragmatic eventration

Diaphragmatic eventration is an uncommon condition that is usually incidentally discovered. The classical patient presentation is an incidental elevation hemidiaphragm on chest X-ray. The most important and common imitator of eventration is diaphragmatic paralysis, which has a different etiology and histopathological picture; however, the clinical presentation in adults is similar and these two conditions are sometimes very difficult to distinguish from each other.

True diaphragmatic eventration is a congenital developmental defect in the muscular portion of the diaphragm with preserved attachments to the sternum, ribs, and dorsolumbar spine, maintaining the anatomical separation of the two cavities. It is rare, with an incidence of  $<0.05\%$ , more common in males, and more often affects the left hemidiaphragm [3].

In contrast to true diaphragmatic eventration, diaphragmatic paralysis is a more common, acquired condition that generally results from traumatic or iatrogenic injury to the phrenic nerve or as a result of tumor invasion.

Diaphragmatic eventration can be bilateral, unilateral, or localized to a certain anatomical zone of the diaphragm (anterior, posterolateral, or medial) [3]. Microscopically, the eventrated portion has disseminated fibroelastic tissues at the expense of myocytes [4]. Patients with diaphragmatic paralysis have a normal amount of muscle fibers, but the main issue is their atrophy.

There have been multiple descriptions of associations of diaphragmatic eventration with other congenital abnormalities like dextrocardia, intestinal malrotation and renal agenesis [5].

Patients who have diaphragmatic eventration may not have the normal caudal movement of the diaphragm necessary for appropriate inspiration. As a result, diaphragmatic movement can be diminished, absent, or even paradoxical.

An imaging study required to diagnose eventration besides chest X-ray is fluoroscopy. Specifically, a fluoroscopic sniff test is indicated. During this test, the diaphragm normally moves downward during sniffing; however, in paralysis or eventration, it moves upwards.

The main treatment for eventrated diaphragm is diaphragmatic plication through various either open or minimally invasive. While diaphragmatic plication is mainly quadriplegics with diaphragmatic paralysis.

### **3. Syndromes with increased truncal compartmental pressures**

#### **3.1 Tension pneumothorax**

Tension pneumothorax is a well-known pathophysiological state in which the thoracic cavity develops very high pressure as a result of accumulated air in the pleural cavity, displacing the mediastinum and preventing the preload from draining back to the right side of the heart. This can affect left-sided heart afterload and ultimately lead to hemodynamic compromise.

The most common mechanism is traumatic lung injury, or iatrogenic injury due central venous cannulation. According to the American Trauma Life Support manual [6], the management of such a life-threatening injury is immediate pleural decompression. This can be done in many ways depending on the physician's experience; either by using a needle, finger, or intercostal pleural drainage tube, as long it is done promptly and safely, to not cause any further injuries. Once the drainage is done, the tension pneumothorax will turn into a simple pneumothorax and the management of a simple pneumothorax is beyond the scope of this book.

#### **3.2 Tension pneumoperitoneum and ascites (Hydroperitoneum)**

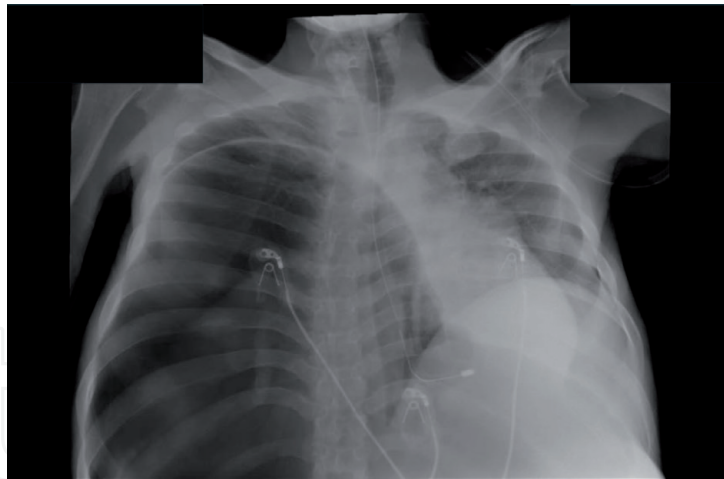
Tension pneumoperitoneum is a much less known pathology compared to tension pneumothorax [7]. In this condition, air or fluid accumulates in the peritoneal cavity, leading to respiratory and hemodynamic compromise. The most common cause of pneumoperitoneum is pathological perforated viscus (e.g., perforated duodenal ulcers, perforated colonic mass). Peritoneal fluid can increase in the abdomen in large amounts, reaching 10–15 L (ascites or hydroperitoneum) due to advanced liver cirrhosis, or it can be malignant ascites secondary to advanced metastatic abdominal malignancy. Both of these conditions can lead to increases in abdominal pressure and compromise of respiratory function.

As a result of increasing cases of liver cirrhosis worldwide, the incidence of cirrhosis-induced ascites is common, and the effect of massive ascites on respiratory function and thoracoabdominal movement (cirtometry) have been studied before and after paracentesis [8]. After paracentesis, minute ventilation, tidal volume, and dyspnea scale were better and a significant p-value, compared to before the procedure, indicated that abdominal pressure will still transmit to the pleural pressure, even in the presence of a normal diaphragm.

The term “tension” has been linked to hemodynamic compromise and shock. Therefore, for ascites to cause respiratory embarrassment without shock would not make it “tension hydroperitoneum” in the conventional wisdom. Most of the cases of hydroperitoneum and respiratory compromise reported in the literature occurred in the pediatric age group, and due to delayed perforated viscus, respiratory compromise can be explained due to the septic inflammatory response, rather than the mere machinal displacement of the diaphragm and pressure transmission [9].

The pathophysiological cascade in tension pneumoperitoneum happens at the beginning, when abdominal pressure exceeds venous pressure and the lower venous return cannot be drained back to the right side of the heart. While the upper body venous return is not enough to sustain the preload due to severe hypovolemia, this results in hemodynamic compromise, a condition termed “tension





**Figure 4.**  
*Thoracoabdominal Compartment syndrome chest radiograph [11].*

pneumoperitoneum”. It is imperative to keep in mind that the thoracic cavity pressure should be normal because the barrier (diaphragm) should be functioning well.

What would happen if the abdominal pressure gets very high while the diaphragm is diseased and cannot prevent the pressure from transmitting to the thoracic cavity, as in diaphragmatic eventration? This condition is known as thoracoabdominal compartment syndrome.

### 3.3 Thoracoabdominal compartment syndrome

Thoracoabdominal compartment syndrome is a recently described syndrome, and there are a few existing case reports that describe it.

The first possible description of such a pathophysiological phenomenon was given by Haldane et al. [10], who reported a case of tension pneumoperitoneum causing hemodynamic compromise. These authors described the reason as tension pneumothorax despite the lack of air in the pleural cavity. Therefore, the exact pathophysiological association of the hemodynamic compromise, as a result of transmitted pressure from the abdominal cavity to the pleural cavity through the intact (but pliable) diaphragm, was not coined as a syndrome until Shaher et al. described it [11].

In the former report, the case was of a perforated gastric ulcer that caused tension pneumoperitoneum. The association of diaphragmatic eventration allowed an increase in abdominal pressure to be transmitted to the thoracic cavity.

The reasons for elevated abdominal pressure in this case was a significantly dilated megacolon with compromise of the thoracic cavity pressure due to the pliable diaphragm, as depicted in **Figure 4**.

A postmortem case report was recently published [12], reporting a thoracoabdominal compartment syndrome in a 65-year-old male, with the colon in right hemithorax with near total lung collapse, mediastinal shift and associated diaphragmatic eventration.

## 4. Conclusion

Thoracoabdominal Syndrome is a rare complication of diaphragmatic eventration, usually present with hemodynamic compromise as a result of transmitted pressure from the abdominal cavity to the pleural space. Moreover, it is usually

associated with multiple congenital abnormalities. Most of the cases reported presented late due to the inability to diagnose early, leading to a very high mortality rate. Diaphragmatic eventration should be surgically repaired through plication as soon as feasible to maintain the physiological function of the diaphragm and to prevent such a syndrome from developing.

### **Conflict of interest**

The author declares no conflicts of interest.

### **Author details**

Abdulaziz Shaher  
Armed Forces Hospital – Southern Region, Abha, Kingdom of Saudi Arabia

\*Address all correspondence to: dr.shaher@gmail.com

### **IntechOpen**

© 2021 The Author(s). Licensee IntechOpen. This chapter is distributed under the terms of the Creative Commons Attribution License (<http://creativecommons.org/licenses/by/3.0>), which permits unrestricted use, distribution, and reproduction in any medium, provided the original work is properly cited. 

## References

- [1] Dewbury K. Ultrasound in obstetrics and gynaecology. London: Churchill Livingstone; 2001.
- [2] Barrett K. Ganong's review of medical physiology. New York: McGraw-Hill Education; 2019.
- [3] Groth S, Andrade R. Diaphragmatic Eventration. *Thoracic Surgery Clinics*. 2009;19(4):511-519.
- [4] Shah-Mirany J. Eventration of the Diaphragm. *Archives of Surgery*. 1968;96(5):844.
- [5] Sharma S, Debnath P, Tripathi R. Bilateral eventration of the diaphragm with malrotation and unilateral renal agenesis. *The Indian Journal of Pediatrics*. 2007;74(5):503-504.
- [6] Advanced Trauma Life Support. München: Elsevier, Urban et Fischer; 2015.
- [7] De Smet R, De Paepe P, Buylaert W, Hachimi Idrissi S. Spontaneous tension pneumoperitoneum presenting as an out of hospital cardiac arrest: A case report and review of the literature. *Acta Clinica Belgica*. 2016;71(4):258-262.
- [8] Witter V, Lima R, Maia M, Duarte H, Paro F. Respiratory and symptomatic impact of ascites relief by paracentesis in patients with hepatic cirrhosis. *Arquivos de Gastroenterologia*. 2020;57(1):64-68.
- [9] Im S, Lim G, Hahn S. Spontaneous gastric perforation in a neonate presenting with massive hydroperitoneum. *Pediatric Radiology*. 2005;35(12):1212-1214.
- [10] Akoglu H, Coban E, Guneyssel O. Tension pneumoperitoneum complicated with tension pneumothorax in a patient with diaphragmatic eventration. *Case Reports*. 2012;2012(apr04 1): bcr0120125512-bcr0120125512.
- [11] Shaher A, Alqahtani AM, Sinnah KN, Al Bakheet SM. Diaphragmatic eventration unusual presentation: A novel thoracoabdominal compartment syndrome case. *BMJ Case Rep*. 2019;12(6):e229475.
- [12] Omenai SA, Adebowale EO, Nwanji ID. Thoracoabdominal compartment syndrome complicating right-sided diaphragmatic eventration with co-existent unilateral renal agenesis. *Autops Case Rep [Internet]*. 2020;10(2):e2020155.