

# We are IntechOpen, the world's leading publisher of Open Access books Built by scientists, for scientists

6,900

Open access books available

185,000

International authors and editors

200M

Downloads

Our authors are among the

154

Countries delivered to

TOP 1%

most cited scientists

12.2%

Contributors from top 500 universities



WEB OF SCIENCE™

Selection of our books indexed in the Book Citation Index  
in Web of Science™ Core Collection (BKCI)

Interested in publishing with us?  
Contact [book.department@intechopen.com](mailto:book.department@intechopen.com)

Numbers displayed above are based on latest data collected.  
For more information visit [www.intechopen.com](http://www.intechopen.com)



# Cytoreductive Procedures and HIPEC in the Treatment of Advanced Ovarian Cancer

*Bogdan Moldovan, Silviu-Tiberiu Makkai-Popa, Costel Rad, Radu Pisica, Vlad Untaru and Doly Stoica*

## Abstract

This chapter is dedicated to cytoreductive procedures and hyperthermic intraperitoneal chemotherapy (HIPEC) in the treatment of advanced ovarian cancer. Cytoreductive procedures and HIPEC constitute nowadays an important weapon in the surgical armamentarium used to treat ovarian cancer. Our service led by Dr. Moldovan Bogdan has an experience of 235 patients that underwent a HIPEC procedure, with an average of 33,5 cases/year which places us among some of the most experienced teams worldwide. We propose a chapter describing the indications and contraindications of such procedures, the surgical approach, followed by a description of our experience, including a review of our indications, the type of chemotherapeutic agents and a case example.

**Keywords:** cytoreductive surgery, HIPEC, carcinomatosis, hyperthermic intraperitoneal chemotherapy, cisplatin, doxorubicin

## 1. Introduction

Ovarian cancer ranks as the seventh most common cancer in women worldwide, as shown by a metanalysis of 125 articles published between 1925 and 2018 [1]. This frequency also comes with a non-neglectable mortality which in the same meta-analysis is estimated at 4,4% of all the cancer cases, in 2018. The mortality index is mostly due to the fact that the diagnosis is made when the disease is already advanced with two thirds of the mortality being attributed to advanced forms of serous carcinoma. Even with the current care recommendations which involve standard cytoreductive surgery and multiple lines of chemotherapy the confounded long-term survival for all disease stages is only 20–30% and is mostly due to peritoneal carcinomatosis [1–6]. As such we find that completing the cytoreductive surgery with hyperthermic intraperitoneal chemotherapy is the best way to ensure the best possible outcomes for ovarian cancer patients. A review of the current literature shows that it improves the 5-year survival to 24–60% compared to an average life expectancy of 12 to 25 months with standard chemotherapy [4, 7].

The aim of this chapter is to bring insight into our current surgical practice of performing extensive cytoreductive surgery and hyperthermic intraperitoneal chemotherapy.

## 2. Historic perspective and rationale for HIPEC

Over time our view of peritoneal carcinomatosis evolved from considering it a terminal disease to considering it a form of locally advanced disease amenable to surgery which is sometimes with curative intent. The first to introduce the concept of cytoreductive surgery was Griffiths in 1975. His work shows a direct link between the radicality of the surgery and the survival of the patients [8, 9]. Five years later Spratt et al. show that hyperthermic intraperitoneal chemotherapy is feasible in peritoneal carcinomatosis [10, 11] and finally, in 1995 Sugarbaker et al. describe the technique of complete peritonectomy with an extraperitoneal approach, which in our opinion is the most suitable technique for most of the cases. He also described the combination of his technique with HIPEC [10].

If we look at the literature, we find articles clearly showing that the peritoneum in general and regions where scars exist – port sites for example are more prone to metastasis compared to solid organs and systemic chemotherapy is effective in about one third of the cases, with a complete response in only 15% of the cases [11]. Hence cytoreduction is extremely important to reduce tumor burden and HIPEC augments its efficacy by the lavage itself which, performed in a recent postoperative setting helps flush the cells resulted from manipulating bulky lesions such as is often the case. It also helps by activating heat shock proteins due to the temperature which is around 42 degrees and gives the chemotherapeutic agent a chance to act locally by putting it in direct contact with the peritoneum.

## 3. HIPEC indications

The established concept of cytoreduction and HIPEC in peritoneal carcinomatosis is that they are to be performed in advanced stages of the disease, however more and more articles, starting with Sugarbaker and continuing with other high-volume surgical centers propose using HIPEC as a prophylactic measure not only in ovarian cancer but also in advanced appendiceal, colonic or gastric malignancies [11–19]. Keeping this in mind, it is our opinion that in the surgical management of ovarian cancer we will soon be able to classify HIPEC procedures into prophylactic – in stages up to II B and conventional – in stages III and IV. Because of the aggressiveness of the procedure, in each and every case we operate we struggle to achieve a complete cytoreduction, otherwise known as CC0 and in order to preoperatively assess in which patients this might be achieved we use staging scores such as the Fagotti score.

Initially, the Fagotti score [20] was described as a laparoscopic means of assessing the feasibility of a HIPEC procedure, but because all surgical manipulation of the peritoneum decreases the chances to perform a radical surgery, we substitute the laparoscopic Fagotti score with an imaging score based on a good quality abdominal and pelvic contrasted, diffusion weighted magnetic resonance imaging (MRI). Besides avoiding unnecessary manipulation of the peritoneum, we consider it superior to laparoscopy because it allows us to assess the areas of the abdomen and pelvis which are difficult to evaluate surgically, especially in a patient that has had previous abdominal surgery. Similar to it is also the Bristow CT score, but in our opinion the Fagotti score based on a good quality MRI examination is better [21].

The Fagotti score contains 5 variables – omental cake, diaphragmatic carcinomatosis, mesenteric retraction, bowel/stomach infiltration and spleen/liver metastasis. If present, each variable receives 2 points. If the Fagotti score obtained on the MRI is less than 8 we go ahead and prepare the patient for HIPEC, while if the score is higher than 8 we prefer to perform a Pressurized Intraperitoneal Aerosol

Chemotherapy (PIPAC) session, continue chemotherapy and reassess the patient by the same MRI score 4–6 weeks after. We can perform 2–3 such PIPAC sessions in the hopes of achieving operability.

Besides the Fagotti score which in our opinion is the best tool for staging ovarian peritoneal carcinomatosis and the Bristow score, there are several other scores which we only mention but not describe in detail as they are not used in case of ovarian cancer carcinomatosis – the Peritoneal Cancer Index (PCI) proposed in 1996 by Sugarbaker and Jaquet [15, 16], the Gilly staging [15, 17] and the simplified PCI system proposed by Zoetmulder [18].

In conclusion to this subsection on staging scores we would like to talk about our standard preoperative workup in cases which are referred to our center as candidates for cytoreductive surgery and HIPEC. This includes an MRI of the abdomen and pelvis with contrast and diffusion weighted imaging and a chest CT.

We prefer MRI because in our experience it correlates best with what we would find on an exploratory laparoscopy allowing us to obtain a more accurate Fagotti score. The chest CT allows us to define the intrathoracic involvement and plan for an eventual diaphragmatic resection. We place bilateral chest tubes at the end of the procedure and if needed the chest drain can also be connected to the HIPEC machine in order to have cytostatic agent circulating also in the pleural cavity.

Based on the imaging findings we can define not only the patients with better chances for having a complete resection but also those where there is a contraindication for HIPEC. The contraindications can be classified in absolute and relative.

Absolute contraindications are:

- inoperable invasion of the liver hilum;
- diffuse, inoperable liver metastases;
- diffuse small bowel lesions in which resection would mean leaving less than 1 m of small bowel;
- unresectable retroperitoneal lymph node masses;
- inoperable distant metastasis.

Relative contraindications are:

- locally advanced multiple relapses, resistant to different chemotherapy regimens;
- progression under neoadjuvant therapy;
- bad performance status and comorbidities.

Pleural involvement which is common, is not a contraindication for performing HIPEC, but rather an indication to also perform hyperthermic intrathoracic chemotherapy (HITOC), eventually as staged procedures.

#### **4. Timing of the cytoreductive and HIPEC procedures**

Because of the variability of the moment when ovarian cancer is diagnosed there are several moments in the natural history of an ovarian cancer case when

cytoreductive procedures and HIPEC can be performed as can be seen in the analysis performed by Helm et al. [14].

The first such moment and the one in which cytoreduction and HIPEC give the best chances of survival is when the diagnosis is made, if complete cytoreduction can be achieved [2]. In the moment of diagnosis, depending on the extent of the disease we can talk about prophylactic HIPEC or conventional HIPEC in later stages [19]. Prophylactic HIPEC in ovarian cancer refers to stages I and II in which we have a cytology sample which is positive for tumor cells, which suggests an increased risk for peritoneal relapse and a decision is made together with the patient and the oncologist to perform HIPEC with a preventive thinking in mind.

Another moment for HIPEC and cytoreduction is after neoadjuvant chemotherapy, because most ovarian cancers respond well to chemotherapy and become operable after a neoadjuvant treatment. The only disadvantage is that it might downsize the peritoneal implants, rather than really downstage the tumor and thus hide implants that otherwise would have been resected, increasing the risk for recurrence.

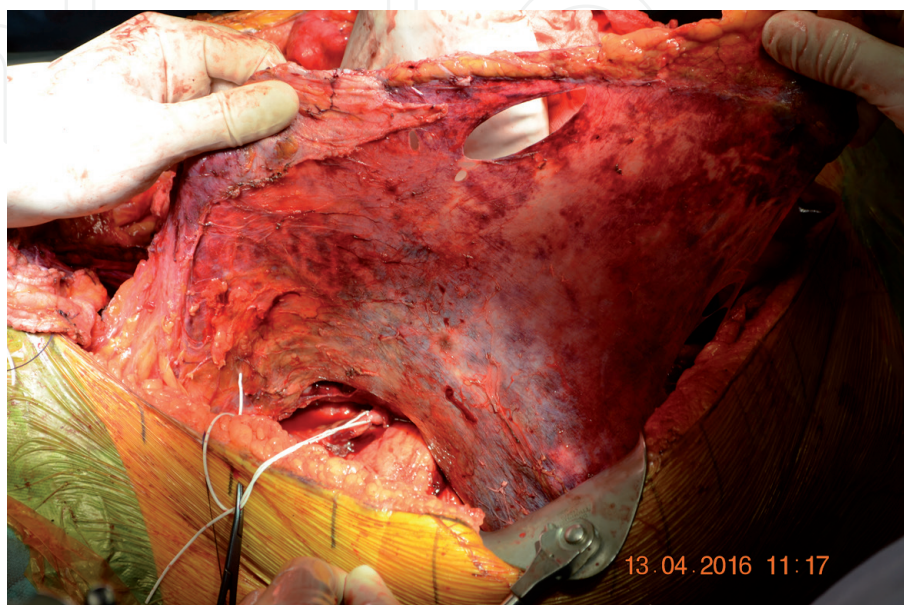
HIPEC can also be performed as a consolidation therapy after neoadjuvant chemotherapy, meaning that it is performed during a second look laparotomy when peritoneal biopsies reveal residual disease.

Another occasion on which these procedures might become useful in ovarian cancer is when a peritoneal relapse is diagnosed and surgery is performed usually after a new course of neoadjuvant chemotherapy which will also determine the chemotherapeutic agent to be used based on the response of the tumor.

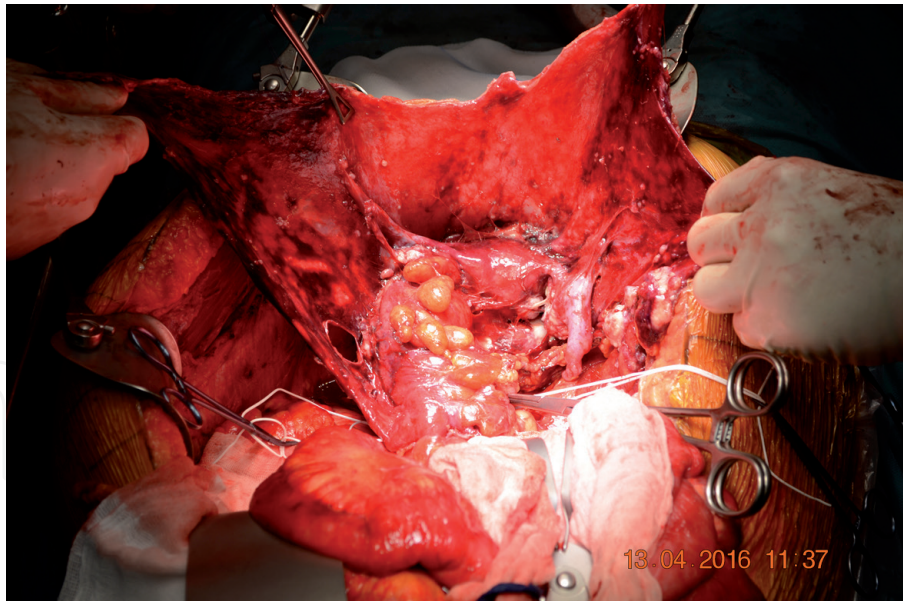
Finally, the last situation in which we would perform HIPEC is as a last resort treatment – basically a salvage procedure.

## 5. Description of the technique for cytoreductive surgery

In ovarian cancer most of the authors recommend a selective peritonectomy technique and not a total peritonectomy, but in our hospital we prefer performing a total extraperitoneal (Sugarbaker) peritonectomy because we have more experience with it and we consider it more radical based on our results [22, 23]. An example of extraperitoneal peritonectomy can be seen in **Figures 1** and **2**.



**Figure 1.**  
*Sugarbaker extraperitoneal peritonectomy.*



**Figure 2.**  
*Sugarbaker extraperitoneal peritonectomy view once the peritoneal cavity is opened.*

We start by detaching the peritoneum completely without opening it by entering a plane located between the peritoneum and the rectus sheath. We continue in this plane laterally until reaching the peritoneum, cranially until the Glisson's capsule and inferiorly we resect the peritoneum covering the bladder with the uterus and the two adnexae, with or without the rectum. As patients usually come to us after a staging laparotomy performed elsewhere, we start by resecting the previous scars which are the most common sites of future relapses. We usually start below the umbilicus as this is the place where we can develop the correct plane at greater ease. Once the round ligament is cut at the level of the deep inguinal ring we can dissect easily laterally until reaching the retroperitoneum and exposing the iliac vessels and the ureters.

We then develop the plane cranially. Sometimes splenectomy is necessary if implants are seen on it or close to it, but it is not indicated as a rule in ovarian cancer.

Once the peritoneum is detached completely cranially and laterally, we enter the peritoneal cavity. A first resection specimen is constituted by the median scar, the umbilicus, the round ligament of the liver which is cut at the level of Rex's recess, the falciform ligament and the urachal fold down to the bladder. The remaining peritoneum will be split into four quadrants. Completing the peritonectomy of the right upper quadrant is considered the most difficult as it consists of:

- resecting the diaphragmatic peritoneum, sometimes with a piece of diaphragm;
- dissection of the Glisson's capsule, if affected, with the eventual metastases;
- cholecystectomy
- liver hilum lymph node dissection
- right colo-epiploic takedown with dissection of the posterior peritoneal sheath of the omental bursa
- resection the peritoneum of the Morison space

- selective peritonectomy of the space between the caudate lobe, the inferior vena cava and the right diaphragmatic crux

In the left upper quadrant, the peritonectomy means:

- resecting the diaphragmatic peritoneum, sometimes with a piece of diaphragm;
- left colo-epiploic takedown
- dissection of the greater curvature
- resection of the peritoneum with or without the spleen
- mobilization of the left colonic flexure, sometimes requiring a colectomy

In the lower abdomen the peritonectomy includes:

- dissection of the peritoneum covering the urinary bladder
- dissection and section of the ovarian vessels
- dissection of the ureters in order to expose and ligate the uterine vessels safely
- sectioning the vagina below the cervix
- dissection of the peritoneum of the Douglas pouch when it is normal macroscopically or with the rectum if there are visible tumor implants
- appendicectomy
- sometimes colonic resections
- pelvic and paraaortic lymphadenectomy.
- sometimes a bladder resection or vascular resections might be necessary

In the central part of the abdomen the small intestine is examined carefully on both sides. Severely affected portions of the small bowel are resected carefully, keeping in mind the risk for short bowel and taking away as little bowel as possible. Mesenteric implants are either resected or Argon beam coagulated. Atypical resections of the stomach can also be performed with the use of linear staplers.

Keeping in mind that the cytoreduction is usually followed by HIPEC we are faced with some delicate decisions regarding the anastomoses we perform. For small bowel we perform a 2-layer latero-lateral continuous suture without stoma. For colorectal anastomoses we perform a mechanical anastomosis using a circular stapler and protecting the anastomosis with a colostomy which we prefer to an ileostomy. And finally, there are cases where we do not perform an anastomosis but rather an end colostomy or ileostomy. These are mostly CC1 cases, posterior pelvic exenteration cases or total colectomy cases in fragile patients, even with a CC0 resection where an anastomosis would be too risky due to the status of the patient.

## 6. Assessing the completeness of cytoreduction – the radicality score

It is considered the most important prognostic score, being estimated at the end of the cytoreductive stage. The penetrability of intraperitoneal chemotherapy is possible for lesions up to 2.5 mm. For most intraperitoneal neoplasms, complete CC0 cytoreduction is required, the CC1 score being considered acceptable only for peritoneal pseudomyxoma, a neoplasm with reduced aggressiveness. The radicality of resection classification is as follows: CC0 – no residual disease, CC1 – residual lesions smaller than 0,25 cm, CC2 – residual lesion between 0,25 and 2,5 cm and CC3 – residual lesions larger than 2,5 cm [18].

The impossibility of a radical surgery CC0-CC1 can determine the change of the operative strategy, either towards a palliative debulking surgery, or towards giving up any gesture of excision. In chemotherapy “naive” tumors, the maximum cytoreduction with HIPEC followed by adjuvant CT is to be considered.

## 7. Description of the HIPEC procedure

For reasons related to the safety of handling cytostatic substances, most HIPEC teams in Europe, including our team use the “closed abdomen” technique in which the abdomen is closed permanently or only temporarily (the skin), with 4 drains inside, coupled to extracorporeal circulation device.

In short, the Rand Performer HT device that we use in our current activity, has the following components: 1) a heater or heat exchanger; 2) a pump system, which includes one or two peristaltic pumps; 3) a tank containing the infusion solution; 4) a circuit that distributes the drugs and heated fluid to the patient's peritoneal cavity. In 1999 the Italian Biomedical Company (Rand Biotech SRL, Medolla, Italy) was the first to develop a device dedicated to HIPEC, used especially for the treatment by hyperthermic perfusion of the peritoneal cavity. The most important advantage of this device (Performer HT) is its portability and adaptability for various purposes, as it can also be used to infuse isolated anatomical regions or organs, such as the treatment of an isolated limb or the separate infusion of the liver or lung. The Performer HT device ensures a flow rate of 100–2000 ml/min and it has up to 8 temperature monitoring lines in various areas of the peritoneal cavity, which has the ability to measure temperatures between 28 °C and 46 °C. In our practice we use tubes with a diameter of 28 Fr, two for inlet (1 - subdiaphragmatic and 1 - in the pelvis) and two for the outlet (1 - subdiaphragmatic and 1 - in the pelvis). We also use two lines for monitoring the intra-abdominal temperature mounted in the pelvis and in the supramesocolic space. In terms of the perfused solution, we use 4–6 liters of warm transport solution (2/3 Ringer, 1/3 Voluven). Once an optimal infusion rate (> 800 ml/min) and an optimal intraperitoneal temperature around 42–43 °C is reached, the cytotoxic drugs are administered. We use Cisplatin (43 mg/L solution/m<sup>2</sup>) or Doxorubicin (15 mg/L solution) for carcinomatosis due to serous ovarian cancer. The duration of chemoperfusion is between 60 and 90 minutes. At the end of the procedure, the abdomen is rinsed with 3 liters of saline and the drains are left in place.

As to the choice of the chemotherapeutic drug, it takes into account the sensitivity of the tumor to platinum salts, which can be seen preoperatively by the response of the tumor to the neoadjuvant chemotherapy. Platinum-sensitive patients will follow the Cisplatin protocol, Platinum-resistant patients, the Doxorubicin protocol.

- Cisplatin (43 mg/L solution/m<sup>2</sup>) - for Platinum CEO sensitive.
- Doxorubicin (15 mg/L solution) - for CEO resistant Platinum.

Other types of protocols using Taxol, Oxaliplatin, 5 Fluorouracil or Mitomycin C, etc. are also cited in the literature.

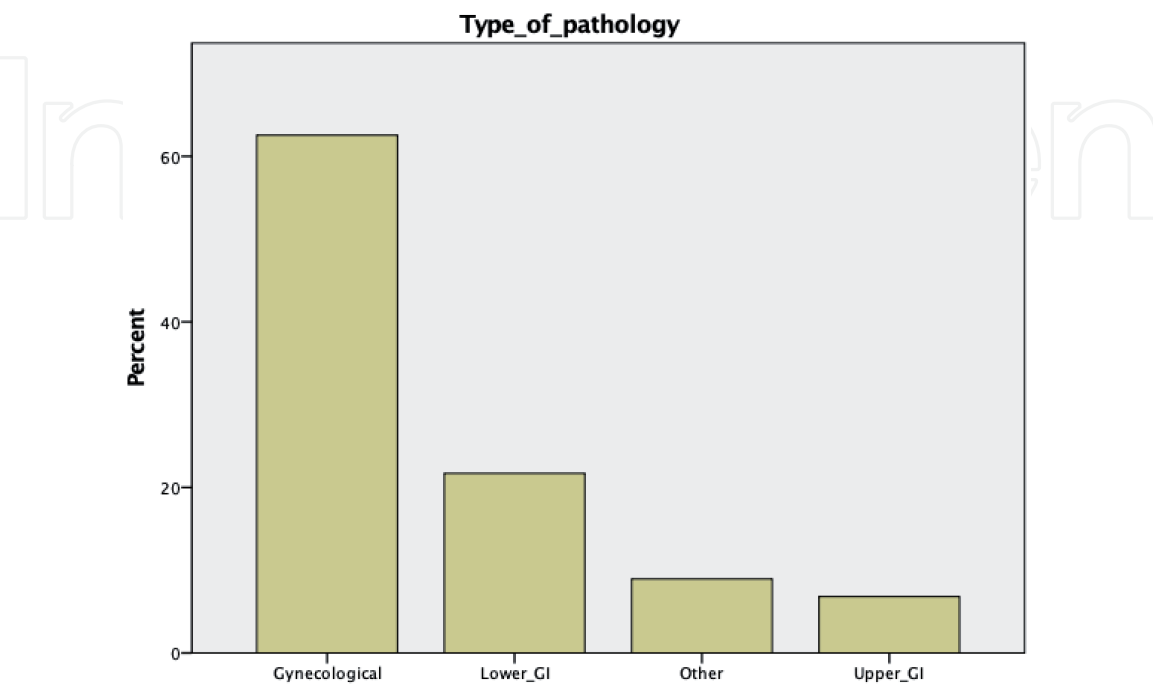
### 8. Our experience

In our experience we performed cytoreductive surgery and HIPEC on a number of 235 cases since we started performing these procedures in our hospital on the 5th of June 2013 which means an average of 33,5 cases/year. From a surgical point of view, critically speaking there were 2 stages: the initial experience 2013-December 2014, dominated by surgical caution, fear of complications, selective peritonectomy by “open” approach, after intraperitoneal exploration and the second stage, starting from January 2015, with the introduction of the Sugarbaker-Deraco extraperitoneal total peritonectomy technique, marked by increased aggression, the association of multiorgan resections often with digestive anastomoses.

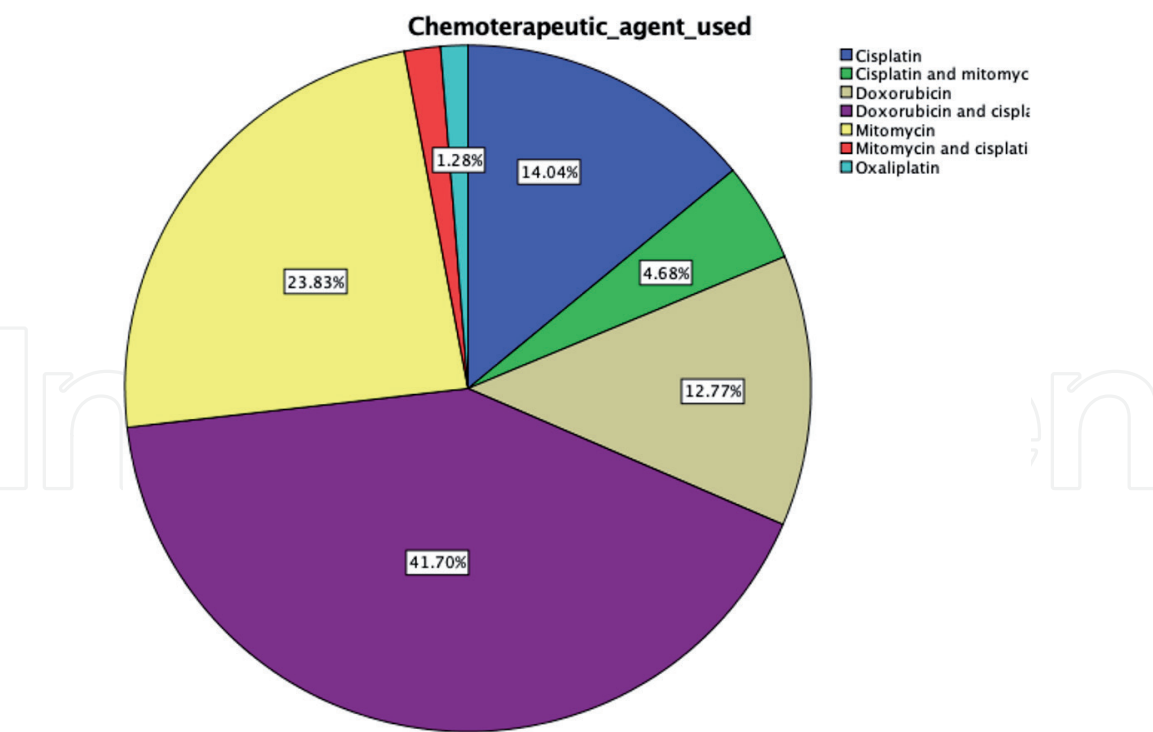
Of these patients there were 188 (80%) females and 47 (20%) males. The mean age of the patients was  $60,92 \pm 10,64$  years. The mean hospital stay was  $9,23 \pm 3,66$  with a minimum of 4 days and a maximum of 32 days. In terms of overall survival, 182 out of 203 patients (89,65%) survived at 1 year and 15 out of 75 patients (20%) survived at 5 years. The mean operating time for these cases was  $7,21 \pm 0,7$  hours and the mean PCI was  $14,5 \pm 0,3$ .

Because of the number of patients and the variety of the pathology we preferred to give a visual representation of the type of pathology approached (**Figure 3**), the type of chemotherapeutic agent we used (**Figure 4**) and whether or not we did a stoma and what type of stoma we did (**Figure 5**). In terms of the radicality of resection you can see in **Figure 6** the proportions of CC0, CC1 and CC2 resections.

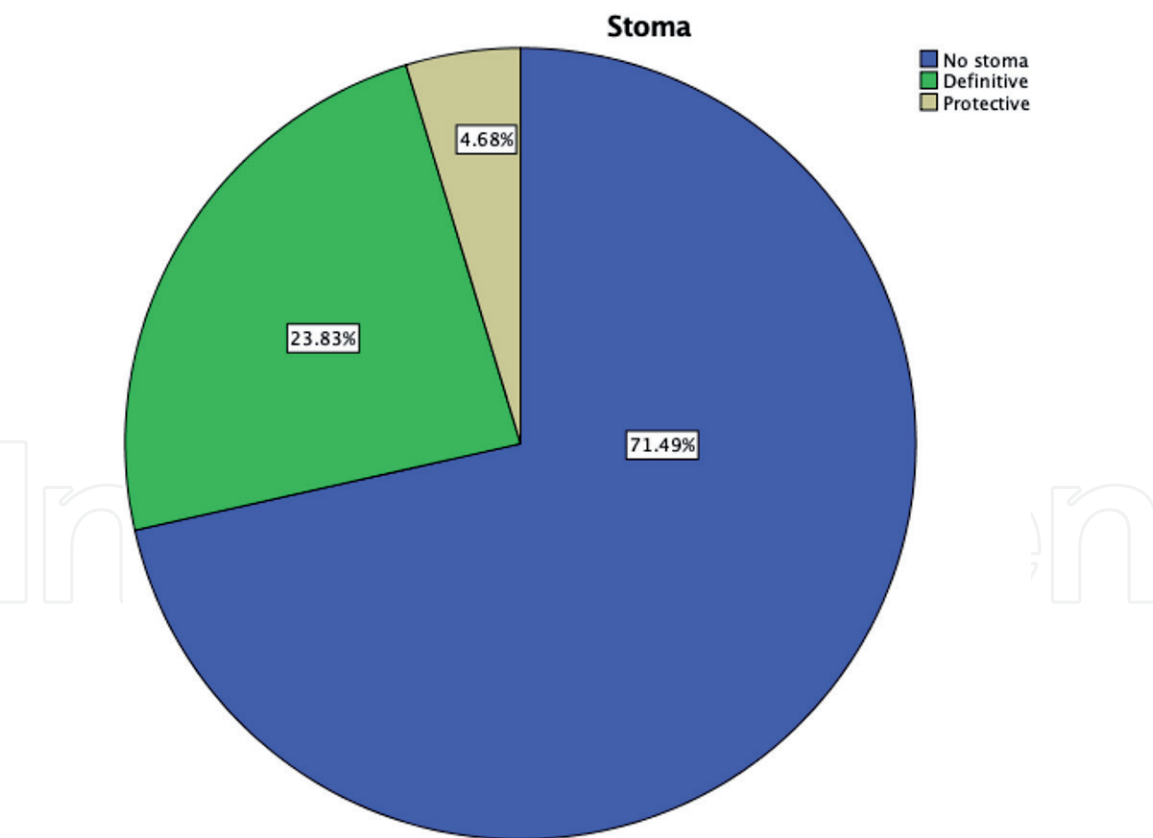
Of particular importance in 2020, we had to reorganize our in-hospital protocols in order to ensure a COVID-free surgical department which allowed us to perform 29 cytoreductive procedures followed by HIPEC since the pandemic was declared on March 11th 2020. We were able to do this by thoroughly screening admitted patients by aligning ourselves to the guidelines emitted by the major surgical and



**Figure 3.**  
*Types of pathologies approached by cytoreduction and HIPEC in our experience.*



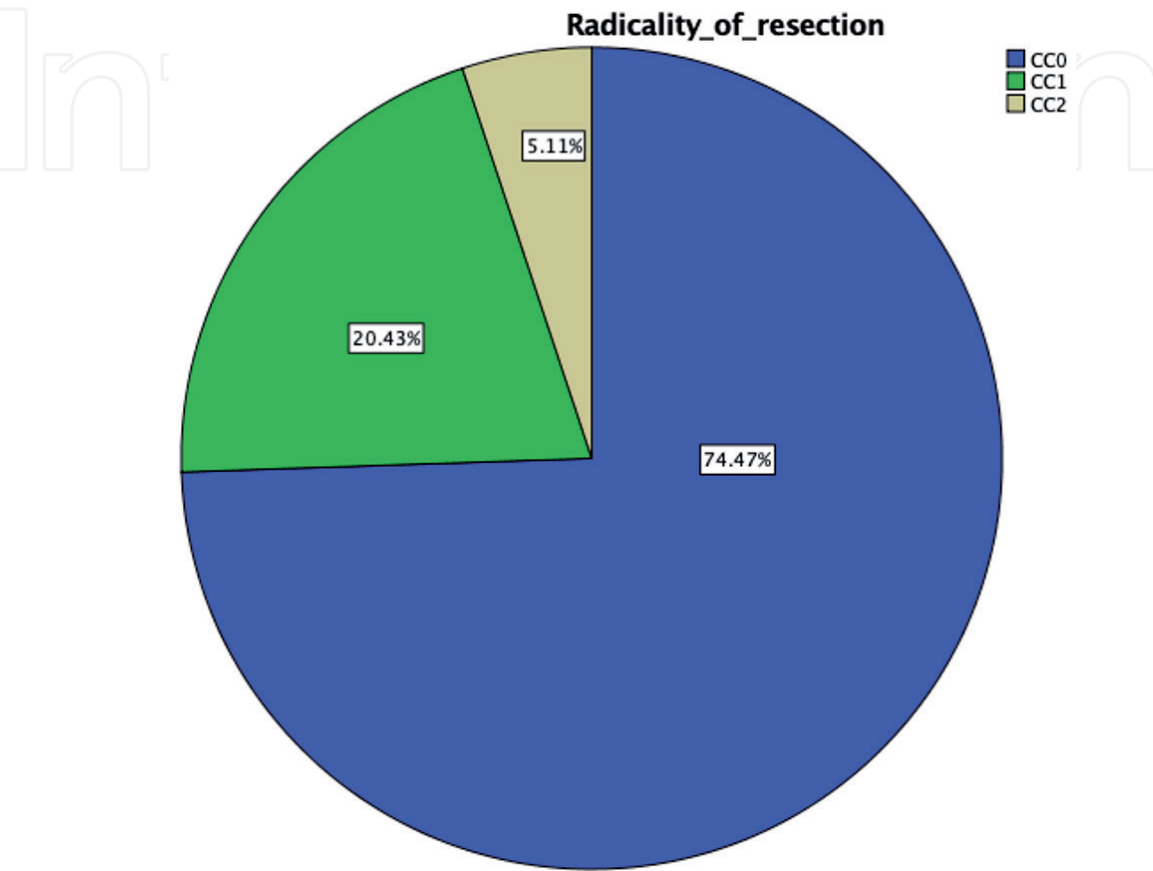
**Figure 4.**  
*Cytostatic agents used in our experience.*



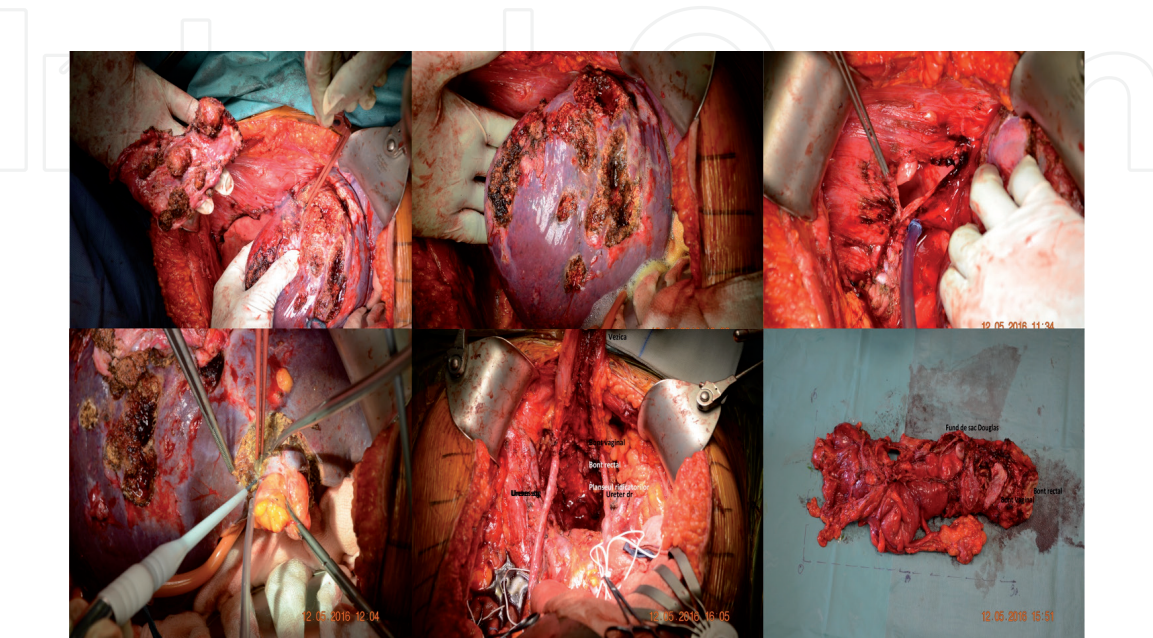
**Figure 5.**  
*Use of stomas in our experience.*

oncological international societies. Initially our screening consisted in PCR tests from nasopharyngeal swab, rapid antibody test and chest CT and according to the guidelines we started only performing PCR from nasopharyngeal swab, leaving rapid antibody and antigen tests and chest CT scans only for patients in which we had a strong clinical suspicion of COVID and a negative PCR test [24].

In terms of multiorgan resections of note are cases of associations between posterior pelvic exenteration, right hemicolectomy and resection of liver metastases, resection of ureter, bladder horn and uretero-vesical reimplantation, total colectomy with extended jejunio-ileal enterectomy, entero-enteral anastomosis and right iliac terminal ileostomy, association of posterior exenteration with regulated left hepatic lobectomy and radiofrequency thermoablation of liver metastasis.



**Figure 6.**  
*Radicality of resection in our experience.*



**Figure 7.**  
*Intraoperative pictures showing multiple organ resections in a patient with recurrent ovarian carcinoma.*

As an example, we would like to present a case of ovarian carcinoma recurrence in a 51 years-old patient previously operated and treated by chemotherapy. The PCI was calculated to be 19 and we performed a CC0 resection with a Sugarbacker extraperitoneal approach associated with a Hartmann resection, multiple liver resections, diaphragmatic resection with phrenic reconstruction, appendicectomy, omentectomy, HIPEC - Doxorubicin 80 mg 60 minutes at 42 °C. Some intraoperative pictures can be seen in **Figure 7**. The patient is still living at 3 years after the procedure and does not show signs of recurrence, despite the fact that she was considered untreatable by other centers before coming in our service.

## 9. Conclusion

Cytoreductive surgery and HIPEC now offer an alternative to ovarian cancer patients that were once considered inoperable and in high-volume centers the complications are minimal. This chapter provides insight into the technique of cytoreductive surgery and HIPEC and presents our experience with these techniques.

## Acknowledgements

The authors would like to thank the producers of the hyperthermic perfusion system – RanD for their excellent support in using the RanD Performer HT system which was used in this case.

## Conflict of interest

The authors declare no conflict of interest.

## Author details

Bogdan Moldovan<sup>1,2\*</sup>, Silviu-Tiberiu Makkai-Popa<sup>1</sup>, Costel Rad<sup>1</sup>, Radu Pisica<sup>1</sup>, Vlad Untaru<sup>1</sup> and Doly Stoica<sup>1</sup>

1 “Sf. Constantin” Hospital, Brasov, Romania

2 Academy of Science People in Romania, Romania

\*Address all correspondence to: [bogdan.moldovan@spitalulsfconstantin.ro](mailto:bogdan.moldovan@spitalulsfconstantin.ro)

## IntechOpen

© 2021 The Author(s). Licensee IntechOpen. This chapter is distributed under the terms of the Creative Commons Attribution License (<http://creativecommons.org/licenses/by/3.0>), which permits unrestricted use, distribution, and reproduction in any medium, provided the original work is properly cited. 

## References

- [1] Momenimovahed Z, Tiznobaik A, Taheri S, Salehiniya H: Ovarian cancer in the world: epidemiology and risk factors. *Int J Womens Health*. 2019;11:287-299. DOI: 10.2147/IJWH.S197604
- [2] Deraco M, Kusamura S, Virzi S, Puccio F, Macrì A, Famulari C, Solazzo M, Bonomi S, Iusco DR, Baratti D: Cytoreductive surgery and hyperthermic intraperitoneal chemotherapy as upfront therapy for advanced epithelial ovarian cancer: multi-institutional phase-II trial. *Gynecol Oncol*. 2011;122:215-220
- [3] Deraco M, Baratti D, Laterza B, Balestra MR, Mingrone E, Macrì A, Virzi S, Puccio F, Ravenda PS, Kusamura S: Advanced cytoreduction as surgical standard of care and hyperthermic intraperitoneal chemotherapy as promising treatment in epithelial ovarian cancer. *EJSO*. 2011;37:4-9
- [4] Hotouras A, Desai D, Sugarbaker PH: Heated IntraPeritoneal Chemotherapy (HIPEC) for Patients With Recurrent Ovarian Cancer: A Systematic Literature Review. *Int J Gynecol Cancer*. 2016;26:661-670
- [5] McGuire WP, Hoskin WJ, Brady MF, Kucera PR, Partridge EE, Look KY, Clarke-Pearson DL, Davidson M: Cyclophosphamide and cisplatin compared with paclitaxel and cisplatin in patients with stage III and IV ovarian cancer. *N Engl J Med*. 1996;334:1-6
- [6] Ozols RF, Bundy BN, Greer BE, Fowler JM, Clarke-Pearson D, Burger RA, Mannel RS, DeGeest K, Hartenbach EM, Baergen R, Gynecologic Oncology Group. Phase III trial of carboplatin and paclitaxel compared with cisplatin and paclitaxel in patients with optimally resected stage III ovarian cancer: a Gynecologic Oncology Group study. *J Clin Oncol*. 2003;21:3194-3200
- [7] Königsrainer I, Beckert S, Becker S, Zieker D, Fehm T, Grischke E-M, Lauk O, Glatzle J, Brücher B, Wallwiener D, Königsrainer A: Cytoreductive surgery and HIPEC in peritoneal recurrent ovarian cancer: experience and lessons learned. *Langenbecks Arch Surg*. 2011;396:1077-1081
- [8] Luyckx M, Leblanc E, Filleron Th, Morice Ph, Darai E, Classe J-M, Ferron G, Stoeckle E, Pomel Ch, Vinet B, Chereau E, Bergzoll C, Querleu D: Maximal cytoreduction in patients with FIGO stage IIIc to stage IV ovarian, fallopian and peritoneal cancer in day-to-day practice, a retrospective French multicentric study. *Int.J.Gynecol.Cancer*. 2012;22:1337-1343
- [9] Griffiths CT: Surgical resection of tumor bulk in primary treatment of ovarian carcinoma. *Natl Cancer Inst Monogr*. 1975;42:101-104
- [10] Chua TC, Robertson G, Liauw W, Farrell R, Yan TD, Morris DL: Intraoperative HIPEC after CRS in ovarian cancer peritoneal carcinomatosis: systematic review of current results. *J Cancer Res Clin Oncol*. 2009;135:1637-1645.
- [11] Sugarbaker PH: Colorectal cancer, prevention and management of metastatic disease. *Biomed Res Int*. 2014;2014:782890 DOI: 10.1155/2014/782890
- [12] Spratt JS, Adcock RA, Muskovin M, Sherril W, Mc Keown J: Clinical delivery system for intraperitoneal HIPEC. *Cancer Res*. 1980;40:256-260
- [13] Sugarbaker PH: Peritonectomy procedures. *Ann Surg*. 1995;221: 29-42
- [14] Helm CW, Bristow RE, Kusamura S, Deraco M: Hyperthermic intraperitoneal chemotherapy with

and without cytoreductive surgery for epithelial ovarian cancer. *J Surg Oncol.* 2008;98:283-290

[15] Portilla AG, Kusamura S, Baratti D, Deraco M: The intraoperative staging system in the management of peritoneal surface malignancy. *J Surg Oncol.* 2008;98:228-231

[16] Jaquet P, Sugarbaker PH: Clinical research methodologies in diagnosis and staging of patients with PC. In: Sugarbaker PH, editor. *Peritoneal carcinomatosis: principals of management.* Boston: Kluwer Academic publishers 1996:359-374

[17] Gilly FN, Carry PY, Sayag AC: Regional chemotherapy (with mitomycin C) and intra-operative hyperthermia for digestive cancers with peritoneal carcinomatosis. *Hepatogastroenterol.* 1994;41:124-129

[18] Witkamp AJ, de Bree E, Kaag MM, Boot H, Beijnen JH, van Slooten GW, van Coevorden F, Zoetmulder FA: Extensive cytoreductive surgery followed by intra-operative hyperthermic intraperitoneal chemotherapy with mitomycin-C in patients with peritoneal carcinomatosis of colorectal origin. *Eur J Cancer.* 2001;37:979-984

[19] Klaver CEL, Musters GD, Bemelman WA, Punt CJA, Verwaal VJ, Dijkgraaf MGW, Aalbers AGJ, van der Bilt JDW, Boerma D, Bremers AJA, Burger JWA, Buskens CJ, Evers P, van Ginkel RJ, van Grevenstein WMU, Hemmer PHJ, de Hingh IHJT, Lammers LA, van Leeuwen BL, Meijerink WJHJ, Nienhuijs SW, Pon J, Radema SA, van Ramshorst B, Snaebjornsson P, Tuynman JB, Te Velde EA, Wiezer MJ, de Wilt JHW, Tanis PJ: Adjuvant hyperthermic intraperitoneal chemotherapy (HIPEC) in patients with colon cancer at high risk of peritoneal carcinomatosis; the COLOPEC randomized multicentre

trial. *MC Cancer.* 2015;15:428. DOI: 10.1186/s12885-015-1430-7

[20] Fagotti A, Ferrandina G, Fanfani F, Garganese G, Vizzielli G, Carone V, Salerno MG, Scambia G: Prospective validation of a laparoscopic predictive model for optimal cytoreduction in advanced ovarian carcinoma. *Am J Obstet Gynecol.* 2008;199:642.e1-6

[21] Bristow RE, Duska LR, Lambrou NC, Fishman EK, O'Neill MJ, Trimble EL, Montz FJ: A model for predicting surgical outcome in patients with advanced ovarian carcinoma using computer tomography. *Cancer* 2000;89:1532-1540

[22] Moldovan B, Pescaru F, Pocreata D, Capalna M: Example of multimodal oncosurgery approach used to treat peritoneal carcinomatosis in a patient with occlusive ovarian carcinoma. *EJGO.* 2016;2:251-254

[23] Moldovan B, Capalna M, Pocreata D, Rad CC, Pescaru F, Stan S, Ioanid N: Aspecte generale. Tehnica chirurgiei cytoreductive si HIPEC. In: Moldovan B, editor. *Tratamentul carcinomului ovarian prin chirurgie citoreductiva si HIPEC.* Brasov: Editura Didactica si Pedagogica, R.A. 2017 :7-42

[24] Makkai-Popa S-T, Rad C, Pisica R, Untaru V, Stoica D, Zolog A, Bosinceanu LM, Moldovan B (forthcoming): Hyperthermic intraperitoneal chemotherapy procedure for uterine sarcoma following a COVID-19 infection - case report. *EJGO.* 2021