

We are IntechOpen, the world's leading publisher of Open Access books Built by scientists, for scientists

6,900

Open access books available

186,000

International authors and editors

200M

Downloads

Our authors are among the

154

Countries delivered to

TOP 1%

most cited scientists

12.2%

Contributors from top 500 universities



WEB OF SCIENCE™

Selection of our books indexed in the Book Citation Index
in Web of Science™ Core Collection (BKCI)

Interested in publishing with us?
Contact book.department@intechopen.com

Numbers displayed above are based on latest data collected.
For more information visit www.intechopen.com



Structural and Biological Basis for Proprioception

José A. Vega and Juan Cobo

Abstract

The proprioception is the sense of positioning and movement. It is mediated by proprioceptors, a small subset of mechanosensory neurons localized in the dorsal root ganglia that convey information about the stretch and tension of muscles, tendons, and joints. These neurons supply of afferent innervation to specialized sensory organs in muscles (muscle spindles) and tendons (Golgi tendon organs). Thereafter, the information originated in the proprioceptors travels throughout two main nerve pathways reaching the central nervous system at the level of the spinal cord and the cerebellum (unconscious) and the cerebral cortex (conscious) for processing. On the other hand, since the stimuli for proprioceptors are mechanical (stretch, tension) proprioception can be regarded as a modality of mechanosensitivity and the putative mechanotransducers proprioceptors begins to be known now. The mechanogated ion channels acid-sensing ion channel 2 (ASIC2), transient receptor potential vanilloid 4 (TRPV4) and PIEZO2 are among candidates. Impairment or poor proprioception is proper of aging and some neurological diseases. Future research should focus on treating these defects. This chapter intends provide a comprehensive update an overview of the anatomical, structural and molecular basis of proprioception as well as of the main causes of proprioception impairment, including aging, and possible treatments.

Keywords: proprioception, muscle spindles, mechanotransduction, ion channels, proprioceptive pathways, spinocerebellar tracts

1. Introduction

Proprioception is a wider sense, that include position and movement of parts of the body relative to one another, and the force and effort associated with muscle contraction and movement. But properly the term *proprioception* applies for the sensory information contributing to sense of self position, whereas *kinesthesia* refers of sense of movement. The first one is regarded as an automatic function and unconscious in contrast with the second one considered as conscious. In the words of Kröger and Watkins [1] “*Proprioceptive information informs us about the contractile state and movement of muscles, about muscle force, heaviness, stiffness, viscosity and effort and, thus, is required for any coordinated movement, normal gait and for the maintenance of a stable posture*”. This information travels to the central nervous system, but differently to other components of somatosensitivity, a great part of the proprioceptive sense does not reach consciousness. This is probably due to suppression as a consequence of the motor signals [2] or inhibitions along somatosensory pathways [3]. The precise knowledge of the pathways of proprioception, especially

those of conscious proprioception, are of capital interest to better understand this sense. The techniques of neuroimaging are providing new insights about the cerebral process of proprioception.

Proprioception originates by the activation of proprioceptors at the periphery. Proprioceptors are a subset of mechanosensory neurons that provide afferent innervation to specialized sensory organs located inside the muscles and tendons, but probably also in joint capsules and ligaments, and the skin. According to Proske and Gandevia [4, 5] the sense of “*proprioception is achieved through a summation of peripheral sensory input describing the degree of, and changes in, muscle length and tension, joint angle, and stretch of skin*”. In fact, the proper definition of proprioception coined by Sherrington in 1906 (“*In muscular receptivity we see the body itself acting as a stimulus to its own receptors—the proprioceptors*”) suggest that the body contains different kinds of proprioceptors. Here we have focused on muscle spindles and Golgi’s tendon organs. Especial interest was done on the mechanisms of mechanotransduction and the ion channel in this process.

Proprioception is impaired in some physiological and pathological situations. It will gain interest in the coming years due to the aging of population: the deficit of proprioception is associated with the increased frequency of falls in the elderly [6–8]. Furthermore, several diseases, especially some neurodegenerative disorders, course with proprioception deficits [9, 10] which treatment require a better knowledge of the molecular aspects of proprioception and new active research.

This chapter is aimed not to perform a Review on all the different aspects of proprioception but just to review some general and recent advances in proprioception. We intend to provide the readers of this book with an up-to-date appraisal of the structural and biological basis of proprioception. There are excellent reviews on the topic [4, 5, 11, 12] and we forward the interested to them. Robert W. Banks’ extraordinary paper (2015) [13] masterfully sums up the history of knowledge of muscle spindles. Likewise, the recent reviews Kröger [14] Kröger and Watkins [1] are mandatory.

2. Proprioceptors

The peripheral receptors of proprioception are located in tissues around the joints, including skin, muscles, tendons, fascia, joint capsules, and ligaments [15] which contains different morphotypes of mechanoreceptors [16]. It is currently believed that proprioception is not generated by a single receptor, but by multiple of receptors. In any case proprioception has been related with sensory receptors localized in the muscles while kinesthesia has been more associated with joint and cutaneous receptors [17–19]. Nevertheless, the historically regarded as true proprioceptors are muscle spindles and Golgi’s tendon organs.

The *joints mechanoreceptors* are Ruffini-like and Pacinian corpuscles which signal joint movement but not movement direction or joint position [15]. Regarding *cutaneous receptors* four kinds of mechanoreceptors are present in glabrous skin (Meissner’s corpuscles, Pacinian corpuscles, Ruffini corpuscles and Merkel cell-neurite complexes) [20–22]. A definitive role of cutaneous mechanoreceptors as proprioceptors has not been definitively established [23–25] although it is possible a convergence between cutaneous and muscle afferents at the spinal cord and thalamic levels.

But independently of the modest contribution of cutaneous and articular mechanoreceptors to proprioception, the main stretch-sensitive receptors are muscle spindles found in most, but not all, skeletal muscles. For instance, they are absent from most cephalic muscles [26, 27]. Interestingly, muscle spindles are more

abundant in muscles in which the precision of movements must be accurate. On the other hand, the main tension-sensitive receptors are the Golgi's tendon organs, located at the ends of muscle fibers [28, 29]. These two sensory organs respond to changes in mechanical conditions, namely in muscle length (muscle spindles) or in actively generated force (Golgi-tendon organs) but both are contraction receptors.

2.1 Muscle spindles

Vertebrate muscle spindles are complex sensory organs that have both sensory and motor innervation. Each muscle spindle receives at least one sensory fiber that innervate specialized muscle fibers denominated intrafusal fibers. These intrafusal fibers also receive motor innervation by γ -motoneurons [30, 31]. Structurally, they are encapsulated mechanoreceptors, and functionally are slowly adapting-loth threshold mechanoreceptors [5].

Muscle spindles are highly variable in number from none in most cephalic muscles (see [27]) to numerous in lumbrical or deep neck muscles [32, 33]. These differences are attributed functional muscular demands of muscles but the number of muscle spindles per motor unit is rather equal [34]. Also, no topographical differences in muscle spindles between mono- and multiarticular muscles were noted [35].

Within the connective capsule that delimits each muscle spindles there are the intrafusal fibers and the periaxial space filled with a fluid. Three zones can be differentiated at the muscle spindle: the central or equatorial zone, the juxta-equatorial zone, and the terminal or polar zone; small segments of the intrafusal fibers can be found outside the poles of the muscle (**Figure 1**).

The intrafusal muscle fibers. Banks and co-workers [36] established that mammalian muscle spindles regularly contain three types of intrafusal muscle fibers. Based on their morphology and the arrangement of nuclei in the equatorial zone they fall into two main categories: nuclear bag fibers and nuclear chain fibers. Bag

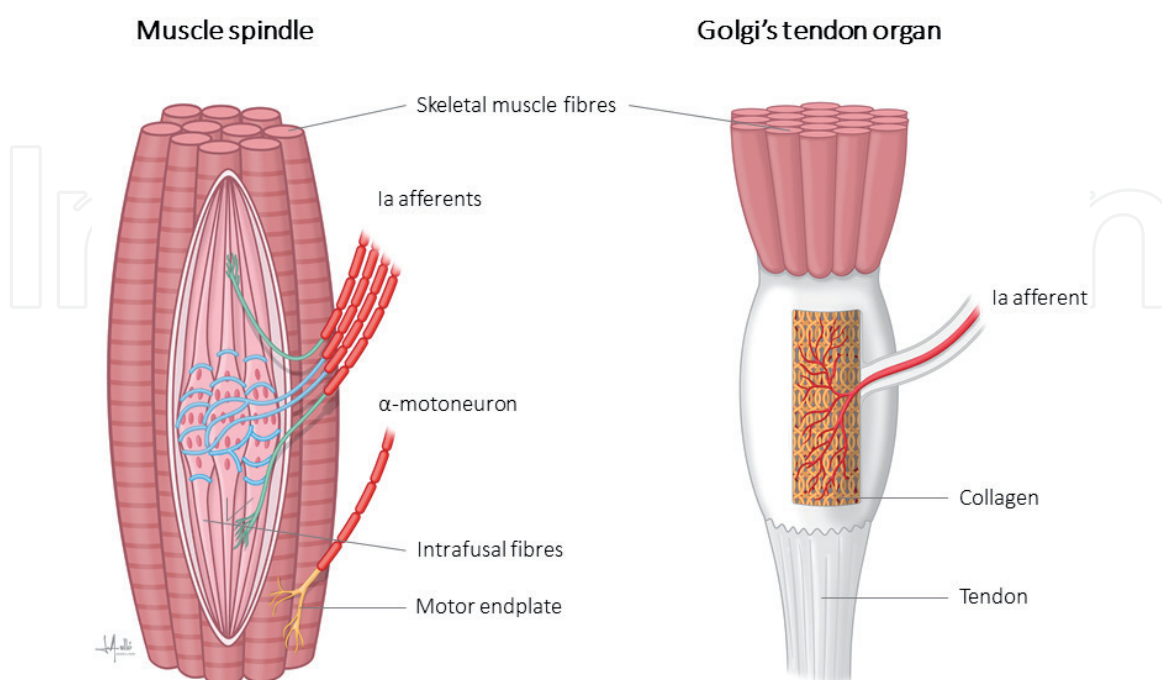


Figure 1. Schematic representation of a muscle spindle and a Golgi's tendon organ. Muscle spindles are capsulated mechanoreceptors that consist of intrafusal muscle fibers (bag1, bag2 and chain), a periaxial space filled with a fluid, and a connective capsule. They are supplied by Ia (blue) and II (green) afferents. Golgi's tendon organs are capsulated mechanoreceptors that consist of collagen fibers and type Ia afferents (red).

and chain fibers differs in structure, histochemical profile (myosin type, ATPase activity [37–39]) and functional properties. Bag fibers are greater in diameter and length than chain fibers, extend outside of the capsule, and they can be subdivided into bag1 and bag2 types (see for a review [40]). Human contains on average 8–20 intrafusal fibers and can lack bag1 or bag2 fibers [37].

As mentioned previously, muscle spindles are stretch detectors, i.e. *“they sense how much and how fast a muscle is lengthened or shortened”* [41]. Accordingly, when a muscle is stretched this change in length is transmitted to the intrafusal fibers which are in turn stretched. And to respond appropriately intrafusal fibers are double innervated by afferent sensory neurons and efferent motoneurons.

Sensory innervation. *“Just as the number of sensory endings varies from spindle to spindle, even within a single muscle, so also does the number of motor axons supplying those spindles”* [13].

There are two types of afferents that innervate intrafusal fibers: primary (type Ia) and secondary (type II) endings which differ in their axonal conduction velocity [13].

Each muscle spindle receives only one **Ia afferent** surrounding like a dock the equatorial zone of all the intrafusal fibers (spirals or annulospiral endings) (**Figure 1**). When spiral endings deform detect changes in length of the muscle. Primary afferents are sensitive to dynamic stretch, have irregular spontaneous or volitionally maintained discharge, and exhibit an off-response at the point of relaxation (i.e., muscle stretch) followed by a slow ramping isometric contraction; they are off during rapid voluntary contraction [13].

The number **type II afferent** endings in a muscle spindle varies from zero to five, and they supply one intrafusal fiber terminating mainly on nuclear chain fibers. The endings of the secondary afferents are spirals ending on the polar ends of the intrafusal fibers (**Figure 1**). Secondary afferents have a regular tonic discharge, and do not exhibit an off-response at the termination of a voluntary ramp-and-hold contraction [42, 43].

Motor innervation. In addition to sensory neurons, intrafusal muscle fibers are also innervated by efferent motoneurons (fusimotor innervation). Axons of motoneurons enter the muscle spindle together with the sensory fibers and innervate intrafusal fibers in the polar regions forming motor endplates.

Motor innervation originates from myelinated **γ -motoneurons** (diameter 4–8 μm), also known as fusimotor motoneurons. They have been differentiated into static and dynamic. Dynamic axons have a weak effect on primary afferent firing while the static ones have a great influence on both primary and secondary afferents (see [43]).

Occasionally additional afferent innervation of muscle spindles originates from axons that also supply extrafusal muscle, known as **β -motoneurons** or skeleto-fusimotor fibers. These fibers supply both intrafusal and extrafusal fibers via motor endplates at the polar ends. The endplates of γ -motoneurons differ structurally from those formed by α -motoneurons on extrafusal fibers, but both are cholinergic synapses with many features in common, including junctional folds and a basal lamina filling the synaptic cleft. [42–46].

Stimulation of γ -motoneurons result in excitation of both Ia and II muscle spindle afferents. On the other hand, stimulation of **α -motoneurons** supplying extrafusal muscle fibers, results in coactivation of γ -motoneurons which in turn causes the contraction of the polar ends of the intrafusal fibers, restoring tension and sensitivity of the muscle spindle to stretch.

Thus, the γ -motoneuron function control the sensitivity of muscle spindle afferents as length detectors. Therefore, the muscle spindle's function as a length

sensor arises essentially from its anatomical relationship with its parent muscle. Any length change in the parent muscle result in stretch of intrafusal fibers that is then detected by sensory receptors located on the equatorial and polar regions of the muscle spindle [44].

2.2 Golgi's tendon organ (tendon spindle)

The Golgi-tendon organ or tendon-spindle, localized at the origins and insertion of tendon, or rarely within the tendon. It is a mechanoreceptor that informs on muscle tension via its Ib afferent (**Figure 1**).

Structurally it consists of a capsule and within it there are loosely packed collagen fibers and muscle fibers (3–50). Among these elements there is a unique Ia afferent which branches to innervate the distal and the proximal parts of the organ [28, 47]. With respect to the skeletal muscle fibers the Golgi-tendon organ is in series between muscle and tendon.

The Golgi-tendon model react to “static and dynamic responses to activation of single motor units whose muscle fibers insert into the Golgi tendon organ, self and cross adaptation, non-linear summation when multiple motor units are active in the muscle, and the proportional relationship between the cross-adaptation and summation recorded for various pairs of motor units” [47, 48].

3. Mechanotransduction in muscle spindles

The sensory terminals of muscle spindles appear to adhere to the surface of the intrafusal muscle fibers, and although they possess a basal lamina in close contact with the plasmalemma it is absent at the sensory terminals.

3.1 Afferent glutamate-ergic neurotransmission in muscle spindles?

Bewick and co-workers [44] have demonstrate the occurrence of a complete glutamatergic neurotransmission system in the afferents of muscle spindles associated to the synaptic-like vesicles typical of those terminals. Exogenous glutamate enhances spindle excitability, an effect that can be pharmacologically blocked with specific molecules. On the other hand, synaptic-like vesicles contain glutamate, which is released during membrane cycling and, subsequently, a requirement for a replenishment mechanism.

This observation, however, does not exclude the possibility that other neuroactive substances also occur in these sensory terminals.

3.2 Ion channels and mechanotransduction in muscle spindles

In addition to the possible classical neurotransmission, the primary mechanism of mechanical transduction in muscle spindle sensory endings is the activation of stretch-sensitive ion channels. In mechanotransduction, i.e. the conversion of mechanical stimuli into biological or electrical signal, is triggered by members of the superfamilies of degenerin-epithelial Na^+ -channels (Deg-ENa⁺C; including acid-sensing ion channels -ASIC-), transient receptor potential channels (TRP), two-pore domain potassium (K_{2p}), and PIEZO [49, 50]. Some of them have been detected directly in proprioceptors as well as in primary sensory neurons innervating them. However, and similarly as in cutaneous mechanoreceptors, the stretch-sensitive channels responsible for transducing mechanical stimuli in spindle afferents awaits definitive identification (see [51]).

There is mounting evidence for the involvement of members of the Deg/ENa⁺C superfamily as mechanosensory channel(s) in mammalian primary afferent neurons, and in the sensory endings of muscle spindles [52–54]. All four subunits of the ENaC channel (α , β , γ and δ) are present in in spindle primary-sensory terminals [44, 54].

ASICs are members are a family of voltage-insensitive cation channels expressed in the nervous system and many types non-nervous cells. In rodents and humans six ASIC subtypes (ASIC1a, ASIC1b, ASIC2a, ASIC2b, ASIC3, and ASIC4) have been identified and their expression patterns are now rather well known [55, 56]. Regarding muscle spindles, evidence has been obtained in favor of a role of ASIC2 as primary mechanotransducer [53, 54]. Consistently, mice deficient in ASIC2, and also in ASIC3, show deficits in mechanical sensitivity [57–59].

PIEZO are Ca²⁺-permeable mechanosensitive channels characterized by their large size and structure [60–62]. Piezo2 is expressed in proprioceptive dorsal root ganglia (DRG) neurons [63, 64] as well as sensory endings of proprioceptors innervating muscle spindles and Golgi tendon organs in mice [64]. Loss of PIEZO2 in proprioceptive neurons results in ataxia and dysmetria, severely uncoordinated body movements and abnormal limb positions, contracture of multiple joints, and muscle weakness, suggesting that PIEZO2 requirement for the activity of these mechanosensors [64–69]. Recently, an elegant study by the Ana Gomis's group corroborated these findings using mesencephalic nucleus proprioceptive neurons [70].

Regarding TRP channels there is little evidence for a role in low-threshold sensation in spindles.

4. Proprioceptive pathways

To drive proprioception to the central nervous system two different pathways must be considered: the unconscious proprioception is conveyed primarily via the spinocerebellar tracts to the cerebellum while the conscious proprioception is conveyed by the dorsal column-medial lemniscus pathway and the thalamus to the cerebral cortex.

Classically, the proprioceptive pathways of the spinal nerves have been described as a 2 neurons chain (**Figure 2**). The primer order neuron is a pseudo-unipolar neuron whose bodies are localized in DRG whose peripheral axonal branches reach proprioceptors (especially muscle spindles and Golgi tendon organs) and the central branch reach the base of the dorsal horn of the spinal cord. The second order neurons are placed in the medial Stilling-Clarke's column (which extends between the medullary segments C8 and L2) and the lateral Bechterew's column, both corresponding to the Rexed's lamina VII of the dorsal horn; in these columns the spinocerebellar tracts (dorsal or Foville-Flechsig fascicle and ventral or Gowers fascicle) originate to ascend and reach the cerebellum. This information is necessary unconscious. The spinocerebellar neurons together provide the major direct sensory projection from the hindlimbs and lower part of the trunk to the cerebellum. A parallel system serving the forelimbs includes the direct cuneocerebellar and rostral spinocerebellar tracts and other indirect pathways via the lateral reticular nucleus and the inferior olive.

Nevertheless, some aspects of the proprioception are conscious, and therefore the information must reach the cerebral cortex. For these components of the proprioceptive sensitivity, the proprioceptive pathways consist of a 3 neurons chain (**Figure 2**). The primary order neurons are placed in DRG and the central branch of their axons ascend throughout the dorsal columns of the spinal cord to reach the gracile and cuneate nuclei in the medulla. In those nuclei are placed the bodies

of the secondary order neurons whose axons project to the ventral postero-lateral (VPL) nucleus of the thalamus (tertiary order neuron) whose axons end in the somatosensory cortex to provide the conscious perception of proprioception.

A particular question arises from cephalic muscles. They are innervated by cranial nerves and most of them (with the exception of jaw muscles and extraocular muscles) lack typical proprioceptors, i.e. muscle spindles. At present is commonly accepted that the proprioception of the cephalic territory depends on the trigeminal nerve [27, 71]. But the Gasser's ganglion of the trigeminal nerve does not contain proprioceptive neurons, while they are localized in the trigeminal mesencephalic nucleus.

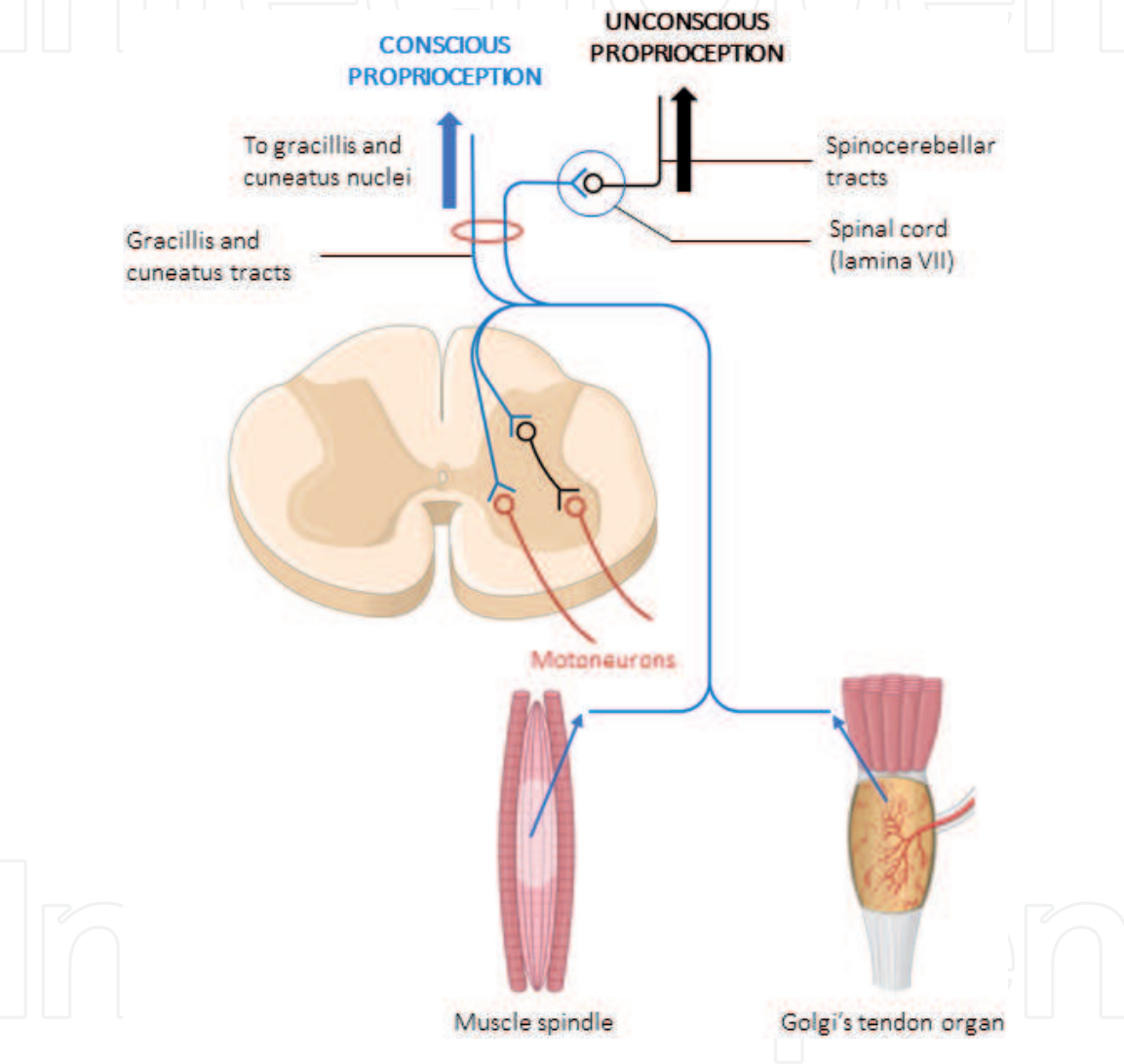


Figure 2.
Schematic representation of proprioceptive unconscious (black) and conscious (blue) pathways reaching the cerebellum and the brain, respectively.

4.1 Primary order neurons: the proprioceptive neurons

The proprioceptive neurons represent a small population (about 7–10%) of DRG primary sensory neurons and correspond with those with the largest cell bodies [72]. They can be classified and distinguished from other dorsal root ganglion neurons as a unique neuronal population using single cell transcriptome analysis [73]. They typically express the neurotrophin receptor TrkC (the preferred ligand for neurotrophin-3) and the Ca^{2+} -binding protein parvalbumin [74], as well as other markers that define this neuronal population [75].

The peripheral branch of the axons of the proprioceptive pseudo-unipolar neurons forms large-myelinated A α and A β fibers in peripheral nerves, while the central branch establish synapse in the spinal cord or ascends throughout the dorsal columns of the spinal cord to reach the gracile and cuneate nuclei in the medulla. Some peripheral branches, however, travel through the cuneatus tract and ascend the cervical spinal cord to reach the medulla oblongata to reach the accessory cuneate nucleus.

4.2 Secondary order neurons: the medial stilling-Clarke's (*nucleus dorsalis*) and lateral Bechterew's columns

The secondary order neurons of the proprioceptive pathways are localized at the base of the dorsal horn of the spinal cord, in correspondence with the VII Rexed's lamina, also known as the intermediate zone of the spinal cord. In this place two nuclear columns were classically considered: the nucleus dorsalis of Clarke (also known as Clarke's column, dorsal nucleus, posterior thoracic nucleus) and the medial nucleus (also known as Bechterew's nucleus). The axons of the neurons localized at these places form the spinocerebellar tracts.

4.3 The spinocerebellar tracts – unconscious proprioception

The tracts that carry unconscious proprioceptive information are collectively known as the spinocerebellar tracts. Within the spinocerebellar tracts, there are four individual pathways: ventral, dorsal, rostral and cuneocerebellar.

4.3.1 Ventral spinocerebellar tract (VSCT; anterior spinocerebellar, Gowers' fascicle)

VSCT originates mainly from the medial part of lamina 7 in the lumbosacral segments, from the dorsolateral nucleus of lamina 9 at L3-L6, and also from the neurons of the ventrolateral nucleus of lamina 9 and the lateral part of lamina 7 at L4-L5 segments [76, 77]. Axons decussate in the anterior white commissure and run in the ventral border of the lateral funiculi. They ascend through the brainstem to the pons where turn dorsally and enter the cerebellum throughout the superior cerebellar peduncle. For the most part, the ventral spinocerebellar tract axons recross the midline in the deep white matter of the cerebellum to terminate ipsilaterally. It terminates in the cortex of the anterior lobe and vermis of the posterior lobe and give collaterals to the globose and emboliform nuclei.

4.3.2 Dorsal spinocerebellar tract (DSCT; posterior spinocerebellar tract, Flechsig's fasciculus, Foville-Flechsig fasciculus)

This nucleus is present from Th1 through the second lumbar spinal segments and is largest in the lower thoracic and upper lumbar segments [77]. The cells of origin of the DSCT are classically described as residing in Clarke's column of the lumbar and thoracic spinal cord segments. The *nucleus dorsalis* of Clarke is a group of neurons localized in the medial part of lamina VII extending from C7 to L2 levels related to the proprioception of the lower limb. Caudally it begins at L2 level and reaches its maximum at Th12 level and above Th8 level its size diminishes, and the column ends at C7 level. Nevertheless, it is represented in other spinal regions by scattered neurons, which become aggregated to form a cervical nucleus at C3 level and a sacral nucleus in the middle of the sacral spine region (**Figure 2**).

In addition, other groups of neurons that also belong to DSCT are located throughout the intermediate and dorsal laminae of the thoracic and lumbosacral segments of the spinal cord. The axons of the DSCT ascend ipsilaterally in the peripheral region of the funiculus lateralis of the spinal cord. Then, they continue to course through the medulla oblongata and finally pass through the inferior cerebellar peduncle and into the cerebellum, and terminate in the cerebellar cortex of lobules I–V, in the anterior lobe and in the posterior lobe vermis and paramedian lobe. In addition to those cortical projections, there is evidence that DSCT fibers also terminate in the medial and interpositus cerebellar nuclei.

4.3.3 Rostral spinocerebellar tract

The rostral spinocerebellar tract appears to be the upper extremity homolog of the ventral spinocerebellar tract. The neurons of origin of this tract are located in Rexed laminae V–VII of the C5–C8 segments. The projection is predominantly ipsilateral, but there is also a minor bilateral projection. The axons of the rostral spinocerebellar tract neurons terminate in the anterior and paramedian lobule cerebellar.

4.3.4 Cuneocerebellar tract (posterior external arcuate fibers, dorsal external arcuate fibers)

DSCT does not convey information from the upper limb since the *nucleus dorsalis* does not extend into the cervical spinal cord. Therefore, there is another proprioceptive pathway for the upper limb: the cuneocerebellar tract. The secondary order neurons of this nucleus pass to the inferior ipsilateral cerebellar peduncle to reach the spinocerebellum.

4.3.5 Other spinocerebellar tracts

There are additional ascending direct and indirect spinocerebellar pathways. The *spinocervical tract* relays in the lateral cervical nucleus and projects to the ventral postero-lateral (VPL) nucleus of the thalamus. The *spinohypothalamic* and *spinoamygdalar* tract provides sensory input to areas of the nervous system involved in controlling autonomic, endocrine and emotional responses. Sensory information from the hindlimbs is also relayed by indirect *spinoreticulocerebellar* pathways through at least two olivocerebellar pathways: the indirect *spinoreticuloolivocerebellar* tract and the direct *spinoolivocerebellar* tract.

These pathways provide necessary information regarding the current status of reflex pathways, as well as muscle tone, length and tension that consent the cerebellum to coordinate and regulate motor activity.

4.4 The brain connection – conscious proprioception

According to Proske and Gadvia [4] there are at least two reasons for including body schemas and images in the study and discussion of proprioception. “First, while proprioceptors provide information about position and movement of the limb, they are unable to signal the length of limb segments and therefore the absolute location of the limb in space. Second, there is the issue of body ownership”. The blind movement of a limb, while proprioceptive feedback informs us about the movement, we need to be able to identify the moving limb as our own [78, 79]. Carruthers has proposed that all representations of the body are available to consciousness [80]. “On-line,” newly constructed body representations, provided by inputs from vision, touch, and

proprioception, generate a perception of the body as it actually is at any moment in time, an image which is able to change from moment to moment. It is distinguished from an “off-line” representation constructed, in part, from current sensory inputs, in part, from stored memories and is available to consciousness both immediately and after retrieval of memories.

In the last times neuroimaging has strongly contributed to the knowledge of the central activity patterns produced by proprioceptive stimuli, to the recognition of the integration of proprioceptive inputs with inputs from other senses and the identification of central areas involved in the integration [81]. These include regions in the parietal cortex [82–85] including the primary somatosensory cortex [86, 87]. Furthermore, parts of the frontal cortex and insula [88, 89] are involved in proprioception.

4.5 The mesencephalic trigeminal nucleus

The mesencephalic trigeminal nucleus is a sensory structure located at the meso-pontine junction and contains the cell bodies of primary order afferent proprioceptors that innervate muscle spindles of the muscles of mastication and other muscles of the head and neck [27, 71]. Whether these primary sensory neurons are generated directly in brain or have a of neural crest origin is still debated. Classically it has been regarded as a representation of a peripheral sensory ganglion similar to DRG that became incorporated into de brainstem during embryonic development, although molecular studies support a central origin for these cells [90, 91].

It projects to the dorsolateral division of the trigeminal motor nucleus and to the supratrigeminal nucleus, which are involved in humans in the jaw-jerk reflex and the periodontal-masseteric reflex [92] (for a review see [93]).

5. Proprioception from a clinical perspective: causes for impaired proprioception

Proprioception is critical factor for stability, and it is well known it deteriorates in aged people [94]. In fact, the proprioceptive system undergoes significant structural and functional changes with aging which cause a progressive decline in somatosensibility including proprioception [95–97].

Aging courses with muscle weakness from sarcopenia, decrease in the number of intrafusal fibers in muscle spindles, and denervation. All together these facts diminished muscle force and consistently the proprioception which, in turn determinate the increase in falls in the elderly with clinical and public health consequences. The specific relationship between muscle strength and proprioception should be explored further as it may provide a basis for the claim that exercise improves standing stability. Interestingly, to achieve a reduction in the incidence of falls, it is not sufficient to improve muscle strength alone as exercises are required which actually challenge standing stability. These changes might contribute to the frequent falls and motor control problems observed in older adults. On the structural level, muscle spindles in aged humans possess fewer intrafusal fibers, an increased capsular thickness and some spindles which show signs of denervation [98, 99].

A variety of neurological diseases are characterized by irregular, jerky movement or posture due to loss of proprioceptive sensory feedback, a disturbance called afferent ataxia. The affected neurons are primary sensory neurons in the dorsal root ganglia relaying body position and movement (proprioception) to the central nervous system. Proprioception dysfunction can be caused by injuries and disorders

that affect any part of the proprioceptive system between the sensory receptors that send the signals to the parts of the brain that receive and interpret them. The risk of proprioception loss increases as we age due to a combination of natural age-related changes to the nerves, joints, and muscles. Examples of injuries and conditions that can cause proprioceptive deficit include: brain injuries, herniated disc, arthritis, multiple sclerosis (MS), stroke, autism spectrum disorder (ASD), diabetes, peripheral neuropathy, Parkinson's disease, Huntington's disease, ALS (amyotrophic lateral sclerosis), or Lou Gehrig's disease. Joint injuries, such as an ankle sprain or knee sprain, joint replacement surgery, such as hip replacement or knee replacement, Parkinson's disease. Primary proprioceptive neurons may be the target of hereditary, developmental, degenerative, toxic, inflammatory and autoimmune pathology. Accordingly, typical clinical consequences of pathology affecting proprioceptive neurons, in addition to afferent ataxia, include loss of deep tendon (stretch) reflexes and of conscious perception of position and movement of body parts, often associated with loss of perception of vibration [9]. Recently, Dionisi and co-workers have obtained proprioceptive primary sensory neurons from iPSCs, and the generation of intrafusal fibers in vitro are opening new perspectives for the treatment of some ataxia linked to altered primary proprioceptive neurons [100, 101].

Author details

José A. Vega^{1,2*} and Juan Cobo^{3,4}

1 Departamento de Morfología y Biología Celular, Grupo SINPOS, Universidad de Oviedo, Oviedo, Spain


2 Facultad de Ciencias de la Salud, Universidad Autónoma de Chile, Santiago de Chile, Chile

3 Departamento de Cirugía y Especialidades Médico-Quirúrgicas, Universidad de Oviedo, Oviedo, Spain

4 Instituto Asturiano de Odontología, Oviedo, Spain

*Address all correspondence to: javega@uniovi.es

IntechOpen

© 2021 The Author(s). Licensee IntechOpen. This chapter is distributed under the terms of the Creative Commons Attribution License (<http://creativecommons.org/licenses/by/3.0>), which permits unrestricted use, distribution, and reproduction in any medium, provided the original work is properly cited. 

References

- [1] Kröger S, Watkins B. Muscle spindle function in healthy and diseased muscle. *Skelet Muscle*. 2021; 11:3.
- [2] Williams SR, Chapman CE. Time course and magnitude of movement-related gating of tactile detection in humans. II. Effects of stimulus intensity. *J Neurophysiol*. 2000; 84: 863-875.
- [3] Ciancia F, Maitte M, Coquery JM. Reduction during movement of the evoked potentials recorded along the extralemniscal pathways of the cat. *Electroencephalogr Clin Neurophysiol*. 1980; 48: 197-202.
- [4] Proske U, Gandevia SC. The kinaesthetic senses. *J Physiol*. 2009; 587: 4139-4146.
- [5] Proske U, Gandevia SC. The proprioceptive senses: their roles in signaling body shape, body position and movement, and muscle force. *Physiol Rev*. 2012; 92:1651-1697.
- [6] Ferlinc A, Fabiani E, Velnar T, Gradisnik L. The Importance and Role of Proprioception in the Elderly: a Short Review. *Mater Sociomed*. 2019; 31: 219-221.
- [7] Henry M, Baudry S. Age-related changes in leg proprioception: implications for postural control. *J Neurophysiol*. 2019; 122: 525-538.
- [8] Ganz DA, Latham NK1. Prevention of Falls in Community-Dwelling Older Adults. *N Engl J Med*. 2020; 382: 734-743.
- [9] Pandolfo M, Manto M. Cerebellar and Afferent Ataxias. *Continuum Lifelong Learn Neurology* 2013; 19: 1343.
- [10] Klockgether T, Mariotti C, Paulson HL. Spinocerebellar ataxia. *Nat Rev Dis Primers*. 2019; 5: 24.
- [11] Proske U, Gandevia SC. Kinesthetic Senses. *Compr Physiol*. 2018; 8: 1157-1183.
- [12] Proske U. Exercise, fatigue and proprioception: a retrospective. *Exp Brain Res*. 2019; 237: 2447-2459.
- [13] Banks RW. The innervation of the muscle spindle: a personal history. *J Anat*. 2015; 227: 115-135.
- [14] Kröger S. Proprioception 2.0: novel functions for muscle spindles. *Curr Opin Neurol*. 2018; 31:592-598.
- [15] Grigg P. Peripheral neural mechanisms in proprioception. *J Sport Rehab*. 1994; 3: 2-17.
- [16] Banks RW, Hulliger M, Saed HH, Stacey MJ. A comparative analysis of the encapsulated end-organs of mammalian skeletal muscles and of their sensory nerve endings. *J Anat*. 2009; 214: 859-887.
- [17] Burke D, Gandevia SC, Macefield G. Responses to passive movement of receptors in joint, skin and muscle of the human hand. *J Physiol*. 1988; 402: 347-361.
- [18] Collins DF, Prochazka A. Movement illusions evoked by ensemble cutaneous input from the dorsum of the human hand. *J Physiol*. 1996; 496: 857-871.
- [19] Frith C. The self in action: lessons from delusions of control. *Consciousness Cognition*. 2005; 14: 752-770.
- [20] Johansson RS, Flanagan JR. Coding and use of tactile signals from the fingertips in object manipulation tasks. *Nat Rev Neurosci*. 2009; 10: 345-359.
- [21] Zimmerman A, Bai L, Ginty DD. The gentle touch receptors

- of mammalian skin. *Science*. 2014; 346: 950-954.
- [22] Cobo R, García-Piqueras J, Cobo J, Vega JA. The Human Cutaneous Sensory Corpuscles: An Update. *J Clin Med*. 2021; 10(2). pii: E227.
- [23] Gandevia SC, Miller S, Aniss AM, Burke D. Reflex influences on muscle spindle activity in relaxed human leg muscles. *J Neurophysiol*. 1986; 56: 159-170.
- [24] Edin BB. Quantitative analyses of dynamic strain sensitivity in human skin mechanoreceptors. *J Neurophysiol*. 2004; 92: 3233-3243.
- [25] Izumizaki M, Tsuge M, Akai L, Proske U, Homma I. The illusion of changed position and movement from vibrating one arm is altered by vision or movement of the other arm. *J Physiol*. 2010; 588: 2789-2800.
- [26] Cobo JL, Abbate F, de Vicente JC, Cobo J, Vega JA. Searching for proprioceptors in human facial muscles. *Neurosci Lett*. 2017; 640:1-5.
- [27] Cobo JL, Solé-Magdalena A, Junquera S, Cobo T, Vega JA, Cobo J. The Proprioception in the Muscles Supplied by the Facial Nerve. In: *Selected Topics in Facial Nerve Disorders*, I. Al-Zwaini and M.J Hussein Eds. InTechOpen, London, 2019, pp. 15.28.
- [28] Jami L. Golgi tendon organs in mammalian skeletal muscle: functional properties and central actions. *Physiol Rev*. 1992; 72: 623-666.
- [29] Proske U. The tendon organ. In: *Peripheral Neuropathy*, edited by Dyck P, Thomas P, Griffin J, Low P, Poduslo J. Philadelphia, PA: Saunders, 1993, p. 141-148.
- [30] Banks RW. The muscle spindle. In: Dyck PJ, Thomas PK, editors. *Peripheral neuropathy*. 4. Philadelphia: WB Saunders; 2005. pp. 131-150.
- [31] Banks RW. The innervation of the muscle spindle: a personal history. *J Anat*. 2015; 227:115-135.
- [32] Soukup T, Pederosa-Domellöf F, Thornell LE. Intrafusal fiber type composition of muscle spindles in the first human lumbrical muscle, *Acta Neuropathol (Berl)*. 2003; 105:18-24.
- [33] Kulkarni V, Chandy MJ, Babu KS: Quantitative study of muscle spindles in suboccipital muscles of human foetuses. *Neurol India*. 2001; 49: 355-359.
- [34] Liu J-X, Eriksson PO, Thornell L-E, Pedrosa-Domellof F. Myosin heavy chain composition of muscle spindles in human biceps brachii, *J Histochem Cytochem*. 2002; 50:171-184.
- [35] Liu J-X, Eriksson PO, Thornell L-E, Pedrosa-Domellof F. Fiber content and myosin heavy chain composition of muscle spindles in aged human biceps brachii. *J Histochem Cytochem*. 2005; 53: 445-454.
- [36] Banks RW, Harker DW, Stacey MJ. A study of mammalian intrafusal muscle fibres using a combined histochemical and ultrastructural technique. *J Anat*. 1977; 123: 783-796.
- [37] Liu J-X, Thornell L-E, Pedrosa-Domellof F. Muscle spindles in the deep muscles of the human neck: a morphological and immunocytochemical study. *J Histochem Cytochem*. 2003; 51: 175-186.
- [38] Ovalle WK, Smith RS: Histochemical identification of three types of intrafusal muscle fibers in cat and monkey based on myosin ATPase reaction *Can J Physiol Pharmacol*. 1972; 50:195-202.

- [39] Kucera J, Dorovini-Zis K. Types of human intrafusal muscle fibers. *Muscle Nerve*. 1979; 2:437-451.
- [40] Thornell LE, Carlsson L, Eriksson PO, Liu JX, Österlund C, Stål P, Pedrosa-Domellöf F. Fibre typing of intrafusal fibres. *J Anat*. 2015; 227: 136-156.
- [41] Matthews PB. Where Anatomy led, Physiology followed: a survey of our developing understanding of the muscle spindle, what it does and how it works. *J Anat*. 2015;227: 104-114.
- [42] Edin BB, Vallbo AB. Dynamic response of human muscle spindle afferents to stretch. *J Neurophysiol*. 1990a; 63: 1297-1306.
- [43] Proske U. The mammalian muscle spindle. *News Physiol Sci*. 1997; 12: 37-42.
- [44] Bewick GS, Banks RW. Mechanotransduction in the muscle spindle. *Pflugers Arch*. 2015; 467:175-90.
- [45] Banks RW. The motor innervation of mammalian muscle-spindles. *Prog Neurobiol*. 1994;43: 323-362.
- [46] Manuel M, Zytnicki D. *alpha*, beta and gamma motoneurons: functional diversity in the motor system's final pathway. *J Integr Neurosci*. 2011; 10: 243-276.
- [47] Proske U. The Golgi tendon organ, *Int Rev Physiol*. 1981; 25:127-171.
- [48] Mileusnic MP, Loeb GE. Mathematical models of proprioceptors. II Structure and function of the Golgi tendon organ, *J Neurophysiol*. 2006; 96:1789-1802.
- [49] Delmas P, Coste B. Mechano-gated ion channels in sensory systems. *Cell*. 2013; 155:278-284.
- [50] Cobo R, García-Piqueras J, García-Mesa Y, Feito J, García-Suárez O, Vega JA. Peripheral Mechanobiology of Touch-Studies on Vertebrate Cutaneous Sensory Corpuscles. *Int J Mol Sci*. 2020; 21(17). pii: E6221.
- [51] Anderson EO, Schneider ER, Bagriantsev SN. Piezo2 in Cutaneous and Proprioceptive Mechanotransduction in Vertebrates. *Curr Top Membr*. 2017; 79: 197-217.
- [52] Ismailov II, Berdiev BK, Shlyonsky VG, Benos DJ. Mechanosensitivity of an epithelial Na⁺ channel in planar lipid bilayers: release from Ca²⁺ block. *Biophys J*. 1997; 72:1182-1192.
- [53] Simon A, Shenton F, Hunter I, Banks RW, Bewick GS. Amiloride-sensitive channels are a major contributor to mechanotransduction in mammalian muscle spindles, *J Physiol*. 2010; 588: 171-85.
- [54] Althaus M, Bogdan R, Clauss WG, Fronius M. Mechano-sensitivity of epithelial sodium channels (ENaCs): laminar shear stress increases ion channel open probability. *FASEB J*. 2007; 21:2389-2399.
- [55] Baron A, Lingueglia E. Pharmacology of acid-sensing ion channels - physiological and therapeutical perspectives. *Neuropharmacology*. 2015; 94:19-35.
- Cheng YR, BY, Chen CC. Acid-sensing ion channels: dual function proteins for chemo-sensing and mechano-sensing. *J Biomed Sci*. 2018; 25: 46.
- [56] Lee CH, Chen CC. Roles of ASICs in Nociception and Proprioception. *Adv Exp Med Biol*. 2018; 1099: 37-47.
- [57] Chen CC, Wong CW. Neurosensory mechanotransduction through acid-sensing ion channels. *J Cell Mol Med*. 2013 ;17: 337-49.

- [58] Lin SH, Sun WH, Chen CC. Genetic exploration of the role of acid-sensing ion channels. *Neuropharmacology*. 2015; 94: 99-118.
- [59] Omerbasic D, Schuhmacher LN, Bernal Sierra YA, Smith ES, Lewin GR. ASICs and mammalian mechanoreceptor function. *Neuropharmacology*. 2015; 94:80-86.
- [60] Murthy SE, Dubin AE, Patapoutian A. Piezos thrive under pressure: mechanically activated ion channels in health and disease. *Nat Rev Mol Cell Biol*. 2017; 18:771-83.
- [61] Saotome K, Murthy SE, Kefauver JM, Whitwam T, Patapoutian A, Ward AB. Structure of the mechanically activated ion channel Piezo1. *Nature*. 2017; 554: 481.
- [62] Zhao Q, Zhou H, Chi S, Wang Y, Wang J, Geng J, Wu K, Liu W, Zhang T, Dong MQ, Wang J, Li X, Xiao B. Structure and mechanogating mechanism of the Piezo1 channel. *Nature*. 2018; 554: 487-492.
- [63] Woo SH, Lukacs V, de Nooij JC, Zaytseva D, Criddle CR, Francisco A, Jessell TM, Wilkinson KA, Patapoutian A. Piezo2 is the principal mechanotransduction channel for proprioception. *Nat Neurosci*. 2015; 18:1756-1862.
- [64] Woo SH, Ranade S, Weyer AD, Dubin AE, Baba Y Qiu Z, Petrus M, Miyamoto T, Reddy K, Lumpkin EA, Stucky CL, Patapoutian A. Piezo2 is required for Merkel-cell mechanotransduction. *Nature*. 2014; 509:622-6.
- [65] Chesler AT, Szczot M, Bharucha-Goebel D, Čeko M, Donkervoort S, Laubacher C, Hayes LH, Alter K, Zampieri C, Stanley C, Innes AM, Mah JK, Grossmann CM, Bradley N, Nguyen D, Foley AR, Le Pichon CE, Bönnemann CG. The role of *PIEZO2* in human mechanosensation. *N Engl J Med*. 2016; 375: 1355-64.
- [66] Haliloglu G, Becker K, Temucin C, Talim B, Küçükşahin N, Pergande M, Motameny S, Nürnberg P, Aydingoz U, Topaloglu H, Cirak S. Recessive *PIEZO2* stop mutation causes distal arthrogryposis with distal muscle weakness, scoliosis and proprioception defects. *J Hum Genet*. 2017; 62:597-501.
- [67] Delle Vedove A, Storbeck M, Heller R, Hölker I, Hebbar M, Shukla A, Magnusson O, Cirak S, Girisha KM, O'Driscoll M, Loeys B, Wirth B. Biallelic loss of proprioception-related *PIEZO2* causes muscular atrophy with perinatal respiratory distress, arthrogryposis, and scoliosis. *Am J Hum Genet*. 2016; 99:1206-16.
- [68] Mahmud AA, Nahid NA, Nassif C, Sayeed MS, Ahmed MU, Parveen M, Khalil MI, Islam MM, Nahar, Z, Rypens F, Hamdan FF, Rouleau GA, Hasnat A, Michaud JL. Loss of the proprioception and touch sensation channel *PIEZO2* in siblings with a progressive form of contractures. *Clin Genet*. 2017; 91:470-5.
- [69] Assaraf E, Blecher R, Heinemann-Yerushalmi L, Krief S, Carmel Vinestock R, Biton IE, Brumfeld V, Rotkopf R, Avisar E, Agar G, Zelzer E. Piezo2 expressed in proprioceptive neurons is essential for skeletal integrity. *Nat Commun*. 2020; 11: 3168.
- [70] Florez-Paz D, Bali KK, Kuner R, Gomis A. A critical role for Piezo2 channels in the mechanotransduction of mouse proprioceptive neurons. *Sci Rep*. 2016; 6:25923.
- [71] Lazarov NE. Neurobiology of orofacial proprioception. *Brain Research Reviews*. 2007; 56:362-383.

- [72] Marmigère F, Ernfors P. Specification and connectivity of neuronal subtypes in the sensory lineage. *Nat Rev Neurosci*. 2007; 8: 114-127.
- [73] Oliver KM, Florez-Paz DM, Badea TC, Mentis GZ, Menon V, de Nooij JC. Molecular development of muscle spindle and Golgi tendon organ sensory afferents revealed by single proprioceptor transcriptome analysis. *bioRxiv*. 2020. DOI: 10.1101/2020.04.03.023986.
- [74] Hippenmeyer S, Vrieseling E, Sigrist M, Portmann T, Laengle C, Ladle DR, Arber S.. A Developmental Switch in the Response of DRG Neurons to ETS Transcription Factor Signaling. *Plos Biol*. 2005; 3: e159.
- [75] Poliak S, Norovich AL, Yamagata M, Sanes JR, Jessell TM. Muscle-type Identity of Proprioceptors Specified by Spatially Restricted Signals from Limb Mesenchyme. *Cell* 2016; 164: 512-525.
- [76] Xu Q, Grant G. Course of spinocerebellar axons in the ventral and lateral funiculi of the spinal cord with projections to the posterior cerebellar termination area: an experimental anatomical study in the cat, using a retrograde tracing technique. *Exp Brain Res*. 2005; 162:250-256.
- [77] Watson C, Paxinos G, Kayalioglu G (Eds). *The spinal cord*. Academic Press, New York, 2008.
- [78] De Vignemont F. Body schema and body image—pros and cons. *Neuropsychologia* 2010; 48: 669-680.
- [79] Longo MR, Haggard P. An implicit body representation underlying human position sense. *Proc Natl Acad Sci USA*. 2010; 107: 11727-11732.
- [80] Carruthers G. Types of body representation and the sense of embodiment. *Conscious Cogn*. 2008; 17: 1302-1316.
- [81] Sanchez-Vives MV, Slater M. From presence to consciousness through virtual reality. *Nat Rev Neurosci*. 2005; 6: 332-339.
- [82] Ehrsson HH, Holmes NP, Passingham RE. Touching a rubber hand: feeling of body ownership is associated with activity in multisensory brain areas. *J Neurosci*, 2005; 25: 10564-10573.
- [83] Ehrsson HH, Spence C, Passingham RE. That's my hand! Activity in premotor cortex reflects feeling of ownership of a limb. *Science* 2004; 305: 875-877.
- [84] Pellieff A, Bonilha L, Morgan PS, McKenzie K, Jackson SR. Parietal updating of limb posture: an event-related fMRI study. *Neuropsychologia*. 2006; 44: 2685-2690.
- [85] Hagura N, Oouchida Y, Aramaki Y, Okada T, Matsumura M, Sadato N, Naito E. Visuokinesthetic perception of hand movement is mediated by cerebro-cerebellar interaction between the left cerebellum and right parietal cortex. *Cereb Cortex*. 2009; 19: 176-186.
- [86] Schaefer M, Flor H, Heinze HJ, Rotte M. Morphing the body: illusory feeling of an elongated arm affects somatosensory homunculus. *Neuroimage*. 2007; 36: 700-705.
- [87] Schaefer M, Heinze HJ, Rotte M. My third arm: shifts in topography of the somatosensory homunculus predict feeling of an artificial supernumerary arm. *Hum Brain Mapp*. 2009; 30: 1413-1420.
- [88] Schwoebel J, Coslett HB. Evidence for multiple, distinct representations of the human body. *J Cogn Neurosci*. 2005; 17: 543-553.

- [89] Tsakiris M, Hesse MD, Boy C, Haggard P, Fink GR. Neural signatures of body ownership: a sensory network for bodily self-consciousness. *Cereb Cortex*. 2007; 17: 2235-2244.
- [90] Dyer C, Linker C, Graham A, Knight R. Specification of sensory neurons occurs through diverse developmental programs functioning in the brain and spinal cord. *Dev Dyn*. 2014; 243: 1429-1439.
- [91] Müller F, O'Rahilly R. The initial appearance of the cranial nerves and related neuronal migration in staged human embryos. *Cells Tissues Organs*. 2011; 193: 215-238.
- [92] Shigenaga Y, Yoshida A, Mitsuhiro Y, Doe K, Suemune S. Morphology of single mesencephalic trigeminal neurons innervating periodontal ligament of the cat. *Brain Res*. 1988; 448: 331-338.
- [93] Yoshida A, Moritani M, Nagase Y, Bae YC. Projection and synaptic connectivity of trigeminal mesencephalic nucleus neurons controlling jaw reflexes. *J Oral Sci*. 2017; 59: 177-182.
- [94] Ribeiro F, Oliveira J. Aging effects on joint proprioception: the role of physical activity in proprioception preservation. *Eur Rev Aging Phys Act*. 2007; 4: 71-76.
- [95] Verschueren SM, Brumagne S, Swinnen SP, Cordo PJ. The effect of aging on dynamic position sense at the ankle. *Behav Brain Res*. 2002; 136: 593-603.
- [96] Landelle C, El Ahmadi A, Kavounoudias A. Age-related impairment of hand movement perception based on muscle proprioception and touch. *Neuroscience*. 2018; 381:91-104.
- [97] García-Piqueras J, García-Mesa Y, Cárcaba L, Feito J, Torres-Parejo I, Martín-Biedma B, Cobo J, García-Suárez O, Vega JA. Ageing of the somatosensory system at the periphery: age-related changes in cutaneous mechanoreceptors. *J Anat*. 2019; 234:839-852.
- [98] Swash M, Fox KP. The effect of age on human skeletal muscle. Studies of the morphology and innervation of muscle spindles. *J Neurol Sci*. 1972; 16: 417-432.
- [99] Liu JX, Eriksson PO, Thornell LE, Pedrosa-Domellof F. Fiber content and myosin heavy chain composition of muscle spindles in aged human biceps brachii. *J Histochem Cytochem*. 2005; 53: 445-454.
- [100] Dionisi C, Rai M, Chazalon M, Schiffmann SN, Pandolfo M. Primary proprioceptive neurons from human induced pluripotent stem cells: a cell model for afferent ataxias. *Sci Rep*. 2020; 10: 7752.
- [101] Barret P, Quick TJ, Mudera V, Player DJ. Generating intrafusal skeletal muscle fibres in vitro: Current state of the art and future challenges. *J Tissue Eng*. 2020; 11: 1-15.