

# We are IntechOpen, the world's leading publisher of Open Access books Built by scientists, for scientists

6,900

Open access books available

185,000

International authors and editors

200M

Downloads

Our authors are among the

154

Countries delivered to

TOP 1%

most cited scientists

12.2%

Contributors from top 500 universities



WEB OF SCIENCE™

Selection of our books indexed in the Book Citation Index  
in Web of Science™ Core Collection (BKCI)

Interested in publishing with us?  
Contact [book.department@intechopen.com](mailto:book.department@intechopen.com)

Numbers displayed above are based on latest data collected.  
For more information visit [www.intechopen.com](http://www.intechopen.com)



# Bone Quality of the Dento-Maxillofacial Complex and Osteoporosis. Opportunistic Radiographic Interpretation

*Plauto Christopher Aranha Watanabe,  
Giovani Antonio Rodrigues, Marcelo Rodrigues Azenha,  
Michel Campos Ribeiro, Enéas de Almeida Souza Filho,  
Rafael Angelo Soares Vieira and Fabio Santos Bottacin*

## Abstract

Research suggests the use of different indexes on panoramic radiography as a way to assess BMD and to be able to detect changes in bone metabolism before fractures occur. Therefore, the objective of this chapter is to describe the use of these parameters as an auxiliary mechanism in the detection of low bone mineral density, as well as to characterize the radiographic findings of patients with osteoporosis.

**Keywords:** osteoporosis, oral cavity, panoramic radiography, mineral density of bone tissue, fractal dimension

## 1. Introduction

Osteoporosis is a chronic disease that affects the mineral density of bone tissue (BMD), leaving it more fragile and predisposing its carriers to a higher risk of fractures. The gold standard for the diagnosis of osteoporosis is dual X-ray densitometry (DXA), an exam that is difficult to access in some countries worldwide. Over the years, researchers have dedicated themselves to studying the radiographic findings of osteoporosis in gnathic bones in an attempt to create indexes or patterns that could assess BMD and thereby detect changes in bone metabolism before fractures occur. Thus, the objective of this chapter is to present concisely data on osteoporosis and to deepen themes related to the presence of the disease in the maxillomandibular region, as well as to review the literature presenting recent research on the use of imaging tests (X-rays, beam computed tomography, among others) to identify and aid in the diagnosis of osteoporosis [1].

## 2. Osteoporosis

Osteo Metabolic diseases are a set of disorders that affect the metabolism of bone tissue promoting a decrease in its mass and consequently causing bone fragility

and an increased incidence of fractures. The various types of osteoporosis, rickets, osteomalacia, primary hyperparathyroidism and Paget's disease are the main diseases that affect the bones [2–4].

These disorders are characterized by an imbalance between the formation and remodeling of bone tissue and among the diseases belonging to this group the most prevalent is osteoporosis which affects bone microarchitecture resulting in tissue fragility and in most cases leading to fractures in various locations in the skeleton such as the spine, hip, femur and wrist [5].

Many factors contribute to the development of this condition, such as age, sex and ethnicity, which are among the main determinants of bone mass level and risk of fractures, and the clinical complications of the disease also include chronic pain, depression, deformities, loss of independence and increased mortality [6].

In operational and diagnostic terms, the World Health Organization (WHO) defines osteoporosis as a condition in which bone mineral density is equal to or less than 2.5 standard deviations below the peak of bone mass found in young adults. Currently, the diagnosis of osteoporosis is based on the identification of different risk factors, the most important of which is the low bone mineral density (BMD) of the femur and lumbar spine [7–10].

Although dual-beam X-ray densitometry (DXA) is considered the gold standard for the diagnosis of osteoporosis, its low predictive power and low availability make it impossible to use it as a method of population screening. The imbalance of bone metabolism caused by osteoporosis leads to a decrease in bone mineral throughout the body. Like other bones in the body, the jaw can be affected by systemic diseases or drug treatments even though it is not directly involved with the disease [7, 11].

### **3. Epidemiology**

The number of osteoporosis cases in the United States of America (USA) was estimated at 14 million people in 2020, with more than two million bone fractures occurring annually as a result of osteoporosis, especially affecting women who account for 70% of cases. In men, although less prevalent, it is estimated that 30% of all hip fractures occur in this gender and the mortality rate due to the consequences of osteoporosis is higher in men than in women [1, 12].

In Brazil, South America, the statistics on the prevalence of osteoporosis are uncertain, showing great variations due to the size of the sample, the population studied and the methodologies employed. More recent studies, however, indicate that the projection for the next 5 years is that approximately 4,485,352 bone fractures will occur as a result of osteoporosis in Brazil, Mexico, Colombia and Argentina [6, 13–14].

As a result, it is relevant to study and deepen knowledge on this disease, which affects a large part of the world population and causes a high rate of morbidity and mortality, with approximately 20% of individuals who suffered hip fractures evolving to death one year after fracture. In Brazil, this rate is 23.6% of people who die 3 months after a fracture of the femur [15].

### **4. Diagnosis and treatment**

The diagnosis of osteoporosis is made by examining bone densitometry (DXA) in which there will be a quantification of bone mineral density and from which it is possible to predict the risk of fractures. This exam method is technical-dependent. Other routine and radiological exams may also be required for this diagnosis and

the evaluation of bone remodeling markers has been shown to be an important tool for clinical monitoring of patients undergoing drug treatment for osteoporosis [1].

Physical exercises with professional supervision are indicated for the non-pharmacological treatment of osteoporosis or osteopenia, as well as calcium and vitamin D supplementation are important and can be part of the treatment routine. In more severe cases, usually patients with a history of recent fractures or patients with a DXA T-score less than or equal to -2.5 standard deviations, pharmacological treatment is indicated [7].

## **5. Osteoporosis and oral cavity**

Over time and the physiological aging process, maxillofacial structures also suffer from this action and especially the bones of the jaw and maxilla, as well as the dental cementum end up showing decreased vascularization, reduced metabolic capacity and in patients affected by osteoporosis, the decrease in bone mineral density can also affect the stomatognathic system [16].

When this occurs, the main oral manifestations of osteoporosis are related to the reduction of the alveolar ridge, increased porosity of the mandible and maxilla bone, periodontal changes, greater spacing between the bone trabeculae and the decrease in the maxillary bone mass and density. In addition to the aforementioned descriptions, researchers from the University of São Paulo (Dentistry Faculties of Ribeirão Preto and São Paulo) also highlight the changes that can occur in the temporomandibular joint, that is, through the reabsorption of its components, such as the condylar region. In addition to these changes in the TMJ, a greater contrast of the oblique line of the mandible and the cortical portion of the cervical vertebrae (frame aspect) can be seen in imaging studies and can contribute to the early recognition of systemic osteoporosis [16].

Thus, imaging tests are recommended to assess the involvement of the maxilla and mandible by osteoporosis, with panoramic radiography being the most used instrument for this purpose. This exam method is also technical-dependent, but regarding the main methods of analysis of bone quality that has been proposed by researchers, the radiomorphometric indices, has good accuracy, as it is also an orthopantomographic technique as we will see below.

## **6. Osteoporosis and periodontal disease**

Tzu-Hsien L; et al. studied Association Between Periodontal Disease and Osteoporosis by Gender, being the diagnosis of periodontitis was defined on the basis of subgingival curettage, periodontal flap operation, and gingivectomy. They claim they found a significant association between periodontitis and osteoporosis among women (odds ratio: 1.96; 95% confidence interval 1.17–3.26) [17].

Regi et al., 2019 studied the radiographic comparison of mandibular bone quality in patients with chronic generalized periodontitis to assess osteoporosis of different age groups (60 patients), group 1 included patients in the age group of 30–44 years and group 2 with an age range of 45–60 years, using radio morphometric indices such as mandibular cortical index (MCI), mental index (MI), and panoramic mandibular index (PMI) in Indian population from dental panoramic radiographs. The authors could conclude that radiomorphometric indices could be used by general dentists to detect patients at higher risk of osteoporosis. This results are in agreement with Kalinowski et al, 2019 that studied the Correlations between periodontal disease, mandibular inferior cortex index and the osteoporotic fracture

probability assessed by means of the fracture risk assessment body mass index tool (Inferior Cortex (MIC) index and osteoporotic fracture probability based on the FRAX BMI tool) [18].

This FRAX BMI tool with radiological evaluation of periodontal disease severity and MIC index could be used in dental practice in determining individual risk of osteoporotic fracture in females and provide new opportunities of selecting those potentially more prone to such fractures. Years before, Iwasaki et al., 2013 conducted cross-sectional study to evaluate the possible association between BMD and clinical attachment loss (AL) with dental restoration information in Japanese community-dwelling postmenopausal females (397 females (average age: 68.2 years)). The results of this study indicated that low systemic BMD was associated with severe AL in Japanese community-dwelling postmenopausal females. Jonasson and Rythén, 2016, had already evaluated alveolar bone loss in osteoporosis. They rated that bone turnover rate in the alveolar mandibular process is probably the fastest; and thus, the first signs of osteoporosis could be revealed at the alveolar bone [19].

Still According to these authors, sparse trabeculation in the mandibular premolar region (large intertrabecular spaces and thin trabeculae) is a reliable sign of osteopenia and a high skeletal fracture risk. But, Springe and Soboleva at 2014 founded that postmenopausal women with reduced general BMD do not appear to have a reduction in the size of the mandibular residual ridge in contrast the results of the Al-Jabrah and Al-Shumailan, also 2014 that founded reduced mandibular height that would be directly related to age and duration of complete denture wearing and women are at more risk to have ridge resorption compared to men.

## **7. Principles of panoramic radiography**

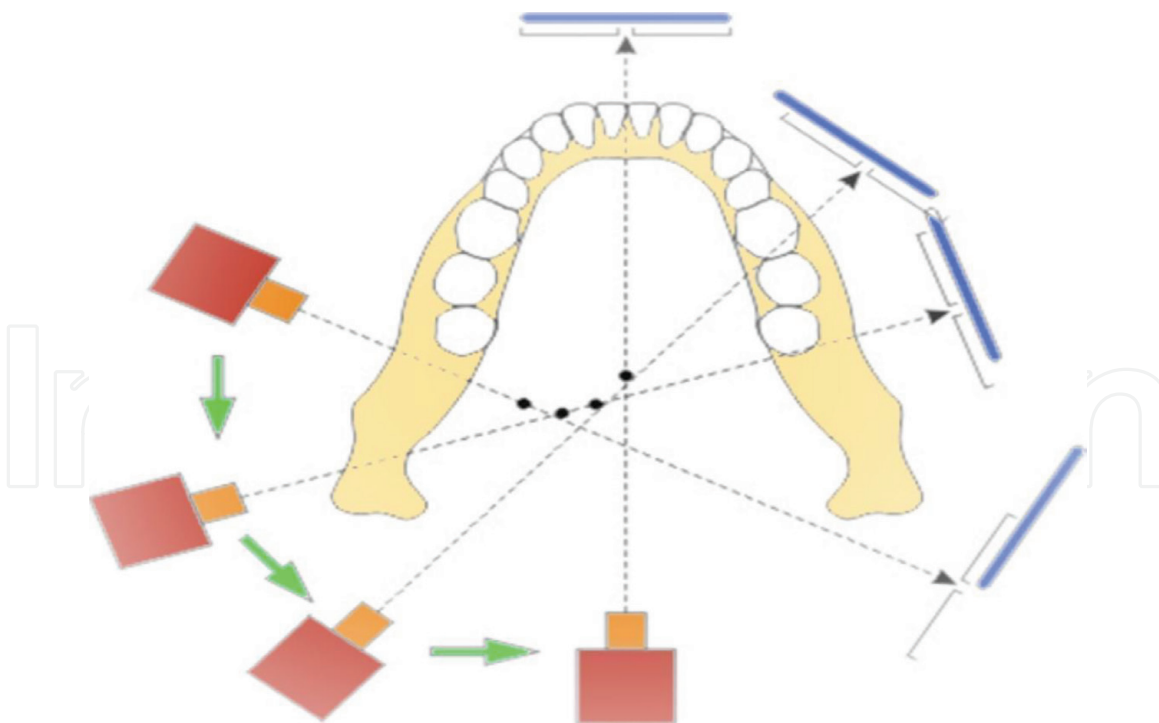
In 1948, Paatero at the University of Helsinki developed orthopantomography based on the principles of medical tomography, that is, a radiographic technique that allows the image of a section of the body to be widely used in medicine and after the advancement in implantology it started to be more used in dentistry. Thus, panoramic radiography is an extra-oral radiographic technique that is more suitable for allowing a better assessment of maxillary bones when compared to intraoral radiographs such as periapical, interproximal or bitewing radiography [20].

For panoramic radiography (PAN), the patient remains immobile while the X-ray source and radiographic sensors move in the opposite direction at one or more centers of rotation. These rotation points can be internal or external to the focal layer. Focal layer in tomography or “focal plane” or “image layer” is the plane that is not blurred in the radiographic image (**Figure 1**).

Panoramic radiography or pantomography is produced using the tomographic curve-surface and is performed by rotating a narrow beam of radiation in a horizontal plane around a virtual point/axis (called the center of rotation) positioned inside the oral cavity. Film and head move in the opposite direction around the patient, who remains stationary. Blurring is determined by the tube distance, focal plane distance, film distance and tube rotation orientation.

The center of rotation changes as the film/sensor and head rotate, allowing the image layer to adapt to the elliptical shape of the dental arches. With this, the vertical and horizontal dimensions are correlated only when the object is within a particular zone, or section plane that represents the image layer, best interpreted as the focal layer. This zone actually corresponds to a three-dimensional area in which the structures are reasonably focused or well defined. Thus, the positioning of the patient in the X-ray apparatus should be such that the dental arches are positioned strictly within this cutting area, resulting in a clear image of the teeth. That way,






**Figure 1.**  
*Schematic illustrating the principle of panoramic radiography (PAN).*

each manufacturer of panoramic X-ray apparatus recommends different layers of cut, because, of course, the dental arches are very different around the world. Objects outside the focal layer, distort. The best equipment allows you to focus on the most different dental arches, always in maximum detail (**Figure 2**) [21].

For the interpretation of these radiographic images, some characteristics need to be considered: objects closer to the film will be narrowed, objects closer to the tube will be widened and out of focus, objects located through the buccal teeth will



**Figure 2.**  
*Phantom, simulating the positioning of the patient in the panoramic X-ray equipment.*

be projected inferiorly and objects located by lingual/palatal teeth will be projected higher. Objects located in the center of the cutting layer will be enlarged by a known factor, usually supplied by the equipment manufacturer, by about 25–40% [22].

Advantages of panoramic radiography:

- Features a unique dental exam through a panoramic representation of the stomatognathic system, including ATM, styloid processes and maxillary sinuses
- Allows the detection of the functional and pathological relationship and its effects on the stomatognathic system
- Provides a document for the treatment and preservation plan
- Reduces radiation exposure through a strategic rotational system that covers a large area

Disadvantages of panoramic radiography:

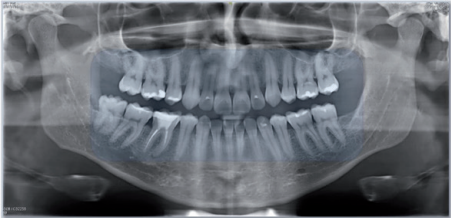
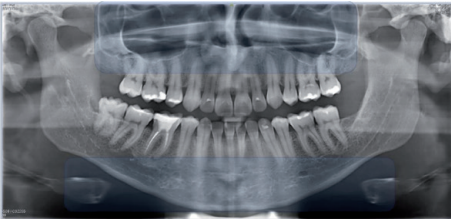
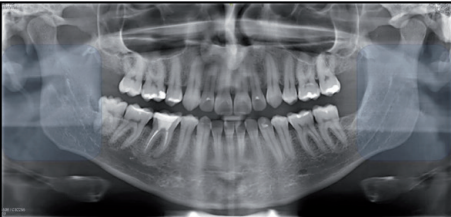
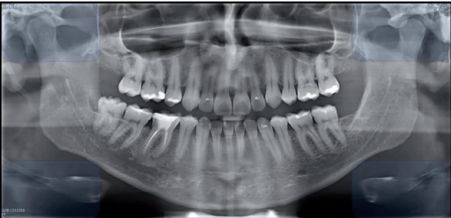
- Patients with extreme class II and III dental relationships make it impossible to have optimal images of the anterior teeth segments
- The ratio of the focus-object distance to the object-film distance is not identical in all cases, which results in a constant magnification factor
- Accurate measures are questioned
- Structures that reside outside the focus layer can be superimposed on normal structures of the jaw and simulate a pathology

The “Guidelines for the Selection of Patients for Dental Radiographic Examinations”, prepared in 2004, by a panel of experts from the American Dental Association-ADA, recommends panoramic radiographic examination together with interproximal radiographs, for every initial patient who needs state assessment. General of the teeth and mouth, and that does not have these images taken in the near period. These guidelines are not a substitute for initial clinical examination and anamnesis. The patient’s vulnerability to environmental factors that may affect his or her oral health should also be considered. The Expert Panel stresses that the panoramic radiographic examination has the main advantages of reducing the dose of radiation exposure, at a lower cost and in addition, it covers a much larger area than the periapical radiographic examination (**Tables 1 and 2; Figure 3**).

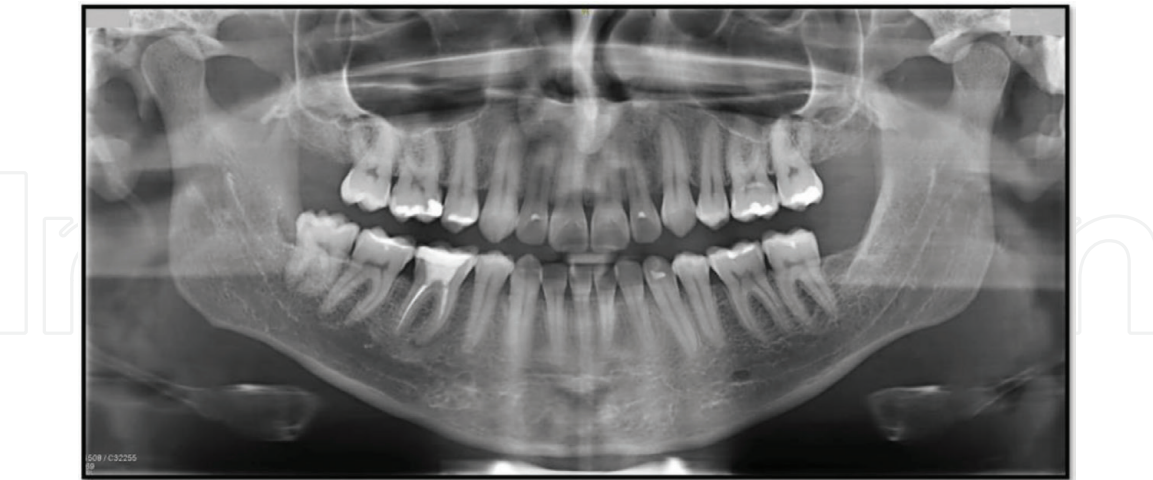
In addition to this main indication, panoramic radiographs will normally be indicated in situations where (**Table 2 and Figure 4**):

New patient - child with mixed dentition	Periapical / occlusal and interproximal or panoramic
New patient - Edentulous	Whole or panoramic mouth
Growth and development assessment - mixed dentition	Periapical / occlusal or panoramic
Growth and development assessment - permanent dentition	Periapical or panoramic to evaluate 3Ms

**Table 1.**  
*Types of requests for different patients and the radiographic prescription indicated.*

	Teeth region on panoramic radiography. Teeth are the main focus of analysis for dentists.
	Region of the jaws and mandible on panoramic radiography. In these regions we will focus the analysis on the maxillary sinuses, their relationship with the dental roots, nasal fossa (septum and lower nasal turbinates) m, in addition to the mandibular body, mandibular canal, mental foramen and lower mandibular cortex, in general, very focused these panoramic images.
	Region of mandibular branches on panoramic radiography. We can also analyze styloid apophysis and possible calcifications of the hyoid style ligament, in addition to the initial third of the cervical spine in many images, mainly of older people.
	Region of the mandibular heads, where in general we can make a comparison between both, and the region of the hyoid bones (double image). Where, just above this region is the bifurcation of the carotid artery where in many situations we can suspect images compatible with atheromas, except for the images of the tritite / thyroid cartilage.

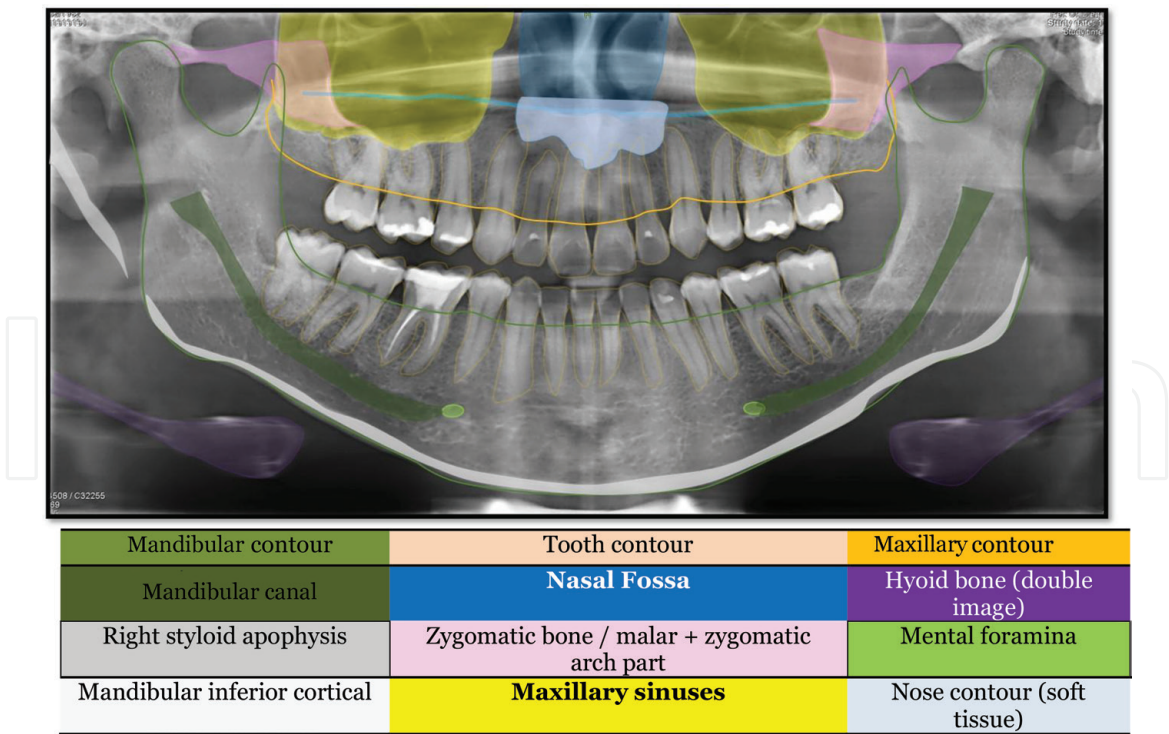
**Table 2.**  
*Panoramic radiography (pan) - ORTHOPANTOMOGRAPHY.*



**Figure 3.**  
*Image of digital panoramic radiography.*

1. A real suspicion, based on a clinical examination, of extensive and / or active pathology outside the alveolar bone.
2. Problems with symptomatic third molars, where the likely treatment will be followed.
3. Evaluation for placement of dental implants





**Figure 4.**  
*Anatomical structures on panoramic radiography.*

4. Trauma involving more than one tooth or suspected of underlying bone damage.
5. Periodontal participation involving a generalized “bag” of more than 5 mm, where the equivalent diagnostic information would require more than 3 intraoral radiographs.
6. Multiple extractions, where equivalent diagnostic information would require more than 3 intraoral radiographs.
7. Evaluation of the growth and development of the maxillomandibular complex for orthodontics/orthopedics and orthognathic surgery.

Below you can see the main regions of the panoramic radiography (**Table 2**), as well as the anatomical structures in **Figure 4**.

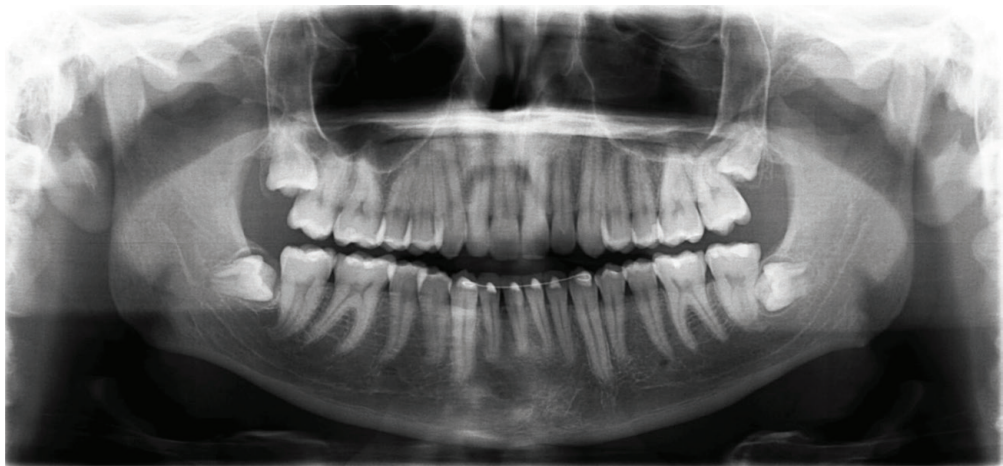## 8. Radiomorphometric indices in osteoporosis

The human skeleton can be divided into axial spine, head on the central axis of the body, and appendicular to the limbs, arms and legs. For medicine, the main structures studied refer to the spine and head of the femur in the hip, and forearm, as these offer the possibility of fractures. We can assume that the maxillomandibular complex is in the head, and thus, it would have characteristics similar to the spine. This really happens, but mainly with the maxilla. The mandible has unique characteristics, even being part of the axial skeleton. Studies show that the decrease in bone mineral density affects the morphometric, densitometric and architectural properties mandible in osteoporotic patients on radiographs, and the main radiographic signs of this condition include a relative generalized radiolucency of the maxilla and mandible or bone rarefaction, decreased thickness of the mandibular

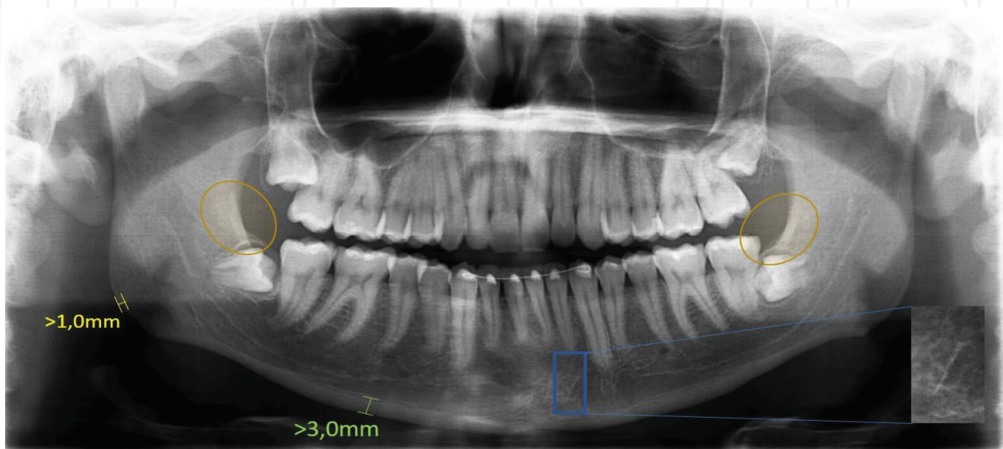
inferior cortex, added to erosions in that same cortex, in addition to generalized accentuation or cortical, maxillary sinus, mandibular canal, nasal fossa, oblique line, among others (**Figures 5–8**) [23].

Several radiomorphometric indices have been proposed to assess the correlation of loss of bone mineral density in the mandible with DXA as the thickness of the mandibular cortex, the mandibular panoramic index, the alveolar crest resorption index, the mandibular cortical index and the fractal dimension of the alveolar/basal bone. These indices represent variations in bone morphology and may be associated with systemic factors [24].

The main measures referring to the radiomorphometric indices relate to the mandible, and as we saw above, in the description of the panoramic radiographic technique, it must always be in the cut layer or cut plane to obtain panoramic radiographs, and so, in general, they are focused. As we have seen, it is also common to produce enlargement of anatomical structures in these panoramic images, and this is provided by the manufacturer of X-ray equipment, on average, but it will hardly vary from structure to structure in different patients. We also know that there are different magnifications between the X-ray equipment, but they all provide the average magnification. Therefore, starting from the

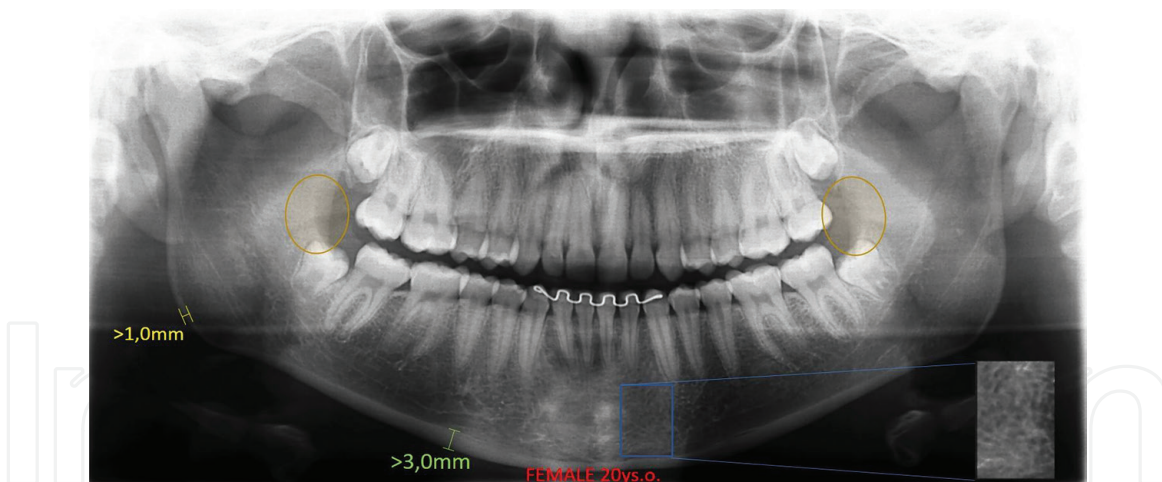


**Figure 5.**  
*Panoramic radiograph of a young adult patient, 21 years old. Note the characteristics of the bony trabeculae, lower cortical mandible (including thickness), region of the retromolar trigone.*

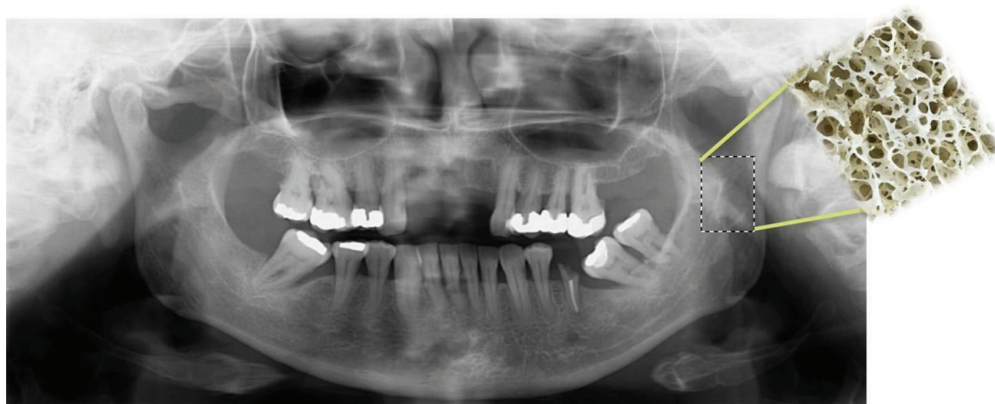


**Figure 6.**  
*Panoramic radiograph of a 21-year-old male adult patient. Note the measurements taken at the mandibular angle (goniac index), still at the mandibular inferior cortex, at the height of the mental foramen (mental index). Look at region of the retromolar trigone, the characteristics of the mandibular bone trabeculae (highlighted), in basal bone.*





**Figure 7.**  
*Panoramic radiograph of a 21-year-old female adult patient. Note the measurements taken at the mandibular angle (goniac index), still at the mandibular inferior cortex, at the height of the mental foramen (mental index), Look at region of the retromolar trigone, the characteristics of the mandibular bone trabeculae (highlighted), in basal bone.*



**Figure 8.**  
*Panoramic radiograph of a young adult male patient, 41 years old. This patient has initial periodontal disease. Note the characteristics of the bone trabeculae in the mandibular ramus (highlighted), a region free of occlusal forces from dental elements.*

premise that we will only analyze images with excellent quality, that is, with the mandible fully contained in the cutting plane of the X-ray equipment, that is, focused, we can rather rely on these measures related to the radiomorphometric indices [25].

The Klemetti index, also called the mandibular cortical index (ICM), was introduced in 1994, based on a sample of postmenopausal women with osteoporosis and it is an index of bone quality morphological evaluation. This qualitative index, classifies the cortical mandibular zone located distal to the mental foramen in three categories: C1 (normal cortex) - when the endosteal margin of the cortex is regular and without defects on both sides; C2 (moderately eroded cortex) - the endosteal margin has semilunar defects or has cortical residues on one or both sides; C3 (severely eroded cortex) - the cortical layer clearly shows the existence of large residues and has a porous aspect [26–27].

Researchers have studied the usefulness of panoramic radiographs in the diagnosis of osteoporosis in the Korean population. In this study, 194 radiographs dated between 2007 and 2010 were analyzed. The authors used three panoramic indexes, the mental index, the mandibular cortical index and a visual estimation index for exam analysis. It is important to note that in this study, each observer was unaware

of the results of each patient's DXA, nor access to their personal information, such as age and sex, as the authors understood that this could influence the final result. After analyzing the data, it is concluded that the three indexes investigated presented themselves as useful tools for the diagnosis of osteoporosis [28–29].

The mandibular cortical thickness index was the most useful as a high-risk exclusion method for a population with low levels of bone mineral density. In turn, the Klemetti index was considered a useful tool, since approximately 80% of people with moderate or severe erosion of the mandibular cortex have osteopenia. However, the risk of bias related to the subjectivity of a qualitative measure such as the Klemetti index needs to be taken into account. Furthermore, the authors suggest that further studies on this topic are needed in order to obtain more accurate and reliable results and conclusions [28].

Another important tool to measure bone quality is the Fractal Dimension, mainly in the evaluation of bone trabeculation, but it is also used in cortical analysis. By Fractal Dimension (FD) it is also possible to assess bone morphometric parameters such as trabecular area or connectivity on panoramic radiographs. Moreover, FD of trabecular bone has been associated with bone strength, according to Camargo et al., 2017 and concluded that FD and MCI offer a significant and relatively high sensitivity, whereas MCW offers a high specificity for screening low BMD. In 2016 these authors, Camargo et al., assessed the correlation between different quality analysis parameters of trabecular pattern in digital panoramic radiographs and relations with forearm bone mass density (BMD) performed by DXA by panoramic radiography. The analysis showed correlations with each other, detecting alterations in the trabecular pattern, significantly, however it cannot be related to BMD with FD. In 2018, Vijayalakshmi et al., studied clinically by estimating and comparing the measurement of trabecular bone pattern in the mandible of normal and osteoporotic volunteers. The authors did not show any significant difference in its architecture between normal and osteoporotic individuals as defined by BMD by periapical radiography. But recommended used these techniques using better-standardized resolution strategies and different estimation methods to gain more insight [30].

Kato CN, et al., 2020 reviewed the use of fractal analysis (FA) in dental images finding 78 articles were found in which FA was applied to panoramic radiographs (34), periapical radiographs (21), bitewing radiographs (4) and concluded that the FD are widely applied to the study of images at dentistry. In this same year, Bulut et al., studied the mandibular indexes and fractal properties on the panoramic radiographs of the patients using aromatase inhibitors (AI) to determine the mandibular cortical and trabecular bone changes in females with breast cancer. Concluded that AI use affects bone quality and evaluating FD and another mandibular index in panoramic radiography and FD can be used to determine the effect of this drug on the jaw bones in the early period [31–32].

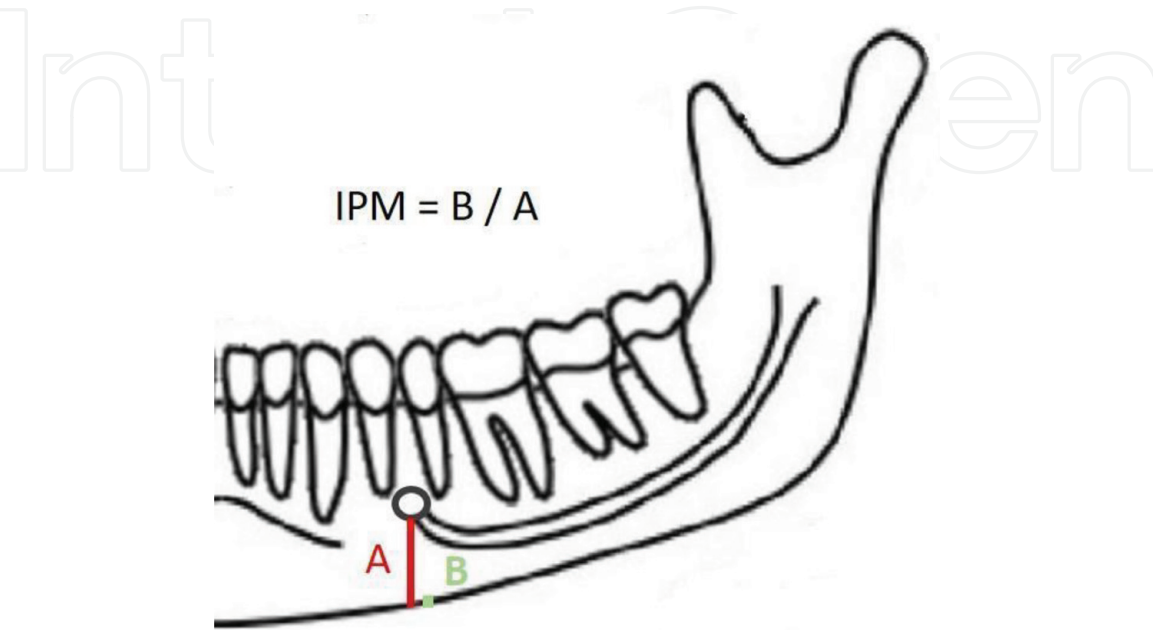
Therefore, it appears that panoramic radiographs can be used as tools to detect low mineral bone density, not for the purpose of diagnosing a certain disease, but rather to identify and properly refer the patient for investigation by bone densitometry, for example, allowing to intercept the progress of the disease.

Despite the vast literature on the subject, there are still radiographic signs that have not been studied, such as the oblique line. It is relatively common to observe on radiographs, an enhancement of the oblique line due to the marked loss of trabecular bone mass in women over 65 years old and toothless, since there is an evident loss of trabecular bone mass in the jaw body and less loss of cortical. Other studies also indicate that the clear highlight of the oblique line and the cervical spine covering plates against the spongy part are signs of osteoporosis. In addition to radiographic signs, other analyzes were not used in osteoporosis, such as the evaluation of inter-trabecular angles to analyze the bone microarchitecture of the mandible [16].



Another important opportunity to study/observe bone sites affected by osteoporosis before as opportunistic dates. This can happen in several and bring, really, important analyzes. Pickhardt et al., 2013 proposed to study To evaluate abdominal computed tomography (CT)-derived bone mineral density (BMD) assessment compared with dual-energy x-ray absorptiometry (DXA) measures for identifying osteoporosis by using CT scans performed for other clinical indications. It was studied 1867 adults undergoing CT and DXA. CT-attenuation values (in Hounsfield units [HU]) of trabecular bone between the T12 and L5 vertebral levels. Thus, the authors were able to conclude that abdominal CT images that include the lumbar spine can be used to identify patients with osteoporosis or normal BMD without additional radiation exposure or cost. Already Buckens et al., 2015 performed opportunistic screening for osteoporosis using computed tomography (CT) examinations that happen to visualize the spine can be used to identify patients with osteoporosis. The authors sought to verify the diagnostic performance of vertebral Hounsfield unit (HU) measurements on routine CT examinations for diagnosing osteoporosis in a separate, external population. This population had CT examination of the chest or abdomen and had also received a dual energy X-ray absorptiometry (DXA) test were retrospectively included. CTs were evaluated for vertebral fractures and vertebral attenuation (density) values were measured. It was possible to verify that simple trabecular vertebral density measurements on routine CT contain diagnostic information related to bone mineral density, but with lower diagnostic accuracy than previously reported. Anyway the authors considered this information might be useful when considering the implementation of opportunistic osteoporosis screening. Also 2015, Barngkgei et al. investigated the use of cone beam computed tomography (CBCT) for predicting osteoporosis based on the cervical vertebrae CBCT-derived radiographic density (RD) using the CBCT-viewer program and concluded that CBCT-derived RD of cervical vertebrae can predict osteoporosis status.

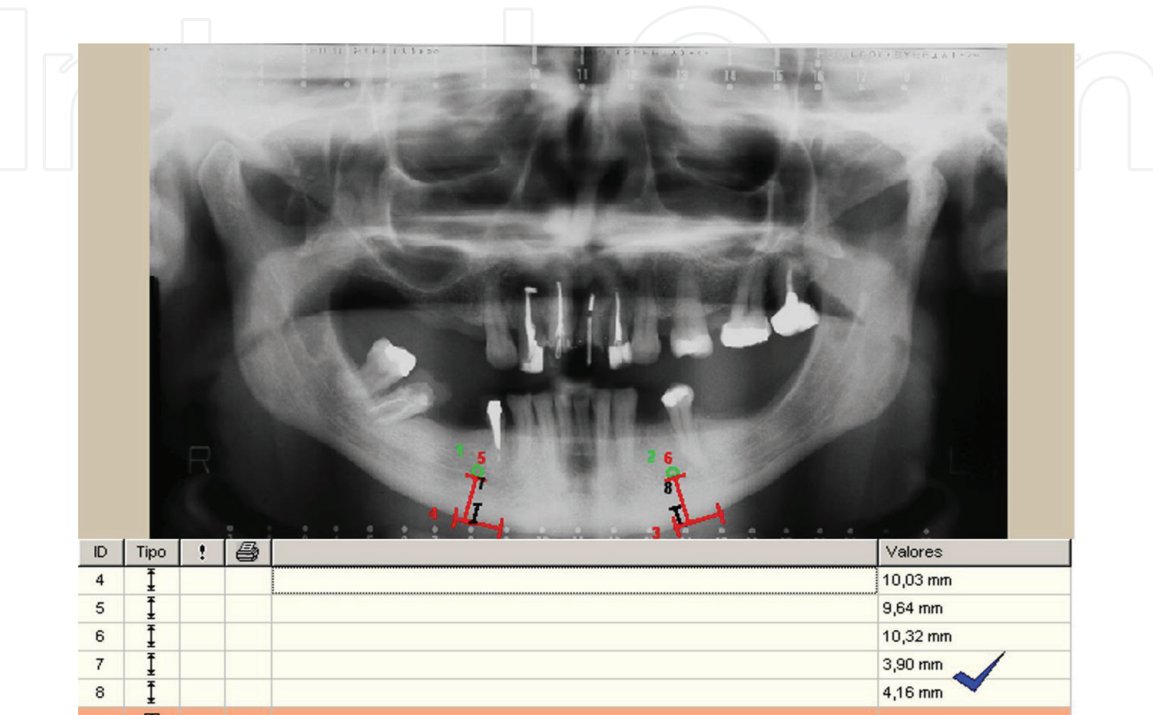
In this line of thought, Cheade et al., 2018 and Cheade et al., 2019, correlated between the bone densities jaws and cervical spine through the HU scale measured in Multislice Computed Tomography (MCT), as opportunistic Screening for Osteoporosis. The authors concluded that there is a positive weak correlation between the cervical vertebrae and buccal sites, but moderate correlation of the



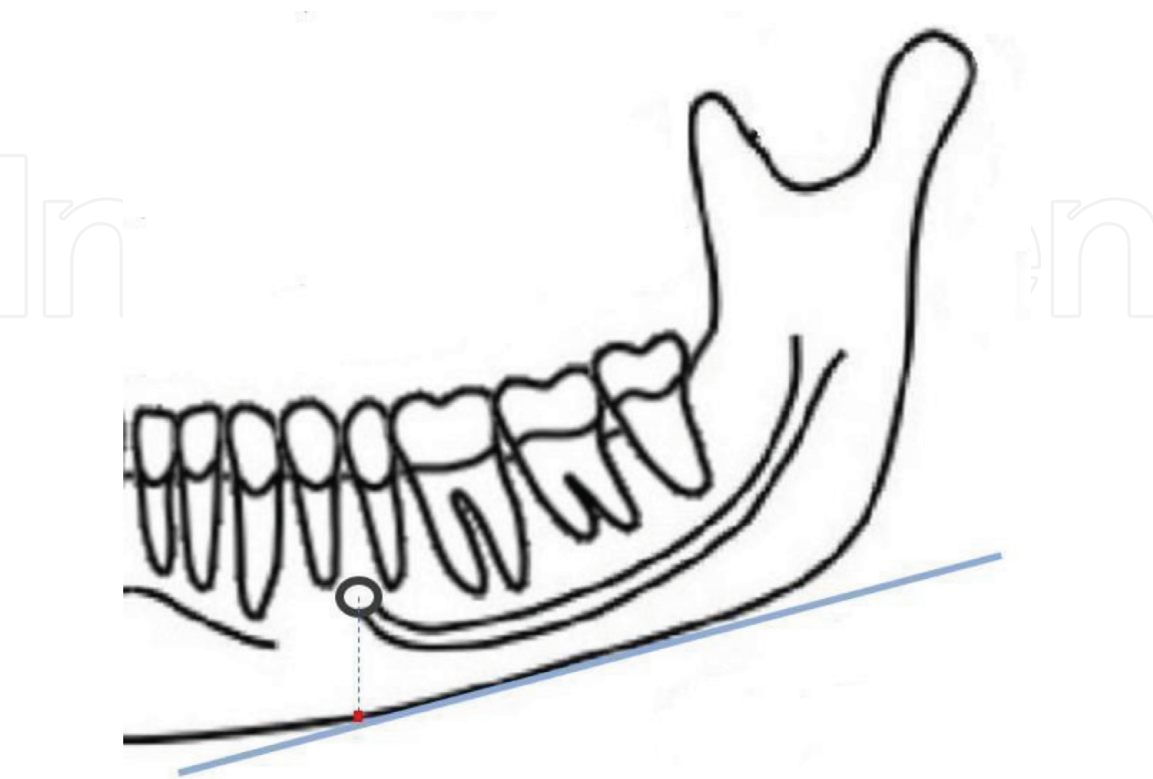
**Figure 9.**  
*Schematic drawing of the mandibular panoramic index.*

cervical vertebrae with the anterior region of the maxilla was funded. Cheade et al., 2019, concluded in this study that as the HU values of the anterior and posterior mandible bone correlate with the HU values of the cervical bone, this test can be applied to osteoporosis screening tools [33–34].

**Mandibular Panoramic Index (IPM):** ratio of the thickness of the mandibular cortex, measured on a line perpendicular to the base of the mandible, at the height of the center of the mental foramen (A), by the distance between the lower limit of



**Figure 10.**  
*Radiographic drawing of the mandibular panoramic index.*



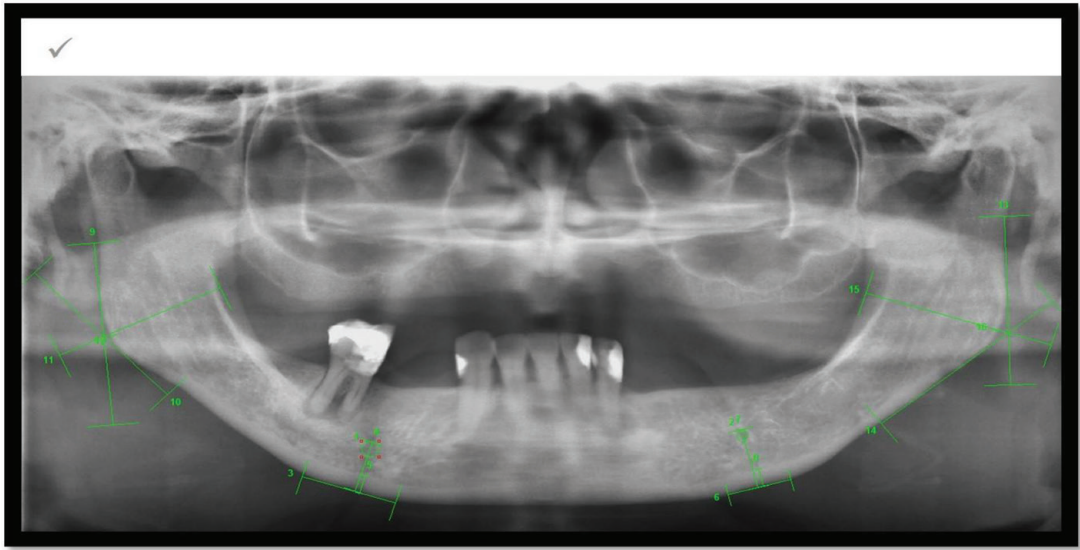
**Figure 11.**  
*Schematic drawing of the mentonian index.*

the mandibular canal and the base of the mandible (B) having as reference value normal IPM greater than or equal to 0.3 (**Figures 9 and 10**) [27].

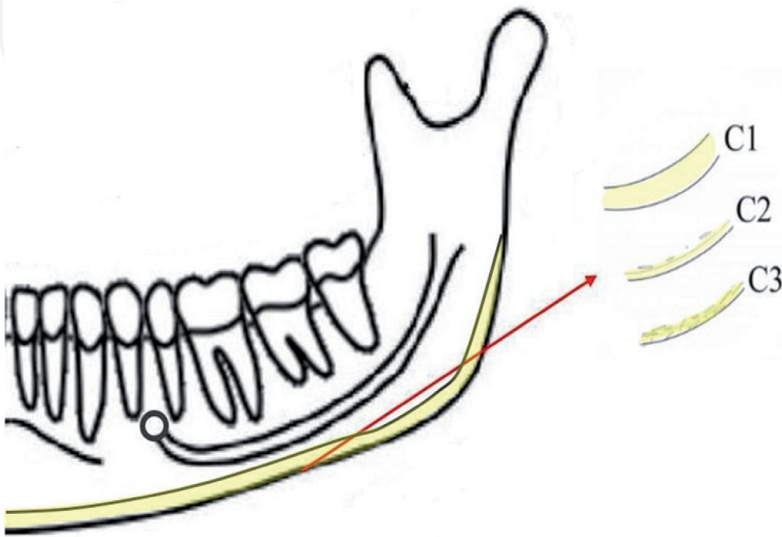
**Mentonian Index (IM):** the thickness of the mandibular cortex, measured on the line perpendicular to the base of the mandible (blue line), at the height of the center of the mental foramen (dashed line) will be considered as having a normal IM reference value greater or equal to 3.1 mm (**Figures 11 and 12**) [35].

**Mandibular Cortical Index (ICM):** the mandibular cortical is evaluated in a qualitative and visual way in three categories C1 (normal cortex) - when the endosteal margin of the cortex is regular and without defects on both sides; C2 (moderately eroded cortex) - the endosteal margin has semilunar defects or has cortical residues on one or both sides; C3 (severely eroded cortex) - the cortical layer clearly shows the existence of large residues and has a porous aspect (**Figure 13**) [36].

**Fractal Dimension (FD):** Digital radiographs are an increasingly popular option in the clinic nowadays. Digitally, such images are composed of pixels with a specific numerical value for each one, two principally methods are of evaluating the pixels



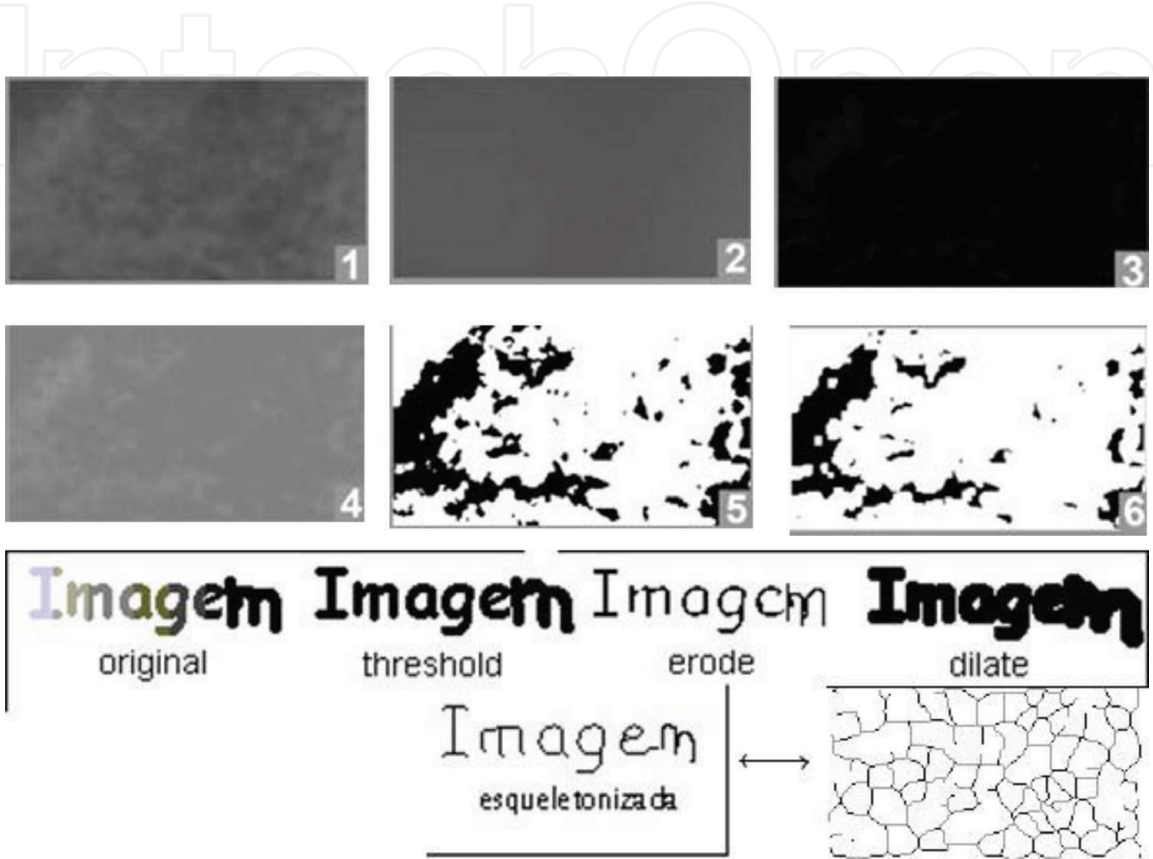
**Figure 12.**  
*Radiographic drawing of the menton index and goniac index measured in mandibular angle.*



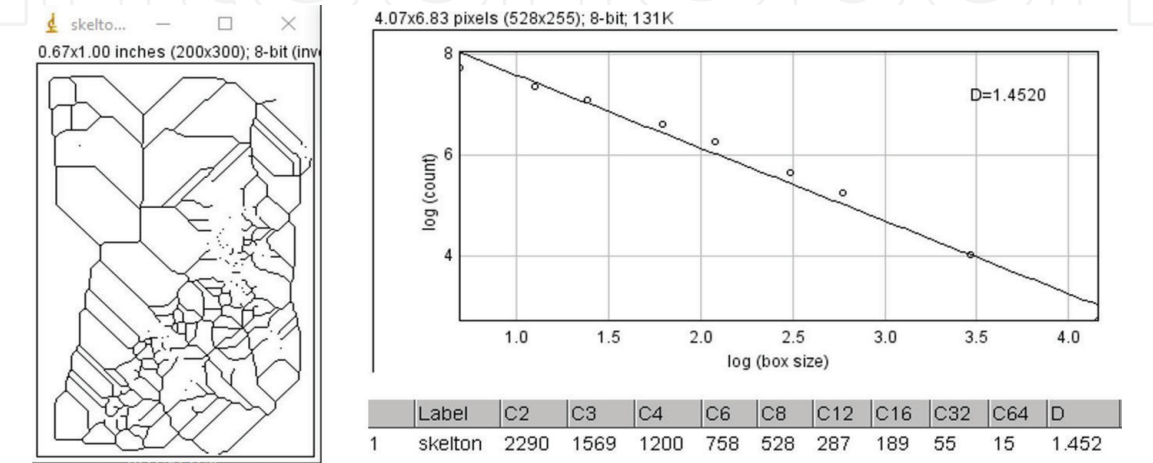
**Figure 13.**  
*Schematic drawing of the mandibular cortical index.*



in these images: Fractal dimension (FD) and Pixel Intensity (PI) analyses. FD is expressed numerically and consists in describing complex shapes and structural patterns in the bone. PI is a grayscale measure, ranging from zero (black) to 256 (white) in a 8-bit digital image (Von Mulhen et al., 1999). Note in **Figure 16**, line A, image 47 has FD = 1.6038, and the% E.T. (percentage of trabecular structures) is equal to 11.28. Now notice line C, image 52, where the FD = 1.3686, and the% E.T. (percentage of trabecular structures) is equal to 5.61. The connectivity of image 47 is 6103.5 and of image 52, only 34.2 (**Figures 14–16**) [37].

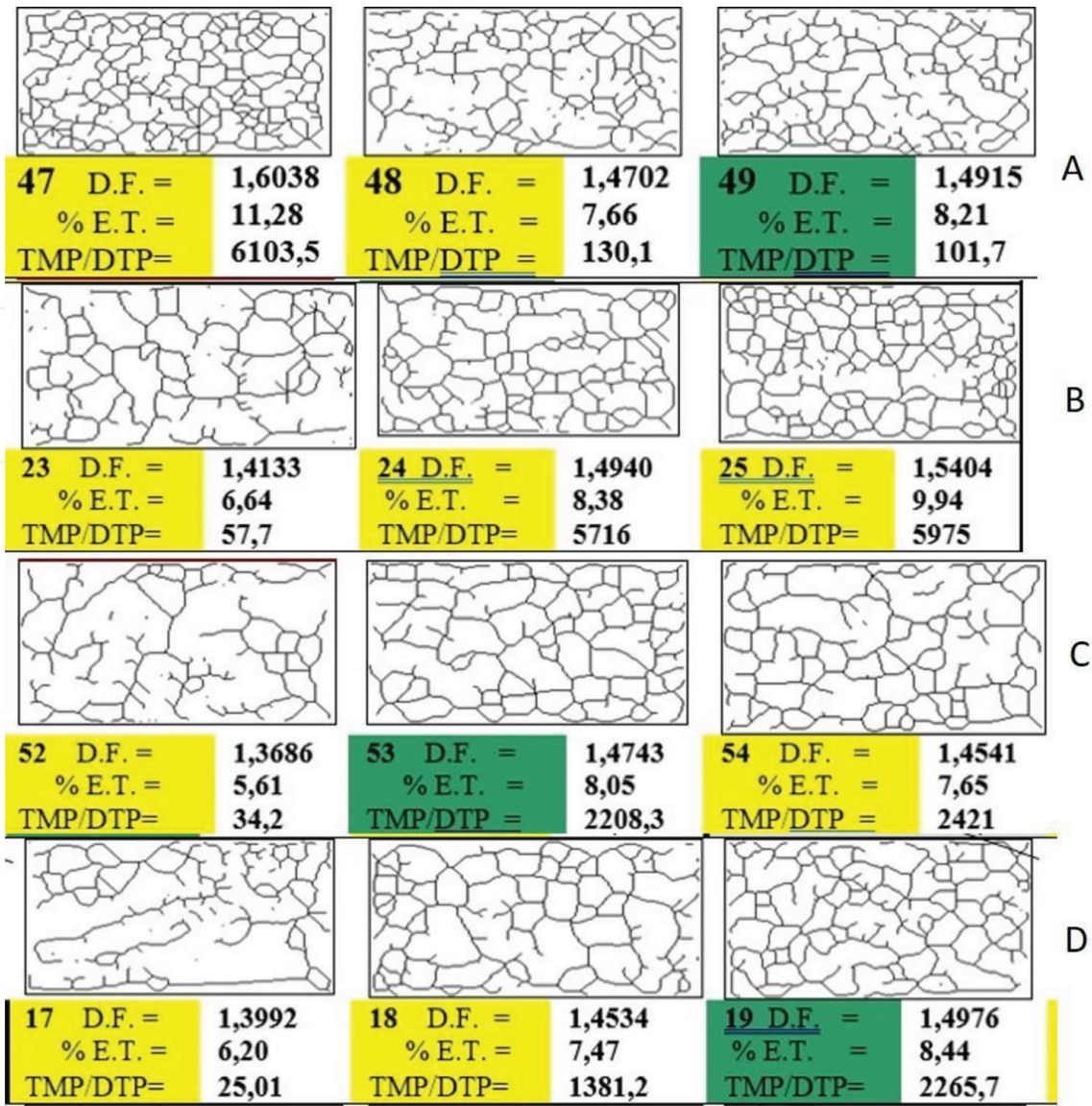


**Figure 14.** Step by step method of the fractal dimension and schematic drawing of the skeletonization process. 1, region of interest of trabecular bone from digitized radiograph of anterior maxilla. 2, highlighted ROI copy of the image in **Figure 7**, with “Gaussian blur” of 33 radius (pixels). 3, Result of subtracting **Image 1**, from **Image 2**. 4, result of adding 128. 5, result of binary transformation (threshold) of the **Image 4**, with 128 brightness value. 6, result of the erode process of the image **Image 5** above.



**Figure 15.** Graphic with the numerical result of the fractal dimension value ( $D = 1.4520$ ) of the skeletonized image sample, seen on the right (ROI seen in **Figure 6**).





**Figure 16.**  
*Samples of skeletonized mandibular regions of interest with the respective fractal dimension values. These regions of interest would be implant sites (ROI similar to the one seen in Figure 6, lying).*

9. Advances in research

In 1991 Benson studied 353 adult individuals between 30 and 79 years of age, equally separated by gender, ethnicity and age, described a measurement index on dental radiography which he called the mandibular index. In 1994, Klemetti compared the diagnostic efficacy of three panoramic indices in relation to bone mineral density in healthy and osteoporotic patients and indicated that panoramic radiography could not be used as a method for diagnosing osteoporosis, but that its indexes could be used to evaluate the disease in the gnathic bones [27].

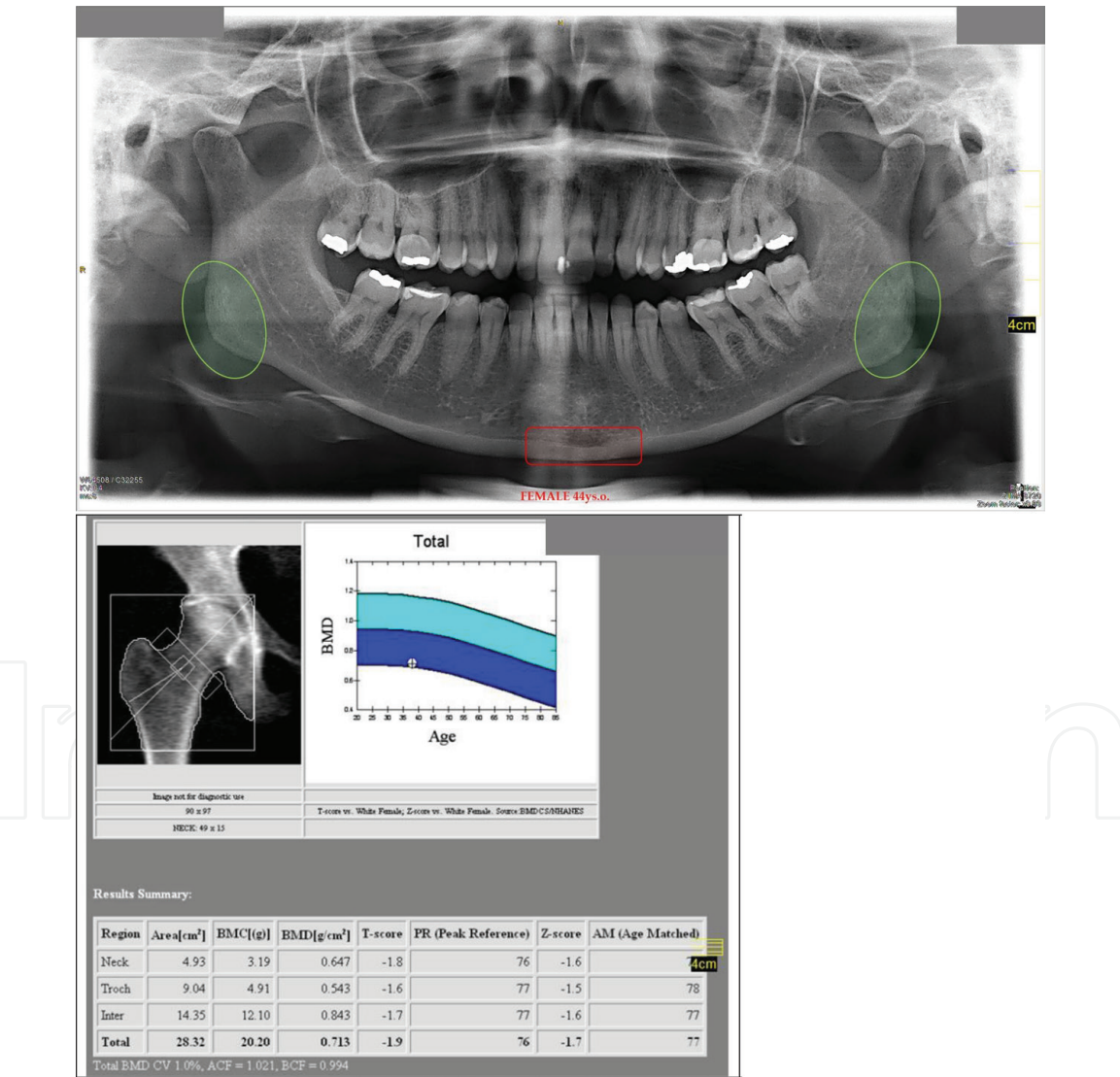
Nakamoto et al., 2003 described the importance of detecting low bone mineral density in postmenopausal women as a way to reduce the incidence of osteoporosis fractures and justified that indices performed on panoramic radiography can be used as a means of detecting these women and tool to refer them for medical evaluation and DXA. As a result, panoramic radiography returns to the scene of science as a way to visualize changes in osteoporosis in the oral cavity and in a systematic way. This information was validated by Taguchi in 2004 and 2005 [38, 39].

In 2006, Yasar carried out a study whose objective was to evaluate the relationship between osteoporosis and the use of radiographic indexes in PAN. In this study,

the introduction of the use of fractal dimension analysis in radiographic images began, however, it was concluded that only measurement of the thickness of the mandibular cortex obtained a statistical difference between the groups of healthy and osteoporotic patients. Later, in 2007, the OSTEODENT project, a collaboration between European research centers for the study of osteoporosis and oral cavity, validated the 2006 findings demonstrating that patients with mandibular cortical thickness less than 3 millimeters were referred for osteoporosis evaluation [40].

In the same year, Taguchi drew the attention of the scientific community to assess the risk of low bone density in the spine of postmenopausal patients who presented oral alterations in osteoporosis. In 2009, Watanabe found a correlation between the elongation of the styloid process and osteoporosis, in addition to also evaluating the radiographic images that indicated calcifications in the blood vessels and the presence of osteoporosis [41].

Continuing his studies, Taguchi in 2010 presented parameters for the evaluation and screening of patients in dental clinic for osteoporosis and again two indexes



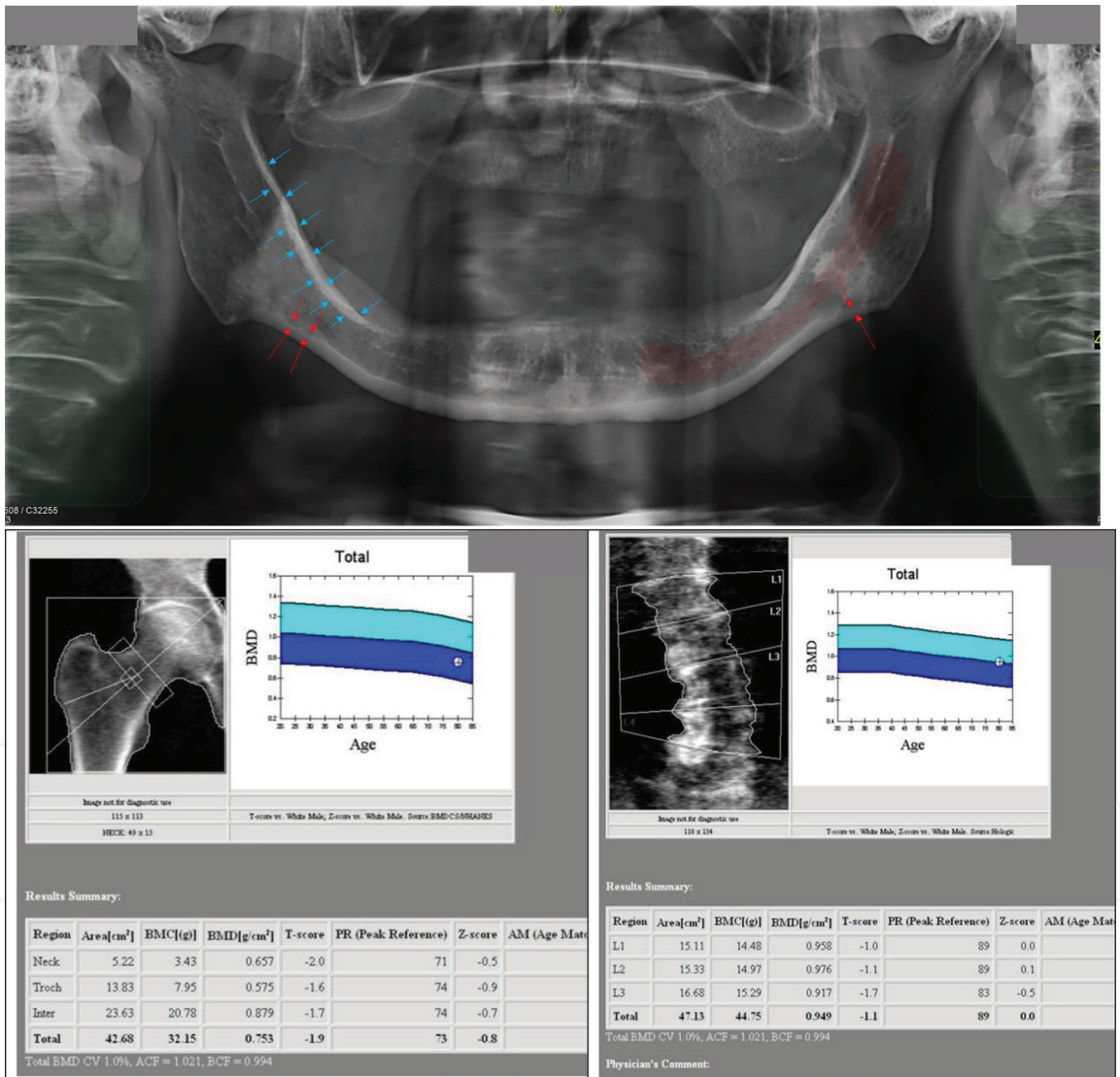
**Figure 17.** Panoramic radiograph with some small bone quality details of a patient with a T-score pointing to OSTEOPENIA on the hip, or the head of the femur. Note the mandibular bone rarefaction. The mandibular inferior cortex is class II, according to Klemetti. Erosion is seen in the anterior region of the mandible, a region disregarded by Klemetti, as this author performed his classification on panoramic analog radiographs, on film, and at a time (1993–1994) when panoramic X-ray equipment had no technical development for better to focus on that region, and they still did not use digital images. The panoramic X-ray equipment had an excellent development since the 21st century, and thus, today we can even consider the anterior mandibular region for these analyzes. We also see that the lower cortex at the angle of the mandible on both sides has excess streaks, showing activity.



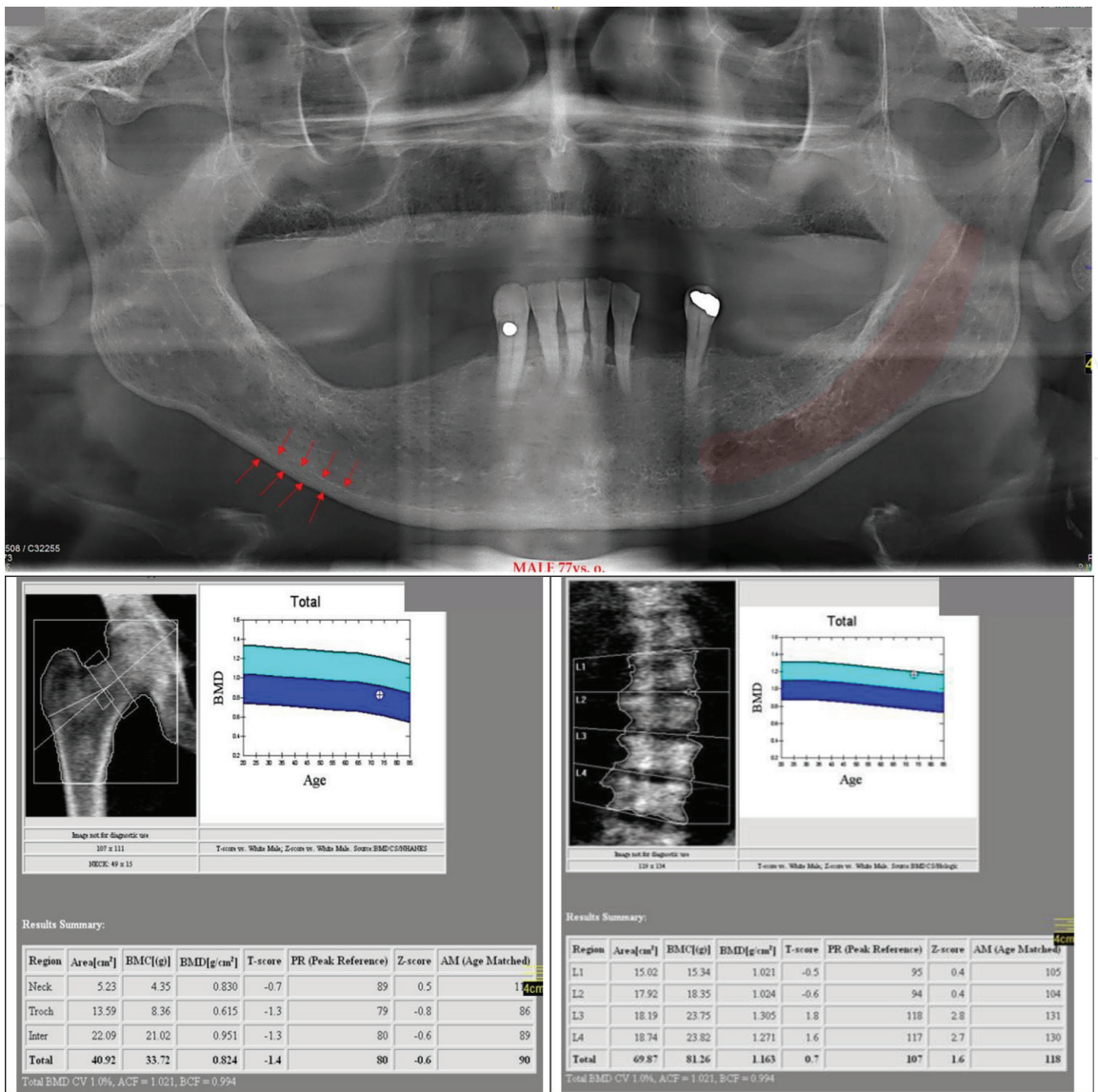
were discarded as predictors of osteoporosis by Leite et al., in the same year, being the indexes of the antegonial and gonial angles (look the **Figure 17**). So, in 2012 Kavitha started studies on digital panoramic radiographs and Devlin in 2013 did not rule out, through a systematic literature review, the use of DXA to the detriment of panoramic radiography [42–44].

Other studies became more popular and the researchers started to evaluate other diseases and conditions through indices in panoramic radiography, such as peri-odontal disease for example (look the reabsorption at **Figures 18** and **19**). In 2017, Munhoz et al., Also investigated the relationship between radiographic indexes, type 2 diabetes mellitus and osteoporosis and since then several studies have sought to define the use of digital tools in oral radiographs for different purposes [45].

Gomes et al., 2014 compared the assessment of mandibular indices on panoramic and cross sectional images using forty-four cone beam computed



**Figure 18.** Panoramic radiography with some small details in bone quality, of an edentulous patient, and with a T-score pointing to OSTEOPENIA in the hip, and in the spine. Note the mandibular bone rarefaction, which is more evident in the sharp contrast of the oblique line, in the region of the retromolar wheat on both sides. The oblique line is a mandibular reinforcement structure, but note its excessive brightness, or its sharp contrast, mainly due to the mandibular bone rarefaction, which causes this brightness to increase. The mandibular inferior cortex is class II, according to Klemetti, and the red arrows point to specific erosions in this structure. Another detail is the loss of the cortical or walls of the mandibular canals on both sides (pointed only on the left side). In addition, it is possible to see the frame aspect of the cervical vertebrae on both sides, indicating the substantial loss of trabecular bone, similar to the rarefaction of the mandibular body. Thus, it is possible to notice in the panoramic radiographic image a generalized cortical enhancement, showing the loss of trabecular structures as a whole.



**Figure 19.** Panoramic radiography with some small details in bone quality, of a partially edentulous patient, with only 6 teeth in the mandible, with a T-score pointing to OSTEOPENIA in the hip, and normality in the spine. The spine, an axial site, as we know, is more trabecular. The femur site would be more cortical. The red arrows point to several erosions in the mandibular inferior cortical on the right side, typically classifying this cortical as Klemetti class II-III. However, the left side cortex is still more preserved. However, we also see that the corticals of the mandibular canal on both sides cannot be delineated or are disappearing. This patient has evident periodontal disease, with widespread alveolar bone crest resorption.

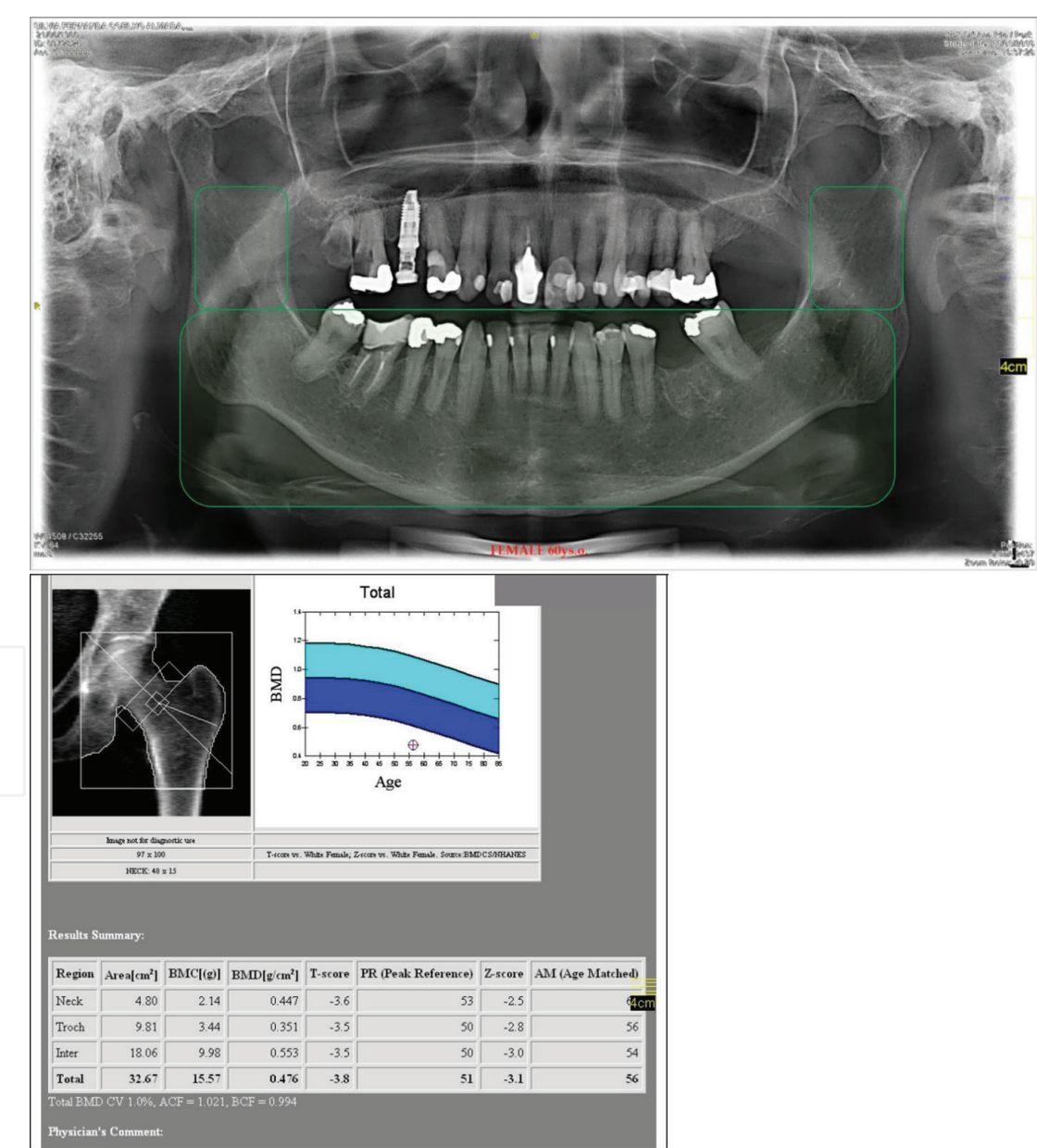
tomography (CBCT) images from postmenopausal female subjects aged more than 45 years without systemic changes. The appearance of the inferior cortex of the mandible was classified according to the mandibular index: C1, the endosteal margin of the cortex was even and sharp; C2, the endosteal margin presented semilunar defects or appeared to form endosteal cortical residues; or C3, the cortical layer formed heavy endosteal cortical residues and was clearly porous [46].

The authors found no statistically significant difference between the exams and concluded that the mandibular index assigned in tomographic images is comparable to that obtained in panoramic images, what was expected, since we were dealing with patients without systemic changes, understand, without an apparent risk of osteoporosis, and we must also consider that the mandibular inferior cortex, as a rule, must be in the focal layer of the panoramic radiographic image, the which favors this analysis of the Klemetti classification (Figure 19). This similar results was found by Cal Alonso, 2016, at panoramic radiography and CBCT panoramic



reconstruction, but the higher values found for the cross-sectional slices certainly would be associated with better accuracy assessment for the CBCT images [47].

Van Dessel et al., also in 2016, study the quantification of bone quality using different cone beam computed tomography devices in comparison to multi-slice computed tomography (MSCT) and micro computed tomography (micro-CT) for objectively assessing cortical bone quality prior to implant placement and trabecular bone, but edentulous human mandibular bone samples (look the **Figures 18** and **19**). This authors found high resolution CBCT offers as a clinical alternative to MSCT to objectively determine the bone quality prior to implant placement. However, not all tested CBCT machines have sufficient resolution to accurately depict the network or cortical bone. Kenawy et al., 2017, conducted a study aimed to assess the effectiveness of radiomorphometric indices based on digital panoramic and cone beam computed tomography (CBCT) images as osteoporosis predictors in healthy and osteoporotic women. These women had dual Energy x-ray absorptiometry (DEXA) exams and they were categorized



**Figure 20.** Panoramic radiography with details on bone quality, of a patient with a T-score pointing to OSTEOPOROSIS on the hip, or femoral head. Note the mandibular bone rarefaction. The mandibular inferior cortex is class II, according to Klemetti. We can also notice the sharp contrast of the oblique line in the retromolar trine on both sides, in addition to the detail of the frame aspect of the cervical vertebrae on the right side.

into either normal or osteopenic/osteoporotic groups. The authors concluded, within the limitation of the yourst study regarding the limited sample size (only 20 patients egyptian females), the bone of the mandible does not appear to reflect the characteristics of the skeleton as a whole [48–49].

About trabecular bone, Barnkggei et al., 2016 studied assessment of jawbone trabecular structure and the dens (the odontoid process of the second cervical vertebra) to test the validity of CBCT among osteoporotic and nonosteoporotic women using CBCT. The authors concluded that the trabecular bone structure of the mandible and maxilla is not affected in osteoporosis as assessed by CBCT. Dens trabecular bone analysis revealed the opposite, so some trabecular bone measures may be assessed by CBCT, which may aid in predicting osteoporosis. These analyzes in CBCT are really difficult to perform, as there are many cuts in each region, which certainly makes it difficult to operate these measures. In the lower cortex of the mandible, this analysis is facilitated due to the small measures involved in the region.

Finally, until the end of 2020, many articles still explored the different indexes and ways of measuring anatomical structures in PAN because it is a wide-ranging examination among the population that is widely used by dentists around the world (**Figures 17–20**).

## 10. Conclusion

Therefore, this chapter sought to show, through more recent knowledge, the interaction between the oral cavity and osteoporosis and thus demonstrate how the imaging exams used in dentistry can be useful to assess the bone structures of the maxilla and mandible in order to recognize in these structures the signs of low bone mineral density and thus be able to contribute to the diagnosis of osteoporosis, a silent systemic disease that affects most elderly people around the world. We believe that this is a worldwide epidemic with high socio-economic costs, high rates of mortality and morbidity, and therefore, health professionals must work together in this task force to fight osteoporosis.

## Conflict of interest

The authors declare no conflict of interest.

IntechOpen

## Author details

Plauto Christopher Aranha Watanabe<sup>1\*</sup>, Giovani Antonio Rodrigues<sup>2</sup>,  
Marcelo Rodrigues Azenha<sup>1</sup>, Michel Campos Ribeiro<sup>3</sup>,  
Enéas de Almeida Souza Filho<sup>3</sup>, Rafael Angelo Soares Vieira<sup>3</sup>  
and Fabio Santos Bottacin<sup>1</sup>

1 Department of Stomatology, Public Oral Healthy and Forensic Dentistry, Ribeirao Preto School of Dentistry, University of São Paulo, Brazil

2 Department of Stomatology, School of Dentistry, University of São Paulo, Brazil

3 North College of Minas/FUNORTE, Montes Claros, MG, Brazil

\*Address all correspondence to: watanabe@forp.usp.br

## IntechOpen

© 2021 The Author(s). Licensee IntechOpen. This chapter is distributed under the terms of the Creative Commons Attribution License (<http://creativecommons.org/licenses/by/3.0>), which permits unrestricted use, distribution, and reproduction in any medium, provided the original work is properly cited. 

## References

- [1] S. C. Radominski *et al.*, “Brazilian guidelines for the diagnosis and treatment of postmenopausal osteoporosis,” *Rev. Bras. Reumatol. (English Ed.)*, vol. 57, no. S 2, pp. 452-466, 2017, doi: 10.1016/j.rbre.2017.07.001.
- [2] C. Cooper and S. Ferrari, “IOF Compendium of Osteoporosis,” *Int. Osteoporos. Found.*, vol. 2nd Editio, pp. 1-76, 2019.
- [3] S. A. L. Corrêa, “Editorial,” *Semin. Cell Dev. Biol.*, vol. 77, pp. 1-2, 2018, doi: 10.1016/j.semcd.2017.10.027.
- [4] L. O. Monteiro, “Doença Osteometabólica : Aspectos de importância para a população Introdução,” pp. 232-243, 2016.
- [5] J. E. Compston, M. R. McClung, and W. D. Leslie, “Osteoporosis,” *Lancet*, vol. 393, no. 10169, pp. 364-376, 2019, doi: 10.1016/S0140-6736(18)32112-3.
- [6] B. Bansal, “Diagnosis of Osteoporosis and Assessment of Fracture Risk,” *ESI Man. Clin. Endocrinol.*, vol. 359, pp. 647-647, 2015, doi: 10.5005/jp/books/12535\_91.
- [7] World Health Organization, “Who Scientific Group on the Assessment of Osteoporosis At Primary Health,” *World Health*, vol. May, no. May 2004, pp. 1-13, 2007, doi: 10.1016/S0140-6736(02)08761-5.
- [8] J. A. Kanis, “Assessment of fracture risk and its application to screening for postmenopausal osteoporosis: synopsis of a WHO report. WHO Study Group,” *Osteoporos. Int. a J. Establ. as result Coop. between Eur. Found. Osteoporos. Natl. Osteoporos. Found. USA*, vol. 4, no. 6, pp. 368-381, Nov. 1994, doi: 10.1007/BF01622200.
- [9] E.-M. Lochmüller, R. Müller, V. Kuhn, C. A. Lill, and F. Eckstein, “Can novel clinical densitometric techniques replace or improve DXA in predicting bone strength in osteoporosis at the hip and other skeletal sites?,” *J. bone Miner. Res. Off. J. Am. Soc. Bone Miner. Res.*, vol. 18, no. 5, pp. 906-912, May 2003, doi: 10.1359/jbmr.2003.18.5.906.
- [10] L. C. Paiva, S. Filardi, A. M. Pinto-Neto, A. Samara, and J. F. Marques Neto, “Impact of degenerative radiographic abnormalities and vertebral fractures on spinal bone density of women with osteoporosis,” *Sao Paulo Med. J.*, vol. 120, no. 1, pp. 9-12, 2002, doi: 10.1590/s1516-31802002000100003.
- [11] S. C. Radominski *et al.*, “Diretrizes brasileiras para o diagnóstico e tratamento da osteoporose em mulheres na pós-menopausa,” *Rev. Bras. Reumatol.*, vol. 57, no. S 2, pp. 452-466, 2017, doi: 10.1016/j.rbr.2017.06.001.
- [12] W. P. Olszynski *et al.*, “Osteoporosis and Treatment in Men : Epidemiology , Prevention ,” *Nutrition*, pp. 15-28, 2004.
- [13] B. C. G. Marinho, L. P. Guerra, J. B. Drummond, B. C. Silva, and M. M. S. Soares, “The burden of osteoporosis in Brazil,” *Arq. Bras. Endocrinol. Metabol.*, vol. 58, no. 5, pp. 434-443, Jul. 2014, doi: 10.1590/0004-2730000003203.
- [14] R. Aziziyeh *et al.*, “The burden of osteoporosis in four Latin American countries: Brazil, Mexico, Colombia, and Argentina,” *J. Med. Econ.*, vol. 22, no. 7, pp. 638-644, Jul. 2019, doi: 10.1080/13696998.2019.1590843.
- [15] M. T. E. Guerra, R. D. Viana, L. Feil, E. T. Feron, J. Maboni, and A. S.-G. Vargas, “One-year mortality of elderly patients with hip fracture surgically treated at a hospital in Southern Brazil,” *Rev. Bras. Ortop. (English Ed.)*, vol. 52, no. 1, pp. 17-23, 2017, doi: 10.1016/j.rboe.2016.11.006.



- [16] P. C. A. Watanabe *et al.*, "Morphodigital study of the mandibular trabecular bone in panoramic radiographs," *Int. J. Morphol.*, vol. 25, no. 4, pp. 875-880, 2007, doi: 10.4067/S0717-95022007000400031.
- [17] T. H. Lin *et al.*, "Association between periodontal disease and osteoporosis by gender," *Med. (United States)*, vol. 94, no. 7, p. e553, 2015, doi: 10.1097/MD.0000000000000553.
- [18] S. Savita, "INTERNATIONAL JOURNAL OF SCIENTIFIC RESEARCH RADIOGRAPHIC COMPARISON OF MANDIBULAR BONE QUALITY IN PATIENTS Periodontology Dr . Benita Maria," no. 1, pp. 27-29, 2019.
- [19] G. Jonasson and M. Rythén, "Alveolar bone loss in osteoporosis: A loaded and cellular affair?," *Clin. Cosmet. Investig. Dent.*, vol. 8, pp. 95-103, 2016, doi: 10.2147/CCIDE.S92774.
- [20] P. F. van der Stelt, "[Panoramic radiographs in dental diagnostics].," *Ned. Tijdschr. Tandheelkd.*, vol. 123, no. 4, pp. 181-187, Apr. 2016, doi: 10.5177/ntvt.2016.04.15208.
- [21] E. Klemetti, S. Kolmakov, and H. Kröger, "Pantomography in assessment of the osteoporosis risk group," *Eur. J. Oral Sci.*, vol. 102, no. 1, pp. 68-72, 1994, doi: 10.1111/j.1600-0722.1994.tb01156.x.
- [22] B. Molander, "Panoramic radiography in dental diagnostics.," *Swed. Dent. J. Suppl.*, vol. 119, pp. 1-26, 1996.
- [23] B. Cakur, S. Dagistan, A. Sahin, A. Harorli, and A. Yilmaz, "Reliability of mandibular cortical index and mandibular bone mineral density in the detection of osteoporotic women.," *Dentomaxillofac. Radiol.*, vol. 38, no. 5, pp. 255-261, Jul. 2009, doi: 10.1259/dmfr/22559806.
- [24] K. Horner and H. Devlin, "The relationships between two indices of mandibular bone quality and bone mineral density measured by dual energy X-ray absorptiometry.," *Dentomaxillofac. Radiol.*, vol. 27, no. 1, pp. 17-21, Jan. 1998, doi: 10.1038/sj.dmfr.4600307.
- [25] A. Taguchi, K. Tanimoto, Y. Suei, and T. Wada, "Tooth loss and mandibular osteopenia.," *Oral Surg. Oral Med. Oral Pathol. Oral Radiol. Endod.*, vol. 79, no. 1, pp. 127-132, Jan. 1995, doi: 10.1016/s1079-2104(05)80088-5.
- [26] A. Taguchi, K. Tanimoto, Y. Suei, K. Otani, and T. Wada, "Oral signs as indicators of possible osteoporosis in elderly women.," *Oral Surg. Oral Med. Oral Pathol. Oral Radiol. Endod.*, vol. 80, no. 5, pp. 612-616, Nov. 1995, doi: 10.1016/s1079-2104(05)80158-1.
- [27] B. W. Benson, T. J. Prihoda, and B. J. Glass, "Variations in adult cortical bone mass as measured by a panoramic mandibular index.," *Oral Surg. Oral Med. Oral Pathol.*, vol. 71, no. 3, pp. 349-356, Mar. 1991, doi: 10.1016/0030-4220(91)90314-3.
- [28] E. Calciolari, N. Donos, J. C. Park, A. Petrie, and N. Mardas, "Panoramic measures for oral bone mass in detecting osteoporosis: a systematic review and meta-analysis.," *J. Dent. Res.*, vol. 94, no. 3 Suppl, pp. 17S-27S, Mar. 2015, doi: 10.1177/0022034514554949.
- [29] O. S. Kim *et al.*, "Digital panoramic radiographs are useful for diagnosis of osteoporosis in Korean postmenopausal women," *Gerodontology*, vol. 33, no. 2, pp. 185-192, 2016, doi: 10.1111/ger.12134.
- [30] T. Alam, I. Alshahrani, K. I. Assiri, S. Almoammar, R. A. Togoo, and M. Luqman, "Evaluation of clinical and radiographic parameters as dental indicators for postmenopausal osteoporosis," *Oral Heal. Prev. Dent.*,

vol. 18, no. 3, pp. 499-504, 2020, doi: 10.3290/j.ohpd.a44688.

[31] C. N. Kato *et al.*, "Use of fractal analysis in dental images: a systematic review," *Dentomaxillofac. Radiol.*, vol. 49, no. 2, p. 20180457, Feb. 2020, doi: 10.1259/dmfr.20180457.

[32] D. G. Bulut, S. Bayrak, U. Uyeturk, and H. Ankarali, "Mandibular indexes and fractal properties on the panoramic radiographs of the patients using aromatase inhibitors," *Br. J. Radiol.*, vol. 91, no. 1091, 2018, doi: 10.1259/bjr.20180442.

[33] M. D. C. C. Cheade, L. Munhoz, E. S. Arita, and P. C. A. Watanabe, "Opportunistic screening for osteoporosis correlating the bone densities of jaws with multislice computed tomography for cervical vertebrae," *Clin. Lab. Res. Dent.*, no. June, pp. 1-6, 2019, doi: 10.11606/issn.2357-8041.clrd.2019.155263.

[34] M. De Cassia, C. Cheade, A. G. Lourenço, P. Christopher, and A. Watanabe, "Correlation between the Bone Densities Jaws and Cervical Spine through the HU Scale Measured in Multislice Computed Tomography : Opportunistic Screening for Osteoporosis," vol. 2, no. 2, pp. 12-21, 2019.

[35] D. Ledgerton, K. Horner, H. Devlin, and H. Worthington, "Panoramic mandibular index as a radiomorphometric tool: An assessment of precision," *Dentomaxillofacial Radiol.*, vol. 26, no. 2, pp. 95-100, 1997, doi: 10.1038/sj.dmfr.4600215.

[36] E. Klemetti, P. Vainio, V. Lassila, and E. Alhava, "Cortical bone mineral density in the mandible and osteoporosis status in postmenopausal women," *Eur. J. Oral Sci.*, vol. 101, no. 4, pp. 219-223, 1993, doi: 10.1111/j.1600-0722.1993.tb01108.x.

[37] T. E. Southard, K. A. Southard, J. R. Jakobsen, S. L. Hillis, and C. A. Najim, "Fractal dimension in radiographic analysis of alveolar process bone.," *Oral Surg. Oral Med. Oral Pathol. Oral Radiol. Endod.*, vol. 82, no. 5, pp. 569-576, Nov. 1996, doi: 10.1016/s1079-2104(96)80205-8.

[38] T. Nakamoto *et al.*, "Dental panoramic radiograph as a tool to detect postmenopausal women with low bone mineral density: Untrained general dental practitioners' diagnostic performance," *Osteoporos. Int.*, vol. 14, no. 8, pp. 659-664, 2003, doi: 10.1007/s00198-003-1419-y.

[39] S. C. White *et al.*, "Clinical and panoramic predictors of femur bone mineral density," *Osteoporos. Int. a J. Establ. as result Coop. between Eur. Found. Osteoporos. Natl. Osteoporos. Found. USA*, vol. 16, no. 3, pp. 339-346, Mar. 2005, doi: 10.1007/s00198-004-1692-4.

[40] F. Yaşar and F. Akgünlü, "The differences in panoramic mandibular indices and fractal dimension between patients with and without spinal osteoporosis," *Dentomaxillofacial Radiol.*, vol. 35, no. 1, pp. 1-9, 2006, doi: 10.1259/dmfr/97652136.

[41] P. C. A. Watanabe, F. C. Dias, J. P. M. Issa, S. A. C. Monteiro, F. J. A. De Paula, and R. Tiossi, "Elongated styloid process and atheroma in panoramic radiography and its relationship with systemic osteoporosis and osteopenia," *Osteoporos. Int.*, vol. 21, no. 5, pp. 831-836, 2010, doi: 10.1007/s00198-009-1022-y.

[42] A. Taguchi, "Triage screening for osteoporosis in dental clinics using panoramic radiographs," *Oral Dis.*, vol. 16, no. 4, pp. 316-327, 2010, doi: 10.1111/j.1601-0825.2009.01615.x.

[43] A. F. Leite, P. T. de S. Figueiredo, C. M. Guia, N. S. Melo, and A. P. de Paula,

- “Correlations between seven panoramic radiomorphometric indices and bone mineral density in postmenopausal women,” *Oral Surgery, Oral Med. Oral Pathol. Oral Radiol. Endodontology*, vol. 109, no. 3, pp. 449-456, 2010, doi: 10.1016/j.tripleo.2009.02.028.
- [44] H. Devlin and C. Whelton, “Can mandibular bone resorption predict hip fracture in elderly women? A systematic review of diagnostic test accuracy,” *Gerodontology*, vol. 32, no. 3, pp. 163-168, 2015, doi: 10.1111/ger.12077.
- [45] L. Munhoz, A. R. G. Cortes, and E. S. Arita, “Assessment of osteoporotic alterations in type 2 diabetes: A retrospective study,” *Dentomaxillofacial Radiol.*, vol. 46, no. 6, pp. 1-5, 2017, doi: 10.1259/dmfr.20160414.
- [46] C. C. Gomes, G. L. De Rezende Barbosa, R. P. Bello, F. N. Bóscolo, and S. M. De Almeida, “A comparison of the mandibular index on panoramic and cross-sectional images from CBCT exams from osteoporosis risk group,” *Osteoporos. Int.*, vol. 25, no. 7, pp. 1885-1890, 2014, doi: 10.1007/s00198-014-2696-3.
- [47] M. B. C. C. Alonso, T. V. Vasconcelos, L. J. Lopes, P. C. A. Watanabe, and D. Q. Freitas, “Validation of cone-beam computed tomography as a predictor of osteoporosis using the Klemetti classification,” *Braz. Oral Res.*, vol. 30, no. 1, May 2016, doi: 10.1590/1807-3107BOR-2016.vol30.0073.
- [48] A. J. Camargo, A. R. G. Cortes, E. M. Aoki, M. G. Baladi, E. S. Arita, and P. C. A. Watanabe, “Diagnostic performance of fractal dimension and radiomorphometric indices from digital panoramic radiographs for screening low bone mineral density,” *Brazilian J. Oral Sci.*, vol. 15, no. 2, pp. 131-136, 2016, doi: 10.20396/bjos.v15i2.8648764.
- [49] C. W. Jeong, K. H. Kim, H. W. Jang, H. S. Kim, and J. K. Huh, “The relationship between oral tori and bite force,” *Cranio - J. Craniomandib. Pract.*, vol. 37, no. 4, pp. 246-253, 2019, doi: 10.1080/08869634.2017.1418617.