

We are IntechOpen, the world's leading publisher of Open Access books Built by scientists, for scientists

6,900

Open access books available

186,000

International authors and editors

200M

Downloads

Our authors are among the

154

Countries delivered to

TOP 1%

most cited scientists

12.2%

Contributors from top 500 universities



WEB OF SCIENCE™

Selection of our books indexed in the Book Citation Index
in Web of Science™ Core Collection (BKCI)

Interested in publishing with us?
Contact book.department@intechopen.com

Numbers displayed above are based on latest data collected.
For more information visit www.intechopen.com



Continuous Curvilinear Capsulorhexis

Liu Qian

Abstract

Continuous curvilinear capsulorhexis (CCC) is an important step in of modern phacoemulsification, which has crucial influence on the surgical process and prognosis. In this chapter, we mainly discuss following aspects: Preoperative preparation, Effects of incision on capsulorhexis, Capsulorhexis, Special cases of capsulorhexis and Capsulorhexis assisted by femtosecond laser. The problem need to pay attention and the solution way in above aspects will be elaborated.

Keywords: continuous, circular, centered, capsulorhexis, cataract

1. Introduction

Thomas Neuhann and Howard Gimbel, considered as pioneers in the development of the centered continuous curvilinear capsulorhexis (CCC) technique, first published their paper on the technique in 1990 [1]. The use of CCC technique makes the rim of the anterior capsule (AC) much stronger and decreases the risk of tearing, thus providing a solid foundation for applying the “chip and flip,” “divide and conquer,” “phaco chop,” and “phaco pre-chop” techniques. What is more, the IOL could be more correctly positioned and stability with the centered continuous curvilinear anterior opening [2–5]. In terms of improving the prognosis, CCC technique could supply a continuous opening with more smooth edges [6]. The morphology of anterior capsule affect position of lens and refractive outcome greatly [7]. CCC helps maintain the intraocular lens (IOL) in the correct position and overlaped by anterior capsule as showed in **Figure 1** which providing a more predictable effective lens position (ELP) [6]. In addition, The CCC technique could reduce the incidence of posterior capsular opacification (PCO) [8–10]. With the current widespread-use of multi-focus intraocular lenses and astigmatism-correcting intraocular lenses, Cataract surgery has entered the refractive age. Centered CCC(CCCC) play a crucial role in obtaining good postoperative visual quality. Tilt and decentration of the IOL can decrease visual acuity which could result in astigmatism [11, 12]. Okada et al. [13] confirmed that decentration of optic center by 0.4 mm could produce 0.25D change in spherical equivalent.

In this chapter, we will elaborate on several aspects include: preoperative preparation; the effects of incision on capsulorhexis. The two parts above mainly discuss the tools, head position of patient, exposure of surgical field of vision, red reflex of microscope, hand position of surgeon and importance of incision. Then capsulorhexis technique and special cases of capsulorhexis will be interpreted. In the end, we will introduce the advantage of femtosecond laser system in capsulorhexis and precautions.

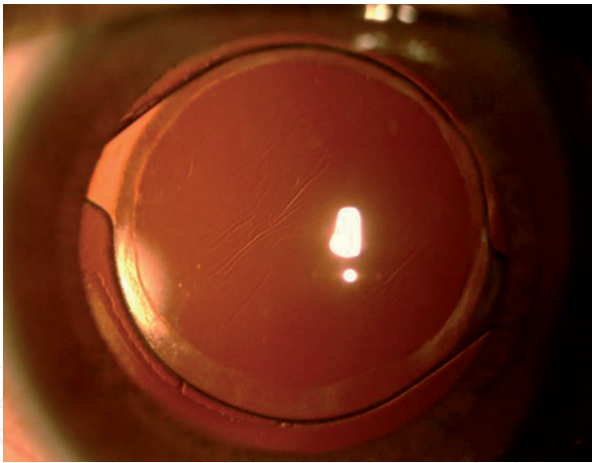


Figure 1.
Color photo of patient 3 months after CCCC. The margin of optic region was overlapped by anterior capsule full-circlely.

2. Preoperative preparation

2.1 Tools for CCC

Initially, a type of irrigating cystotome (designed by Charles Kelman) and a needle were employed in CCC. The first forceps, specifically used to conduct capsulorhexis, were designed by Peter Utrata in 1988, and are still used today.

Forceps were designed in different lengths, with columnar and flat handle (**Figure 2**) and the tips were curved and flat (**Figure 3**). Compared with columnar handle, the flat handle is easier for thumb and index finger to hold and middle finger to support and relatively more lighter. After the viscoelastic agent was injected into the front chamber, the anterior capsule is flattened. The flat tip has more room to move around in the anterior chamber. The curved tip generate height difference in the anterior chamber. Limited by the incision, the movement of curved tip is restricted. The choice of length, depends on the habit and hand size of the operator and the last choice of columnar and flat handle or curved and flat tip depends on the habit too.

Aim to reduce the incidence of infection after operation especially to decrease surgically induced astigmatism and the influence on corneal optical performance in refractive cataract surgery, corneal incision size was reduced from over 3 mm to less

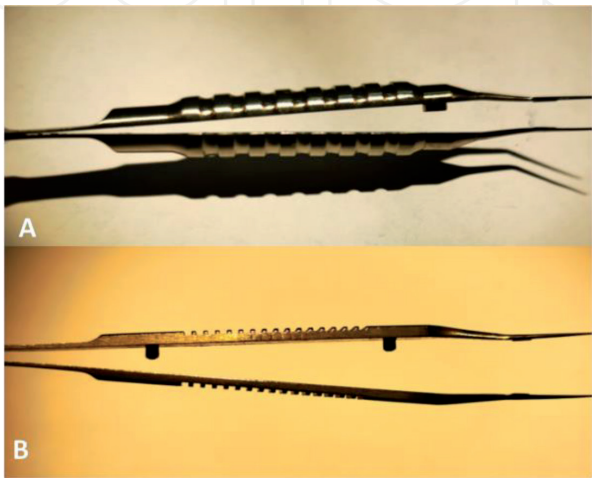


Figure 2.
Different designs of forceps handle. A is columnar and B is flat.

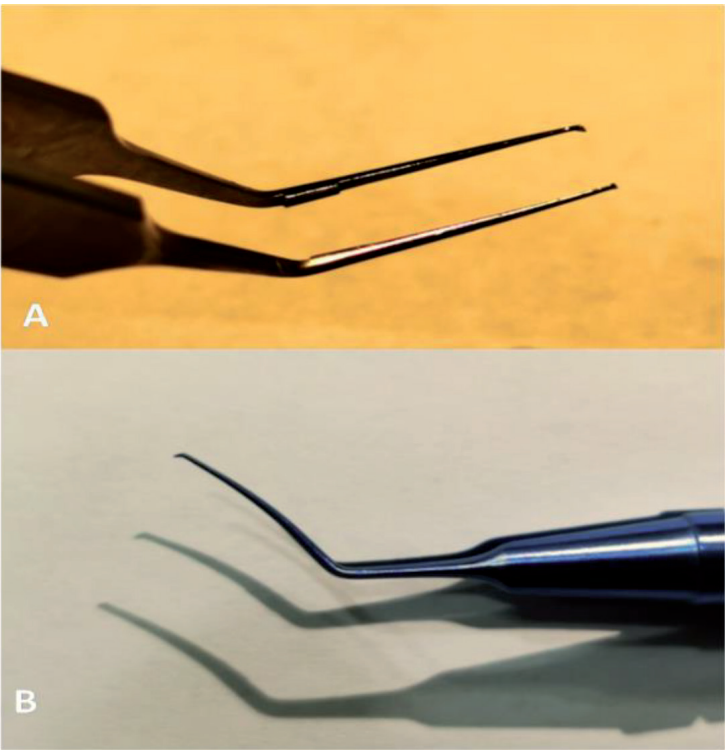


Figure 3.
Different designs of forceps tip. A is flat and B is curved.

than 2 mm [14–19]. The related equipment is also required to be further improved. Smaller incisions limit the movement of traditional capsular forceps. Calladine-Inamura Capsulorhexis Forceps increases the opening and closing range of the tip in the anterior chamber by the hinge design on the forearm as showed in **Figure 4** to complete capsulorhexis through small incision. Ikeda MICS Capsulorhexis Forceps is tube designed with small diameter as 0.7 mm (showed in **Figure 5**) could enter anterior chamber for capsulorhexis through small paracentesis.

Scales of 5 mm and 2.5 mm are marked on some of the flat-tipped forceps, as shown in **Figure 6**, which can be useful as a measurement reference for the operator.

2.2 Patient’s head position

The position of the head is vital to ensure the centrality of the AC opening. The patient’s head should be kept horizontal for the lens plane to remain horizontal

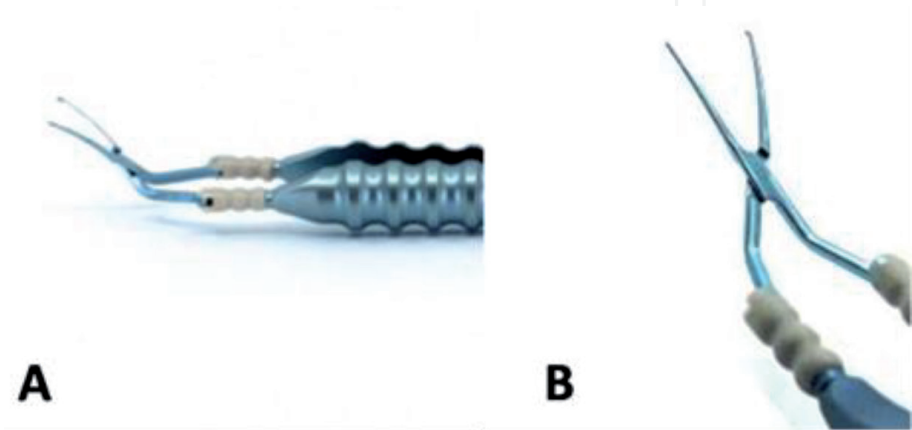


Figure 4.
Calladine-Inamura Capsulorhexis forceps. Hinge design on the forearm in a and the detail in B.

(**Figure 7**). The AC opening could be decentered downwards if the jaw is too elevated (**Figure 8**), or upwards if the forehead is too elevated (**Figure 9**).

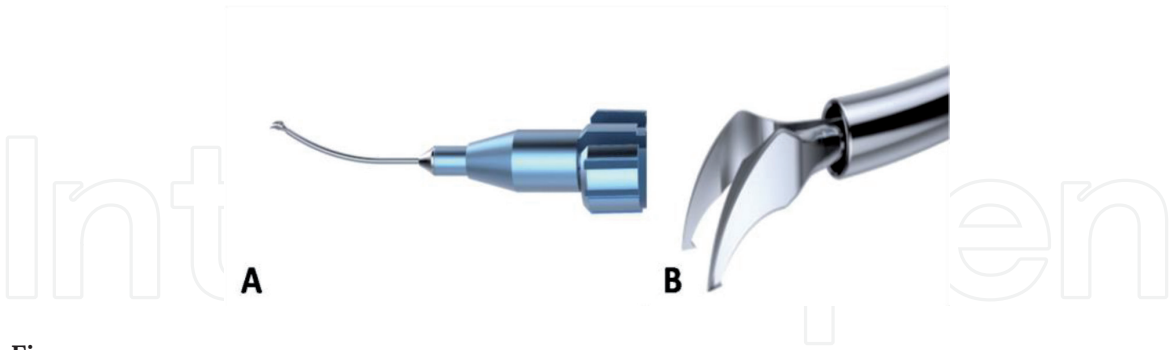


Figure 5.
Ikedo MICS Capsulorhexis forceps. Tube design without joint in A and the detail of tip in B.




Figure 6.
The scale is marked on the tip of forceps as scratches. The distal one is 2.5 mm, the proximal is 5 mm.

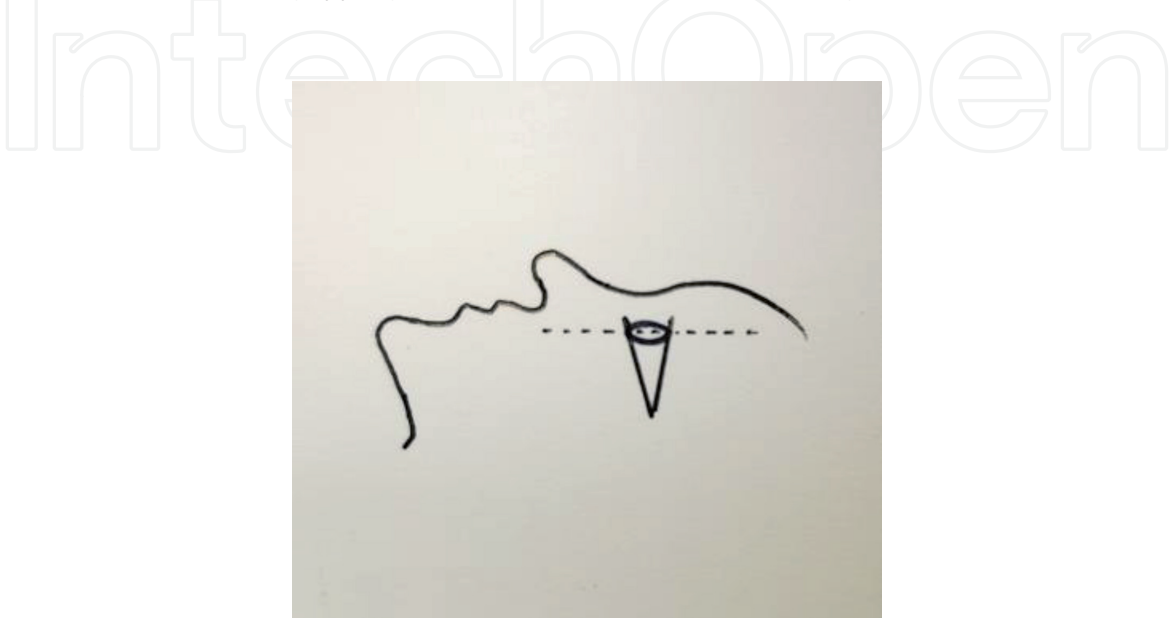


Figure 7.
The plane of the lens should be kept level by adjusting the position of head before operation.

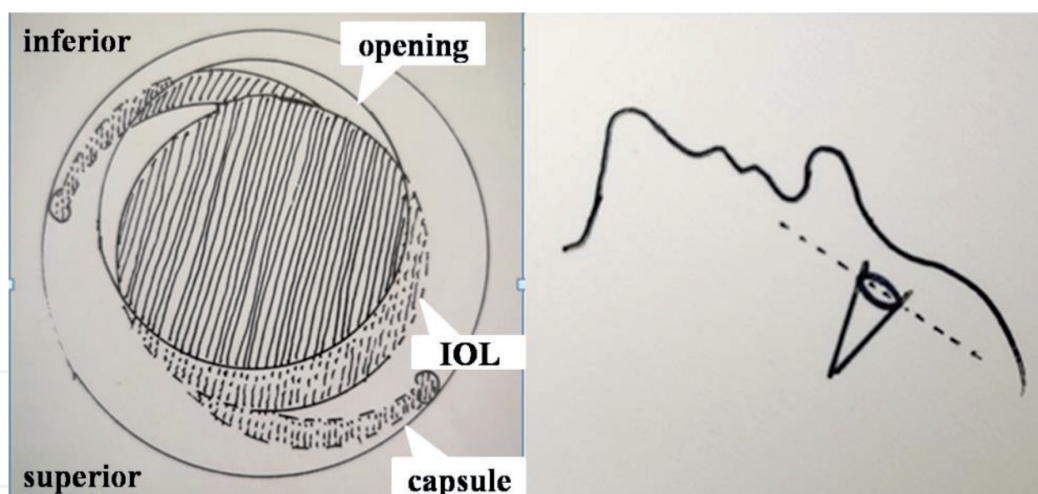


Figure 8.
The AC opening would be decentered towards inferior if the jaw is too elevated.

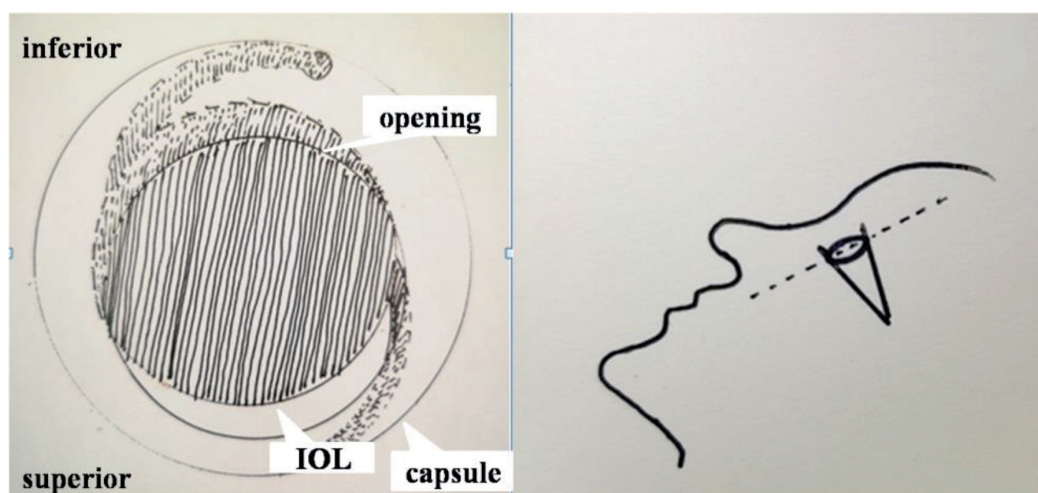


Figure 9.
The AC opening would be decentered towards superior if the forehead is too elevated.

2.3 Surgical field of vision

The pupils must be fully dilated to expose the surgical field. One drop of 0.5% tropicamide is instilled every 15 min (four times), to maintain the diameter of the pupil greater than 6.0 mm.

The rare cases in which cataracts are complicated with uveitis, the pupil cannot be dilated adequately because the iris is atrophic and inelastic. In such cases, the pupil can be stretched by two choppers, as shown in **Figure 10**, which is known as the pupil-stretch technique. Moreover, alternative devices and techniques are available. For example the iris can be fixed by iris hooks through a series of side-incisions to dilate the pupil (**Figure 11**), and the use of the Malyugin ring can reduce the number of side incisions required (**Figure 12**). There are also many other pupil expansion devices, such as Hydro view Iris Protector Ring, B-HEX Pupil Expander, I-Ring pupil expander etc., can be used in clinic.

However, the use of instruments or pupil-stretch technique can lead to tears of the iris muscle fiber, resulting in pupil malformation and even the risk of hemorrhage as show in **Figure 10** (red arrow). In such cases, coreoplasty can be performed using Vannas capsulotomy scissors, as shown in **Figure 13**.

Moreover, when the pupillary area of chronic uveitis is adhered to the AC by an exudative membrane, capsulorhexis forceps could be used to dilacerate the

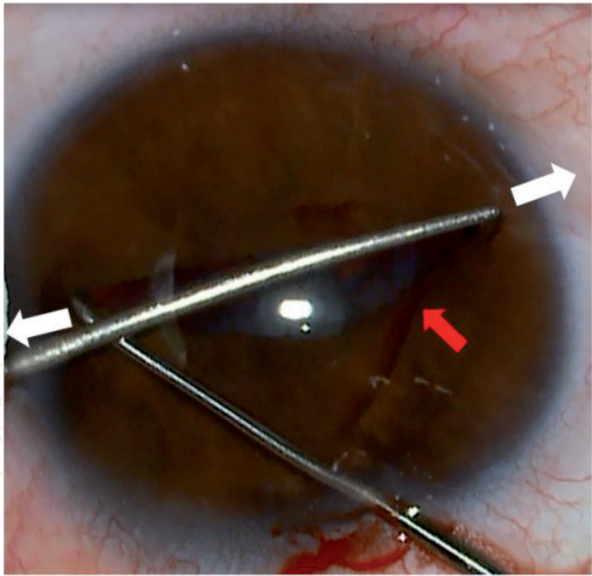


Figure 10.
To stretch the pupil in the opposite direction (white arrow) with two chopping hook. The relevant side-effect are hemorrhage (red arrow) and transformation of pupil after operation.




Figure 11.
Iris hooks to fix the iris through side incision which is composed of a hook (red arrow) and gasket (white arrow).

membrane (**Figure 14**). After both these procedures, the pupils can be dilated injection of a viscoelastic agent.

2.4 Red reflex during surgery

The red reflex test, which is performed using a microscope, is very important at each step of cataract surgery. It allows the surgeon to clearly see the capsulorhexis path by illuminating the AC (white arrow in **Figure 15**), and visualization of the path can be enhanced by adjusting the ratio of coaxial to paraxial light on the microscope (**Figure 16**).

In cases of mature or hyper mature cataracts, the light reflects off the posterior segment, generating a retro-illumination of the AC, which is insufficient for correctly performing capsulorhexis. In such cases, Trypan blue dye could be used to stain the AC.

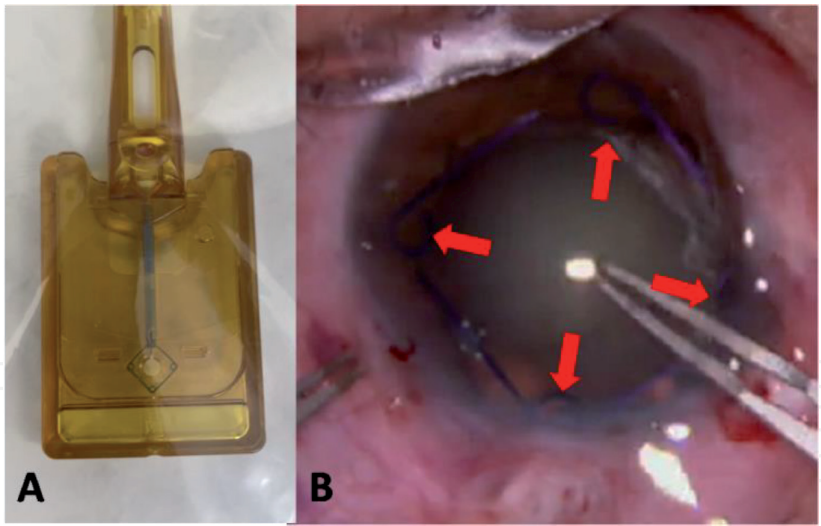


Figure 12.
Malyugin ring after disinfection and sealing is showed in A. Malyugin ring stretch the pupil during operation as showed in B (red arrow).

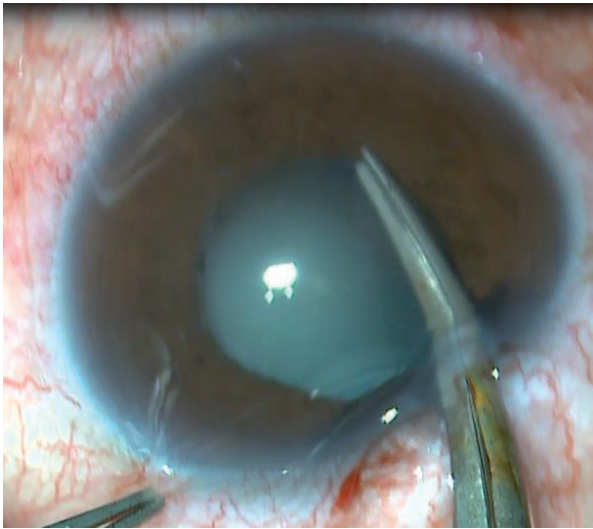


Figure 13.
Coreoplastyis applied by capsulotomy Vannas scissors to amplify the vision field.

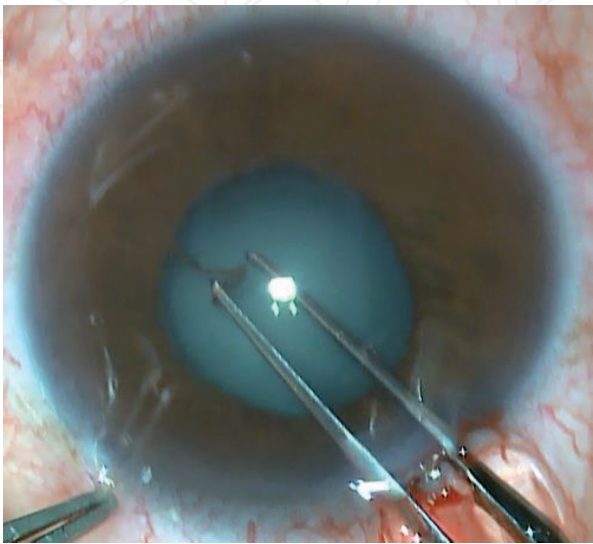


Figure 14.
Capsulorhexis forceps is used to tear the membranes to remove its restriction on the pupil.

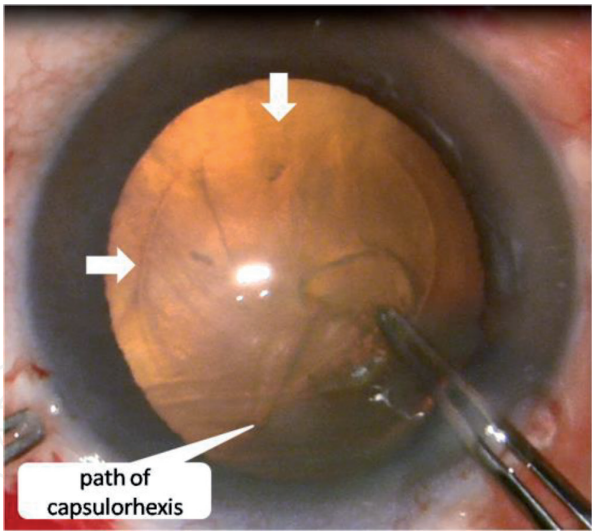


Figure 15.
Capsulorhexis path is clear with good red reflex (white arrow).

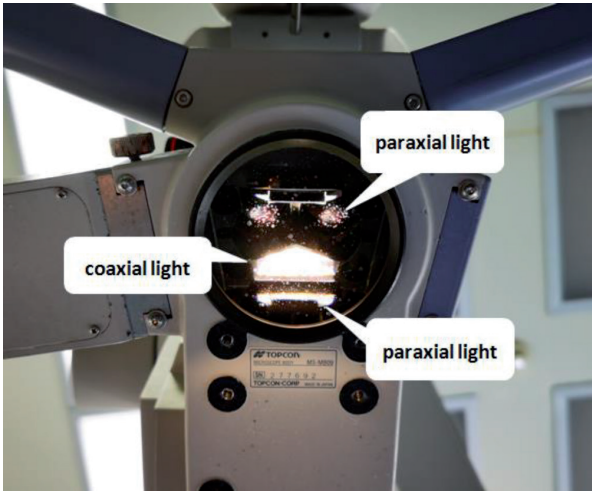


Figure 16.
Coaxial light and paraxial lights on the operation microscope.

2.5 Hand position

To avoid wrist dangling, the surgeon's hands or wrists should rest steadily against the patient's forehead. This will allow the surgeon's hands to move synchronously with the patient's head if the they move head abruptly. The angle at which the hands placed varies according to the practitioner's habits.

3. Effects of incision on capsulorhexis

An ideal surgical incision is the fundamental prerequisite for successful capsulorhexis. In Europe and America, a temporal incision is preferred, while in Asia it is mostly performed at an 11 o' clock position. Regardless of the orientation, when the incision is made, the direction of the tunnel knife should be along the meridian of the cornea, as shown in **Figure 17**.

A meridional incision does not limit the movement of capsular forceps, which ensures that the anterior opening is centered and perfectly round. When the incision deviates from the meridian, the boundaries of the inner incision will limit the track for the capsulorhexis forceps as shown in **Figure 18**.

In addition, if the incision is too close to the center of the cornea, the range will be affected, leading to a small and off-center capsulorhexis, as shown by the red arrows in **Figure 19**.

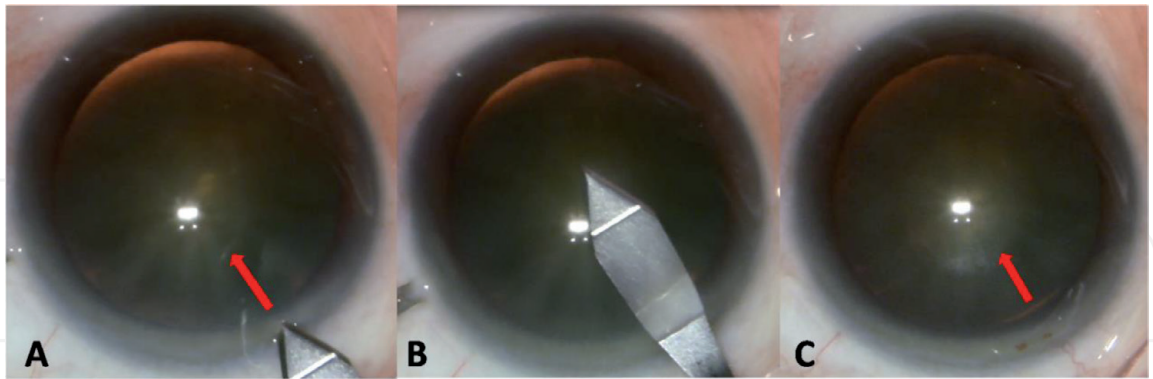


Figure 17.
The direction of incision should along meridian direction (C) from positioning (A) to the process of making the incision (B).

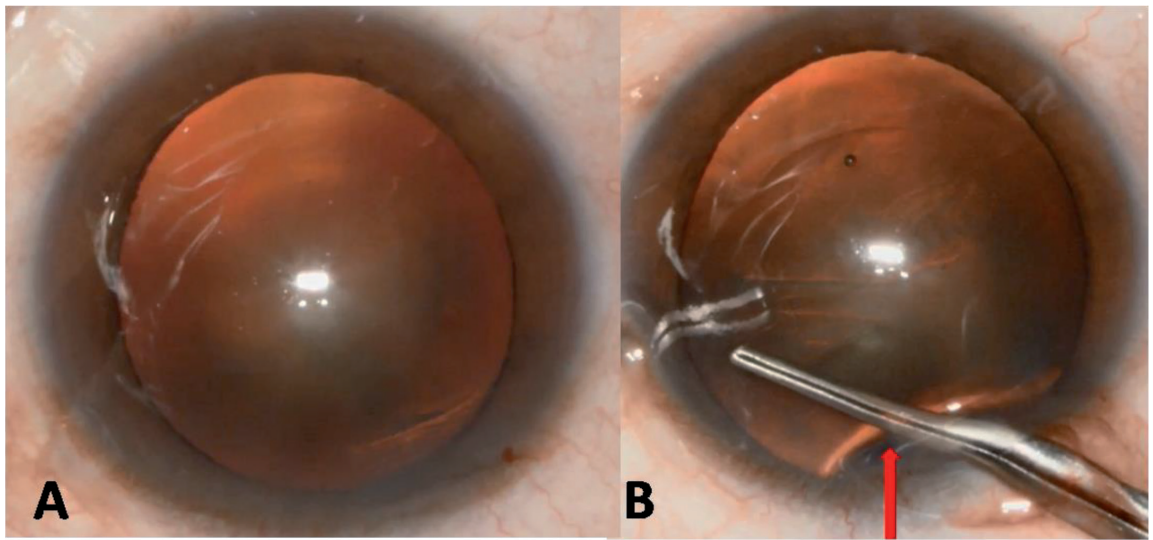


Figure 18.
Incision deviates from the meridian showed in A. the boundaries of deflective inner incision limit the movement of capsulorhexis forceps as showed in B.

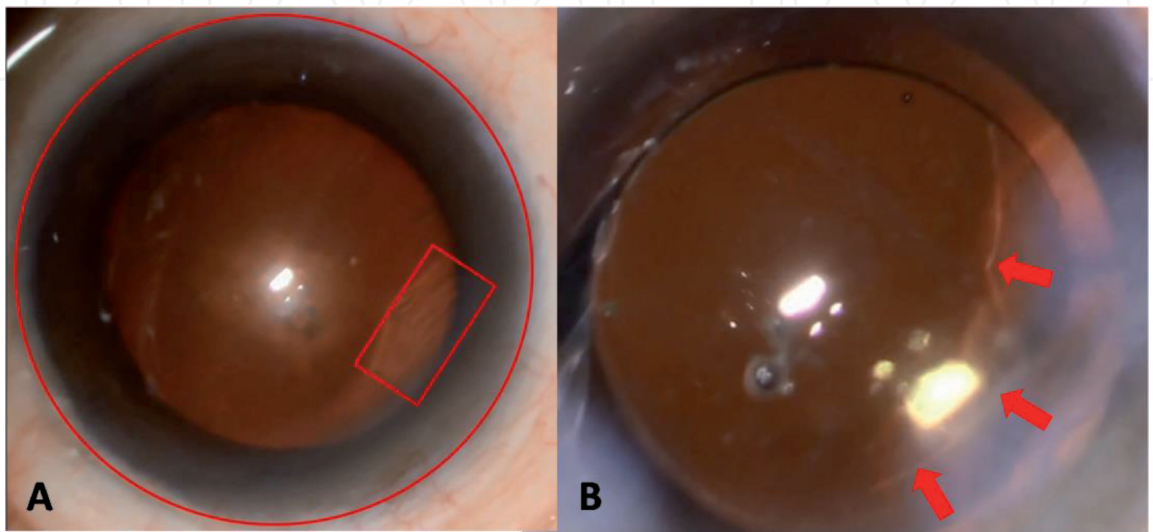


Figure 19.
Incision (red box) is too close to the center of the cornea relative to the limbus (red circle). The irregular AC opening (red arrow) followed the non-ideal incision.

4. Capsulorhexis

4.1 Viscoelastic injection

When a viscoelastic agent is injected into the eye, the needle should move inside out, while filling the whole anterior chamber with the viscoelastic to flatten the AC. Otherwise, the path of the capsulorhexis would slide in the direction of the suspensory ligament.

4.2 Bimanual coordination

Coordinate your hands, hold the tweezers in your dominant hand and slightly fixate the eyeball to maintain the cornea in the middle. The hand holding the tweezers should be soft and not put pressure on the eyes. Otherwise, the viscoelastic agent can extrude from the incision, resulting in uneven force on the AC and capsular tear. However, too much pressure on the eyeball will cause folds on the cornea, which affects the surgical field of vision.

4.3 The production of the lamella

The process of capsulorhexis is equivalent to drawing a circle. With the eye in position, consider the focal point reflected by the microscope light as the center, and tear the forceps from this point (red circle in **Figure 20**) to open the AC, with an outward radius of approximately 2.5 mm.

4.4 Capsulorhexis technique

The limbus can be used as reference to guide the capsulorhexis [20]. For the unexperienced surgeon, the technique is difficult given the narrow diameter of 5–5.5 mm. To aid the process, the marks on forceps in **Figure 6** or the marks made on the cornea before initiation of capsulorhexis, can be used for guidance.

The following points should be considered during capsulorhexis:

- a. If excessive pressure is applied by the forceps on the internal incision, the viscoelastic agent could spill out from the incision site. This would leave the

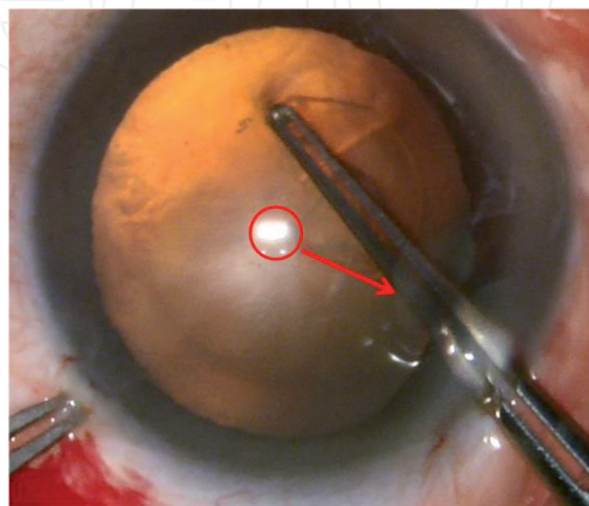


Figure 20.

The light spot (red circle) would be center of capsule if the position of head and eye maintain level. The radius of capsulorhexis is showed as red arrow.

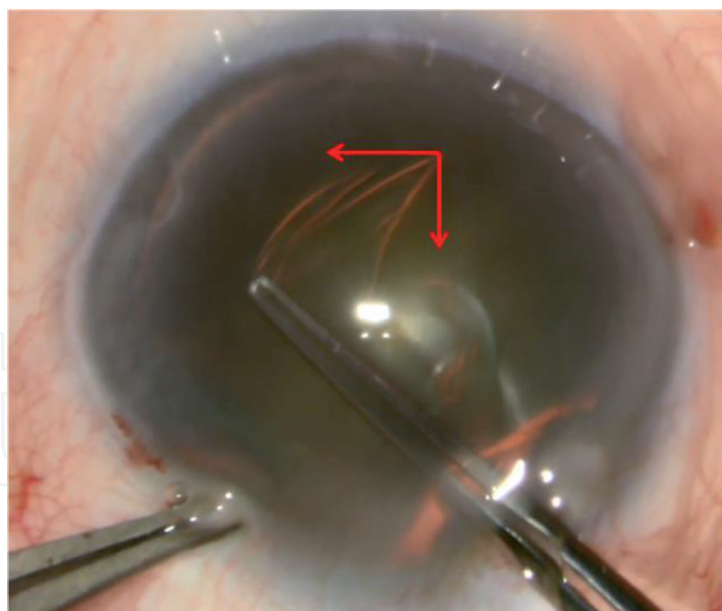


Figure 21.

The force of capsulorhexis is composed of forces in two direction as showed by red arrows. One is along the tangent of the circle, and the other is towards the center of the circle.

anterior chamber partially filled, and the resulting unbalanced forces applied on the AC, will cause capsulorhexis failure.

- b. The trajectory of the capsulorhexis will depend on the balance of two forces exerted during the movement of the forceps by the surgeon, as shown in **Figure 21** by red arrows. One is the tearing force along the tangent of the circle, and the other is the pulling force perpendicular to the tangent, towards the center of the circle. Only when the two forces are balanced, will the trajectory be correct and the capsulorhexis completed successfully. If the tearing force along the tangent of the circle is larger, the trajectory of the capsulorhexis would shift laterally, causing a tear. If the pulling force is larger, the trajectory of capsulorhexis would deviate towards the center, resulting in a very small capsulorhexis.
- c. A skilled surgeon can complete the capsulotomy in 3 to 4 attempts, while a beginner should increase the number of attempts and stop before the capsule trajectory cannot be controlled. Extra care should be taken at the joint, and an additional capsulotomy may be added if necessary.
- d. During the movement, avoid lifting the forceps too high, to avoid scratching the corneal endothelium.

5. Special cases of capsulorhexis

5.1 Capsulorhexis in children

Congenital cataracts in children can be a challenge for surgeons, and should not be attempted by beginners, for several reasons:

- a. The AC of children is more flexible, which makes it difficult to cut with forceps. The discission needle made by 1 ml syringe is the preferred instrument in this case, as shown in **Figure 22**.

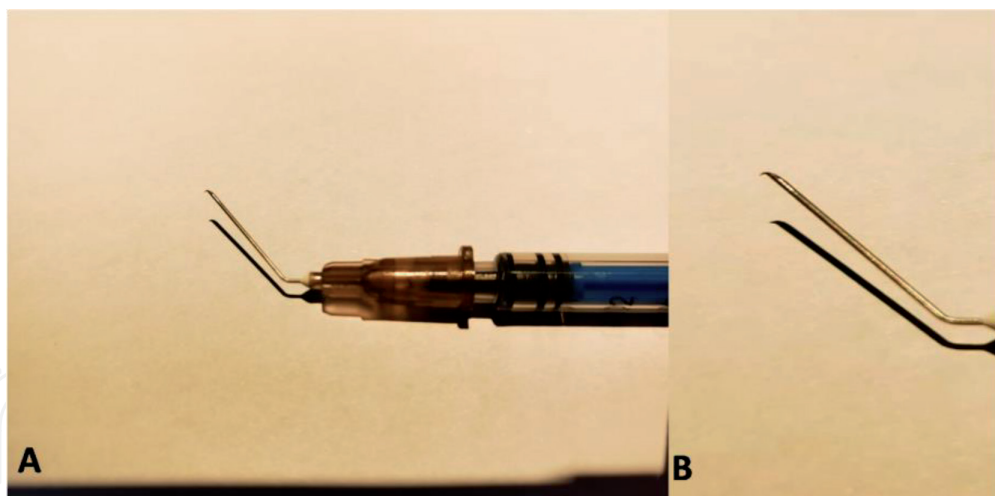


Figure 22.

A showed the discission needle made by 1 ml syringe. B showed the detail of the needle.

- b. Owing to the increased toughness and flexibility of the AC, the trajectory of capsulorhexis can be difficult to control. The pulling force should be slightly increased to avoid tearing and an oversized opening.
- c. Cataracts with congenital lens abnormality are usually associated with suspensory ligament anomaly, which can be a challenge even for a skilled operator.

5.2 Uveitis complicated cataract

The challenge in this situation is the difficulty of pupil dilation due to iris degeneration caused by uveitis, which has a significant impact on the surgical field of vision. The measures recommended for this situation have been already mentioned in the **surgical field of vision** section.

5.3 Mature cataract

In mature cataracts, the capsular membrane is relatively brittle and often accompanied by intumescent lens, as shown in **Figure 23**.

Due to the excessive expansion of the surface, the AC often tears-out, forming the Argentinian flag sign. To avoid this, the method of capsule decompression is recommended as follows:

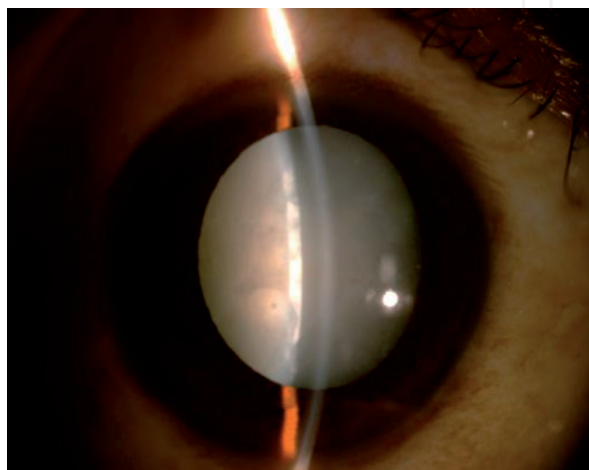


Figure 23.

Color photo of white cataract with intumescent lens and shallow anterior chamber.

- a. Dye the capsule with Trypan blue to increase visibility
- b. Puncture the central area of the AC with the tip of a needle or forceps as A in **Figure 24**, with a resulting liquefied cortical efflux (red arrow in B of **Figure 24**). A blunt needle can then be used to clear this efflux.
- c. Alternatively a discission needle can be used to puncture the AC and then clear the liquefied cortex under the AC directly. Remember to bevel the needle downwards and to maintain the operation in the central area of the AC as C in **Figure 24**.
- d. When the liquefied cortex is cleared, the central area of the AC will collapse (D in **Figure 24**). At this point, the AC can be flattened by injection of viscoelastic, and capsulorhexis initiated. The process of capsulorhexis could be then divided into two steps as needed, beginning with a small opening, and the then extending the radius to approximately 2.5 mm.

5.4 The challenge of small pupil and flabby suspensory ligament

A disease that often causes difficulty with capsulorhexis is exfoliation syndrome, because of two clinical aspects. Firstly, the pupils cannot be dilated past 5 mm,

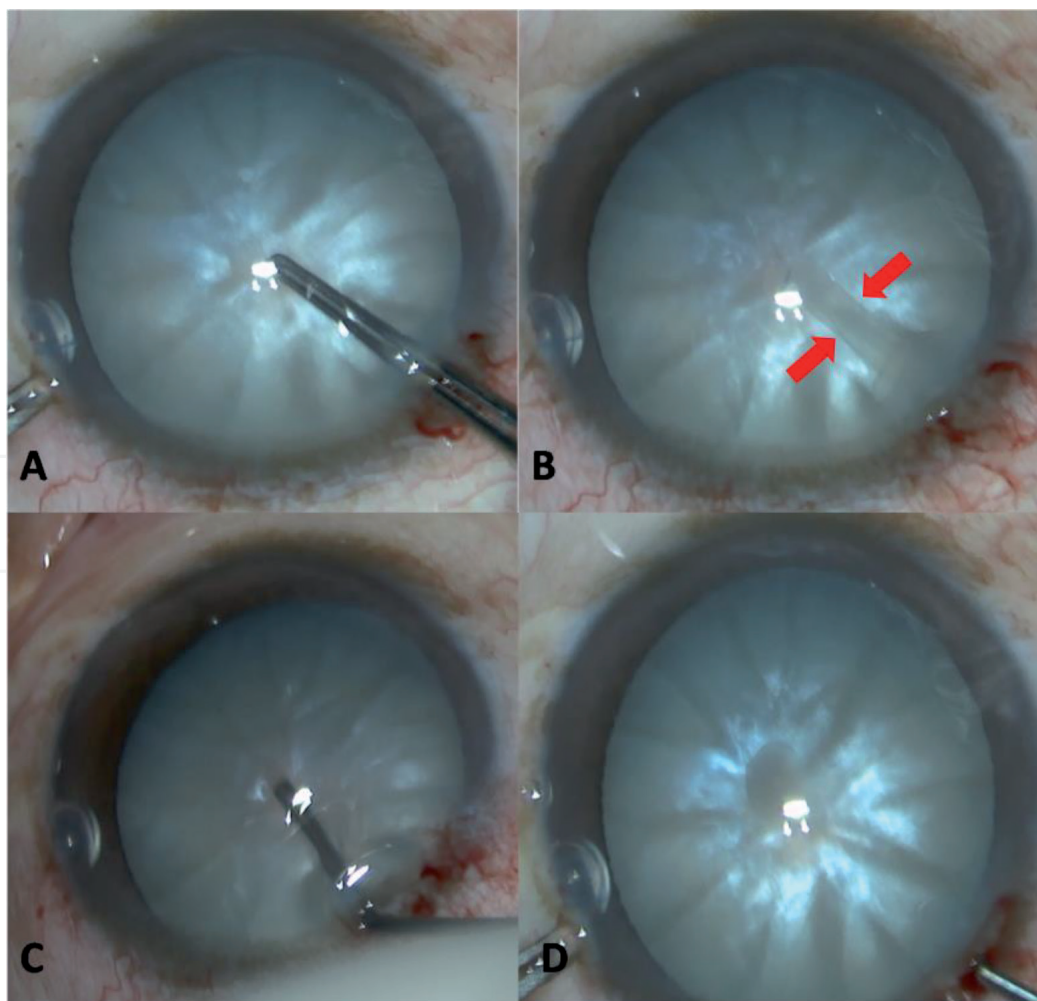


Figure 24.
Decompression of intumescent lens. To pierce the intumescent AC with the tip of capsulorhexis forceps (A). The liquefied cortex spills out (red arrows in B). Discission needle was applied to clear the liquefied cortex beneath AC (C). AC collapse appeared as larger annular reflections (D).

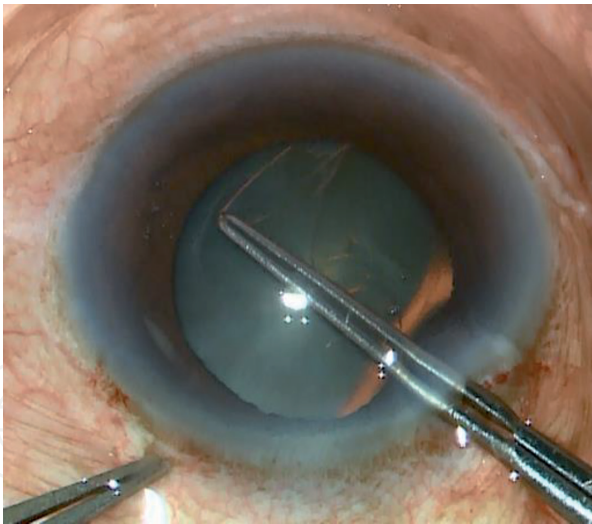


Figure 25.
The pupil is too small to expose the trajectory of the capsulorhexis. Skilled surgeons could perform a blind capsulorhexis.

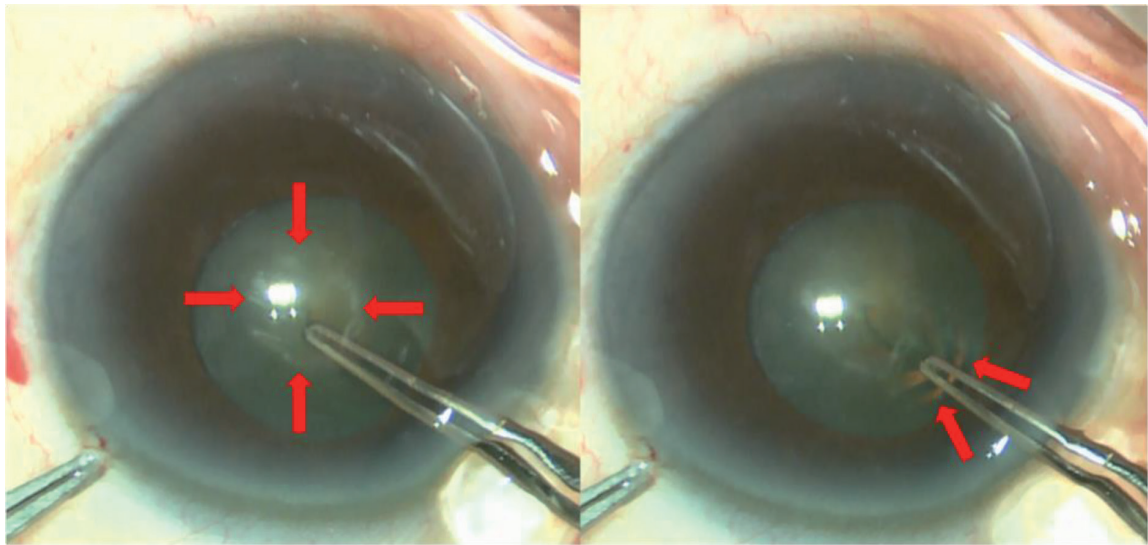


Figure 26.
Suspensory ligament of exfoliation syndrome is extremely flabby which could appear as the radial and wrinkled reflections during capsulorhexis (red arrow).

generating an insufficient red reflex for the operator to perform the procedure comfortably. The Malyugin ring, as mentioned in the section on the surgical field of vision, can be used in such situations. However, skilled surgeons often perform a blind capsulorhexis. The trajectory of the capsulorhexis is covered by the iris, as shown in **Figure 25**.

The other difficulty is extreme relaxation or even rupture of the suspensory ligament, which can be difficult to detect, even with UBM (Ultrasound Biomicroscopy). As the pupil cannot be dilated large enough and therefore the condition of suspensory ligaments around the capsule is not clear. However, the extent of the suspensory ligament relaxation can be judged by the folds caused by the tip of the capsular tweezers when touching the surface of the AC during capsulorhexis as showed in **Figure 26**.

When such a situation occurs, the surgeon should be careful, and the number of capsulorhexis should be appropriately increased to improve controllability. This method is also suitable for small pupils in diabetic patients and patients with prostatitis treated with Finasteride. Beginners should be aware of this disease and refer the cases to experienced surgeons.

6. Capsulorhexis assisted by femtosecond laser

Femtosecond laser capsulorhexesis superior in accuracy and precision compared with manual capsulorhexis, as well as the tensile strength of the capsule opening. An accurate circular, continuous and centered capsulorhexis as achieved by a femtosecond system cannot be achieved manually [21] (**Figure 27**). Because of these advantages, capsulorhexis assisted by a femtosecond laser is even more critical for premium IOLs. Presently, femtosecond laser surgery is also used in mature, traumatic, and for other cataract patients with suspensory ligament abnormalities [22–26].

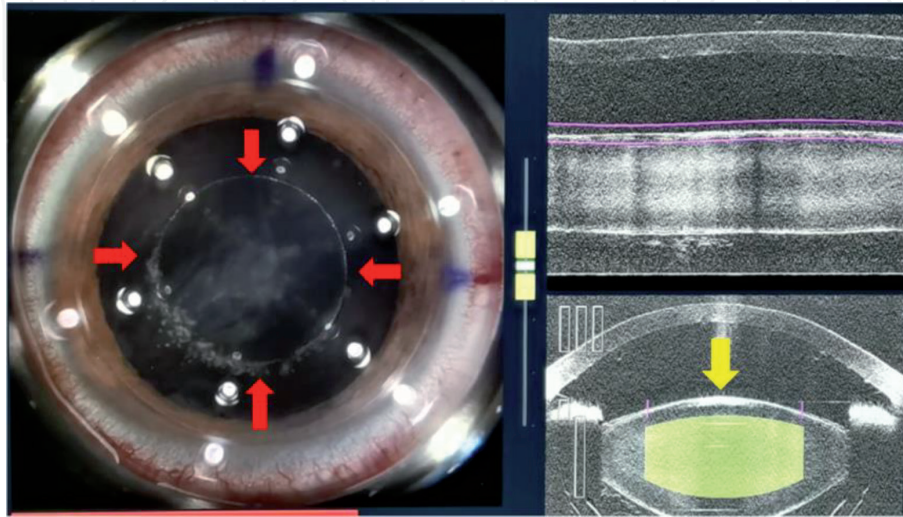


Figure 27.

The display interface of femtosecond laser during capsulorhexis. A perfect AC opening (red arrow) was conducted. Lens plane was also displayed by anterior OCT (yellow arrow).

This system greatly reduces the risk of capsulorhexis with due attention to the following recommendations:

1. The patient needs to be able to cooperate.
2. The patient's head and eye position should remain absolutely horizontal, as shown in **Figure 5**. Excessive upturn and downturn can lead to failure of capsulorhexis. Therefore, patients with head tremor and uncooperative eye position should be cautious. We can refer to the surface of the lens shown in anterior OCT of this system as yellow arrow in **Figure 27**.
3. The pupil must be dilated to at least 5 mm.

7. Conclusion

As cataract surgery enters the refractive age, the criteria “continuous, circular, and centered” have become the basic requirement of the capsulorhexis technique. Therefore, it is extremely important for the surgeon to master the technique of capsulorhexis.

Conflict of interest

The authors declare no conflict of interest.

IntechOpen

IntechOpen

Author details

Liu Qian

Department of Cataract, Shanxi Eye Hospital, Taiyuan, Shanxi, China

*Address all correspondence to: liuuqian@126.com

IntechOpen

© 2021 The Author(s). Licensee IntechOpen. This chapter is distributed under the terms of the Creative Commons Attribution License (<http://creativecommons.org/licenses/by/3.0>), which permits unrestricted use, distribution, and reproduction in any medium, provided the original work is properly cited. 

References

- [1] Gimbel HV, Neuhann T. Development, advantages, and methods of the continuous circular capsulorhexis technique. *J Cataract Refract Surg.* 1990;16(1):31-7.
- [2] Wyględowska-Promieńska D, Jaworski M, Koziel K, Packard R. The evolution of the anterior capsulotomy. *Videosurgery Miniinv.* 2019;14(1):12-18.
- [3] Gimbel HV, Neuhann T. Development, advantages, and methods of the continuous circular capsulorhexis technique. *J Cataract Refract Surg.* 1990; 16:31-7.
- [4] Gimbel HV, Neuhann T. Continuous curvilinear capsulorhexis. *J Cataract Refract Surg.* 1991;17:110-1.
- [5] T Neuhann. Theory and surgical technic of capsulorhexis. *Klin Monbl Augenheilkd.* 1987;190(6):542-5.
- [6] Bhavana Sharma, Robin G Abell, Tarun Arora, Tom Antony, Rasik BVajpayee. Techniques of anterior capsulotomy in cataract surgery. *Indian Journal of Ophthalmology.* 2019;64(4):450-460.
- [7] Kranitz K, Takacs A, Mihaltz K. Femtosecond laser capsulotomy and manual continuous curvilinear capsulorhexis parameters and their effects on intraocular lens centration. *J Refract Surg.* 2011;27:558-63.
- [8] Hollicke EJ, Spalton DJ, Meacock WR. The effect of capsulorhexis size on posterior capsular opacification: One-year results of a randomized prospective trial. *Am J Ophthalmol.* 1999;128:271-9.
- [9] Aykan U, Bilge AH, Karadayi K, Akin T. The effect of capsulorhexis size on development of posterior capsule opacification: Small (4.5 to 5.0 mm) versus large (6.0 to 7.0 mm). *Eur J Ophthalmol.* 2003;13:541-5.
- [10] Ravalico G, Tognetto D, Palomba M. Capsulorhexis size and posterior capsule opacification. *J Cataract Refract Surg.* 1996;22:98-103.
- [11] Hayashi K, Hayashi H. Effect of anterior capsule contraction on visual function after cataract surgery. *J Cataract Refract Surg.* 2007; 33(11):1936-1940.
- [12] Wirtitsch MG, Findl O, Menapace R, Kriechbaum K, Koepl C, Buehl W, et al. Effect of haptic design on change in axial lens position after cataract surgery. *J Cataract Refract Surg.* 2004;30:45-51.
- [13] Okada M, Hersh D, Paul E, van der Straaten D. Effect of centration and circularity of manual capsulorhexis on cataract surgery refractive outcomes. *Ophthalmology.* 2014;121:763-70.
- [14] Chee SP, Bacsal K. Endophthalmitis after microincision cataract surgery. *J Cataract Refract Surg.* 2005;31:1834-5.
- [15] Alió J, Rodríguez-Prats JL, Galal A, Ramzy M. Outcomes of microincision cataract surgery versus coaxial phacoemulsification. *Ophthalmology.* 2005;112:1997-2003.
- [16] Elkady B, Piñero D, Alió JL. Corneal Incision Quality in Microincisional Cataract Surgery (MICS) vs. Microcoaxial Phacoemulsification. *J Cataract Refract Surg.* 2009;35:466-74.
- [17] El Kady B, Alió J, Ortiz D, Montalbán R. Corneal aberrations after microincision cataract surgery. *J Cataract Refract Surg.* 2008;34:40-5.
- [18] Yao K, Tang X, Ye P. Corneal astigmatism, high order aberrations, and optical quality after cataract surgery: Microincision versus small-incision. *J Refract Surg.* 2006;22:S1079-82.
- [19] Jiang Y, Le Q, Yang J, Lu Y. Changes in corneal astigmatism and high order aberrations after clear corneal

tunnel phacoemulsification guided by corneal topography. *J Refract Surg.* 2006;22:S1083-8.

[20] Wang X, Dong J, Deng M. Limbus-centered marking technique-assisted continuous circular capsulorhexis. *Medicine (Baltimore).* 2021 Jan 15;100(2):e24109.

[21] Friedman NJ, Palanker DV, Schuele G, Andersen D, Marcellino G, Seibel BS, Batlle J, Feliz R, Talamo JH, Blumenkranz MS, Culbertson WW. Femtosecond laser capsulotomy. *J Cataract Refract Surg.* 2011;37(7):1189-1198.

[22] Pei-Wei Huang, Wei-Hsuan Huang, Yuan-Che Tai, Chi-Chin Sun. Femtosecond laser-assisted cataract surgery in a patient with traumatic cataract and corneal opacity after LASIK: a case report. *BMC Ophthalmol.* 2020;20(1):218.

[23] Soon-Phaik Chee, Melissa H Y Wong, Aliza Jap. Management of Severely Subluxated Cataracts Using Femtosecond Laser-Assisted Cataract Surgery. *Am J Ophthalmol.* 2017;173:7-15.

[24] Armando S. Crema, Aileen Walsh, Iris S. Yamane, Bruna V. Ventura, Marcony R. Santhiago. Femtosecond Laser-assisted Cataract Surgery in Patients With Marfan Syndrome and Subluxated Lens. *J Refract Surg.* 2015;31(5):338-341.

[25] Jeewan S Titiyal, Manpreet Kaur, Archita Singh, Tarun Arora, Namrata Sharma. Comparative evaluation of femtosecond laser-assisted cataract surgery and conventional phacoemulsification in white cataract. *Clin Ophthalmol.* 2016;22(10):1357-64.

[26] Danmin Cao, Yong Wang, Rong Lei, Mahmood Khan, Li Wang. Femtosecond laser-assisted cataract surgery in a spherophakic lens: An unusual case report. *Medicine (Baltimore).* 2019;98(44):e17426.