

We are IntechOpen, the world's leading publisher of Open Access books Built by scientists, for scientists

6,900

Open access books available

185,000

International authors and editors

200M

Downloads

Our authors are among the

154

Countries delivered to

TOP 1%

most cited scientists

12.2%

Contributors from top 500 universities



WEB OF SCIENCE™

Selection of our books indexed in the Book Citation Index
in Web of Science™ Core Collection (BKCI)

Interested in publishing with us?
Contact book.department@intechopen.com

Numbers displayed above are based on latest data collected.
For more information visit www.intechopen.com



Thoracic Organ Procurement during Multi-Organ Retrieval

*Suresh Keshavamurthy, Vipin Dulam, Eros Leotta,
Mohammed A. Kashem and Yoshiya Toyoda*

Abstract

Procurement of thoracic organs can be divided into two major categories- donation after brain death (DBD) or donation after circulatory determination of death (DCDD). In this section we will focus primarily on DBD, which is the commoner of these two or at times referred to as standard procurement. DCDD is a relatively new and promising field that has helped ameliorate donor shortage, aided by the latest advances in medical technology. However, DBD continues to be the major avenue of organ donation. There are several different combinations of thoracic procurement surgeries: heart, double lung, single lung/ 2-single lungs, heart-lung en bloc for transplantation, Double Lung procurement for Bronchial arterial revascularization, Heart and Lung procurement in DCDD donors with the OCS, NRP or Lungs for EVLP.

Keywords: thoracic organ procurement, multi-organ harvest, DCD

1. Introduction

We believe that procurement is 50% of the transplant operation and deserves due emphasis. Often times it is assigned to a junior member of the team and consequently impacts the outcome due to the learning curve involved. We have put together our experience to serve as a road-map to help improve the art and science of procuring thoracic organs for transplantation [1].

In the first section of this chapter we will focus primarily on DBD, which is the commoner of these two or at times referred to as 'standard procurement.' We will expound on Heart, Lung/s and combined Heart-Lung procurement.

2. Donation after brain death

2.1 DBD: heart only procurement

First, we will focus on an isolated heart procurement. This is with the understanding that it is the sole organ being procured from the chest.

The surgeons must first familiarize themselves with the donor's vital signs, ECG, ECHO, angiogram, labs and any other form of imaging that's available in order to assess the hemodynamic stability and anatomy of the donor to avoid surprises. Perhaps even more importantly, donor blood type and match information must be confirmed. These are (but not limited to) the donor's MHC status, antibody checks, and ABO

blood type compatibility. Other donor information such as Hepatitis B, Hepatitis C, and HIV status should also be double checked in the donor chart on site. Discrepancies should be conveyed to the rest of the transplant team at the recipient site immediately. The suitability of the organ with respect to size match in terms of a predicted heart mass ratio should be confirmed. At the site, a copy of the consent for donation and the donor's brain death status as per the specific state's legislated criteria are to be obtained for the procurement surgery teams records. Finally, confirm that the donor had no other changes in status since the procurement team's original debrief and arrival at the site. Specifically, the surgeon must look out for worsening lab values, such as changes in the lactate levels, and any increase in pressor requirements. The usage of Thyroxine (T4) as part of the donor recruitment process is also recommended [2].

The procurement team's next step should be to assess if there is appropriate arterial and venous access for the donor. At times one sees that the donor only has a femoral arterial access line. This leaves the patient without any blood pressure monitoring when the abdominal team ligates the aorta during their cannulation. Because of this, the anesthesia team can get alarmed and give boluses of pressor medications, which in turn can have a deleterious effect on the heart. Therefore, we recommend upper limb invasive pressure monitoring system such as a radial artery line or brachial arterial access.

The sternum is opened via a median sternotomy in a standard fashion limiting blood loss and securing hemostasis. It is our practice to measure intracardiac pressures from the Right Atrium, Left Atrium and Pulmonary Arteries from the donor heart to get an accurate estimate of the patient's hemodynamics. These parameters are immediately communicated to the implanting surgeon. These measures give the team a snapshot of the cardiac function of the donor's heart.

The heart surgeon will have to share the IVC with the liver surgeon. This can be a point of contention regarding the length of IVC to be taken by the cardiac surgeon versus the length taken by the liver transplant team. An ambitious cardiac surgeon might divide the IVC at the level of the diaphragm with traction on the heart to the extent where the IVC retracts below the diaphragm and leaves but a stump for the liver transplant team. Hence, it is prudent to discuss with the liver surgeon beforehand as to where to transect the IVC. Staying above the diaphragmatic reflection has been the standard practice. Avoiding traction while harvesting is important, though one often sees the liver team retracting the liver down!

The procurement surgeon should pay special attention to the venting that is done to decompress the donor heart. With multiple teams sitting in the fray, this aspect of the surgery is often ignored at the patient's peril. The techniques to vent the heart are either through the LA appendage, the interatrial groove, the posterior left atrial wall or directly amputating the pulmonary veins [3]. In this scenario, where we are discussing heart only procurement, it is useful to vent through the pulmonary veins (the pulmonary vein orifices can be connected in the back table). However, if other thoracic transplant teams (like the lung team) are involved then they will be perfusing the lungs with 4–6 liters of Perfadex (*PERFADEX® Plus is an extracellular, low potassium, dextran-based electrolyte preservation solution for rapid cooling, perfusion and cold static storage of donor lungs – pre-supplemented with calcium ions and THAM; Perfadex® Goteborg, Sweden solution*). Our experience shows that it is best to vent through the left atrial appendage. Venting through the interatrial groove can also be done (must be dissected out before the cross-clamp application) but it comes with a major hazard- the heart may go into atrial fibrillation and cause hemodynamic compromise. Venting primarily through the posterior left atrial wall is also an option.

For this, the surgeon first picks up the heart to access that portion of the left atrium but once the opening is made and the heart is let down back into its position in the chest cavity, it is not predictable if the hole will stay open to adequately vent the heart. Furthermore, lifting the heart during cardioplegia administration might

cause aortic sufficiency. The pulmonary veins can be amputated at their origins and we can divide the pulmonary artery as high as we need to in order retain the bifurcation. It is also wise to divide the SVC high up above the azygos vein to give the implanting surgeon additional SVC length.

These are special situations in which it is important to know the anatomy of the recipient and to discuss with the implanting surgeon specific requirements.

3. Adult congenital heart disease recipients

Recipients of Adult congenital heart disease needing heart transplantation for advanced heart failure have generally undergone multiple open-heart procedures in the past. Therefore, they might need additional donor tissue to reconstruct the recipient anatomy.

In those recipients with an anomalous left superior vena cava (LSVC), the implanting surgeon will need extra length of the SVC and also need to harvest the innominate vein to allow for restoration of continuity of the LSVC in the recipient [4]. On the other hand, in the donors with an LSVC one must be extra conscious of the donor heart vasculature. There have been noted cases where the coronary sinus drains into the LSVC instead of the RA [5]. Ligating the LSVC without ascertaining drainage to the RA could prove to be disastrous for the recipient because after implantation and circulation restoration, the heart has no drainage avenue and hence may become edematous and lead to primary graft dysfunction. Any additional systemic/pulmonary venous drainage anomalies are also important to note on both the recipient and donor.

For certain circumstances, such as a recipient with complex congenital heart disease who may require reconstruction of the pulmonary arteries, additional tissue may need to be procured either in continuity with the donor heart or separately, such as the descending thoracic aorta or innominate vein. If possible, the PA bifurcation along with the RPA and LPA should be procured if the lungs are not being placed [6].

If possible for these subset of patients it is important to procure a long length of the donor aorta till the arch, the PA with the bifurcation and extra lengths of RPA and LPA, donor carotid artery, descending thoracic aorta, donor pericardium, etc. to aid reconstruction and repair in the recipient.

4. LVAD explants/redo chest

Since these patients have an outflow graft placed on the ascending aorta. The procurement surgeon must harvest the ascending aorta as distal as possible past the three arch branches in the donor. This gives the implanting surgeon enough length and flexibility to decide where to do the aortic anastomosis.

5. Heterotopic heart transplant

This chapter mainly focuses on orthotopic heart transplantation (the standard explant of the old diseased heart, and implant of a new donor heart into the chest cavity). However, there is another form of heart transplant which has been performed since the 1970's called heterotopic heart transplantation [7]. While this is rare, there are few select indications for this procedure, and we wanted to include this for completion.

An extra length of aorta is required, and the pulmonary veins must be transected close to their origin to give the recipient surgeon enough room to operate with. The procuring surgeon must also take as much of the SVC/IVC as possible. The Pulmonary Artery will need to be augmented with a graft material in the recipient

because the implanting surgeon will connect the pulmonary artery of the new heart to the pulmonary artery of the recipient's native heart. Therefore, it becomes extra important to take as much of the pre-bifurcation PA as possible.

6. Final steps

After explantation of the heart, the surgeon should check for a patent foramen ovale (PFO); if one does exist, then a PFO closure using a 4-0 prolene suture should be performed as quickly as possible before putting the heart in the cooler. Inspect the pulmonary artery and aorta, mitral valve, tricuspid valve for any anatomical abnormalities/clots/vegetations/iatrogenic damage. At this point, inform the recipient surgeon if there is any injury. If there is, then donor pericardium can be packed to repair these injuries in the recipient OR.

Some teams prefer to leave the cardioplegia cannula attached to the donor aorta. In these centers the cardioplegia cannula can be placed lower down on the aorta. However, if the cannula is removed and the suture tied to mark the point of cannulation, the cannulation site can be higher up and the same can be excised/trimmed prior to implantation.

Pack the heart in the preservative solution and ensure it is completely immersed in it. The first bag should not contain any ice, while the second and third bags do contain ice. There are special containers that maintain uniform cooling of the heart (Paragonix SherpaPak™) in 4 degrees centigrade [8]. These containers help to optimize donor heart transport by maintaining uniform cooling and perhaps extend the donor warm ischemia time.

6.1 DBD- procurement of heart and lung for separate centers

In this section we want to discuss procurement of both the lungs and the heart as separate organs from the same donor but for different recipients. (Note: the procurement surgeon however might still be from the same center) In this scenario, the heart is being taken for transplant, while simultaneously, the lungs are being procured either as double lung, single lung, or two single lungs. This implies that both the heart surgeon and lung surgeon (unless one surgeon is taking both for two separate patients in the same center) will be present.

Assuming that each of the two lungs are being taken by different centers, and the heart is being taken by another center, up to three different surgeons could be present for procurement of the thoracic organs. It requires the utmost cooperation and communication with each other to be able to successfully execute such a multi-organ procedure.

We recommend the heart surgeon start first and inspect the heart. The sternotomy is performed in the midline once all teams are present, signed in and the basic checks are conducted. Hemostasis is achieved using ample amounts of bone wax. The pericardium should be split down the middle. Three pericardial stay sutures should be put on either side of the pericardial opening and tag them to hemostats. Based on our practice we recommend that the pericardial stay sutures not be hitched up to the drapes at this point. The reason for this is it causes tension on the pericardium, and when the lung surgeon is trying to inspect and recruit the lungs with a Valsalva maneuver it squeezes the heart to cause hemodynamic compromise [9].

Once the heart is appropriately visualized, the heart surgeon should check the quality of the heart by palpating the coronary arteries to assess for atherosclerosis, visually confirm the heart's contractility, and by checking the right atrium, the right ventricle, the pulmonary artery and the aorta. It is also important to check if there are any

palpable thrills or any anomalies in the systemic venous drainage or pulmonary venous drainage. Our practice is to measure the intracardiac pressures; the PA, RA, and LA and communicate them with the implanting surgeon for cross check. It is important to avoid opening the pleura. This is when the lung surgeon steps into the limelight.

Once the lung surgeon approaches the table, the pleura should be opened widely. We recommend opening the pleura bluntly rather than using the diathermy. We have seen many instances where opening the pleura by a diathermy causes an air leak because it accidentally punctures the lung surface. These air leaks are difficult, notorious, and persistent. After one part of the pleura is opened bluntly, then the surgeon can insert one finger behind the pleura but above the lung tissue. The surgeon can now safely use a bovie with the finger protecting the lung in order to divide the rest of the pleura in standard fashion. At this stage inspect the lungs and recruit and atelectatic areas. The lung surgeon is now ready for Valsalva. After communicating this with the anesthesiologist, the lung surgeon reaches for the lower lobe, lifts it up and gives Valsalva at 30 cmH₂O pressure [9]. It is important to refer here to the earlier point about leaving the pericardial stay sutures unhitched. If they had been hitched and the lung surgeons performed the Valsalva, the heart will get compressed between the hitched-up pericardium and the lung/s. This would cause a precipitous drop in blood pressure. Therefore, leave the pericardial stay sutures unhitched, and incise the pleura widely, so that the heart has more room to move. Once the lung surgeon has ascertained the quality of the lung by checking its compliance, and inspecting any abnormalities such as masses or contusions, then the stay sutures can be hitched up on either side. Depending on institution protocol, pulmonary vein blood gases are taken from the right upper, right lower, left upper and left lower pulmonary veins making sure the ventilator settings are on fiO₂ of 100% and PEEP of 5.

The procurement then resumes in standard fashion. First the surgeon dissects the aorta and the pulmonary artery, then uses an umbilical tape to loop the aorta, while separating the svc from the pulmonary artery. Then the surgeon loops the SVC and ligates the azygos vein (this step is optional). The azygos vein is fragile and can be easily injured precipitating brisk bleeding which is difficult to manage. We prefer not to dissect the IVC or interatrial groove before heparin is given so that we avoid hemodynamic compromise and rhythm disturbances such as atrial fibrillation. Therefore, it is prudent to always have internal defibrillation paddles on the sterile table opened and ready to use during procurement. Standard dose of heparin is then given- 30,000 units (adjust according to patient weight). Then the cardioplegia stitch is taken, and the aorta is cannulated. We suggest a dual lumen cardioplegia cannula and transduce the pressure line to monitor the aortic root pressure of the patient. This helps us by telling us the cardioplegia perfusion pressure (ideal is 60–80 mmHg) [10].

Once the heart surgeon cannulates the aorta, the lung surgeon places the purse string on the PA. At this point the surgeons must decide where to divide the Pulmonary artery. On the one hand, one would want to keep an adequate length for the heart surgeon, so it is important to not cut it too short. On the other hand, one would want to leave the bifurcation of the PA intact for the lung surgeon. Therefore, we usually use the right pulmonary arteries as a guide and place the purse string suture at that level. Once the purse string suture is placed, we suggest using a right angle canula and directing the bevel of the cannula towards the pulmonary valve. The reason for this is to avoid improper perfusion of the pulmonary arterial flush. Often, novice procurement surgeons do everything correctly except turn the bevel of the cannula towards the left PA. This results in preferential flow into the left lung with minimal flow into the right lung, which causes mal perfusion with improper protection of the right lung. If using a different type of cannula, it is still important to ensure adequate distribution of the pulmoplegia.

Once all the teams are ready, the heart surgeon cross clamps the aorta and the lung surgeon administer the prostaglandin. The injection site should be as close to the purse string suture on the PA as possible to avoid additional puncture to that artery. This is when all the teams should be extremely alert because the prostaglandin causes the BP to drop. Then, the SVC is snared, and the left atrial appendage is divided by placing a Satinsky clamp on it and the tip is amputated. It is important not to put traction on the LAA while placing the clamp to avoid injury to the base of the appendage or Left Circumflex artery. For this reason, some surgeons are averse to the idea of placing a clamp on the LAA [11].

However, if they are venting through the interatrial groove, then that that should be done first before dividing the IVC. The next step is to divide the anterior wall of the IVC. Wait for about 3–4 beats after this is done to. Be patient as the heart empties, and cross clamp the flaccid heart's aorta as distally as possible towards the arch vessels and start the infusion of the cardioplegia solution. Please note that it is not until the heart is noticed to be fully arrested that the lung team can start the Perfadex solution - be aware to not start them simultaneously. Meanwhile, the surgeon should be constantly observing the heart- feeling the left ventricle to make sure its soft and feeling the aorta to make sure it is firm.

When the Pulmoplegia is being perfused into the PA, note that one should see the efflux through the Left atrial appendage. Keep monitoring the color of the lungs to look for uniform blanching indicating even distribution of the flush solution whilst continuing to ventilate the lungs and simultaneously dropping the FIO2 to 50%. Avoid manipulating the heart during this process. If the LV distends for any reason, stop the cardioplegia and the pulmoplegia, release the cross clamp on the aorta and gently decompress the heart. and then reapply the cross clamp and resume cardioplegia, and pulmoplegia. If the distension continues, open the LA appendage more. If that still does not work, use the interatrial groove to vent. Usually around 4–6 liters of the perfadex solution is given but it varies per hospital protocol.

Keep the cardioplegia running if the perfadex is running. This makes sure the perfadex does not enter the coronaries and wash out the cardioplegia. If the cardioplegia is done before the pulmoplegia, then an aortotomy should be made while the clamp is still there, and a yonkaeur sucker should be inserted into the aorta to suction out and avoid any perfadex solution going into the heart. Once all the flush is done for both the heart and lung, the pulmonary artery cannula is removed, and the prolene suture is cut away. The IVC is then completely divided, taking care to avoid any injury to the right inferior pulmonary vein.

The next step is optimal division of the left atrium. Our recommended approach is to gently retract the heart up while we incise the posterior LA wall and proceed using a Metzenbaum scissors to enlarge the incision leaving an adequate cuff of LA for the lungs at least a 1 cm rim. On the right side, stop the dissection as you reach the IVC. At this point, we recommend the heart be retracted to the left. With the flaccid heart and bloodless field, it should be easier to dissect out the interatrial groove. and leave at least a one-centimeter cuff for the lung implant [12].

Finally, we can transect the aorta as high as possible depending on how much aorta is needed. For the PA extend the incision from where it has been cannulated. Visualize the carina of the PA. Make sure you can see the opening of the right PA. Divide the PA in such as fashion that the bifurcation remains with the lung block. Do not use too much traction while dividing the PA because that can cause distortion. Make sure that the original cut is perpendicular as to leave adequate PA for the heart team. Now that all the divisions are done, release the snare on the SVC, divide the SVC, the azygos vein and anything else holding the heart behind as it is gently lifted out.

The lungs are then harvested in standard fashion. It is always helpful to have the nasogastric tube so that one can feel the esophagus. The arch vessels and innominate

artery are divided, at which point the trachea is exposed and looped. The trachea is then stapled at 60% tidal volume. The lungs are then taken to the back table and given 250 cc's of retrograde flush through each pulmonary vein [13]. There are different ways of effectively conducting the retrograde flush. Some do it in situ in the chest, while others take the lung bloc to the back table. We prefer taking it to the back table and use 250 cc's of perfadex per vein so in total about a liter of retrograde flush (amongst all four veins).

One technique is a foley catheter with an inflated bulb at the tip; inserted into each vein sequentially as the flush is administered. The caveat with this is that one may inadvertently injure the pulmonary vein ostium (which is delicate) by excessively distending it. The other technique, personal communication from Dr. Hassan Nemeh at Henry Ford Health System, is to use a retrograde cardioplegia catheter which has a self-inflating balloon, so it is much more elegant and less traumatic [14]. The only problem with this is it is not part of the standard kit, so the procurement surgeons must remember to bring it with them. Yet another technique that can be used is to utilize the rubber tubing that comes on the end of tubing. Insert the tube into the pulmonary vein and then pinch the vein to provide a tight seal. Whichever technique may be used, note that it is important to have the perfadex solution only 30 cm above the table and run it by gravity; avoid delivering it at excessive pressure which can lead to pulmonary edema!

When the retrograde flush is being perfused be sure to inspect the pulmonary artery for any clots. It is not uncommon to see tiny emboli. If, however large clots are seen, it is important to alert the implanting surgeon who might either choose to abandon or repeat a retrograde flush at the implanting center. Some teams are utilizing EVLP in such situations. After completion of the retrograde flush look inside the PA to assess if there are any clots remaining.

6.2 Heart Lung en Bloc

'Heart-Lung en Bloc' transplantation surgery has become less frequent over the years [15]. However, there are still select indications for it, and one should be aware of how it is performed. The procurement surgeon performs the assessments for both heart and double lungs (as discussed in the earlier section) and oversees physiological and anatomical assessments both for the heart and lungs. The heart assessment is made in standard fashion- the coronaries are palpated, the aorta is inspected, the right atrium and pulmonary artery are assessed, and any palpable thrills are ruled out. Look thoroughly for contusions and note any evidence of trauma. Injuries which could impact implantation should be thoroughly discussed with the rest of the team. Once the assessment is complete and the heart is deemed good for transplant, we proceed to assess the lungs in standard fashion. Our assessment includes bronchoscopy, ventilatory mechanics, compliance and gentle recruitment followed by selective pulmonary vein blood gasses done on a vent setting of 100% fiO_2 and PEEP of 5 cmH_2O .

Administer heparin to do the donor as soon as all the teams are ready. The aorta is then cannulated, and the PA cannulation follows shortly after (as described earlier, the bevel should be turned towards the pulmonary valve). It is important that the pulmoplegia (Perfadex) be kept no higher than 30 cm off the table thereby letting it run by gravity.

Once all the teams are ready for cross clamp, prostaglandin is injected into the PA. The heart is vented through the left atrial appendage. A major notable difference from the double lung procurement is that there is no retrograde flush; only an antegrade flush is done. The SVC (superior vena cava) is snared above the level of the azygos vein; the azygos vein would have been ligated earlier. The IVC is partially transected at a point of agreement with the liver team.

It is prudent to patiently wait for the heart to empty, and then cross clamp the ascending aorta right below the innominate artery. We suggest not clamping the

aorta when the heart is still ejecting. After this, start the cardioplegia infusion, while also measuring the aortic root pressure and wait for the heart to arrest prior to starting pulmoplegia [16]. As soon as the flush is started, we cover the heart, lungs, and entire pleural cavity with ice slush. All the while be aware that the heart is not distending, that the aortic root is firm, the LV is soft and of course that the LA appendage is adequately draining. Look at lung surfaces to see that they're evenly blanched.

Request the Anesthesia team to decrease the FiO_2 to 50% and ventilate the lungs for proper distribution of pulmoplegia to all the lobes. Again, it is important to keep an eye on the LV to make sure it is not distending. Avoid lifting the heart so as not to cause aortic insufficiency! Ensure there is a backup cardioplegia bag in case of a hypertrophied LV. Avoid pulmoplegia going into the coronaries! Either keep the root distended with additional cardioplegia or transect the aorta and place a yonkaeur sucker till the pulmoplegia is done.

Once the cardioplegia and the pulmoplegia are done, the pulmoplegia cannula is removed and the purse-string suture is secured. Similarly, the cardioplegia cannula is removed and the suture secured depending upon institution preference. We then complete the inferior vena cava (IVC) transection and then transect the ascending aorta as high as possible. We then divide the inferior pulmonary ligaments on both sides and complete the division of the posterior pericardium. It is important to keep the nasogastric tube so that we can palpate and tell where the esophagus is to not contaminate the mediastinum. Be sure to dissect anterior to the esophagus and go up to the level of the azygos vein and then divide the azygos vein.

Now for the final steps. Loop the trachea as high as possible. After a few recruitment breaths, the endotracheal tube is withdrawn, and trachea is stapled at 60% of the tidal volume. Then we divide the SVC as high as possible near junction of innominate vein, taking care to avoid retaining a piece of central line while transecting the SVC. Now we have IVC, SVC, Aorta and trachea all divided. Important not to have more than 60% of the tidal volume to avoid barotrauma. The heart lung bloc is delivered onto back table. Quick inspection is made for iatrogenic injuries. The heart lung bloc is then packed in the heart solution. Have adequate solution enough to immerse the entire bloc. The inner bag contains only the preservative solution, while the second and third bag have ice slush. The heart-lung is then labeled accordingly and packed in the cooler for transportation. It is important to communicate to the implanting surgeon the conduct of the harvest and update him about any iatrogenic injuries and need for repairing the left atrial appendage venting site.

7. Donation after circulatory death

7.1 DCDD- lung only procurement surgery (heart not placed for transplant)

Once an offer for a DCDD lung is received the surgeon and the pulmonologist will process the offer just like a standard one. More specifically, the blood gasses, the X-Ray, the CT scan (if not available, request one), the ventilatory timeline, and the bronchoscopy findings (not always done) should all be analyzed. The nature of the donor death should also be scrutinized very closely- such as drowning or hanging [17].

The key in assessing a DCDD lung offer in comparison to a standard DBD offer is that the target PaO_2 is 350 mmHg as a rule out. In our clinical practice, we currently do not venture to inspect a DCD lung unless the p/f ratio is adequate [18]. Using 350 mmHg is a good starting point especially in those centers where DCD volume is not very high. There are few centers who place all DCDD lungs on EVLP and have different

set of guidelines. For a DBD offer we would venture to inspect the lung even with a PaO₂ of 300 mmHg or lower. The reason for this discrepancy is that in a standard DBD we have the ability to recruit the lung, assess it, check the blood gases and decide in the operating room if the lung is suitable for transplantation. In DCD- what we have is what we get- so we must ascertain the lung status before we head over to the center, which explains why we have more stringent cut-off: to make sure that the lung is acceptable radiologically (CT scan preferred) and physiologically. Bronchoscopy is often done after withdrawal of care (most of the time it is for flushing) and it is done in a rush [6].

In conclusion we must be very careful with the pre-operative assessment in a DCD lung. There are certain centers, especially Toronto, where all the DCD lungs are put on EVLP. Hence it does not matter what the PaO₂ ratio is [19]. They then evaluate these lungs while on EVLP, but not all centers have that luxury yet. Before a DCD Lung transplant procurement is initiated at the recipient center, the following questions should be asked in a checklist format:

1. Where is life support being withdrawn? ICU/OR (**Figure 1**)
2. Is there adequate central vein access
3. Will the patient be extubated? Is it acceptable to disconnect the ventilator and leave the tube-suspected difficult intubation?
4. Will they leave the NG/OG on suction?
5. What is the institution policy after withdrawal-certification; when can the team start-quiescent period?
6. Will they permit bronch prior to withdrawal?
7. How much heparin is being given? Is it at least 30,000 units. If not then plan to add 50,000 units into the first bag of perfadex.
8. When is the heparin being administered? Ideally it should be at least 3–5 minutes prior to withdrawal of life support.
9. Are there at least 2 wide bore functioning suctions available and adequate amount of soft slush available?
10. Does the center have a functioning sternal saw and chest spreader- preferably a transplant spreader (one with spikes)

For the actual withdrawal of life support, it is preferable to have 2 surgeons on the lung procurement team. Withdrawal is initiated by removal of the endotracheal tube, however in some cases when there is extensive airway edema due to potential difficulty in securing airway, the ventilator is disconnected instead after discussion with the anesthesiology team.

Of note, it is important to have the nasogastric tube (NG) maintained on continuous suction during the withdrawal of life sustaining therapy. This action prevents aspiration of gastric contents and facilitates dissection near the esophagus [20]. It is also important to communicate the importance of the NG to the anesthesia team before extubating. The surgical team is then scrubbed and ready in the adjacent operating room or sterile corridor. The patient is prepped and draped in sterile fashion with a hand being left out for the family if they are coming into the operating

room to pay their last respects. A sterile sleeve is made available for the stethoscope usage to auscultate and declare death. The flush solution is prepared by injecting prostaglandin into the first bag of Perfadex [21]. The lines are then passed off the

DCD Organ Procurement Phases

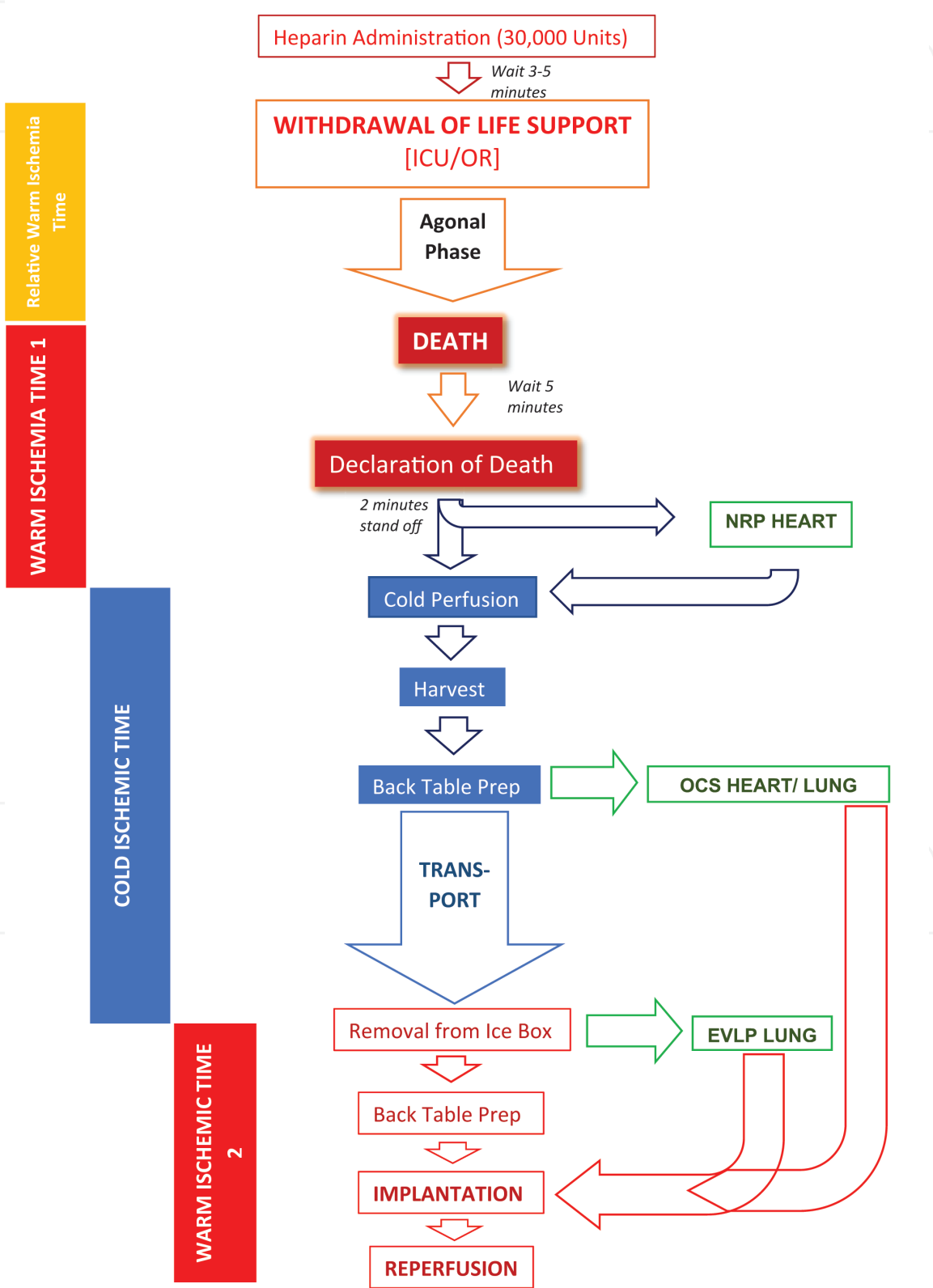


Figure 1. DCD-Donation after circulatory death, ICU-Intensive care unit, OR-Operating Room, NRP-Normothermic Regional Perfusion, OCS-organ Care system, EVLP-Ex-vivo lung perfusion.

sterile field, hung on the IV pole, and then accessed. Alternatively, the flush bags can be kept in the ice box at the side of the table after being reconstituted and spiked.

Death is declared as per local hospital protocol. The patient is then re-intubated. Median sternotomy is performed, and the pericardium is opened by pick up technique with forceps and scissors. (Please note that there is no bovie used during a DCD procurement!) The IVC is then vented by partial transection in a location previously discussed with the liver procurement team.

At this juncture the Liver team is frantically trying to clamp the descending thoracic aorta in the chest if they do not have access below the diaphragm. The thoracic team can help by quickly opening the left pleura, releasing the inferior pulmonary ligament, mobilizing the lung, then looping the descending thoracic aorta bluntly and helping to place the cross clamp so that they can start perfusing the abdominal organs. We can then focus on perfusing the lungs.

8. Techniques of pulmonary artery flush

1. Often times we have found in our experience that it is easy to use a straight, stiff cannula (a femoral arterial cannula) especially when there is a single surgeon or there is insufficient help. Using a #15 blade a small nick is made in the RVOT just enough to permit the cannula entry and the cannula is introduced into the PA after advancing across the pulmonary valve. This effectively delivers equitable antegrade PA flush and obviates the need for a purse string and effectively holds the cannula in place.
2. When qualified help is available, a 4-0 Prolene purse string suture is placed on the main pulmonary artery just below the bifurcation/more towards the RVOT. Using a #11 blade an arteriotomy is performed. This is then gently dilated with a tonsil/Schnitz and a right angled/straight cannula is inserted. If angled, then ensure the bevel is pointing towards the pulmonary valve. The cannula is connected to the Perfadex flush solution. The ascending aorta is cross clamped, the left atrial appendage is amputated and 60-70 ml/kg of Perfadex is then infused in antegrade fashion. Both pleural cavities are widely opened bluntly with fingers and the chest cavity packed with soft ice. After the patient is re-intubated by the Anesthesiology team/second surgeon, the lungs are then ventilated with tidal volume of 6-8 cc/kg and FiO_2 of 50%. The second surgeon then proceeds with bronchoscopy while the first surgeon continues with the flush. If only one surgeon is available, then take this time to re-intubate. Proceed to then ventilate and bronch while the flush runs and the chest is adequately packed in ice.

Following instillation of the Perfadex solution, the cannula is removed. The lungs are then recruited with Valsalva maneuver at 30 cm H₂O and both lungs are sequentially examined in standard fashion. The heart is then excised in standard fashion. In certain instances, there is consent for homograft valves and sufficient care needs to be exercised while excising the heart to preserve the valves [22].

Next, dissection begins first by dividing the inferior pulmonary ligament (bilateral) and the posterior pericardium. The main and right pulmonary artery are dissected away from the aorta. Bilaterally, the inferior pericardium is then divided at the level of the esophagus. Then the posterior pericardium is divided in a horizontal fashion just above the esophagus to the level of the pulmonary veins. The aortic arch is then transected. The superior aspect of the arch is then exposed and divided as distal as possible along the arch vessels so that a portion of the wall of the arch and descending aorta are left as a cuff to prevent dividing the ligamentum arteriosum.

Attention is then turned to the trachea which is isolated just above the carina with blunt dissection. A TA-30 stapler is passed around the trachea 3 rings above the carina [23]. The lungs are inflated to 60% tidal volume-to avoid baro-trauma (especially if the lungs are being flown back to the recipient institution), and the endotracheal tube is withdrawn. The stapler is used to divide the trachea. The lung bloc is removed from the donor after division of any remaining attachments.

The lung bloc is taken to the back table. Retrograde flush is performed at 250–500 cc/vein x4. If lot of clots/thrombi are seen exiting the PA during retro flush one can take a call regarding quality (small clots are not uncommon).

The double lung bloc is then examined for compliance, color, any areas of inadequate perfusion, atelectasis etc. (refer to DBD procurement of lungs section). Once the procurement surgeon is satisfied that the lungs are suitable for transplantation the recipient surgeon is called, and if accepted the lungs are then split on the back table and packed in standard fashion. The main PA is divided at the insertion site of the pulmonary artery cannula. The atrial cuff is then created approximately 1 cm from insertion of the pulmonary veins into the left atrium. The atrium is then divided in the midline with scissors. The left mainstem bronchus is divided with a TA-30 stapler near the hilum. An additional liter of cold Perfadex solution is instilled bilaterally via the pulmonary veins with a balloon catheter. The lungs are packed first in a bag containing Perfadex, followed by 2 bags containing ice cold saline slurry. The organs are subsequently transported to their respective transplant centers.

8.1 If only 1 surgeon performing procurement

If only 1 surgeon is available on the procurement team, the steps occur as described until flush occurs with the Perfadex solution. The chest is then packed with ice and ventilation continues. The lung procurement surgeon will scrub out. The surgeon will then along with the anesthesia team intubate the patient, perform bronchoscopy, and initiate ventilation. The surgeon will then scrub back in and continue to harvest in the previously described fashion.

8.2 DCD heart only placed for transplantation (OCS)

The process of DCD heart only procurement with Organ care system (OCS) is a relatively new technology, which will be discussed in this section. For this procedure, it is very important to ensure that two surgeons are present as part of the procurement team. The reason for this will become more relevant as the discussion of the technique ensues. After the patient's hemodynamic status, drips, lactates, troponins, echo, and other vital parameters have been checked out the procurement team proceeds to the donor center and there the traditional checklist is followed. These include (but are not limited to) the blood groups and that the UNOS IDs being checked. At that point, the procuring team and the local organ procurement organization (OPO for short) will familiarize themselves with the local institutional/hospital protocol. The donor team will park the Transmedics-organ care system (OCS) in one of the corners of the operating room, plug in the power, ready the equipment and will ensure that every object, instrument, and machine is given a green signal for the procedure. The patient is prepped and draped in sterile fashion and all lines are passed off. The cardioplegia is spiked and ready to be infused at short notice. We make sure that there is a functioning sternal saw, a sternal retractor and the appropriate aortic cross-clamp. Lastly, we ensure there are 2 working and connected suctions.

About 3–5 minutes before withdrawal of care, 30,000 units of heparin are given intravenously into a central vein in the donor. The donor procurement team will then scrub in and be ready while they wait in the sterile corridor. Upon withdrawal of life

support the OPO coordinator will communicate the hemodynamic status of the donor (which is the arterial blood pressure and pulse oximeter) to the team at every 5 minutes intervals. For the DCD heart while there is no set or accepted timing. From what we have seen generally, 18–23 minutes of waiting time is acceptable. Beyond this time, the heart team deems that there has been a prolonged ischemia phase. Hence, the wait time is limited to 23 minutes. In totality, the mandatory 5 minutes after cessation of electrical activity (before the patient was pronounced) and the 1–2 minutes time before the team is permitted to start brings the total time to around 30 minutes. This is the time interval beyond which the cardiac team would walk. The liver team generally waits for 30 minutes while the lung team has a more permissive waiting period of up to 60 minutes.

Then the surgical team comes in, with all their instruments already on a side table right next to the operating table. Using a knife, an incision is made all the way down to the bone. The next item is the sternal retraction. Once the sternotomy is done, the retractor is placed, and the pericardium is opened in the midline using forceps and a scissor. The heart is exposed at that point and the right atrium is cannulated with a 32 French venous cannula and this is then connected to that blood collecting bag which was handed off to the perfusion team member. He/she will then collect 1100 cc of blood at least (800–1100 cc of blood from the donor will be collected).

In the meantime, a purse-string on the aorta and a cardioplegia needle is placed in the ascending aorta. Once we have completed blood collection, the aorta is cross-clamped, and we then infuse cardioplegia in standard fashion. We give 2 L of cardioplegia into the aortic root and we then packed the chest with ice. The IVC is vented and from that point on the tip of the left atrial appendage is also amputated. From that point on the procurement proceeds in standard fashion. The IVC is incised at the point where the liver team and the cardiac team agree to. Once the cardioplegia is completed, the pulmonary veins are anterior rated, the IVC transaction is completed, the pulmonary arteries are divided beyond the bifurcation of the IO at the level of the aortic arch. The SVC is divided as high as possible above the level of the azygos vein and the heart is finally explanted and is then taken onto the back table. There, instrumentation is done to place the heart on the OCS machine. We will encourage readers look for that part of the information as it is beyond the purview of this chapter.

9. Bronchial artery revascularization

Bronchial Artery Revascularization has been done to alleviate the Achilles heel of lung transplantation which bronchial healing. This has been an area of intense focus especially since the early issues that lung transplantation had with tracheal dehiscence and bronchial dehiscence. However, it is very labor intensive and has not taken off as a major standard of practice yet. There are a few proponents of this technique who have shown excellent results [24]. One of these groups is the Cleveland Clinic, championed by Prof. Gosta Pettersson who has worked on it for a long time since his days in Denmark. He has trained several surgeons in the Cleveland Clinic with this approach [25].

As one is aware, the lung has dual blood supply. One is from the bronchial arteries and one is from the pulmonary arteries. The major idea of the BAR procedure is to procure the lungs as we normally do, but to also retain the bronchial arteries from their origins in the aorta. In order to achieve this, the lungs are removed en bloc with the trachea intact like they are in a standard procedure, except this time the thoracic esophagus and descending aorta accompany them as well. This way, the RICBA and left bronchial arteries are included.

After IV heparin administration, the donor aorta is cross clamped and cold lung perfusate is administered via the PA. Normally we flush the lungs with 4–6 L of perfadex. 4 Liters are used for antegrade perfusion and then 1 Liter perfadex for retrograde

perfusion on the back table. One liter of perfedex must be infused into the descending aorta. A cross clamp should be put on the aortic arch to keep the solution from escaping. This ensures perfusion of the bronchial arteries which come off the descending thoracic aorta. The NG tube is pulled back (but not all the way, because it is still important to keep it in the esophagus) before stapling the esophagus off- this is to ensure the NG tube is not stapled inside the esophagus. Then one must go around to the aorta and transect it at the level of the diaphragm. To prevent spillage the esophagus must be also be stapled off as high as possible at the neck. Keep in mind that one must try to minimize the dissection around the trachea. The trachea is also stapled off as high as possible [24].

Finally, the double lung bloc and its accompanying tissue is excised from the donor while moving cranially. Be sure to include the paraspinal tissue as well to minimize any possibility of injury to the bronchial arteries. The PA is divided near its bifurcation, and sufficient left atrial cuff is harvested in standard fashion.

After arrival in the recipient operating room, the esophagus is separated on the back table. After the esophagus is removed, the descending aorta is opened vertically in the midline and the bronchial arteries identified. The surgeon must locate the RICBA and the left bronchial artery. The use of a coronary probe can help in this matter. The RICBA is identified in the right. On the right, once the RICBA is identified, clips are applied to its intercostal branch. The left bronchial artery (or arteries) is/are identified with probing if needed. On either side, a single bronchial artery of reasonable size is usually sufficient for complete revascularization. However, if a convincing bronchial artery is not identified or if an important bronchial artery is damaged, BAR should be aborted and standard bilateral sequential LTx should be performed [24].

Author details

Suresh Keshavamurthy^{1*}, Vipin Dulam², Eros Leotta³, Mohammed A. Kashem³ and Yoshiya Toyoda³

1 Division of Cardiothoracic Surgery, Department of Surgery, University of Kentucky College of Medicine, Lexington, KY, USA

2 Lewis Katz School of Medicine, Philadelphia, PA, USA

3 Division of Cardiovascular Surgery, Department of Surgery, Temple University Hospital, Philadelphia, PA, USA

*Address all correspondence to: suresh.keshavamurthy@uky.edu

IntechOpen

© 2021 The Author(s). Licensee IntechOpen. This chapter is distributed under the terms of the Creative Commons Attribution License (<http://creativecommons.org/licenses/by/3.0>), which permits unrestricted use, distribution, and reproduction in any medium, provided the original work is properly cited. 

References

- [1] Mooney, Jj., Medlin H, Mohabir PK et al. "Donation After Circulatory Determination of Death Donor Characteristics and Lung Donor Utilization Within the United States." *The Journal of Heart and Lung Transplantation*, vol. 34, no. 4, 2015, doi:10.1016/j.healun.2015.01.785.
- [2] Salim A, Vassiliu P, Velmahos GC, et al. The Role of Thyroid Hormone Administration in Potential Organ Donors. *Arch Surg*. 2001;136 (12):1377-1380. doi:10.1001/archsurg.136.12.1377
- [3] Sudhir Sundaresan, MD, Gregory D. Trachiotis, MD, Motoi Aoe, MD, G. Alexander Patterson, MD, and Joel D. Cooper, Donor Lung Procurement: Assessment and Operative Technique MD Division of Cardiothoracic Surgery, Department of Surgery, Washington University School of Medicine, Barnes Hospital, St. Louis, Missouri
- [4] Tyrak KW, Holda J, Holda MK, Koziej M, Piatek K, Klimek-Piotrowska W. Persistent left superior vena cava. *Cardiovasc J Afr*. 2017;28(3):e1-e4. Published 2017 May 23. doi:10.5830/CVJA-2016-084
- [5] Kurtoglu E, Cakin O, Akcay S, Akturk E, Korkmaz H. Persistent Left Superior Vena Cava Draining into the Coronary Sinus: A Case Report. *Cardiol Res*. 2011;2(5):249-252. doi:10.4021/cr85w
- [6] Copeland, H., Hayanga, J.W.A., Neyrinck, A., Macdonald, P., Dellgren, G., 2020. Donor heart and lung procurement: A consensus statement. *The Journal of Heart and Lung Transplantation*.. doi:10.1016/j.healun.2020.03.020
- [7] Erwan Flécher, Olivier Fouquet, Vito Giovanni Ruggieri, Céline Chabanne, Bernard Lelong, Alain Leguerrier, Heterotopic heart transplantation: where do we stand?, *European Journal of Cardio-Thoracic Surgery*, Volume 44, Issue 2, August 2013, Pages 201-206, <https://doi.org/10.1093/ejcts/ezt136>
- [8] Michel S.G., LaMuraglia G.M., Madariaga M., Anderson L.M. (2015). Innovative cold storage of donor organs using the Paragonix Sherpa Pak™ devices. *Heart, Lung and Vessels*, 7, 246-255.
- [9] Kumar C.M., Van Zundert A.A.J. Intraoperative Valsalva maneuver: a narrative review. *Can J Anesth/J Can Anesth* 65, 578-585 (2018). <https://doi.org/10.1007/s12630-018-1074-6>
- [10] Lopes JB, Santos CCMD Júnior. Coronary Perfusion Pressure during Antegrade Cardioplegia in On-Pump CABG Patients. *Braz J Cardiovasc Surg*. 2017;32(3):171-176. doi:10.21470/1678-9741-2017-0035
- [11] Katona A, Temesvári A, Szatmári A, Nemes A, Forster T, Fontos G. Left circumflex coronary artery occlusion due to a left atrial appendage closure device. *Postepy Kardiol Interwencyjne*. 2015;11(1):69-70. doi:10.5114/pwki.2015.49192
- [12] McAlpine WA. Heart and Coronary Arteries. Berlin/Heidelberg: Springer-Verlag; 1975:58-59.
- [13] Hayama M, Date H, Oto T, Aoe M, Andou A, Shimizu N. Improved lung function by means of retrograde flush in canine lung transplantation with non-heart-beating donors. *J Thorac Cardiovasc Surg*. 2003 Apr;125(4):901-6. doi: 10.1067/mtc.2003.296. PMID: 12698154.
- [14] Vigneswaran, W. (Ed.), Garrity, E. (Ed.), Odell, J. (Ed.). (2016). Lung Transplantation. Boca Raton: CRC Press, <https://doi.org/10.1201/b19234>

- [15] Lund LH, Khush KK, Cherikh WS, Goldfarb S, Kucheryavaya AY, Levvey BJ, et al. The Registry of the International Society for Heart and Lung Transplantation: Thirty-fourth Adult Heart Transplantation Report-2017; Focus Theme: Allograft ischemic time. *J Heart Lung Transplant*. 2017;36(10):1037-46
- [16] Griffith BP, Magliato KE. Heart-lung transplantation. Operative Techniques in Thoracic and Cardiovascular Surgery. 1999;4(2):124-41
- [17] Rao V, Dhanani S, MacLean J, et al. Effect of organ donation after circulatory determination of death on number of organ transplants from donors with neurologic determination of death. *CMAJ*. 2017;189(38):E1206-E1211. doi:10.1503/cmaj.161043
- [18] Keshavamurthy S, Murthy SC, Pettersson GB, Mason DP. Lungs from donation after cardiac death for transplantation. *Eur J Cardiothorac Surg*. 2013 Jul;44(1):189. doi: 10.1093/ejcts/ezs696. Epub 2013 Jan 15. PMID: 23321432.
- [19] Machuca TN, Cypel M. Ex vivo lung perfusion. *J Thorac Dis*. 2014;6(8):1054-1062. doi:10.3978/j.issn.2072-1439.2014.07.
- [20] Metheny NA, Clouse RE, Chang YH, Stewart BJ, Oliver DA, Kollef MH. Tracheobronchial aspiration of gastric contents in critically ill tube-fed patients: frequency, outcomes, and risk factors. *Crit Care Med*. 2006;34(4):1007-1015. doi:10.1097/01.CCM.0000206106.65220.59
- [21] Salizzoni S, Toyoda Y. Effects of Prostaglandin E1 and Nitroglycerin on Lung Preservation In: Principles of Pulmonary Protection in Heart Surgery. Springer London; 2010:81-89. Doi: 10.1007/978-1-84996-308-4_9
- [22] Herreros JM, Mastrobuoni S, Ubilla M, Rábago G, Lorente Ruiz M, Rifón J, Hernández M. Trasplante de homoinjertos valvulares cardiacos y vasculares [Cardiac and vascular homograft valves transplant]. *An Sist Sanit Navar*. 2006;29 Suppl 2:153-61. Spanish. PMID: 16998523.
- [23] Chekan E, Whelan RL. Surgical stapling device-tissue interactions: what surgeons need to know to improve patient outcomes. *Med Devices (Auckl)*. 2014;7:305-318. Published 2014 Sep 12. doi:10.2147/MDER.S67338
- [24] Yun JJ, Unai S, Pettersson G. Lung transplant with bronchial arterial revascularization: review of surgical technique and clinical outcomes. *J Thorac Dis*. 2019;11(Suppl 14):S1821-S1828. doi:10.21037/jtd.2019.09.09
- [25] Pettersson GB, Karam K, Thuita L, Johnston DR, McCurry KR, Kapadia SR, Budev MM, Avery RK, Mason DP, Murthy SC, Blackstone EH. Comparative study of bronchial artery revascularization in lung transplantation. *J Thorac Cardiovasc Surg*. 2013 Oct;146(4):894-900.e3. doi: 10.1016/j.jtcvs.2013.04.030. Epub 2013 Jun 29. PMID: 23820173.