

We are IntechOpen, the world's leading publisher of Open Access books Built by scientists, for scientists

6,900

Open access books available

186,000

International authors and editors

200M

Downloads

Our authors are among the

154

Countries delivered to

TOP 1%

most cited scientists

12.2%

Contributors from top 500 universities



WEB OF SCIENCE™

Selection of our books indexed in the Book Citation Index
in Web of Science™ Core Collection (BKCI)

Interested in publishing with us?
Contact book.department@intechopen.com

Numbers displayed above are based on latest data collected.
For more information visit www.intechopen.com



Introductory Chapter: Endoscopy in Small Bowel Diseases

*Usha Goenka, Gajanan Ashokrao Rodge
and Mahesh Kumar Goenka*

1. Introduction

The small bowel diseases are known to pose a diagnostic challenge for the clinicians in a day-to-day practice. Different small bowel pathologies can broadly be divided as vascular, inflammatory or neoplastic disorders. The most common indication for imaging of small bowel in clinical practice is obscure gastro-intestinal (GI) bleeding. Other indications for small bowel evaluation include Crohn's disease, tuberculosis, NSAID induced ulcers, small bowel malignancies, polyposis syndromes and malabsorptive disorders.

The routine means of endoscopic evaluation in the form of upper gastro-intestinal (GI) endoscopy and lower GI endoscopy limit the assessment of GI tract upto the duodenum and ileum respectively. The small bowel was initially out of reach for the diagnostic and therapeutic endoscopy procedures. In 1982 Shinya first reported the use of push enteroscopy and described finding of a small bowel tumour [1]. Use of push enteroscopy was later reported in different studies in the subsequent years [2–4]. Later came the sonde (French word for probe) enteroscopy which involves passage of a thin trans-nasal endoscope with a hood or balloon on its tip that is dragged distally by peristaltic movements of the intestine. It took a period of 13 years for its development [5]. Lewis et al., reported the use of sonde enteroscopy and found the small bowel bleeding site in 33% of patients who presented with obscure GI bleeding (60 patients) [6]. However due to the disadvantages as requirement of longer time, limited passage in presence of adhesions, strictures, and motility disturbances it was later found to be inefficient and lost its popularity.

Barium imaging and computed tomography (CT) scans were the mainstay of small bowel imaging till the year 2000. The innovation of wireless capsule endoscopy has revolutionised the small bowel imaging and has made its own place in the diagnostic algorithm for various small bowel diseases. A randomised trial comparing wireless capsule and push enteroscopy for detecting small bowel lesions in nine canine small bowels showed that the capsules significantly performed better than push enteroscopy [7]. Subsequent studies also showed that capsule endoscopy had higher diagnostic yield and was better than push enteroscopy in patients with chronic GI bleeding [8]. Even in today's date video capsule endoscopy plays an important role in the diagnosis of small bowel diseases. However, the disadvantage lies in the inability to sample small bowel mucosa and perform therapeutic interventions.

Hironori Yamamoto introduced the technique of double balloon enteroscopy (DBE) and showed that the double balloon method facilitates passage of endoscope to the small intestine. This advent of DBE was a major breakthrough for the diagnosis and treatment of small bowel disorders [9]. Single-balloon enteroscopy

(SBE) was later introduced in a couple of years [10]. The advantage of SBE was that it is technically easier to perform compared to DBE. Spiral enteroscopy (SE) was introduced in 2008 which was a similar technique for deep small-bowel intubation that used a spiral overtube to plect the bowel loops of small intestine [11]. The various device assisted techniques have been compared in a metaanalysis by Gu Y, et al. [12]. DBE and SBE had similar clinical outcomes and SE also showed comparable diagnostic and therapeutic yields with DBE. SBE had a shorter procedure time at the cost of less depth of insertion when compared with DBE.

The latest innovation of the motorised spiral enteroscopy (MSE) looks promising. Neuhaus H et al., initially reported the technique and clinical use of the novel MSE [13]. It evaluates the small bowel in a controlled manner, gives a good diagnostic yield, requires less time and has proven to be safe in the published studies. The first prospective clinical feasibility study has been recently published and has shown promising results [14]. Subsequent studies and case reports have shown the use of MSE for diagnosis and treatment of small bowel lesions [15, 16]. **Figure 1** shows the timeline of development of different techniques in small bowel endoscopy.

This book will give a detailed overview regarding the different techniques of small bowel endoscopy such as device assisted enteroscopy, capsule endoscopy, etc. Role of endoscopy in diseases of small bowel such as Inflammatory Bowel Disease (IBD) is discussed in separate chapters. We also have a chapter “Role of Imaging in small bowel Crohn’s disease” which discusses the different radiological investigations like barium studies, CT scan and Magnetic Resonance Imaging in patients with IBD.

The different aspects of intra-operative endoscopy and its role in the management of small bowel diseases have been emphasised in a separate chapter. All procedures have some complications and similarly perforation in the small bowel is a possible complication of small bowel endoscopy. Early recognition is the key and so we have a chapter on “Early recognition and management of small bowel perforation”. The role of endoscopic ultrasound (EUS) is also now well established in the field of gastroenterology with many applications. This book includes a chapter on “Role of EUS in assessment of duodenal wall lesion”.

The book has been written by experts in the respective fields and we hope it will prove to be a valuable resource for all the training and practising gastroenterologists, physicians and surgeons who are looking for a composite overview of endoscopy in small bowel diseases.

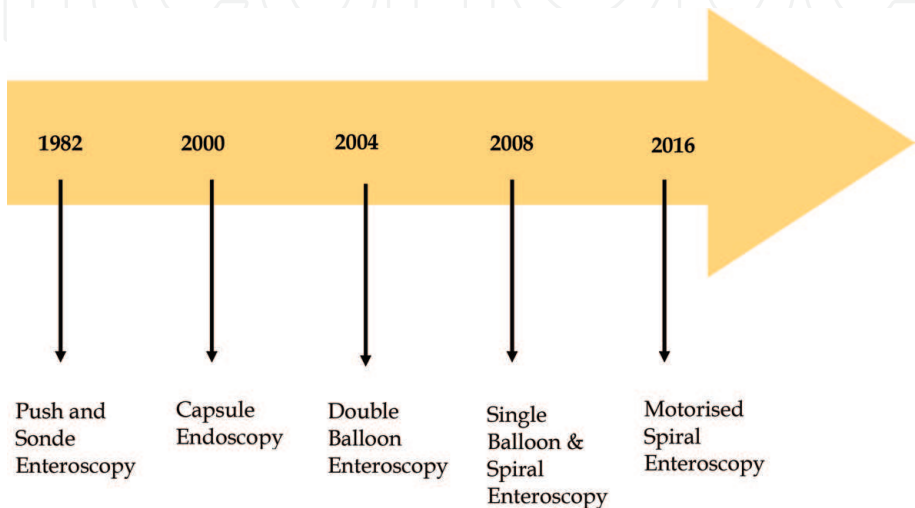


Figure 1.
The timeline changes in development of small bowel endoscopy.

IntechOpen

Author details

Usha Goenka¹, Gajanan Ashokrao Rodge² and Mahesh Kumar Goenka^{2*}

1 Department of Interventional Radiology and Clinical Imaging, Apollo Gleneagles Hospital, Kolkata, India

2 Institute of Gastrosiences and Liver, Apollo Gleneagles Hospital, Kolkata, India

*Address all correspondence to: mkgkolkata@gmail.com

IntechOpen

© 2021 The Author(s). Licensee IntechOpen. This chapter is distributed under the terms of the Creative Commons Attribution License (<http://creativecommons.org/licenses/by/3.0>), which permits unrestricted use, distribution, and reproduction in any medium, provided the original work is properly cited. 

References

- [1] Shinya H, McSherry C. Endoscopy of the small bowel. *Surg Clin North Am*. 1982;62:821-824.
- [2] Parker H, Agayoff J. Enteroscopy and small bowel biopsy utilizing a peroral colonoscope. *Gastrointest Endosc*. 1983;29:139-140.
- [3] Hashmi M, Sorokin J, Levine S. Jejunal leiomyoma: an endoscopic diagnosis. *Gastrointest Endosc*. 1985;31:81-83.
- [4] Shigematsu A, Iida M, Hatanaka M, et al. Endoscopic diagnosis of lymphangioma of the small intestine. *Am J Gastroenterol*. 1988;83:1289-93.
- [5] Tada M, Kawai K. Small bowel endoscopy. *Scand J Gastroenterol*. 1984;19 Suppl 102:39-52.
- [6] Lewis B, Wayne J. Gastrointestinal bleeding of obscure origin: the role of small bowel enteroscopy. *Gastroenterology*. 1988;94:1117-1120.
- [7] Appleyard M, Fireman Z, Glukhovsky A, et al. A randomized trial comparing wireless capsule endoscopy with push enteroscopy for the detection of small-bowel lesions. *Gastroenterology*. 2000 Dec;119:1431-1438.
- [8] Hartmann D, Schilling D, Bolz G, et al. Capsule endoscopy versus push enteroscopy in patients with occult gastrointestinal bleeding. *Z Gastroenterol*. 2003;41:377-382.
- [9] Yamamoto H, Kita H, Sunada K, et al. Clinical outcomes of double-balloon endoscopy for the diagnosis and treatment of small-intestinal diseases. *Clin Gastroenterol Hepatol*. 2004;2:1010-1016.
- [10] Kawamura T, Yasuda K, Tanaka K, et al. Clinical evaluation of a newly developed single-balloon enteroscope. *Gastrointest Endosc*. 2008;68:1112-1116.
- [11] Akerman PA, Agrawal D, Cantero D, Pangtay J. Spiral enteroscopy with the new DSB overtube: a novel technique for deep peroral small-bowel intubation. *Endoscopy*. 2008;40:974-978.
- [12] Gu Y, Shi X, Yang Y, et al. Single-balloon and spiral enteroscopy may have similar diagnostic and therapeutic yields to double-balloon enteroscopy: Results from a meta-analysis of randomized controlled trials and prospective studies. *World J of Meta-Anal*. 2020;8:153-162
- [13] Neuhaus H, Beyna T, Schneider M, Devière J. Novel motorized spiral enteroscopy: first clinical case. *Video GIE* 2016;1: 32-33.
- [14] Beyna T, Arvanitakis M, Schneider M, et al. Motorised spiral enteroscopy: first prospective clinical feasibility study. *Gut* 2020;0: 1-7.
- [15] Ramchandani M, Rughwani H, Inavolu P, et al. Diagnostic yield and therapeutic impact of novel motorized spiral enteroscopy in small-bowel disorders: a single-center, real-world experience from a tertiary care hospital (with video). *Gastrointest Endosc*. Epub. 2020.
- [16] Rodge GA, Ramchandani M, Shah BB, Afzalpurkar S, Raj DB, Goenka MK. Hemoclips during motorized spiral enteroscopy—A unique case. *Indian J Gastroenterol* (2020). <https://doi.org/10.1007/s12664-020-01097-w>