

We are IntechOpen, the world's leading publisher of Open Access books Built by scientists, for scientists

6,900

Open access books available

186,000

International authors and editors

200M

Downloads

Our authors are among the

154

Countries delivered to

TOP 1%

most cited scientists

12.2%

Contributors from top 500 universities



WEB OF SCIENCE™

Selection of our books indexed in the Book Citation Index
in Web of Science™ Core Collection (BKCI)

Interested in publishing with us?
Contact book.department@intechopen.com

Numbers displayed above are based on latest data collected.
For more information visit www.intechopen.com



Bleeding and Hysteroscopy in Uterine Myomatosis

*Sergio Rosales-Ortiz, Tammy Na Shieli Barrón Martínez,
Diana Sulvaran Victoria, Jocelyn Arias Alarcon,
Janeth Márquez-Acosta and José Fugarolas Marín*

Abstract

Uterine leiomyomas are one of the most common diseases in women. However, there is still much about them we do not know. These tumours, also known as fibroids or myomas, affect women mainly during their reproductive years, and they are diagnosed in up to 70% to 80% of women during their lives. The most relevant part of this disease is the profound impact in the quality of life of women, in the provision of health services, and on the costs all around the world. Even though, the majority of women with fibroids are asymptomatic, approximately 30% of them will present severe symptoms, with a broad range of problems such as: abnormal uterine bleeding, infertility, and obstetric complications. There are multiple factors involved in the biology of fibroids: genetic, epigenetic, hormonal, proinflammatory, angiogenic and growth factors, growth factors that are capable of inducing and promoting the development of fibroids. The leiomyoma is surrounded by a pseudocapsule generated by compression and ischaemia of the tumour towards the myometrium and is composed by multiple elements that promote healing and tissue repair of the myometrium after myomectomy. Therefore, its conservation in the myometrium is essential, regardless of the surgical technique used. Resection by hysteroscopy can be performed in an office or in an operating room, depending on the characteristics of the fibroid, it is required a good diagnosis and experience.

Keywords: bleeding, hysteroscopy, pseudocapsula, submucosa fibroids

1. Introduction

Uterine leiomyomas are one of the most common diseases in women. However, there is still much about them we do not know. These tumours, also known as fibroids or myomas, affect women mainly during their reproductive years, and they are diagnosed in up to 70% to 80% of women during their lives. The most relevant part of this disease is the profound impact in the quality of life of women, in the provision of health services, and on the costs all around the world.

Even though, the majority of women with fibroids are asymptomatic, approximately 30% of them will present severe symptoms, with a broad range of problems such as: abnormal uterine bleeding, infertility, and obstetric complications.

There are multiple factors involved in the biology of fibroids: genetic, epigenetic, hormonal, proinflammatory, angiogenic and growth factors, growth factors that are capable of inducing and promoting the development of fibroids.

The leiomyoma is surrounded by a pseudocapsule generated by compression and ischaemia of the tumour towards the myometrium and is composed by multiple elements that promote healing and tissue repair of the myometrium after myomectomy. Therefore, its conservation in the myometrium is essential, regardless of the surgical technique used.

Resection by hysteroscopy can be performed in an office or in an operating room, depending on the characteristics of the fibroid, it is required a good diagnosis and experience.

2. The relevant of fibroids

Abnormal uterine bleeding (AUB) refers to uterine bleeding that, by its characteristics in duration, volume, frequency, and regularity, are outside the 5th and 95th percentiles for the female population in reproductive age and non-pregnant. In such manner that range of variation in the menstrual bleeding pattern can be very wide affecting one or more characteristics at the same time.

The abnormal uterine bleeding is divided into acute and chronic — acute when, according to a medical evaluation, the amount of bleeding justifies an immediate intervention to avoid complications secondary to blood loss. It is defined as chronic when this symptom occurs persistently in last 6 months [1].

The widespread term of heavy menstrual bleeding, refers to a sub-category of AUB, and it refers to a subjective symptom expressed by the woman as the excessive loss of blood and impacts her physical, emotional and social well-being as well as her quality of life. This term moves away from an objective measurement of volume of more than 80 ml, or a specific score and focuses on the perception of the patient, therefore, it has a better clinical focus [2].

One important aspect of AUB is that it is one of the main causes for seeking gynaecological care among 5% and 30% of women in reproductive age, and approximately one third of that population will suffer from AUB at one moment in their lives, which represents high direct and indirect costs in their medical attention [3].

The aetiology of AUB is broad since various pathophysiological mechanisms are involved, requiring the physician to have an individualised approach and a clear understanding of the systematised study and treatment options.

In 2011, the International Federation of Gynaecology and Obstetrics (Fédération Internationale de Gynécologie et d'Obstétrique, FIGO), in contribution with a large group of clinical and non-clinical researchers of 17 countries of six continents, published a system and a set of clinical recommendations about AUB to provide a detailed update with the objective of standardising different terminologies and definitions used up to that date to refer to symptoms of altered menstrual bleeding and to establish a correlation with possible underlying causes, so as to facilitate research, education and standardised and replicable medical care [4].

An AUB classification was introduced, with nine categories based on the PALM-COEIN acronym, which divides causes into structural and non-structural pathologies.

Structural pathologies can be evaluated by imaging studies and/or defined histopathologically (polyps, adenomyosis, leiomyomas and malignancy or atypical endometrial hyperplasia: PALM).

Regarding non-structural causes, these cannot be detailed by means of imaging studies, these require a detailed clinical evaluation, and an appropriate physical examination supported by laboratory tests. In most cases, a diagnosis can be established, one which corresponds to the COEIN acronym (coagulopathy,

ovulatory dysfunction, primary endometrial dysfunction, iatrogenesis and not otherwise classified) [4, 5].

In 2018, FIGO recommendations were updated, including clarifications on terminologies and definitions, as well as modifications in the PALM-COEIN system which include the reassignment of some entities and orientation for subclasses of leiomyomas [5].

Leiomyomas are monoclonal tumours comprised of muscle tissue of the uterus, also referred in literature as fibroids or myomas. These represent the pelvic tumour, frequently benign, more common in women in reproductive age. At age 50, almost 70% of white women and 80% of African American women will have developed at least one fibroid [6].

There are many risk factors associated with myomatosis, and these are still being described. Among these: African American race, age, delayed pregnancy, nulliparity, early menarche, caffeine, genetic alterations, obesity, a diet rich in red meat and, recently discovered, the crucial role of progesterone and its receptors in pathophysiology, growth and development of these tumours [7, 8].

Even though myomatosis has a high prevalence in women, most of them are asymptomatic and are diagnosed as an incidental finding in a routine gynaecological examination. The main symptom of patients with leiomyomas is AUB, referred by women as profuse and prolonged bleeding, bleeding between periods, and frequent and irregular periods. These menstrual alterations are frequently used to being accompanied by the presence of pelvic tumours, dysmenorrhoea, chronic pelvic pain, infertility, compressive symptoms, and obstetric complications.

Other relevant aspects in the detriment of the quality of life of women with myomatosis are a negative impact in their sex life (42.9%), bad performance at work (27.7%), and impaired couple and family relations (27.2%). In this way, a third of women with leiomyomas will seek medical attention. Symptomatic cases will depend on size, number, and localisation of these [7, 9].

Several uterine fibroids classifications have been described. Most of them have considered the degree of extension in the myometrium and/or the distortion of the uterine cavity. Currently, this has changed, and several factors are considered in order to establish a better therapeutic approach, its possibility of success, the complete removal of fibroids and lower risk of complications.

The classification adopted by the ESGE (European Society for Gynaecological Endoscopy) based on Wamsteker's, proposes a classification of submucous fibroids according to the depth within the myometrium, classified as: G^{-0} is an intrauterine pedunculated fibroid, $G-1$ fibroid is majorly in the uterine cavity or has less than 50% of penetration inside of myometrium, and $G-2$ is mostly ($> 50\%$) inside of the myometrium [10].

The classification proposed by Lasmar, takes into consideration, the depth of the fibroid in addition to other characteristics such as size, placement inside of the cavity, the extension of the injury in the endometrium, and the uterine wall involved, granting a rating that gives a prognosis on the difficulty or complexity of the removal, as well as the therapeutic options for its management (**Figure 1**) [11].

Another classification that also gives a rating according to size, localization, myometrium penetration and base extension is the STEPW classification. (**Figure 2**).

The FIGO classification considers any location of the fibroids and describes eight types, as well as a hybrid class (an association of two types of fibroids). It is common for different types of fibroids to be present at the same time (depending on the site), and with this classification, a more representative "map" of the distribution of the fibroids can be made. However, this classification can have difficulties when applied to very big uteri and with multiple fibroids.

SCORE	GROUP	Complexity and treatment options
0-4	I	Low complexity. Hysteroscopic myomectomy.
5-6	II	High complexity. Hysteroscopic myomectomy, consider the use of GnRH, o resectoscopy in two steps.
7-9	III	Consider other alternatives to hysteroscopic technique.

Figure 1.
Lasmar classification.

Size (cm)	SC	Topography	SC	Extension of the base	SC	Penetration	SC	Wall	SC
<2	0	Lower third	0	<1/3	0	0	0	Fibroid in the lateral wall	Plus one to SC total
>2.1-5	1	Middle third	1	1/3 to 2/3	1	<50%	1		
>5.1	2	Upper third	2	>2/3	2	>50%	2		

Figure 2.
Adapted of STEPW classification. SC: Score. Size: Larger diameter by any image study. Topography: It refers to where the fibroid is placed in the uterus. Extension of the base: How much of the uterine wall is covered by the fibroid compared to thirds. Penetration: Depth of the fibroid within the myometrium. Wall: When the fibroid is in the lateral wall, add one point to the total score.

The FIGO classification updated in 2018 is as follows:

Submucous fibroids — those located exactly below the endometrium and that protrude, disrupting the uterine cavity in different degrees are types 0, 1, 2 and 3.

Type 0: Pedunculated or with its base on the endometrial wall, but the fibroid is completely located inside of endometrial cavity.

Types 1 and 2 require that a portion of the injury is intramural (Type 1 < 50% of the average diameter and Type 2 > 50%).

Type 3 are completely intramural but are also in contact with the endometrium. Type 3 formally distinguishes itself of Type 2 by means of a hysteroscopy, using the lowest intrauterine pressure possible to allow visualisation.

Intramural fibroids (Type 4) are completely located inside of the myometrium without protruding into the endometrial nor the serosal surface.

Subserosal fibroids (Types 5, 6 and 7) represent the mirror image of the sub-mucousal ones — type 5 with more than 50% of intramural penetration, type 6 less than 50% intramural and type 7 is attached to the serosal surface by a stalk.

In another place (Type 8): The localization must be specified, for example: cervical, intraligamentary, and so on.

Hybrid or transmural fibroids are classified by their relation to the endometrial and serosal surfaces. In these cases, one must refer first to the portion that is in contact with the endometrium [4, 5, 12].

3. The relation between the fibroid and the bleeding

The relationship between AUB and uterine myomatosis is still not fully understood, and there is a contradiction that many women with fibroids have a completely normal bleeding pattern. However, a clear relation between AUB and

submucousal fibroids is observed in the context of the degree of distortion and penetration into the uterine cavity that can generate submucousal fibroids and the possible occurrence of AUB. According to literature, fibroids (FIGO 0, 1, 2 y 3) are the most symptomatic [7].

Diverse mechanisms have been proposed to explain the relationship between the AUB caused by myomatosis, however, these do not explain clearly how all these facts are intimately involved.

Previously, the most described mechanisms were the increase in the endometrial surface and the presence of fragile and congested vascularity around the perimyome, currently, it is believed that the effect of fibroids on the endometrial function represents a change in the surface inside of the uterine cavity that is not limited to areas that cover the fibroid or fibroids. Some of these changes can have an impact in the responsiveness and endometrial implantation, as well as in AUB.

An increase in uterine vascularity with larger calibre vessels that can overcome the action of platelets has also been proposed. As well as changes in the patterns of myometrial contractility, ulceration of the surface of the fibroid, degeneration of the fibroid and venous ectasia by due to of compression of the fibroid [3, 13].

In recent years, more knowledge has been gained about complex the cellular and molecular changes associated with fibroids and the AUB, with an impact in angiogenesis, alteration of vasoactive substrates and growth factors, as well as alterations in coagulation, that highlight complex interactions among coagulation, neoangiogenesis and vasoconstriction [14].

Fibroids will behave as one independent functional unit with the capacity to secrete different bioactive factors, which generate changes in situ and produce an effect on the uterus. One of these changes is the increase in the secretion of TGF- β 3 (transforming growth factor beta 3), which is involved in the alteration of the homeostatic and fibrinolytic normal pathways in the endometrium since it reduces the plasminogen activator-1 (PAI-1), thrombomodulin and antithrombin III, which could explain one of mechanisms associated with AUB — an increased quantity of TGF- β has also been related to the remodelling and proliferation of extracellular matrix that could modulate the growth of fibroids [1, 15].

Regarding the causes related to the increased in bleeding in women with fibroids, different angiogenic factors have been described, such as the vascular endothelial growth factor (VEGF), basic fibroblast growth factor (bFGF), heparin-binding epidermal growth factor (HB-EGF), platelet-derived growth factor (PDGF), parathyroid hormone-related protein (PTHrP) and prolactin [2, 14].

On the other hand, there is an alteration of endothelin-1 (ET-1) and prostaglandin F2 alpha (PGF2 α), both strong vasoconstrictors that intervene in the amount of menstrual bleeding by regulating the contractility of the myometrium and the vasoconstriction of the spiral artery (ET-1) [16].

4. Endometrial changes

Understanding changes generated by fibroids at the endometrial level is very complex, since it is not only a physical effect on the anatomy of the uterus exerted by intramural and submucosal fibroids, but a significant effect in the endometrial physiology and the expression and function of endometrial genes [17].

An important phenomenon to understand endometrial changes, is inflammation. It is well established that an inflammatory component is involved in most physiological processes, specifically in the reproductive process, inflammation has direct interference with follicular development, ovulation, implantation, pregnancy, labor, and menstruation are not exempt.

Inflammation is understood as the presence of leukocytes (immune cells) of different within the reproductive tract tissue, without being associated with an infectious process. This invasion of leukocytes alters function by having specific role in local regulation.

Specific sequential changes in different kinds of leukocytes can be proven inside of the human endometrium during the different phases of normal and abnormal menstrual cycles. Leukocytes are very scarce in number throughout the proliferative phase, but significantly increase all through the secretory phase, taking into consideration that around 40% of all stromal cells in the premenstrual phase are leukocytes, mostly natural killer cells (NK) and granulocytes.

The decrease in progesterone increases the expression of inflammatory mediators, including IL-8, MCP-1 and nitric oxide which promote the recruiting of endometrial leukocytes. Macrophages and neutrophils are important in the defence of the epithelium when the epithelial barrier is broken because of any reason, for example, menstrual bleeding.

Leukocytes also have the potential to release regulatory molecules that stimulate the mechanisms of endometrial repair, consequently, so the alteration of immune cells and cytokine mediators are related to the symptoms of abnormal uterine bleeding and pelvic pain, always starting from the inflammatory process produced by the menstrual cycle, fibroids, and endometriosis among other pathologies [18, 19].

Besides endometritis and endometrial micro-erosions, vascular alterations are another important factor in the causes of bleeding and endometrial alterations [20].

From the complex onset of fibroid tumorigenesis, induced among others by the t (12-14) translocation, the deletion of 7q, HMGA₂ gene of the locus 12q14-q15, that, under the oestrogen-progesterone promoter stimulus, the micro-environment, growth factors with mitotic activity such as growth factor 3, fibroblast growth factor, epidermal growth factor, and insulin-like growth factor, besides promoting tumour growth, are leukocyte chemoattractants, generating an accumulation of inflammatory cells inside of the fibroid tissue and the corresponding endometrium that could affect the function from menstruation to fertility [21, 22].

Another aspect related to leukocytes is the relation between the vascular endothelial growth factor (VEGF) of intravascular neutrophils and the proliferation of endometrial cells from the subendometrial capillary plexus that develops small vessels in the capillary plexus — this angiogenic process is present alongside functional activity in the proliferative phase and in pathological states [22].

Among the effects that fibroids exert on the endometrium, are the altered genetic expression and changes in the immune environment and vasoconstrictive factors, generating from a decrease in production of transcription factors necessary for implantation, within the window of implantation (WOI) to the altered production of coagulation factors during menstruation [17].

To understand these changes, it is necessary to understand how human endometrial stromal cells (HESC) regulate the expression of the tissue factor (TF), which is the main promoter of coagulation at this level, complemented by the effect of progesterone which increases a second haemostatic factor in the HESC, the plasminogen activator inhibitor-1 (PAI-1) — if this order is altered, the stability of the stromal endometrial matrix and the vascular extracellular matrix are lost by the action of the matrix metalloproteinase (MMP) -1, 3 and 9. This increases the inflammatory activity and an uncontrolled angiogenesis, with an endometrium that loses its homeostatic and proteolytic ability, and being highly vascularised.

An increase in TF expression accompanied by decreased endometrial blood flow produces hypoxia and reactive oxygen species (ROS) induce an aberrant

angiogenesis and inflammation. Hypoxia produces the release of endometrial cells' apoptosis inducers secreted by human endometrial stromal cells (HESC) [23].

An altered angiogenesis due to the presence of fibroids produces fragile, hyper dilated, thinned vessels that bleed easily. The alteration of endometrial blood flow produces local hypoxia and the generation of ROS that increase the production of angiogenic factors such as the vascular endothelial growth factor (VEGF) in human endometrial stromal cells and Angiopoietin-2 (Ang-2) in endometrial cells with a decrease in HESC of angiostatic (Ang-1) [24].

5. The pseudo-capsule

In order to understand more about fibroids, it is essential to understand the myometrium as a structure comprised of bundles of smooth muscle fibres surrounded by connective tissue with a network of blood and lymphatic vessels — this is the place where fibroids grow, comprised of intertwined fascicles of disordered smooth muscle cells, abundant fibrous tissue with type I and III collagen (**Figure 3**).

During its growth, fibroids compress the myometrium forming a pseudo-capsule composed of collagen fibres, neurofibres and blood vessels. Occasionally, bridges of collagen fibres and vessels that join the myometrium with the fibroid can be formed (**Figures 4 and 5**) [25].

The pseudocapsule vessels that come from the surrounding myometrium are grouped in a vascular network and the veins surrounding the fibroid in the shape of a plexus forming the image of a “ring of fire”, easily detectable with a Doppler ultrasound (**Figure 6**) [26].

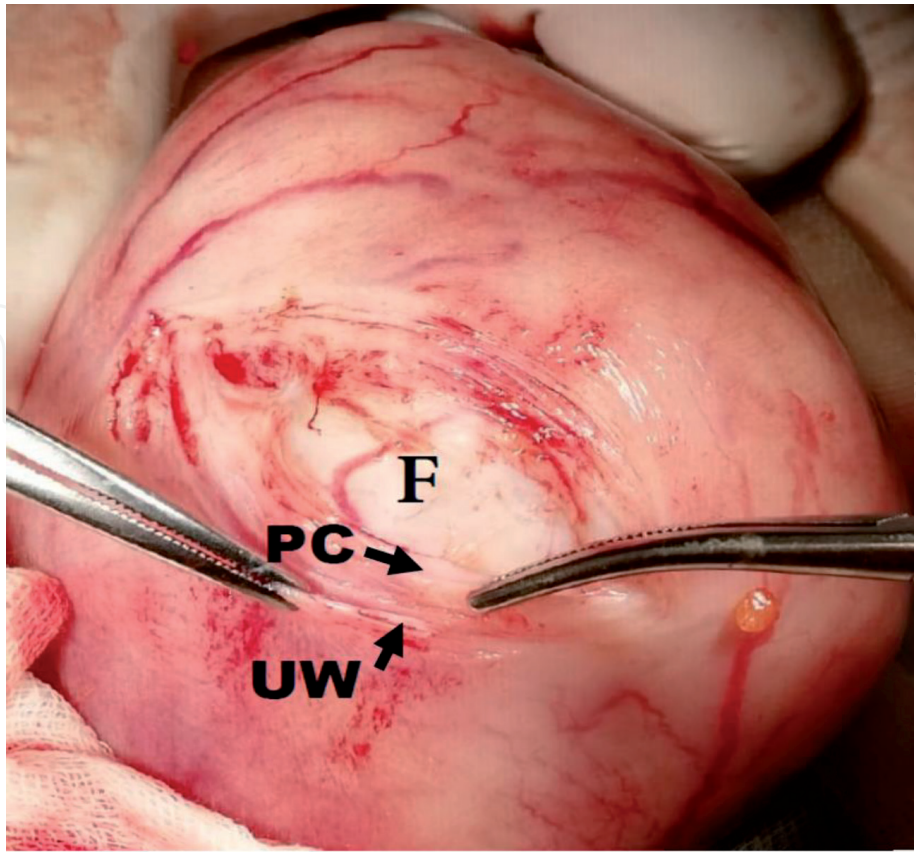


Figure 3.
Showing the uterine wall (UW) with th dissected pseudocapsule (PS) and the myoma at the bottom.

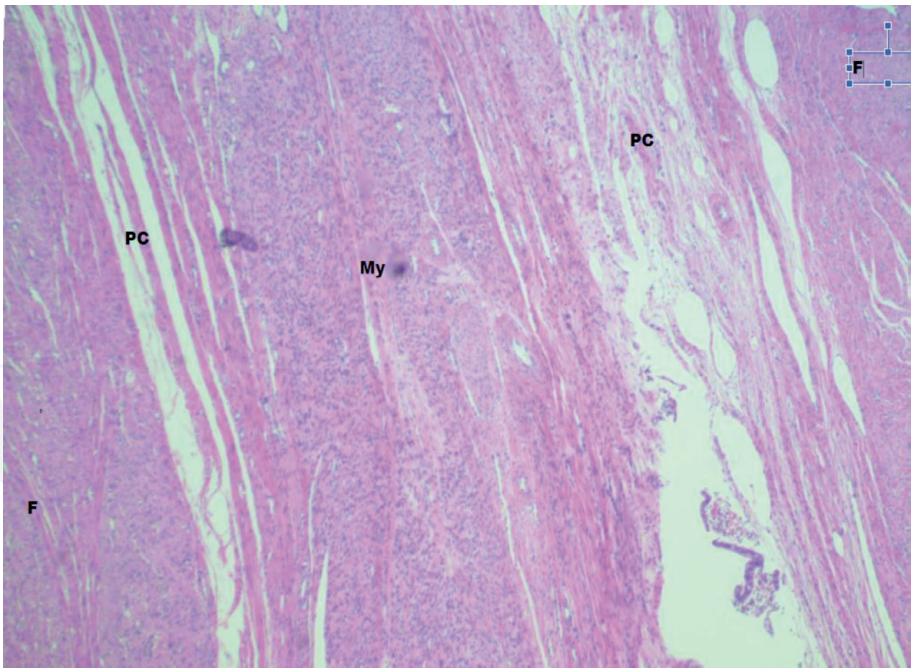


Figure 4.
Image with two fibroids at the ends (F), two pseudocapsules (PC) and the myometrium in the center (my).

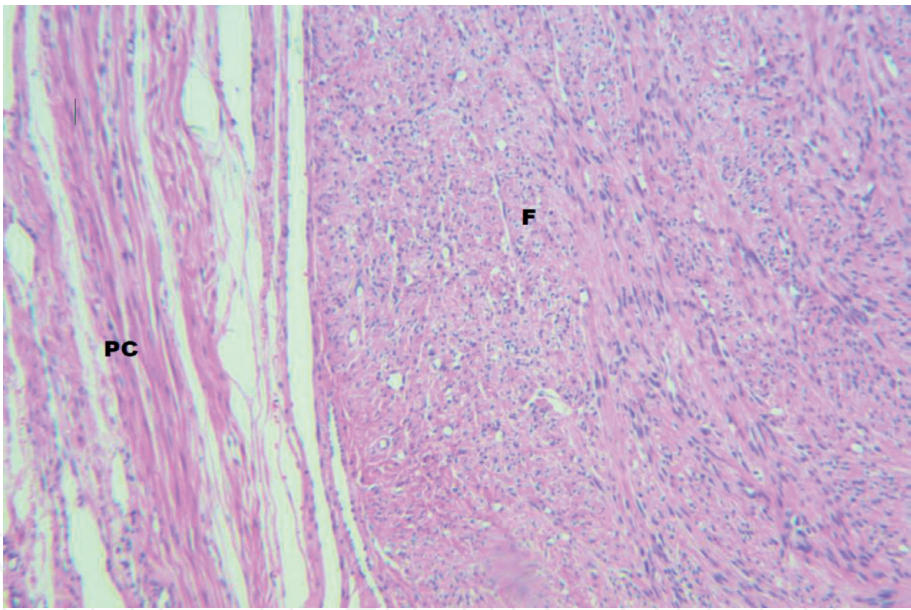


Figure 5.
Magnified image of the pseudocapsule (PC) and fibroid (F).

Angiogenesis of the fibroid's pseudo-capsule leads to the formation of a protective vascular capsule, in addition, to being responsible for the blood supply to the central nucleus of the tumour.

The biological genesis of the pseudo-capsule is not well described, however, there is evidence that is originated from the myometrium that surrounds the fibroid, therefore, the fibroid is not originated from the pseudo-capsule, but it is part of the myometrium that compresses it [27].

The pseudo-capsule is a structure rich in neuropeptides and neurotransmitters, which have a very important role in wound healing and innervation repairing besides being key in sexual and reproductive functions and being the study objective for new future treatments.

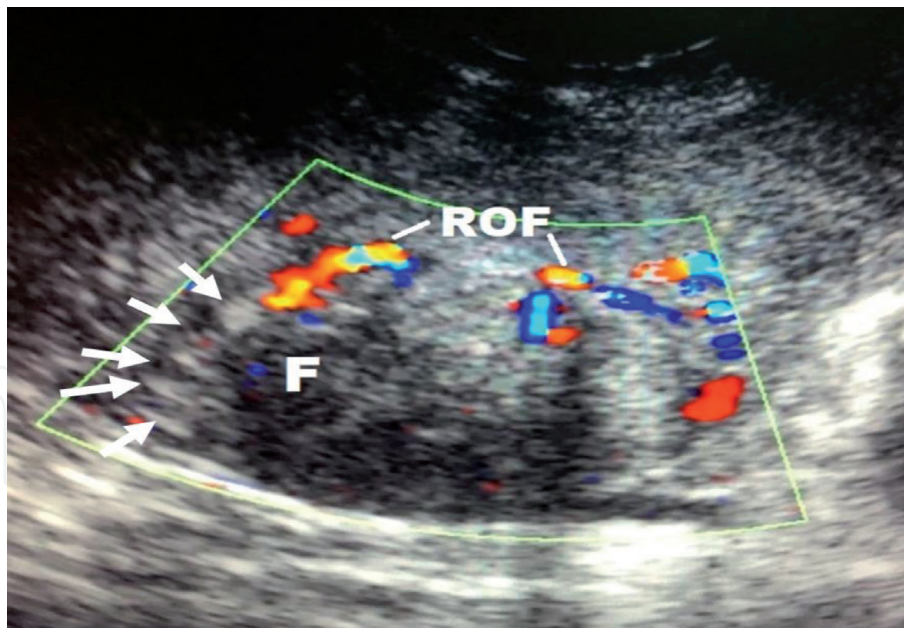


Figure 6.
 Ultrasound with a fibroid in the center, with peripheral Doppler showing the ring of fire, the arrows delimit the pseudocapsule.

Neurotransmitters such as: Substance P (SP), Vasoactive Intestinal Peptide (VIP), Neuropeptide Y, Oxytocin, Vasopressin, PGP 9.5, calcitonin gene-related peptide and Growth hormone releasing hormone play an important role in the wounds' inflammatory and healing cascades [28].

The neurofibres of the pseudo-capsule contain SP and VIP just as the myometrium without pregnancy.

It is possible that these neuropeptides have influence in the physiology of the uterine contraction, cervix dilation and during labour [29].

Other research focused on the opioid neuropeptides enkephalin (ENK) and oxytocin (OXT). The study revealed the lack of positive ENK neurofibres at the bottom of the uterus and in the fibroid's pseudo-capsule in the body of the uterus, and presence of these in the isthmic-cervical area. Fibres positive for OXT were observed in the pseudo-capsule in all uterine regions, lesser at the bottom, and a higher quantity in the cervical isthmus. This indicates a larger research of neuropeptides about the impact in neurofibres in obstetric complications such as spontaneous miscarriage and cervical dystocia during labour [30].

Literature mentions the importance of knowing the fibroid's pseudo-capsule during a myomectomy, since performing a correct technique enhances the prognosis of quality of life and fertility rate in women affected by uterine myomatosis [31].

The objective of the myomectomy is to enucleate the fibroid, always preserving the pseudo-capsule. Myomectomy's technique takes prostate cancer surgery as a base, a procedure that preserves the neurovascular bundles that surround the prostate with the objective of reducing the probability of post-operative impotence and incontinence.

Taking into account these findings according to the prostatic capsule and the importance of nerve-sparing surgery, these were implemented in the surgery known as intracapsular myomectomy, preserving the fibroid's pseudo-capsule and neurovascular bundle with the objective of improving reproductive function. It is performed by coagulating, cutting, and breaking the pseudo-capsule's fibrous bridges, then extracting the fibroid directly dissecting the fibromuscular skeleton that surrounds it, always using low energy instruments (less than 30 watts). The closing of the

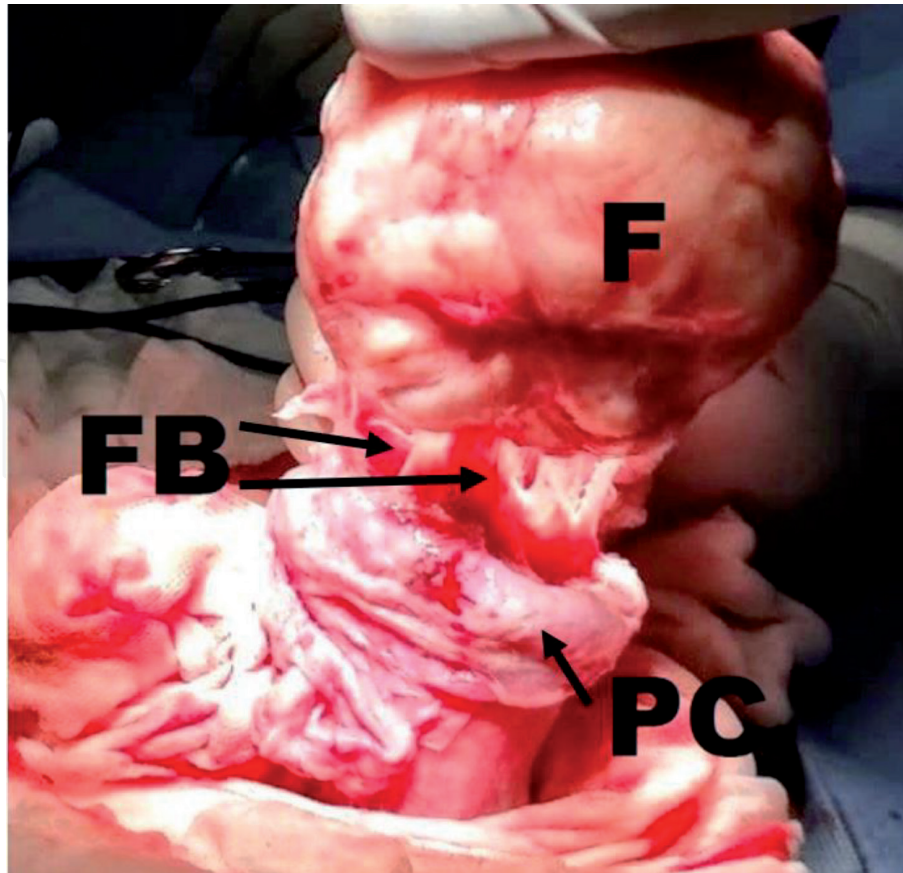


Figure 7.
Miomectomy image with dissection of fibroma (F), pseudocapsule (PC) and between fibroconnective bridges (FB).

myometrium is performed depending on the type of fibroid found — in subserosal fibroids it is performed in one plane, and in intramuscular fibroids two planes are closed (**Figure 7**). This surgical principle can be applied to all myomectomies: laparotomy, laparoscopy, and caesarean myomectomy. In comparison with intracapsular myomectomy through laparotomy or laparoscopy, laparoscopic myomectomy proved to have more benefits: lesser intraoperative and postoperative bleeding, reduced bladder pain after the removal of the Foley catheter, less use of analgesic medication and a shorter hospital stay — reduced appearance of fever, myometrial scar, bruising, ileus, and use of antibiotics were also observed during the post-operative period in comparison with laparotomy [32].

6. Leiomyomatosis and infertility

Most of leiomyomas are asymptomatic, symptoms are usually correlated with the number, size, location, and degenerative changes that these suffer — these are considered hormone-dependent. It is estimated that 30% of cases cause abnormal uterine bleeding, chronic pelvic pain and other symptoms that can affect the patients' quality of life. Leiomyomas also cause anaemia, recurrent pregnancy loss, preterm birth, urinary incontinence, subfertility, and infertility [33, 34].

The relation between leiomyomas and infertility has been a concern for a long time. *The American Society for Reproductive Medicine (ASRM)* mentions that these uterine tumours are associated with infertility from 5% to 10% of cases and are catalogued as directly responsible for infertility from 2% to 3% of patients. However, the exact mechanism, by which these cause infertility, is still in debate. Consequently, several mechanisms have been proposed to explain the possible

adverse effects of fibroids on fertility, such as: alteration of the endometrial contour that interferes with implantation, alteration of endometrial blood flow that affects endometrial responsiveness, ulceration, thinning, endometrial inflammation and atrophy, endometrial biochemical alterations, triggering of uterine contractility dysfunction that alters the embryonic movement and tube obstruction. According to the *American Fertility Society Guideline for Practice*, fibroids can be associated with 5% to 10% of infertility cases, although as a sole factor, these only influence from 2% to 3% [35].

Normally, the uterus presents uterine contractions, these begins in the uterine fundus and continue towards the cervix, and their frequency increases in the early follicular phase. In the periovulatory and luteal phase, the direction of contractions is inverted, that is to say, from the cervix to the fundus, favouring the fertilisation process [36].

Fibroids as a mechanical factor is one of the simplest mechanisms that would explain infertility in this group of patients with larger and intracavitary fibroids being those that interfere in the process of transporting eggs and sperm, as well as implantation [37]. Another mechanism is through the production of cytokines and chronic inflammation — these underlying mechanisms are the ones that increase the uterine contractility mainly due by overproduction of cytokines. One study showed a considerable increase in uterine peristalsis in the presence of fibroids and after myomectomy in this group of patients, a pregnancy rate of 40% was obtained [38, 39].

The implantation process is one of the most complex and perfectly orchestrated processes in the human being. The foetal success depends on immunological changes in the mother, and it is based on modifications in the innate and adaptive immune system, in which embryo implantation and placenta development are presented thanks to immune reactions mediated by the following cytokines: TNF (tumour necrosis factor) α and β , interleukin 1, 2, 10 and 6, among others [40].

In patients with submucous fibroids, it has been proven that a significant decrease in IL-10 and glycodelin levels, the latter being a key protein to promote angiogenesis and suppress NK (natural killer) cells in the implantation process [41]. The presence of fibroids has shown alterations in the subendometrial area, a region highly rich in macrophages and NK cells. In patients with leiomyomatosis, a decrease in concentrations of these two cell populations has been proven, altering the steroid receptors at the endometrial level that are essential for the implantation process [42].

Pregnancy, live births, and implantation rates are significantly lower in patients with leiomyomatosis [43]. The presence of submucosal leiomyomas decreases the birth rate by 70%, while intramural fibroids show a decrease in the birth rate by 30% [44].

It is known that the presence of fibroids shows a deleterious effect upon the uterine contractility, depending on its location and size, particularly those that distort the submucosal and intramural uterine cavity in 60% of women younger than 40 years of age, and in 80% of women younger than 50 years of age.

One of fibroids subtypes that most affects fertility is leiomyoma with bizarre nuclei (LBNs) which, in turn, is linked with higher concentrations of MIB1 (mind-bomb E3 ubiquitin protein ligase 1, which is an apoptosis regulator, also known as Ki-67) in the endometrium. This means, that not only the size and location of the fibroid plays a role in the subfertility observed in patients with leiomyomatosis, but also the morphological subtype of fibroids. Furthermore, this shows that regardless of the location of the fibroids, the fertility rate was lower compared with the controls. Showing a relative risk of clinical pregnancy of 0.85 with CI 95%: 0.73–0.98 and a live birth rate with a RR: 0.69 with CI 95% 0.59–0.82 and an increase in the abortion rate with a RR 1.68 CI 95%: 1.37–2.05, in patients with uterine leiomyomatosis [45].

7. Hysteroscopic management of submucous fibroids

The coming of hysteroscopy in gynaecologic surgery has offered a new conservative approach to the treatment of pathologies of the uterine cavity.

Going back to the FIGO classification adopted by ESGE (European Society of Gynaecological Endoscopy) of submucous fibroids, describing the extent of miometrial involvement of submucosal fibroids visualised by hysteroscopy. According to the degree of myometrial penetration: submucosal fibroids grade 0, grade 1 and sometimes grade 2 submucous fibroids are candidates for this management (**Figure 8**).

The criteria for scheduling the surgical procedure must be clear, and these include a pre-operative evaluation that considers in detail the size, location, myometrial depth, distance from the fibroid to the serosa layer of the uterus, and the number of fibroids with possible degree of tissue degeneration with ultrasound or MRI, knowledge of the management of electrolytic or non-electrolytic distension fluids, and hysteroscopic irrigation pump, experience in the use of monopolar or bipolar resectoscopes, diode laser or mechanic resectors and when to select each one of them, and surgical judgement to use different techniques and to know when to stop the procedure or program it in two sessions [46].

Contraindications for a resectoscopy are: pelvic inflammatory disease or herpes infection, a distance of less than 5 mm from the fibroid to the uterine serosa, large size uterine cavity that does not allow the suitable distension and view of tumours, and a lack of surgical ability of the surgeon.

The success rate of 90% in myomectomies depends on the appropriate selection of the patient and being within the range of possible complications — from 1% to 5% in fibroids of less than 3 cm in diameter.

The entire fibroid must be removed without leaving any residual tissue and respecting the dissection plane of the pseudocapsule, which is part of the myometrium and favours the appropriate healing of the uterine wall.

The myomectomy can be performed in the office or in the operating theatre according to patient's characteristics, intra-wall extension of the tumour,

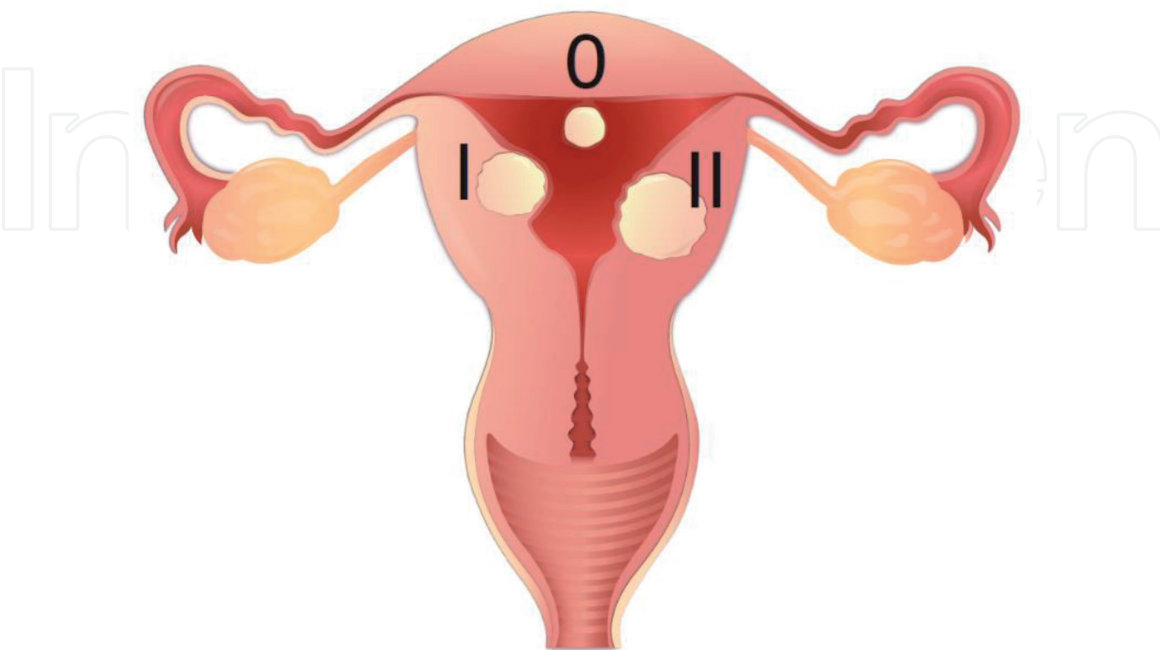


Figure 8.
ESGE classification of submucous leiomyomas.

estimated surgical time since office procedures should not exceed more than 20 minutes, the diameter of the instrument, and if anaesthesia is required to improve the conditions and results of the surgery [47].

As decision criteria G-0 and G-1 fibroids with a minimum myometrial component and smaller than 15 mm can be treated in the office. Hysteroscopic resections can still be attempted in G-1 fibroids of less than from 4 to 5 cm and G-2 fibroids of less than from 5 to 6 cm of diameter in the operating theatre and with anaesthesia since pain occurs when surgically working in the myometrium that has sensory innervation.

In order to calculate the volume of the fibroid, the $V = 4/3\pi r^3$ [3] formula must be used.

Using a 4 mm resectoscope loop, 0.5 cm [3] is removed per minute and a 5 cm diameter fibroid has 65.4 cm [3], so on average the procedure will require two hours, being within the pertinent time limit for a hysteroscopy [48].

In the office, scissors and 5 Fr grasper clamps can be used in fibroids of less than 15 mm, sectioning the pedicle in order to extract it and, if it is not possible to, wait from 30 to 45 days for the uterus to spontaneously expel it, or the tumour can also be divided into two parts in order to extract fragments.

There is the, OPPIuM technique in G2 myomas, consisting in performing a cut with monopolar energy alongside the intracavitary fibroid's peripheral line of reflection, and in a second surgery in 30 days, resecting the leiomyoma that has emerged into the uterine cavity with a resectoscope, facilitating the procedure.

There is also the possibility of using a 45-watt diode laser with wavelengths of 980 nm and 1470 nm to cut or vaporise the fibroid with a lower rate of complications and a better vision without generating bubbles. The cutting depth is 1 mm and with special fibres, vaporisation and selective clotting of the tissue are achieved.

The gold standard is the resection with 15 Fr bipolar loop mini-resectoscope and 3 mm loop in the office and in the operating theatre, 27 Fr bipolar resectoscope with a 4 mm loop in order to completely the fibroid, while preserving the pseudocapsule. The "cut" must be programmed from 60 Watt to 70 Watt to avoid post-operative adhesences. It is convenient to have the Collins loop and the cold Mazzon loops to enucleate the residual tissue, complete the surgery, and completely remove the leiomyoma.

There are mechanic tissue resection devices of different thicknesses — 15 Fr to 24 Fr with a reciprocating cutting blade and a 0 degree vision with better liquid control, that cut and aspirate the tissue by using saline solution, avoiding thermal damage to endometrium/myometrium and fluid overload. The surgeon must have the experience to align the instrument which is straight and does not allow much mobility, with the fibroid in a peripheric way, and in case any vein or artery presents haemorrhage, remove the device a few millimetres from the surgical site and wait that the continuous flow clears the vision and then directs it towards the vessel and completely resects it towards its origin.

No prophylactic or post-operative antibiotic is needed, it is only used if there is a history of pelvic inflammatory disease.

The success of the hysteroscopic myomectomy depends on a personalised study of each patient and its therapeutic goals, performing a complete diagnosis both clinical and with laboratory and imaging studies including an ultrasound or magnetic resonance to perfectly locate the type and number of fibroids, their depth within the myometrium, and the distance to the serosa layer of the uterus.

Correctly selecting if the procedure can be performed in an office or in an operating theatre, because one of the main goals is the complete removal of all the

tumour tissue in one or two surgical sessions, remembering that the office surgery limit is 25 minutes and that the ability to work comfortably depends on the patient's pain threshold, in addition the use of the appropriate 5 mm surgical material.

Both in the case of surgery in an office and in an operating theatre, being familiar with more than one instrument allows a better selection of the type of energy to use and guarantee the safety of the patient and avoid possible complications [49].

Author details

Sergio Rosales-Ortiz*, Tammy Na Shieli Barrón Martínez, Diana Sulvaran Victoria, Jocelyn Arias Alarcon, Janeth Márquez-Acosta and José Fugarolas Marín
UMAE, Hospital de Gineco Obstetricia No. 4 “Luis Castelazo Ayala”,
Mexican Institute of Social Security, Mexico City, Mexico

*Address all correspondence to: dr.sergiorosalesortiz@gmail.com

IntechOpen

© 2021 The Author(s). Licensee IntechOpen. This chapter is distributed under the terms of the Creative Commons Attribution License (<http://creativecommons.org/licenses/by/3.0>), which permits unrestricted use, distribution, and reproduction in any medium, provided the original work is properly cited. 

References

- [1] Fraser IS, Critchley HO, Broder M, Munro MG. The FIGO recommendations on terminologies and definitions for normal and abnormal uterine bleeding. *Semin Reprod Med* 2011;29(5):383-390.
- [2] Chodankar R, Critchley HOD. Biomarkers in abnormal uterine bleeding, *Biol Reprod* 2019;101(6): 1155-1166.
- [3] Whitaker L, Critchley HO. Abnormal uterine bleeding. *Best Pract Res Clin Obstet Gynaecol* 2016;34:54-65.
- [4] Munro MG, Critchley HO, Broder MS, Fraser IS. FIGO Working Group on Menstrual Disorders FIGO classification system (PALM-COEIN) for causes of abnormal uterine bleeding in nongravid women of reproductive age. *Int J Gynaecol Obstet* 2011;113(1):3-13.
- [5] Munro, MG, Critchley HO, Fraser IS. FIGO Menstrual Disorders Committee. The two FIGO systems for normal and abnormal uterine bleeding symptoms and classification of causes of abnormal uterine bleeding in the reproductive years: 2018 revisions. *Int J Gynaecol Obstet* 2018;143(3):393-408.
- [6] Baird DD, Dunson DB, Hill MC, Cousins D, Schectman JM. High cumulative incidence of uterine leiomyoma in black and white women: ultrasound evidence. *Am J Obstet Gynecol* 2003; 188(1):100-107.
- [7] Donnez J, Dolmans MM. Uterine fibroid management: from the present to the future. *Human reproduction update* 2016;22(6): 665-686.
- [8] Kim JJ, Sefton EC. The role of progesterone signaling in the pathogenesis of uterine leiomyoma. *Mol Cell Endocrinol* 2012;358(2):223-231.
- [9] Zimmermann A, Bernuit D, Gerlinger C, Schaefer M, Geppert K. Prevalence, symptoms and management of uterine fibroids: an international internet-based survey of 21,746 women. *BMC Womens Health* 2012;12:6.
- [10] Wamsteker K, Emanuel MH, De Kruif JH. Transcervical hysteroscopic resection of submucous fibroids for abnormal uterine bleeding: Results regarding the degree of intramural extension. *Obstet Gynecol* 1993;82(5):736-740.
- [11] Lasmar RB, Barrozo PR, Dias R, Oliveira MA. Submucous myomas: A new presurgical classification to evaluate the viability of hysteroscopic surgical treatment - preliminary report. *J Minim Invasive Gynecol* 2005;12(4):308-311.
- [12] Laughlin-Tommaso SK, Hesley GK, Hopkins MR, Brandt KR, Zhu Y, Stewart EA. Clinical limitations of the International Federation of Gynecology and Obstetrics (FIGO) classification of uterine fibroids. *Int J Gynaecol Obstet* 2017;139(2): 143-148.
- [13] Munro MG. Classification of menstrual bleeding disorders. *Rev Endocr Metab Disord* 2012;13(4):225-234.
- [14] Stewart EA, Nowak RA. Leiomyoma-related bleeding: a classic hypothesis updated for the molecular era. *Hum Reprod Update* 1996;2(4):295-306.
- [15] Sinclair DC, Mastroyannis A, Taylor HS. Leiomyoma simultaneously impair endometrial BMP-2-mediated decidualization and anticoagulant expression through secretion of TGF-beta3. *J Clin Endocrinol Metab* 2011;96(2):412-421.
- [16] Maybin JA, Critchley HO. Menstrual physiology: implications for endometrial

pathology and beyond. *Hum Reprod Update* 2015;21(6):748-761.

[17] Ikhen DE, Bulun SE. Literature Review on the Role of Uterine Fibroids in Endometrial Function. *Reproductive Sci* 2018;25(5):635-643.

[18] Berbic M, Ng CHM, Fraser IS. Inflammation and endometrial bleeding. *Climacteric* 2014;17Suppl2:47-53.

[19] Maybin JA, Critchley HO, Jabbour HN. Inflammatory pathway in endometrial disorders. *Mol Cell Endocrinol* 2011;335(1):42-51.

[20] Ferenczy A. Pathophysiology of endometrial bleeding. *Maturitas* 2003;45(1):1-14.

[21] Laganá AS, Vergara D, Favilli A, La Rosa VL, Tinelli A, Gerli S, et al. Epigenetic and genetic landscape of uterine leiomyomas: a current view over a common gynecological disease. *Arch Gynecol Obstet* 2017;296(5):855-867.

[22] Gargett CE, Rogers PA. Human endometrial angiogenesis. *Reproduction* 2001;121(2):181-186.

[23] Lockwood CJ. Mechanisms of normal and abnormal endometrial bleeding. *Menopause* 2011;18(4):408-411.

[24] Schatz F, Guzeloglu-Kayisli O, Arlier S, Kayisli UA, Lockwood CJ. The role of decidual cells in uterine hemostasis, menstruation, inflammation, adverse pregnancy outcomes and abnormal uterine bleeding. *Hum Reprod Update* 2016;22(4):497-515.

[25] Tinelli A, Sparic R, Kadija S, Babovic I, Tinelli R, Mynbaev O, et al. Myomas: anatomy and related issues. *Minerva Ginecol* 2016;68(3):261-273.

[26] Tinelli A, Malvasi A. Uterine fibroid pseudocapsula. In Tinelli, Malvasi A.

Uterine myoma, myomectomy and minimally invasive treatment. Springer 2015:73-93.

[27] Di Tommaso S, Massari S, Malvasi A, Vergara D, Maffia M, Greco M, et al. Selective genetic analysis of myoma pseudocapsula and potential biological impact on uterine fibroid medical therapy. *Expert Opin Ther Targets* 2015;19(1):7-12.

[28] Mettler L, Tinelli A, Hurst BS, Teigland C, Sammur W, Dell'edera D, et al. Neurovascular bundle in fibroid pseudocapsula and its neuroendocrinologic implications. *Exper Rev Endocrinol Metab* 2011;6(5):715-722.

[29] Malvasi A, Tinelli A, Cavallotti C, et al. Distribution of substance P (SP) and vasoactive intestinal peptide (VIP) in pseudocapsules of uterine fibroids. *Peptides* 2011;32(2):327-332.

[30] Tinelli A, Pacheco L, Haimovich S. Hysteroscopy. In Tinelli A, Mynbaev O, Sparic R et al. Physiology and importance of the myoma's pseudocapsule. Springer 2018: 337-351.

[31] Tinelli A, Mynbaev O, Sparic R. Physiology and importance of the myoma's pseudocapsule. In Tinelli A, Pacheco L, Haimovich S. Editors. Hysteroscopy. Springer, 2018: 337-351.

[32] Tinelli A, Malvasi A, Hurst BS, Tsin DA, Davila F, Dominguez, et al. Surgical Management of Neurovascular Bundle in uterine fibroid pseudocapsule. *JSLs* 2012;16(1):119-129.

[33] Hernández VM, Valerio-Castro E, Valdez ZCL, Barrón VJ, Luna RRM. Miomatosis uterina: implicaciones en la salud reproductiva. *Ginecol Obstet Mex* 2017;85(9):611-633.

[34] Ramos-Ramos JA, Flores AJD, Hernández-Álvarez C, et al. Miomatosis

uterina en pacientes infértiles: descripción de un grupo poblacional y experiencia de seis años. *Acta Med* 2015;13(2):92-96.

[35] Lisiecki M, Paszkowski M, Woźniak S. Fertility impairment associated with uterine fibroids - a review of literature. *Prz Menopauzalny* 2017;16(4):137-140.

[36] Lyons E, Taylor P, Zheng X, Ballard G, Levi C, Kredentser JV. Characterization of subendometrial myometrial contractions throughout menstrual cycle in normal fertile women. *Fertil Steril* 1991; 55(4): 771-774.

[37] Purohit P, Vigneswaran K. Fibroids and Infertility. *Curr Obstet Gynecol Rep* 2016;5:81-88.

[38] Richards PA, Richards PD, Tiltman AJ. The ultrastructure of fibromyomatous myometrium and its relationship to infertility. *Hum Reprod Update* 1988;4:520-525.

[39] Yoshino O, Nishiss O, Osuga Y, Asada H, Okuda S, Orisaka M, et al. Myomectomy decreases abnormal uterine peristalsis and increases pregnancy rate. *J Minim Invasive Gynecol* 2012;19(1):63-67.

[40] Veenstra van Nieuwenhoven AL, Heineman MJ, Faas MM. The immunology of successful pregnancy. *Hum Reprod Update* 2003;9(4):347-57.

[41] Ben-Nagi J, Miell J, Mavrelos D, Naftalin J, Lee C, Jurkovic D. Endometrial implantation factors in women with submucous uterine fibroids. *Reprod Biomed Online* 2010;21(5):610-615.

[42] Kitaya K, Yasuo T. Leukocyte density and composition in human cycling endometrium with uterine fibroids. *Hum Immunol* 2010;71(2):158-163.

[43] Vam Heertum K, Barmat L. Uterine fibroids associated with infertility. *Womens Health* 2014;10(6):645-653.

[44] Rackow B, Taylor HS. Submucosal uterine leiomyomas have a global effect on molecular determinants of endometrial receptivity. *Fertil Steril* 2010;93(6):2027-2034.

[45] Pritts EA, Paker WH, Olive DL. Fibroids and infertility: an updated systematic review of the evidence. *Fertil Steril* 2009;91(4):1215-1223.

[46] Mazzon I, Bettocchi S, Fascilla F, DE Palma D, Palma F, Brunella et al. Resectoscopic myomectomy. *Minerva Ginecol.* 2016;68(3):334-344.

[47] Lasmar R, Lasmar B. Limiting Factors of office hysteroscopic myomectomy. In: In Tinelli A, Alonso L Haimovich S. Editors. *Hysteroscopy* Springer, 2018:357-362.

[48] Lasmar RB, Barrozo PR, Dias R, Oliveira MA. Submucous myomas: a new presurgical classification to evaluate the viability of hysteroscopic surgical treatment--preliminary report. *J Minim Invasive Gynecol.* 2005;12(4):308-311.

[49] Deutsch A, Sasaki KJ, Cholkeri-Singh A. Resectoscopic Surgery for Polyps and Myomas: A Review of the Literature. *J Minim Invasive Gynecol.* 2017;24(7):1104-1110.