

We are IntechOpen, the world's leading publisher of Open Access books Built by scientists, for scientists

6,900

Open access books available

186,000

International authors and editors

200M

Downloads

Our authors are among the

154

Countries delivered to

TOP 1%

most cited scientists

12.2%

Contributors from top 500 universities



WEB OF SCIENCE™

Selection of our books indexed in the Book Citation Index
in Web of Science™ Core Collection (BKCI)

Interested in publishing with us?
Contact book.department@intechopen.com

Numbers displayed above are based on latest data collected.
For more information visit www.intechopen.com



Role of Small Bowel Endoscopy in Diagnosis and Management of Inflammatory Bowel Disease: Current Perspective

Partha Pal, D. Nageshwar Reddy and Zaheer Nabi

Abstract

The evaluation of small bowel in inflammatory bowel disease (IBD) is mainly performed in cases with newly diagnosed or suspected Crohn's disease (CD). The available modalities for small bowel evaluation include radiological imaging (barium meal follow through, magnetic resonance enteroclysis, computed tomography enteroclysis) and small bowel endoscopy also known as enteroscopy. The main advantage of small bowel endoscopy over radiological imaging is that it allows for obtaining biopsy specimen required for histological confirmation of the diagnosis. Various endoscopic modalities for endoscopic evaluation of small bowel include push enteroscopy and device assisted enteroscopy (DAE). Push enteroscopy allows only limited evaluation of proximal small bowel. Therefore, DAE is generally preferred over push enteroscopy for small bowel evaluation. DAE includes single balloon enteroscopy, double balloon enteroscopy, and spiral enteroscopy. The available literature suggests that there is no significant difference in the diagnostic yield among the available DAE devices. Therefore, the choice of DAE is largely dependent on the availability as well as local expertise. More recently, motorised spiral enteroscopy has been introduced. The main advantage of this novel DAE is ease of use with the possibility of evaluating the entire small bowel via per-oral route. However, the data regarding the use of motorised spiral enteroscopy is limited and comparative trials are required in future.

Keywords: small bowel, endoscopy, advances

1. Introduction

Evaluation of the small bowel in inflammatory bowel disease (IBD) is indicated primarily in patients with newly diagnosed or suspected Crohn's disease (CD) [1]. Small bowel evaluation can also be helpful in IBD- unclassified (IBD-U) who can be re-classified as CD in a significant number of cases. Small bowel evaluation in these settings can be done by imaging (barium meal follow through - BMFT, magnetic resonance enterography/enteroclysis - MRE, computed tomography enterography/enteroclysis -CTE) or by endoscopy. Small bowel endoscopy refers to endoluminal examination of the small bowel. Endoscopic evaluation of small bowel can be done by small bowel video capsule endoscopy (VCE) (**Figure 1A**), push enteroscopy,

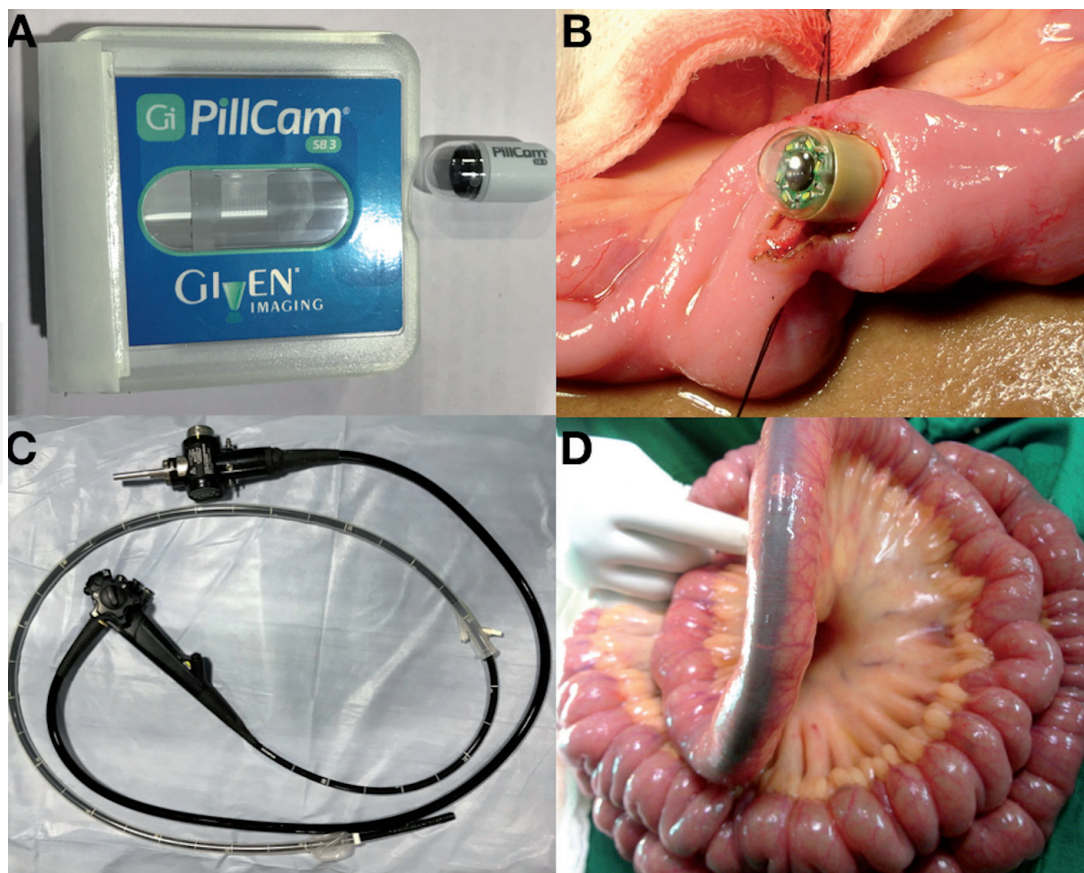


Figure 1.
Types of small bowel endoscopy. A. Video capsule endoscopy for small bowel (PillCam, given imaging ltd., Yokneam Illit, Isareal), B. retained capsule removed at laparotomy, C. single balloon enteroscope (SIF-Q180, Olympus, Tokyo, Japan) with overtube and balloon, D. intra-operative enteroscopy being performed at laparotomy.

device assisted enteroscopy (DAE) (which includes single balloon enteroscopy-SBE, double balloon enteroscopy - DBE, spiral enteroscopy, novel motorised spiral enteroscopy - NMSE and balloon guided endoscopy) (**Figure 1C**) and intra-operative enteroscopy (IOE) (**Figure 1D**) [2].

In about two-thirds of patients with CD, small bowel is involved at diagnosis [3]. Among them, 90% have involvement of terminal ileum. Skip lesions in terminal ileum can lead to false negative results. So for diagnosis of suspected CD, ileo-colonoscopy is the first line investigation [4]. VCE is the preferred initial diagnostic modality in cases with suspected CD and negative ileo-colonoscopy in the absence of obstructive symptoms or known stenosis. However, small bowel evaluation is warranted in all newly diagnosed cases of CD as small bowel is involved in every 2 out of 3 CD patients and the involvement can be discontinuous. In this scenario, cross sectional imaging (CTE/MRE) is preferred over VCE due to its potential to assess transmural and extra-luminal disease. VCE is indicated subsequently if cross sectional imaging is non-contributory. Patients with suspected small bowel involvement on cross sectional imaging or VCE, DAE with small bowel biopsy can provide definitive evidence of CD. Additionally, DAE is recommended for treatment of small bowel strictures amenable for endoscopic therapy, small bowel bleeding and retrieval of foreign bodies/retained capsule. For assessing the response to therapy in small bowel CD, VCE can be considered in primarily non-stricturing CD [2]. Hence, small bowel endoscopy has major implications in the diagnosis and classification, therapeutic decision making and altering treatment outcomes in IBD [5].

2. Indications of SB endoscopy in IBD

The Indications of small bowel endoscopy in IBD are [2, 5]

1. Suspicion of isolated small bowel CD,
2. Assessment of small bowel involvement in patients with confirmed CD,
3. Assessment for post-operative recurrence of CD in small bowel after ileo-colonic resection [6],
4. Small bowel assessment in IBD-U,
5. As a therapeutic tool in small bowel CD (stricture dilatation, retained capsule or foreign body retrieval, haemostasis for small bowel bleed).
6. Evaluation of anaemia and unexplained abdominal symptoms in cases with ulcerative colitis (UC) [7],
7. To rule out CD prior to elective colectomy in refractory UC,
8. Investigate anaemia after ileal pouch anal anastomosis (IPAA) in UC [8].

3. Role of small bowel endoscopy in suspected CD

There is no single reference standard for diagnosis of CD. Constellation of clinical history, biochemical and stool biomarkers, endoscopy, cross sectional imaging and histopathology is required for diagnosis of CD [9, 10]. Upto 30% CD patients have isolated small bowel disease. Improvement in endoscopic techniques (VCE, DAE, NMSE) as well as radiographic techniques (CTE/MRE) have revolutionised the diagnosis of small bowel CD [5]. However, options for histopathological confirmation in isolated CD is still limited, which is important in resource limited countries where infections (eg. tuberculosis) still predominate and needs to be excluded prior to initiation of therapy [11].

4. VCE in CD

The original VCE (PillCam, Given imaging Ltd., Yokneam Illit, Isreal) (**Figure 1A**) was designed for visualisation of small bowel which has undergone many modifications such as higher image resolution and increasing diagnostic yield by faster adjustable frame rate and real time analysis capability [12].

4.1 VCE in suspected small bowel CD

European society of gastrointestinal endoscopy (ESGE) recommends VCE as the first line investigation in suspected small bowel CD in whom ileo-colonoscopy is negative in the absence of obstructive symptoms/known stenosis (**Figure 2**) [2]. This recommendation is based on the high sensitivity and negative predictive value (NPV) (ranging from 96–100%) of VCE in small bowel CD. However, the accuracy and diagnostic yield of VCE in suspected CD could not be determined precisely due

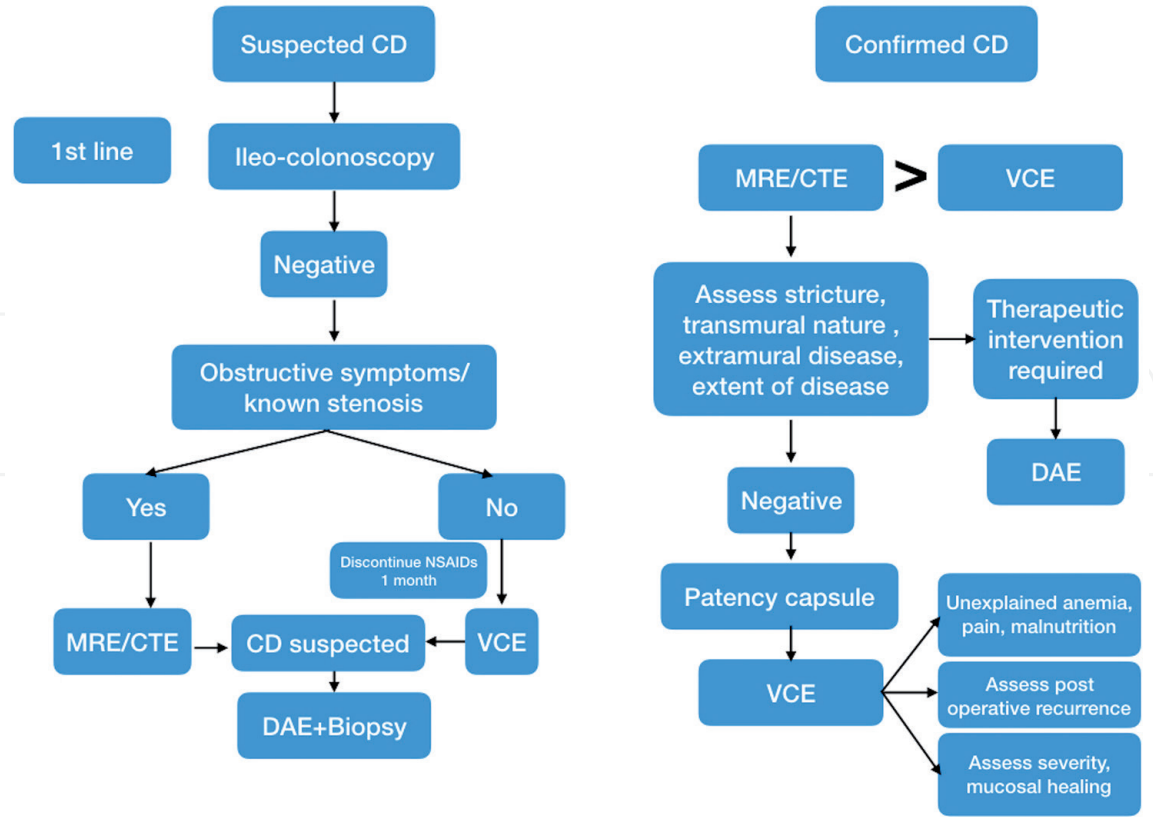


Figure 2.
Algorithm for small bowel evaluation in a suspected or known case of Crohn's disease (CD). DAE- device assisted enteroscopy, MRE- magnetic resonance enteroclysis, CTE- computed tomography enteroclysis, VCE- video capsule endoscopy.

to lack of gold standard for CD diagnosis and non-specific nature of findings on VCE. The lesions detected in VCE can be due to other causes such as non-steroidal anti-inflammatory drugs (NSAIDs) use, cryptogenic multifocal ulcerated stenosing enteritis, intestine tuberculosis, lymphoma, small bowel malignancy and intestinal Behcet's disease. VCE findings like small mucosal breaks or erosions are seen in upto 20% of normal individuals. Hence, the positive predictive value (PPV) of VCE is dependent on the patient population and criteria for CD diagnosis in VCE [13]. Lewis score (LS) can be helpful in this regard. LS <135 signifies clinically non-significant lesion. LS > 135 detects significant small bowel lesion with 83.2% overall accuracy. LS between 135–790 is mild and > 790 indicates moderate to severe disease [14].

4.2 VCE in confirmed small bowel CD

In patients with confirmed CD on ileo-colonoscopy, further small bowel evaluation is warranted irrespective of findings on ileo-colonoscopy (**Figure 2**). In this regard, dedicated small bowel cross sectional imaging (CTE/MRE) scores over VCE due to the ability to assess strictures, transmural involvement, intra-abdominal complications (abscess/fistula), extra-intestinal manifestations and anatomical distribution of the disease [2]. VCE is recommended subsequently if cross sectional imaging is non-contributory and if VCE findings could influence management. Small bowel CD only visible on VCE with normal cross sectional imaging is a new entity. A recent retrospective study have showed that it has a more favourable course compared to general CD with lower risk of complicated disease and requirement of step up therapy [15]. If VCE is indicated in confirmed CD, functional patency of the bowel should be confirmed with patency capsule given high rate of

capsule retention in known CD (upto 13%) [2, 16]. In 27–40% cases, CTE/MRE finding suggestive of small bowel stricture may preclude VCE. However, not all strictures cause significant mechanical obstruction and patency capsule can be useful in this scenario [5]. The negative predictive value for ruling out a stricture is not different between patency capsule and non-enteroclysis small bowel radiologic examination according to a retrospective study [17].

Meta-analysis by Dionisio et al. have shown that VCE was superior to small bowel follow through (SBFT)/small bowel enteroclysis (36%) and CTE (39%) with higher diagnostic yield (71%). In comparison, the diagnostic yield of VCE was inferior to MRE (79%) [18]. However, VCE is superior to CTE/MRE in diagnosing proximal small bowel lesions and detects small bowel lesions in 50% patients with previously diagnosed ileal CD [19]. VCE can also be considered when symptoms suggestive of small bowel disease (anaemia, malnutrition, pain abdomen) do not correlate with imaging findings. In a retrospective study, VCE led to a change in management in 45% cases in these settings [19]. VCE can be helpful in suspected flares of CD, where small bowel cross sectional imaging is normal [20].

Another indication of VCE is longitudinal follow up of small bowel CD to see for response to therapy such as mucosal healing [2]. Endoscopic mucosal healing has emerged as an important therapeutic target in CD as it can predict future relapses. In a prospective, observational cohort study from Israeli IBD Research Nucleus (IIRN) it was shown that VCE predicted both short and long term flare risk in patients with quiescent, asymptomatic CD. Increment in Lewis score was better than MRE global score [21]. Similarly, in a prospective study including paediatric CD patients, VCE based treat to target strategy significantly increased number of patients achieving mucosal healing or deep remission [22].

Capsule retention in established CD can be treated with an observant, conservative trial of medical therapy using steroids and/or immunomodulators failing which endoscopic retrieval with DAE can be attempted. Even in case of failure of endoscopic retrieval of retained capsule, most of the patients can be managed conservatively in the absence of obstructive symptoms [23]. Only a minority finally require surgery (**Figure 1B**). In a retrospective study of more than 2300 patients, among 301 CD patients (196 with confirmed small bowel involvement), 5 (1.6%) developed capsule retention but only 2 required surgical intervention [24].

4.3 Role of VCE scores to evaluate CD

Objective clinical activity scores are recommended to assess disease severity, small bowel involvement and response to medical therapy [2]. However, it should be borne in mind that these scores are for assessing type, location and severity of small bowel involvement but not for diagnosis of small bowel CD. For diagnosis of small bowel CD, Mow et al. proposed a cut off of more than 3 ulcers which is widely used for diagnosis of CD and has modest positive predictive value (PPV): 50–70% [25]. This however does not give any idea about location, severity and other inflammatory features such as edema and stenosis [2, 13]. There are two widely used validated scores to assess severity of small bowel CD on VCE: the Lewis score (LS) and the Capsule endoscopy Crohn's disease activity index (CECDAI) (**Tables 1 and 2**) [26, 27]. LS is based upon distribution and presence of ulcers (**Figure 3A, B**), villous edema and stenosis (**Figure 3C**). CECDAI evaluates severity of inflammation, extent of disease and stenosis. Among the two, CECDAI is simpler and was shown to be more reflective for active small bowel inflammation than LS in a comparative study [28]. There is strong correlation between LS and CECDAI but only moderate correlation with stool biomarkers such as faecal calprotectin [29]. A study showed that LS between 135–790 was equivalent to 4.9–6.9 score in CECDAI [28].

Parameters	Number	Longitudinal extent	Descriptors
First tertile			
Villous appearance	Normal - 0	Short segment - 8	Single - 1
	Edematous - 1	Long segment - 12 Whole tertile - 20	Patchy –14 Diffuse –17
Ulcer	None-0	Short segment - 5	< 1/4–9
	Single-3	Longsegment-10	1/4–1/2–12
	Few-5	Whole tertile - 15	>1/2–18
	Multiple - 10		
Second tertile			
Villous appearance	Normal - 0	Short segment - 8	Single - 1
	Edematous - 1	Long segment - 12	Patchy –14
		Whole tertile - 20	Diffuse - 17
Ulcer	None-0	Short segment - 5	<1/4–9
	Single - 3	Long segment - 10	1/4–1/2–12
	Few-5	Whole tertile - 15	>1/2–18
	Multiple - 10		
Third tertile			
Villous appearance	Normal - 0	Short segment - 8	Single - 1
	Edematous - 1	Long segment - 12 Whole tertile - 20	Patchy –14 Diffuse –17
Ulcer	None-0	Short segment - 5	< 1/4–9
	Single-3	Longsegment-10	1/4–1/2–12
	Few-5	Whole tertile - 15	>1/2–18
	Multiple - 10		
Stenosis (rated for the whole study)			
Stenosis	None-0	Ulcerated - 24	Traversed - 7
	Single –14	Non-ulcerated - 2	Not traversed - 10
	Multiple - 20		

Table 1.
The Lewis score for the assessment of small bowel lesions using small bowel capsule Endoscopy [26].

In a retrospective study on patients with established CD, VCE led to treatment escalation in 45% patients. The indications of small bowel VCE were unexplained anaemia, discrepancy between symptoms and imaging, evaluation of full extent of CD to document mucosal healing [30]. Nevertheless, the risk of capsule retention even with normal cross sectional imaging study should be kept in mind in established CD prior to VCE and hence patency capsules are strongly recommended [12].

4.4 Role of patency capsule

Patency capsule use is strongly recommended in established CD prior to small bowel VCE to assess functional patency of small bowel. Patency capsule can be used selectively (in patients with symptoms of intestinal obstruction/history of intestinal obstruction or surgery/ patients with stricture on cross sectional imaging) or non-selectively (in all CD patients). A retrospective multi-center study have shown that the risk capsule retention was not significantly different with non-selective use (2.1%) compared to elective use (1.5%). But retention rate is as high as 11% after positive patency test [31].

CECDAI Scoring System		
CECDAI	Proximal	Distal
A. Inflammation score		
0 = None		
1 = Mild to moderate edema/hyperemia/denudation		
2 = Severe edema/hyperemia/denudation		
3 = Bleeding, exudate, aphthae, erosion, small ulcer (≥ 0.5 cm)		
4 = Moderate ulcer (0.5–2 cm), pseudopolyp		
5 = Large ulcer (2 cm)		
B. Extent of disease score		
0 = None		
1 = Focal disease (single segment)		
2 = Patchy disease (multiple segments)		
3 = Diffuse disease		
C. Narrowing (stricture)		
0 = None		
1 = Single-passed		
2 = Multiple-passed		
Segmental score = A × B + C		
Total score = (A1 × B1 + C1) + (A2 × B2 + C2)		

Table 2.
The capsule endoscopy Crohn’s disease activity index (CECDAI) for the assessment of small bowel lesions using small bowel capsule Endoscopy [27].

Two types of patency capsules have been described: the Given patency capsule (M2A) and the Agile patency capsule. Agile capsule has two timer plugs compared to one timer plug in Given patency capsule. Agile capsule starts dissolving after 30 hours compared to 40–100 hours with Given patency capsule. Given capsule is composed of lactose whereas Agile capsule is composed of dissolvable components surrounding a small radio frequency identification tag which can be detectable by X ray [32, 33]. Rare cases of symptomatic intestinal occlusion have been reported with patency capsules [33, 34]. Agile capsule further reduces the risk of symptomatic intestinal obstruction. Hence, risk of symptomatic obstruction is minimal and patency capsules can be used safely. Most of the cases of abdominal pain due to obstruction is relieved by conservative measures with only a small minority requiring endoscopic or surgical intervention [33, 35].

Given unclear benefit of non-selective use of patency capsules in CD and high risk of capsule retention in CD, the use of patency capsule should be based on clinical history, imaging finding, clinician’s discretion and availability.

4.5 Assessment of postoperative CD recurrence

Intestinal resection is eventually required in upto three fourth of CD patients after 20 years of disease [36]. Postoperative recurrence after ileo-colonic resection can occur in upto 70% patients after 20 years post surgery. Ileal lesions can be scored by Rutgreet’s score at the first ileocolonoscopy (ideally at 6 months postoperatively) which help to predict post operative recurrence: i0, no lesions; i1—less

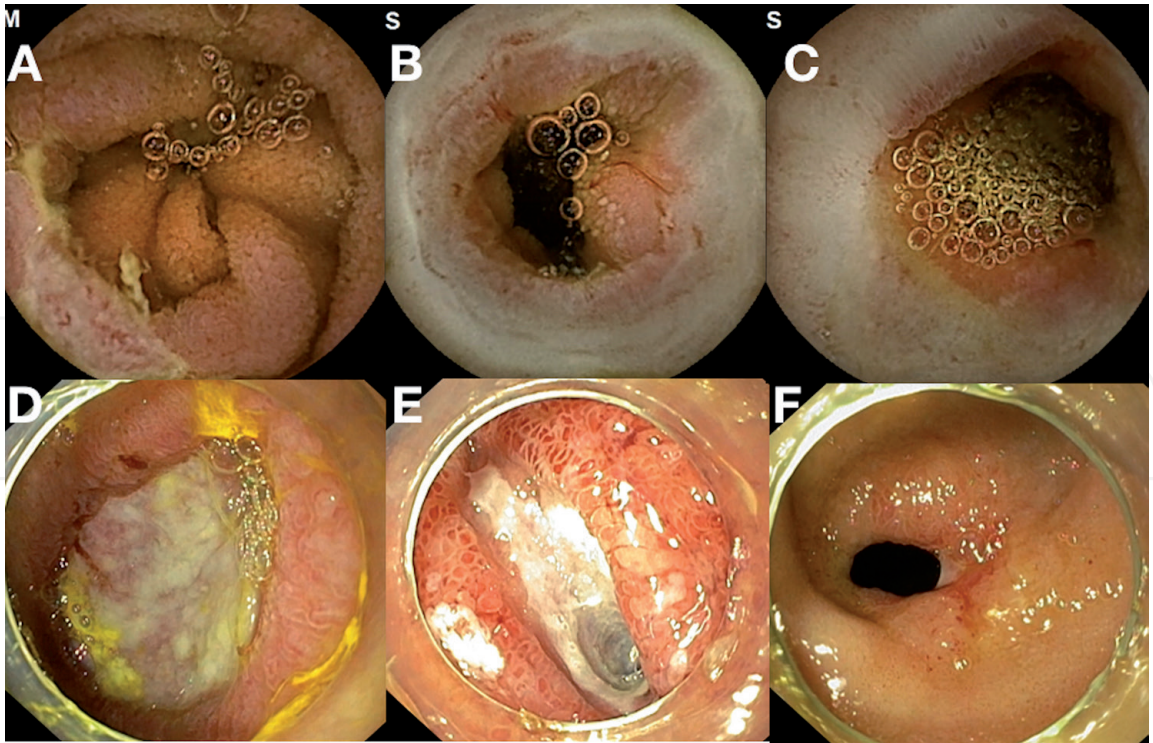


Figure 3.
Small bowel capsule endoscopy (A-C) and enteroscopy (D-F) in Crohn's disease (CD). A and B showing ulcers in CD, C. ulcerated stricture in CD, D. large deep ulcer in CD on device assisted enteroscopy (DAE), E. tight inflammatory stricture in CD, F. mildly inflamed stricture in CD on DAE.

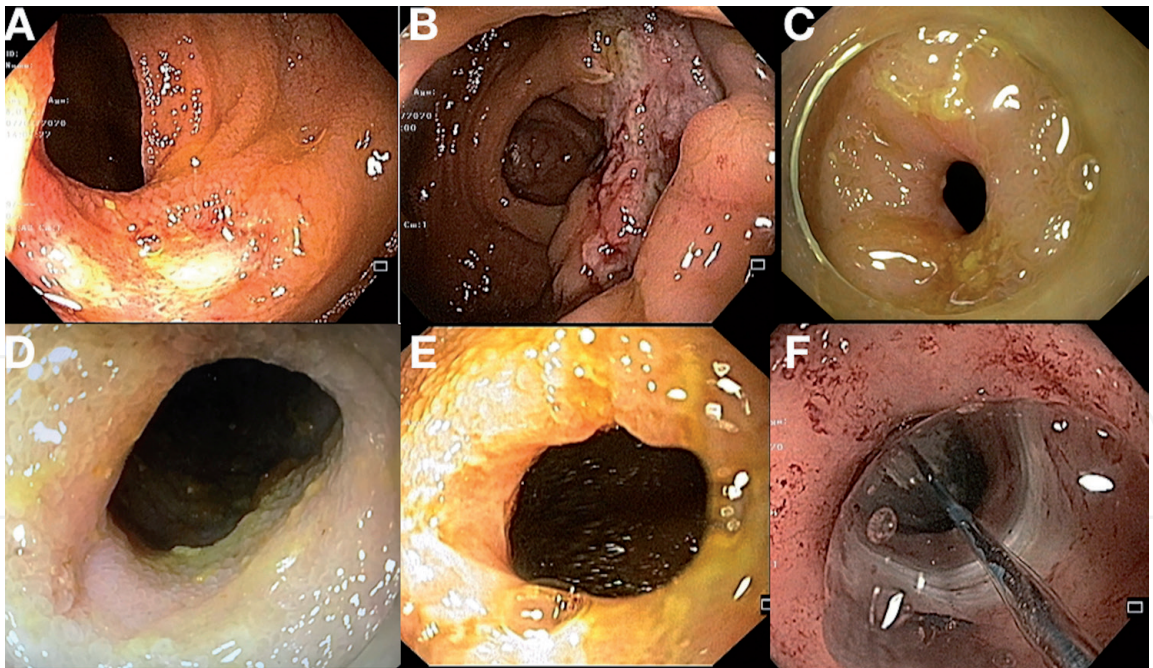


Figure 4.
Post-operative recurrence of Crohn's disease (CD) (A-B) and endoscopic management of CD strictures. A. Ileal recurrence of CD on ileoscopy. B. Anastomotic site recurrence of CD after ileo-cecal resection in CD seen on colonoscopy. C. Inflammatory stricture in CD- not ideal for endoscopic dilatation, D and E- mild or non- inflammatory fibrotic stricture - ideal for endoscopic dilatation, F. endoscopic balloon dilatation being performed in CD stricture.

than 5 aphthous lesions: i2- >5 aphthous lesions with normal mucosa between the lesions, or skip areas of larger lesions or lesions confined to the ileocolonic anastomosis (i.e., <1 cm in length); i3-diffuse aphthous ileitis with diffusely inflamed mucosa; i,4-diffuse inflammation with larger ulcers, nodules, and/or narrowing.

Apart from prediction of post operative recurrence, treatment can be decided based upon the scoring system for recurrent CD [37].

Ileo-colonoscopy is the standard test to diagnose post operative recurrence of CD (**Figure 4A, B**), but emerging data shows that VCE can diagnose CD recurrence in significantly higher number of patients compared to ileo-colonoscopy and can lead to change in management in more than half of the patients [38–40]. A recent study has shown that ileal rather than anastomotic recurrence is more likely to predict long term outcomes in CD (**Figure 4A, B**) [41]. Hence, VCE has the potential to improve clinical outcomes in postoperative CD beyond the scope of ileo-colonoscopy.

4.6 Assessment of IBD-unclassified (IBD-U)

VCE in IBD-U can detect new small bowel lesions compatible with CD in 17–70% patients. However, a normal VCE can not preclude the future evolution of new small bowel lesions suggestive of CD [42, 43]. In a study 5/25 (20%) IBD- U patients with normal VCE developed CD on follow up [44]. This is particularly important in paediatric IBD. Additional information provided by VCE can impact management in this scenario [45].

5. Enteroscopy in IBD

The drawbacks of VCE like lack of therapeutic ability, low specificity and inability to perform histological confirmation are circumvented by DAE. DAE includes double balloon enteroscopy (DBE), single balloon enteroscopy (SBE), balloon guided enteroscopy (BGE) and spiral enteroscopy. The detailed technical aspects of all DAE techniques are out of the scope of the current chapter.

5.1 SBE/DBE

SBE, in contrast to DBE does not have any balloon at the tip of the enteroscope and hence handling of the balloon control unit is easier. DBE may be preferred over SBE in the presence of adhesions. Additionally, during retrograde DAE, which is technically more difficult than antegrade DAE, SBE may be more prone to backward slippage compared to DBE due to lack of balloon at the enteroscope tip [46].

5.2 BGE

A novel through the scope (TTS), on-demand balloon assisted enteroscopy have been recently described which can be performed by push and pull technique by a disposable advancing balloon through the working channel of a colonoscope with a minimal working channel diameter of 3.7 mm. The advantage of this technique is feasibility, safety and shorter procedure duration without adverse events. The learning curve is also smaller as compared to other DAE techniques. The main drawback of this procedure is sub-optimal stability of endoscope during therapeutic procedures due to lack of aching balloon. This has been recently overcome by using a colonoscope with an integrated latex free balloon at the bending section. In a multi-centre study in adults, the average insertion length were 158 cm (50–350 cm) and 89 cm (20–150 cm) from antegrade and retrograde approach respectively, with an average procedure time of 15.5 minutes [47]. More recently, the feasibility and safety of this NaviAid AB device (Smart Medical Systems Ltd., Ra'anana, Israel) has

been shown in paediatric population [48]. Therapeutic interventions can be performed after removing the balloon catheter. This novel technique obviates the need for a enteroscope and setting up of over-tube balloons.

5.3 SE/NMSE

Spiral enteroscopy (SE) involves the use of over-tube with raised spiral edges which is rotated clockwise for advancement of enteroscope pleating small bowel loops. The over-tube has been now replaced by novel motorised spiral enteroscopy (NMSE) composed of a reusable endoscope with integrated motor permitting rotation of a short spiral over-tube in the insertion tube portion of the endoscope and a motor control unit. The motor control unit is composed of a foot pedal and visual force gauge. The advantages of NMSE are shorter procedure time, relative ease of use, high diagnostic yield (>80%), higher total enteroscopy rates (>60%) [49–51]. Therapeutic interventions like stricture dilatation and retrieval of retained capsule endoscope have been described with NMSE [52]. Due to large diameter of overtube in NMSE, it is not suitable for use in children.

5.4 Indications of DAE in CD

DAE in CD is indicated particularly in suspected isolated small bowel CD in whom ileo-colonoscopy/ small bowel cross sectional imaging are inconclusive and histological diagnosis can alter patient management (**Figure 3D-F**). In patients with established CD, DAE can diagnose and treat stenotic complications (**Figure 4C-F**), assess mucosal healing for adjusting medical therapy and precisely locate lesions to direct targeted resection (**Figure 2**) [9].

DAE in suspected and established CD is done for diagnostic and therapeutic intent respectively. In suspected CD, DAE is performed to confirm CD beyond the reach of endoscopy and ileo-colonoscopy by obtaining biopsy and thus excluding alternative diagnosis like tuberculosis and small bowel malignancy. The diagnostic yield ranges between 22–70% in suspected CD.

5.4.1 Diagnostic DAE

Diagnostic yield is particularly higher if DAE is preceded by other small bowel investigations like CTE/MRE/VCE which help to identify the lesion and guide insertion route (oral or rectal). Total enteroscopy rates in this setting ranges from 20–80% [53, 54]. Diagnostic yield of DAE is comparable to VCE according to two meta-analysis which concluded that VCE should be considered first due to non-invasive nature [55, 56]. But, histological confirmation can not be obtained by VCE which is important in areas where infections (like tuberculosis) predominate. It should be borne in mind that DAE is technically challenging specially in the presence of adhesions, associated with higher rates of complications (0.72% major complications rate, 10 times higher perforation rate compared to colonoscopy) in CD and requires deep sedation/general anaesthesia [57, 58]. Perforation risk is higher in patients with active CD, altered anatomy and anastomotic ulcerations [58]. Hence, DAE should be performed only if the findings can alter therapeutic management. In a prospective study, DAE led to step up in therapy in three forth of CD patients leading to clinical remission in nearly 90% patients [59].

Most of the studies on DAE in CD patients has been done with SBE or DBE. The diagnostic yield (**Table 3**) of DAE in suspected and known CD are 27%–79% and 53%–87% respectively. The agreement between small bowel imaging and DAE is higher in patients with known CD (75.6%) compared to those with suspected CD

Author	DAE system	Patient subgroup	Study design	Suspected CD (n)	Known CD (n)	Diagnostic yield suspected CD (%)	Diagnostic yield confirmed CD (%)	Impact on management: suspected CD (%)	Impact on management: confirmed CD (%)
Broide et al, 2020	BGE	Paediatric IBD	Prospective	15 (IBD)	16 (IBD)				
Holleran et al, 2018	SBE	Adult CD	Retrospective	13	39	39	77	69	
Tun et al, 2016	DBE	Adult CD	Retrospective	100	0				45
Christian et al, 2016	Retrograde SBE	Adult CD	Retrospective	29		41.4		17	
Rahman et al, 2015	DBE	Adult CD	Retrospective	43	38	79	87	77	82
Navaneethan et al, 2014	SBE or DBE	Adult CD	Retrospective	22	43	27	53		53
Schulz et al, 2014	DBE	Adult CD	Retrospective	16	0	69			
Urs et al, 2014	DBE	Paediatric CD	Prospective	3	5			66	100
Uchida et al, 2012	DBE	Paediatric CD	Prospective	8	4			75	75
De Riddler et al, 2012	SBE	Paediatric CD	Prospective	14	6			57	83
Di Nardo, 2012	SBE	Paediatric CD	Prospective	16	14			87	64
Möschler et al, 2011	DBE	Adult CD	Prospective	193		47			
Kondo et al, 2010	DBE	Adult CD	Retrospective	25	50	47		53	

Author	DAE system	Patient subgroup	Study design	Suspected CD (n)	Known CD (n)	Diagnostic yield suspected CD (%)	Diagnostic yield confirmed CD (%)	Impact on management: suspected CD (%)	Impact on management: confirmed CD (%)
Mensink et al, 2009	DBE	Adult CD	Retrospective	0	40	60		75	

Table 3.
Summary of studies on diagnostic yield of device assisted enteroscopy (DAE) in Crohn’s disease (CD); SBE- single balloon enteroscopy, DBE- double balloon enteroscopy, BGE- balloon guided enteroscopy [69–78, 81–86]

(36.4%). The diagnostic yield is higher if DAE is preceded by prior small bowel evaluation to decide the insertion route. The diagnostic yield drops drastically if DAE is performed for non-specific abdominal symptoms. DAE can significantly impact patient management in 17% to 82% [60–68].

5.4.2 Therapeutic DAE

DAE can be performed with therapeutic intent in established CD to dilate short (<5 cm), non-inflammatory strictures (4E-F), insert stents, inject intra-lesional steroid, remove foreign body like capsule or Bezoar and rarely to treat major haemorrhage in CD. Reported technical success for stricture dilatation ranges from 60–80% and perforation rates as high as 9% has been described [69].

Strictures in Crohn's disease (CD) are secondary to inflammation, fibrosis, or both. The risk of fibrotic stricture increases with the disease duration; such strictures are seen in 30% to 35% of patients within 10 years of diagnosis of CD [36]. Despite biologic use, the incidence of strictures remains unchanged in CD [70]. Endoscopic stricturotomy and balloon dilatation are the most common endoscopic procedures performed for CD strictures. However, both are associated with a high risk of recurrence, re-intervention and surgery.

The use of self-expanding metal stents (SEMS) have been reported for CD strictures with high technical success rate. However, it is associated with risk of perforation, stent migration, and fistula [71, 72]. Premature stent failure is the drawback of biodegradable stents, used to circumvent adverse events of SEMS. Currently available biodegradable stents are not specifically designed for CD strictures [73–75].

In a recent single-center series of CD patients, removable SEMS therapy for short (6 cm) fibrostenotic strictures of terminal ileum/ ileocolonic anastomoses was technically successful in 95.8%. The stents were removed within 7 days. On long-term follow-up (3–50 months), none of the patients required stricture-related surgery [76]. The global interventional inflammatory bowel disease (IBD) group recommendations has positioned fully covered SEMS for refractory strictures in selected patients failing balloon dilatation and endoscopic stricturotomy [77].

The technical success rate (defined as successful dilatation leading to endoscope passage) of endoscopic balloon dilatation (EBD) for CD strictures varies from 72% to 100% (**Table 4**). The clinical success, defined as improvement in patient's obstructive symptoms, is around 60%.

The dilatation diameter varied from 12.4 to 17 mm with maximum of 20 mm. The recurrence rate varied from 14% to 78.5% based on duration of follow up. In studies with more than 3 years of follow up, the recurrence rates were 48% and 78.5%, respectively. Overall, most recurrences can be successfully treated with repeat balloon dilatation with a cumulative surgery free rate of 78% at 3 years. So, long term high recurrence rates and need for repeated dilatation or surgery should be kept in mind prior to EBD for CD strictures [69, 78–82].

5.4.3 DAE in paediatric patients

DAE is safe and effective for children aged >3 years and weight > 14 kg. DAE is challenging in children due to small abdominal cavity, thinner small bowel wall and a narrow lumen requiring considerable expertise. Five studies (2 SBE, 2 DBE and 1 BGE) have evaluated the role of DAE in paediatric IBD. In these studies, DAE either led to treatment escalation or was used to perform stricture dilatation. Definitive IBD type was ascertained in patients with IBD-U after BGE in a feasibility and safety study. These studies did not report any major complications with diagnostic or therapeutic DAE. DAE related complications in paediatric patients are reported

Author	DAE system	Study design	CD (n)	Total number of dilations (per patient mean)	Dilation diameter: mean (range) (mm)	Technical success (%)	Clinical success (%)	Perforation (%)	Follow up (months)	Recurrence rate (%)
Hirai et al, 2018	SBE or DBE	Prospective	95	90 (1)	15 (8–20)	94	70	0	24	NA
Holleran et al, 2018	SBE	Retrospective	13	14 (1)	13 (12–15)	100	80	0	8	23
Sunada et al, 2016	DBE	Retrospective	85	321 (3.8)	12.4 (8–20)		87	5	41.9 (0–141)	78.5
Navaneethan et al, 2014	SBE or DBE	Retrospective	6	7 (1.16)	43	100	100	16		
Hirai et al, 2014	DBE	Retrospective	65		NA [12–18]	80	80	1.5		48
Gill et al, 2014	DBE	Retrospective	10	17 (1.8)	13.5 (10–16.5)	80	70	20		14
Hirai et al, 2010	DBE	Retrospective	25	55 (2.2)	NA [12–18]	72	72	0	11	22
Kondo et al, 2010	DBE	Retrospective	8	18 (1.5)		100	87.5	0		
Despott et al, 2009	DBE	Prospective	11	18 (2)	15.4 (12–20)	73	73	9	20.5	25
Ohmiya et al, 2009	DBE	Retrospective	16	NA	NA [8–20]	96	69	0	16	31
Pohl et al, 2007	Push enteroscopy	R	16	15 (1.5)	17 (12–20)	80	60	0	10	40
Fukumoto et al, 2007	DBE	Prospective	193	35 (1.52)	NA	NA	74	0	12	26

Table 4.

Summary of studies on endoscopic balloon dilatation of Crohn's disease small bowel strictures with device assisted enteroscopy (DAE); SBE- single balloon enteroscopy, DBE- double balloon enteroscopy, BGE- balloon guided enteroscopy [78–82].

mostly with therapeutic DAE. Overall complications with a large DBE series (n = 257) is 5.4% (10.4% in patients <10 years). The largest SBE series (n = 189) does not report any major adverse events except for transient pain and distension (28%) and one case of self limited bleeding [48, 73, 81–87].

5.4.4 Complications of DAE

Major complications like bleeding, perforation or pancreatitis with DAE are found in about 0.72% (which may be higher in patients with Crohn's disease). Rate of perforation with DAE is around 0.11% according to results of a large Japanese registry of nearly thirty thousand patients. The risk of perforation was nine fold higher in IBD patients on steroids [88]. The rate of perforation with endoscopic balloon dilatation can be as high as 9% [60]. Bleeding after DAE has been reported in around 2.5% which is mostly self limiting [61]. Pancreatitis can occur in upto 0.3% patients after DAE from antegrade approach [89]. In paediatric IBD settings, although overall complication rates of upto 5.4% is reported, none reported major complications even with therapeutic procedures [75].

6. Intra-operative enteroscopy in CD

Earlier studies have shown that IOE has useful role in surgical decision making in ulcers and strictures in CD [90, 91]. In our experience (unpublished observation), IOE helped to identify ulcers/strictures missed on initial pre-operative evaluation (31.8%, 7/22) (**Figure 1D**). In case of multiple strictures, IOE also helped in deciding the extent of surgical resection. In 30% (6/20) of the cases, strictures were severe (not allowing enteroscope passage) and rest had mild, passable strictures. Of the subjects with severe strictures (6/20), 3 were judged to have mild stricture on inspection and palpation during laparotomy. Hence, IOE has important role in guiding surgical management of small intestinal ulcers/strictures [82, 83].

7. Conclusion

Small bowel endoscopy is essential for both diagnostic and therapeutic purposes in suspected and confirmed CD. This is particularly valuable for diagnosis when upper endoscopy, ileo-colonoscopy and cross sectional small bowel imaging are non-contributory or non-diagnostic. VCE is useful if there are no obstructive symptoms or known stenosis although DAE guided biopsy is important in scenarios when alternative pathology requires exclusion specially in countries where tuberculosis is endemic. Newer devices like motorised spiral enteroscopy and balloon guided enteroscopy have revolutionised the management of small bowel CD. DAE is be safe and effective in both adults and children with CD. Apart from therapeutic interventions like foreign body retrieval, endoscopic balloon dilatation, stent placement and haemostasis; small bowel endoscopy could be useful in postoperative CD recurrence detection and document mucosal healing and response to therapy.

Conflicts of interest

None.

Financial disclosures

None.

IntechOpen

IntechOpen

Author details

Partha Pal, D. Nageshwar Reddy and Zaheer Nabi*
Asian Institute of Gastroenterology Hyderabad, Telangana, India

*Address all correspondence to: zaheernabi1978@gmail.com

IntechOpen

© 2021 The Author(s). Licensee IntechOpen. This chapter is distributed under the terms of the Creative Commons Attribution License (<http://creativecommons.org/licenses/by/3.0>), which permits unrestricted use, distribution, and reproduction in any medium, provided the original work is properly cited. 

References

- [1] Kim M, Jang HJ. The role of small bowel endoscopy in small bowel Crohn's disease: when and how? *Intest Res.* 2016 Jul;14(3):211-7. doi: 10.5217/ir.2016.14.3.211. Epub 2016 Jun 27. PMID: 27433142; PMCID: PMC4945524.
- [2] Pennazio M, Spada C, Eliakim R, et al. Small-bowel capsule endoscopy and device-assisted enteroscopy for diagnosis and treatment of small-bowel disorders: European Society of Gastrointestinal Endoscopy (ESGE) Clinical Guideline. *Endoscopy.* 2015 Apr;47(4):352-76.
- [3] van Assche G, Dignass A, Panes J et al. The second European evidence-based Consensus on the diagnosis and management of Crohn's disease: Definitions and diagnosis. *J Crohns Colitis* 2010; 4: 7-27
- [4] Jensen MD, Nathan T, Rafaelsen SR et al. Ileoscopy reduces the need for small bowel imaging in suspected Crohn's disease. *Dan Med J* 2012; 59: A4491
- [5] Bourreille A, Ignjatovic A, Aabakken L, et al., World Organisation of Digestive Endoscopy (OMED) and the European Crohn's and Colitis Organisation (ECCO). Role of small-bowel endoscopy in the management of patients with inflammatory bowel disease: an international OMED-ECCO consensus. *Endoscopy* 2009; 41:618-637.
- [6] Condino G, Calabrese E, Onali S et al. Small bowel capsule endoscopy for assessing early postoperative recurrence of Crohn's disease: a prospective longitudinal study. *Gastroenterol* 2013; 144 Suppl 1: S425
- [7] Mehdizadeh S, Chen G, Enayati PJ et al. Diagnostic yield of capsule endoscopy in ulcerative colitis and inflammatory bowel disease of un-classified type (IBDU). *Endoscopy* 2008; 40: 30-35
- [8] Shen B, Remzi FH, Santisi J et al. Application of wireless capsule endoscopy for the evaluation of iron deficiency anemia in patients with ileal pouches. *J Clin Gastroenterol* 2008; 42: 897-902
- [9] Maaser C, Sturm A, Vavricka SR, et al; European Crohn's and Colitis Organisation [ECCO] and the European Society of Gastrointestinal and Abdominal Radiology [ESGAR]. ECCO-ESGAR Guideline for Diagnostic Assessment in IBD Part 1: Initial diagnosis, monitoring of known IBD, detection of complications. *J Crohns Colitis.* 2019 Feb 1;13(2):144-164.
- [10] Lashner B. Clinical features, laboratory findings, and course of Crohn's disease. In: Kirsner JV (ed) *Inflammatory bowel disease.* 5th edn. Philadelphia: Saunders, 2000: 305-314
- [11] Banerjee R, Pal P, Mak JWY, Ng SC. Challenges in the diagnosis and management of inflammatory bowel disease in resource-limited settings in Asia. *Lancet Gastroenterol Hepatol.* 2020 Dec;5(12):1076-1088. doi: 10.1016/S2468-1253(20)30299-5. PMID: 33181087
- [12] Hilmi I, Kobayashi T. Capsule endoscopy in inflammatory bowel disease: when and how. *Intest Res.* 2020 Jul;18(3):265-274. doi: 10.5217/ir.2019.09165. Epub 2020 Jul 7. PMID: 32623876; PMCID: PMC7385570.
- [13] Tukey M, Pleskow D, Legnani P, Cheifetz AS, Moss AC. The utility of capsule endoscopy in patients with suspected Crohn's disease. *Am J Gastroenterol.* 2009 Nov;104(11):2734-9. doi: 10.1038/ajg.2009.404. Epub 2009 Jul 7. PMID: 19584828

- [14] Monteiro S, Boal Carvalho P, Dias de Castro F, et al. Capsule endoscopy: diagnostic accuracy of Lewis score in patients with suspected Crohn's disease. *Inflamm Bowel Dis* 2015; 21:2241-2246.
- [15] Chateau T, Damico F, Zallot C, Mathieu N, Peyrin-Biroulet L. Crohn's Disease Only Visible on Small Bowel Capsule Endoscopy: A New Entity. *Dig Dis Sci*. 2020 Aug 18. doi: 10.1007/s10620-020-06553-3. Epub ahead of print. Erratum in: *Dig Dis Sci*. 2020 Sep 25;; PMID: 32809105.
- [16] Liao Z, Gao R, Xu C et al. Indications and detection, completion, and retention rates of small-bowel capsule endoscopy: a systematic review. *Gastrointest Endosc* 2010; 71: 280-286
- [17] Yadav A, Heigh RI, Hara AK, et al. Performance of the patency capsule compared with nonenteroclysis radiologic examinations in patients with known or suspected intestinal strictures. *Gastrointest Endosc*. 2011 Oct;74(4):834-9.
- [18] Dionisio PM, Gurudu SR, Leighton JA et al. Capsule endoscopy has a significantly higher diagnostic yield in patients with suspected and established small-bowel Crohn's disease: a meta-analysis. *Am J Gastro- enterol* 2010; 105: 1240-1248
- [19] Dussault C, Gower-Rousseau C, Salleron J, Vernier-Massouille G, Branche J, Colombel JF, Maunoury V. Small bowel capsule endoscopy for management of Crohn's disease: a retrospective tertiary care centre experience. *Dig Liver Dis*. 2013 Jul;45(7):558-61. doi: 10.1016/j.dld.2012.11.004. Epub 2012 Dec 11. PMID: 23238033.
- [20] Kopylov U, Nemeth A, Koulaouzidis A, et al. Small bowel capsule endoscopy in the management of established Crohn's disease: clinical impact, safety, and correlation with inflammatory biomarkers. *Inflamm Bowel Dis*. 2015 Jan;21(1):93-100.
- [21] Ben-Horin S, Lahat A, Amitai MM, et al; Israeli IBD Research Nucleus (IIRN). Assessment of small bowel mucosal healing by video capsule endoscopy for the prediction of short-term and long-term risk of Crohn's disease flare: a prospective cohort study. *Lancet Gastroenterol Hepatol*. 2019 Jul;4(7):519-528. doi: 10.1016/S2468-1253(19)30088-3. Epub 2019 May 9. PMID: 31080097.
- [22] Oliva S, Aloï M, Viola F, Mallardo S, Civitelli F, Maccioni F, Hassan C, Papoff P, Cucchiara S, Cohen SA. A Treat to Target Strategy Using Panenteric Capsule Endoscopy in Pediatric Patients With Crohn's Disease. *Clin Gastroenterol Hepatol*. 2019 Sep;17(10):2060-2067. e1. doi: 10.1016/j.cgh.2018.10.015. Epub 2018 Oct 13. PMID: 30326301.
- [23] Cheon JH, Kim YS, Lee IS et al. Can we predict spontaneous capsule passage after retention? A nationwide study to evaluate the incidence and clinical outcomes of capsule retention *Endoscopy* 2007; 39: 1046-1052
- [24] Viazis N, Zacharakis G, Saprikis E et al. A single center experience of 2300 consecutive patients undergoing capsule endoscopy: indications and diagnostic yield. *Endoscopy* 2011; 43: A129
- [25] Mow WS, Lo SK, Targan SR et al. Initial experience with wireless capsule enteroscopy in the diagnosis and management of inflammatory bowel disease. *Clin Gastroenterol Hepatol* 2004; 2: 31-40
- [26] Gralnek IM, de Franchis R, Seidman E et al. Development of a capsule endoscopy scoring index for small bowel mucosal inflammatory change. *Aliment Pharmacol Ther* 2008; 27: 146-154
- [27] Gal E, Geller A, Fraser G et al. Assessment and validation of the new

- capsule endoscopy Crohn's disease activity index (CECDAI). *Dig Dis Sci* 2008; 53: 1933-1937
- [28] Omori T, Kambayashi H, Murasugi S, Ito A, Yonezawa M, Nakamura S, Tokushige K. Comparison of Lewis Score and Capsule Endoscopy Crohn's Disease Activity Index in Patients with Crohn's Disease. *Dig Dis Sci*. 2020 Apr;65(4):1180-1188. doi: 10.1007/s10620-019-05837-7. Epub 2019 Sep 20. PMID: 31541367.
- [29] Yablecovitch D, Lahat A, Neuman S, et al. The Lewis score or the capsule endoscopy Crohn's disease activity index: which one is better for the assessment of small bowel inflammation in established Crohn's disease? *Therap Adv Gastroenterol* 2018;11:1756283X17747780.
- [30] Dussault C, Gower-Rousseau C, Salleron J, Vernier-Massouille G, Branche J, Colombel JF, Maunoury V. Small bowel capsule endoscopy for management of Crohn's disease: a retrospective tertiary care centre experience. *Dig Liver Dis*. 2013 Jul;45(7):558-61. doi: 10.1016/j.dld.2012.11.004. Epub 2012 Dec 11. PMID: 23238033.
- [31] Nemeth A, Kopylov U, Koulaouzidis A, Wurm Johansson G, Thorlacius H, Amre D, Eliakim R, Seidman EG, Toth E. Use of patency capsule in patients with established Crohn's disease. *Endoscopy*. 2016 Apr;48(4):373-9. doi: 10.1055/s-0034-1393560. Epub 2015 Nov 12. PMID: 26561918
- [32] Spada C, Spera G, Riccioni M, Biancone L, PetruzzIELLO L, Tringali A, Familiari P, Marchese M, Onder G, Mutignani M, Perri V, PetruzzIELLO C, Pallone F, Costamagna G. A novel diagnostic tool for detecting functional patency of the small bowel: the Given patency capsule. *Endoscopy*. 2005 Sep;37(9):793-800. doi: 10.1055/s-2005-870246. PMID: 16116528.
- [33] Caunedo-Alvarez A, Romero-Vazquez J, Herrerias-Gutierrez JM. Patency and Agile capsules. *World J Gastroenterol* 2008; 14: 5269-5273.
- [34] Rasmussen B, Nathan T, Jensen MD. Symptomatic patency capsule retention in suspected Crohn's disease. *J Crohns Colitis* 2016; 10: 1445-1447.
- [35] Garg S, Anand R, Dubin E, Kantsevov S, Dutta S. Endoscopic management of retained patency capsules. *Endoscopy* 2014; 46: Suppl 1 UCTN:E662-3.
- [36] Cosnes J, Cattan S, Blain A, et al. Long-term evolution of disease behavior of Crohn's disease. *Inflamm Bowel Dis* 2002;8:244-50.
- [37] Rutgeerts P, Geboes K, Vantrappen G, Beyls J, Kerremans R, Hiele M. Predictability of the postoperative course of Crohn's disease. *Gastroenterology* 1990;99:956-963.
- [38] Pons Beltrán V, Nos P, Bastida G, et al. Evaluation of postsurgical recurrence in Crohn's disease: a new indication for capsule endoscopy? *Gastrointest Endosc* 2007;66:533-540.
- [39] Bourreille A, Jarry M, D'Halluin PN, et al. Wireless capsule endoscopy versus ileocolonoscopy for the diagnosis of postoperative recurrence of Crohn's disease: a prospective study. *Gut* 2006;55:978-983.
- [40] Sorrentino D, Nguyen VQ. Clinically significant small bowel Crohn's disease might only be detected by capsule endoscopy. *Inflamm Bowel Dis* 2018;24:1566-1574.
- [41] Hammoudi N, Auzolle C, Tran Minh ML, et al. Postoperative Endoscopic Recurrence on the

Neoterminal Ileum But Not on the Anastomosis Is Mainly Driving Long-Term Outcomes in Crohn's Disease. *Am J Gastroenterol*. 2020 Jul;115(7):1084-1093.

[42] Kalla R, McAlindon ME, Drew K et al. Clinical utility of capsule endoscopy in patients with Crohn's disease and inflammatory bowel disease unclassified. *Eur J Gastroenterol Hepatol* 2013; 25: 706-713

[43] Joossens S, Reinisch W, Vermeire S et al. The value of serologic markers in indeterminate colitis: a prospective follow-up study. *Gastroenterology* 2002; 122: 1242-1247

[44] Maunoury V, Sovoye G, Bourreille A et al. Value of wireless capsule endoscopy in patients with indeterminate colitis (inflammatory bowel disease type unclassified). *Inflamm Bowel Dis* 2007; 13: 152-155

[45] Min SB, Le-Carlson M, Singh N, et al. Video capsule endoscopy impacts decision making in pediatric IBD: a single tertiary care center experience. *Inflamm Bowel Dis*. 2013 Sep;19(10):2139-45.

[46] Nardo GD, Esposito G, Ziparo C, Micheli F, Masoni L, Villa MP, Parisi P, Manca MB, Baccini F, Corleto VD. Enteroscopy in children and adults with inflammatory bowel disease. *World J Gastroenterol*. 2020 Oct 21;26(39):5944-5958. doi: 10.3748/wjg.v26.i39.5944. PMID: 33132646; PMCID: PMC7584063.

[47] Ali R, Wild D, Shieh F, et al. Deep enteroscopy with a conventional colonoscope: initial multicenter study by using a through-the-scope balloon catheter system. *Gastrointest Endosc* 2015;82: 855-60.

[48] Broide E, Shalem T, Richter V, Matalon S, Shirin H. The Safety and Feasibility of a New Through-the-scope

Balloon-assisted Enteroscopy in Children. *J Pediatr Gastroenterol Nutr*. 2020 Jul;71(1):e6-e11. doi: 10.1097/MPG.0000000000002706. PMID: 32187142.

[49] Ramchandani M, Rughwani H, Inavolu P, et al. Diagnostic yield and therapeutic impact of novel motorized spiral enteroscopy in small-bowel disorders: a single-center, real-world experience from a tertiary care hospital (with video). *Gastrointest Endosc*. 2020 Jul 12:S0016-5107(20)34541-7. doi: 10.1016/j.gie.2020.07.001. Epub ahead of print. PMID: 32663489.

[50] Beyna T, Arvanitakis M, Schneider M, et al. Total motorized spiral enteroscopy: first prospective clinical feasibility trial. *Gastrointest Endosc*. 2020 Oct 31:S0016-5107(20)34934-8. doi: 10.1016/j.gie.2020.10.028. Epub ahead of print. PMID: 33144239.

[51] Beyna T, Arvanitakis M, Schneider M, et al. Motorised spiral enteroscopy: first prospective clinical feasibility study. *Gut*. 2020 Apr 24;gutjnl-2019-319908. doi: 10.1136/gutjnl-2019-319908. Epub ahead of print. PMID: 32332141.

[52] Inavolu P, Singh AP, Kanakagiri H, Reddy DN, Ramchandani M. Motorized spiral enteroscope-assisted retrieval of video capsule in a patient with Crohn's disease. *VideoGIE*. 2020 Jul 22;5(10):488-491. doi: 10.1016/j.vgie.2020.05.014. PMID: 33103006; PMCID: PMC7570370.

[53] Gay G, Delvaux M. Double balloon enteroscopy in Crohn's disease and related disorders: our experience. *Gastrointest Endosc* 2007; 66: S82 – S90

[54] Manes G, Imbesi V, Ardizzone S et al. Use of double-balloon enteroscopy in the management of patients with Crohn's disease: feasibility and diagnostic yield in a high-volume centre

for inflammatory bowel disease. *Surg Endosc* 2009; 23: 2790-2795

[55] Pasha SF, Leighton JA, Das A et al. Double-balloon enteroscopy and capsule endoscopy have comparable diagnostic yield in small-bowel disease: a meta-analysis. *Clin Gastroenterol Hepatol* 2008; 6: 671-676

[56] Chen X, Ran ZH, Tong JL. A meta-analysis of the yield of capsule endoscopy compared to double-balloon enteroscopy in patients with small bowel diseases. *World J Gastroenterol* 2007; 13: 4372-4378

[57] Xin L, Liao Z, Jiang YP et al. Indications, detectability, positive findings, total enteroscopy, and complications of diagnostic double-balloon endoscopy: a systematic review of data over the first decade of use. *Gastrointest Endosc* 2011; 74: 563-570

[58] Gerson L, Chiorean M, Tokar J et al. Complications associated with double balloon enteroscopy: the US experience. *Am J Gastroenterol* 2008; 103: S109 – S110

[59] Mensink PB, Aktas H, Zelinkova Z et al. Impact of double-balloon enteroscopy findings on the management of Crohn's disease. *Scand J Gastroenterol* 2010; 45: 483-489

[60] Navaneethan U, Vargo JJ, Menon KV, Sanaka MR, Tsai CJ. Impact of balloon-assisted enteroscopy on the diagnosis and management of suspected and established small-bowel Crohn's disease. *Endosc Int Open* 2014; 2: E201-E206

[61] Rahman A, Ross A, Leighton JA, et al. Double- balloon enteroscopy in Crohn's disease: findings and impact on management in a multicenter retrospective study. *Gastrointest Endosc* 2015; 82: 102-107 [PMID: 25840927 DOI: 10.1016/j.gie.2014.12.039]

[62] Tun GS, Rattehalli D, Sanders DS, McAlindon ME, Drew K, Sidhu R. Clinical utility of double-balloon enteroscopy in suspected Crohn's disease: a single-centre experience. *Eur J Gastroenterol Hepatol* 2016; 28: 820-825

[63] Holleran G, Valerii G, Tortora A, et al. The use of single balloon enteroscopy in Crohn's disease and its impact on clinical outcome. *Scand J Gastroenterol* 2018; 53: 925-929 [PMID: 29966446 DOI: 10.1080/00365521.2018.1476914]

[64] Di Nardo G, Oliva S, Aloï M, et al. Usefulness of single-balloon enteroscopy in pediatric Crohn's disease. *Gastrointest Endosc* 2012; 75: 80-86

[65] Kondo J, Iijima H, Abe T, et al. Roles of double-balloon endoscopy in the diagnosis and treatment of Crohn's disease: a multicenter experience. *J Gastroenterol* 2010; 45: 713-720

[66] Möschler O, May A, Müller MK, Ell C; German DBE Study Group. Complications in and performance of double-balloon enteroscopy (DBE): results from a large prospective DBE database in Germany. *Endoscopy* 2011; 43: 484-489

[67] Christian KE, Kapoor K, Goldberg EM. Performance characteristics of retrograde single-balloon endoscopy: A single center experience. *World J Gastrointest Endosc* 2016; 8: 501-507

[68] Mensink PB, Groenen MJ, van Buuren HR, Kuipers EJ, van der Woude CJ. Double-balloon enteroscopy in Crohn's disease patients suspected of small bowel activity: findings and clinical impact. *J Gastroenterol* 2009; 44: 271-276

[69] Despott EJ, Gupta A, Burling D et al. Effective dilation of small-bowel strictures by double-balloon enteroscopy in patients with

symptomatic Crohn's disease (with video). *Gastrointest Endosc* 2009; 70: 1030-1036

[70] Rieder F, Zimmermann EM, Remzi FH, et al. Crohn's disease complicated by strictures: a systematic review. *Gut* 2013;62:1072-84.

[71] Navaneethan U, Lourdasamy V, Njei B, et al. Endoscopic balloon dilation in the management of strictures in Crohn's disease: a systematic review and meta-analysis of nonrandomized trials. *Surg Endosc* 2016;30:5434-43.

[72] Lan N, Shen B. Endoscopic stricturotomy with needle knife in the treatment of strictures from inflammatory bowel disease. *Inflamm Bowel Dis* 2017;23:502-13.

[73] Loras C, Pérez-Roldan F, Gornals JB, et al. Endoscopic treatment with self-expanding metal stents for Crohn's disease strictures. *Aliment Pharmacol Ther* 2012;36:833-9.

[74] Attar A, Branche J, Coron E, et al. P608 New anti-migration extractible metal stents for Crohn's disease strictures: a nationwide GETAID-SFED cohort study. *J Crohns Colitis* 2017;11:S389-90.

[75] Karstensen JG. Biodegradable stents for the treatment of bowel strictures in Crohn's disease: technical results and challenges. *Endosc Int Open* 2016:E296-300.

[76] Das R, Singh R, Din S, et al. Therapeutic resolution of focal, predominantly anastomotic Crohn's disease strictures using removable stents: outcomes from a single-center case series in the United Kingdom. *Gastrointest Endosc* 2020;92:344-52.

[77] Shen B, Kochhar G, Navaneethan U, et al. Practical guidelines on endoscopic treatment for Crohn's disease strictures: a consensus statement from the Global

Interventional Inflammatory Bowel Disease Group. *Lancet Gastroenterol Hepatol* 2020;5:393-405.

[78] Hirai F, Beppu T, Sou S, Seki T, Yao K, Matsui T. Endoscopic balloon dilatation using double-balloon endoscopy is a useful and safe treatment for small intestinal strictures in Crohn's disease. *Dig Endosc* 2010; 22: 200-204

[79] Gill RS, Kaffes AJ. Small bowel stricture characterization and outcomes of dilatation by double-balloon enteroscopy: a single-centre experience. *Therap Adv Gastroenterol* 2014; 7: 108-114

[80] Hirai F, Beppu T, Takatsu N, et al. Long-term outcome of endoscopic balloon dilation for small bowel strictures in patients with Crohn's disease. *Dig Endosc* 2014; 26: 545-551

[81] Sunada K, Shinozaki S, Nagayama M, et al. Long-term Outcomes in Patients with Small Intestinal Strictures Secondary to Crohn's Disease After Double-balloon Endoscopy-assisted Balloon Dilation. *Inflamm Bowel Dis* 2016; 22:380-386

[82] Hirai F, Andoh A, Ueno F, et al. Efficacy of Endoscopic Balloon Dilation for Small Bowel Strictures in Patients With Crohn's Disease: A Nationwide, Multi-centre, Open-label, Prospective Cohort Study. *J Crohns Colitis* 2018; 12: 394-401

[83] Yokoyama K, Yano T, Kumagai H, Mizuta K, Ono S, Imagawa T, Yamamoto H, Yamagata T. Double-balloon Enteroscopy for Pediatric Patients: Evaluation of Safety and Efficacy in 257 Cases. *J Pediatr Gastroenterol Nutr* 2016; 63: 34-40

[84] de Ridder L, Mensink PB, Lequin MH, Aktas H, de Krijger RR, van der Woude CJ, Escher JC. Single-balloon enteroscopy, magnetic resonance enterography, and abdominal US useful

for evaluation of small- bowel disease
in children with (suspected) Crohn's
disease. *Gastrointest Endosc* 2012;
75: 87-94

[85] Urs AN, Martinelli M,
Rao P, Thomson MA. Diagnostic and
therapeutic utility of double-balloon
enteroscopy in children. *J Pediatr
Gastroenterol Nutr* 2014; 58: 204-212

[86] Uchida K, Yoshiyama S, Inoue M,
Koike Y, Yasuda H, Fujikawa H, Okita Y,
Araki T, Tanaka K, Kusunoki M. Double
balloon enteroscopy for pediatric
inflammatory bowel disease. *Pediatr Int*
2012; 54: 806-809

[87] Reddy PM, Kulkarni S, Nabi Z, et al.
Single balloon enteroscopy in children
for evaluation of small bowel diseases
in children: A large, tertiary center
study. *J Pediatr Surg*. 2020 Nov 2:S0022-
3468(20)30778-8. doi: 10.1016/j.
jped surg.2020.10.025. Epub ahead of
print. PMID: 33189296

[88] Odagiri H, Matsui H, Fushimi K,
Kaise M, Yasunaga H. Factors associated
with perforation related to diagnostic
balloon-assisted enteroscopy: analysis
of a national inpatient database in Japan.
Endoscopy 2015; 47: 143-146

[89] Gerson LB, Tokar J, Chiorean M,
et al. Complications associated with
double balloon enteroscopy at nine US
centers. *Clin Gastroenterol Hepatol*
2009; 7: 1177-1182, 1182.e1-1182. e3

[90] Hotokezaka M, Jimi SI, Hidaka H,
et al. Role of intraoperative enteroscopy
for surgical decision making with
Crohn's disease. *Surg Endosc*.
2007;21(7):1238-1242. doi:10.1007/
s00464-006-9154-z

[91] Esaki M, Matsumoto T, Hizawa K,
et al. Intraoperative enteroscopy detects
more lesions but is not predictive of
postoperative recurrence in Crohn's
disease. *Surg Endosc*. 2001;15(5):455-
459. doi:10.1007/s004640000174