

# We are IntechOpen, the world's leading publisher of Open Access books Built by scientists, for scientists

6,900

Open access books available

185,000

International authors and editors

200M

Downloads

Our authors are among the

154

Countries delivered to

TOP 1%

most cited scientists

12.2%

Contributors from top 500 universities



WEB OF SCIENCE™

Selection of our books indexed in the Book Citation Index  
in Web of Science™ Core Collection (BKCI)

Interested in publishing with us?  
Contact [book.department@intechopen.com](mailto:book.department@intechopen.com)

Numbers displayed above are based on latest data collected.  
For more information visit [www.intechopen.com](http://www.intechopen.com)



# Short and Long Term Oral Hygiene Maintenance Protocols for Traumatic Dental Injuries

*Girish Suragimath and Ashwinirani SR*

## Abstract

Traumatic dental injuries (TDIs) occur when a person undergoes trauma due to variety of reasons. Traumatic injuries are part of the growing up years and can have ever lasting wounds with scarring on the affected individuals. Treatment and rehabilitation of the teeth with traumatic injuries are essential for long term survival of the teeth. Immediate care, appropriate diagnosis and treatment with comprehensive follow-up are essential for a favorable prognosis of the affected teeth. A coordinated effort from different specialties including general dentist, oral radiologist, pediatric dentist, periodontist, oral surgeon, orthodontist and endodontist is essential for success of the treatment. Team efforts involving these different specialists will help the patient to receive successful long term outcome. Proper oral hygiene maintenance during and after traumatic dental injury, is required to stop the deterioration of the tooth and periodontal structures. The caregiver in children and the adult with traumatic dental injuries should be educated and guided about the proper oral hygiene techniques especially in the areas with dental injury. Dentist must be aware of the treatments rendered to the teeth with trauma and should have up-to-date knowledge of the oral hygiene measures to be inculcated in the subjects with dental trauma. This chapter highlights the oral hygiene measures to be followed by the subjects with TDIs and also includes measures to be followed by the dentist in such a scenario.

**Keywords:** dental trauma, interdental cleaning aids, mouth wash, oral hygiene, toothbrush, traumatic dental injuries

## 1. Introduction

Trauma to the hard and soft tissues occurs when a subject undergoes injuries due to motor vehicle accidents, physical fights; self-infested wounds, assaults, bicycle accidents or while playing sports. Other reasons of traumatic injury can be domestic abuse in adults and child abuse in children. Anterior teeth in both primary and permanent dentition are most commonly affected by dental trauma. Primary and permanent anterior teeth are not only important for esthetics but also essential for phonetics, mastication, integrity of supporting tissues, psychological and mental wellbeing [1]. Traumatic injuries are part of the growing up years and can have ever lasting wounds with scarring on the affected individuals. Dental trauma refers to injury to the oral and perioral structures i.e. teeth (enamel, dentin, pulp and cementum), gums, periodontal ligament, alveolar bone and also involves

nearby soft tissues around the teeth such as the lips, tongue, etc. Traumatic dental injuries (TDI's) are part of body injury and occur frequently in children and young adults accounting to 5% of all the bodily injuries [2]. School going children up to 25% experience dental trauma and 33% of adult's less than 19 years of age have permanent dentition trauma [3]. Incisor teeth both in maxilla and mandible are the most commonly affected teeth with highest incidence in maxillary central incisors. A prospective study in 2017 found that among patients with maxillofacial fractures, 41.8% of them had concomitant dental injuries of two or more teeth [4]. Immediate care, appropriate diagnosis and treatment with comprehensive follow-up are essential for a favorable prognosis of the affected teeth.

Dental treatment of TDI's is usually delayed and not given as much attention as general medical treatment. Immediate dental consultation and treatment could improve long-term prognosis of the injured teeth [5]. Timing of the dental care rendered to patient who have undergone trauma is critical in management and saving of the teeth. Dentist must have the essential knowledge regarding the management of patients with trauma especially during the emergency phase of treatment. Appropriate management of patients with dental trauma requires coordinated efforts of different specialties including general dentists, oral radiologist, pediatric dentist, periodontist, oral surgeon and endodontist. Team efforts involving these different specialists will help the patient to receive successful long term outcome.

When a subject undergoes a traumatic incident, he or she is mentally disturbed and may tend to get disoriented with time and space. The person with dental trauma will experience difficulty in maintaining daily oral hygiene and this leads to dental plaque accumulation. The neglect of oral hygiene during and after dental trauma will lead to gingivitis which if untreated may lead to periodontitis and tooth loss. Studies have also shown that Oral Health-Related Quality of Life (OHRQoL) is affected by TDI's and it negatively impacts on the OHRQoL of children and their families [6]. It is imperative that oral hygiene standards are maintained during and post dental trauma for the long term survival of teeth with dental trauma. Twice daily brushing with soft bristled manual brush or electric toothbrush with toothpaste, interdental cleaning with dental floss or interdental brush and use of mouth rinse every day is apt to keep the teeth and mouth clean. Dentist must educate about oral hygiene maintenance and special instructions to be followed during TDI's to patients.

## **2. Epidemiology**

The prevalence of injury and TDI's has been observed in children and young adults of every country of the world. Different authors have reported different incidences and prevalence's of TDI's from many countries. A 12-year review of the literature reports that 25% of all school children experience dental trauma and 33% of adults have experienced trauma to the permanent dentition, with the majority of injuries occurring before age nineteen [7].

A study on prevalence of TDI's conducted in India reported 59.2% of males and 40.8% of female's experienced dental injury and they concluded that males experienced more TDI's due to the outdoor activities [8]. Study conducted on Saudi Arabian children mention a incidence of TDI's is 1–3% and prevalence of 20–30%, similar results were also observed in studies conducted in Europe [9, 10]. The prevalence of missing anterior teeth as a result of dental trauma is reported as 12 per 1000 children in one cross-sectional epidemiological study [11]. A 2017 prospective study found that among patients with maxillofacial fractures, 41.8% of them had concomitant dental injuries to two or more teeth [4]. The trauma prevalence in one

study showed 10.13% children suffered TDI's and only 3.37% of the children had undergone treatment for those injuries [12]. Studies have concluded that anterior teeth with increased incisal over jet and inadequate lip coverage were significant predictors for the occurrence of TDI's [13]. Children and adolescents in the poor socio economical conditions had greater incidence of TDI's and they had not received proper treatment for those TDI's.

3. Management of traumatic dental injuries

Timing of the dental care rendered to patient who have undergone trauma is critical in management and saving of the teeth. Dentist should be aware of management and treatment of patients with trauma especially during the emergency phase (Table 1). A coordinated efforts of different specialty including general dentists, pediatric dentist, periodontist, oral surgeon and endodontist is essential. Team efforts involving these different specialists will help the patient receive successful long term prognosis [15]. Avulsion of permanent teeth is one of the most serious dental injuries, prompt and correct emergency management is essential for attaining the best outcome after this injury [16].

Description	Primary dentition	Permanent dentition
Concussion/subluxation	Observe, soft foods for 1 week, dental radiograph to rule out root fracture	Observe, soft foods for 1 week, dental radiograph to rule out root fracture
Luxation	Reposition tooth or extract, do not splint	Dental radiograph, reposition tooth, splint for 4 week
Extrusion	Reposition tooth or extract, do not splint	Dental radiograph, reposition tooth, splint for 2 week
Intrusion	Dental radiograph, observe and allow to re erupt, extract if alveolar plate is compromised	Dental radiograph, observe and allow to re erupt, surgical or orthodontic repositioning, root canal treatment
Uncomplicated crown fracture	Restore tooth, smooth sharp edges, dental radiograph to rule out root fracture	Restore tooth, smooth sharp edges, radiograph to rule out root fracture
Complicated crown fracture	Dental radiograph, pulp treatment, restore or extract tooth, observe for infection	Dental radiograph, pulp treatment, restore tooth, observe for infection, may require root canal treatment
Root fracture	Dental radiograph, extract if root fracture is in middle or cervical third of root	Dental radiograph, splint, may require root canal treatment; if in cervical third, may need to extract
Avulsion	Do not replant, dental radiograph to rule out intrusion if tooth is not located	Do not handle the root, replant within 30 min or place in recommended transport medium (balanced salt solution, cold milk); dental radiograph, replant and splint as soon as possible; systemic antibiotics, soft diet, chlorhexidine, close follow-up

Table 1.  
Dental treatment plan for traumatic injuries in the primary and permanent dentition [14].

Dentist must assess the periodontal ligament (PDL) cells of the avulsed tooth, before commencing treatment: [16].

- The PDL cells are most likely viable. The tooth has been replanted immediately or within a very short time (about 15 minutes) at the place of accident.
- The PDL cells may be viable but compromised. The tooth has been kept in a storage medium (e.g., milk, HBSS (Save-a-Tooth or similar product), saliva, or saline, and the total extra-oral dry time has been <60 minutes).
- The PDL cells are likely to be non-viable. The total extra-oral dry time has been more than 60 minutes, regardless of the tooth having been stored in a medium or not.

The treatment of TDIs patients involves five phases [2, 17–22].

- Emergency phase
- Follow up phase
- Restorative phase
- Rehabilitation phase
- Maintenance phase

### **3.1 Emergency phase**

When a patient with trauma arrives at the dental clinic, certain necessary actions have to be taken to start the treatment. Proper history of the etiology of the injury preferably in a structured checklist will be beneficial. The dentist can follow these steps for treating patients with dental trauma.

- a. The dentist must thoroughly evaluate the injury to the dental and adjacent tissues. Careful extra oral and intraoral clinical examination and radiographic investigation is essential to arrive at the diagnosis of exact damage caused by the trauma.
- b. Patient's general health and history of systemic diseases must be collected to plan the treatment accordingly.
- c. History of previous dental injuries and the treatment received by the patient for the current injury should be ascertained before starting the treatment protocol.
- d. Symptoms of central nervous system injury like vomiting, nausea, confusion, blurred vision, bleeding or fluid from ear or nose, difficulty in speech, loss of consciousness, amnesia should be assessed. The patient has to be referred to a neurologist for consultation of Central Nervous System (CNS) symptoms.
- e. Areas of pain should be re-examined properly and source, etiology and pain relief measures and medications should be prescribed accordingly.

- f. Radiographic assessment including Orthopantomogram (OPG), Intraoral periapical radiographs (IOPA) and occlusal radiographs will aid in proper judgment about the injury and its extent. Cone beam computed tomography (CBCT) can be availed in case of serious injuries such as crown/root, root and alveolar fractures, as well as luxation injuries.
- g. Thorough decontamination and disinfection of intraoral and extra oral wounds should be carried out, to rid of all the contaminants.
- h. Areas of bleeding should be detected and pressure pack, cautery or suturing of the artery can be used to stop the bleeding.
- i. Injection of Tetanus vaccine, also known as tetanus toxoid (TT) can be given to prevent spasms in the muscles.
- j. If there is fracture of maxilla or mandible, reduction of the fracture segments should be carried out and they can be stabilized with help of arch bar wiring or plates.
- k. Sutures can be placed in open wounds and dressing can be used over the extra oral wounds.

### **3.2 Immediate follow-up phase**

During the subsequent visits after three days, dentist should evaluate healing of the primary lesions and occlusion of teeth should be checked for any discrepancies. Sensitivity tests should be carried out on all teeth with trauma and the opposing teeth. Cold testing is recommended over electric pulp testing in young patients. The pulp test has to be carried out during the follow-up visits as the teeth with trauma are nonresponsive for several weeks. Dentist should help achieve complete healing of soft and hard tissue structures. Healing complications are more common in teeth with vertical fracture of teeth, trauma in supporting tissues and avulsion. Complications usually occur in the first three months and necrotic pulp was the most common complication [23].

### **3.3 Restorative phase**

The Restorative phase should include restoration of fractured and decayed teeth. Fractured teeth have to be carefully examined, for type and extent of the fracture and the need for endodontic and periodontal treatments. A multidisciplinary approach will improve the prognosis of the teeth. Non-surgical periodontal therapy (NSPT) including scaling, root planing, patient education and local drug delivery should be carried out, to keep the tissues in healthy state. Dentist must observe the gums for any inflammation and periodontal examination for periodontitis and check for ulcers or irritation due to prosthetic appliances.

### **3.4 Rehabilitation phase**

Rehabilitation phase includes occlusal corrections with orthodontic tooth movement. Psychological counseling among children will help children to overcome and forget traumatic events of TDI's. Patient should be educated and motivated to maintain healthy teeth, gums and periodontium for long term rehabilitation.

### 3.5 Maintenance phase

Maintenance phase or oral hygiene phase should be carried out during all the phases of treatment of TDI's. Regular oral hygiene maintenance with either manual or powered toothbrush should be started in immediate follow-up phase and maintained throughout life. Brushing twice daily once early morning and once before going to bed is best advised. The interdental areas between the teeth should be kept clean with appropriate interdental cleaning aids. Mouthwashes should be routinely used to maintain the overall health of oral structures like teeth, gums, periodontium, oral mucosa and tongue.

Regular visit to the dentist for periodic checkup and examination should be followed by the patients who experienced TDI's. Dentists must keep the patients with TDI's on maintenance therapy for regular interaction and follow-ups.

## 4. Oral hygiene aids

*“Correct and routine tooth brushing will soon iron out, so to speak, all the irregularities in, and restore normal colour and contour to, the gingivae ... thus, since the toothbrush may also readily aid in the resolution of these incipient symptoms, its potentiality in their prevention is evident.”*

- Hirschfeld [4].

Hirschfeld advocated tooth brushing to keep teeth and gums clean free from dental caries or periodontal diseases [24]. Cleaning of teeth and oral hygiene maintenance are carried out using toothbrushes and interdental cleaning aids. Commercially available varieties of dental products can be used to keep the mouth clean. Toothbrush with toothpaste is the most commonly employed teeth cleaning oral hygiene aid. American Dental Associations (ADA) advocates brushing of teeth twice daily, use of interdental cleaning aids regularly and oral rinse with mouthwashes every day to keep good oral health. Tooth brushing and interdental cleaning remain the mainstays of prevention of periodontal diseases. The primary approach requires individually tailored instruction for implementation of a systematic oral hygiene regimen [25].

Toothbrushes come in different designs and function.

- Manual tooth brush
- Powered toothbrush
- Sonic, Ultrasonic and Ionic toothbrushes

### 4.1 Manual toothbrush

Manual tooth brush with toothpaste is commonly used all over the world to clean the teeth. Manual toothbrushes come in different sizes and design and basically classified according to the diameter of the bristles as soft, medium and hard.

Different brushing techniques are used to clean the teeth by different individuals. Tooth brushes can be used with horizontal scrub, vertical scrub, vibratory, sweeping, rotatory motion or combination of them. Various researchers have recommended different brushing techniques like Bass, Charter's, Stillman, Fone, Leonard, Hirschfeld's, Smith-Bell and many more. Modified Bass technique also called sulcus cleansing method is advised for healthy patients with no gingival disease. Fone's technique or circular method of brushing is advised for children

as it is easy to learn. Modified Stillman's method is recommended in patients with gingival recession for gingival massage. Charter's method is most useful in patients with fixed prosthesis or orthodontic appliances and post periodontal surgery.

#### 4.2 Powered/electric toothbrush

Powered toothbrush are also called electric toothbrush, they make rapid automatic bristle movements, either to and fro or rotatory-oscillation to clean the teeth. Electric brushes can be classified according to their type of action as side to side vibration, Counter oscillation, Rotation or Circular. Compared to manual toothbrushes; electric-powered ionic ones were significantly efficient in removing plaque in the premolar and molar areas [26, 27]. Powered toothbrush manufacturers do not recommend a specific brushing method, the Swiss Dental Society, in 2001 developed an instruction manual for use of electric tooth brushes. Instructions for brushes with a sweeping and/or oscillating rotary motion are as follows:

- The brushes are positioned on the tooth surfaces in a 45-or 90-degree angle to the incisal plane.
- Only when positioned should the brush be switched to "on."
- The mouth should be almost closed.
- The brush should be moved slowly over and around each tooth for 3 to 5 seconds, making sure that the bristles clean the crevices between the teeth.
- The brush head can be lifted distally and mesially into the interproximal areas to reach the interdental area; the brush always remains on a single tooth.
- After a period of approximately 5 seconds, the brush is moved to the next tooth surface and repositioned [27].

#### 4.3 Sonic, ultrasonic and ionic toothbrushes

Sonic tooth brushes bristles vibrate at lower frequency and ultrasonic, indicates a brush action where the bristles vibrate at ultrasonic frequencies ( $> 20$  kHz). An ionic brush releases an electrical charge to the tooth surface which disrupts the attachment of dental plaque [28].

#### 4.4 Interdental cleaning aids

Interdental cleaning aids are usually dental floss, toothpick or small interdental brush and Uni-tufted brushes. The use of interdental cleaning aid depends upon the spacing between the teeth and gingival tissue in the interdental spaces. Interdental cleaning of teeth is best achieved by using interdental brushes and these brushes should therefore be the first choice in patients with open interdental spaces [29].

Several interdental cleaning aids are available for cleaning of interdental areas. The use interdental cleaning device and method can vary depending upon the type of interdental embrasure (**Table 2**).

Dental floss: Dental floss is most useful in cleaning the interdental areas where the contacts between the teeth are tight and no space is present between the teeth and there is no recession of interdental papilla. Dental floss can be used by rotating around the fingers or they also can be used with a floss holder.

Type of interdental space	Interdental cleaning device to be used
Narrow interdental space with intact interdental papillae	Dental floss or toothpick
Little interdental space with slight papilla recession	Dental floss, toothpick or small interdental brush
Wide interdental space with complete loss of interdental papilla	Interdental brush
Wide interdental space with diastema of teeth	Uni-tufted brush or gauze strip

**Table 2.**  
*Interdental space present and interdental aid to be used.*

**Toothpicks:** toothpicks are used in the tight interdental areas and it can be used as normal cleaning instrument anywhere required. Toothpicks have been used to clean teeth since ages; they come in different designs and varieties.

**Interproximal brushes:** Miniature interproximal brushes are available and they can be used in the interdental areas with slight papillary recession. Interproximal brushes are designed like a miniature bottle cleaning brushes are used in to and fro direction in the interdental areas.

**Uni-tufted brush:** Uni-tufted brushes are used in wide interdental areas with open embrasure and adjacent teeth with no contact. They help in cleaning of the open contact and make them plaque free.

**Water jet/piks:** water jets are the instruments which spray water with pulsations and pressure. Water jets have shown to be effective in removing debris from the interdental areas in patients who avoid the use of dental floss. Mouthwashes can also be used instead of the water; this increases its action due to the anti-plaque nature of the mouthwash.

#### 4.5 Tongue cleaners and mouthwashes

Tongue cleaners are used to clean the dorsal surface of the tongue, which harbors maximum number of microorganisms. Tongue cleaners are usually flat surfaced made up of wood or plastic to scrape the surface of the tongue.

An oral rinse help in promotion of good oral hygiene, reduce oral discomfort, provide moisture to oral tissues and reduce bad breath [1, 15]. Mouthwashes are essential to completely rid of microorganisms from all the parts of oral cavity. ADA advocates use of mouthwash for regular maintenance of oral hygiene. Many mouthwashes with different chemical formulations are available in the market. Chlorhexidine containing mouth washes are considered gold standard. Other chemicals used are Bisguanides, Hydrogen Peroxide, Sodium Hypochlorite, Salt and Herbal mouthwashes.

Rationale for the use of mouthwashes:

Antiseptics present in mouthwashes are effective against the bacteria found within dental plaque, when they are in a planktonic form; they show both bacterio-static and bactericidal activity.

Mouthwashes have a number of advantages:

- They are available without prescription.
- They have a good safety record.
- No significant bacterial resistance has been reported.
- They require little skill and motivation on behalf of the patient.

Mouth rinses serve a variety of purposes

- Antiplaque/Anti gingivitis Rinses

1. Therapeutic Antiseptics

- Phenol products: Listerine, Chloraseptic
- Chlorhexidine products: Peridex, Corsodyl
- Sanguinaria products: Viadent

2. Cosmetic antiplaque rinses: Plax, Close-Up Anti-Plaque

- Therapeutic Anti cavity Fluoride Rinses  
Act+, Fluorigard+, Listermint with Fluoride.
- Cosmetic Breath Freshening Mouth Rinses  
Cepacol, Lavoris, Scope, Signal, Clear Choice, Rembrandt Mouth Refreshing Rinse.
- Others
  - a. Topical antibiotic rinses
  - b. Enzyme rinses
  - c. Artificial saliva rinses
  - d. Rinses that control tartar

Types of mouthwashes.

1. First generation anti-plaque agents

- Capable of reducing plaque scores by 20–50%.

2. Second generation anti-plaque agents

- Overall plaque reduction by 70–90% and exhibit slow release properties.

3. Third generation anti-plaque agents

- Exhibit better retentive properties over second generation agents.

Triclosan and Chlorhexidine mouthwashes have been widely used in recent times. Triclosan delays plaque maturation and inhibits formation of prostaglandin leukotrienes which is a key controller of inflammation. Chlorhexidine acts against plaque and bacteria.

## 5. Oral hygiene maintenance in deciduous dentition

The primary dentition is fragile compared to the permanent dentition. The parent or the caregiver has to be delicate and gentle while brushing of teeth. It is advised to use a soft bristle brush in circular motion to clean the teeth. In the area

of trauma and teeth with trauma, extra care should be given not to hurt and cause more pain and complications to the child.

In the area of injury during the healing phase, a cotton swab dipped in 0.12% chlorhexidine or antiseptic mouthwash can be used to clean the teeth and soft tissues. The cleaning of teeth and soft tissues should be carried out twice daily morning and night.

Use of mouthwashes in children is not advised as they may swallow the mouthwash instead of rinsing. In the area, where sutures are placed toothbrush usage should be avoided and gentle cleaning with a cotton swab is advised, so that the sutures do not get disturbed. After traumatic injuries of the primary dentition, most complications are associated to infection due to caries [30]. Post trauma after complete healing of the soft tissues radiographic assessment should be carried out to see any damage to the tooth buds of permanent teeth. Deciduous teeth are not usually splinted to avoid disturbance to the permanent tooth buds. If splinting of deciduous teeth is carried out than the interdental areas below the splint fiber or wire should be kept clean by the use of interdental brushes in to and fro motion.

## **6. Oral hygiene maintenance in mixed dentition**

The mixed dentition is the period when maximum dental trauma cases occur. Professional oral hygiene like scaling and root planning can be rendered to the patients in this age group.

Tooth brushing with soft bristled brush with caution in the traumatic areas is advised. Dental flossing to keep the interdental areas clean and prevent interdental plaque accumulation has to be incorporated in the oral hygiene practice. It is important to check for the trauma to the tooth buds of permanent teeth and render treatment accordingly. If the patient is accustomed to using powered toothbrush, he or she needs to be careful while brushing around teeth with dental trauma. The use of mouthwashes to reduce plaque growth helps in easy oral hygiene maintenance. If the teeth are splinted for stabilization during healing phase, use of interdental brushes such as proxo brush is advised to keep the interdental regions clean.

## **7. Oral hygiene in dental trauma of permanent dentition**

In the permanent dentition oral hygiene around the traumatized teeth becomes vital and post trauma care is essential for long term prognosis. The teeth with traumatic injuries may have cracks, fractures, luxation or may be replanted and this alters the natural shape and structure of the teeth. Many different oral hygiene methods have to be followed to maintain hygiene around these teeth. It is better to have supra-gingival prosthesis of the fractured tooth as subgingival placement of the crown margin is plaque accumulating and leads to periodontitis if not well maintained.

## **8. Oral hygiene maintenance in special situations**

Oral hygiene maintenance methods have to be modified to meet the special clinical situations.

### **8.1 Splinted teeth**

The splint should be placed on the buccal surfaces of the maxillary teeth to enable lingual access for endodontic procedures and to avoid occlusal interference [31–34].

Splinting up to four months is advised in root fractures at the cervical third [13]. The use of semi rigid splint and flexible splints is more indicated than the rigid one as per The International Association of Dental Traumatology (IADT), and splinting done for long periods can cause root resorption or ankylosis of teeth [35, 36].

Care must be taken in teeth which are splinted during the healing phase. Interdental cleaning under and over the wire or fiber splint can be carried out with an interproximal brush.

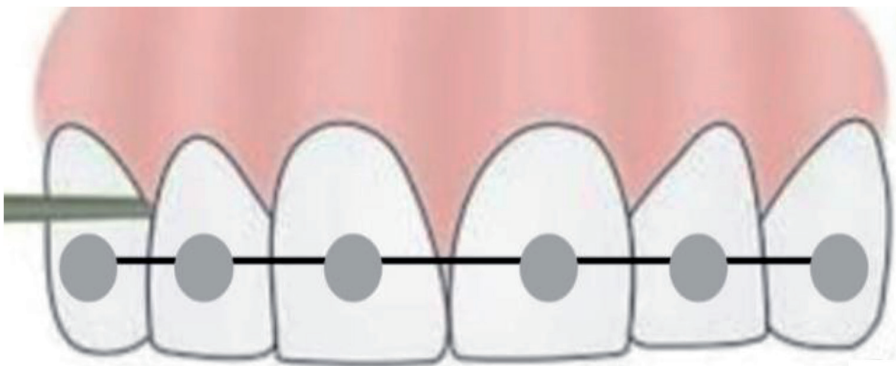
**8.2 Teeth with ligature wiring splint**

Brushing must be done carefully and mouthwash should be advised to be rinsed regularly to stop the plaque growth. Interdental brush or proxa brushes are best suited for use under the wire of splints and interdental areas.

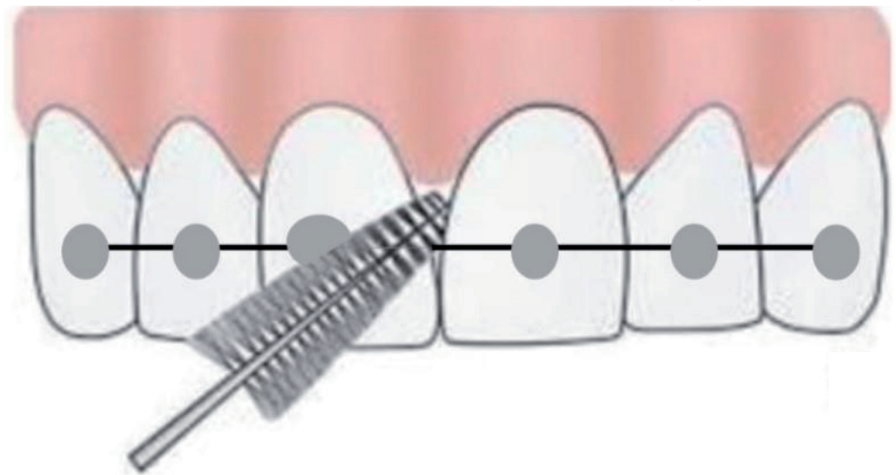
The interdental area between the teeth harbor's plaque and it has to be cleaned with interdental aids using dental floss, interdental brushes or unitufted brushes.

Dental floss a thread like material is used to clean interdental area with tight inter-dental contact. The dental floss is inserted or passed between the two teeth and moved in to and fro motion to clean the interdental area below the gum papilla. Dental floss is passed between every interdental area between teeth and activated to get rid of plaque. **Figure 1** shows the use of dental floss between upper right lateral incisor and canine.

Interdental brushes have shown to be the best in interdental cleaning. The use of interdental bushes can only be accomplished, if slight spacing is present between adjacent teeth either due to spacing or minimal gingival recession. **Figure 2** shows the use of interdental brush in between two central incisors.



**Figure 1.**  
*The use of dental floss between upper right lateral incisor and canine.*

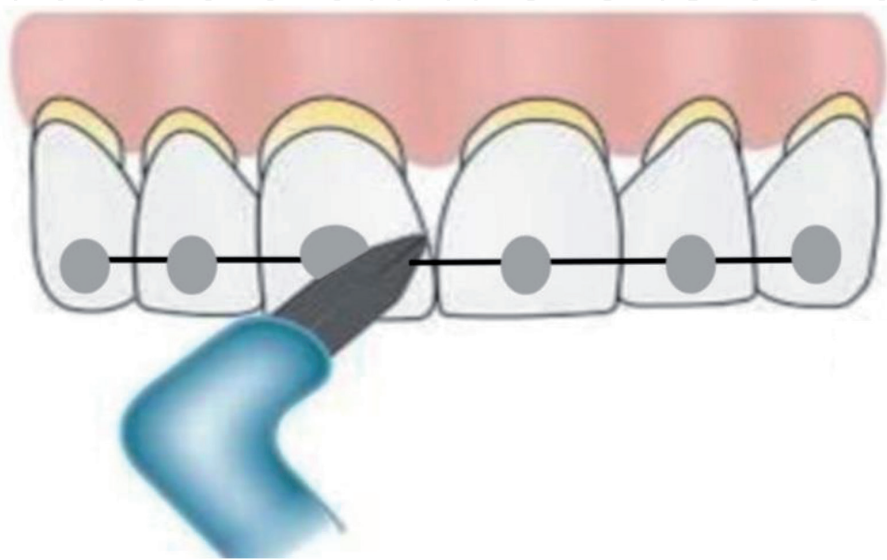


**Figure 2.**  
*The use of interdental brush between two central incisors.*

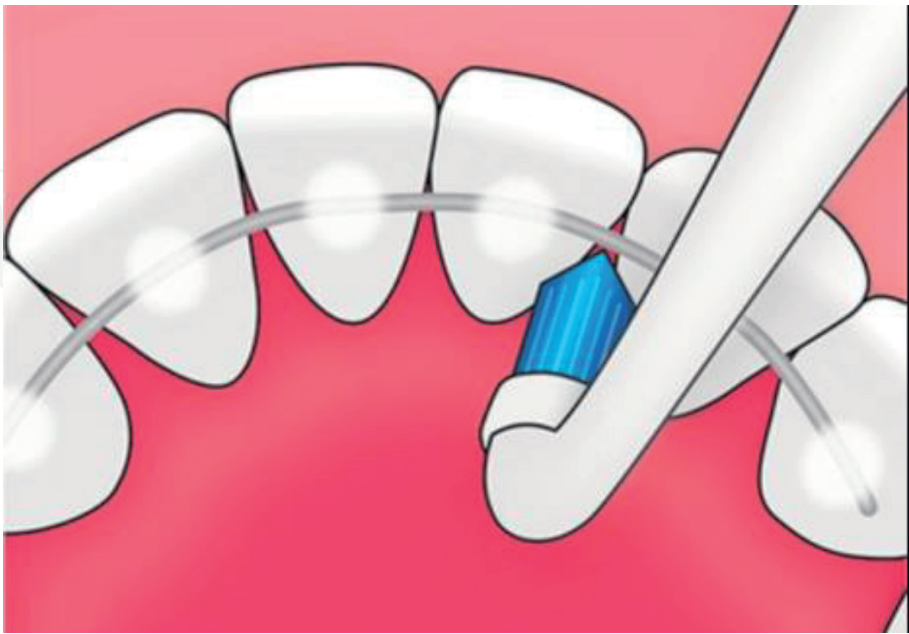
Unitufted or single tufted brushes are advocated in patients with spacing between teeth or severe gingival recession. Unitufted brushes are easy to use and effective in cases with big interdental space. **Figure 3** shows the use of unitufted brush between the two central incisors. **Figure 4** shows the use of unitufted brush on the lingual side under beneath the ligature or fiber splint.

8.3 Sub gingival fracture

Teeth with sub gingival fracture line should be observed closely and maintained plaque free otherwise, gingivitis and periodontitis can develop and jeopardize the prognosis of the tooth.



**Figure 3.**  
*The use of unitufted brush between two central incisors below the dental splint.*



**Figure 4.**  
*The use of unitufted brush on the lingual surface of mandibular anterior teeth below the dental splint.*

#### **8.4 Teeth with prosthesis**

Teeth with crowns and bridges should be monitored regularly for excess cement or leakage of the cement, which can be plaque accumulating. The margins of prosthesis should be placed supra gingivally whenever possible and have to be monitored regularly for periodontal health.

#### **8.5 Composite restoration**

Brushing on the teeth with composite build-up, inlay or onlay restoration should be carried out with caution. These teeth should not be brushed vigorously to avoid abrasion of the composite material and exposure of fracture line.

#### **8.6 Removable denture**

Removable dentures and any device or bite guard used by the patient should be removed and cleaned after every meal to avoid bacteria, fungi, plaque and tartar growth. The oral mucosa covered by the prosthesis, including the palate, must be cleaned at least once a day with a soft toothbrush. Mechanical cleaning of prosthesis under running water with help of denture brush should be done both on outer and inner surfaces [3].

#### **8.7 Permanent tooth avulsion ('Knock Out of tooth')**

- Hold the tooth by its crown (white part). Do not touch the root (Yellow part).
- Wash the teeth for ten seconds under cold tap water. Do not scrub.
- Replant the tooth in the original socket in jaw.
- Bite on handkerchief (to hold in position).
- Refer to the dental office for fixation and antibiotics.
- If the tooth cannot be replanted, place the tooth in cold milk and refer to the dental office immediately (within 20 min) [3].

#### **8.8 Long term maintenance of TDI's**

- The teeth that undergo TDI's have to be maintained for a long time as there may be occurrence of complications such as pulp necrosis, root resorption and root ankylosis.
- Regular follow-up and prompt treatment will improve the overall prognosis and improve the quality of life in the affected individual.
- Follow up of TDI's up to 5 years has been advocated by International Association of Dental Traumatology [37].

## **9. Conclusion**

The research of published data suggests that there is a lack of proper knowledge on emergency dental first-aid among the parents, care givers, school authority and general public. In most of the countries worldwide, no attempt has been made by the government or other dental organizations to educate people on the management of dental trauma. TDI's are an important general and public health issue and public awareness of its importance should be bolstered to enable equitable access for injury care. Greater emphasis on prevention and the significance of emergency care for dental injuries will reduce the financial burden of the individual and improve the quality of life [6].

Research conducted to assess the treatment and management of TDI's have shown that the treatments provided at emergency care units are often inadequate and patients remain unsatisfied with care provided. The International Association of Dental Traumatology (IADT) has given a comprehensive guidelines management of TDI's, which can be accessed via Internet ([www.iadt-dentaltrauma.org](http://www.iadt-dentaltrauma.org)) [38]. The IADT recently developed a core outcome set (COS) for traumatic dental injuries (TDI) in children and adults, these guidelines should be followed and, even in extreme situations, replantation of teeth should always be considered [39]. Interactive website has been introduced for clinicians (Dental Trauma Guide, [www.dentaltraumaguide.org](http://www.dentaltraumaguide.org)) which can be used by dentist and health care workers either via computer or smart phone during a trauma situation [40]. Mobile phone based free App was introduced by IADT (IADT ToothSOS Mobile App) to help user to take care of a dental trauma at the scene of an accident.

Dental injuries cause both periodontal and pulpal complications. The delay in dental consultation for TDI's increases the amount of complications that develop later during the maintenance. Time lapse between the TDI's and the date of dental consultation is a decisive element in the therapeutic choice and influences the prognosis [5]. The parents and individuals should be educated to consult a dentist immediately after trauma and take prompt treatment for the TDI's to reduce the complications that develop at the later date.

There is need for refinement of dental curriculum for the management of TDI's in terms of design, content, teaching methodology and long term maintenance for better prognosis of the patients with dental trauma [41].

The prevalence of TDI's in Europe and many other continents is one in five school going children and if untreated they affect the quality of life of children. The environment of the school and action taken towards management of TDI's is very crucial. Schools with supportive social and physical environment have fewer occurrences of TDI's. Schools should adopt health and safety policies, improvements in the physical environment and closer supervision of children while playing will reduce the occurrence of TDI's [42]. School teachers and physical instructors should be educated about emergency management of TDI's and consult child specialist and dentist at the earliest to lessen post traumatic complications. Studies have pointed out that health promotion policies, safe environment at the schools, correction of predisposing risk factors of TDI's and use of protective intraoral and extra oral devices while physical activity will lessen the financial burden caused by TDI's [43]. Conducting health educational programs to improve the level of general knowledge about prevention and managing TDI's at the schools is necessary [44].

Parents, Education authorities, and children involved with sports and recreation activities should be educated about the risk factors involved and management of TDI's. Screening programs to identify children with high anatomic (incisal over jet and inadequate lip coverage) and behavioral risk for occurrence of traumatic injury and necessary corrective measures (preventive orthodontic treatment and use

of Mouth guards) will help reduce the occurrence of injury among children [45]. Mounting posters, leaflets at public places along with media campaigns using television, social networking sites and internet will educate people for managing avulsed permanent teeth [1]. The teachers and school management should be educated about TDIs and emergency care and referral to dentist as schools with good physical structures and promote health activities had lesser prevalence of TDIs [46, 47].

The dentist treating TDIs must involve other specialists including Oral Radiologist, Pediatrician, Paedodontist, Endodontist, Periodontist, Prosthodontist, Orthodontist and Oral maxillofacial Surgeon. Dentist must capture good quality photographs of the TDIs and lesions and can use them to discuss the treatment protocol with specialists. Studies have proved that photographic assessment method of dental trauma was valid and reliable as compared to the oral clinical examination [48].

Dentist must be aware of different types of TDIs and its immediate treatments [49]. Dentist should educate good oral hygiene maintenance techniques to the patients suffering from TDIs. During the healing and splinting of teeth, oral hygiene cleaning with interdental brushes will help the patients.

Complications even with the best of treatment guidelines followed occur occasionally and pulp necrosis is the most observed complication [12]. Dentist must refer the patient to other specialists whenever deemed necessary. Combined efforts of different specialists will improve the prognosis of the teeth and soft tissues.

**Conflict of interest**

“The authors declare no conflict of interest.”

**Notes/thanks/other declarations**

We would like to thank Dr. Reema Shah and Dr. Harshada Zagade postgraduate students in Periodontology for editing and preparation of the figures.

**Acronyms and abbreviations**

TDI's	Traumatic Dental Injuries
OHRQoL	Oral Health-Related Quality of Life
PDL	Periodontal Ligament
IADT	International Association for Dental Traumatology
CNS	Central Nervous System
IOPA	Intraoral periapical radiographs
OPG	Orthopantomogram
CBCT	Cone beam computed tomography
TT	Tetanus Toxoid
ADA	American Dental Association
NSPT	Non-Surgical Periodontal Therapy

IntechOpen

### **Author details**

Girish Suragimath<sup>1\*</sup> and Ashwinirani SR<sup>2</sup>

1 Department of Periodontology, School of Dental Sciences, Krishna Institute of Medical Sciences Deemed to be University, Karad, Maharashtra State, India

2 Department of Oral Medicine and Radiology, School of Dental Sciences, Krishna Institute of Medical Sciences Deemed to be University, Karad, Maharashtra State, India

\*Address all correspondence to: drgirishsuragimath@gmail.com

### **IntechOpen**

© 2021 The Author(s). Licensee IntechOpen. This chapter is distributed under the terms of the Creative Commons Attribution License (<http://creativecommons.org/licenses/by/3.0>), which permits unrestricted use, distribution, and reproduction in any medium, provided the original work is properly cited. 

## References

- [1] Pujita C, Nuvvula S, Shilpa G, Nirmala S, Yamini V. Informative promotional outcome on school teachers' knowledge about emergency management of dental trauma. *J Conserv Dent*. 2013 Jan;16(1):21-7. doi: 10.4103/0972-0707.105293. PMID: 23349571; PMCID: PMC3548340.
- [2] Andreasen JO, Lauridsen E, Gerds AT, Ahrensburg SS. Dental Trauma Guide: A source of evidence-based treatment guidelines for dental trauma. *Dent Traumatol*. 2012;28:142-147.
- [3] DiAngelis AJ, Andreasen JO, Ebeleseder KA, Kenny DJ, Trope M, Sigurdsson A, Andersson L, Bourguignon C, Flores MT, Hicks ML, Lenzi AR, Malmgren B, Moule AJ, Pohl Y, Tsukiboshi M. Guidelines for the Management of Traumatic Dental Injuries: 1. Fractures and Luxations of Permanent Teeth. *Pediatr Dent*. 2016 Oct;38(6):358-368. PMID: 27931478.
- [4] Ghosh, R., Gopalkrishnan, K. and Adirajaiah, S. Association of dental injuries with maxillofacial fractures: a 10-year retrospective study. *Oral Surg*. 2017;10: 210-215. doi:10.1111/ors.12253
- [5] Kallel I, Douki N, Amaidi S, Ben AF. The incidence of complications of dental trauma and associated factors: a retrospective study. *Int J Dent*. 2020;2020:2968174.
- [6] Milani AJ, Alves NF, Espirito-Santo TM, Ribeiro LG, Ammari MM, Antunes LS et al. Impact of Traumatic Dental Injuries on Oral Health-Related Quality of Life of Preschool Children and Their Families Attending a Dental Trauma Care Program. *Port J Public Health*. 2019;37(1):19-25. doi: 10.1159/000501525
- [7] Glendor U. Epidemiology of traumatic dental injuries – a 12 year review of the literature. *Dent Traumatol* 2008;24: 603-611.
- [8] Das M, Reddy L V, Singh S. Prevalence of traumatic dental injuries among 5-16 years-old children and knowledge of teachers in the management of dental injuries. *J Indian Assoc Public Health Dent* 2019;17:328-332.
- [9] Al-Ansari A, Nazir M. Prevalence of dental trauma and Receipt of Its Treatment among Male School Children in the Eastern Province of Saudi Arabia. *Scientific World Journal*. 2020;2020:1-6. doi:10.1155/2020/7321873.
- [10] Andreasen JO, Ravn JJ. Epidemiology of traumatic dental injuries to primary and permanent teeth in a Danish population sample. *Int J Oral Surg*. 1972;1(5):235-239. doi: 10.1016/s0300-9785(72)80042-5. PMID: 4146883.
- [11] Chadwick BL, White DA, Morris AJ, Evans D, Pitts NB. Non-carious tooth conditions in children in the UK, 2003. *Br Dent J*. 2006 Apr 8;200(7):379-384. doi: 10.1038/sj.bdj.4813424. PMID: 16607325.
- [12] Govindarajan M, Reddy VN, Ramalingam K, et al. Prevalence of traumatic dental injuries to the anterior teeth among three to thirteen-year-old school children of Tamilnadu. *Contemp Clin Dent* 2012;3(2):164-167. DOI: 10.4103/0976-237X.96819.
- [13] Levin, L, Day, PF, Hicks, L, et al. International Association of Dental Traumatology guidelines for the management of traumatic dental injuries: General introduction. *Dent Traumatol*. 2020; 36: 309-313. <https://doi.org/10.1111/edt.12574>
- [14] Keels MA, Section on Oral Health, American Academy of Pediatrics. Management of dental trauma in a primary care setting. *Pediatrics*. 2014 Feb;133(2):e466–e476. DOI: 10.1542/peds.2013-3792.

- [15] Emerich K, Gazda E. Review of recommendations for the management of dental trauma presented in first-aid textbooks and manuals. *Dent Traumatol*. 2010 Jun;26(3):212-216. doi: 10.1111/j.1600-9657.2010.00900.x. PMID: 20572837.
- [16] Fouad AF, Abbott PV, Tsilingaridis G, Cohenca N, Lauridsen E, Bourguignon C, et al International Association of Dental Traumatology guidelines for the management of traumatic dental injuries: 2. Avulsion of permanent teeth. *Dent Traumatol*. 2020 Aug;36(4):331-342. doi: 10.1111/edt.12573. Epub 2020 Jun 13. PMID: 32460393.
- [17] Azodo CC, Erhabor P. Management of tooth mobility in the periodontology clinic: An overview and experience from a tertiary healthcare setting. *Afr J Med Health Sci* 2016;15:50-57.
- [18] Dental Trauma Guide. IADT treatment guidelines, Avulsion- First aid for avulsions 2019. Available from: <https://dentaltraumaguide.org/free-dental-guides/permanent-teeth/avulsion/>. [Accessed 05 October 2020].
- [19] Day PF, Kindelan SA, Spencer JR, Kindelan JD, Duggal MS. Dental trauma: part 2. Managing poor prognosis anterior teeth--treatment options for the subsequent space in a growing patient. *J Orthod*. 2008 Sep;35(3):143-155. doi: 10.1179/146531207225022590. PMID: 18809778.
- [20] Diangelis AJ, Andreasen JO, Ebeleseder KA, Kenny DJ, Trope M, Sigurdsson A, Andreasen L, Bourguignon C, Flores MT, Hicks ML, Lenzi AR, Malmgren B, Moule AJ, Pohl Y, Tsukiboshi M; International Association of Dental Traumatology. International Association of Dental Traumatology guidelines for the management of traumatic dental injuries: 1. Fractures and luxations of permanent teeth. *Dent Traumatol*. 2012 Feb;28(1):2-12. doi: 10.1111/j.1600-9657.2011.01103.x. Erratum in: *Dent Traumatol*. 2012 Dec;28(6):499. PMID: 22230724.
- [21] Andersson L, Andreasen JO, Day P, Heithersay G, Trope M, Diangelis AJ, et al. International Association of Dental Traumatology. International Association of Dental Traumatology guidelines for the management of traumatic dental injuries: 2. Avulsion of permanent teeth. *Dent Traumatol*. 2012 Apr;28(2):88-96. doi: 10.1111/j.1600-9657.2012.01125.x. PMID: 22409417.
- [22] Andreasen JO, Andreasen FM, Bakland LK, Flores MT, Andersson L. *Traumatic dental injuries, a manual*, 3rd edn. Chichester, West Sussex: Wiley-Blackwell; 2011. p. 48-53.
- [23] Soares TR, Luiz RR, Risso PA, Maia LC. Healing complications of traumatized permanent teeth in pediatric patients: a longitudinal study. *Int J Paediatr Dent*. 2014 Sep;24(5):380-386. <https://doi.org/10.1111/ipd.12082>
- [24] Hirschfeld I. Tooth-brush trauma recession: A clinical study. *J Dent Res*. 1931;11:61-63.
- [25] Fotinos S. Panagakos and Cesar A. Migliorati (February 19th 2014). Concepts of Oral Hygiene Maintenance that Would Apply for the Different Groups of Patients, Diagnosis and Management of Oral Lesions and Conditions: A Resource Handbook for the Clinician, Cesar A. Migliorati and Fotinos S. Panagakos, IntechOpen, DOI: 10.5772/57597. Available from: <https://www.intechopen.com/books/diagnosis-and-management-of-oral-lesions-and-conditions-a-resource-handbook-for-the-clinician/concepts-of-oral-hygiene-maintenance-that-would-apply-for-the-different-groups-of-patients>.

- [26] Scannapieco FA, Gershovich E. The prevention of periodontal disease-An overview. *Periodontol* 2000. 2020 Oct;84(1):9-13. doi: 10.1111/prd.12330. PMID: 32844421.
- [27] Heasman PA, McCracken GI. Powered toothbrushes: a review of clinical trials. *J Clin Periodontol* 1999;26:407-420.
- [28] Singh G, Mehta DS, Chopra S, Khatri M. Comparison of sonic and ionic toothbrush in reduction in plaque and gingivitis. *J Indian Soc Periodontol*. 2011 Jul-Sep; 15(3): 210-214. doi: 10.4103/0972-124X.85662
- [29] Slot DE, Dörfer CE, Van der Weijden GA. The efficacy of interdental brushes on plaque and parameter of periodontal inflammation: a systematic review. *Int J Dent Hyg*. 2008; 6:253-264.
- [30] Flores MT. Traumatic injuries in the primary dentition. *Dent Traumatol*. 2002 Dec;18(6):287-298. doi: 10.1034/j.1600-9657.2002.00153.x. PMID: 12656861.
- [31] Von Arx T, Filippi A, Lussi A. Comparison of a new dental trauma splint device (TTS) with three commonly used splinting techniques. *Dent Traumatol* 2001; 17: 266-274.
- [32] Kathariya R, Devanoorkar A, Golani R, Shetty N, Vallakatla V, Bhat MY, *et al*. To splint or not to splint: The current status of periodontal splinting. *J Int Acad Periodontol* 2016;18:45-56.
- [33] Jamal S, Motiwala MA, Ghafoor R. Conventional and contemporary approaches of splinting traumatized teeth: A review article. *J Pak Med Assoc*. 2020 Feb;70(Suppl 1)(2):S53-S59. PMID: 31981337.
- [34] Geeta T, Preethi S. Management of complex crown root fracture using fibre post – A case report. *Endodontology* 2014;26(3):211-216.
- [35] Nicolau B, Marcenes W, Sheiham A. The relationship between traumatic dental injuries and adolescents' development along the life course. *Community Dent Oral Epidemiol* 2003;31:306-313
- [36] Goswami M, Eranhikkal A. Management of Traumatic Dental Injuries Using Different Types of Splints: A Case Series. *Int J Clin Pediatr Dent* 2020;13(2):199-202.
- [37] Sharif MO, Tejani-Sharif A, Kenny K, Day PF. A systematic review of outcome measures used in clinical trials of treatment interventions following traumatic dental injuries. *Dent Traumatol*. 2015; 31: 422-428.
- [38] Lopes LB, Botelho J, Machado V. Severe Case of Delayed Replantation of Avulsed Permanent Central Incisor: A Case Report with Four-Year Follow-Up. *Medicina (Kaunas)*. 2020 Sep 25;56(10):503. doi: 10.3390/medicina56100503. PMID: 32992684; PMCID: PMC7599862.
- [39] Kenny KP, Day PF, Sharif MO, Parashos P, Lauridsen E, Feldens CA, *et al*. What are the important outcomes in traumatic dental injuries? An international approach to the development of a core outcome set. *Dent Traumatol*. 2018;34:4-11.
- [40] Andersson L. Epidemiology of traumatic dental injuries. *J Endod*. 2013;39(3 Suppl):S2–S5.
- [41] Mahmood IA, Morshidi DNA, Hamzah SH, Baharuddin IH, Ahmad MS. Malaysian Dental Students' Knowledge of Managing Dental Trauma in Children. *Eur J Dent Educ*. 2020 Nov 20. doi: 10.1111/eje.12632. Epub ahead of print. PMID: 33217767.

[42] Malikaew P, Watt RG, Sheiham A. Prevalence and factors associated with traumatic dental injuries (TDI) to anterior teeth of 11-13 year old Thai children. *Community Dent Health* 2006;23:222-227.

[43] Patel M C, Sujana S G. The prevalence of traumatic dental injuries to permanent anterior teeth and its relation with predisposing risk factors among 8-13 years school children of Vadodara city: An epidemiological study. *J Indian Soc Pedod Prev Dent* 2012;30:151-157

[44] Rouhani A, Movahhed T, Ghoddusi J, Mohiti Y, Anilhashemi E, Akbari M. Anterior Traumatic Dental Injuries in East Iranian School Children: Prevalence and Risk Factors. *Iran Endod J.* 2015;10(1):35-38.

[45] Suhad H. Al-Jundi Dental emergencies presenting to a dental teaching hospital due to complications from traumatic dental injuries. *Dent Traumatol.* 2002;18:181-185.

[46] McIntyre J.D. Lee J.Y. Trope M. et al. Effectiveness of dental trauma education for elementary school staff. *Dent Traumatol.* 2008; 24: 146-150.

[47] Quezada-Conde, MDC, Alvarez-Velasco, PDL, Lopez, EF, et al. Influence of school environment on occurrence of traumatic dental injuries in 12 years old children. *Dent Traumatol.* 2020; 36: 510-517. <https://doi.org/10.1111/edt.12559>

[48] Pinto, G.d.S., Goettems, M.L., Brancher, L.C., da Silva, F.B., Boeira, G.F., Correa, M.B., dos Santos, I.d.S., Torriani, D.D. and Demarco, F.F. Validation of the digital photographic assessment to diagnose traumatic dental injuries. *Dent Traumatol.* 2016;32: 37-42. doi:10.1111/edt.12204

[49] Namdev R, Jindal A, Bhargava S, Bakshi L, Verma R, Beniwal D. Awareness of emergency management of dental trauma. *Contemp Clin Dent.* 2014;5:507