

We are IntechOpen, the world's leading publisher of Open Access books Built by scientists, for scientists

6,900

Open access books available

185,000

International authors and editors

200M

Downloads

Our authors are among the

154

Countries delivered to

TOP 1%

most cited scientists

12.2%

Contributors from top 500 universities



WEB OF SCIENCE™

Selection of our books indexed in the Book Citation Index
in Web of Science™ Core Collection (BKCI)

Interested in publishing with us?
Contact book.department@intechopen.com

Numbers displayed above are based on latest data collected.
For more information visit www.intechopen.com



The Cervical Hybrid Arthroplasty

Pablo Pazmiño

Abstract

The cervical hybrid arthroplasty is a surgical option for appropriately indicated patients, and high success rates have been reported in the literature. Complications and failures are often associated with patient indications or technical variables, and the goal of this chapter is to assist surgeons in understanding these factors.

Keywords: cervical hybrid arthroplasty, cervical disc arthroplasty, disc replacement, artificial disc replacement (ADR), cervical artificial disc replacement (C-ADR), anterior cervical discectomy and fusion (ACDF), radiculopathy, myelopathy, cervical degenerative disc disease, cervical disc herniation, herniated disc

1. Introduction

Spine surgeons and patients together are confronted with several surgical options when managing cervical pains which have not responded to conservative treatment options. Multilevel cervical disc pathology is defined as two or more segments of the cervical spine that have herniated, or degenerated, which are subsequently causing significant axial pain with radiculopathy, resulting in disability and a loss of productivity. Anterior cervical discectomy and fusion (ACDF) is considered the gold standard treatment for multilevel cervical spondylosis. However there are some long term drawbacks involving the development of subsidence, pseudarthrosis and the degeneration of adjacent segments [1–4]. Cervical artificial disc replacement (C-ADR) has been demonstrated to be a safe and effective means of treating single-level or multilevel cervical disc pathology by several prospective studies from the United States Food and Drug Administration and by some meta-analyses [5–11]. In patients who have multilevel pathology, there is a growing enthusiasm towards definitive management in the form of a cervical hybrid arthroplasty [12–15]. The cervical hybrid arthroplasty is a procedure wherein an artificial disc replacement can be placed at one level, with a cervical fusion device implanted at another nearby injured disc (**Figure 1**).

2. Methodology

2.1 Indications

While indications for both fusions and arthroplasty are always in a state of flux certain considerations can be made to this point. Both implants share similar clinical goals of decreased pain with increased function, and therefore there is considerable overlap in regards to their surgical indications. As a general rule both fusions and arthroplasty can be indicated for any skeletally mature patient who has neck pain and/or radiculopathy which has failed a course of six weeks of conservative nonoperative therapy.

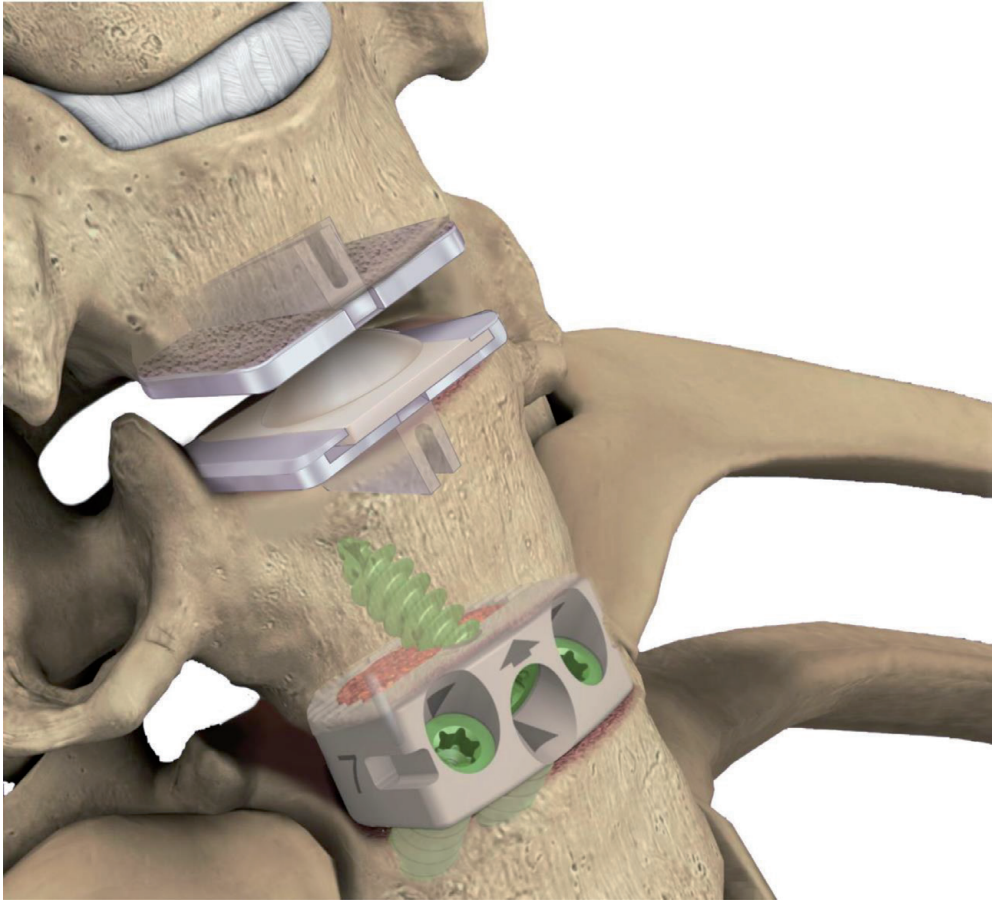


Figure 1.
The cervical hybrid arthroplasty.

Nonoperative treatments vary among medication, therapy, traction, chiropractic, acupuncture, activity modification, epidural injections and pain management.

Cervical hybrid arthroplasty Inclusion Criteria:

- Has cervical disc pathology at two [2] cervical levels (from C3 C7) requiring surgical treatment and involving intractable radiculopathy, neck pain and/or myelopathy.
- Has a herniated disc and/or osteophyte formation at each level to be treated that is producing symptomatic nerve root and/or spinal cord compression. The pathology correlates directly with documented findings on patient history and exam (e.g., neck pain with arm pain, functional deficit and/or neurological deficit), and the requirement for surgical treatment is confirmed by imaging studies (e.g., MRI, CT, x-rays, etc.).
- Has the presence of progressive symptoms or signs of nerve root/spinal cord compression despite continued non-operative management.
- Has no prior surgical intervention at the involved levels or any subsequent planned/staged surgical procedure at the involved or adjacent level(s).
- The cervical disc arthroplasty implant can be considered for symptomatic patients within the earlier stages of disc pathology, prior to bony collapse and significant spurring in order to limit postoperative heterotopic ossification.
- Must be at least 18 years of age and be skeletally mature at the time of surgery

2.2 Contraindications

Often with cervical pathology a fusion based implant is warranted, so for the purpose of this chapter we will set our focus on contraindications specific to the arthroplasty implant.

- Advanced abnormal changes such as bony collapse at the proposed surgery level.
- Advanced degeneration or trauma to the facet joints on the back of the spine.
- An active systemic infection or infection at the surgical site.
- An unnatural shape (e.g. hyperkyphosis deformity, hyperlordosis deformity) of the neck.
- A known allergy to titanium, stainless steel, polyurethane, polyethylene or ethylene oxide residuals.
- A known allergy to PEEK, ceramic, or the given implants requisite metallurgy.
- Has documented or diagnosed cervical instability relative to adjacent segments at either level, defined by dynamic (flexion/extension) radiographs showing:
 - Sagittal plane translation >3.5 mm, or
 - Sagittal plane angulation >20°;
- Has severe pathology of the facet joints of the involved vertebral bodies.
- Has been previously diagnosed with osteopenia or osteomalacia.
- Has been previously diagnosed with diagnosis of osteoporosis.
- If the level of bone mineral density is a T score of –1.5 or lower.
- Has presence of spinal metastases.
- Has overt or active bacterial infection, either local or systemic.
- Has chronic or acute renal failure or prior history of renal disease.
- Has received drugs or therapies that may interfere with bone metabolism within two weeks prior to the planned date of spinal surgery (e.g., chemotherapy, radiation, steroids or methotrexate), excluding routine perioperative anti-inflammatory drugs.
- Has a history of an endocrine or metabolic disorder known to affect osteogenesis (e.g., Paget's Disease, renal osteodystrophy, Ehlers-Danlos Syndrome, or osteogenesis imperfecta).
- Has a condition that requires postoperative medications that interfere with the stability of the implant, such as steroids, chemotherapy, or radiation. (This

does not include low-dose aspirin for prophylactic anticoagulation and routine perioperative anti-inflammatory drugs).

- Has a history of heterotopic ossification [16, 17].
- Has a history of a prior failed or delayed fusion at the proposed arthroplasty level.

3. Implants

3.1 Arthroplasty implants

Since 1955 there have been several accounts of a variety of implants which were the harbinger of the modern day cervical arthroplasty. Initial reports of disc replacements ranged from methylmethacrylate injections to unconstrained spheres composed of various substances ranging from silicone, rubber, and stainless steel [18–20]. Early arthroplasty designs never achieved much in the form of widespread practical application as they were forsaken after sparse clinical use. However, early success with lumbar disc replacements ushered in a new era of spinal arthroplasty in the cervical spine. In 1991 the Bristol/Cummins disc is credited as the first of the modern articulating Cervical Artificial Disc Replacement (C-ADR) devices which was implanted in 20 patients and was reported to be functional in several for as long as 12 years postoperatively [21]. Since then an array of designs have flooded the marketplace with materials ranging from metal-on-metal, metal-on-plastic, non-articulating metal bonded to plastic, plastic embedded in cloth, polymer fibers wound around a polycarbonate urethane core, and PEEK on PEEK [17, 22–24]. Despite a wide array of designs and formulations, manufacturers have been unable to emulate and reproduce the mechanical and load bearing properties of the innate human disc. Therefore the various axial and shear loads are still being transferred to the index and neighboring adjacent levels. In order to offset these loads different bearing designs have been conceived, each of which vary based on the amount of impedance, restraint and stability they confer to the spinal unit and dorsal facet joints. Implants without any mechanical impedance built in are considered unconstrained and allow for significant mobility while sacrificing some implant stability. Constrained devices impede movement of the spinal unit within the range of normal physiologic motion and infer greater implant stability by removing shear forces on the facet joints, but in turn place significant stress on the surfaces at the vertebral endplate-implant junction. Semiconstrained implants allow motion just outside the physiologic norm in effort to theoretically decrease the mechanical stresses felt at both at the facet joints and the interface between the implant and the bony surfaces. While often successful, these varied designs have also brought with them a concomitant range of complications with documented occurrences of extrusions, heterotopic ossification, osteolysis, and hardware failure [16, 23, 25–28].

3.2 Fusion implants

Following implantation of the disc replacement a successful cervical hybrid arthroplasty is conditional upon a solid foundation in the form of the adjacent fusion. Fusion implants can be grouped into stand alone versus standard plate and interbody cage designs. Often Allograft, Carbon fiber, Polyetheretherketone (PEEK), and titanium (Ti) have been designated for interbody cage designs. Each material varies in regards to their unique biocompatibility, surface topography, osseointegration, and imaging characteristics. Some implant manufacturers are also borrowing traits from other designs in efforts to improve upon attributes they lack. For example some designers are taking the

once inert PEEK cage and bio-actively coating them with either Hydroxyapatite (HA) or Ti, creating a composite design in efforts to improve osseous integration.

4. Surgical rationale and decision making

4.1 Implant placement and rationale

The cervical hybrid arthroplasty provides the unique opportunity where with one procedure the surgeon can address an area of junctional kyphosis while simultaneously preserving motion at a neighboring disc. When considering all scenarios for a cervical hybrid surgery, there should be a consistent rationale in regards to which level to fuse and in which level to place the arthroplasty.

For the most part there are some straightforward scenarios which dictate which level warrants the cervical fusion implant. If one disc is entirely collapsed, demonstrates significant bony spurs, and/or heterotopic ossification, this level would assuredly justify the fusion implant. If the operative level lies within the inferior aspect of the spine (i.e. Cervical 6–7, C7-T1) sufficient reasoning exists towards the insertion of a fusion spacer at this level as opposed to an arthroplasty. This is because along the inferior limb of the cervical spine, the sub adjacent interspace levels are morphologically larger and well documented as demonstrating less motion [29–31]. Their size and innate stiffness coupled with the stability conferred by their adjoining anatomy makes these levels are ideally suited towards forming the foundation of the hybrid construct and bearing any subsequent transferred loads [31–33]. By contrast, the interspaces along the more cephalad aspect of the spine (Cervical 2–3, Cervical 3–4) routinely comprise a smaller footprint and consequently can only accommodate a smaller implant. As a result these smaller interspaces are often ideally suited towards fusion spacers which tend to come in more sizes and options. Furthermore if there is any indication of ongoing myelopathy or an underlying contiguous myelomalacia, this level would best be served with a fusion implant which would provide a stable postoperative environment. Otherwise in patients who have myelopathy only those without instability and symptoms due to soft disc herniations with or without minor spurs would be good candidates for an arthroplasty.

The core principle behind all arthroplasties is their perceived objective, once implanted, towards minimizing the biomechanical stresses placed on adjacent levels. With this in mind deciding which level should obtain the arthroplasty device is of paramount importance. As a rule of thumb, all efforts are geared towards placing the arthroplasty at the top of the overall construct in order to minimize stress at the superior neighboring and often more mobile disc [29, 34]. When this is not possible, in a circumstance where there are three disc herniations and the decision has been made only to operate on two of the discs because they are the only symptomatic levels, then the arthroplasty should be placed at the level nearest the third disc in hopes of preventing it from further deterioration. Studies have shown that the arthroplasty implant would limit transmission of angular, horizontal, and translation forces experienced by the adjacent third level disc [35–40].

4.2 Sequence of implantation

The sequence of implantation should be considered well in advance during the preoperative planning phase in order to limit complications. During insertion, tapping of the implants with the mallet can lead to an aggravation of an underlying stenotic area, or the migration and loosening of a previously inserted prosthesis [41, 42]. In order to avoid this for all cervical hybrid arthroplasty procedures a

thorough decompression of all the intended disc spaces should be performed prior to any implant insertion, with priority given to the most stenotic level. In all circumstances the C-ADR should be implanted prior to the ACDF portion of the procedure. If implanting more than one arthroplasty, all trialing, rasping, drilling for both prostheses should be performed prior to C-ADR implantation [41, 43].

5. Surgical technique and pearls

5.1 Patient positioning

Patients commonly notice posterior neck pain following disc arthroplasty. The pain can be a result of surgical positioning, intraoperative distraction on the facet joints and capsules, or an indirect distraction on the endplates from the implant itself. Often these implants are inserted with a considerable amount of force so in order to limit the unsupported transfer of these forces to the paraspinal musculature and facet joints, a properly contoured support should be placed along the posterior aspect of the neck (**Figure 2a**).

5.2 Surgical approach and discectomy

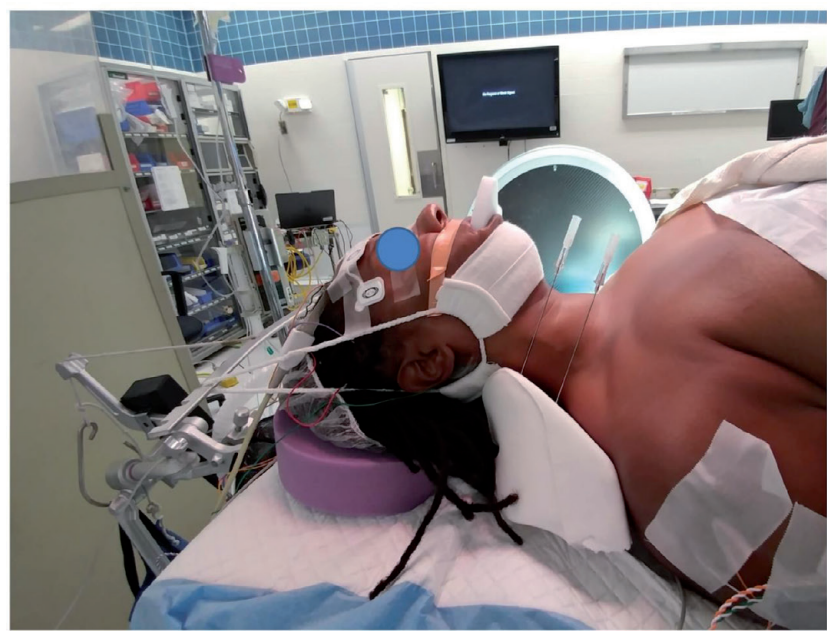The cervical hybrid arthroplasty is performed in the supine position under general anesthesia. A transverse incision in line with the planned arthroplasty level is employed for two- or three- level hybrid procedures (**Figure 2a**). Alternatively a longitudinal incision can be used for a more extensive procedure such as a multilevel procedure requiring corpectomies at the fusion level. Implantation of the arthroplasty always demands optimal visualization and therefore the incision should be inline with the proposed arthroplasty interspace while taking into consideration both the trajectory needed and the requisite instrumentation (**Figure 2b**). With that in mind following the skin incision, a standard Anterior Smith Robinson approach provides sufficient access to whichever interspace the surgeon plans to address first. After complete discectomy the endplates are denuded of all cartilaginous tissue with curettage prior to removal of any posterior uncinates or bone spurs. Prior to its removal the posterior longitudinal ligament is inspected for any tears or defects, which may give rise to sequestered fragments causing impingement on the thecal sac or neuroforamina. Once the discectomy has been performed care should be taken to remove any anterior or posterior osteophytes in order to contour the interspace inline with the proposed implant, and in doing so ensure a secure fit.

5.3 Measuring intraoperative depth

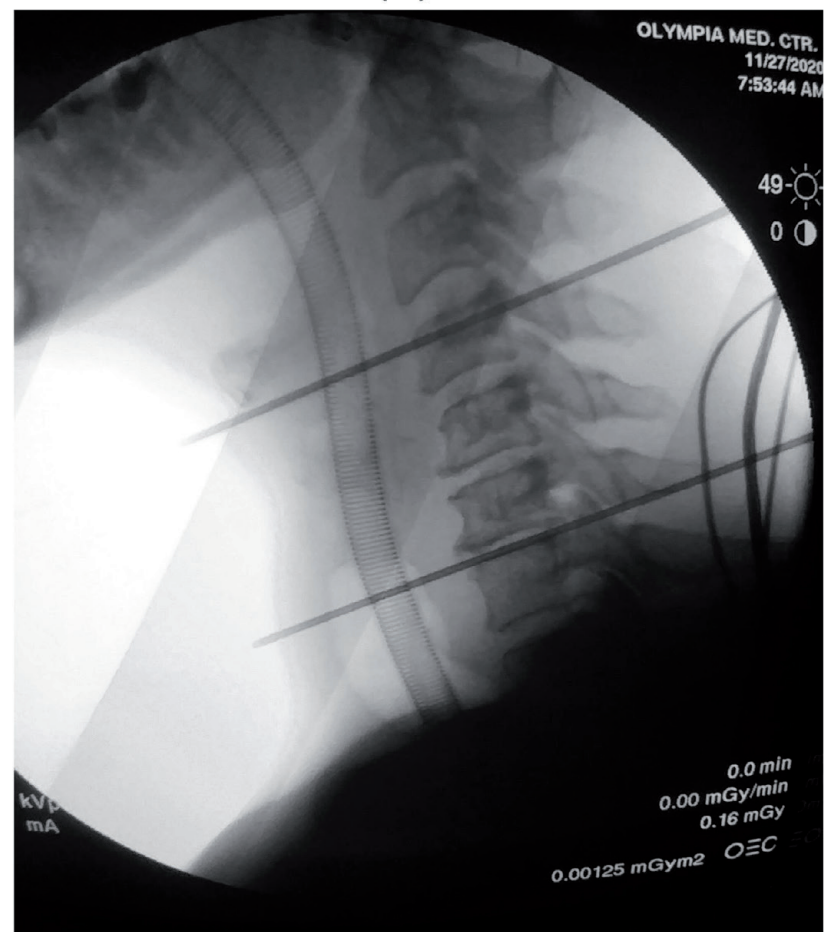
The width and depth of the intended arthroplasty can be assessed prior to even selecting a trial with the placement of an intraoperative ruler (**Figure 3a, b, Video 1**). Predetermination of the dimensions of the trial for the arthroplasty can easily be attained in this manner and thereby avoids catastrophic implant or trial related complications and consequences [42].

5.4 Midline placement

During a cervical hybrid arthroplasty the C-ADR implant should routinely be placed first so no adjacent plate or hardware obstructs any anatomic or fluoroscopic visualization. In order to secure proper midline positioning during intraoperative placement some arthroplasty implants have instrumentation designed to help verify



(a)



(b)

Figure 2.
(a) The cervical spine is supported here with a foam cushioned pillow, often used by the anesthesiologists when placing the patients in a prone position. In this case the foam cushion supports the neck by acting as a counter force to any horizontal translational or shear forces at play during final implant tapping and placement. Here a cervical bite block is used and a 10 lb. weight allows for axial traction through a neck holster. During surgery this same neck holster can be pulled by the anesthesiologist to allow indirect distraction of the interspace and therefore ease placement of the prosthesis and fusion spacers intraoperatively. The C-arm, pictured here, is left in the lateral position for the majority of the case. (b) Coincidentally the cushion also provides a stable surface where needles can be placed to confirm the length of the surgical incision for a longitudinal skin incision preoperatively.

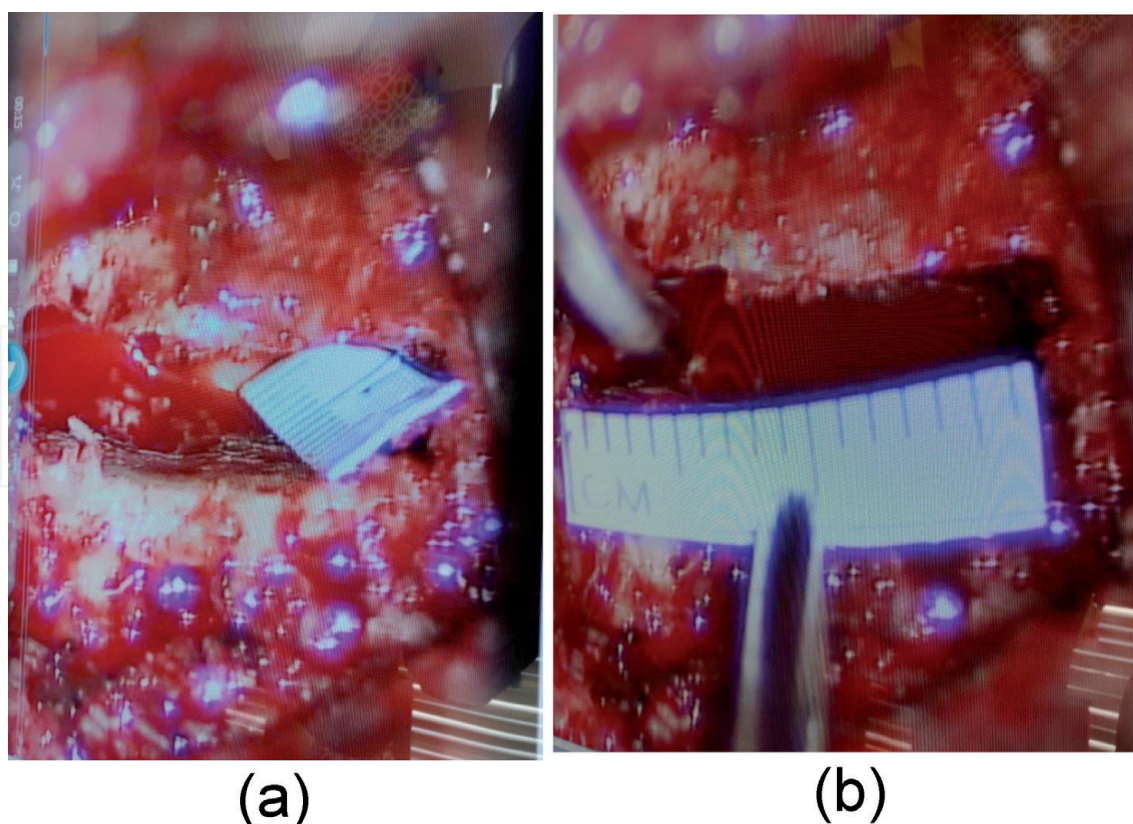


Figure 3.

(a) A standard ruler is cut to 16 mm and this ruler can then be placed within the interspace to evaluate the depth of the trial, and therefore implant needed. (b) This ruler can then be placed within the interspace to evaluate the width of the trial, and therefore implant needed.

the ideal location. This is important because minimizing prosthetic deviation to within 1.2 mm of the ideal center midline position, has been shown to ensure no detrimental clinical outcomes or long term repercussions [44]. In order to secure proper midline positioning first a collinear Anterior Posterior (AP) fluoroscopic view must be secured in line with the intended interspace (**Figure 4**). Once an appropriate image has been obtained, accurate midline positioning of the prosthesis can be confirmed (**Figure 5a-c**). In order to confirm proper midline positioning attention should be made towards discrete morphological and anatomical landmarks. First with visual inspection, confirming equidistant placement of the trial in regards to the longus colli. On fluoroscopy the spinous processes should lie en face and midline with respect to their corresponding vertebral bodies. The edges of the trial should lie equidistant with respect to each of the ascending bilateral uncinat joints. Final midline placement can be confirmed with fluoroscopic visualization (**Figure 5a**).

5.5 Measuring fluoroscopic depth

Most implant trials come with a drill, chisel, or similar device used to cut grooves in the vertebral body for insertion of the final implant. In order to confirm final implant placement the final imaging obtained while trialing can be compared with the spinal implant to confirm final and accurate positioning (**Figure 6a-c**).

5.6 Final implantation

After midline confirmation under fluoroscopy of the arthroplasty attention should be made towards sealing any exposed cancellous surfaces with bone wax in

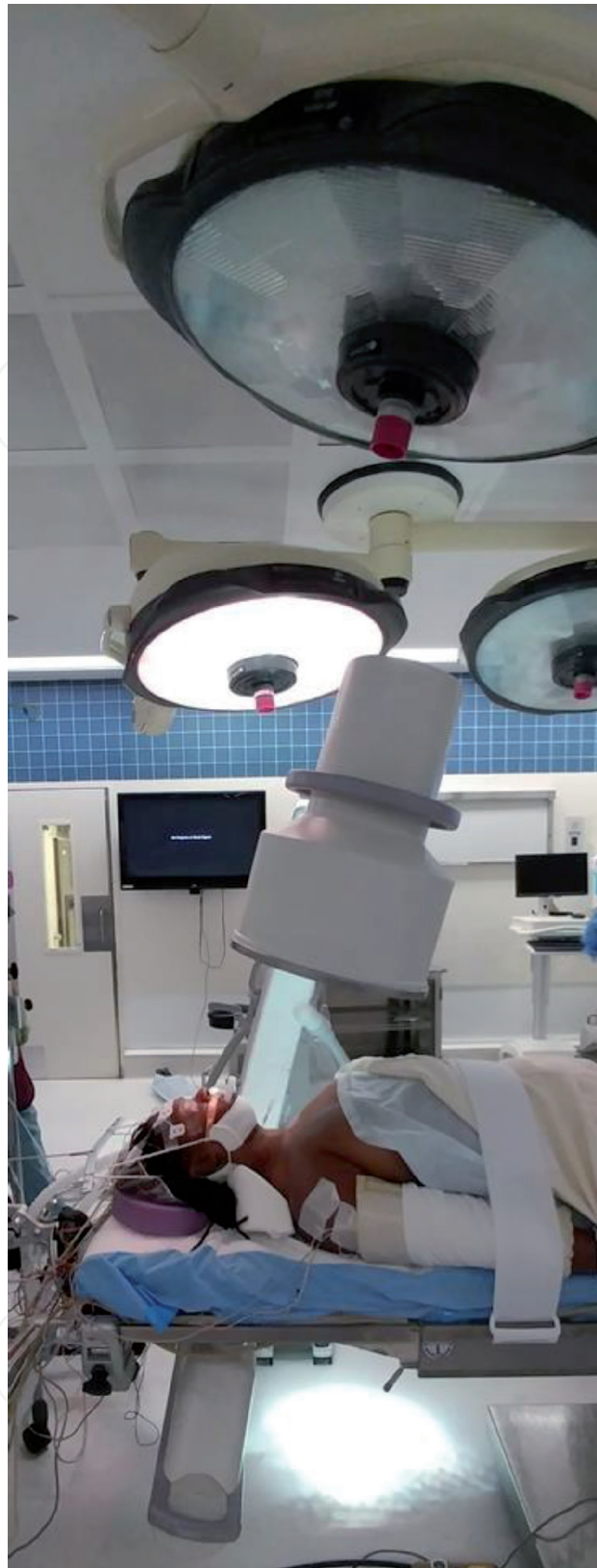


Figure 4.
Ferguson view is an AP view of the cervical disc space taken with opening of collimation and caudal tilt angulation of the x-ray tube 30° to 35°.

order to prevent heterotopic ossification. Next retractors can be repositioned at the adjacent level for placement of the fusion implant in standard fashion. If using a plate attention should be paid towards the proximity of the plate in regards to the adjacent disc space as this has been found to be the critical determinant of adjacent level heterotopic ossification [45, 46].

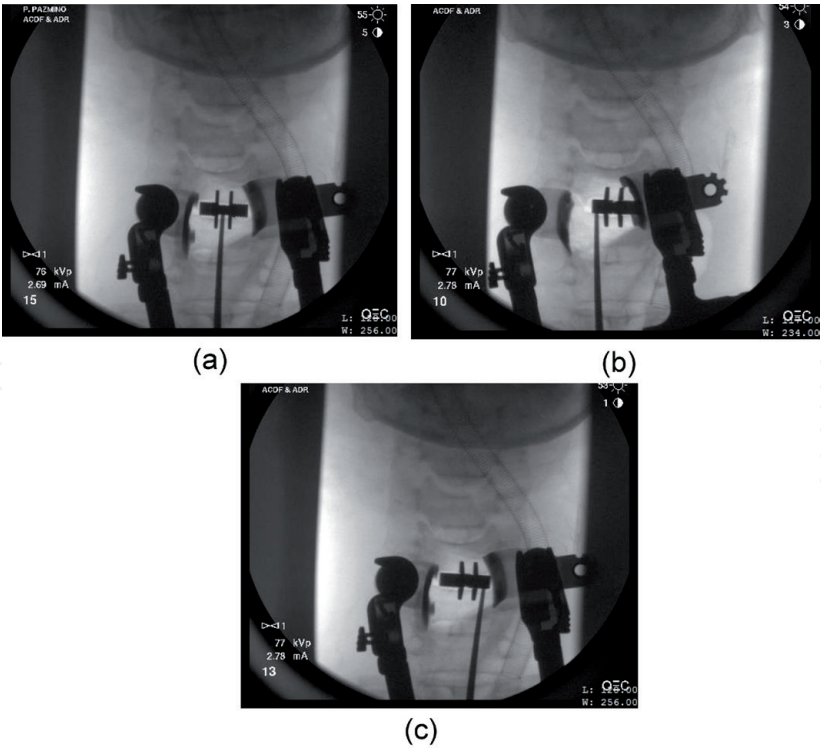


Figure 5.
(a) Proper midline positioning of the prosthesis can be confirmed fluoroscopically with placement of a nerve hook within the instrumentation until a center center “field goal” view is obtained. The nerve hook is clearly bisecting the flanges of the trial. Drilling in this orientation will lock in an appropriately midline positioned implant. (b) Improper midline placement: Here the nerve hook is no longer bisecting the flanges of the implant which confirms the implant is malrotated towards the right, the retractor needs to be loosened and repositioned so that the trial can be repositioned accordingly. (c) Improper midline placement: Here the nerve hook is no longer bisecting the flanges of the implant which confirms the implant is malrotated towards the left and needs to be repositioned accordingly.

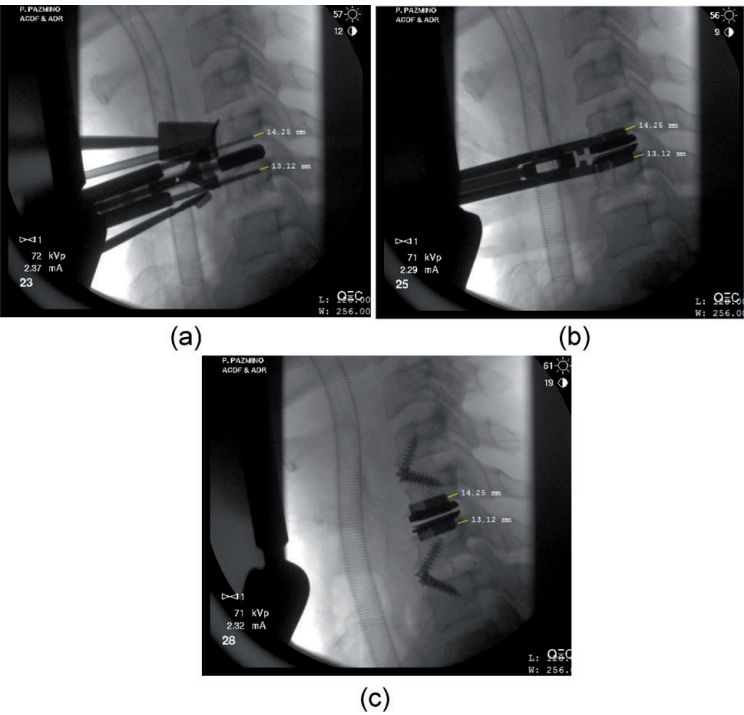


Figure 6.
(a) Prior to removal of the trial, discrete measurements can be taken to confirm the exact depth of the insertion of the drill bit. Measurements are obtained from the tip of the drill to the posterior margin of each vertebral body. (b) This depth can then be compared to the implant positioning as tapping occurs to confirm final placement of the arthroplasty. Measurements are obtained from the tip of the implant to the posterior margin of each vertebral body. (c) A final xray and measurements can be obtained to ensure the final implant has not moved after removal of the instrumentation. This will help confirm if any final tamping needs to be performed.

6. Case studies

6.1 Case 1 C56 ADR C67 ACDF

51 year old female who presents with cervical pains which she describes as 80% neck pain and 20% arm/shoulder pain, which is 100% left-sided in a C6 and C7 distribution. MRI of the cervical spine demonstrated a C5-C6 3 mm disc herniation with facet arthropathy and severe bilateral foraminal stenosis (**Figure 7a,b**). At C6-C7 a 2 mm left paracentral disc protrusion was noted with severe bilateral foraminal stenosis (**Figure 7c**). For her pain, the patient had tried a prolonged course of conservative management in the form of physical therapy, heating pads, and ice packs. She had tried medications in the form of NSAID's, muscle relaxants and narcotics. She had consulted with pain management and undergone injection procedures in the form of transforaminal epidural injections at C56 and later

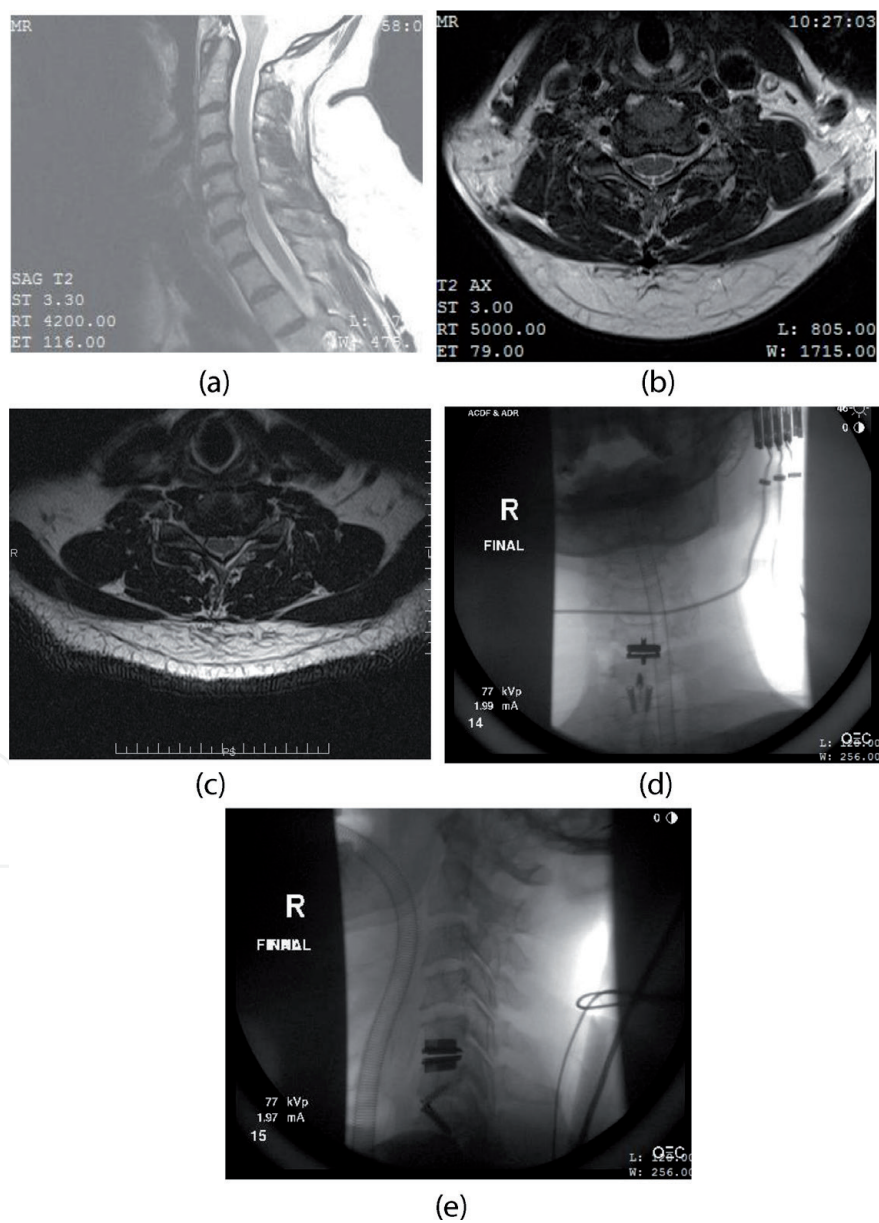


Figure 7.
(a) Sagittal MRI of the cervical spine demonstrated a C5-C6 and C67 disc herniations. (b) Axial MRI of the cervical spine demonstrated a C5-C6 bilobed herniation with severe bilateral foraminal stenosis. (c) At C6-C7 a 2 mm disc protrusion was noted with severe bilateral foraminal stenosis. (d) AP Xray artificial disc replacement at C56 and anterior cervical discectomy and fusion at C67. (e) Lateral Xray artificial disc replacement at C56 and anterior cervical discectomy and fusion at C67.

at C6/7, which each provided one hundred percent pain relief and lasted for one month. Patient underwent an uncomplicated Artificial Disc Replacement at C5/6 and Anterior Cervical Discectomy and Fusion at C6/7, and has since noted complete resolution of her symptoms (**Figure 7d, e**).

6.2 Case 2 C4/5 ACDF C5/6 ADR C6/7 ACDF

48 year-old female who presented with 95% neck pain and 5% shoulder pain, which is 50% right-sided and 50% left, sided in a C5, C6, and C7 distribution. MRI of the cervical spine demonstrated at the C4-C5 level moderate central spinal

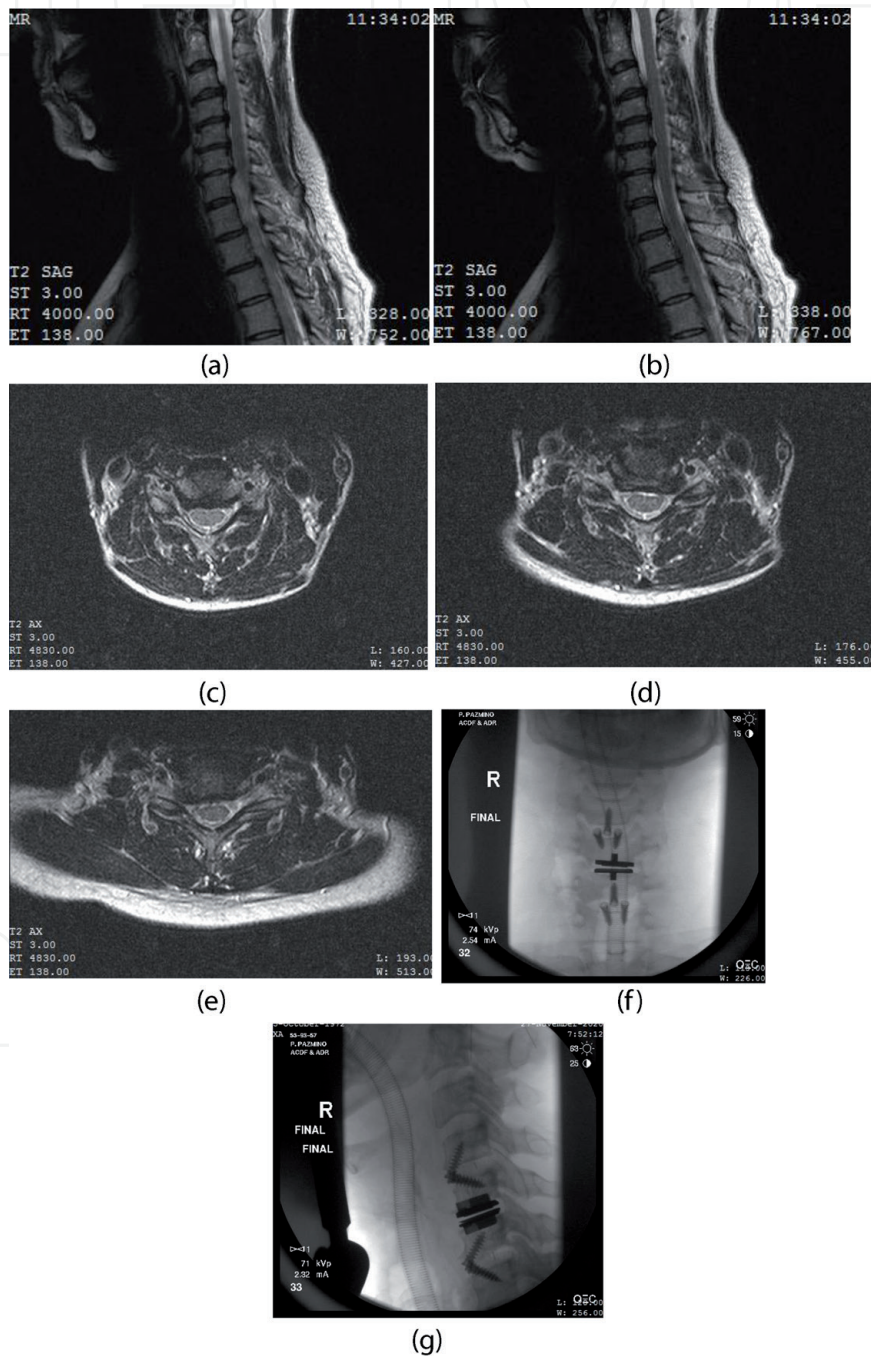


Figure 8. (a, b) Sagittal MRI of the cervical spine demonstrated herniations at the C4-C5, C5/6, C6/7. (c) Axial MRI of the cervical spine demonstrated C4/5 large disc herniation with neuroforaminal stenosis. (d) Axial MRI of the cervical spine demonstrated C5/6 eccentric disc herniations with left sided neuroforaminal stenosis. (e) Axial MRI of the cervical spine demonstrated C6/7 eccentric disc herniation with right sided neuroforaminal stenosis. (f) AP Xray artificial disc replacement at C5/6 and anterior cervical discectomy and fusion at C4/5, and C6/7. (g) LATERAL Xray artificial disc replacement at C5/6 and anterior cervical discectomy and fusion at C4/5, and C6/7.

canal stenosis, a 4 mm disc protrusion with moderate-to-severe neural foraminal, narrowing bilaterally and impingement on the exiting nerve roots bilaterally (**Figure 8a-c**). At the C5-C6, level, there was a 4 mm left paracentral disc protrusion with severe neural foraminal narrowing on the left and moderate foraminal narrowing on the right. There is impingement on the exiting nerve roots bilaterally greater on the left than the right (**Figure 8d**). At the C6-C7 level, there was a 5 mm right paracentral disc protrusion with severe neural foraminal narrowing on the right with impingement on the exiting nerve roots on the right (**Figure 8e**). There is moderate neural foraminal narrowing on the left and moderate central spinal canal stenosis. For her pain, the patient had tried a prolonged course of conservative management in the form of physical therapy, chiropractic treatment, heating pads, and ice packs. She had tried medications in the form of NSAID's, muscle relaxants and narcotics. She had consulted with pain management and undergone three injection procedures in the form of transforaminal epidural injections at C45, C56 and later at C67, each of which provided seventy percent pain relief and lasted for one to three months. Patient underwent an uncomplicated Artificial Disc Replacement at C56 and Anterior Cervical Discectomy and Fusion at C45 and C67, and has since noted resolution of her symptoms (**Figure 8f, g**).

7. Conclusions

In properly indicated patients, with meticulous preoperative planning and sound surgical technique, cervical hybrid arthroplasty offers an excellent surgical option and is a safe and effective alternative to multilevel fusion for the management of cervical radiculopathy and myelopathy.

Conflict of interest

“The authors declare no conflict of interest.”

Author details

Pablo Pazmiño
SpineCal, Santa Monica, CA, USA

*Address all correspondence to: doctor@spinecal.com

IntechOpen

© 2021 The Author(s). Licensee IntechOpen. This chapter is distributed under the terms of the Creative Commons Attribution License (<http://creativecommons.org/licenses/by/3.0>), which permits unrestricted use, distribution, and reproduction in any medium, provided the original work is properly cited. 

References

- [1] Kim Y-S, Park J-Y, Moon BJ, Kim S-D, Lee J-K. Is stand alone PEEK cage the gold standard in multilevel anterior cervical discectomy and fusion (ACDF)? Results of a minimum 1-year follow up. *J Clin Neurosci*. 2018 Jan;47:341-346.
- [2] Flynn TB. Neurologic Complications of Anterior Cervical Interbody Fusion [Internet]. Vol. 7, *Spine*. 1982. p. 536-9. Available from: <http://dx.doi.org/10.1097/00007632-198211000-00004>
- [3] Barysh O, Fedoryna E. COMPLICATIONS AND MISTAKES AFTER ANTERIOR CERVICAL INTERBODY FUSION WITH AUTOLOGOUS BONE GRAFTS [Internet]. Vol. 0, *ORTHOPAEDICS, TRAUMATOLOGY and PROSTHETICS*. 2014. p. 97. Available from: <http://dx.doi.org/10.15674/0030-59872014497-103>
- [4] Qian B. P100. Analysis of failure and complications associated with anterior cervical fusion cage [Internet]. Vol. 4, *The Spine Journal*. 2004. p. S112. Available from: <http://dx.doi.org/10.1016/j.spinee.2004.05.228>
- [5] Murrey D, Janssen M, Delamarter R, Goldstein J, Zigler J, Tay B, et al. 152. 5-Year Results of the Prospective, Randomized, Multicenter FDA Investigational Device Exemption (IDE) ProDisc-C TDR Clinical Trial [Internet]. Vol. 9, *The Spine Journal*. 2009. p. 80S. Available from: <http://dx.doi.org/10.1016/j.spinee.2009.08.188>
- [6] Murrey D, Janssen M, Delamarter R, Goldstein J, Zigler J, Tay B, et al. Results of the prospective, randomized, controlled multicenter Food and Drug Administration investigational device exemption study of the ProDisc-C total disc replacement versus anterior discectomy and fusion for the treatment of 1-level symptomatic cervical disc disease. *Spine J*. 2009 Apr;9(4):275-286.
- [7] Delamarter R, Zigler JE, Balderston RA, Cammisa FP, Goldstein JA, Spivak JM. Prospective, randomized, multicenter Food and Drug Administration investigational device exemption study of the ProDisc-L Total Disc Replacement compared with circumferential arthrodesis for the treatment of two-level lumbar degenerative disc disease: results at twenty-four months [J Bone Joint Surg Am 2011;93(8):705-15. Epub 2011 Mar 11 [Internet]. Vol. 11, *The Spine Journal*. 2011. p. 793. Available from: <http://dx.doi.org/10.1016/j.spinee.2011.08.423>
- [8] Zigler JE, Delamarter RB. Five-year results of the prospective, randomized, multicenter, Food and Drug Administration investigational device exemption study of the ProDisc-L total disc replacement versus circumferential arthrodesis for the treatment of single-level degenerative disc disease [Internet]. Vol. 17, *Journal of Neurosurgery: Spine*. 2012. p. 493-501. Available from: <http://dx.doi.org/10.3171/2012.9.spine11498>
- [9] Kearns S, Janssen M, Murrey D, Delamarter R. Five-Year Results of the Prodisc-C Multicenter Randomized Clinical Trial [Internet]. Vol. 11, *The Spine Journal*. 2011. p. S46. Available from: <http://dx.doi.org/10.1016/j.spinee.2011.08.120>
- [10] Murrey DB, Zigler JE, Delamarter RB, Spivak JM, Janssen ME. Seven-Year Results of the ProDisc-C Multicenter Randomized Clinical Trial [Internet]. Vol. 12, *The Spine Journal*. 2012. p. S61-2. Available from: <http://dx.doi.org/10.1016/j.spinee.2012.08.181>
- [11] Anderson PA, Nassr A, Currier BL, Sebastian AS, Arnold PM, Fehlings MG,

et al. Evaluation of Adverse Events in Total Disc Replacement: A Meta-Analysis of FDA Summary of Safety and Effectiveness Data. *Global Spine J.* 2017 Apr;7(1 Suppl):76S – 83S.

[12] Hollyer MA, Gill EC, Ayis S, Demetriades AK. The safety and efficacy of hybrid surgery for multilevel cervical degenerative disc disease versus anterior cervical discectomy and fusion or cervical disc arthroplasty: a systematic review and meta-analysis. *Acta Neurochir.* 2020 Feb;162(2):289-303.

[13] He J, Ding C, Liu H, Wu T, Huang K, Hong Y, et al. Does Fusion Affect Anterior Bone Loss in Adjacent Cervical Disc Arthroplasty in Contiguous Two-Level Hybrid Surgery? *World Neurosurg.* 2020 Nov;143:e127–e135.

[14] Boddapati V, Lee NJ, Mathew J, Vulapalli MM, Lombardi JM, Dyrszka MD, et al. Hybrid Anterior Cervical Discectomy and Fusion and Cervical Disc Arthroplasty: An Analysis of Short-Term Complications, Reoperations, and Readmissions. *Global Spine J.* 2020 Jul 24;2192568220941453.

[15] Cardoso MJ, Mendelsohn A, Rosner MK. Cervical hybrid arthroplasty with 2 unique fusion techniques. *J Neurosurg Spine.* 2011 Jul;15(1):48-54.

[16] Mehren C, Wuertz-Kozak K, Sauer D, Hitzl W, Pehlivanoglu T, Heider F. Implant Design and the Anchoring Mechanism Influence the Incidence of Heterotopic Ossification in Cervical Total Disc Replacement at 2-year Follow-up. *Spine.* 2019 Nov 1;44(21):1471-1480.

[17] Zeng J, Liu H, Chen H, Ding C, Rong X, Meng Y, et al. Comparison of Heterotopic Ossification After Fixed- and Mobile-Core Cervical Disc Arthroplasty. *World Neurosurg.* 2018 Dec;120:e1319–e1324.

[18] Hamby WB, Glaser HT. Replacement of spinal intervertebral discs with locally polymerizing methyl methacrylate: experimental study of effects upon tissues and report of a small clinical series. *J Neurosurg.* 1959 May;16(3):311-313.

[19] Cleveland DA. The use of methylacrylic for spinal stabilization after disc operations. *Marquette Med Rev.* 1955;20:62-64.

[20] FASSIO, B. Discal prosthesis made of silicone : experimental study and 1st clinical cases. *Nouv Presse Med.* 1978;7:207.

[21] Cummins BH, Robertson JT, Gill SS. Surgical experience with an implanted artificial cervical joint. *J Neurosurg.* 1998 Jun;88(6):943-948.

[22] Hui N, Phan K, Kerferd J, Lee M, Mobbs RJ. Comparison of M6-C and Mobi-C cervical total disc replacement for cervical degenerative disc disease in adults. *J Spine Surg.* 2019 Dec;5(4):393-403.

[23] Mehren C, Heider F, Sauer D, Kothe R, Korge A, Hitzl W, et al. Clinical and Radiological Outcome of a New Total Cervical Disc Replacement Design. *Spine.* 2019 Feb 15;44(4):E202–E210.

[24] Markwalder T-M, Wenger M, Marbacher S. A 6.5-year follow-up of 14 patients who underwent ProDisc total disc arthroplasty for combined long-standing degenerative lumbar disc disease and recent disc herniation [Internet]. Vol. 18, *Journal of Clinical Neuroscience.* 2011. p. 1677-81. Available from: <http://dx.doi.org/10.1016/j.jocn.2011.04.024>

[25] Pitsika M, Nissen J. Spinal cord compression due to nucleus migration from Mobi-C total disc replacement [Internet]. *British Journal of Neurosurgery.* 2020. p. 1-4. Available

from: <http://dx.doi.org/10.1080/02688697.2020.1716942>

[26] Byval'tsev VA, Kalinin AA, Stepanov IA, Pestryakov YY, Shepelev VV. [Analysis of the results of total cervical disc arthroplasty using a M6-C prosthesis: a multicenter study]. *Zh Vopr Neurokhir Im N N Burdenko*. 2017;81(5):46-55.

[27] McAfee PC. Classification of Heterotopic Ossification in Artificial Disc Replacement [Internet]. *The Artificial Disc*. 2003. p. 157-163. Available from: http://dx.doi.org/10.1007/978-3-662-05347-8_14

[28] Harris L, Dyson E, Elliot M, Peterson D, Ulbricht C, Casey A. Delayed periprosthetic collection after cervical disc arthroplasty. *J Neurosurg Spine*. 2019 Dec 13;1-8.

[29] Lind B, Sihlbom H, Nordwall A, Malchau H. Normal range of motion of the cervical spine. *Arch Phys Med Rehabil*. 1989 Sep;70(9):692-695.

[30] Panjabi MM, Duranceau J, Goel V, Oxland T, Takata K. Cervical human vertebrae. Quantitative three-dimensional anatomy of the middle and lower regions. *Spine*. 1991 Aug;16(8):861-869.

[31] White AA, Panjabi MM. *Clinical Biomechanics of the Spine*. Lippincott Williams & Wilkins; 1978. 534 p.

[32] Panjabi MM, Ito S, Pearson AM, Ivancic PC. Injury Mechanisms of the Cervical Intervertebral Disc During Simulated Whiplash [Internet]. Vol. 29, *Spine*. 2004. p. 1217-25. Available from: <http://dx.doi.org/10.1097/00007632-200406010-00011>

[33] White AA, Panjabi MM. Biomechanical Considerations in the Surgical Management of Cervical Spondylotic Myelopathy [Internet]. Vol. 13, *Spine*. 1988. p.

856-60. Available from: <http://dx.doi.org/10.1097/00007632-198807000-00029>

[34] Buchowski JM, Daniel Riew K. Primary Indications and Disc Space Preparation for Cervical Disc Arthroplasty [Internet]. *Motion Preservation Surgery of the Spine*. 2008. p. 185-192. Available from: <http://dx.doi.org/10.1016/b978-1-4160-3994-5.10021-3>

[35] Wu T-K, Meng Y, Wang B-Y, Hong Y, Rong X, Ding C, et al. Is the behavior of disc replacement adjacent to fusion affected by the location of the fused level in hybrid surgery? [Internet]. Vol. 18, *The Spine Journal*. 2018. p. 2171-80. Available from: <http://dx.doi.org/10.1016/j.spinee.2018.04.019>

[36] Wu T-K, Meng Y, Liu H, Wang B-Y, Hong Y, Rong X, et al. Biomechanical effects on the intermediate segment of noncontiguous hybrid surgery with cervical disc arthroplasty and anterior cervical discectomy and fusion: a finite element analysis [Internet]. Vol. 19, *The Spine Journal*. 2019. p. 1254-63. Available from: <http://dx.doi.org/10.1016/j.spinee.2019.02.004>

[37] Hu L, Wu T, Liu H, Wang B, Zhang J, Meng Y, et al. Influence of Fusion on the Behavior of Adjacent Disc Arthroplasty in Contiguous 2-Level Hybrid Surgery In Vivo [Internet]. Vol. 132, *World Neurosurgery*. 2019. p. e929-40. Available from: <http://dx.doi.org/10.1016/j.wneu.2019.07.073>

[38] Wu T-K, Meng Y, Liu H, Hong Y, Wang B-Y, Rong X, et al. Primary cervical disc arthroplasty versus cervical disc arthroplasty adjacent to previous fusion [Internet]. Vol. 97, *Medicine*. 2018. p. e11755. Available from: <http://dx.doi.org/10.1097/md.00000000000011755>

[39] Park DK, Lin EL, Phillips FM. Index and Adjacent Level Kinematics After

Cervical Disc Replacement and Anterior Fusion [Internet]. Vol. 36, Spine. 2011. p. 721-30. Available from: <http://dx.doi.org/10.1097/brs.0b013e3181df10fc>

development after anterior cervical fusion without plate fixation. Spine 2009;34:30-3. Spine. 2009 Jul 1;34(15):1626-1627; author reply 1627.

[40] Hyun Y-S, Park J-S, Song K-W, Kim G-L, Lee J-Y, Shin J-H. Clinical and Radiographic Results of Artificial Disc Replacement Combined with Anterior Cervical Discectomy and Fusion Versus Two-Level Anterior Cervical Discectomy and Fusion in Two-Level Cervical Disc Disease [Internet]. Vol. 24, Journal of Korean Society of Spine Surgery. 2017. p. 211. Available from: <http://dx.doi.org/10.4184/jkss.2017.24.4.211>

[46] Yang J-Y, Song H-S, Lee M, Bohlman HH, Riew KD. Adjacent level ossification development after anterior cervical fusion without plate fixation. Spine. 2009 Jan 1;34(1):30-33.

[41] Meng Y, Wang X, Zhao Z, Wang B, Wu T, Liu H. Intraoperative Anterior Migration of the Prestige-LP Cervical Disc Owing to an Inappropriate Implantation Sequence During Continuous 2-Level Artificial Cervical Disc Replacement: A Case Report with 8-Year Follow-Up [Internet]. Vol. 116, World Neurosurgery. 2018. p. 194-200. Available from: <http://dx.doi.org/10.1016/j.wneu.2018.05.093>

[42] Chen J, Wang X, Yuan W, Tang Y, Zhang Y, Wan M. Cervical myelopathy after cervical total disc arthroplasty: case report and literature review. Spine. 2012 May 1;37(10):E624-E628.

[43] Wang X-F, Meng Y, Liu H, Hong Y, Wang B-Y. Surgical strategy used in multilevel cervical disc replacement and cervical hybrid surgery: Four case reports. World J Clin Cases. 2020 Sep 6;8(17):3890-3902.

[44] Patel VV, Andrews C, Pradhan BB, Bae HW, Kanim LEA, Kropf MA, et al. Computed tomography assessment of the accuracy of in vivo placement of artificial discs in the lumbar spine including radiographic and clinical consequences. Spine. 2006 Apr 15;31(8):948-953.

[45] Li L. Re: Yang JY, Song HS, Lee M, et al. Adjacent level ossification