

# We are IntechOpen, the world's leading publisher of Open Access books Built by scientists, for scientists

6,900

Open access books available

185,000

International authors and editors

200M

Downloads

Our authors are among the

154

Countries delivered to

TOP 1%

most cited scientists

12.2%

Contributors from top 500 universities



WEB OF SCIENCE™

Selection of our books indexed in the Book Citation Index  
in Web of Science™ Core Collection (BKCI)

Interested in publishing with us?  
Contact [book.department@intechopen.com](mailto:book.department@intechopen.com)

Numbers displayed above are based on latest data collected.  
For more information visit [www.intechopen.com](http://www.intechopen.com)



# Cataract Surgery in Post-Vitrectomized Eyes

*Olivia Esteban, Javier Mateo, Paula Casas, Javier Lara  
and Javier Ascaso*

## Abstract

Because of the application of vitreoretinal surgical techniques to a broader range of posterior segment diseases and because cataract develops frequently in postvitrectomy eyes, cataract surgeons should be familiar with the challenges of cataract extraction in vitrectomized eyes. Cataract surgery after pars plana vitrectomy significantly improves visual acuity in 85% of cases, limited by retinal comorbidity and surgical complications. However, despite recent advances, this surgery remains a special challenge. The cataract surgeon can prepare for these challenges with awareness of such potential factors as an excessively mobile posterior capsule, silicon oil removal and special considerations concerning intraocular lens selection and power calculation. And consider the postoperative complications as posterior capsule opacification or refractive errors.

**Keywords:** cataract, intraocular lens, vitrectomy

## 1. Introduction

Pars plana vitrectomy is a surgical technique that allows a successful treatment of many diseases of the posterior segment of the eye, such as retinal detachment, proliferative diabetic retinopathy, vitreous hemorrhage, epiretinal membrane, or macular hole, among others. The increase in vitreoretinal surgery procedures has led to a predictable and consequent increase in cataract surgery in these eyes. Therefore, the ophthalmologist must be aware of the special characteristics of this type of patient and the impact of a vitrectomized eye on cataract surgery.

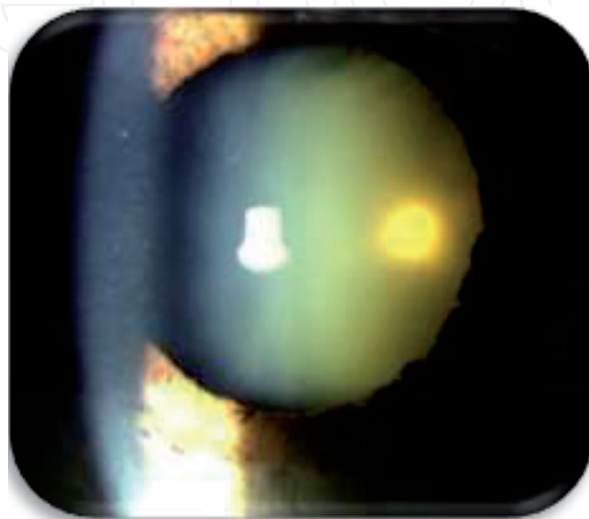
## 2. Development of cataract

Cataract formation or progression is one of the most frequent complications we can find after vitreoretinal surgery. According to several studies, up to 65–80% of the eyes develop a cataract in the 24 months following vitrectomy. [1–6]

Although posterior subcapsular and cortical cataracts can be formed after surgery especially in young patients, nuclear cataracts are much more frequent. Transient subcapsular opacification in the early postoperative period is not unusual. The time interval between vitrectomy and phacoemulsification can vary between 9 and 29 months. [1–3, 7–12]

Even though the exact etiology of cataracts formed after vitrectomy is not known, there are several elements that seem to have a role in it as predisposing or precipitating factors:

- Age: patients over 50 years of age show a significant increase in cataract incidence after retinal surgery when compared to younger ones. They usually develop a nuclear sclerosis, whereas posterior subcapsular opacification is more usual at earlier ages. Whenever there is a previous cataract, vitrectomy favors its progression. [1, 2, 8, 13–15]
- Composition of fluid infusion into the vitreous cavity: the high concentration of 150 mmHg of oxygen in the irrigating solutions used during vitrectomy, much higher than the 17 mmHg of the anterior vitreous or the 30 mmHg of the aqueous, may contribute to the oxidation of the proteins of the lens, thus accelerating the formation of cataracts. However, it remains to be demonstrated that this exposure to high levels of oxygen is maintained in the postoperative period. [2, 15–17]
- Diabetes: there seems to be a lower rate of cataract progression in vitrectomized diabetics (especially in cases of ischemic retinopathy) compared to patients without diabetes, given that the oxygen level in their vitreous is lower (**Figure 1**). [18, 19]
- Direct surgical damage: iatrogenic cataracts can be generated by direct trauma to the posterior lens capsule from the instruments used during pars plana vitrectomy, causing its rupture and producing a very rapid lens opacification. Trauma is more likely to be suffered in long difficult surgeries, such as retinal detachment with vitreoretinal proliferation. If a cataract is formed in the four months following retinal surgery, traumatic etiology should be suspected. [1, 20]
- Light toxicity: intense exposure to surgical microscope light or the fiber optic probe can be a factor that facilitates the oxidative damage of lens proteins. However, light sources currently incorporate Xenon light filter systems that eliminate the phototoxic fraction of the blue-ultraviolet wavelength, reducing the phototoxicity caused in the lens or in the retina. [2]



**Figure 1.**  
*Development of a nuclear cataract in a diabetic patient after six months of vitrectomy.*

- Vitreous gel removal: the elimination of the vitreous seems to increase the level of retrolental oxygen, generating oxidation of the lens proteins. The incidence of cataracts is much higher after an extensive removal of the vitreous gel and it drops significantly when a limited vitrectomy or a nonvitrectomizing technique is performed. In other surgical procedures that do not include vitrectomy, such a scleral buckling or pneumatic retinopexy, the risk of inducing cataracts is also lower. [1, 2, 6, 17, 21, 22]
- Vitreous substitutes: the presence of gas bubble (SF<sub>6</sub> or C<sub>3</sub>F<sub>8</sub>) or silicone oil in the vitreous chamber raise the incidence of lens opacification when compared with eyes without any tamponade after surgery. Long lasting substances increase even more the cataract progression. Lens opacity in patients with silicone oil is associated with epithelial cell metaplasia due to inhibition of lens metabolism (anaerobic glycolysis). Secondary gas-related lens opacities can appear as posterior subcapsular vacuoles, which sometimes can be transient and disappear if a layer of liquid is maintained between the gas bubble and the posterior surface of the lens. It is important for the patient to keep the head in a prone position, to prevent the meniscus of the gas bubble from contacting the posterior surface of the lens, and to avoid metabolic disruption of the lens cells. [1, 2, 8]
- Small gauge vitrectomy: although theoretically one of the advantages of the minimally invasive vitreo retinal surgery (23, 25 or 27 gauge) was the lower incidence of cataracts following the operation, there are no studies that demonstrate this relationship. No significant differences have been found between the different systems in the rate of cataract development. It seems that the progression of the lens opacification depends more on the amount of vitreous gel removed rather than the size of the instruments that are used. [1, 23–25]

### 3. Considerations before cataract surgery

The surgical criteria should be early, avoiding advanced cataracts requiring higher ultrasound power or poor posterior pole exploration. The final visual acuity after retinal surgery and the underlying retinal pathology for which vitrectomy was required to predict the visual prognosis of the patient should be identified through the anamnesis: retinal detachment with or without macular involvement, proliferative diabetic retinopathy with or without macular edema, history of ocular trauma or high myopia, among others. At times, it is difficult to determine whether the degree of visual impairment in the patient is due to underlying retinal pathology or to cataract progression. In patients operated on for macular disease who present metamorphopsia or central scotoma, these symptoms will persist after cataract surgery. Likewise, it is important to identify the time interval between vitrectomy and cataract, since when opacity occurs at intervals of less than 4 months, iatrogenic lens touch in the posterior capsule must be ruled out. [20]

In the ophthalmological examination, pupillary dilation should be evaluated, as in uveitic or diabetic eyes, and the state of the zonular fibers, since there may be phacoiridodonesis due to alteration of the zonule in vitrectomized eyes. It is important to perform a fundus examination to rule out retinal pathology and, occasionally, to perform an optical coherence tomography (OCT) to assess the status of the macula. In patients with macular edema, the need to treat it with an intravitreal injection before surgery or during the procedure itself will be assessed. In the case of not being able to visualize the fundus, an ocular ultrasound should be performed

to assess the state of the retina and be able to rule out complications such as vitreous hemorrhage or retinal detachment that require combined surgery.

#### **4. Intraocular lens calculation**

Intraocular lens power calculation is based on the measurement of anatomical eye parameters. Regardless of the formula we apply, to calculate the intraocular lens (IOL) in our patients we must know precisely the axial length (AL), keratometry and anterior chamber depth (ACD). Prediction of IOL power in eyes undergoing retinal surgery can sometimes be challenging and certain considerations should be taken into account.

##### **4.1 Axial length measurement**

AL in our patients can be quantified using optical or ultrasonic methods. Optical methods are more comfortable because they do not require contact with the patient and are more examiner-independent. However, there are cases where we will turn to ultrasonic methods, especially because of media opacity.

Measuring AL requires proper foveal fixation, this could be an important source and error in patients with retinal pathologies. [26, 27] Newly developed equipment such as the IOL master 700, incorporates an OCT system to ensure a correct measurement aligned with the patient's fovea [27] this is especially important in cases of macular pathology and staphyloma. [28]

##### **4.2 Axial length in vitrectomized eyes**

In vitrectomized patients with no fluid exchange the vitreous is replaced by aqueous humor. This is not a problem with ultrasonic biometry because of the transmission rate of aqueous and vitreous humors are practically the same (1532 m/sec ultrasound velocity). In the same way, the vitreous has an optical refractive index of 1.3346 and the aqueous of 1.3336. This small difference generates a myopic shift of  $-0.13$  diopters (D) in vitrectomized eyes that has little clinical relevance. [29, 30]

Ultrasound biometry measures AL from corneal vortex to internal limiting membrane along the optical axis. Optical systems quantify AL from corneal vortex to retinal pigment epithelium along visual axis. [31] So, macular status as macular edema or submacular fluid can affect the measurement of axial length in ultrasonic biometry. The difference in measurement with respect to the axis confers superiority to the optical biometer, which achieves more accurate measurements as long as the visual fixation of the patient is preserved to look at the laser target. [32]

Elevated myopia or staphyloma are more common in vitrectomized patients. [33] These factors along with poor visual binding are frequent cause of erroneous AL measurements. It is likely that one of the most complex situations to determine AL is the case of high retinal detachment with macula-off, where the patient cannot fix and foveal detachment generates an underestimation of AL. [34]

##### **4.3 Axial length in oil-filled eyes**

Phacoemulsification and silicone oil (SO) removal in a single act could avoid surgical risks and is optimal for patients with cataract formation in a short time after vitrectomy with SO tamponade. Obtaining accurate AL measurements in silicone oil-filled eyes can be difficult.



Whenever possible, we should quantify the AL in oil-filled eyes with optical biometers (optical interferometry or reflectance) because of the optical laser is not appreciably affected by SO, by its molecular weight or by the interfaces that remain between aqueous humor and silicone in eyes with incomplete filling. [35, 36] In the main menu of our optical biometer we will select the option “vitreous cavity filled with oil” and the refractive index of light will change from 1.33 in vitreous to 1.4 in silicone oil (**Figure 2**). [37]

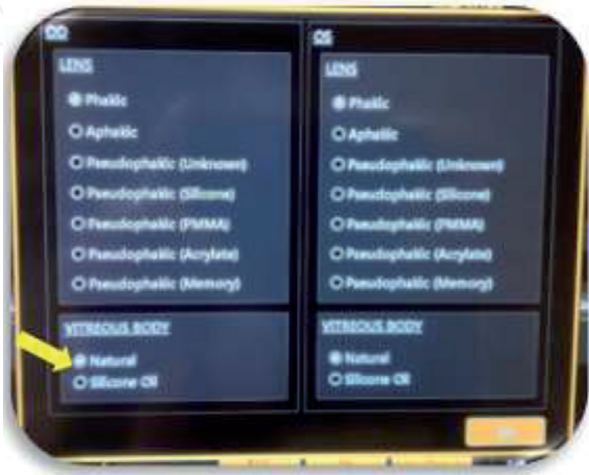
However, cataracts generated by silicone oil are often dense and do not allow optical biometrics to be performed. It is estimated that in 4.7–17% of AL measurements, interferometry cannot be performed due to poor visual acuity, corneal opacity or dense cataract among others. [38, 39] Low coherence reflectometry and optical coherence tomography use longer wavelength than interferometry, so we can assume that the proportion of eyes measured with these techniques should be greater. [40] In cases where measurement with optical systems cannot be performed AL measurement becomes a biometric challenge.

The replacement of vitreous with silicone oil implies that the propagation of acoustic waves is modified. The speed of sound in a medium is inversely related to the refractive index of the medium. Because silicone has a higher rate than vitreous, it reduces the speed of sound a 36% approximately. The sound velocity declines from 1532 m/sec in the vitreous to 980 m/sec in 1000 centistokes molecular weight silicone oil. [41] This reduction in speed generates a higher axial length measurement. If we do not calibrate our ultrasonic biometer, we will generate a hypermetropic refractive defect.

If we use higher molecular weight silicone oil the speed variation would be different [42–45].

If our ultrasonic biometer does not have a speed adjustment for eyes with silicone oil, we can multiply a corrective factor of 0.64 to the vitreous cavity length obtained with a speed of 1532 m/sec. [46] To calculate the axial length we will have to add the rest of the structures (anterior chamber depth, lens thickness and retrosilicone space) to the value obtained from vitreous cavity with the corrective factor. [37]

Another source of error appears when the vitreous cavity is not completely filled with SO. An aqueous space is generated between the oil and the retina, the “retrosilicone space”. It is maximum in supine position, decreases when the patient is erect and is minimized in the prone position. [47] And as we have seen before, it should



**Figure 2.**  
*Optical biometry and topography (Aladdin Topcon®). Select silicone oil in biometer before measuring AL.*

be taken into account for IOL calculation. If we do not consider it, leads to a shorter and erroneous measurement of the AL in A-mode biometry.

Abu El Einen et al. [43] found better refractive results in oil-filled eyes explored by immersion B-guided than in contact A-mode biometry. Although both are echographic techniques, immersion ultrasound prevents us from possible compression of the scanning probe on the cornea and mode B helps us to locate fovea, specially in patients with staphyloma or fluid interfaces. [48]

In addition to slower sound speed, SO absorbs sound, leading to poor penetration with low-quality echoes. [49] This significant sound attenuation generates poor identification of the retinal spike by contact A-mode biometry. [50] In these cases biometry may be unsatisfactory and other methods as we mention below have been proposed. Vitreoretinal surgeons should know that the appearance of cataract occurs after 3 months in 100% of the eyes with SO. [51, 52] Therefore, a useful strategy would be to perform a pre-vitrectomy biometry in all cases with macula on in which there is a possibility of fluid exchange by SO. [53] In these cases, we should take into account that the placement of a scleral buckle during surgery will also modify the axial length of the patient. [54, 55]

Another option is the two-step surgery with the removal of cataract and silicone oil in a first step and the placement of an implant in a second time if the retina remains stable. [56, 57]

El-Baha et al. perform more complex techniques with intraoperative biometry after remove SO with a sterilized ultrasonic biometer probe. [58] Elbendary et al. make an intraoperative calculation with a portable retinoscope. [59] These techniques consume more intraoperative time and require more specific devices that are not available in all centers, including a large stock of IOL powers.

#### **4.4 Silicone oil refractive effect**

In some patients, SO is not removed and is left inside the eye indefinitely. This is the case of eyes with recurrent bleeding or multiple retinal re-detachments among others. In this situation, if we want to extract the cataract we must take into account the refractive effect of SO when calculating IOL. SO acts as a negative lens because of its lower refractive index compared to vitreous. We must add +2 to +3 D to the calculated IOL to compensate for this effect, always in flat-convex lenses with the flat face toward the vitreous cavity. [60]

#### **4.5 Changes in other eye parameters after vitrectomy**

The anterior segment morphology has a crucial role for the refractive results after surgery. Moreover, calculation of effective lens position (ELP) in vitrectomized eyes is influenced by factors inherent to vitreous surgery.

The most uncertain factor in biometry after phaco-vitrectomy is postoperative ACD. Modification of ACD is controversial and there is no consensus on whether it increases or decreases. Mijnsbrugge et al. [61] reported a more posterior position of the IOL in the phacovitrectomy group compared to single phacoemulsification group, attributed to loss of vitreous support. Gülliklik, Neudorfer and Li [62–64] described no significant change in ACD postoperatively in phacovitrectomy group. And Hamoudi and Huang [65, 66] found an earlier position of IOL secondary to capsular fibrosis.

The influence of gas tamponade on refractive outcomes has also been studied, a myopic shift appears related to anterior lens displacement and shallower aqueous depth due to buoyancy and surface tension of the gas. [67] Even when the gas has already completely disappeared, it seems that the IOL could be fixed in a more anterior position. [67]

#### 4.6 Lens calculation formulas in vitrectomized eyes

In recent years, the development of new biometric formulas to calculate the power of IOL to be implanted to our patients has allowed the minimization of post-surgical refractive surprises. New biometric calculation formulas use a variety of strategies, such as the inclusion of more predictive ELP values, the use of ray tracing, or artificial intelligence to achieve optimal post-surgical results.

There is currently no consensus on the most accurate method for biometric calculation in vitrectomized patients.

Lamson et al. [26] observed in a retrospective study that refractive outcomes using eight biometric formulas (Holladay 1, SRK/T, Barrett, Hill-radial basis function, Ladas and Holladay 2) were more variable and more hyperopic than in non-vitrectomized populations. The Holladay 2 formula obtained the highest percentages of postoperative refraction with predicted errors between  $\pm 0.50$  D and  $\pm 1$  D. However, we should point out that the study was retrospective and analyzed a reduced sample of patients. In addition, there were important uncontrolled variables such as the implanted IOL model, which was not the same in all participants of the study. This hyperopic shift in vitrectomized eyes also was reported by Lee et al. [68]

Recently, another retrospective study published by Tan et al. [69] evaluated the refractive results obtained in cataract surgery in vitrectomized eyes by applying next-generation formulas (Barett Universal II, EVO, Kane, and Ladas super formula) against traditional formulas (Haigis, Hoffer Q, Holladay 1, and SRK/T) with Wang-Koch axial length adjustment if required. Before the lens constants were optimized, hyperopic outcomes were noted for all formulas, except for the Kane formula, which revealed no statistically significant bias. However, lens constant optimization enabled optimal and comparable results for all formulas.

As general recommendations to calculate IOL in vitrectomized eyes we suggest.

The optimization of the constant in clinical practice or, if not possible, choose a slightly myopic refractive target for the IOL to be implanted ( $-0.5$  D).

Traditional formulas in miopic patients with axial length more than 26 mm should be used with Wang-Koch's correction.

The presence of silicone oil in the vitreous cavity does not change the choice of the biometric formula.

#### 4.7 Considerations in combined phaco-vitrectomy

Phaco-vitrectomy is mandatory in cases of retinal surgery with prior cataract. In addition, a large proportion of patients undergoing vitrectomy will develop cataract in the following years. Therefore, phaco-vitrectomy is a common procedure even without prior cataract as it saves costs and risks of a second intervention.

Unlike surgery in previously vitrectomized patients, where the tendency was to a hypocorrection after phacoemulsification (see "LENS CALCULATION FORMULAS IN VITRECTOMIZED EYES"). Phacoemulsification performed concurrently with vitrectomy seems to be associated with myopic shift in the refractive outcome [26, 34, 61, 70] Tranos et al. [70] found that postoperative refractive deviation greater than 0.5 D was associated with shallower ACD and increased macular thickness. Shiraki and Schweitzer [71, 72] related the myopic shift in combined phaco-vitrectomy with the gas tamponade commonly used in cases of retinal detachment. On the other hand, Vandergeest et al. [73] found no tendency toward a myopic shift and they got an elevated percentage of refractive accuracy in combined procedures.



Different from phacoemulsification in previously vitrectomized cases and faced with the variability of published results, our recommendation in cases of phaco-vitrectomy combined surgery would be to calculate the intraocular lens with a refractive target of zero.

## **5. Intraoperative complications**

It has been reported that cataract extraction in eyes with previous vitrectomy is often more complicated because of various anatomic changes in the eye. In the vitrectomized eye, whose vitreous cavity was filled with air, gas or liquid solutions, the aqueous humor is the one that ends up occupying said space, so the lens does not have the counter pressure of the vitreous, which is a semi-solid and viscous substance, and during cataract surgery can occur significant variations in the depth of the anterior chamber that make the procedure difficult. Potential complications that may arise from this situation include bad pupil dilatation, zonule damage, posterior synechia, posterior capsule tears, increase mobility of complex lens-iris and altered intraocular fluid dynamics as a result of the absence of the anterior hyaloid face. Thus, cataract surgery (phacoemulsification) in vitrectomized eyes has been reported to be associated with an increased rate of complications. [74–77]

Cataract surgery in the vitrectomized eye can be performed under topical anesthesia, or in complex cases local anesthesia. When surgery was performed under topical anesthesia, the anterior chamber was irrigated with lidocaine 0.5% before it was filled with an ophthalmic viscosurgical device. There are ophthalmologists who prefer peri- or retrobulbar anesthesia, since when the anterior chamber is deepened, oscillations of the irido-crystalline diaphragm occur with variation in pupillary diameter that generates discomfort to the patient. If the surgery is performed using local anesthesia (retrobulbar), it is necessary to be cautious with the pressure exerted by the Honan balloon. Excessive pressure exerted by this balloon could damage or increase damage to a compromised zonule, increasing the risk of intraoperative drop of the nucleus into the vitreous cavity. For this reason, the use of topical anesthesia is preferable for cataract surgery in previously vitrectomized eyes. Finally, general anesthesia will be reserved for children, neurological and psychiatric patients and bad collaborators.

Biro et al. reported posterior capsule tears and dropped nucleus in 7,3% in 41 vitrectomized patients. [78]

Nevertheless, others authors suggest that eyes with and without prior pars plana vitrectomy (PPV) have a similar likelihood of having intraoperative complications. These authors reported that recognize the differences in the physiologic state of the vitrectomized eye compared with that of non-vitrectomized eyes reduced the frequency of intraoperative complications. [79]

A clear corneal incision for performing the phacoemulsification was recommended, avoiding the conjunctival-scleral scarring from previous retinal surgery. [80]

No intraoperative wound-related problems have been described using this clear corneal approach, with a 3-step wound construction with a 50% vertical groove.

In patients with inadequate dilation of the pupil, the use of intracameral phenylephrine or the insertion of iris retractors or pupillary elongation maneuvers will be evaluated, and if there are posterior synechiae, synechiolysis will be performed with the help of viscoelastics.

In the case of severe crystalline opacities that do not allow the visualization of the background orange reflex, the use of trypan blue in the staining of the anterior capsule, facilitating capsulorhexis, will be considered. In vitrectomized eyes, trypan

blue must be introduced into the anterior chamber slowly to avoid its diffusion to the vitreous chamber through zonular dehiscences. If this happens, phacoemulsification can be very complicated by the loss of the foveal reflex, increasing the risk of rupture of the posterior capsule.

If possible, very small capsulorhexis should be avoided to avoid capsular phimosis that later hinders the evaluation of the retinal periphery. Both cohesive viscoelastics that have expansive property allowing the management of mydriasis, and dispersives that protect the corneal endothelium can be used.

Phacoemulsification with a constant pressure minimizes complications in the event of significant ocular collapse. [81]

Fluctuations in the anterior chamber, such as the antero and retropulsion phenomenon, can be minimized by keeping the infusion bottle low, although sometimes there are unavoidable intraoperative mioses that make surgery difficult.

Accurately sized wounds, including the clear corneal incision for the phaco tip and the side port for the nucleus manipulator, help to maintain a relatively sealed chamber during surgery and minimize fluctuation of the anterior chamber depth.

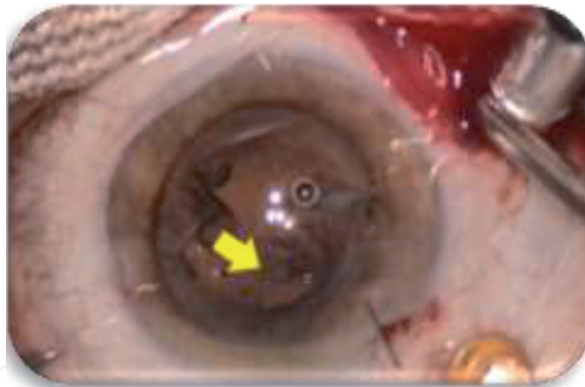
In the case of having a reverse pupillary blockage, produced when the iris contacts the anterior capsule, preventing the flow from reaching the posterior chamber, it can be solved either by lifting the iris with a second instrument from the paracentesis or using the phaco tip lifting the iris and put the foot pedal in the irrigation level before any phaco manipulation.

In a study of 75 vitrectomized eyes, this blockage was observed in 53.3% of the cases during cataract surgery, especially in younger patients, with greater axial length and greater anterior chamber depth. [82]

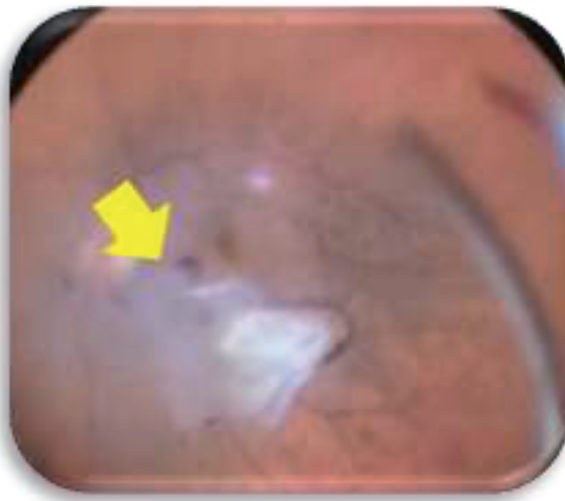
Infusion deviation syndrome occurs when fluid migrates backward through the zonule and it increases the volume of the vitreous and causes flattening of the anterior chamber. Titiyal et al. [83] presented this complication in 12.3% of the 89 vitrectomized eyes during cataract surgery. To prevent this, it is recommended to carry out the hydration maneuvers carefully, reduce the flow of fluid within the anterior chamber (lowering the height of the bottles if possible or reducing the flow/aspiration rate). Once this complication appears, it is very useful to place in the pars plana a vitrectomy trocar without a valve to allow the pressure to escape from the posterior chamber and to be able to continue performing phacoemulsification.

Maneuvers that push the lens during phacoemulsification and cause zonular tension should be avoided. Thorough careful hydrodissection, confirmation of adequate lens rotation before phacoemulsification and gentle nucleus manipulation help to avoid unnecessary zonular damage and posterior capsule tears. If there is a fall of the nucleus or fragments to the vitreous cavity after the rupture of the posterior capsule, aggressive maneuvers should not be carried out when trying to recover them since they can generate ruptures in the retina and subsequent retinal detachment. The appropriate management in these cases is to perform a posterior approach to the complication through pars plana vitrectomy. In general, it is recommended to complete the vitrectomy if necessary, ensure by direct visualization that retinal tears have not been generated, removal of all fragments (either using the vitreotome or using the posterior chamber phacoemulsifier). In these cases, exploration of the peripheral retina to detect tears by indentation is highly recommended (**Figures 3 and 4**).

If there is good capsular support, a lens can be placed in the capsular bag remnants or in the sulcus if the anterior capsule remains intact. In the latter case, it is highly recommended to perform the Gimbel maneuver, which consists of dislocating the optic of the intraocular lens through the opening of the anterior capsule, keeping the haptics of the lens in sulcus. With this maneuver great stability in the implanted intraocular lens is obtained. The technique provides stability and



**Figure 3.**  
*Posterior capsule tear (yellow arrow) in a post-vitrectomized cataract surgery.*



**Figure 4.**  
*Subluxated fragments of the lens (yellow arrow) to the retina in a complicated post-vitrectomized cataract surgery.*

long-term centration of the IOL and prevents vitreous from extending anterior to the IOL. [84]

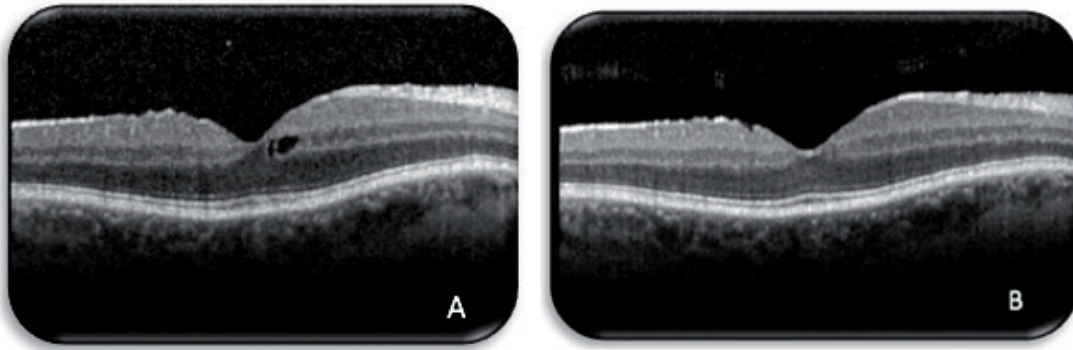
If there is no capsular support, other alternatives must be chosen to place the intraocular lens, such as the sulcus-sutured lens or the iris fixation lenses.

The use of multifocal lenses in eyes with retinal pathology remains controversial, so it is generally preferred to implant single vision lenses.

## 6. Postoperative complications

Vitrectomized patients after cataract surgery have a higher risk of postoperative complications. In patients with previous macular surgery and diabetic eyes, a higher incidence of cystic macular edema has been observed. It was reported after a mean time of 42 days after cataract surgery. [85] Nevertheless, there are other studies which have not found CME however, OCT was not routinely used. Therefore, it is important to monitor these patients with fundus and OCT postoperatively since some are refractory cases and require subtenon or intravitreal treatment (**Figure 5**). [86, 87]

Patients with a history of retinal detachment or high myopia surgery may have a higher incidence of retinal detachment, so the peripheral retina should be evaluated throughout the postoperative period. The incidence of RD has been reported between 2% and 8% in different studies [88–90]. Cataract surgery in these patients



**Figure 5.**  
*Asymptomatic cystic macular edema four weeks after cataract surgery in a vitrectomized patient (A).  
Resolution of macular cystics after topical non-steroidal anti-inflammatory treatment (B).*

can no have intra-operative complication which may predispose to RD. Therefore, this complication was a consequence of the previous posterior segment pathology in these eyes.

The incidence of posterior capsular opacification (PCO) was higher in vitrectomized eyes compared with nonvitrectomized eyes. [91, 92] It is ranging between 2.2% and 19.9% [15–17] within the first year after surgery. [88–90].

Finally, another complication in vitrectomized patients undergoing cataract surgery may be long-term subluxations or dislocations of the lens to the vitreous cavity. High myopia was the most frequent predisposing factor in 18.1% of the 83 eyes with this complication. [93]


In summary, cataract development and progression are known as frequent complications of PPV. Because of the application of vitreoretinal surgical techniques to a broader range of posterior segment diseases and because cataract surgery is frequently performed in postvitrectomy eyes, cataract surgeons should be familiar with the challenges of cataract extraction in vitrectomized eyes.

## Author details

Olivia Esteban\*, Javier Mateo, Paula Casas, Javier Lara and Javier Ascaso  
Hospital Clínico Universitario Lozano Blesa, Zaragoza, Spain

\*Address all correspondence to: [oliviaestebanfloria@hotmail.com](mailto:oliviaestebanfloria@hotmail.com)

## IntechOpen

© 2021 The Author(s). Licensee IntechOpen. This chapter is distributed under the terms of the Creative Commons Attribution License (<http://creativecommons.org/licenses/by/3.0>), which permits unrestricted use, distribution, and reproduction in any medium, provided the original work is properly cited. 



## References

- [1] Feng H, Adelman RA. Cataract formation following vitreoretinal procedures. *Clin Ophthalmol* 2014;8:1957-1965.
- [2] Panozzo G, Parolini B. Cataracts associated with posterior segment surgery. *Ophthalmol Clin N Am* 2004;17:557-568.
- [3] Cherfan GM, Michels RG, de Bustros S, Enger C, Glaser BM. Nuclear sclerotic cataract after vitrectomy for idiopathic epiretinal membranes causing macular pucker. *Am J Ophthalmol* 1991;111:434-438.
- [4] Jackson TL, Nicod E, Angelis A, Grimaccia F, Prevost AT, Simpson ARH, Kanavos P. Pars plana vitrectomy for vitreomacular traction syndrome: a systematic review and metaanalysis of safety and efficacy. *Retina*. 2013;33:2012-2017.
- [5] Jackson TL, Donachie PH, Sparrow JM, Johnston RL. United Kingdom National Ophthalmology Database study of vitreoretinal surgery: report 2, macular hole. *Ophthalmology* 2013;120:629-634.
- [6] Yee KMP, Tan S, Oberstein SYL, Filas B, Nguyen JH, Nguyen-Cuu J, Sebag J. Incidence of cataract surgery after vitrectomy for vitreous opacities. *Ophthalmology Retina* 2017;1:154-157.
- [7] Chang MA, Parides MK, Chang S, Braunstein RE. Outcome of phacoemulsification after pars plana vitrectomy. *Ophthalmol* 2002;109:948-954.
- [8] Thompson JT. The role of patient age and intraocular gas use in cataract progression after vitrectomy for macular holes and epiretinal membranes. *Am J Ophthalmol* 2004;137:250-257.
- [9] Biro Z, Kovacs B. Results of cataract surgery in previously vitrectomized eyes. *J Cataract Refract Surg* 2002;28:1003-1006.
- [10] Titiyal JS, Agarwal E, Angmo D, Sharma M, Kumar A. Comparative evaluation of outcomes of phacoemulsification in vitrectomized eyes: silicone oil versus air/gas group. *Int Ophthalmol* 2017;37:565-574.
- [11] Ahfat FG, Yuen CH, Groenewald CP. Phacoemulsification and intraocular lens implantation following pars plana vitrectomy: a prospective eye study. *Eye* 2003;17:16-20.
- [12] Blodi BA, Paluska SA. Cataract after vitrectomy in Young patients. *Ophthalmology* 1997;104:1092-1095.
- [13] Cherfan GM, Michels RG, de Bustros S, Enger C, Glaser BM. Nuclear sclerotic cataract after vitrectomy for idiopathic epiretinal membranes causing macular pucker. *Am J Ophthalmol* 1991;111:434-438.
- [14] Melberg NS, Thomas MA. Nuclear sclerotic cataract after vitrectomy in patients younger than 50 years of age. *Ophthalmology* 1995;102:1466-1471.
- [15] De Bustros S, Thompson JT, Michels RG, Enger C, Rice TA, Glaser BM. Nuclear sclerosis after vitrectomy for idiopathic epiretinal membranes. *Am J Ophthalmol* 1988;105:160-164.
- [16] Truscott RJ. Age-related nuclear cataract-oxidation is the key. *Exp Eye Res* 2005;80:709-725.
- [17] Holekamp NM, Shui YB, Beebe DC. Vitrectomy surgery increases oxygen exposure to the lens: a possible mechanism for nuclear cataract formation. *Am J Ophthalmol* 2005;139:302-310.

- [18] Holekamp NM, Shui YB, Beebe D. Lower intraocular oxygen tension in diabetic patients: possible contribution to decreased incidence of nuclear sclerotic cataract. *Am J Ophthalmol* 2006;141:1027-1032.
- [19] Holekamp NM, Bai F, Shui YB, Almony A, Beebe DC. Ischemic diabetic retinopathy may protect against nuclear sclerotic cataract. *Am J Ophthalmol* 2010;150:543-550.
- [20] Elhousseini Z, Lee E, Williamson TH. Incidence of lens touch during pars plana vitrectomy and outcomes from subsequent cataract surgery. *Retina* 2016;36:825-829.
- [21] Saito Y, Lewis JM, Park I, Ikuno Y, Hayashi A, Ohji M, Tano Y. Nonvitrectomizing vitreous surgery: a strategy to prevent postoperative nuclear sclerosis. *Ophthalmology* 1999;106:1541-1545.
- [22] Sawa M, Saito Y, Hayashi A, Kusaka S, Ohji M, Tano Y. Assessment of nuclear sclerosis after nonvitrectomizing vitreous surgery. *Am J Ophthalmol* 2001;132:356-362.
- [23] Ibarra MS, Hermel M, Prenner JL, Hassan Ts. Longer-term outcomes of transconjunctival sutureless 25-gauge vitrectomy. *Am J Ophthalmol* 2005;139:831-836.
- [24] Faia LJ, McCannel CA, Pulido JS, Hatfield RM, Hatfield ME, McNulty VEW. Outcomes following 25-gauge vitrectomy. *Eye* 2008;22:1024-1028.
- [25] Almony A, Holekamp NM, Bai F, Shui YB, Beebe D. Small-gauge vitrectomy does not protect against nuclear sclerotic cataract. *Retina* 2012;32:499-505.
- [26] Thomas L Lamson 1, Jane Song 2, Azin Abazari 2, Sarah B Weissbart 2. Refractive outcomes of phacoemulsification after pars plana vitrectomy using traditional and new intraocular lens calculation formulas. *J Cataract Refract Surg.* 2019 Mar;45(3):293-297.
- [27] [www.zeiss.com/iolmaster700](http://www.zeiss.com/iolmaster700)
- [28] Vounotrypidis E, Haralanova V, Muth DR, Wertheimer C, Shajari M, Wolf A, Priglinger S, Mayer WJ. Accuracy of SS-OCT biometry compared with partial coherence interferometry biometry for combined phacovitrectomy with internal limiting membrane peeling. *J Cataract Refract Surg.* 2019 Jan;45(1):48-53.
- [29] Shioya M, Ogino N, Shinjo U (1997) Change in postoperative refractive error when vitrectomy is added to intraocular lens implantation. *J Cataract Refract Surg* 23:1217-1220.
- [30] Wang JK, Chang SW. Refractive results of phacoemulsification in vitrectomized patients. *Int Ophthalmol.* 2017 Jun;37(3):673-681.
- [31] Hoffer KJ. Axial length: laser interferometry. Basics of the IOL master. In: Hoffer Kenneth J, editor. *Iol power*. Thorofare: SLACK; 2011. 63-65.
- [32] Mohamed Abou Shousha , Sonia H Yoo. Cataract surgery after pars plana vitrectomy. *Curr Opin Ophthalmol.* 2010 Jan;21(1):45-49.
- [33] Michele Coppola , Alessandro Rabiolo , Maria Vittoria Cicinelli, Giuseppe Querques 2, Francesco Bandello 2. Vitrectomy in high myopia: a narrative review. *Int J Retina Vitreous.* 2017 Oct 2;3:37.
- [34] Yong-Kyu Kim , Se Joon Woo , Joon Young Hyon , Jeeyun Ahn , Kyu Hyung Park . Refractive outcomes of combined phacovitrectomy and delayed cataract surgery in retinal detachment. *Can J Ophthalmol.* 2015 Oct;50(5):360-366.

- [35] Kunavisarut P, Poopattanakul P, Intarated C, Pathanapitoon K. Accuracy and reliability of IOL master and A-scan immersion biometry in silicone oil-filled eyes. *Eye (Lond)* 2012;26(10):1344-1348.
- [36] Roessler GF, Huth JK, Dietlein TS, et al. Accuracy and reproducibility of axial length measurement in eyes with silicone oil endotamponade. *Br J Ophthalmol* 2009;93:1492-4.
- [37] Piotr Kanclerz 1, Andrzej Grzybowski 2 3. Accuracy of Intraocular Lens Power Calculation in Eyes Filled with Silicone Oil. *Semin Ophthalmol*. 2019;34(5):392-397.
- [38] Hirnschall N, Murphy S, Pimenides D, Maurino V, Findl O. Assessment of a new averaging algorithm to increase the sensitivity of axial eye length measurement with optical biometry in eyes with dense cataract. *J Cataract Refract Surg*. 2011;37(1):45-49.
- [39] Mana Tehrani 1, Frank Krummenauer, Eric Blom, H Burkhard Dick. Evaluation of the practicality of optical biometry and applanation ultrasound in 253 eyes. *J Cataract Refract Surg* . 2003 Apr;29(4):741-746.
- [40] Piotr Kanclerz 1, Andrzej Grzybowski 2 3. Accuracy of Intraocular Lens Power Calculation in Eyes Filled with Silicone Oil. *Semin Ophthalmol*. 2019;34(5):392-397.
- [41] Hoffer KJ. Special circumstances silicone oil power. In: Hoffer Kenneth J, editor. *Iol power*. Thorofare: SLACK; 2011. 221-222
- [42] Hoffer KJ. Ultrasound velocities for axial eye length measurement. *J Cataract Refract Surg* 1994;20:554-562.
- [43] Khaled G Abu El Einen 1, Mervat H Shalaby, Hoda T El Shiwy. Immersion B-guided versus contact A-mode biometry for accurate measurement of axial length and intraocular lens power calculation in siliconized eyes. *Retina*. 2011 Feb;31(2):262-265.
- [44] Silicone Oil Retinal Detachments IOL Power Calculations. East Valley Ophthalmology. <http://www.doctor-hill.com/iol-main/silicone.htm>.
- [45] M A Rehman Siddiqui 1, M Amer Awan, Andrew Fairhead, Hatem Atta. Ultrasound velocity in heavy ocular tamponade agents and implications for biometry. *Br J Ophthalmol* . 2011 Jan;95(1):142-144.
- [46] Murray DC, Potamitis T, Good P, et al. Biometry of the silicone oil-filled eye. *Eye* 1999;13:319-324.
- [47] Takei K, Sekine Y, Okamoto F, Hommura S. Measurement of axial length of eyes with incomplete filling of silicone oil in the vitreous cavity using x ray computed tomography. *Br J Ophthalmol*. 2002;86(1):47-50.
- [48] Zaldivar R, Shultz MC, Davidorf JM, Holladay JT. Intraocular lens power calculations in patients with extreme myopia. *J Cataract Refract Surg* 2000; 26:668-674.
- [49] Hammouda Hamdi Ghoraba 1, Alaa Amer El-Dorghamy, Ahmed Fahmy Atia, Abd El-Aziz Ismail Yassin. The problems of biometry in combined silicone oil removal and cataract extraction: a clinical trial. *Retina*. 2002 Oct;22(5):589-596.
- [50] Larkin GB, Flaxel CJ, Leaver PK. Phacoemulsification and silicone oil removal through a single corneal incision. *Ophthalmology* 1998;105: 2023-2027.
- [51] Assi A, Woodruff S, Gotzaridis E, Bunce C, Sullivan P. Combined phacoemulsification and transpupillary drainage of silicone



oil: results and complications. *Br J Ophthalmol* 2001; 85:942-945.

[52] Nawrocki J, Ghoraba H, Gabel VP. Problems with silicon oil removal. A study of 63 consecutive cases. *Ophthalmologie* 1993;90:258-263.

[53] Grinbaum A, Treister G, Moisseiev J. Predicted and actual refraction after intraocular lens implantation in eyes with silicone oil. *J Cataract Refract Surg* 1996;22:726-729.

[54] Shira Sheen Ophir, Asaf Friehmann, Alexander Rubowitz. Circumferential silicone sponge scleral buckling induced axial length changes: case series and comparison to literature. *Int J Retina Vitreous*. 2017 Mar 27;3:10.

[55] Lee DH, Han JW, Kim SS, Byeon SH, Koh HJ, Lee SC, Kim M. Long-term Effect of Scleral Encircling on Axial Elongation. *Am J Ophthalmol*. 2018 May;189:139-145.

[56] Batman C, Cekic O. Phacoemulsification and silicone oil removal through a single incision. *Ophthalmologie* 1999;106:1234-1236.

[57] V G Madanagopalan 1, Pradeep Susvar 1, M Arthi 2. Refractive outcomes of a single-step and a two-step approach for silicone oil removal and cataract surgery. *Indian J Ophthalmol* . 2019 May;67(5):625-629.

[58] Samir Mohamed El-Baha 1, Tarek Samir Hemeida Comparison of refractive outcome using intraoperative biometry and partial coherence interferometry in silicone oil-filled eyes. *Retina*. 2009 Jan;29(1):64-68.

[59] Amal M Elbendary 1, Mohamed M Elwan. Predicted versus actual intraocular lens power in silicon-oil-filled eyes undergoing cataract extraction using automated intraoperative retinoscopy. *Curr Eye Res*. 2012 Aug;37(8):694-697.

[60] Hill W. Understanding silicone oil. Mesa Arizona. [cited 2020 November 1]; Available in: <https://doctor-hill.com/iol-power-calculations/silicone-oil/>.

[61] Joris Vander Mijnsbrugge 1, Jean-Francois Fils 2, Joyce Jansen 3, Minh-Tri Hua 3, Peter Stalmans 3. The role of the vitreous body in effective IOL positioning. *Graefes Arch Clin Exp Ophthalmol*. 2018 Aug;256(8):1517-1520.

[62] Güllikilik G, Erdur S, Özbek M, Özsütçü M, Adabasi M, Demirci G, Kocabora M, Eliacik M (2016) Changes in anterior chamber depth after combined phacovitrectomy. *Turk J Ophthalmol* 46:161-164

[63] Meira Neudorfer 1, Nir Oren, Adiel Barak. High-frequency ultrasound biomicroscopy of the anterior segment morphometry before and immediately after pars plana vitrectomy. *Eur J Ophthalmol* . Mar-Apr 2011;21(2):173-178

[64] Li Y, Yang CX, Qing GP, Wei WB (2013) Changes in anterior chamber depth following vitrectomy. *Chin Med J* 126(19):3701-3704

[65] Hamoudi H, La Cour M. Refractive changes after vitrectomy and phacovitrectomy for macular hole and epiretinal membrane. *J Cataract Refract Surg*. 2013;39:942-947.

[66] Chunmei Huang 1, Tonghe Zhang 1, Jian Liu 1, Qiang Ji 2, Ruili Tan 1. Changes in axial length, central cornea thickness, and anterior chamber depth after rhegmatogenous retinal detachment repair. *BMC Ophthalmol*. 2016 Jul 25;16:121.

[67] Nobuhiko Shiraki , Taku Wakabayashi , Hirokazu Sakaguchi , Kohji Nishida . Effect of Gas Tamponade on the Intraocular Lens Position and Refractive Error after Phacovitrectomy: A Swept-Source Anterior Segment



OCT Analysis. *Ophthalmology* . 2020 Apr;127(4):511-515.

[68] Na Young Lee , Shin Hae Park, Choun Ki Joo. Refractive outcomes of phacoemulsification and intraocular lens implantation after pars plana vitrectomy. *Retina*. 2009 Apr;29(4):487-491.

[69] Tan X, Zhang J, Zhu Y, Xu J, Qiu X, Yang G, Liu Z, Luo L, Liu Y. Accuracy of New Generation Intraocular Lens Calculation Formulas in Vitrectomized Eyes. *Am J Ophthalmol*. 2020 Sep;217:81-90.

[70] Paris G Tranos, Bruce Allan , Miltiadis Balidis , Athanasios Vakalis, Solon Asteriades , George Anogeianakis, Magda Triantafilla, Nikolaos Kozeis, Panagiotis Stavrakas. Comparison of postoperative refractive outcome in eyes undergoing combined phacovitrectomy vs cataract surgery following vitrectomy. *Graefes Arch Clin Exp Ophthalmol*. 2020 May;258(5):987-993.

[71] Nobuhiko Shiraki , Taku Wakabayashi , Hirokazu Sakaguchi, Kohji Nishida . Optical Biometry-Based Intraocular Lens Calculation and Refractive Outcomes after Phacovitrectomy for Rhegmatogenous Retinal Detachment and Epiretinal Membrane. *Sci Rep*. 2018 Jul 27;8(1):11319..

[72] Kelly D Schweitzer , Raúl García. Myopic shift after combined phacoemulsification and vitrectomy with gas tamponade. *Can J Ophthalmol*. 2008 Oct;43(5):581-583.

[73] Leonie J van der Geest , Martin J Siemerink 1, Marco Mura , Maarten P Mourits , Ruth Lapid-Gortzak 2. Refractive outcomes after phacovitrectomy surgery. *J Cataract Refract Surg*. 2016 Jun;42(6):840-845.

[74] Misra A, Burton RL. Incidence of intraoperative complications during

phacoemulsification in vitrectomized and nonvitrectomized eyes: prospective study. *J Cataract Refract Surg*. 2005 May;31(5):1011-1014.

[75] Biro Z, Kovacs B. Results of cataract surgery in previously vitrectomized eyes. *J Cataract Refract Surg* 2002; 28: 1003-1006.

[76] Chang MA, Parides MK, Chang S, Braunstein RE. Out- come of phacoemulsification after pars plana vitrectomy. *Ophthalmology* 2002; 109:948-954.

[77] Lacalle VD, Gárate FJO, Alday NM, et al. Phacoemulsi- fication cataract surgery in vitrectomized eyes. *J Cataract Refract Surg* 1998; 24:806-809.

[78] Biro Z, Kovacs B. Results of cataract surgery in previously vitrectomized eyes. *J Cataract Refract Surg* 2002; 28: 1003-1006.

[79] Misra A, Burton RL. Incidence of intraoperative complications during phacoemulsification in vitrectomized and nonvitrectomized eyes: prospective study. *J Cataract Refract Surg*. 2005 May;31(5):1011-1014.

[80] Braunstein RE, Airiani S. Cataract surgery results after pars plana vitrectomy. *Curr Opin Ophthalmol* 2003; 14:150-154.

[81] Sachdev N, Brar GS, Sukhija J, et al. Phacoemulsification in vitrectomized eyes: results using a 'phaco chop' technique. *Acta Ophthalmol*. 2009;87(4): 382-385.

[82] Ghosh S, Best K, Steel DH. Lens-iris diaphragm retropulsion syndrome during phacoemulsification in vitrectomized eyes. *J Cataract Refract Surg*. 2013;39(12):1852-1858.

[83] Titiyal JS, Agarwal E, Angmo D, et al. Comparative evaluation of outcomes of phacoemulsification in

- vitrectomized eyes: silicone oil versus air/gas group. *Int Ophthalmol* 2016.
- [84] Gimbel HV, DeBroff BM. Intraocular lens optic capture. *J Cataract Refract Surg*. 2004 Jan;30(1):200-206.
- [85] Rey A, Jürgens I, Maseras X, Dyrda A, Pera P, Morilla A. Visual outcome and complications of cataract extraction after pars plana vitrectomy. *Clin Ophthalmol*. 2018 May 25;12:989-994.
- [86] Titiyal JS, Agarwal E, Angmo D, Sharma N, Kumar A. Comparative evaluation of outcomes of phacoemulsification in vitrectomized eyes: silicone oil versus air/gas group. *Int Ophthalmol*. 2017;37(3):565-574.
- [87] Ahfat FG, Yuen CH, Groenewald CP. Phacoemulsification and intraocular lens implantation following pars plana vitrectomy: a prospective eye study. *Eye*. 2003;17(1):16-20.
- [88] Ahfat FG, Yuen CH, Groenewald CP. Phacoemulsification and intraocular lens implantation following pars plana vitrectomy: a prospective study. *Eye* 2003; 17: 16-20.
- [89] Chang MA, Parides MK, Chang S et al. Outcome of phacoemulsification after pars plana vitrectomy. *Ophthalmology* 2002; 109: 948-954.
- [90] Biro Z, Kovacs B. Results of cataract surgery in previously vitrectomized eyes. *J Cataract Refract Surg* 2002; 28: 1003-1006.
- [91] Chang MA, Parides MK, Chang S, Braunstein RE. Outcome of phacoemulsification after pars plana vitrectomy. *Ophthalmology*. 2002; 109(5):948-954.
- [92] Shaumburg DA, Dana MR, Christen WG, Glynn RJ. A systematic overview of the incidence of posterior capsule opacification. *Ophthalmology*. 1998; 105(7):1213-1221.
- [93] Rey A, Jürgens I, Dyrda A, et al. Surgical outcome of late in-the-bag intraocular lens dislocation treated with pars plana vitrectomy. *Retina* 2016;36(3):576-581.