

We are IntechOpen, the world's leading publisher of Open Access books Built by scientists, for scientists

6,900

Open access books available

185,000

International authors and editors

200M

Downloads

Our authors are among the

154

Countries delivered to

TOP 1%

most cited scientists

12.2%

Contributors from top 500 universities



WEB OF SCIENCE™

Selection of our books indexed in the Book Citation Index
in Web of Science™ Core Collection (BKCI)

Interested in publishing with us?
Contact book.department@intechopen.com

Numbers displayed above are based on latest data collected.
For more information visit www.intechopen.com



Cranial Trepanation: Case Studies between the IV Century BC and VI Century in Southern Italy

*Alessio Vovlas, Nunzio Di Nunno, Ginevra Panzarino
and Sandro Sublimi Saponetti*

Abstract

Cranial trepanation is among the oldest head surgical procedures, creating a hole through the skull. This procedure is the surgical removal of a portion of the skull as a medical treatment to cure a specific disease or as a religious or magical ritual. Cranial trepanation has been reported from very early times and widespread all over the world. This work is based on data from six trepanned skulls from the Hellenistic Age (IV century BC) to the Late Antiquity (VI century). The samples come from Puglia (Southern Italy), from the northern (the peninsula of Gargano) to the central area: three cases come from Vieste (Foggia), Ischitella (Foggia) and Alberona (Foggia), the others three from Gravina in Puglia (Bari) and Canosa (Barletta, Andria, Trani). All skulls have been evaluated via an anthropological, radiological and odontological approach. This study indicates the value of a methodology, which encompasses anthropology, radiology and imaging, and archeo-forensic investigations, highlighting the need for multidisciplinary teamwork in any assessment of human remains. The study supports the hypothesis of the presence of a long tradition of medical centres in the Mediterranean basin area.

Keywords: trapanation, skull, puglia, radiology, head surgery

1. Introduction

Cranial trepanation represents one of the earliest forms of head medical surgery [1] performed on the skull to remove a fragment of *calvarium* using sharp instruments or drill. Trepanation, or trephination, has been used frequently in the past in many cultures over the world [2]. This procedure implicates incision of the scalp, cutting through the soft tissue and removal of the bone [3] without damage to the underlying blood vessels, meninges and brain [4]. According to Verano [5] we use trepanation to describe ancient cranial surgery, supporting the Greek origin of the term *trypanon* (a drill or a borer), and trephination to the surgery performed with the “trephine”, the most widely used tool for this procedure through the end of the 19th century [6].

This surgical procedure was first documented in Neolithic [7–9] and widely adopted in later times. The earliest written description is provided by Hippocrates of Cos in the *Corpus Hippocraticum* in the V centuries BC [10]. The author described scraping, incision and perforation techniques. Then Celso [11], Eliodoro [12] and

Galeno [13] described two instruments: the *modiolus* a cylindrical piece of iron used for small perforations, and the *terebra* for larger perforations. The diameter of the perforation was in direct proportion to the diameter of the instrumentation employed.

Although writings are a precious source of information, skeletal remains are crucial as they present a direct indication of these procedures allowing us to study them in detail. Ancient examples can be found throughout the world since prehistory and their numbers are in thousands [14, 15]. Its use declined during the mediaeval period [16] and some primitive communities still perform this procedure [17].

In 1867 French surgeon-anthropologist Paul Broca, after examining a pre-Columbian skull sent to him to Peru by Ephraim George Squier, surprised scientist and physician by suggesting that the cranial opening presented on the skull was the result of a trepanation [18]. Even nowadays, some societies still perform this form of intervention, practising the same techniques reported in ancient times [6].

Campillo [19] grouped the main techniques used for trepanation in three general procedures: grooving, scraping and incising (boring, chiseling or cutting). Sometimes these techniques can then be combined with each other [20].

Grooving is the most recurrent trepanation technique used in Europe and probably the easier to perform. In grooving, according to Aufderheide et al. [21] a pointed instrument etches a round or oval groove. It implicates drilling the bone with a sharp and hard stone or a metallic element (groove), repeatedly drawing and redrawing the groove through to the *diploe* while pressure is exerted. Scraping is the oldest trepanning technique [22] consists in thrusting with a forward and backward movement on the bone surface, until the vault wears away and perforation is complete. For this procedure multifaceted stone or later advanced instruments such as scrapers (raspatories) were also used [23]. Incising method is the most common technique recorded in South America [24] however has been scarcely used in Europe. Depending on the tools used, the hole, usually with serrated edges, can have different polygonal shapes, mainly rectangular if a knife was used, or circular [25, 26] if a pointed tool was used.

In Italy we know this practice even in prehistoric times and singular cases of cranial trepanation have been described by various authors [8, 27–34] also from apulian context [35–38].

The aim of the current study is to report and describe six cases of trepanations discovered in necropolis located in southern Italy. Furthermore discusses the survival rates, considers sex and age of the affected individuals, the localization of the trepanations and might provide explanations for the surgical operation.

2. Materials and methods

All the crania are undergone anthropological observation to establish a general biological profile. According to the commonly used methodology were determined gender and age [39–41] and morphometrical indicators [42]; also periodontal pathologies [2] and caries [2, 43], tartar deposits [44] and hypoplastic enamel [45] in order to establish possible nutritional stress and/or previous disease pathologies. The estimation of stature and body mass was carried out according to the methods of Trotter and Gleser [46, 47] and Ruff [48]. The investigation concerns the skeletal markers of biomechanical stress through evaluation and interpretation of any syndesmotoc pathologies, enthesopathy, supernumerary articulatory facets or degenerative disease of the articulations [49–53]; finally, the criteria of Borgognini Tarli and Repetto [54] was used in order to evaluate any possible alterations to the spinal column. It was applied geometrical techniques concerning the transversal sections of the humerus and the femur [55–59]. The crania were examined by radiological investigation with Computerized Axial Tomography with 3D reconstruction (CAT, Siemens Somatom

Emotion 16 slice). The images were acquired with 1 mm slices and total radiation Kv 130 and mAs 240. Then the images were digitally elaborated with the Siemens Syngo workstation. The CT examination allowed evaluating the degree of bone remodeling of the cranial perforation. Furthermore, the examination of the CT scan images allowed for an evaluation regarding the degree of bone remodeling, or remodeling of the cranial perforation, which had taken place. It could be determined whether the perforation had been performed near death or whether the perforation had prolonged the subject's life. Also, it was used the method based which takes in consideration the relationship between the volume of the dental pulps (measured in pixels) concerning the entire volume of the dentition [60] on the canines to evaluate an approximate age.

3. Results

3.1 The trepanned crania

The findings are six and come from Apulia (South Italy), from the northern to the central area: three cases come from Vieste (Foggia), Ischitella (Foggia) and Alberona (Foggia); the others three from Canosa (Barletta, Andria, Trani) and Gravina in Puglia (Bari) (**Figure 1**). Three skulls (Gravina, Vieste and Ischitella) are dated to the Greek Classical period (IV-III centuries BC); the other three (Alberona and the two cases from Canosa) between the Late Roman period and the Late Antique period (III-VII centuries).

For each case study we reported: 1) Archeological information (archeological site, the number of the grave and period); 2) biological profile (gender, age at death, height and body mass); 3) presence of anatomical variations; 4) pathologies;

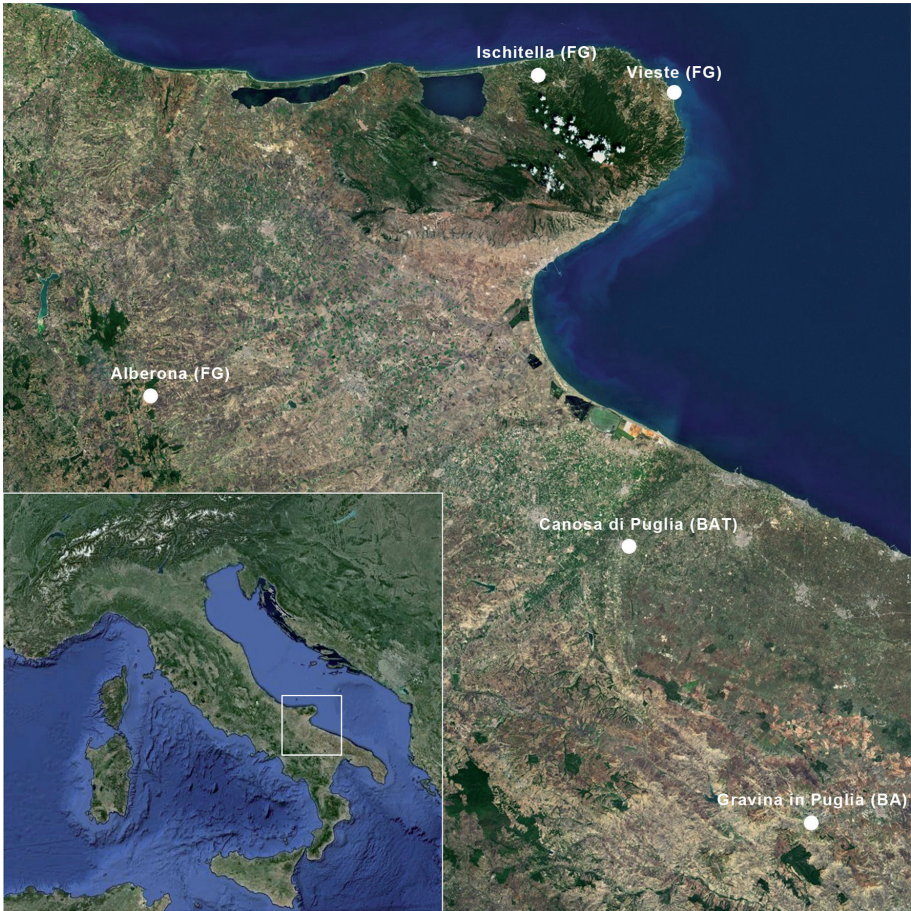

Figure 1.
Italy, Apulia (square): Geographical location of the graves.

5) Cranial characteristics; 6) characteristics of the lesion (location, shape, measurements, type of edges, healing); 7) reference. The findings date span from 1981 up until 2010: some skulls are incomplete and so do not have all the information.

3.2 Case 1: CSP 2

1. Archeological information: Canosa (Barletta-Andria-Trani); San Pietro archeological area (2001); II archeological dig; tomb n.2.; period VI-VII centuries.
2. Biological profile: male. Presumed age at death: 21–25 years old based on the centres of ossification and dental eruption. Estimated height: 178.5 cm. Body mass: 78 kg.
3. Anatomical variations: none.
4. Pathologies: cribra cranii, widespread porosity in correspondence to the greater wings of the sphenoid bone, cribra orbitalia type cribotica (grade 6 di Hengen [61]), vascular striae across the frontal bone, suprainiac fossa [62], occipital bone, severe periodontal disease, vascular perforations on periarticular regions of the long bones. Differential diagnosis for lesions observed on this individual can include: scurvy, trauma, trepanomatosi, non-specific osteomyelitis and possible osteoblastoma, large parietal foramina. We can exclude the possibility that these lesions may be the result of treponematosi, non-specific osteomyelitis or osteoblastoma because the framework of that lesions may be associated with scurvy in adults - as regards periostitis and periodontal disease [47] - and with scurvy in infant - as regards cribra orbitalia, the vascular impressions on the ectocranial surface of frontal bone [63], the diffuse porosity on the large wing of the sphenoid bone, the porosity on the hard palate and severe periodontal disease [45]. Association between periodontal disease and subdural hemorrhages, in particular, indicates scurvy, the sign of avitaminosis C.
5. Cranial characteristics: hyperdolichocrania, camecraia, acrocrania, hyperurimetopic, hyperleptoprosopia, leptorinia, hypsiconchia, mesorine. Cranial capacity: 1560 cc.
6. Characteristics of the lesion: thick, triangular-shaped, symmetrical lesions in correspondence to the parietal foramina. Each triangle has one side which is parallel to the parietal foramen of the sagittal suture with a sideways facing apex. Borders present signs of new bone formation, with obliterated diploe. The medial side of the lesion, on the left parietal bone, situated 12 mm from the parietal foramen of the sagittal suture. The measurements of the perforation are as follows; transversal diameter 14.7 mm, sagittal diameter 10.2 mm. The medial side of the perforation on the left parietal bone is 10 mm from the parietal foramen on the sagittal suture. The measurements of the perforation are as follows; transversal diameter 10.4 mm, sagittal diameter 6.1 mm. Both lesions have rounded margins and are sloping inwards. The smooth lanceolate depression of the edges indicates apposition of new cortical bone around the lesions in a person who survived to the procedure. This data suggests that the perforations were performed on a live subject who consequently survived the intervention and it may be a consequence of subdural hemorrhage for scurvy (**Figure 2**) [64].
7. Reference: [36].

3.3 Case 2: SST 25

1. Archeological information: Gravina in Puglia (Bari); Santo Stefano archeological area (1993); chamber tomb n.25; *kline* II; dep. IV; period: III century BC.
2. Biological profile: male; presumed age at death: 48–57 years old; estimated height: 174 cm; body mass: 89 kg.
3. Anatomical variations: evidence of metopic suture on the frontal bone. Cleaved acromion the left shoulder.
4. Pathology: hit by a pointed weapon (probably an arrow); calcifications in the right maxillary sinus.
5. Cranial characteristics: hyperdolichocrania, camecraia, acrocrania, hyper-
eurimetopic, hyperleptoprosopia, leptorinia, hypsiconchia, hyperleptorinia;
cranial capacity: 1593 cc.
6. Characteristics of the lesion: the lesion is located on the left parietal bone, near the parietal eminence. It has an elliptical, irregular shape 18 mm x 15 mm with a major vertical axis. The posterior margins of the lesion are 72 mm from the craniometric point, *lambda*, while the inferior angle is situated 45.3 mm from the *asterion*. The margins of the lesion are more irregular along the superior side, and decline inwards, rather like the sides of a volcano, up to the point when they meet a bony layer, which occupies the superior part of the perforation. On the external surface 6 mm from the lower-inferior margin of the lesion, there is a small elliptic perforation 4 mm x 2 mm in size, which obliquely penetrates the cranial cavity. The apposition of the osseous tissue seems to have occurred at a later time than the perforation. The remarkably rounded margins suggest that the subject consequently survived the cranial trepanation, living for a long time, perhaps more than a year (**Figure 3**). The small perforation near the trepanation was probably done to drain the wound.
7. Reference: [38].

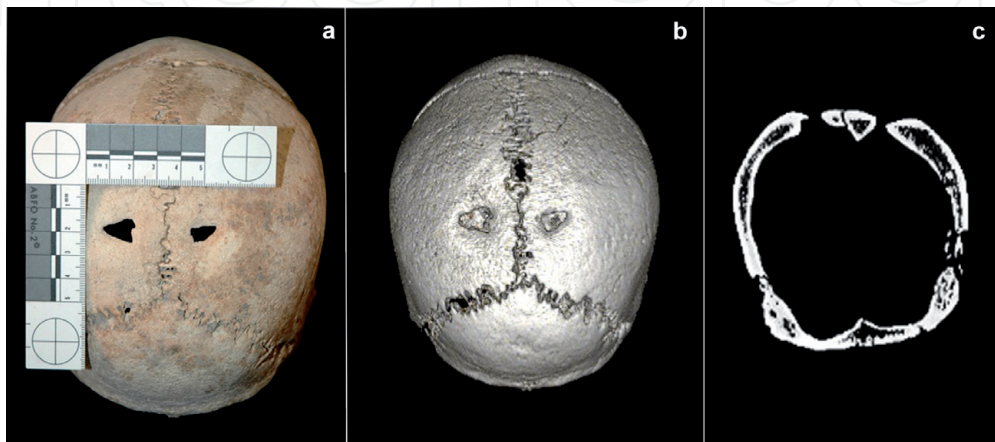


Figure 2.
“CSP 2”: Photo report (a) and CT scan (b), superior view; X-ray (c), coronal view.

3.4 Case 3: ISCH 3.2

1. Archeological information: Ischitella (peninsula of Gargano, Foggia); Monte Civita archeological area (2010); tomb n.3; interred II; period: IV century BC.
2. Biological profile: male; presumed age at death: 36–44 years old; estimated height: 165.5 cm; body mass: 76 kg.
3. Anatomical variations: none.
4. Pathology: incised lesions with no sign of the formation of scar tissue on the left femoral diaphysis and the right tibia. Osteochondritis dissecans on the right femoral head.
5. Cranial characteristics: hyperdolichocrania, camecrania, hypertapeinocrania, hypereurimetopic, mesenie, mesoconchia, leptorinia. Cranial capacity: 1291 cc.
6. Characteristics of the lesion: there is a smooth margined, trapezoidal shaped lesion present on the occipital squama of the cranium, along the right occipito-temporal suture and in correspondence to the mastoid process. The lesion is regular in shape and size. The perforation reveals, at an ectocranial level, that the greatest diameter, antero-posteriorly situated, measures 17 mm while the shorter side measures 8.6 mm. The radiological observation confirm that the lesions appear irregular contours and not rounded as to no bone remodeling post-intervention: the absence of apposition of osseous tissue suggests that either the subject did not survive trepanation or that the procedure was, in fact, carried out post mortem since the lesion did not undergo cicatrisation (**Figure 4**).
7. Reference: none.

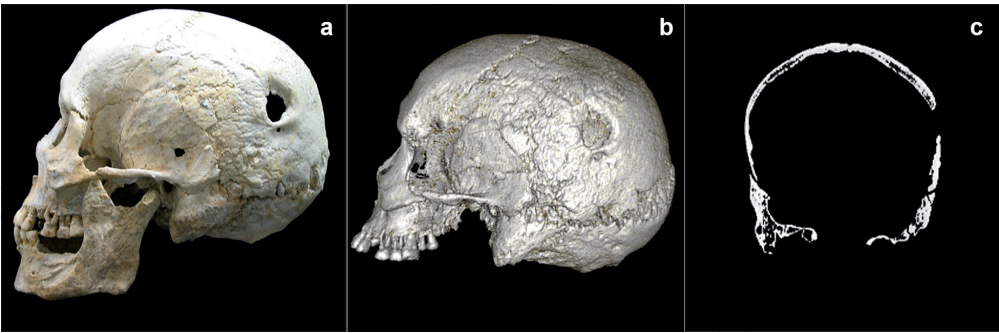


Figure 3.
“SST 25”: Photo report (a) and CT scan (b), lateral view; X-ray (c), coronal view.

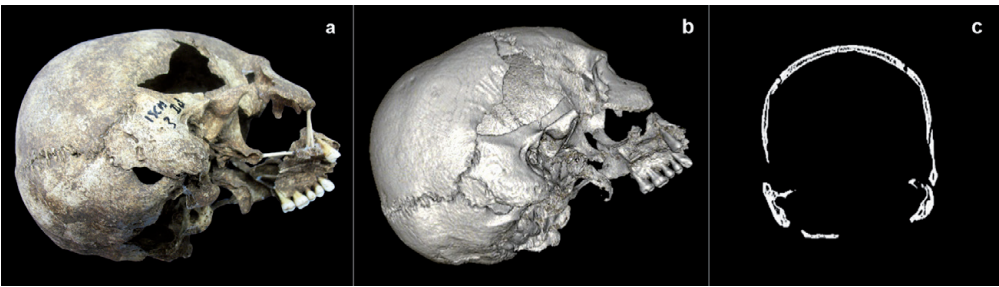


Figure 4.
“ISCH 3.2”: Photo report (a) and CT scan (b), occipital-lateral view; X-ray (c), coronal view.

3.5 Case 4: ALB 1

1. Archeological information: Alberona (Foggia); Church of the Nativity of the Virgin Mary (1995); period: III-IV century (according to radiocarbon dating).
2. Biological profile: male (gender grading =0,97); age at death: 40 years old; estimated height: 164 cm; body mass: 68 kg.
3. Anatomical variations: *torus acusticus*.
4. Pathology: none.
5. Cranial characteristics: hyperdolichocrania, ortocrania, metriocrania, stenome-topic, mesenie, hypsiconchia, mesorine; cranial capacity: 1414 cc.
6. Characteristics of the lesion: on the left parietal bone and covering a part of the occipital bone a quadrilateral shaped lesion is present with the medial edge almost brushing the lambda craniometric point, while the inferior edge skirts past the lamboidal area of the lamboid suture. The lesion measures 29.9 mm in a cranial-caudal direction and 31.6 mm towards the biparietal area. The appo-sition of osseous tissue suggests that the subject consequently survived cranial trepanation (**Figure 5**).
7. Reference: [37].

3.6 Case 5: VIE r.s.18

1. Archeological information: Vieste (peninsula of Gargano, Foggia); Vieste, Via Spina (2008); period: III century BC.
2. Biological profile: male; generically adult. We cannot provide more detailed information because it's impossible to attribute its post-cranial skeleton.
3. Anatomical variations: none.

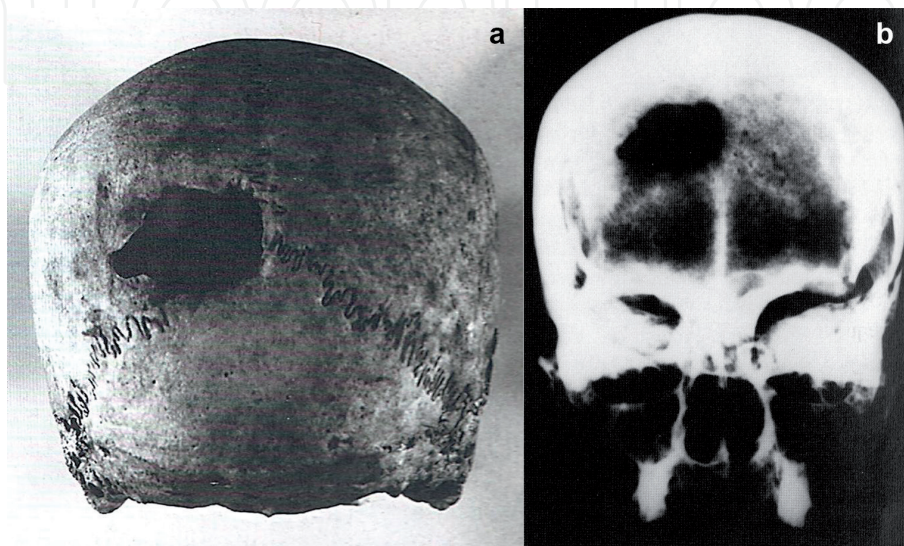


Figure 5.
“ALB 1”: Photo report (a) and X-ray (b), occipital view.

4. Pathology: round shape blunt injury located on the left parietal bone at the coronal suture of the left *pars bregmatica*.
5. Cranial characteristics: undetectable.
6. Characteristics of the lesion: on the left of the squama occipitalis, a pyri-form shaped lesion is present. Its base is placed medially and the apex laterally encompassing the medial aspect of the lamboid suture. The ectocranial dimensions are transversely 23.2 mm x 11 mm. The cranio-caudal dimensions, 19.2 mm. The ectocranial dimensions are transversely 21.4 mm x 11 mm, cranio-caudal 19.2 mm. The medial margin of the lesion slopes internally to form an inverted volcano shape. The margin appear moderately rounded. The apposition of osseous tissue suggests that the subject consequently survived cranial trepanation (**Figure 6**).
7. Reference: [36].

3.7 Case 6: the “Bologna skull”

1. Archeological information: Canosa (Barletta-Andria-Trani); unknown origin (recovered from Bologna in 1999); period: VI century (according to radiocarbon dating).
2. Biological profile: probably a female; young adult (according to the patency of the cranial sutures).
3. Anatomical variations: undetectable.
4. Pathology: undetectable.
5. Cranial characteristics: without the mandible.
6. Characteristics of the lesion: the semi-circular shaped lesion is situated on the right parietal bone. The margins of the perforation are fairly regular and the walls of the lesion are vertical and perpendicular to the parietal bone there is an evident loss of bone tissue around the hole with crateriform enlargement with the diploe visible on all sides of the perforation. The anterior margin of the perforation is 9 mm away from the bregma along the right coronal suture. The medial edge is 13.5 mm from the bregma along the sagittal suture. The ectocranial dimensions are 12.5 mm x 11 mm. The absence of apposition of

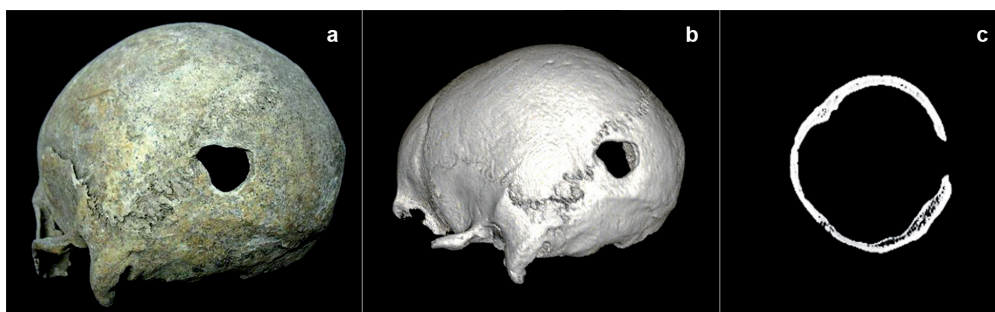


Figure 6.
“VIE r.s. 18”: Photo report (a) and CT scan (b), occipital-lateral view; X-ray (c), coronal view.

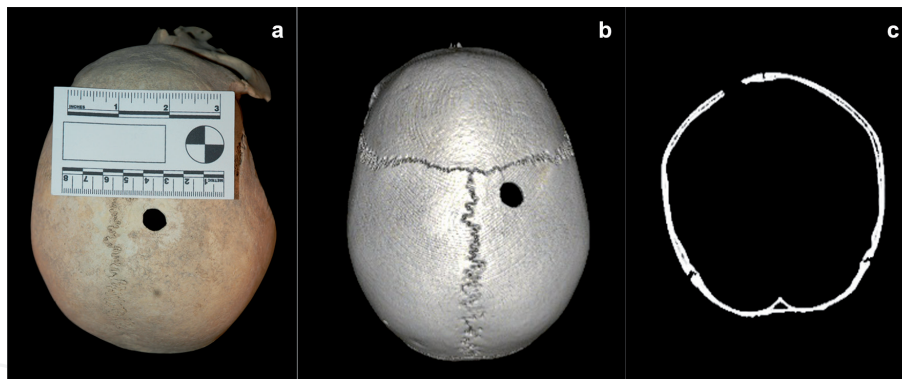


Figure 7.
The “Bologna skull”: Photo report (a) and CT scan (b), superior view; X-ray (c), coronal view.

osseous tissue and not evident thickening marginal bone remodeling suggests that the subject did not survive trepanation as the lesion did not undergo cicatrization (Figure 7).

7. Reference: [27, 36].

4. Discussion

About distribution of this evidence by gender and age on the sample, five subjects are male (CSP 2; SST 25; ISCH 3.2.; ALB 1; VIE r.s.18) and just one probably female (the “Bologna skull”). All the crania are from adult subjects as most found in the anthropological literature, except for rare cases [32, 64, 65]. Mariani-Costantini and colleagues ([32], analyzed the skull of a child from Imperial Rome, that showed evidence of hydrocephaly. The authors argue against hydrocephaly as the need for trepanation, performed to alleviate symptoms of this disease. The most common hypothesis surrounding trepanation is that it was performed as a surgical treatment in cases of severe disease, including scurvy [64], meningiomas and bone tumors [66], chronic ear infections [67], headaches and seizures [33]. In Roman time individuals were trepanned to alleviate intracranial pressure due to trauma or disease, treat possible cranial fractures [68]. In a case of cranial trepanation found in a Roman necropolis (Cassino, Italy, 3rd century BC) the surgical procedure seems to be referred to a treatment of a sword wound [31]. Five skulls have just one lesion (SST 25; ISCH 3.2.; ALB 1; VIE r.s.18; the “Bologna skull”); in one case (CSP 2) the result of the trepanation is a double hole. As also seen in a number of cases, the skull can be poly-trephined by two or more holes [8].

The site of cranial intervention is systematic: in four of the cases (CSP 2; SST 25; ALB 1; “Bologna skull”) involves the parietal bone (two holes on the right side, three on the left); in three cases (ISCH 3.2.; ALB 1; VIE r.s.18) involves the occipital bone; finally in only one skull (ISCH 3.2.) the temporal bone, on the right. The shape of the lesion is regular and attributable to geometric shapes (triangle, trapezium, quadrilateral, piriform, semicircular) in five cases (CSP 2; ISCH 3.2.; ALB 1; VIE r.s.18; the “Bologna skull”), except one case (SST 25). Measures ranging from a minimum of 8.6 mm to a maximum of 31 mm. The edges of the lesions are rounded and sloping inward where the operation has been successful and the patient survived; otherwise, where the intervention did not have healing or was made *post mortem*, the edges are irregular and the diploe is visible on all sides of the perforation.

Analysis of skeletal features shows in four cases (CSP 2; SST 25; ALB 1; VIE r.s.18), convincing evidence that the cranial trepanations were carried out *ante mortem*: the hypothesis is confirmed both by radiographic and tomographic examination, which revealed evidence of remodeling of the cranial tables, indicative of the subjects having survived the procedures. Bone regrowth is representative of the individual's extended postoperative survival and his rehabilitation.

However, in two cases (ISCH 3.2.; the "Bologna skull"), are absent signs of osseous remodeling, suggesting that the subjects did not survive the trepanation or alternatively that the procedure was made *post mortem* on the corpse. As documented in both ancient and present times, trephination has also been reported to be adopted as a magic-ritual practice. In *post-mortem* symbolic trephinations, cranial bones were being used as religious objects that have curative powers in Medieval Europe and bone roundels were worn as ornaments or amulets [69, 70].

Different techniques of drilling are attested. In three cases (CSP 2; SST 25; ALB 1) the morphology of the trepanned apertures – especially the broad shallow bevel of the edges - indicates that was probably used the scraping technique, when a sharp-edged tool is repeatedly scraped over a designated portion of the bone until the vault was away and oval or round-shaped perforation is complete: the edges, in fact, are of this type - a broad shallow bevel, smooth and remodeled - while the diploe is not visible.

A double well healed skull trephination associated with a post-cranial traumatic event occurring *intra vitam* to a young male from the Early Chalcolithic cemetery of Pontecagnano (South Italy, ca. 4900–4500 cal BP). X-ray and 3D-CT scan skull-cap evaluation revealed that an orifice was probably produced by scraping with a sharp stone tool, obtained by clockwise rotation motion of a right-handed surgeon facing the patient [71]. A second trephination instead seems carried out by drilling with a stone point as a tool, which produced a round, cone-shaped hole, involving only the external cortical layer.

In two cases (the "Bologna skull"; VIE r.s.18) the trepanned apertures indicate that was probably used the incision/chiseling technique: edges are steeply beveled and the diploe is visible. The latter case (ISCH 3.2) is an unusual trepanation for anatomical location and it's difficult to recognize the precise technique. A metal or a hard instrument was employed, maybe drills and chisels.

Cranial trepanation is the most valid explanation for the presence of these holes on the skulls, excluding the possibility that they are anatomical variations, matches of trauma, secondary breaks after the deposition or diagenetic events of the soil. Concerning CSP 2, based on differential diagnosis cranial trepanation is the most valid hypothesis. For this study, we reconsidered the possibility that it can be caused by a pathology. Enlarged parietal foramina or "Catlin marks" are symmetrical, normally oval defects in the parietal bone situated on each side of the sagittal and involve the lack of ossification of the posterior membranous parietals suture. In the past, enlarged parietal foramina were confused with trepanations [72]. Concerning this finding, we do not totally exclude the possibility that the holes were caused by this pathology. But, based on the data obtained from the CT image, there appears to be a re-apposition of the bone after the trepanation. This further supports the hypothesis of medical intervention. In this case, it would be an operation performed by a person with in-depth anatomical knowledge.

From contemporaneous perspective, the motivation of trepanation events in the past can only be conjectured. Although in literature various motives are debated, grouped into two wide-ranging categories: therapeutic and ritual [73].

Explanations for ritual trepanations are the hardest to interpret, as their motive is culturally based [74]. Motivations for therapeutic trepanations are mainly

CASE	SKULL	SITE	PERIOD	SEX	AGE	LOCATION	TECHNIQUE	HEALING
1	CSP 2	Canosa - S.Pietro	VI-VII century	M	Young adult (21–25)	Parietal (right side; left side)	Scraping	Present
2	SST 25	Gravina - S.Stefano	III century BC	M	Mature (48–57)	Parietal (left side)	Scraping	Present
3	ISCH 3.2.	Ischitella - Monte Civita	IV BC century	M	Adult (36–44)	Occipital; temporal (right side)	Chiseling	Absent
4	ALB 1	Alberona - Church of the Nativity of the Virgin Mary	II-III century	M	Adult (40)	Parietal (left side); occipital	Scraping	Present
5	VIE r.s. 18	Vieste - Vieste via Spina	III century BC	M	Generically adult	Occipital	Not determinable	Present
6	“Bologna skull”	Canosa - unknow origin	VI-VII century	F	Young adult (20–30)	Parietal (right side)	Chiseling	Absent

Table 1.
Summary view of the data.

twofold: were performed to alleviate trauma caused by various factors (e.g. open and closed fractures of the skull, remove foreign bodies) or treat injury and illness [75, 76].

In our case studies there are no specific evidences which can highlight the motives behind the trepanation. We cannot motivate the procedure, if for therapeutic, magic/ritual or both reason, based on the location, the technique, the shape, the success of the surgery or other cultural or archeological evidence. In one case (CSP 2) it's possible that the drilling is therapeutic, to rid the tissues of the head from subperiosteal hemorrhage, one of the main symptoms of scurvy, of which he was ill the subject [64]; in another case (SST 25) we hypothesize that the hole, caused by a pointed weapon, maybe an arrow, produced a penetrating wound with the formation of an epidural or subdural hematoma, which necessitated the surgical operation. The absence of signs of healing in two cases (ISCH 3.2.; the "Bologna skull") suggests two possible interpretations: therapeutic if the surgical operation is not successful and the patient died during or shortly after; ritual if these drillings have been made after the death of the subject. **Table 1** shows a summary view of the data.

However, only a scarce numbers of studies have underline the role of anesthesia [77] to minimize pain during operations performed. Mednikova [78] suggests that immersion in altered states of consciousness may have been a necessary part of the process of trepanation, along with shamanic practices, such as consumption of psychotropic substances or ecstatic dance. Inserting these elements in the Mediterranean and southern Italian context, it is possible to mention how Tarantism in Puglia has been known since ancient times as an ecstatic and therapeutic dance for other kinds of pathology. We have no direct evidence about the use of drugs or different methods of altering consciousness used. We can only speculate about the consumption of fungi [79] or the use of smoke from the burning leaves, such as the use of juniper (*Juniperus sibirica*) and thyme (*Thymus vulgaris*) in shamanic practices in some Siberia population [80], as reported in ethnographic materials collected worldwide. John Moyle in his work "Chirurgus marinus or the Sea surgeon" suggests administering alcohol, in specific Cordial, a liqueur obtained from various plants, before head surgery [81].

In some tombs in the vicinity of some of the findings analyzed, in Daunia, some anthropomorphic stone funerary monuments (VIII - VI century BC) were found at the end of the last century. Studying the figurative scenes drawings, Leone [82] hypothesized the use of *Papaverum somniferum* in medical practice.

5. Conclusion

The approach of this work is global, both in terms of geographic and chronological point of view. First, the burials are representative of the territory of Apulia, from the northern to the central area of the region. The findings also cover a long period (nine centuries) from the Greek Classical (IV-III centuries BC) (SST 25; ISCH 3.2.; VIE r.s. 18) to the Late Antique period (III-VII centuries for CSP 2; ALB 1; the "Bologna skull"). Therefore, the chronological and geographical distribution and some common characteristics of the trepanation, as described in the chapter of "Discussion", allow us to draw some historical considerations. First of all, it's attested a great number of scraping, the oldest trepanning technique [22] that provides the greatest control over the process and involves the lowest risk of damaging the brain, using, especially before the widespread use of metals, a sharp-edged oval stone but more advanced instruments such as metal scrapers (raspatories) [83]. Also the large geographical distribution and chronology of the

case studies allow us to support the hypothesis of the presence of a long tradition of medical centres in Apulia. We hypothesize the existence of two medico-surgical centres for craniotomy: the oldest is of probable Greek origin, maybe Taranto (Southern Italy), the most important Greek cities of South Italy and Sicily (“magna Grecia”) where it circulates Greek culture, including the medical-surgical theories of Hippocrates. Moreover, the presence of a Greek medical school in Southern Italy could be hypothesized concerning the presence of other similar findings from Pontecagnano (Salerno, Italy) [84], Poggiardo [35] and Hymera [85]. Chronologically successive is a second centre that could be Canosa, the city of the miraculous Bishop Sabinus (514–566), connected to the Byzantine military, considering the events linked with the Greek-Gotica war (535–553) and the Longobardian invasions of Italy in 568.

The study of cranial perforation also allows us to underline the utmost importance of radiodiagnostic examination as well as a multidisciplinary approach to reach an optimum situation for a complete evaluation of human remains. The analysis of cranial osteological information should be multidisciplinary involving anthropology, forensic pathology, odontology and radiography. Human skeletal remains with pathological lesions of dubious origin should always undergo, not only direct observation with systems of magnification but also an in-depth multidisciplinary and structural radiological examination to create a correct diagnostic picture regarding the origin and characteristics of the pertinent lesions, applying forensic sciences standards. Such findings could have an important historical and cultural relevance regarding the methods and reasons for cranial perforation which would enable such lesions to be identified either as those executed as a therapeutic measure or those executed as part of a ritualistic magic cult.

Acknowledgements

The authors are grateful to Emilio Nuzzolese, Department of Public Health Sciences and Pediatrics - University of Turin, for radiological analysis. The authors also thank the external reviewer for their insightful suggestions, which greatly improved this work.

IntechOpen

Author details

Alessio Vovlas^{1,2*}, Nunzio Di Nunno³, Ginevra Panzarino¹
and Sandro Sublimi Saponetti¹

1 Laboratory of Anthropology, Department of Biology, “Aldo Moro” University of
Bari, Via Orabona 4, 70125, Bari, Italy

2 Aps Polyxena, Via Petrarca 12, 70014, Conversano (Bari), Italy

3 Department of History Society and Human Studies, University of Salento-Lecce,
73100, Lecce, Italy

*Address all correspondence to: alessiovovlas@email.it

IntechOpen

© 2020 The Author(s). Licensee IntechOpen. This chapter is distributed under the terms of the Creative Commons Attribution License (<http://creativecommons.org/licenses/by/3.0>), which permits unrestricted use, distribution, and reproduction in any medium, provided the original work is properly cited. 

References

- [1] Arnott R, Finger S, Smith C. Trepanation: History, Discovery, Theory. Swets & Zeitlinger, Lisse. 2003
- [2] Brothwell DR. Digging up bones. London, British Museum (Natural History). 1972.
- [3] Roberts MC, Manchester K. The archaeology of disease. 2005;3.
- [4] Lisowski FP. Prehistoric and early historic trepanation. Diseases in antiquity. 1967:651-72.
- [5] Verano JW. Differential diagnosis: trepanation. International Journal of Paleopathology. 2016 Sep 1;14:1-9.
- [6] Gross CG. Trepanation from the Palaeolithic to the Internet. Trepanation: History, Discovery, Theory. Swets & Zeitlinger, Lisse. 2003 Jan 1:307-22.
- [7] Alt KW, Jeunesse C, Buitrago-Téllez C, Wächter R, Boës E, Pichler SL. Evidence for stone age cranial surgery. Nature. 1997; 387: 360.
- [8] Capasso L, Michetti E, Pierfelice L, D'Anastasio R. Neurosurgery 7000 years ago in central Italy. The Lancet 2002; 359(9324), 2206.
- [9] HersHKovitz I. Trephination: the earliest case in the Middle East. Journal of the Israel Prehistoric Society. 1987, 20: 128-135.
- [10] Vegetti M. Ippocrate. Opere. Utet, Torino. 1965.
- [11] Pencer WG. Celsus, De Medicina. Loeb Classical Library, London-Cambridge. 1961.
- [12] Raeder I. Oribasius, Collectiones Mediacarum reliquiae. Corpus Medicorum Graecorum VI 2.1, Lipsiae et Berolini.1931.
- [13] Kuehn CG *De methodo medendi, in Galeni Opera omnia*, X. Lipsiae, 1825
- [14] Crubézy É, Bruzek J, Guilaine J, Cunha E, Rougé D, Jelinek J. The antiquity of cranial surgery in Europe and in the Mediterranean basin. Comptes Rendus de l'Académie des Sciences-Series IIA-Earth and Planetary Science. 2001;332(6):417-23.
- [15] Lillie MC. Cranial surgery dates back to Mesolithic. Nature. 1998. 391(6670):854.
- [16] Germanà F, Fornaciari G. Trapanazioni, craniotomie e traumi cranici nell'Italia antica. Pisa: Giardini editori e stampatori. 1992.
- [17] Aufderheide AC. The enigma of ancient cranial trepanation. Minnesota medicine. 1985 Feb;68(2):119.
- [18] Fernando HR, Finger S. Ephraim George Squier's Peruvian skull and the discovery of cranial trepanation. Trepanation history, discovery, theory. 2005 Sep 26:3-18.
- [19] Campillo D. Neurosurgical pathology in prehistory. Acta Neurochirurgica. 1984 Sep 1;70(3-4):275-90.
- [20] Buikstra JE. Standards for data collection from human skeletal remains. Arkansas archaeological survey research series. 1994;44.
- [21] Aufderheide AC, Rodríguez-Martín C, Langsjoen O. The Cambridge encyclopedia of human paleopathology (Vol. 478). Cambridge: Cambridge University Press; 1998.
- [22] Weber J, Wahl J. Neurosurgical aspects of trepanations from Neolithic times. International Journal of Osteoarchaeology. 2006 Nov;16(6):536-45.

- [23] Lawrence C. The evolution of surgical instruments: An illustrated history from ancient times to the twentieth century. *Bulletin of the History of Medicine*. 2007;81(3):661-2.
- [24] Verano JW. Trepanation in prehistoric South America: geographic and temporal trends over 2,000 years. *Trepanation history, discovery, theory*. 2003 Jan 1(17):223-36.
- [25] Campillo D, Guixé EG, López MC. La trepanación prehistórica. Edicions Bellaterra; 2007.
- [26] Prioreshi P. Possible reasons for Neolithic skull trephining. *Perspectives in biology and medicine*. 1991;34(2):296-303.
- [27] Facchini F, Rastelli E, Ferrero L, Fulcheri E. Cranial trepanation in two skulls of early medieval Italy. *Homo*. 2003 Jan 1;53(3):247-54.
- [28] Fornaciari G, Naccarato G. La trapanazione del cranio in Italia. *Le Origini della Chirurgia Italiana*. Ministero per i Beni Culturali e Ambientali. Edigrafital S.p.A., Teramo, 1993;67-79.
- [29] Giuffra V, Fornaciari G. Trepanation in Italy: a review. *International Journal of Osteoarchaeology*. 2017 Sep;27(5):745-67.
- [30] Piombino-Mascali D, Batoli F, Pagni G, Fornaciari GI, Mallegni F. A late renaissance case of trepanation and pseudopathological damage from Populonia (central Italy). *Journal of Paleopathology*. 2006;18(1):15.
- [31] Rubini M. A case of cranial trepanation in a Roman necropolis (Cassino, Italy, 3rd century BC). *International Journal of Osteoarchaeology*. 2008 Jan;18(1):95-9.
- [32] Mariani-Costantini R, Catalano P, di Gennaro F, Di Tota G, Angeletti LR. New light on cranial surgery in ancient Rome. *The Lancet* 2000;355(9200), 305-307.
- [33] Capasso L, Di Tota G. Possible therapy for headaches in ancient times. *International Journal of Osteoarchaeology*, 1996; 6(3), 316-319.
- [34] Pasini A, Donati R, Bramanti B, Salzani L, Gualdi-Russo E. New Evidence of Prehistoric Neurosurgery in Italy: The Case of Castello Del Tartaro. *World neurosurgery*, 2019; 128, 556-561.
- [35] Mallegni F. Analisi antropologica e paleopatologica degli inumati di Poggiardo. *Studi di Antichità* 1981;2: 175-196
- [36] Nuzzolese E, Sublimi Saponetti S, Scattarella V, Capece M, Di Nunno N. Case Studies of Cranial Trepanation in Apulia (Southern Italy) Through Forensic Imaging. In *Putting out forensic house in order: examining, validation and expelling incompetence*. American Academy of Forensic Sciences. 2010;16:278-279.
- [37] Scattarella V, Sublimi Saponetti S, Cusianna N, Gattulli A. A case of skull trephination from late Imperial Rome. *Journal of Paleopathology*. 1996;8:85-8.
- [38] Saponetti SS, Scattarella V, Volpe G. Cranial Trepanation in an Individula of the Hellenistic Age (III century bc) from the Necropolis of Contrada Santo Stefano (Gravina, Bari, Italy). *Journal of Paleopathology*. 1998;10(3):121-6.
- [39] Ferembach D, Schwidetzky I, Stloukal M. Raccomandazioni per la determinazione dell'età e del sesso sullo scheletro. *Rivista di Antropologia*. 1977-1979;60: 5-51
- [40] Lovejoy CO, Meindl RS, Pryzbeck TR, Mensforth RP. Chronological metamorphosis of the auricular surface of the ilium:

a new method for the determination of adult skeletal age at death. *American journal of physical anthropology*. 1985 Sep;68(1):15-28.

[41] Vallois HV. Vital statistics in prehistoric populations as determined from archaeological data. The application of quantitative methods in archaeology. 1960(28):186.

[42] Martin R, Saller K. *Lehrbuch der Anthropologie*. G. Fischer, Stuttgart. 1956.

[43] Duyar I, Erdal YS. A new approach for calibrating dental caries frequency of skeletal remains. *Homo*. 2003 Jan 1;54(1):57-70.

[44] Dobney K, Brothwell D. A method for evaluating the amount of dental calculus on teeth from archaeological sites. *Journal of Archaeological Science*. 1987 Jul 1;14(4):343-51.

[45] Goodman AH, Armelagos GJ, Rose JC. Enamel hypoplasias as indicators of stress in three prehistoric populations from Illinois. *Human biology*. 1980 Sep 1;51:5-28.

[46] Trotter M, Gleser GC (1958) A re-evaluation of the estimation of stature base on measurements of stature taken during life and on long bones after death. *American Journal of Physical Anthropology*. 1958;16:79-88.

[47] Trotter M, Gleser GC. Corrigenda to "Estimation of stature from long limb bones of American White and Negroes". *American Journal of Physical Anthropology*. 1977;47: 355-356

[48] Ruff CB, Trinkaus E, Holliday TW. Body mass and encephalization in Pleistocene Homo. *Nature*. 1997 May;387(6629):173-6.

[49] Kennedy KA. Skeletal markers of occupational stress. *Reconstruction of Life from the Skeleton*. 1989:129-60.

[50] Lai P, Lovell NC. Skeletal markers of occupational stress in the fur trade: a case study from a Hudson's Bay Company fur trade post. *International Journal of Osteoarchaeology*. 1992 Sep;2(3):221-34.

[51] Pálfi A. Traces de activités sur le squelettes des ancien Hongrois. *Bulletins et Mémoires de la Société d'Anthropologie de Paris*. 1971;4(3-4): 209-231

[52] Robb JE. Issues in the skeletal interpretation of muscle attachments. In *Annual Meeting of the Paleoanthropology Society*, Anaheim, California April 1994 Apr 19 (pp. 19-20).

[53] Rogers J, Waldron T, Dieppe P, Watt I. Arthropathies in palaeopathology: the basis of classification according to most probable cause. *Journal of Archaeological Science*. 1987 Mar 1;14(2):179-93.

[54] Borgognini Tarli SM, Repetto E. Skeletal indicators of subsistence patterns and activity regime in the Mesolithic sample from Grotta dell'Uzzo (Trapani, Sicily): A case study. *Human Evolution*. 1986;4:331-352

[55] Capasso L, Kennedy KA, Wilczak CA. *Atlas of occupational markers on human remains*. Edigrafital; 1999.

[56] Larsen CS. *Bioarchaeology interpreting behaviour from the human skeleton*. Cambridge University Press, Cambridge. 1999.

[57] Ledger M, Holtzhausen LM, Constant D, Morris AG. Biomechanical beam analysis of long bones from a late 18th century slave cemetery in Cape Town, South Africa. *American Journal of Physical Anthropology: The Official Publication of the American Association of Physical Anthropologists*. 2000;112(2):207-16.

- [58] Stock J, Pfeiffer S. Linking structural variability in long bone diaphyses to habitual behaviors: foragers from the southern African Later Stone Age and the Andaman Islands. *American Journal of Physical Anthropology: The Official Publication of the American Association of Physical Anthropologists*. 2001 Aug;115(4):337-48.
- [59] Roy TA, Ruff CB, Plato CC. Hand dominance and bilateral asymmetry in the structure of the second metacarpal. *American Journal of Physical Anthropology*. 1994 Jun;94(2):203-11.
- [60] Cameriere R, Ferrante L, Belcastro MG, Bonfiglioli B, Rastelli E, Cingolani M. Age estimation by pulp/tooth ratio in canines by peri-apical X-rays. *Journal of forensic sciences*. 2007 Jan;52(1):166-70.
- [61] Hengen OP. Cribra orbitalia: Pathogenesis and probable etiology. *Homo*, 1971; 22: 57-76
- [62] Holliday TW. Postcranial evidence of cold adaptation in European Neandertals. *American Journal of Physical Anthropology: The Official Publication of the American Association of Physical Anthropologists*. 1997 Oct;104(2):245-58.
- [63] Cargill T. Legion of Lesions – Exploration of Scorbutic Cranial Lesions from a Romano British Cemetery. Poster presented at the 41st North American Annual Meeting of the Paleopathology Association, April 8-9, Calgary, Alberta Canada. 2014.
- [64] Mogle P, Zias J. Trephination as a possible treatment for scurvy in a middle bronze age (ca. 2200 BC) skeleton. *International Journal of Osteoarchaeology*. 1995 Mar;5(1):77-81.
- [65] Bereczki Z. Evidence of surgical trephinations in infants from the 7th–9th centuries AD burial site of Kiskundorozsma-Kettőshatár. *Acta Biologica Szegediensis*. 2010 Jan 1;54(2):93-8.
- [66] Smrcka V, Kuzelka V and Melkova J. Meningioma probable reason for trephination. *International Journal of Osteoarchaeology*. 2003, 13.5 (2003): 325-330.
- [67] Mann G. Chronic ear disease as a possible reason for trephination. *International Journal of Osteoarchaeology*, 1991, 1.34: 165-168.
- [68] Capasso L, Capelli A. A Trephined Skull from Central Italy, Dated to Roman time (1st-2 century AD). *Paleopathology Association European Members Meeting* (9th, 1992, Barcelona, Spain) 1995; p. 103-106.
- [69] Ruffer MA. Studies in paleopathology: some recent researches on prehistoric trephining. *Journal of Pathology and Bacteriology*. 1918; 22: 90-104.
- [70] Oakley KP, Brooke WM, Akester AR, Brothwell DR. 133. Contributions on Trepanning or Trephination in Ancient and Modern Times. *Man*, 1959; 93-96.
- [71] Petrone P, Niola M, Di Lorenzo P, Paternoster M, Graziano V, Quaremba G, Buccelli C. Early medical skull surgery for treatment of post-traumatic osteomyelitis 5,000 years ago. *Plos one*, 2015; 10(5), e0124790.
- [72] Ortner DJ. Identification of pathological conditions in human skeletal remains. Academic Press; 2003 Jan 10.
- [73] Gresky J, Batieva E, Kitova A, Kalmykov A, Belinskiy A, Reinhold S, Berezina N. New cases of trepanations from the 5th to 3rd millennia BC in Southern Russia in the context of previous research: Possible evidence for a ritually motivated tradition of cranial

surgery?. American journal of physical anthropology. 2016 Aug;160(4):665-82.

[74] Premužić Z, Šikanjić PR, Papeša AR. A case of Avar period trepanation from Croatia. Anthropological review. 2016 Dec 1;79(4):471-82.

[75] Nemeskéri J, Alán K, Harsányi L. Trephined skulls from the tenth century. Akadémiai Nyomda; 1965.

[76] Weber J, Czarnetzki A. Brief communication: neurotraumatological aspects of head injuries resulting from sharp and blunt force in the early medieval period of southwestern Germany. American Journal of Physical Anthropology: The Official Publication of the American Association of Physical Anthropologists. 2001 Apr;114(4):352-6.

[77] Zäuner SP, Wahl J, Boyadziev Y, Aslanis I. A 6000-Year-Old Hand Amputation from Bulgaria—The Oldest Case from South-East Europe?. International Journal of Osteoarchaeology. 2013 Sep;23(5):618-25.

[78] Mednikova MB. Trepanations among ancient peoples of Eurasia. Scientific World: Moscow, Russia. 2001.

[79] Høyersten JG. Manifestations of psychiatric illness in texts from the medieval and Viking era. Archives of Psychiatry and Psychotherapy. 2015 Jun 1;2:57-60.

[80] Slepchenko SM, Vybornov AV, Slavinsky VS, Tsybankov AA, Matveev VE. Ante Mortem Cranial Trepanation in the Late Bronze Age in Western Siberia. International Journal of Osteoarchaeology. 2017 May;27(3):356-64.

[81] Moyle J. Chirurgus marinus or The sea-chirurgion. London. 1702.

[82] Leone L. Oppio, Papaver somniferum. La pianta sacra ai Dauni

delle stele. Bollettino Camuno Studi Preistorici. 1995;28:57-68.

[83] Novak M, Nađ M, Pleše T, Čavka M. Skeletal evidence of trepanning on a 5th century skull from Ludbreg, Croatia. Acta medico-historica Adriatica. 2013 Dec 15;11(2):197-212.

[84] Fornaciari G, Mezzetti MG, Roselli A. Trapanazione cranica del IV secolo a.C. da Pontecagnano (Salerno). Studi Etruschi 1990;56:285-286.

[85] Fabbri F, Fornaciari G, Caramella D, Accomando G, Vassallo S. Discovery of the first hippocratic cranial trepanation from the Greek colony of Himera, Sicily (6th–5th century B.C.). Paleopathology newsletter. 2006; 136:6-10.