

We are IntechOpen, the world's leading publisher of Open Access books Built by scientists, for scientists

6,900

Open access books available

185,000

International authors and editors

200M

Downloads

Our authors are among the

154

Countries delivered to

TOP 1%

most cited scientists

12.2%

Contributors from top 500 universities



WEB OF SCIENCE™

Selection of our books indexed in the Book Citation Index
in Web of Science™ Core Collection (BKCI)

Interested in publishing with us?
Contact book.department@intechopen.com

Numbers displayed above are based on latest data collected.
For more information visit www.intechopen.com



Uveal Melanoma

Kristina Horkovicova and Alena Furdova

Abstract

Currently, melanoma of uvea is the most well-known essential tumor, which is intraocular and malignant. Treatment using radiation has now supplanted enucleation as the therapy of decision. Radioactive eye plaques and treatment using proton are being the two most examined radiotherapeutic modalities. All the more as of late, stereotactic radiosurgery and fractionated stereotactic radiotherapy have risen as promising, non-intrusive medicines for uveal melanoma. Technique called stereotactic radiosurgery might be viewed as like “not surgery” on the grounds no extractions are included. All things being equal, it is a serious strategy for radiation treatment that conveys high dosages of radiation to exceptionally little territories and volumes.

Keywords: intraocular tumor, uveal melanoma, radiotherapy, stereotactic radiosurgery

1. Introduction

Malignant melanoma of uvea (iris, ciliary body, and choroid), is the most widely recognized essential intraocular danger in grown-ups. Uveal melanoma (UM) is analyzed generally in more established age, with a dynamically increasing age-explicit frequency rate that tops close to the age of seventy. Ocular melanoma is probably going to metastasize in different regions of the body, for example, breast, lung, kidney or liver.

There are many factors associated with the development of uveal melanoma. The most important include genetic factors, race, color of the eyes, fair coloring of the skin and the ability to tan. Many observational studies up to date have attempted to explore the relationship between sunlight exposure and risk of uveal melanoma development [1].

Usually, uveal melanomas are in early stages of their development completely asymptomatic. The comparatively low incidence of iris melanomas (anterior segment melanoma) has been attributed to the characteristic features of these tumors. Iris melanomas also rarely metastasize. Posterior melanoma - choroidal melanoma is the most common ocular melanoma type. This type is involved in over 75% of all intraocular melanomas. Iris melanoma which is in anterior segment is cytologically less malignant and metastasize less frequently than posterior uveal melanomas.

Ordinarily, choroidal melanoma is brown colored, raised mass, and the level of its pigmentation can go from dim earthy colored to thoroughly white, amelanotic.

In advanced stages the symptoms are dependent on tumor location. The most important test to establish the presence of intraocular melanoma, is the examination by an experienced clinician at specialized Ophthalmology Department. Diagnostic testing can be extremely valuable in establishing and confirming the diagnosis.

Prognosis can be influenced by number of factors. The most important are the histopathologic type of cells, the size of tumor, tumor volume, the margins of the tumor, karyotype and grading and staging by TNM Classification (e.g. extraocular extension). Cell type, however, remains the most often used predictor of outcome with genetic results.

The treatment relies upon the site of birthplace (choroid, ciliary body or iris), the size, volume and area of the injury, the general status of the patient, age of the patient and whether extraocular attack, repeat or metastasis has happened. Extraocular augmentation, repeat, and metastasis are related with a very helpless guess and long-term endurance cannot be normal [2].

Elective therapy modalities have been proposed as of late including extremist careful evacuation of the eye globe (enucleation), nearby resection, light procedures: plaque brachytherapy, charged-molecule radiotherapy, stereotactic photon bar illumination treatment or in start of the tumor transpupillary thermotherapy and photodynamic treatment.

Over the past 3–4 decades diagnostic methods have improved and radiotherapy (external beam, charged particle or brachytherapy) has become the preferred treatment for most of the patients with uveal melanoma. The aim of the treatment is to improve survival and preserve eye globe anatomically with aim to preserve the best vision in patients with uveal melanoma. Different radiation modalities are currently in use in treatment of posterior uveal melanoma in many Ophthalmology Centers. One of the methods of “conservative” approach is the stereotactic radiosurgery (SRS) by linear accelerator [2–5].

2. Uvea and uveal tumors

The uveal parcel frames the center layer (or “vasculo-strong” coat) mass of the eyeball. Uvea layer is a combination of veins, pigmented cells and muscles, woven together by connective tissue. It has a nutritive capacity of the eye globe. The uveal parcel comprises of three anatomical parts, all profoundly vascular and pigmented. The noticeable part in front is the iris (part of the foremost portion of the eye) and it makes the shade of the eye globe. The iris consolidates in reverse into the ciliary body, and the ciliary body offers path to the choroid, to the back fragment of the eye globe, which is such a vascular undercoat between the sclera and the shade retina. It is substantial pigmented, along these lines engrossing light which has gone through the retina.

2.1 Uvea layer

The pigmented cells (the melanocytes) - are derived from the neural crests which have migrated to the skin and mucous membranes. Melanocytes synthesize a special organelle called a melanosome – this is responsible for the characteristic color of the skin in different races. Melanosis (melanocytosis) refers to increased pigmentation caused by hyperplasia or hypertrophy of melanocytes.

Changes in melanocytes usually cause melanomas. Melanocytes produce melanin, which is responsible for skin and hair tone. It can show up on ordinary skin or it might start as a mole or other territory that has changed in appearance. A few moles that are available upon entering the world may form into melanomas during the adulthood.

Benign tumor composed of nevus cells or melanocytes is nevus. In nevi cells contain melanosomes and are therefore capable of producing pigment melanin [1].

2.2 Uveal melanoma

Melanoma is a malignant tumor resulting from a transformation of melanocytes or nevus cells. It may be pigmented or non-pigmented. Melanoma is caused mainly by intense, occasional UV exposure (frequently leading to sunburn), especially in those who are genetically predisposed to the disease. Most melanomas are dark or earthy colored, however they can likewise be skin-shaded, pink, red, purple, blue or white. In the event that melanoma is perceived and treated early, it is quite often reparable, however on the off chance that it is not, the tumor can progress and spread to different pieces of the body, particularly liver, where it turns out to be difficult to treat and can be deadly. Melanomas frequently metastasize widely and the regional lymph nodes, liver, lungs and brain are likely to be involved.

Intraocular melanoma is the most common primary ocular malignant tumor in adults and develops from uvea. Intraocular tumors might be benign or malignant.

Intraocular melanoma is a quite rare type of tumor and it occurs most often in elderly people. There is lot of cases when ophthalmologists detected intraocular melanoma during a routine eye examination. The chance of recovery is depending on factors such as the size, localization and cell type of the tumor. Extraocular extension is the term used to describe the intraocular melanoma which spreads to the optic nerve or nearby tissue of the eye socket and is the sign of the advanced stage of the tumor [6].

Intraocular melanoma of the ciliary body and choroid (structures together called the posterior uvea), is the most common primary ocular malignant tumor in adults. Iris melanomas are a subset of uveal melanomas that tend to have a more benign course, in comparison with posterior uveal melanomas. Anterior segment melanomas have a lower incidence of metastases when compared to ciliary body and choroidal melanomas. Anterior segment melanomas account for about 15% of all uveal melanomas. The incidence of uveal melanoma increases with age and reaches a maximum between the 6th and 7th decade of life. It is more common in males and is uncommon or rare in kids and darker looking people. Uveal melanomas are infrequently two-sided. Be that as it may, the quantity of patients with two-sided inclusion is more noteworthy than would be anticipated by chance alone, subsequently inferring a potential hereditary inclination.

As mentioned before, choroidal melanoma represents the most common primary intraocular tumor in adults. Peak incidence is in the early 60s representing about 7.5 cases per one million populations. Incidence is rare in younger adults under 30 years of age with an estimated peak incidence of about six cases per one hundred million. Caucasians are 8 times more likely to develop the melanoma than Africans or Afro-Americans and 3 times more likely than Asians. Intraocular melanoma is arising from choroid in more than 75% of all the cases. Whether some environmental exposure triggers the development of uveal melanoma remains an open question. Sunlight has been proposed as an environmental risk factor for melanoma generally. Unlike cutaneous melanoma, incidence rates for uveal melanoma have not increased over time and last decades and it does not vary by latitude [7, 8].

2.3 Diagnostic method of uveal melanoma

The first step to diagnose uveal melanoma is patient's history. Patients with uveal melanoma may present with complaints of visual acuity reduction, but many can be without symptoms and the condition is discovered on routine ocular examination or by glasses prescription. In eyes with clear optic media, the diagnosis of posterior uveal melanoma can be made by indirect ophthalmoscopy.

- a. ophthalmoscopy, fundus photography,
- b. transillumination,
- c. perimetry,
- d. fluorescein angiography, indocyanine green angiography,
- e. ultrasonography (A and B modes),
- f. ultrasound biomicroscopy - UBM,
- g. optical coherence tomography - OCT,
- h. computed tomography - CT,
- i. magnetic resonance imaging - MRI,
- j. fine-needle biopsy
- k. whole body PET/CT to distinguish metastasis.

Depending on their site of growth, posterior uveal melanomas differ in their symptoms, clinical presentation and appearance. A ciliary body melanoma can attain a large size, volume, before it is clinically recognized. It can be seen in association with one or more dilated episcleral blood vessels, it can present itself as an epibulbar pigmented lesion if there is transscleral extension of the tumor. Also, cataract, and/or lens subluxation or secondary glaucoma due to infiltration of the trabecular meshwork in the angle of the eye can be present. The tumor can be envisioned clinically through a broadly enlarged understudy by cut light assessment as an arch formed collection in the area or it can have a diffuse circumferential development design known as “ring melanoma”. It can develop anteriorly into the front chamber – iridocorneal point and iris (iridociliary melanoma) or back into the choroid (ciliochoroidal melanoma).

A melanoma of choroid ordinarily presents as a sessile or curve formed collection arranged under the retina. Initial step analytic techniques can be aberrant ophthalmoscopy, ultrasound and fluorescein angiography. Surface orange color at the degree of the retinal shade epithelium can be imagined clinically, particularly in more modest back melanomas. Retinal separations can be seen auxiliary to the tumor development just as Bruch membrane rupture (cellar layer bellow the retinal shade epithelium). We can divide melanoma of chodoid into two groups the first is melanoma with pigment and the second one is melanoma withou pigment and can likewise accept a spread development design with just negligible tumor diameter under 3 mm.

Melanoma of ciliary body and melanomas of choroidea may develop cataracts, extraocular extension, secondary glaucoma. Orbital infiltration can be seen usually when the tumor has large volume, higher stage and they therefore have a worse prognosis [9].

Due to the huge range of clinical, morphologic and cytological changes and an absence of discrete stages it is hard to foresee clinical result in singular instances of uveal melanoma based on intraocular tumor size. His size and volume is perhaps the best boundary used to foresee metastatic infection.

A little tumor - melanoma - is characterized as estimating 3 mm or less in thickness and under 10 mm in breadth because of TNM plot. A tumor is delegated medium-sized in the event that it measures between 3 to 5 mm in thickness and between 10 to 15 mm in width. A huge tumor is more prominent than 5 mm in thickness and in excess of 15 mm in breadth.

Patients, who are diagnosed with a primary choroidal “intraocular” melanoma, have usually no signs or symptoms of metastatic tumor. Even with total body positron emission tomography/computed tomography (PET/CT) imaging, very few patients are found to have their melanomas spread to other parts of their body. Others may be found to have metastasis over the following years. The overall percentage of the patients diagnosed for choroidal melanoma does not develop metastatic melanoma. The size of the tumor is one of the very important factors to predict the risk for metastatic spreading. Treatments that limit tumors ability to enlarge will decrease the chance of metastasis because removing the eye tumor is the best method to prevent future spread from that tumor. It is very important for the patients to have periodic general medical examinations because the treatment itself does not affect micrometastasis that can be already present at the time the treatment occurs.

Patients who have metastatic choroidal melanoma, as mentioned above, seem to have no symptoms. For this reason, they should have periodic medical examinations, physical examinations, blood tests and radiographic imaging tests as X-ray, MRI, CT or PET/CT. Later on, patients may have symptoms like loss of their appetite, difficulty with breathing or fatigue.

The highest percentage of metastatic choroidal melanoma is likely to be found in the liver. Metastases in this area of the body can be discovered by blood tests or abdominal imaging studies even in cases when patients are asymptomatic. Besides this, other organs also can be affected, e.g. subcutaneous lymph nodes, lung, bone and brain. A needle biopsy can be used to aspirate tumor cells for cytopathologic examination, when a liver or skin metastasis is suspected.

The liver is the known site of metastasing of choroidal melanoma. Hepatic enzyme levels are tested in all patients with melanoma of uvea. The most sensitive tests of liver capacity are serum antacid phosphate levels, glutamate oxaloacetic transaminase, lactate dehydrogenase and gamma-glutamyl transpeptidase. These test results are negative at closure hour in the majority of patients with choroidal melanoma. If any of the results of these research devices is anomalous, ultrasonography and CT of the liver are displayed. Both imaging modalities have low susceptibility to metastases with a diameter of less than 10–20 mm [10–13].

2.4 Survival modeling of intraocular melanoma

Endurance displaying gives a sign of guess. Likewise, it empowers exceptional measures to be focused just as it improves the assessment of clinical methodology.

Endurance rates give a more precise system so as to depict the visualization for patients with a specific stage and type of disease. These rates are frequently founded on past results of huge quantities of individuals who had the sickness, however they cannot anticipate what will occur in a specific patient's case. In patients whose malignancy is bound to the eye, the five-year endurance rate is about 80%. This is as opposed to melanomas that have spread to inaccessible pieces of the body, where the five-year endurance rate is about 15%.

2.4.1 Prognostic factors for uveal melanoma

Pigmented choroidal lesions that are somewhat raised might be called vague sores and present a test concerning determination and the board. Given the dangers

and restrictions regarding getting histological affirmation of harm, ophthalmologists need to depend on clinical qualities recognized as prescient of development and metastasis so as to separate little melanomas from raised choroidal melanocytic tumors that are likely kindhearted. Shields et al. distinguished five components related with danger of development of little choroidal melanocytic lesions under 3 mm in diameter using examinations retrospectively of around 1300 patients [14].

These factors were:

1. posterior tumor margin touching the disc;
2. visual symptoms;
3. tumor thickness bigger than 2.0 mm;
4. subretinal fluid;
5. orange pigment.

In 4 percent of patients was observed growth of lesion with none of risk factor, in 36 percent of patients was present one risk factor, and three or more factors were present in more than 50 percent of patients.

Clinical factors associated with an increased risk of metastasis included:

1. growth documentation;
2. increased tumor diameter (bigger than/equal to 1.1 mm);
3. posterior margin touching the disc.

The small-tumor observational study conducted by the COMS Group identified similar risk factors associated with tumor growth; namely

1. apical tumor thickness was greater,
2. initial basal diameter was larger,
3. orange pigment was present,
4. there were no drusen,
5. retinal pigment epithelial change adjacent to the tumor was absent.

Prognostic factors for uveal melanoma can be subdivided into three categories: clinical, histopathological and genetical. Clinical predictive factors have been extensively described. Location of the tumor, its thickness and diameter are clinical factors predicting tumor growth. In addition, age at time of treatment, male gender and secondary glaucoma were prognostic relevant. Shields constructed a mnemonic “TFSOM” “to find small ocular melanoma” (thickness greater than 2 mm, subretinal fluid, symptoms, orange pigment and margin at the disc) to assist in identifying small choroidal melanoma at risk for growth. The most important histopathological markers predicting clinical behavior are the presence of epithelioid cells, largest tumor diameter, sclera invasion, and presence of vascular loops. Other valuable prognostic factors are the presence of mitotic figures and tumor-infiltrating

lymphocytes. The cell sort of uveal melanoma is identified with guess. Patients with tumors made out of unadulterated axle cells have a more ideal guess, and those with a part of epithelioid cells (blended or epithelioid-cell types) have a more awful visualization. Melanomas with a low mitotic movement show a superior anticipation. Tumor invasion by lymphocytes has been related with diminished endurance [15].

3. Overview of methods of treatment of uveal melanoma

These days there are a lot greater treatment choices other than enucleation, which was the main alternative for a large portion of a century ago. The more moderate treatment choices mean to save the influenced eye and hold vision. Treatment of uveal melanoma relies upon different variables including age of the patients, foundational strength of the patient, state of the contrary eye, tumor size and area.

Nevertheless, metastases cannot be prevented. Based on the theoretical models, clinically manifest metastases are likely to occur 5 or 6 years onset of the systemic dissemination. By the time we diagnosis uveal melanoma, micrometastases may have been spread as of now. Along these lines, metastatic sickness happening after therapy is not unprecedented. Roughly 50% of the patients will kick the bucket from the sickness inside 10 to 15 years of enucleation. When a metastasis is found the endurance is under 7 months. In the event that a metastasis emerges as a lone injury in the liver, expanded endurance might be acquired by nearby resection of the tumor mass.

Tumor area and size are considered to be two of the primary factors in deciding on the treatment of ocular melanoma. There is no reason to save the eye if a small melanoma in a necessary place completely destroyed vision. It is important to remember this - patients who have undergone enucleation and individuals who have undergone radiation treatment respond appropriately when they receive information about the nature of their patients after treatment. The most important for them was tumor endurance.

Treatment using radiation is a typical therapy for intraocular melanoma that utilizes high energy radiation to kill tumor cells. Radiation treatment can regularly safeguard some vision, albeit once in a while this is lost at any rate since radiation harms different pieces of the eye. The structure of the eye is saved and this is mainly the advantage of this sort of treatment.

Radiation treatment can be divided into two categories. External radiation treatment that utilizes a machine outside the body to send radiation toward the tumor, and the second type is inside radiation treatment that utilizes a radioactive substance fixed in needles, seeds, wires, or catheters that are set legitimately into or close to the tumor. The manner in which the radiation treatment is given relies upon the sort and phase of the tumor being dealt with. In ophthalmooncology field we utilize both photon pillar light and furthermore proton beam irradiation.

The metastatic free survival rate, the local control and the late toxicity were studied in patients that underwent fractionated Stereotactic Radiation Therapy (fSRT) for uveal melanoma. These patients had a median follow-up 32 months and were given five fractions of 10 Gy. The results showed that fSRT is an effective treatment for uveal melanoma with a good local control. There were performed 15 enucleations after irradiation mainly because of neurovascular glaucoma [16].

Plaque therapy is the most often utilized framework for delivering radiation. The other methods are Gamma Knife or methods that include proton beam. Radiation plaque treatment which offers great tumor control, can frequently safeguard helpful vision, and has a fundamental visualization that is practically identical to that of

enucleation. Enucleation remains the standard strategy for the board of the biggest melanomas of the choroid and ciliary body. The Collaborative Ocular Melanoma Study (COMS) is randomized clinical trial assessing essential enucleation versus beam radiation done externally followed by enucleation in the management of patients with choroidal melanomas. The study demonstrated that the two options to be used in same medium sized tumors. COMS studied also treatment of large tumors and found out that combined external radiotherapy followed by enucleation shown that there is no limit in orbital recurrence of the tumor mass [10–13].

3.1 One day session stereotactic radiosurgery for uveal melanoma: our experience

Stereotactic radiosurgery (SRS) is technically challenging therapeutic irradiating method. SRS complements or supplies (replaces) classic surgical intervention. The purpose of using SRS is single, because high therapeutic irradiation dosage is to involve only an exact specified tumor structure, while the other organs and structures are contemporary protected. We use special hardware equipment of workstation and software. Professional experiences of specialists of various fields (neurosurgeon trained in stereotactic radiosurgery, radiation oncologist, ophthalmologist, radiologist, clinical physicist and registered nurse trained for radiosurgery) are needed.

The surgery is determined by patient preparation before surgery intervention. This consists of processing of health of the patient and whole patients imaging documentation. It is important to analyze the patient's illnesses and the patient's indication by the Indicating Commission (BTB). The Commission consists of the members as a neurosurgeon trained in radiosurgery, radiation oncologists, ophthalmologists, radiologists and clinical physicists. Just after the see the records and imaging of the patients they decides whether to do SRS or not. The Progress Committee selects, on the basis of a recommendation on the suitability of ophthalmic oncological surgery, which evaluates the suitability of conventional surgery, stereotactic radiosurgery, fractional stereotactic radiosurgery, intensity modulated radiotherapy (IMRT) or three-dimensional conformal radiotherapy (3 D-CRT).

Indicated patients for stereotactic radiosurgical intervention are concerned for inpatient care Ophthalmology Department of Faculty of Medicine, Comenius University in Bratislava. The whole hospitalization lasts most often three days. The patient admission includes interview with the patient with detailed information about the course of operation, performance benefits as well as acquaintance with potential acute and late postoperative complications (adverse effects), after the informed consent is signed by the patient.

Patient's affirmation in hospital bed department (clinical care) is carried two days before the surgery. Clinical examination will be done in detail. The documentation patient brought is studied, in case there are some missing examinations they are done and completed by the time of the surgery and a preoperative pharmacotherapy treatment in hospital bed department is placed on. One day before the stereotactic radiosurgery (SRS) patient has to use premedication. Within the preoperative premedication the patient is using the antiedema therapy, which intensity depends on the size, location of the lesion and the presence of edema. The presented therapy continues at the day of surgery and also the following day.

The patient's record must incorporate the age at treatment, volume and size of tumor, the most extreme stature of the tumor estimated by A, B scan ultrasound. The presence and the degree of secondary retinal detachment, and note if there is an extrascleral expansion must be recorded in patients file. Tumor volume, in every

patient straightforwardly after computer CT and MRI assessment is determined as the progression of SRS strategy and is included to the scheme of stereotactic planning.

Mechanical fixation to the stereotactic (Leibinger) frame is done before stereotactic irradiation immobilization of the affected eye. Stiches are put under 4 direct extraocular muscles through conjunctiva and through the upper and lower lid. The stereotactic frame is fixed to the head and the stiches are attached to the stereotactic frame on the side of affected eye. The patient undergoes a CT examination with the eye tied to the patient's frame. After fixation and administration of the drug contrast agent, the examination is performed on one-millimeter scans. After completing the CT examination, the patient is transferred to an MRI examination. The patient undergoes an MRI examination with the eye still fixed on a stereotactic frame. After placement in the MRI, a contrast agent is administered. MRI and CT imaging records are sent to a computer console in the computer room.

At that point after the CT and MRI examinations patient is transported to the resting room of Department of radiotherapy of St. Elizabeth Oncological Institute and is waiting for exposure in the linear accelerator.

Clinical physicist processes imaging records for the purpose of fusion and subsequent planning of stereotactic radiosurgery irradiation. By the fusion of images obtained from the CT and MRI it is obtained an accurate image and the structure-relationship of operated patient. CT examination does not always perfect morphology image of targeting and risk structures, but it is an accurate and does not distort the displaying structures. MRI can distort displaying targeted and risk structures, particularly in the area of bone structures arises the distortion. Neural structures are showed in three dimensions, which allows a reconstruction and good distinctiveness of targeted and risk neural structures. Planning system communicates only with the CT imaging, in which information is transmitted from other investigating modalities. Clinical physicist makes by the fusion the correction of the treating volume of a focus and risk structures from the MRI records to CT imaging.

After imaging the target and risk structures, the neurosurgeon draws the target volumes and risk structures in sections of one millimeter in a CT record and consults them with an ophthalmologist and radiologist. The planning of stereotactic treatment after the fusion of CT and MR is optimized according to the critical structures, which are the lens, the optic nerve on both sides, and chiasma is also marked as the critical structure.

The best plan is after applied for therapy at linear accelerator. Calculation of tumor volume depends on the ROI (region of interest) of the tumor and 3D reconstruction is done. The planned therapeutic dose is 35.0 Gy by 99% of DVH (dose volume histogram). Model LINAC C 600 C/D Varian with 6 MeV X is utilized.

3.1.1 Stereotactic planning

The stereotactic treatment arranging after combination of CT and MRI pictures is streamlined by the basic structures - focal point, optic nerve, and furthermore focal point and optic nerve at the contralateral side, chiasm.

The planned therapeutic dose in SRS is 35.0 Gy, TDmin. The dose varies from 35.0 to 38.0 Gy, TDmax 37.0–50.0 Gy to the margin of the lesion. We use PTV (treatment volume planning) at least 95% isodose planning. Doses for critical structures such as the optic nerve and optic disc are less than 8.0 Gy and 10.0 Gy for the anterior segment of the eye (**Figures 1 and 2**).

The clinical physicist embeds the plan into the verification system after printing the radiation parameters and documentation. At the same day after the planning is finished the patient undergoes irradiation at linear accelerator in the afternoon.

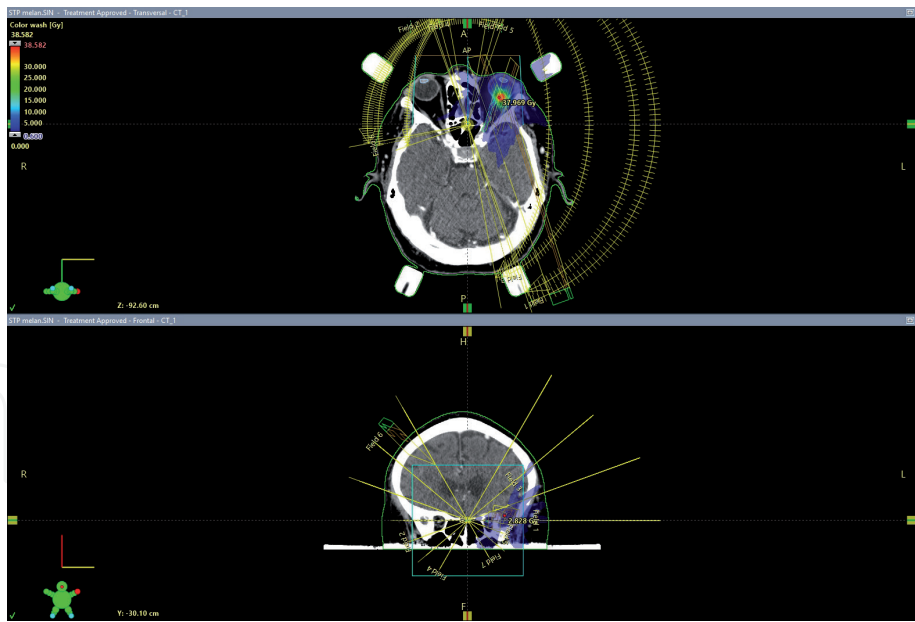


Figure 1.
Stereotactic planning scheme for patient with uveal melanoma on linear accelerator (TD – 35.0 Gy) – Part a.
origin: Dept. of stereotactic radiosurgery, Bratislava.

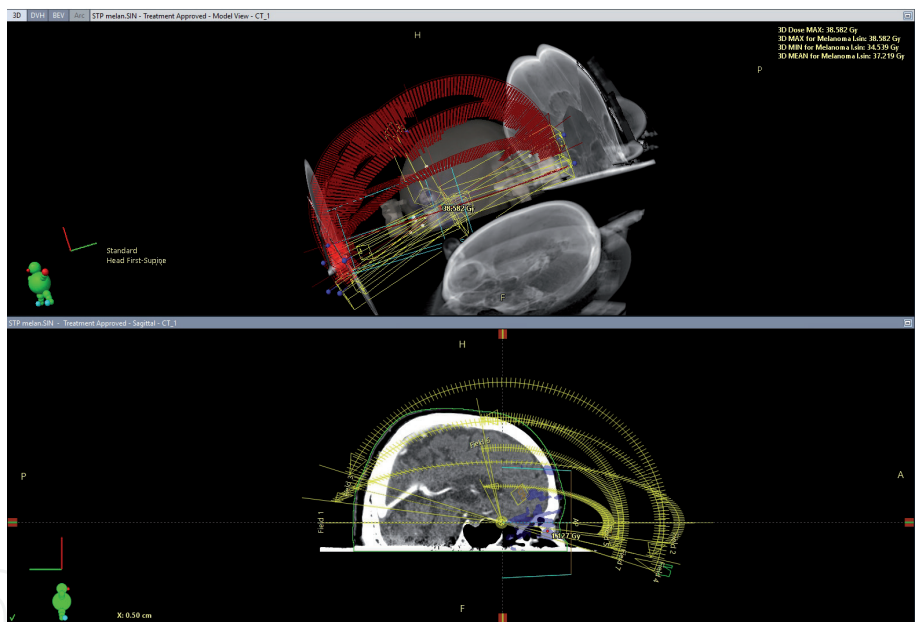


Figure 2.
Stereotactic planning scheme for patient with uveal melanoma on linear accelerator (TD – 35.0 Gy) – Part B.
origin: Dept. of stereotactic radiosurgery, Bratislava.

Mechanical fixation to the stereotactic frame ensures that the head while the examination and treatment is in the same, right position. Along with the merger of images from CT and MRI is guaranteed the accuracy of the method in the order of tenths of a millimeter.

When the exposure is completed the patient is unfixed from the operating table and moved into the operating room. According to volume and collimators the whole procedure lasts from 15 to 50 minutes.

In the case of application of stereotactic radiosurgery using micro-multileaf collimator makes clinical physicist verification plan using the verification phantom. He inserts the irradiation plan of patient into verification system of linear accelerator and verifies the accuracy of irradiation plan applications into verification phantom by irradiation of verification phantom by the dosimetric system.

3.1.2 Stereotactic radiosurgery for uveal melanoma: Our results

Treatment of uveal melanoma in Slovakia is performed on direct quickening agent LINAC. One-fraction LINAC radiotherapy/radiosurgery is an unusual approach to treatment of choroidal melanoma. Hypofractionation with a broad shoulder in linear-quadratic model for radioresistant tumors like choroidal melanoma is still in discussion.

We evaluated in our study local failure which leads into enucleation as an end point in patients treated by SRS with long-term follow-up having accrued at the time of analysis. We evaluate in our study the treatment of posterior uveal melanoma by one-day session of LINAC stereotactic radiosurgery.

The first goal of our study was to evaluate treatment BCVA decline in patients who has posterior uveal melanoma treated with SRS in 6 months interval 24 months after SRS.

The second goal was to find out whether the group of patients with better initial visual acuity on the beginning of treatment would have also a better chance to preserve vision. The observed after-treatment decline in BCVA was 24 months interval after the treatment.

The third goal was observation of the tumor regression by the maximum elevation measurement using B-scan ultrasound in the group of patients with single irradiation (SRS) in interval 1 and 2 years after the treatment.

For patients treated by SRS in the period 2001–2008 was a retrospective analysis was undertaken. At the Department of Ophthalmology, Comenius University in Bratislava we reviewed 84 patients records with choroidal melanoma or with ciliary body melanoma treated in this period. 44 patients underwent primary enucleation (52.4%) out of 84 patients and 40 patients underwent SRS as an initial treatment (47.6%). The diagnosis was established on the basis of ophthalmological examination, ultrasound, CT or MRI examination. Excluded from analyzed cohort were metastatic intraocular tumors, juxtapapillary localized tumors and melanocytomas.

Each patient record must have details such as the age at treatment, tumor size, tumor volume, the maximum height of the tumor by A, B scan ultrasound, the presence and the extent of secondary retinal detachment, and if there are signs of extrascleral spread.

The tumors were divided into 3 groups as follows: small up to 4 or 5 mm of maximal elevation, middle 4–8 mm, and large over 8 mm.

In the group of one stereotactic irradiation, an increase in the tumor was observed in a 6-month interval by ultrasound with a B-scan ophthalmologist. We compared tumor regression by measuring maximal elevation using B-scan ultrasound in a group of 25 patients with single irradiation (SRS) at 12 and 24 months post-treatment.

3.1.3 Enucleation versus stereotactic radiosurgery: Our results

We analyzed the treatment outcome and possible survival difference between radical surgical treatment (primary enucleation) and stereotactic radiosurgery (SRS) at the Department of Ophthalmology, Comenius University in Bratislava, in patients with posterior uveal melanoma.

Patients treated for uveal melanoma in posterior during the period 2001–2008 are analyzed in the study. The goal of the study was to compare the relapse-free survival in the cohort of patients initially treated by SRS or they primary underwent enucleation. Together we included 84 patients. Treatment was determined on a case-by-case basis.

We analyzed each patient's record with ciliary body or choroidal melanoma treated by enucleation. We divided them into two groups: first group had 44 patients (52%) using surgical treatment and the second group had 40 patients (48%) using SRS treatment. The therapeutic attitude was set up based on ophthalmoscopy, ultrasound (A, B mode), other ophthalmological findings, visual acuity, and general status of each patient and MRI examination. Volume of the tumor was determined by using the formula:

$$\text{Tumor volume} = \frac{\pi}{6} * \text{length} * \text{width} * \text{height} \quad (1)$$

$$Td = \frac{0,30103 * \text{number of months}}{\log_{10}(\text{final volume}) - \log_{10}(\text{starting volume})} \quad (2)$$

The disease-free interval was defined as the period from treatment (either enucleation or SRS) until the development of metastasis, or the death of the patient. The patients after enucleation were examined by ophthalmologist every six months, with a monthly interval in the first six months, dependent on problems with using individual prosthesis. The patients after stereotactic radiosurgery were examined by an ophthalmologist every three months: visual acuity, biomicroscopy (slit lamp), intraocular pressure, ultrasound in A and B mode, fundus photography and since the year 2007 also OCT (optical coherence tomography) was routinely done. Post radiation complications and tumor dimension and extent of secondary retinal detachment were observed. The patients were observed in the period from 2001 (01/01) to 2008 (31/12) and the data were analyzed.

The disease-free interval was defined as the time from treatment until the development of metastases. Patients were seen in three months interval in the first year after the SRS, later in six months interval following SRS. Patients in both groups were regularly in six months interval recommended to their oncologist to a liver ultrasound, abdominal ultrasound, liver function test, brain CT, chest X-ray to confirm or exclude the presence of metastases. In individual cases they were recommended to brain CT or PET/CT.

In the period 2001–2008 a total number of 84 patients with intermediate or large uveal melanoma were treated with either radical surgical removal of the whole eyeball (enucleation), or SRS. In a group of 40 patients who underwent SRS there were 22 male and 18 female - the total median age was 55 years; the median age of female was 54 years and 58 years of male. In a group of 44 patients with enucleated eyes the median age was 68.5 year. In the group there were 21 males (median age 64), and 23 females (median age 73). The median tumor volume in group of stereotactic patients was 0,65 cm³ (0,4 - 0,8), in group of enucleated patients 1,1 cm³ (0,8 - 1,25).

Five patients treated in the first step with SRS required subsequent enucleation due to the complications - secondary neovascular glaucoma. Three patients of this subgroup underwent pars plana vitrectomy with endoresection of the tumors plus silicon oil, but the enucleation was necessary due to the complication - relapse of the tumor.

Histopathologically in the group of enucleated eyes after SRS due to complications in four patients with malignant melanoma of the mixed cell type, in two cases an epithelioid type, and in one case a spindle-cell type A was confirmed.

In the group of primary enucleated eyes, there were four findings of an epithelioid-cell type, one case of a nodular type, as well as 10 cases of both, a mixed-cell type and 29 cases of a spindle-cell type (A or B) melanoma.

The age and tumor volume are important explanatory variables (termed covariates) that are assumed to be associated with survival and need to be incorporated in the model. Results on logistic regression confirmed significance of the model with the predictors age and tumor volume ($P = 0.01$). The tumor volume was a significant unique predictor ($P = 0.035$); age with its borderline probability value of 0.1 could be assumed as possibly associated with the outcome. The estimator of survival rates adjusted for these predictors was constructed based on Cox's regression model which examines the relationship between survival and both predictors.

3.1.4 Complications after stereotactic radiosurgery: Our results

The fundamental objective of radioactive therapy is to control malignancy while maintaining useful vision. Present techniques result in a high incidence of tumor control for intermediate and small lesions (< 8 mm in height). Tumor control for enormous sores is not ideal, also, here is a higher frequency of late complexities bringing about hindered vision in huge sores. All things considered, radiation portion decrease to the uninvolved piece of the eye will lessen the rate of late difficulties while keeping up a high occurrence of tumor control for more modest tumors.

Utilizing of 3-D radiation dosimetry is accepted that will have significant advantage as far as therapy enhancement and lower frequency of late inconveniences. Such a 3-D framework grants exact pre-treatment arranging and adjustments of the arrangement at short notification, for example, on account of new intraoperative discoveries. There is overpowering proof that threatening melanoma of the uveal plot can be dealt with securely with radioactive plaques with long haul endurance rates equivalent to those of enucleation. We think, that the vessels around the optic plate are harmed by full portion light, prompting retinal ischemia, and this courtesies the presence of neovascular glaucoma. Safeguarding of the eye work is normal in most of radioactive-plaque treatment treated patients. Utilization of low energy isotopes, collimation of individual seeds, and routine utilization of 3-D imaging and 3-D dosimetry should assist with promoting improve episcleral plaque treatment. In writing the rate of post-radiotherapy enucleation from all causes is about 20%. The diminishing of the occurrence of intricacies as waterfall, radiation papillitis, radiation maculopathy, optional glaucoma is because of extremely exacting signs of back uveal melanoma. Today, no randomized planned investigation of the impact of the elective moderate medicines for choroidal melanoma on visual result have been performed.

In our group of patients after Ru106/Rh106 plaque treatment the accompanying late intricacies prompted crumbling of visual keenness and were seen at the last subsequent assessment:

- macular pulverization due to scarring around the tumor, optic nerve decay,
- macular degeneration, retinopathy, fractional focal point haziness, complete waterfall, glassy discharge, optional glaucoma, apoplexy of the focal retinal vein.

The patient will develop radiation cataract if more than 30% of the periphery of the lens is irradiated. If the diameter of the tumor is large, invasion of the iris may occur, or if the anterior margin of the tumor is well in front of the equator, the lens may be more sensitive to irradiation. Post-radiation cataracts can occur even if less than 30% of its periphery is irradiated.

Our clinical experience shows that auxiliary enucleation after stereotactic radiosurgery because of light neuropathy and optional glaucoma was essential just in 11.5% in 3 to 5 years stretch after illumination.

3.1.5 Follow-up

The patient after SRS is controlled regularly ambulatory, the clinical and MRI examinations are carried out, which are made ambulatory, initially and MRI is controlled after 3 months after SRS, first year, next two years in half yearly intervals, then 1 time a year in a following 5 years. Patient is monitored by an ophthalmologist in 2 weeks, later 6 weeks and 3 months interval - visual acuity, intraocular pressure, slit lamp examination, fundus photo, ultrasound – B-scan, OCT, perimetry. In 3-months' interval patient is send to MRI control [2, 17, 18].

4. Discussion

Fifty years back, enucleation was the main acknowledged choice of treatment for melanoma, perception until recorded development was supported for little tumors that could not be unquestionably analyzed as melanomas on beginning introduction. These days with the openness and showed sufficiency of eyeball-sparing medicines, a conflict can be made for before treatment of these vague lesions. Data from the COMS primers reveals that melanoma-related mortality varies with tumor size at period of treatment. For medium estimated tumors (portrayed as tumors 2.5 to 10 mm in apical height and up to 16 mm in greatest basal width), melanoma-express mortality was 10% at five years, and 18% at 10 years. For huge tumors (those astounding the size models for medium tumors in either apical height or greatest basal expansiveness; or peripapillary tumors with an apical height more conspicuous than 8 mm), the rates extended to generally 27% at five years and 40% at 10 years. Also, as referenced above, archived development before treatment has been demonstrated to be a danger factor for metastasis. In any case, development might be a marker for more forceful tumors, and it has not been demonstrated that treating these tumors prior diminishes mortality [7].

Our present strategies for radiotherapy consider powerful nearby tumor control with eyeball preservation, yet visual morbidity is still high. In this manner, it is important to gauge the mortality hazard caused via cautious perception before treatment of uncertain sores against the outcomes of visual misfortune actuated by treatment.

In a small COMS tumor observation study, there were six melanoma-related transitions from a cohort of 67 tumor patients treated after baseline perception. Only two of these transitions occurred within five years of enrollment, resulting in an inaccurate five-year death rate with an explicit melanoma of 3% [11].

One-portion LINAC radiotherapy/radiosurgery is an abnormal way to deal with treatment of choroidal melanoma. Hypofractionation with a wide shoulder in straight quadratic model is still in conversation for radioresistant tumors like choroidal melanoma. In this examination we assessed nearby disappointment prompting enucleation as an end point in patients treated by SRS with long haul development having accumulated at the hour of investigation [19].

Picture combination of a differentiation improved attractive reverberation imaging (MRI) and figured tomography (CT) is utilized for treatment arranging co-ordinates. A few creators incline toward light before enucleation for huge uveal melanoma. This treatment is utilized in a method of SRS with a solitary division managed with a valuable spatial exactness utilizing a collimating framework.

Because of our outcomes the saw after-treatment decrease in BCVA was not emphatically connected with higher pervasiveness of better BCVA before SRS, however the anatomical outcome after the treatment was at any rate anatomically saved eyeball [17].

Empowering our outcomes legitimize further examinations to assess one day meeting method and its viability as an option in contrast to other light helpful methodologies. On the off chance that we utilized single SRS treatment just, in patients with tumor volume over 0.6 cm^3 the danger of relapse was high, over half and extra treatment was essential. As per our experience the portion of 35.0 Gy is not adequate light and may cause backslide just in patients with high volume tumors, over 0.6 cm^3 . By breaking down individual patient's consequences of this examination, we presume that this treatment is adequate for little and middle of the road tumors with the rise not more than 6 mm, resp. volume up to 0.4 cm^3 as per individual stereotactic arranging plan of every patient as a solitary treatment system. Auxiliary enucleation after stereotactic radiosurgery due to mild neuropathy and secondary glaucoma was vital in only 11.5% at 3 to 5 years after illumination. In our examination, proximal tumor control was effective in 95% of patients at 3 years after stereotactic radiosurgery and in 85% of patients at 5 years after stereotactic radiosurgery [20].

As indicated by our outcomes one-day session SRS with 35.0 Gy is adequate to treat little and center stage melanoma. No endurance distinction inferable from stereotactic light or consolidated and surgical attitude - enucleation of uveal melanoma has been exhibited in the review concentrate in Slovak Republic. Enucleation after SRS in 7 patients was in stretch 6 months to two years after SRS. A little distinction is conceivable, yet a clinically significant contrast in death rates, regardless of whether from all causes or from metastatic melanoma, is improbable.

A high degree of local control can be achieved with a five-year control rate exceeding 95% in patients treated with charged particles. Radiotherapy with a 62 MeV proton rod with a cyclotron achieves a high rate of close tumor control and visual protection, with the visual outcome depending on the size and area of the tumor.

Huge, imminent, randomized preliminaries were intended to look at mortality figures for medium-sized melanomas treated by brachytherapy or enucleation. The outcomes could not show the distinction in death rates between the two treatment bunches following a limit of 12 years of development.

In the most recent years, the administration of patients with uveal melanoma has changed toward eyeball saving strategies. Options other than extreme enucleation range from perception to perception to transpupillary thermotherapy, block-extraction, endoresection with standards plana vitrectomy, brachytherapy utilizing an assortment of radioisotopes, outside bar radiotherapy, charged particles and stereotactic radiosurgery or strategies can be approached. SRS has recently been proposed as an optional treatment for posterior uveal melanoma. Treatment for each patient should be selected according to the patient's general condition, stage and nature of the tumor. COMS is planned to provide remote information on regular history as well as a useful speech.

Single-division stereotactic radiosurgery is normally finished with a Gamma Knife just as more as of late with a CyberKnife. The remedial single portion has been diminished to as low as 35.0 Gy in the course of recent years without decrease in tumor control. Dosages of 40.0 Gy conveyed at the half isodose bring about great nearby tumor control and satisfactory harmfulness. Since radiobiological contemplates show a potential favorable position of hypo fractionated treatment over a solitary huge portion to clean uveal melanoma cell lines, fractionated stereotactic radiotherapy (SRT) has increased extra interest. Other than expanded tumor control, poisonousness ought to hypothetically be diminished by fractionation.

Direct quickening agents (LINAC) have the upside of an attainable fractionation. Most LINAC contemplates utilize a hypo fractionated plan of 4–5 portions and complete dosages somewhere in the range of 50.0 and 70.0 Gy. The viability of SRT for uveal melanoma has been demonstrated in various investigations with neighborhood tumor control rates announced over 90%, 5 and 10 years after treatment. Radiogenic results after SRT are accounted for also to different types of radiotherapy, with waterfall advancement, radiation retinopathy, opticopathy and neovascular glaucoma being liable for most of optional vision misfortunes and auxiliary enucleations. Generally speaking, stereotactic photon beam radiotherapies (SRS and SRT) are viewed as compelling treatment modalities for uveal melanoma, with promising late tumor control and poisonousness rates. SRS is a generally new strategy, so there is a requirement for multi-focus preliminary to contrast the results following stereotactic radiosurgery and different techniques. Nonetheless, as of recently, no investigation has been acted in this point. Studies contrasting endurance rates following enucleation versus more current treatment modalities, including SRS, recommended comparative rates for tantamount sores and in light of the fact that revealed nearby tumor control rate following SRS seem similar, we offer SRS to patients who might somehow or another require enucleation [1].

Stereotactic photon treatment of uveal melanoma, in light of CT and MRI pictures, is a protected and exact treatment choice. Neighborhood control was discovered to be superb. Due to choice models, the quantity of patients in the investigation with decreased visual sharpness will likely expansion later on.

Neighborhood power over 95% shows up in certain investigations: in the investigation of Dieckmann nearby control is 98% after a middle perception time 33 months follow up. The perception time is still too short to even consider allowing complete ends, yet their outcomes are tantamount with the 82–98% nearby control rate detailed by different gatherings after a middle perception season of as long as 15 years [21].

Visual misfortune after proton pillar light was depicted in 33–47% following 1 and 2 years, individually, for tumors situated close to the optic plate and fovea.

Different creators announced in a review study that light of 30.0 Gy of in excess of 2 mm of the optic nerve head started an optic neuropathy.

In the investigation of Dieckmann because of troublesome tumor size and area in the region of basic structures, for example optic nerve and macula, visual decrease was seen in a high number of the patients. After a perception season of beyond what a half year visual sharpness can be assessed in 79 patients. In the gathering of 77 patients 85.5% gave visual sharpness of 0.1 or better before radiotherapy. LINAC based stereotactic light for melanoma of uvea is plausible and all around endured. Can be offered to patients with medium measured and horribly found melanoma of uvea who are looking for an eye-protecting therapy [22].

To accomplish great visual keenness result it is significant right limitation of the tumor. Brachytherapy Ru106 of back choroidal melanoma accomplishes great preservation of vision if the tumor does not stretch out near the optic nerve or fovea. Realize that the intensity of a test to look at endurance in at least two gatherings is connected not to the all out example size but rather to the quantity of functions of interest, (for example, passing for this situation). At the end of the day, the endurance tests perform better when the editing is not excessively substantial, and, specifically, when the example of controlling is comparable over the various gatherings. High number of right-blue-penciled information (from those patients who actually were alive toward the finish of perception, or exited the investigation for different reasons other than death before its end) could influence the unwavering quality of the outcomes. Subsequently, the substantial controlling may confuse the assessment of the endurance model, since it diminishes the comparable number of

subjects uncovered (in danger) at later occasions, decreasing the successful example sizes. Also, little example sizes may additionally expand the impact of the presumption infringement. It is not sensible, notwithstanding, to drop the chose informative variable(s) from the model, since there are “genuine world” reasons why these specific factors ought to stay in the last model [23].

To this date, no preliminary examination of the dosimetry, safety and viability of SRS or evaluation of gamma knife radiosurgery results for melanoma has been performed. So far information from several reported cases recommends that SRS can have comparable close tumor control rates, metastases, death rates and involvement rates brachytherapy. Late examinations recommend that gamma knife radiosurgery and SRS may be an appropriate choice for the treatment of uveal melanoma in those patients in whom ulcers are not suitable for conventional brachytherapy. The findings in the setting recommend a part of SRS in the treatment of selected cases of uveal melanoma [24].

Entanglements after specific techniques can prompt auxiliary neovascular glaucoma and may result to the enucleation, that is the reason the eye maintenance is one of the fundamental objectives of the moderate treatment. A multivariate information investigation by utilizing the directed learning methods, specifically the calculation known as Regularized Least Squares (RLS) was utilized in investigation of Mosci. Their examination was the biggest one in Italy and they exhibited the brilliant neighborhood tumor control, endurance and eye consistency standard after the proton shaft light treatment. As their results suggest, further improvements in treatment delivery may be important in determining visual outcomes and complexities after proton shaft therapy in visual melanoma dosing and delivery [25].

The basic problems of radiotherapy in one meeting are the effects of propagation and hypofractionation of the part. The size and area of the tumor, for example closer than 2 mm from the optical plate, are the main components for determining the clinical evaluation of the visual acuity result.

Distinguishing proof of danger variables may lessen the paces of repeat and lead to less inconveniences, safeguarding of the eye, improved visual capacity and, conceivably, better endurance result. Repeat of optic neuropathy after stereotactic radiosurgery is an issue by intraocular tumors as well as for example by perichiasmal tumors stereotactic illumination. Albeit uncommon, optic neuropathy may follow radiosurgery to injuries close to the visual pathways. Cautious portion arranging guided by MRI with limitation of the maximal portion to the visual pathways to under 8.0 Gy will probably diminish the frequency of this entanglement.

Similar issues with visual sharpness misfortune as in stereotactic radiosurgery are found in patients after other radiotherapy methods, for example brachytherapy. In the sequential arrangement of patients after Ru106 brachytherapy, patients held some helpful vision in the principal postoperative years and a couple even improved visual sharpness, notwithstanding, the drawn out visual result is poor with a proceeding with visual keenness misfortune over the long run. Countless patients became visually impaired or lost perusing capacity following 5 years, either due to radiation confusions or auxiliary enucleation.

Stereotactic radiosurgery and fractionated stereotactic radiotherapy have developed as promising, non-intrusive medicines for uveal melanoma [26]. Albeit, verifiably, melanoma has been viewed as a moderately radioresistant tumor, fresher information have tested this perspective, and radiation treatment is currently viewed as a helpful segment of the restorative armamentarium for harmful melanoma. As indicated by our outcomes a solitary one-day meetings SRS with 35.0 Gy is adequate to treat little and center stage melanoma. No endurance distinction inferable from stereotactic light or joined and careful mentality - enucleation of uveal melanoma has been exhibited in the review concentrate in Slovakia.

In our examination bunches researched, endurance investigation changed for indicators demonstrated that the gathering of patients after stereotactic radiosurgery had similar result as the gathering of patients treated with extremist medical procedure. In light of our examination, we expect that the endurance guess is basically dictated by the personality of the tumor in relationship to the status of the patient. Clinically, the main factors that influence the metastatic cycle are the limitation and size (volume) of the sore.

There has been played out no multicenter preliminary to survey dosimetry, wellbeing and adequacy of SRS, or to assess results of gamma knife radiosurgery for melanoma yet, yet information from a few announced case arrangement recommend that SRS could have comparative nearby tumor control rate, metastasis rate, death rate and intricacies rate when contrasted with brachytherapy. Late investigations have proposed that gamma knife radiosurgery and SRS might be a fitting option for treating uveal melanoma in those patients, in whom sores are ineligible for customary brachytherapy. The discoveries in the arrangement propose a part of SRS in the treatment of chose instances of uveal melanoma. Treatment by either essential enucleation or SRS as per our outcomes does not seem to impact the improvement of metastases in patients with uveal melanoma; the endurance anticipation is basically controlled by the stage and character of the tumor.

No endurance contrast inferable from stereotactic light or extremist careful disposition - enucleation of uveal melanoma has been shown in this review study. A little contrast is conceivable, yet a clinically significant distinction in death rates, regardless of whether from all causes or from metastatic melanoma, is far-fetched. SRS is a non-intrusive option in contrast to enucleation in the treatment of uveal melanoma with a high tumor control. There is a requirement for multi-focus preliminaries to think about the results following stereotactic radiosurgery in treatment of uveal melanoma.

5. Conclusion

The single light of the tumor itself is another methodology – it has been appeared to accomplish ultrasonic tumor relapse along these lines to brachytherapy. SRS of extracerebral sores like uveal melanoma has been developed over the most recent twenty years and is an elective treatment for center and enormous back choroidal melanoma. With plaque radiotherapy, eye rescue is accomplished, and especially for cases in which the tumor is found away from the optic circle or macula, helpful vision can be held after treatment.

As indicated by the creators experience dependent on consequences of their exploration aftereffects of the adequacy of LINAC-based stereotactic radiosurgery treatment in addition to joined strategies in patients with back uveal melanoma in stage T2/T3, the stereotactic radiosurgery is a successful strategy to treat middle of the road phase of uveal melanoma. At last, one-venture LINAC-based SRS with a solitary portion 35.0 Gy can treat patients with center back uveal melanoma and save the eyeball or be the initial step of consolidated strategies: illumination before endoresection or cyclectomy.

Conflict of interest

None of the authors has conflict of interest with this submission.

Printed form supported by KEGA 023 STU-4/2020, VEGA 1/0395/21, APVV - 17 – 0369.

IntechOpen

IntechOpen

Author details

Kristina Horkovicova and Alena Furdova*
Department of Ophthalmology, Faculty of Medicine, Comenius University,
Bratislava, Slovakia

*Address all correspondence to: alikafurdova@gmail.com; furdova1@uniba.sk

IntechOpen

© 2021 The Author(s). Licensee IntechOpen. This chapter is distributed under the terms of the Creative Commons Attribution License (<http://creativecommons.org/licenses/by/3.0>), which permits unrestricted use, distribution, and reproduction in any medium, provided the original work is properly cited. 

References

- [1] Furdova A, Sramka M. Uveal Malignant Melanoma and Stereotactic Radiosurgery: Intraocular Uveal Melanoma and One-Day Session Stereotactic Radiosurgery at Linear Accelerator. Saarbrücken: LAP LAMBERT Academic Publishing; 2014 188 p
- [2] Furdova A, Strmen P, Waczulikova I, Chorvath M, Sramka M, Slezak P. One-day session LINAC-based stereotactic radiosurgery of posterior uveal melanoma. *European Journal of Ophthalmology*. 2012;22(2):226-235
- [3] Furdová A, Oláh Z. Histologically verified intraocular tumors in the Slovak Republic 1984-1989. *Ceská a Slovenská Oftalmologie*. 1995 Oct;51(5):284-288
- [4] Shields JA, Tumors SCL. An Atlas and Textbook. Philadelphia, Pa: Lippincott Williams & Wilkins; 2008. p. 598
- [5] Damato B. Ocular treatment of choroidal melanoma in relation to the prevention of metastatic death - a personal view. *Progress in Retinal and Eye Research*. 2018 Sep;66:187-199
- [6] Damato B. Recent developments in ocular oncology. In: Grzybowski A, editor. *Current Concepts in Ophthalmology*. Springer International Publishing; 2020. pp. 275-293
- [7] Damato BE, Singh AD, editors. *Clinical Ophthalmic Oncology: Uveal Tumors* [Internet]. 3rd ed. Springer International Publishing; 2019 [cited 2020 Mar 19]. Available from: <https://www.springer.com/gp/book/9783030178789>
- [8] Shields CL, Mashayekhi A, Shields JA. By sleight of hand, prognosis determined-even for small choroidal melanoma. *JAMA Ophthalmol*. 2018 May 1;136(5):488-489
- [9] Laver NV, McLaughlin ME, Duker JS. Ocular melanoma. *Archives of Pathology & Laboratory Medicine*. 2010 Dec;134(12):1778-1784
- [10] Collaborative Ocular Melanoma Study Group. The COMS randomized trial of iodine 125 brachytherapy for choroidal melanoma: V. Twelve-year mortality rates and prognostic factors: COMS report No. 28. *Arch Ophthalmol Chic Ill 1960*. 2006 Dec;124(12):1684-93.
- [11] Collaborative Ocular Melanoma Study Group. Assessment of metastatic disease status at death in 435 patients with large choroidal melanoma in the Collaborative Ocular Melanoma Study (COMS): COMS report no. 15. *Arch Ophthalmol Chic Ill 1960*. 2001 May;119(5):670-6.
- [12] Diener-West M, Reynolds SM, Agugliaro DJ, Caldwell R, Cumming K, Earle JD, et al. Development of metastatic disease after enrollment in the COMS trials for treatment of choroidal melanoma: Collaborative Ocular Melanoma Study Group Report No. 26. *Arch Ophthalmol Chic Ill 1960*. 2005 Dec;123(12):1639-43.
- [13] Honavar SG. Is collaborative ocular melanoma study (COMS) still relevant? *Indian Journal of Ophthalmology*. 2018;66(10):1385-1387
- [14] Shields CL, Naseripour M, Cater J, Shields JA, Demirci H, Youseff A, et al. Plaque radiotherapy for large posterior uveal melanomas (> or =8-mm thick) in 354 consecutive patients. *Ophthalmology*. 2002 Oct;109(10):1838-1849
- [15] Shields CL, Cater J, Shields JA, Singh AD, Santos MC, Carvalho C. combination of clinical factors predictive of growth of small choroidal

melanocytic tumors. *Arch Ophthalmol* 1960. Mar. 2000;**118**(3):360-364

[16] Muller K, Naus N, Nowak PJCM, Schmitz PIM, de Pan C, van Santen CA, et al. Fractionated stereotactic radiotherapy for uveal melanoma, late clinical results. *Radiother Oncol J Eur Soc Ther Radiol Oncol*. 2012 Feb;**102**(2):219-224

[17] Furdova A, Sramka M, Chorvath M, Kralik G, Furda R, Gregus M. Clinical experience of stereotactic radiosurgery at a linear accelerator for intraocular melanoma. *Melanoma Research*. 2017 Oct;**27**(5):463-468

[18] Furdova A, Sramka M, Chorvath M, Kralik G, Krasnik V, Krcova I, et al. Stereotactic radiosurgery in intraocular malignant melanoma--retrospective study. *Neuro Endocrinology Letters*. 2014;**35**(1):28-36

[19] Furdova A, Strmen P, Sramka M. Complications in patients with uveal melanoma after stereotactic radiosurgery and brachytherapy. *Bratislavské Lekárske Listy*. 2005;**106**(12):401, 16642665-406

[20] Furdova A, Babal P, Kobzova D, Zahorjanova P, Kapitanova K, Sramka M, et al. Uveal melanoma survival rates after single dose stereotactic radiosurgery. *Neoplasma*. 2018 Nov 15;**65**(6):965-971

[21] Dieckmann K, Georg D, Zehetmayer M, Bogner J, Georgopoulos M, Pötter R. LINAC based stereotactic radiotherapy of uveal melanoma: 4 years clinical experience. *Radiotherapy and Oncology*. 2003 May;**67**(2):199-206

[22] Dieckmann K, Georg D, Bogner J, Zehetmayer M, Petersch B, Chorvat M, et al. Optimizing LINAC-based stereotactic radiotherapy of uveal melanomas: 7 years' clinical experience. *Int J Radiat Oncol • Biol • Phys*. 2006 Nov 15;**66**(4):S47-S52

[23] Shields CL, Kaliki S, Furuta M, Fulco E, Alarcon C, Shields JA. American joint committee on cancer classification of posterior uveal melanoma (tumor size category) predicts prognosis in 7731 patients. *Ophthalmology*. 2013 Oct;**120**(10):2066-2071

[24] Arnett ALH, Reynolds MM, Pulido JS, Parney IF, Laack NN. Gamma knife stereotactic radiosurgery for the treatment of primary and metastatic ocular malignancies. *Stereotactic and Functional Neurosurgery*. 2017 Nov 4;**95**(6):363-368

[25] Mosci C, Mosci S, Barla A, Squarcia S, Chauvel P, Iborra N. Proton beam radiotherapy of uveal melanoma: Italian patients treated in Nice, France. *European Journal of Ophthalmology*. 2009 Aug;**19**(4):654-660

[26] Henderson MA, Shirazi H, Lo SS, Mendonca MS, Fakiris AJ, Witt TC, et al. Stereotactic radiosurgery and fractionated stereotactic radiotherapy in the treatment of uveal melanoma. *Technology in Cancer Research & Treatment*. 2006 Aug;**5**(4):411-419