

# We are IntechOpen, the world's leading publisher of Open Access books Built by scientists, for scientists

6,900

Open access books available

185,000

International authors and editors

200M

Downloads

Our authors are among the

154

Countries delivered to

TOP 1%

most cited scientists

12.2%

Contributors from top 500 universities



WEB OF SCIENCE™

Selection of our books indexed in the Book Citation Index  
in Web of Science™ Core Collection (BKCI)

Interested in publishing with us?  
Contact [book.department@intechopen.com](mailto:book.department@intechopen.com)

Numbers displayed above are based on latest data collected.  
For more information visit [www.intechopen.com](http://www.intechopen.com)



# Principles of Anesthesia and Airway Management in Head and Neck Surgery

*Muhammad Jaffar Khan, Tarek Tageldin,  
Muhammad Waqas Farooqi, Odai Qasim Khamash,  
Umair Shahid, Mohamed El-Fatih Abdul-Rahman,  
Mohamed Elarref and Jazib Hassan*

## Abstract

This topic aims to discuss key aspects of anesthetic and airway management for head and neck surgery. Airway management is a central part of patient care and management in Head and Neck Surgery. Common challenges in Head and Neck surgery are shared airway, distorted airway anatomy due to existing pathology; risk of airway obstruction, disconnection or loss of airway intra-operatively; risk of soiling of the airway due to bleeding and surgical debris; and the potential for airway compromise post-operatively. The option for airway management technique is influenced by patient's factors, anesthetic needs, and surgical requirements. Intubation technique necessitating either a small or large cuffed tracheal tube with a throat pack provides the highest level of airway protection. Non-intubation or open airway techniques involve mask ventilation, apneic techniques, and insufflation techniques, or the use of a laryngeal mask airway. Lastly, jet ventilation techniques may be conducted via a supraglottic, subglottic or transtracheal routes. It is essential to have clear airway management plans including rescue airway strategies that should be communicated with the surgeons and patients at the earliest opportunity.

**Keywords:** head and neck surgery, shared airway, airway management, anesthesia management, preoperative endoscopy, total intravenous anesthesia (TIVA), bronchoscopy, transoral robotic surgery, functional endoscopic surgery, laser surgery, virtual endoscopy

## 1. Introduction

Head and neck (H&N) surgery encompasses an expanded spectrum of procedures varying greatly in complexity, duration, and complications. They range from simple surgeries such as dental procedure, adenotonsillectomy to precise and image-guided laryngologic, neurotologic, and skull-base surgery, complex obstructive sleep apnea (OSA) surgery, sophisticated transoral robotic surgery (TORS), transoral laser microsurgery (TLM), and major head and neck oncological surgery with extensive free-flap reconstruction.

Head and neck surgery presents unprecedented challenges for the anesthesiologists including shared airways, concurrent comorbidities, anesthesia techniques, and postoperative complications. A Shared Airway is the term commonly used in Head and Neck surgery which is characterized by “any procedure where the anesthesiologist needs to maintain a patient’s airway patency, oxygenation, and ventilation in a similar airway anatomical space in which the surgeon operates.” Both the anesthetists and surgeons must have a clear knowledge and understanding of their respective roles in managing the ‘shared airway’. The role of the anesthetist must be to provide safe general anesthesia for the patient, an uninterrupted airway during the perioperative period, and a clear field for the surgeon by applying various hypotensive anesthesia techniques. This chapter focuses on key aspects of anesthesia and airway management strategies for common Head and Neck surgical presentations, with relevance to the current evidence base and clinical guidelines. It is aimed to be a comprehensive review for residents and fellows training in the fields of anesthesia and head and neck surgery.

2. Difficult airway management in head and neck (H&N) surgery: background

It is estimated that the occurrence of difficult airway and complications are more frequent in H&N patients than in the general surgical population. In the Fourth National Audit Project (NAP4) from the Royal College of Anesthetists and the Difficult Airway Society in the United Kingdom (UK), data regarding major airway complications were collected prospectively in approximately three million anesthetized patients throughout the UK [1]. The incidence of airway-related complications was nearly 40% in H&N surgeries [2] and almost 75% of the cases required emergency surgical airway (ESA) for “cannot intubate/cannot oxygenate” (CICO) situations. Likewise, the incidence of the emergency surgical airway (ESA) was even higher in another retrospective study of 452,461 patients in the Danish Anesthesia Database [3]. In this study, the overall incidence of ESA in ear, nose, and throat surgery was reported as 1.6 events per thousand, which was 27 times higher than in the general surgical population (0.06 per thousand). The H&N oncological patients are at even higher risk of difficult airway management, predominantly males, with an incidence of over 12% experienced difficult direct laryngoscopy and tracheal intubation [4]. In NAP4, of the 21 cases of difficult

Factors associated with airway management related complication	Inadequate airway assessment
	Inadequate planning for airway management and for failure of intubation
	Multiple intubation attempts
	Inappropriate use of a supraglottic airway (SGA) device
	Obesity
	Failure to correctly interpret capnography and recognize esophageal intubation early
	Anesthesia for head and neck surgery
	Intubation in the emergency department or intensive care unit

Table 1.  
NAP4 identified several factors associated with major airway complications.

airway observed on anesthesia induction, 13 cases occurred in patients with upper airway tumors [1]. Additionally, numerous studies have indicated that difficult tracheal intubation, defined as three or more attempts on direct laryngoscopy, may be observed in up to 7–9% of H&N cases [5–7], which is up to four folds higher than the general surgical population [8–11]. In the NAP4 study, several factors have been associated with airway related complications (see **Table 1**). Furthermore, anesthesiologists experience greater challenges during extubation and post-anesthesia recovery period [1, 12].

### 3. General principles: preoperative assessment

The preoperative Anesthesia assessment is imperative in reducing risk during shared airway procedure and must include a detailed general medical and surgical history, previous anesthetic exposure, and general physical examination as well as a focused airway assessment. It is paramount to have a multidisciplinary approach to an anticipated difficult airway in H&N surgery which requires a high degree of cooperation and communication with the surgeon, allowing for early identification of high-risk patients, and reciprocal anticipation of the potential problems and adequate preparation to face the challenges. Expertise in H&N anesthesia and complex airway management should be encouraged as it improves the outcome and reduces airway complications. The goal of preoperative assessment is to recognize patients with potentially difficult airways, stratify the risks, manage the co-morbidities, and optimize the patient’s condition before major H&N surgery (see **Table 2**).

#### 3.1 Airway assessment: history and physical exam

Preanesthesia assessment invariably includes airway evaluation to identify and predict difficulty in airway management. The incidence of difficult airway is higher for patients who undergo H&N surgeries than for general surgical procedures. Therefore, the primary priority in airway assessment is to determine whether airway is compromised. A detailed history should be obtained before the surgery which incorporates reviewing previous anesthesia records with a particular focus on airway management, identifying risk factors of possible difficult mask ventilation and tracheal intubation. History of previous difficult tracheal intubation is one of the most important predictors of the anticipated difficult airway [9, 11]. It is worth mentioning that a history of prior easy intubation does not guarantee

Anesthesia considerations in Head and Neck Surgery	Multidisciplinary approach and close-in line communication
	Presence of expertise in H&N anesthesia and complex airway management
	Anticipation of challenges during intubation and extubation
	Shared Airway with the surgeon and related challenges
	Different approach to airway management specific to surgery
	Different Anesthesia technique and positioning challenges
	Post Anesthesia recovery and Airway support

**Table 2.**  
*Anesthesia considerations in head and neck surgery.*

subsequent uneventful airway management in H&N procedures, due to the progression of the underlying pathological processes and their significant effect on the airway anatomy [13]. Anatomic anomaly relating to the face, mouth, nose, pharynx, or larynx must be thoroughly investigated. Hoarseness, drooling, dysphagia, orthopnea, stridor, cough, and recent onset of snoring may indicate airway compromise. Patients with vocal cord paralysis may be at increased risk for perioperative pulmonary aspiration. Prior H&N radiotherapy induces tissue fibrosis as well as long-standing epiglottic and glottic edema, leading to a non-compliant airway with limited mouth opening and restricted neck movement [9], which may make both mask ventilation and laryngoscopy potentially difficult [14]. Routine bedside airway assessment tools can be performed such as the American Society of Anesthesiologists (ASA) bedside airway assessment tool which includes Mallampati classification, thyromental distance, inter-incisor distance, neck mobility, and body mass index (BMI), etc. [15]. However, it is poorly predictive of difficult airway in Head and Neck surgery because it fails to assess the inside pathology and severity of the upper airway such as base of the tongue, glottic and vallecular lesions, etc. [8, 16]. Numerous risk factors associated with difficult airway management have been identified (see **Table 3**) [17].

3.2 Pre-operative assessment of comorbidities

Head and Neck surgery may entail a wide range of patient populations from young and healthy to elderly, geriatric patients with significant cardiovascular, respiratory, endocrine, and renal diseases who are also at high risk for postoperative delirium and cognitive dysfunction. The perioperative risk related to major H&N surgery rises with advanced age and an increased number of comorbidities. As part of the multidisciplinary team, the anesthesiologist plays a crucial role in deciding the treatment plans, optimizing the patient’s condition pre-operatively, and weighing the risk to benefit ratio of the surgery. Patients with cardiovascular diseases such as uncontrolled hypertension, cerebrovascular, and coronary artery disease, chronic renal insufficiency, must be evaluated for cardiac risk prior to noncardiac surgery and if required must be referred to cardiologists. Cardiopulmonary exercise testing (CPET) can be a useful aid to decision making, particularly where more extensive or complex surgery is being performed. Also, poorly controlled heart failure (New York Heart Association Grade 3–4) is associated with poor prognosis. Brain natriuretic peptide (BNP) and N-terminal proBNP are useful biomarkers for

Risk factors for predicted difficult airway management	Mallampati grade 3 or 4
	Decreased thyromental distance
	Male gender and Age > 57 years
	Absence of teeth
	Presence of beard
	Obstructive sleep apnea or History of snoring
	Decreased Mandibular protrusion
	Thick or short neck
	Neck radiation changes or a neck mass
	Obesity (BMI > 30)

**Table 3.**  
*Risk factors associated with difficult airway management [17].*



perioperative screening of heart failure patients. Moreover, the hypotensive anesthesia technique should be avoided and intraoperative hyper or hypotension should be aggressively managed. Pulmonary comorbidities are common in H&N patients. Preoperative optimization of Chronic obstructive pulmonary disease (COPD) via treatment of acute infection and appropriate use of bronchodilators and steroids is crucial to prevent post-operative pulmonary complications. Furthermore, COPD patients may not tolerate intraoperative ventilation techniques such as spontaneous ventilation, one-lung ventilation, apneic intermittent, or jet ventilation. Likewise, patients with obstructive sleep apnea (OSA) are predisposed to difficult or challenging airways and are more sensitive to sedatives and opioids which should be used cautiously. H&N procedures involving the lower cranial nerves (Cranial nerves X, XI, and XII) may increase the risk of airway obstruction or aspiration in the post-operative period. H&N cancer patients are of particular concern as smoking and alcohol are the common cause of cancer, which also predispose them to post-operative malnutrition.

### **3.3 Pre-operative investigations and imaging studies**

Head and Neck surgery patients must have baseline investigations which include complete blood count, biochemical profile with urea and electrolytes, coagulation profile, liver function test, blood sugar, and electrocardiography. Other investigations such as chest x-ray, pulmonary function tests, and arterial blood gases may be requested based on the risk factors and symptoms at presentation.

Imaging studies with computed tomography (CT) or magnetic resonance imaging (MRI) and flexible nasal endoscopy aid to determine the extent of the pathology and its impact on the airway and the surrounding soft tissues. The preoperative endoscopic airway examination (PEAE) in particular is useful for examining the upper airway to assess the significance of the swelling and distortion, the location, size, the spread of the lesions, the degree of obstruction, and vocal cords' mobility. Moreover, preoperative awake nasal endoscopy can be carried out by the anesthesiologist before induction which gives a real-time image of the upper airway and the larynx and is useful in formulating airway management strategies including awake intubation and surgical airway [18].

### **3.4 Premedication**

Premedication to reduce anxiety and secretions may be helpful in patients going for H&N surgery with minor airway lesions but should be avoided in patients with H&N masses compromising the airway. Antisialagogues may be administered in the preoperative phase to minimize oral and tracheobronchial secretions. The patient should be monitored closely when premedicated, preferably in the holding area of the OR. During the preoperative visit, anesthesiologist should attempt to reduce the patient's fears and anxiety.

## **4. Intraoperative anesthesia management of H&N surgery**

The main intraoperative goal is the appropriate choice of airway technique and airway device tailored to the patient and surgical technique. Other goals are the provision of expert airway management, a continuous plane of anesthesia, clear and immobility of the surgical field, smooth and fast recovery from anesthesia. and surgery with the implementation of enhanced recovery after surgery (ERAS) protocol for fast-track discharge of patients [19].

## **4.1 Anesthesia management**

### *4.1.1 Intraoperative monitoring technique*

Standard American Society of Anesthesiologists (ASA) monitors [20] such as Blood pressure, Electrocardiography, Pulse oximetry for O<sub>2</sub> saturation, capnography, and temperature monitoring are usually applied during H&N surgery. Invasive blood pressure monitoring and advanced hemodynamic monitoring is usually considered in patients with significant cardiovascular disease or long procedures, and when excessive blood loss is expected. One study suggested that the use of goal-directed fluid therapy based on cardiac output monitoring helps guide fluid therapy and avoid fluid overload in free flap transfer [21]. Processed electroencephalogram (EEG) monitoring helps assess the depth of anesthesia and guide anesthetic drug dosing to provide a stable plane of anesthesia during surgery. Moreover, Neuromonitoring such as electromyography (EMG) monitoring of facial nerve in some head and neck surgery may guide to modify the anesthesia technique accordingly.

### *4.1.2 Positioning*

The majority of head and neck surgeries are done in a supine position with a 15–20-degree head-up tilt to improve venous drainage. Anesthesiologists must pay meticulous attention to the patient's positioning especially since the head of the operating table is usually turned 90–180 degrees away from the anesthesia machine, limiting immediate access to the airway. Thus, long ventilator tubing and vascular access lines are required and the endotracheal tube should be secured effectively to avoid accidental extubation and disconnection. The eyes should be protected with an occlusive dressing to keep the lid closed and to prevent skin preparation solution from entering the eyes. Goggles or eye pads may be used; all pressure points must be padded, and intermittent pneumatic calf compression is applied.

### *4.1.3 Fluid management and blood loss*

Large-bore venous access is essential for major resections when significant blood loss is anticipated. Also, the need for invasive or advanced cardiac output monitoring is determined by the patient's comorbidities as well as the nature and extent of the surgery. They are useful in assessing fluid response and guiding fluid therapy. Hypotensive anesthesia and hemodilution techniques may minimize blood loss, but must be practiced with care to maintain adequate blood flow to free flaps. Moreover, urine output should be monitored in prolonged surgeries.

### *4.1.4 Choice of anesthesia techniques*

General anesthesia is the technique of choice as it provides airway protection, ensures adequate oxygenation, ventilation, immobility, and avoids distracting the surgeon. In some selected H&N surgeries, monitored anesthesia care can be provided to maintain spontaneous ventilation and a responsive patient with intact airway reflexes. The choice of induction technique for general anesthesia (intravenous versus inhalational agents) is based on patient factors, surgical needs, and potential for compromised ventilation. Preoperative assessment and consultation with the surgeon will determine the technique of endotracheal intubation (awake or asleep), selection of an intravenous versus inhalation induction technique, and whether to use a neuromuscular blocking agent (usually avoided if

Advantages of TIVA in Head and Neck surgery	Rapid titration of anesthesia to the desired clinical effect
	Allows immobility and facilitates nerve monitoring
	Allows rapid and smooth emergence after surgery
	Reduction in Postoperative Nausea and vomiting
	Induction of moderate hypotension may reduce blood loss and provide clear surgical field
	Technique of choice in laryngologic surgery during jet ventilation or intermittent apnea ventilation

**Table 4.**  
*Advantages of Total intravenous anesthesia in head and neck surgery.*

nerve monitoring to be used intraoperatively). The NAP4 report highlighted that inhalation induction may result in total airway obstruction in patients with H&N pathology, where patients do not exhale the anesthetic gases and rapid hypoxia ensues. The theoretical advantage of gas induction is that it is a slow induction that preserves spontaneous ventilation. Additionally, maintenance of anesthesia can be obtained either with total intravenous anesthesia (TIVA) or inhalation anesthetics or a combination of inhalation anesthetic with intravenous infusion of a short-acting anesthetic. Because many H&N surgeries are associated with high incidences of postoperative nausea and vomiting (PONV), propofol-based anesthesia may be a preferable technique of choice to prevent PONV [19, 22]. Many centers use total intravenous anesthesia (TIVA) with target-controlled infusion (TCI) of propofol and opioids (see **Table 4**). In TCI, pumps are programmed to deliver an induction bolus followed by a maintenance infusion based on patient’s demographics. TIVA is also useful to facilitate a clear surgical field by titrating the anesthetics to desired blood pressure [systolic blood pressure below 100 mmHg and mean arterial pressure of 60 to 70 mmHg [23]]. However, controlled hypotension should be avoided in patients with uncontrolled blood pressure, cerebrovascular or coronary artery disease, as well as chronic renal and hepatic insufficiency.

4.2 Preparing and planning for airway management

Devising safe and optimal airway management depends on close in line communication between the anesthesiologist and surgeon, airway evaluation, reviewing imaging studies, type of surgery, location of the lesion, patient’s symptoms, and tolerance of the procedure and knowing the risk associated.

4.3 Airway management techniques

The technique for airway management should be formulated with the surgeon preoperatively which includes reviewing preoperative imaging studies and endoscopy, choice of airway management device, route for tracheal intubation, awake versus sleep endotracheal intubation, use of jet ventilation, and backup strategies, including preparation for a surgical airway. The goal of a pre-planned and optimal airway approach is to achieve adequate ventilation, oxygenation, and airway protection against aspiration. The following general airway management strategies should be considered:

- General anesthesia with endotracheal intubation
- General anesthesia using a supraglottic device



- General anesthesia using an Operative laryngoscopy in conjunction with jet ventilation
- Use of intermittent apnea
- General anesthesia using the patient's natural airway or spontaneous ventilation
- Local anesthesia in conjunction with intravenous sedation, with the patient breathing spontaneously

#### *4.3.1 Options for endotracheal intubation technique*

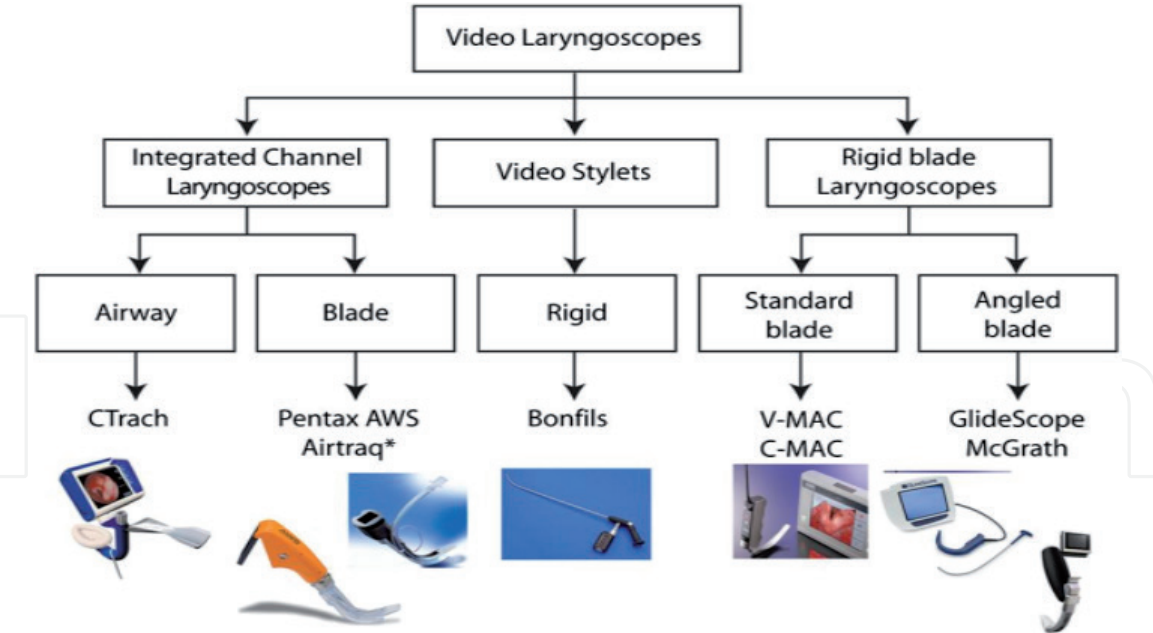
##### *4.3.1.1 Laryngoscopy technique*

It is often prudent to opt for video-laryngoscopy (VL) as a primary tracheal intubation technique because most H&N patients have high incidences of anticipated difficult airway. Multiple attempts with direct laryngoscopy (DL) should be avoided as it will lead to bleeding, soiling, edema, and fragmentation of any friable tissue in the airway that may dramatically worsen the subsequent laryngoscopic view and facemask ventilation [1, 24]. Thus, VL could be considered as a primary intubation technique in H&N patients to maximize the likelihood of first-attempt success [25]. In one meta-analysis of randomized controlled trials that compared VL versus DL in patients with anticipated or simulated difficult airways, VL was associated with improved glottic view, more likely successful intubation, and a higher chance of first-attempt intubations [26]. The provider should nonetheless approach all anticipated difficulties with caution. In one study, there was an overlap in predictive factors such as previous radiotherapy, malignancy, and previous surgery that led to difficulty in both DL and VL [27].

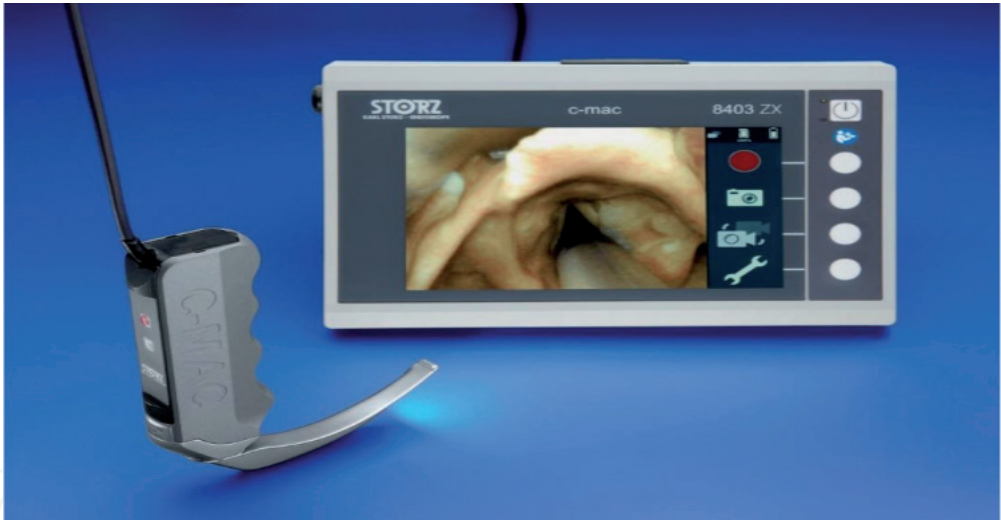In conclusion, multiple attempts should be avoided as it leads to airway trauma and obstruction and alternative laryngoscopic or intubation techniques should be considered with caution (**Figures 1 and 2**).

##### *4.3.1.2 Comparison between awake and asleep flexible fiberoptic endotracheal intubation in head and neck surgery*

There is a common perception that awake fiberoptic intubation (AFOI) is the safest approach to difficult airway management [28]. Certainly, advantages of maintenance of airway patency, gas exchange, and protection against aspiration during the intubation process are offered by awake intubation. AFOI is helpful in patients with supraglottic obstruction, e.g. epiglottic or tongue base obstruction, but it is not the preferred technique in patients with a critically narrowed laryngeal inlet where there are copious secretions, difficulty in maintenance of spontaneous ventilation, and small laryngeal aperture. Adequate topicalization is key to the patient's comfort and successful airway management. Asleep fiberoptic intubation has certain benefits such as patient comfort, avoidance of anxiety, and smooth transformation to other airway devices if necessary. However, asleep fiber optic intubation may lead to a difficult airway due to airway collapse and hypoxia from depressed respiratory function. The possibility of a successful exit strategy must be evaluated when considering asleep fiber optic intubation. In NAP4, both awake and asleep flexible fiberoptic intubation have relatively high failure rates in patients with H&N pathology, with a frequency up to 60 percent [1, 29]. The most common causes for failure of flexible scope intubation include the inability to identify the



**Figure 1.**  
*A classification of video laryngoscopic devices. CTrach image courtesy of LMA North America. Pentax AWS image courtesy of Ambu USA. Airtraq image courtesy of Prodol Meditec S.A. Bonfils and C-MACA ^ VC 2012 Photo Courtesy of KARL STORZ Endoscopy-America, Inc. GlideScope image courtesy of Verathon, USA. The McGrath series 5 image courtesy of Aircraft Medical, UK. VC 2012 Healy et al.; licensee BioMed Central Ltd. Reproduced under the terms of its Creative Commons Attribution License (2.0).*

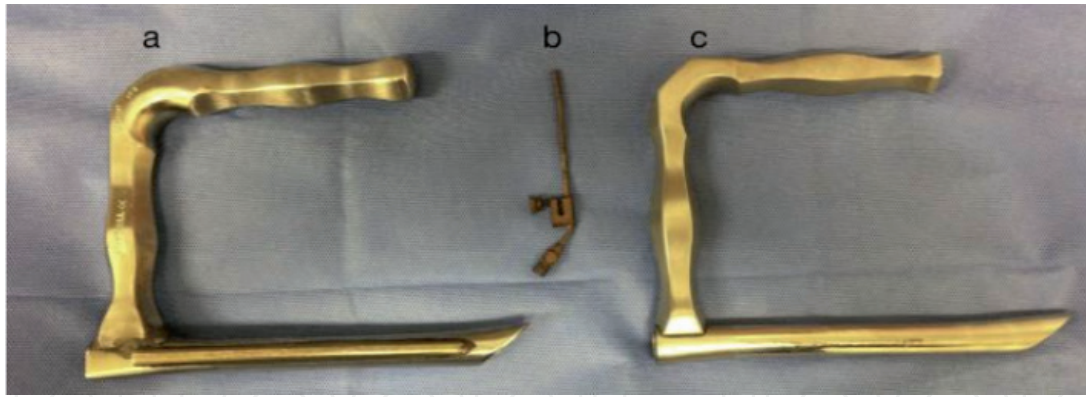


**Figure 2.**  
*4th generation Video Laryngoscope.jpg” by KARL STORZ Endoscope is licensed with CC BY-SA 4.0. To view a copy of this license, visit <https://creativecommons.org/licenses/by-sa/4.0>.*

glottis, difficulty passing the scope, bleeding, and airway obstruction. In conclusion, awake fiberoptic intubation should be considered first in patients with head and neck pathology with an understanding of the pre-existing limitations to flexible scope intubation.

4.3.1.3 Surgical laryngoscopy and rigid bronchoscopy

Rescue endotracheal intubation using operative laryngoscopy such as anterior commissure scope or rigid bronchoscope (**Figure 3**) has been effective and shown to be successful in difficult airway scenarios or when direct laryngoscopy fails [31–33]. Hillel and colleagues have shown that the use of surgical laryngoscopes helped secure over 35% of difficult airways and reduced the number of emergent



**Figure 3.**

ENT endoscope examples. (a) Dedo scope with external channel for light source; (b) Venturi jet for insertion into rigid scope; and (c) anterior commissure scope with narrower lumen. Reprinted from [30] Published by Elsevier Ltd.

cricothyroidotomies to nearly half [34]. After an operative laryngoscope or rigid bronchoscope is placed, manual ventilation can be provided safely through the lumen of the scope and subsequently, endotracheal intubation can be performed with the aid of an airway exchange catheter or a gum elastic bougie [35]. Thus, operative laryngoscopy and rigid bronchoscopy can rescue failed tracheal intubation and cannot intubate/cannot oxygenate (CICO) situations.

#### *4.3.1.4 Optical stylet intubation devices*

Optical intubation stylets (such as Bonfils, Clarus video System, Sensascope, Levitan optical stylets, etc.) may be helpful and offer an advantage over flexible scopes. These rigid optical stylets can help bypass mobile supraglottic and glottic masses, and once the glottis is entered, the endotracheal tube will follow the trajectory of the stylet in the patient's trachea. However, studies reported a wide range of success rates with the use of optical stylet [36, 37]. Success rates are higher with experienced users with the mean time to intubation at 23 seconds [38].

#### *4.3.2 Supraglottic airway devices*

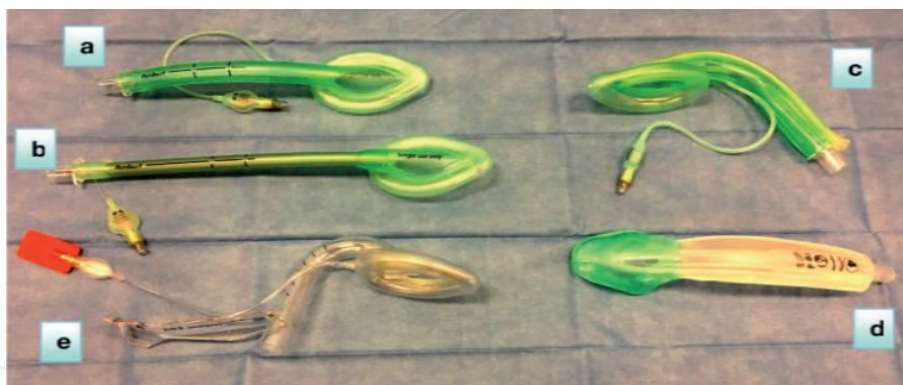
Laryngeal mask airway (LMA) devices (**Figure 4**) offer many advantages in H&N surgery. They may be used:

- as primary ventilator devices and to provide smooth emergence from anesthesia in many elective H&N surgeries, such as ear, nasal and intranasal surgery, and facial cosmetic surgery.
- as conduits for endotracheal intubation (intubating LMA).
- as rescue devices in patients who are difficult to intubate or mask ventilate.

If LMAs are deemed necessary, the anesthetist should opt for the second generation whose seal design have been shown with less leakage and reduced risk of aspiration.

However, there are limitations to the supraglottic airway devices in H&N pathology. They may be difficult to place in patients with history of neck irradiation; limited mouth opening; and glottic, hypopharyngeal, or subglottic lesions.





**Figure 4.** Supraglottic airway devices (single use). (a) Classic LMA (Ambu AuraStraight disposable laryngeal mask). (b) Flexible LMA (Ambu AuraFlex disposable laryngeal mask). (c) Second Generation LMA (Ambu AuraGain disposable laryngeal mask). (d) i-gel supraglottic airway. (e) Intubating LMA (LMA Fastrach). Reprinted from [39]. Crown Copyright © 2018 Published by Elsevier Ltd. All rights reserved.

#### 4.3.3 Combined video laryngoscopy and flexible fiberoptic intubation technique

The combination of VL and flexible scope or optical stylet is gaining popularity in complex airway management [40–42]. Video laryngoscopy provides an enlarged view of the glottis and facilitates manipulation of the flexible scope or optical stylet in patients with distorted anatomy or airway tumors. The combined technique allows continuous visualization and reduced trauma to friable tumors or masses.

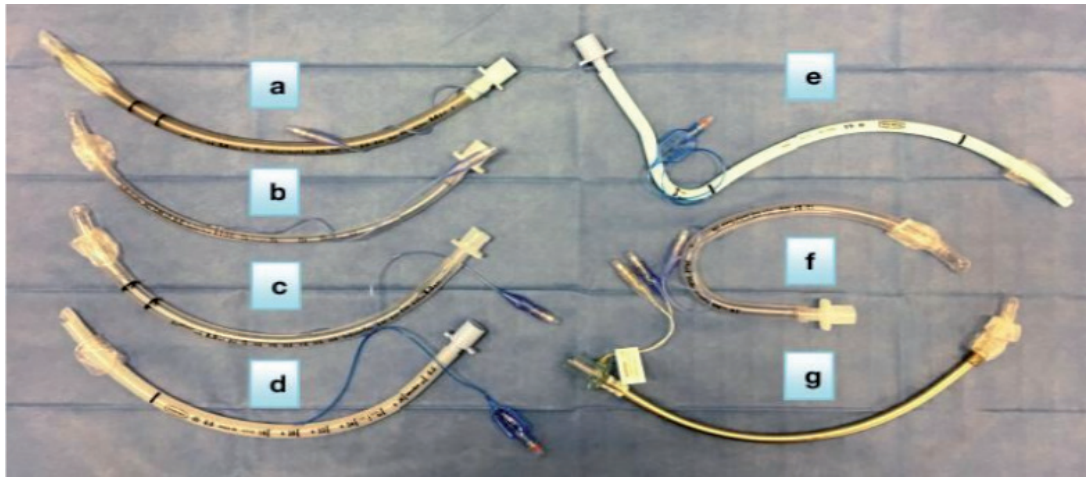
#### 4.3.4 Surgical airway

Surgical airway is considered when endotracheal intubation fails or when traditional endotracheal intubation is not a feasible option due to the nature and unique requirements of the surgery. Awake tracheostomy under local anesthesia should be strongly considered as a primary plan in patients with significant airway obstruction. It may also be planned as the primary intubation strategy in patients who are expected to have significant airway compromise postoperatively possibly due to extensive reconstructive surgery. An alternative is awake cricothyroidotomy (CTM) which can be safely performed for any patients with difficult airways [43]. In case of emergency airway management, surgical cricothyroidotomy is strongly preferred over the percutaneous cricothyroidotomy as the chance of failure of emergency transcatheter CTM is nearly 60% in H&N patients according to NAP4 report.

#### 4.3.5 Choice of endotracheal tube

The type and size of tubes depending on the type of surgeries, location, invasiveness of the surgery, and the patient's factors (**Figure 5**). The size and type of ETT should be determined with the surgeon. Endotracheal tubes must be appropriately sized and adequately secured to prevent accidental extubation or displacement during surgery.

- A reinforced, flexible ETT is an excellent choice for shared airway procedures. They are commonly utilized for intraoral surgery.
- Nasal endotracheal intubation (e.g. Nasal RAE tube) is commonly preferred for procedures such as transoral robotic surgery, orthognathic and maxillo-mandibular surgery, base of tongue surgery, and some dental procedures as it provides better visualization of the oral cavity.



**Figure 5.** Tracheal Tubes. (a) Armored flexible (Mallinckrodt Lo-Contour Reinforced TT). (b) Micro laryngeal (Mallinckrodt Microlaryngeal TT Cuffed). (c) Standard (Mallinckrodt Hi-Contour Cuffed TT). (d) Standard Profile Cuff (Portex Profile Soft Seal Cuff). (e) Preformed Polar North Facing Nasal (Portex Ivory PVC, North Facing, Nasal, Profile Soft Seal Cuff, Polar Preformed). (f) Preformed RAE South Facing Oral (Mallinckrodt Oral RAE TT Cuffed). (g) Laser (Mallinckrodt Laser TT Dual Cuffed). Reprinted from [39]. Crown Copyright © 2018 Published by Elsevier Ltd. All rights reserved.

- A small-sized micro laryngeal tube (5-mm internal diameter tube but are longer than standard tube) is commonly used for micro laryngeal surgery to facilitate surgical access.
- A specialized laser-resistant endotracheal tube is used for airway laser surgery.
- Nerve integrity monitor endotracheal tube may be used for specific H&N procedures closely approximating the laryngeal nerves.

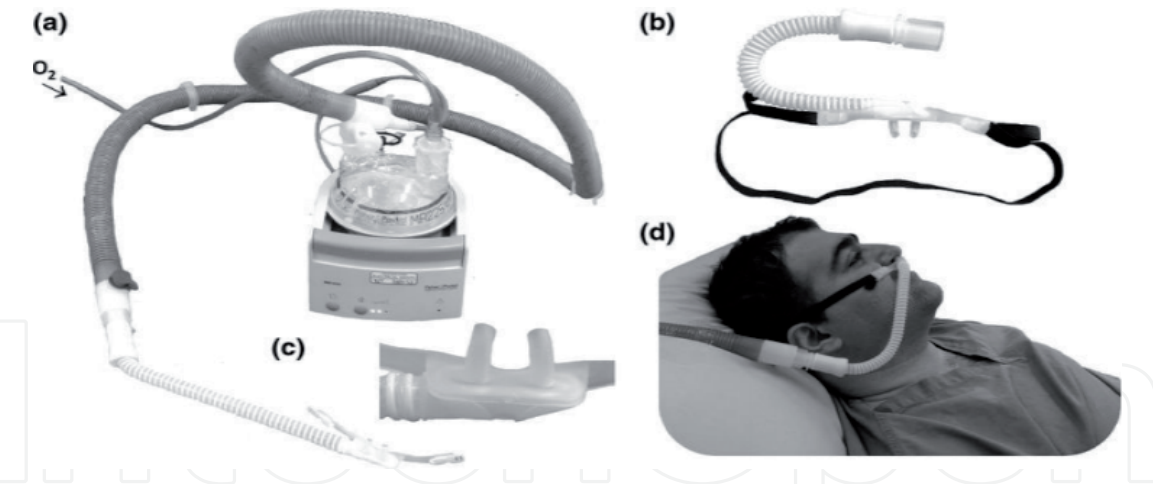
#### 4.4 Oxygenation and ventilation strategies

Maintenance of oxygenation and ventilation is the cornerstone of shared airway management in H&N surgery as these patients are at high risk of failed tracheal intubation and a “cannot intubate, cannot ventilate” situation. Traditional methods of increasing the apneic window during induction involve spontaneous facemask ventilation with 100 percent oxygen. Transnasal high-flow rapid insufflation ventilator exchange or THRIVE delivered through a nasal high-flow oxygen delivery system has been shown to increase the apnea time in a patient with difficult airway to an average of 14 minutes (**Figure 6**) [44]. THRIVE provides apneic oxygenation, continuous positive airway pressure to avoid atelectasis, as well as flow-dependent dead space and carbon dioxide flushing, and its role in difficult airway management is presently being studied. Alternatively, a pre-operative transtracheal jet ventilation (TTJV) cannula or an Arndt cricothyroidotomy catheter can be used for tracheal oxygen insufflation [45] to facilitate ventilation. For patients at risk of rapid desaturation or anticipated difficult airway, the provider may use the head-up position, then noninvasive ventilation (NIV) for preoxygenation followed by apneic oxygenation after induction of anesthesia.

Various ventilatory techniques are applied to meet the demands of H&N surgery such as the type of surgery and the access required to the operative site. Following are the ventilator mode techniques used during laryngologic surgery

- **Spontaneous ventilation with local anesthesia or sedation:** this mode of ventilation allows patients to maintain their airways, but few tolerate procedures with such mode of ventilation.





**Figure 6.**  
The OptiFlow high-flow humidified oxygen delivery system. The oxygen humidification unit (a) receives oxygen from a standard oxygen regulator and delivers humidified oxygen to a custom-built transnasal oxygen cannula (b and c) like a standard nasal oxygen cannula (d). Reprinted from [44]. © 2014 The Authors Anaesthesia published by John Wiley & Sons Ltd on behalf of Association of Anaesthetists of Great Britain and Ireland.

Type by technique	Type by location
• Conventional jet ventilation or LFJV (manual via high pressure manual jet)	• Supraglottic (via rigid ENT laryngoscope)
• High Frequency jet ventilation via machine with low tidal volumes and high frequencies	• Subglottic (via special catheter)
	• Transtracheal (via cannula)

**Table 5.**  
Classification of jet ventilation.

- **Spontaneous respiration with general anesthesia:** common in pediatric; oxygenation and ventilation are provided via Storz bronchoscopy for upper airway endoscopic procedures.
- **Intermittent, Positive-pressure ventilation:** this is usually carried out using a micro laryngoscopy tube (MLT), and allows for the use of standard anesthetic equipment in a normal operating setup. However, it provides a mobile operative field that moves with respiration and sometimes surgical access is reduced or obscured especially in surgery involving the posterior third of the glottis.
- **Intermittent apnea without endotracheal intubation:** this has the advantage of providing an unobstructed surgical view but poor airway protection and inadequate control of anesthesia depth. The patient's airway is intubated in cases of desaturation and but may be extubated prior to surgery resumption.
- **Jet ventilation:** consists of rapid insufflation of gas (oxygen) at high velocity via a narrow nozzle into an open airway. It can be done at either low or high-frequencies. Jet ventilation can be delivered via supraglottic, infraglottic, or transtracheal routes and it provides the optimal surgical view with reduced stimulation (Table 5). Paralysis and TIVA are usually required for this technique.

- i. **Low-frequency jet ventilation (LFJV)** is delivered using a high-pressure gas source via a narrow cannula attached to a suspension laryngoscope or bronchoscope. Ventilatory frequency is usually around 10–30 cycles per minute. The stream of high-velocity gas entrains air and increases the tidal volume but reduces the oxygen concentration of the inspired gas. It is easy to perform, requiring uncomplicated anesthetic equipment and allows a clear surgical view. Inhalational anesthesia may not be delivered easily, so total intravenous anesthesia is preferred. However, there are certain disadvantages such as mobility of the operative field, difficulty monitoring airway pressure, risk of gas entrainment, and barotrauma
- ii. **High-frequency jet ventilation** is more commonly used especially for infraglottic and transtracheal routes. HFJV is usually set at 150 cycles per minute, delivering tidal volumes as small as 1 to 3 ml/kg. HFJV provides a motionless and still surgical field. TIVA is the anesthesia of choice. However, there are possible risks of gastric insufflation, carbon dioxide retention, and barotrauma

#### 4.5 Analgesia

A multimodal approach in the form of acetaminophen, non-steroidal anti-inflammatory drugs, gabapentin, opioids, and local as well as regional anesthesia can be given perioperatively. Post-operative patient-controlled analgesia can be considered with step down to oral opioids as required.

#### 4.6 Postoperative nausea and vomiting (PONV) prophylaxis

Patients who undergo H&N surgery are at high risk of postoperative nausea and vomiting and should be managed aggressively as it can result in increased morbidity. A multimodal approach to prophylaxis is essential, encompassing TIVA with intraoperative dexamethasone (8 mg Intravenous), 5-HT<sub>3</sub> antagonist (e.g. ondansetron 4 to 8 mg intravenous), and utilization of multimodal analgesia to minimize opioid requirement.

Classes of antiemetics are

- 5-HT<sub>3</sub> receptor antagonists (e.g. ondansetron)
- Nk-1 receptor antagonists (e.g. aprepitant)
- Corticosteroids (e.g. dexamethasone)
- Butyrophenones (e.g. haloperidol)
- Antihistamines (e.g. meclizine)
- Anticholinergics (e.g. scopolamine)
- Phenothiazines (e.g., metoclopramide)

#### 4.7 Emergence and extubation

The goals of safe emergence from anesthesia include smooth, rapid emergence and extubation, avoidance of straining, bucking, and coughing, and a

complete, pain-free awakening. Extubation plan should be formulated thoroughly with the surgeons in the preoperative period. One may consider the extubation guidelines as outlined by the Difficult Airway Society of the United Kingdom or American Society of Anesthesiologists Practice Guidelines for the management of the difficult airway [46, 47]. In cases of anticipated post-operative airway complications, extubation may be delayed and patient should be transported to the intensive care unit. Extubation considerations should include the following options:

- Fully awaken the patient and extubate immediately postoperatively
- If anticipating airway compromise, admit to the intensive care unit for a delayed tracheal extubation
- Conduct tracheostomy.

## **5. Postoperative management**

Enhanced recovery after surgery protocol should be applied to facilitate fast-track discharge as most of the H&N surgeries are done on an ambulatory basis [19]. Those patients who require post-operative airway management should be cared for in intensive care unit. Varadarajan and colleagues [48] proposed that any of the following could be indications for postoperative ICU admission:

- Patients requiring post-op assisted ventilation
- Patients requiring diagnostic or therapeutic bronchoscopy
- Patients requiring invasive hemodynamic or cardiac monitoring such as in the setting of hemodynamic instability
- Patients with multiorgan failure requiring critical care management.

## **6. Special considerations**

### **6.1 Anesthesia considerations for transoral robotic surgery (TORS)**

Transoral robotic surgery is a minimally invasive surgical technique most widely used for radical tonsillectomy, oropharyngeal cancer resection, localization of occult primary head and neck tumors, supraglottic partial laryngectomy, and treatment of snoring and obstructive sleep apnea [49]. TORS allows exceptional surgical treatment of head and neck pathology while minimizing morbidity and improving functional outcomes as compared with open surgical approaches. Anesthetic challenges include shared airway with a robot and limited access to the patient intraoperatively. Airway management includes nasal RAE or wire-reinforced endotracheal intubation and the use of TIVA with a combination of TCI propofol and remifentanyl as the choice of anesthetic. Possible complications include pressure point injury and deep vein thrombosis due to prolonged surgery, risk of airway fire, aspiration, and post-operative bleeding. As TORS expands, local guidelines must be produced that support high standards of perioperative care [49, 50].

## **6.2 Anesthesia considerations for laser surgery**

Laser surgery is employed to treat laryngeal pathoses such as papilloma, laryngomalacia, vocal cord cysts, vocal cord polyps and granulomas, and post-operative scar tissues. Laser micro laryngoscopy enables precise management of a wide range of upper airway conditions. The type of airway management required for laser surgery is determined by whether access is needed to the hypopharynx, supraglottis, larynx, or subglottis. Ventilatory techniques that may be used include continuous endotracheal intubation with specialized laser tubes, spontaneous ventilation with insufflation techniques, intermittent apneic technique, or jet ventilation (supraglottic or subglottic) and with TIVA. TIVA using propofol and remifentanyl titrated to maintain spontaneous ventilation is an alternative technique. Laser-resistant endotracheal tubes are used as airway fire poses a major risk. For a fire to occur, the triad of fuel (e.g., ETT, drapes, sponges), oxygen, and ignition source is needed. The American Society of Anesthesiologists (ASA) published an operating room fire algorithm that guides managing airway fires [51]:

- Declare a fire and alert the team
- Halt the procedure and the laser beam
- Irrigate the surgical field with saline
- Immediately cease airway gases/ventilation and remove ETT
- Remove sponge and other flammable materials from the airway
- Resume bag-mask ventilation and prepare for reintubation once the airway fire is extinguished
- Examine the airway for evidence of debris, thermal injury, or foreign bodies and consider bronchoscopy

## **6.3 Anesthesia considerations for endoscopic sinus surgery**

Functional endoscopic sinus surgery is an effective, low-risk procedure for chronic rhinosinusitis, nasal polyposis, epistaxis control, tumor excision, foreign body removal, treatment of sinus mucocoeles, and more. Anesthetic considerations include local versus general anesthesia, supraglottic airway devices versus endotracheal intubation, inhaled anesthesia versus TIVA, and the preferences of the surgical team while taking the patient's comorbidities into account. The main goals are to provide a bloodless surgical field, patient immobility, stable hemodynamic conditions, and smooth emergence. Different techniques are utilized to induce "controlled hypotension" which reduces bleeding and improves the surgical visual field. However, this procedure has potential major complications which include orbital hematoma resulting in blindness or reduced vision, cerebrospinal fluid leaks, renal or arterial injury, severe hemorrhage, and death.

## **6.4 Anesthesia consideration for major oral and maxillofacial cancer surgery**

Because oral cancers are associated with smoking and alcohol excess, cardiopulmonary compromise and malnutrition are more common comorbidities. Moreover, airway difficulty can arise due to distortion of the airway by the tumor or as a



consequence of radiotherapy. Surgery is typically performed using general anesthesia with tracheal intubation (preferably nasal ETT) and invasive hemodynamic monitors depending on the extent of the surgery and the patient's comorbidities. Hypotensive anesthesia is encouraged to reduce blood loss. Long-acting paralytics should be avoided when electromyography is employed, TIVA is often a preferred anesthetic choice. The application of ERAS to major head and neck cancer surgery has led to other guidelines for perioperative management.

### **6.5 Anesthesia consideration for free flap transfer**

Tissue transfer in the form of a pedicled or microvascular free flap is commonly employed to reconstruct defects following H&N cancer resection [52]. The graft may consist of soft tissues, bone, or both. Anesthetic management aims to maintain a full, hyperdynamic circulation with increased cardiac output, liberal fluid resuscitation, peripheral vasodilation, and normothermia to maximize flap perfusion. Hematocrit should be maintained at 30–35% to improve oxygen transfer and red cell velocity within the microcirculation. Vasoconstrictors are usually discouraged as they can contribute to graft ischemia. Intraoperative and postoperative flap monitoring is achieved clinically (by bedside examination of the flap color, temperature, turgor, edema, and capillary refill), and by using technical means such as Doppler ultrasound or near-infrared spectroscopy.

### **6.6 Anesthesia consideration for craniofacial surgery**

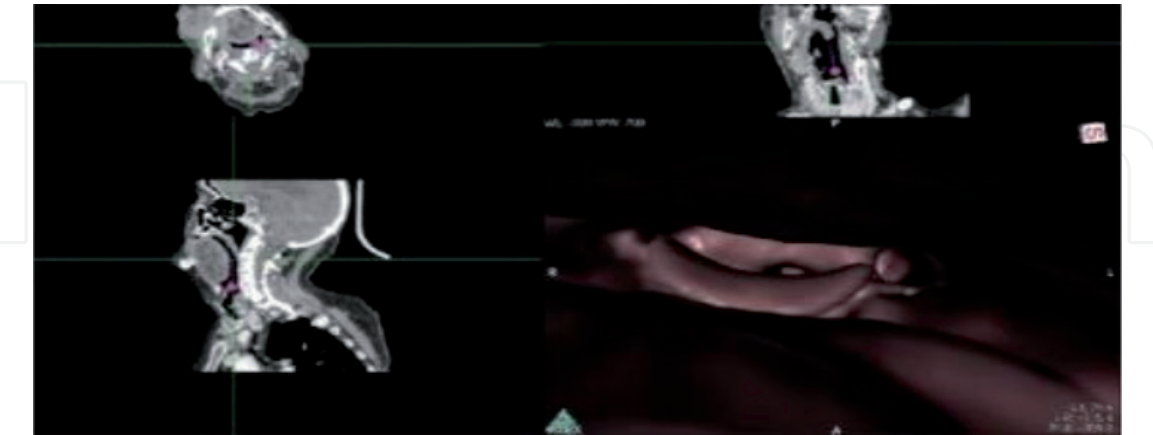Craniofacial surgery addresses congenital or acquired deformities through cleft lip and palate repair, temporomandibular joint surgery, and orthognathic procedures. Obstructive sleep apnea and congenital airway deformities is common in these patients. In general, nasal intubation is frequently preferred in orthognathic surgery. Submental intubation may be required if the nasal route is difficult or if the surgeon requires access to the upper portion of the face. In submental intubation, an incision is first made through the submental skin into the floor of the mouth. After routine oral intubation, the proximal end of the endotracheal tube is passed through the floor of the mouth out to the submental skin. The process is reversed at the end of the surgery and the patient is extubated orally. Bleeding is a potential risk that can be controlled by positioning the patient head up, ensuring free venous drainage, utilizing local anesthesia containing adrenaline, and utilizing controlled hypotension. Antibiotic prophylaxis, multi-modal analgesia, PONV prophylaxis, and steroids to reduce swelling are also important components of perioperative management.

## **7. Virtual endoscopy and 3-D reconstruction for airway evaluation in H&N pathology**

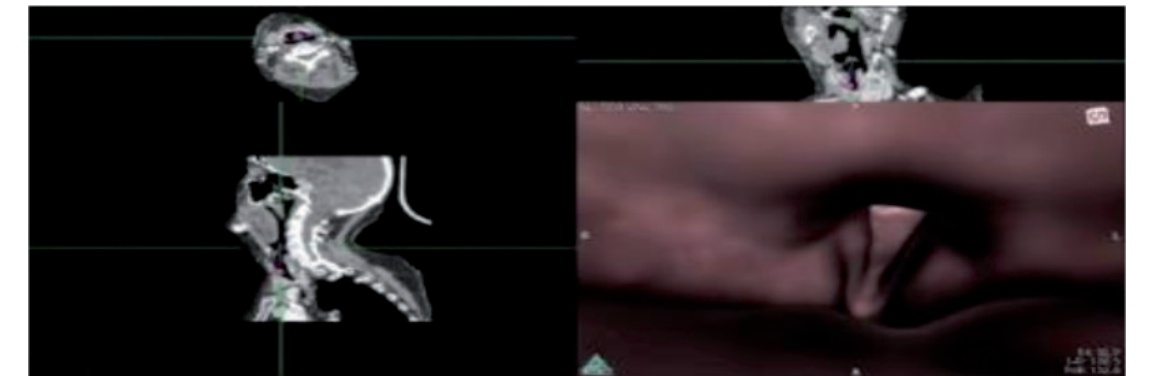
Preemptive imaging of the airway is a valuable aide to traditional clinical airway evaluation for strategizing airway management. The NAP4 highlighted that 40% of the patients with head and neck pathology developed airway related complications. These failures were attributed to shortcomings in airway evaluation, planning, and adaptations of airway and anesthetic techniques according to the patient's pathology. Virtual endoscopy (VE) has been utilized by radiologists for many years to assess, identify, and stage the various lesions. VE utilizes multidimensional CT images to construct 3D endoscopic images at various sites from the nasopharynx to a tracheo-bronchial tree [53]. VE enables computer-generated 3-dimensional portrayal of the airway cavity (**Figures 7–9**). Virtual endoscopy is a valuable and safe tool as it provides



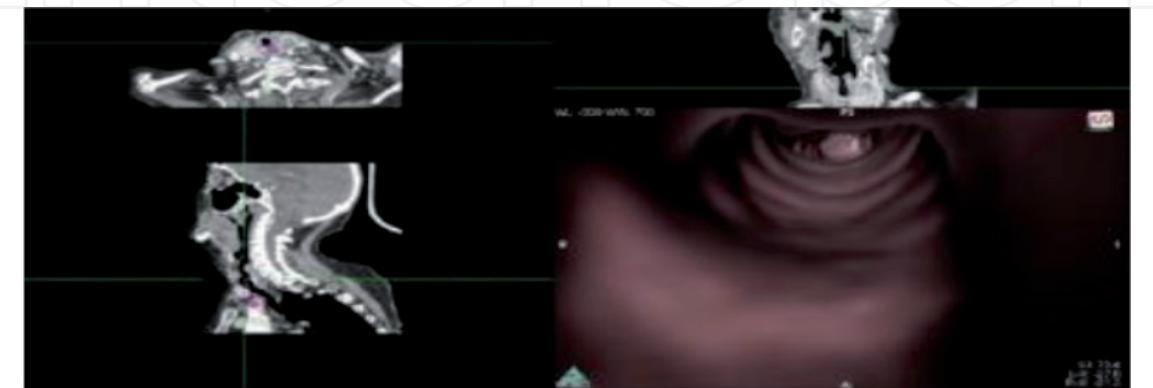
a complete, non-invasive, and anatomically accurate portrayal of the patient’s airway, starting from nasopharynx or oro-pharynx to the tracheobronchial tree. The virtual airway can be reconstructed from the patient’s pre-existing diagnostic CT images using the OsiriX software [54–56]. VE can contribute significantly to preemptive strategies against the NAP4 highlighted shortcomings and help improve overall patient outcome.



**Figure 7.** Supraglottic virtual endoscopy reconstruction showing the epiglottis [54]. Reprinted with permission from Dr. Imran Ahmad FRCA, Consultant Anaesthetist, Clinical Lead for Airway Management, Service Clinical Lead for Anaesthesia & Theatres, Guy’s Hospital, Guy’s & St Thomas’ NHS Foundation Trust, London, UK & Honorary Senior Lecturer, King’s College London, UK.



**Figure 8.** Virtual endoscopy reconstruction showing the glottic opening [54]. Reprinted with permission from Dr. Imran Ahmad FRCA, Consultant Anaesthetist, Clinical Lead for Airway Management, Service Clinical Lead for Anaesthesia & Theatres, Guy’s Hospital, Guy’s & St Thomas’ NHS Foundation Trust, London, UK & Honorary Senior Lecturer, King’s College London, UK.



**Figure 9.** Subglottic virtual endoscopy reconstruction showing the trachea [54]. Reprinted with permission from Dr. Imran Ahmad FRCA, Consultant Anaesthetist, Clinical Lead for Airway Management, Service Clinical Lead for Anaesthesia & Theatres, Guy’s Hospital, Guy’s & St Thomas’ NHS Foundation Trust, London, UK & Honorary Senior Lecturer, King’s College London, UK.

## **8. The COVID-19 pandemic and head and neck surgery**

The novel coronavirus disease 2019 (COVID-19) has become a pandemic exposing many unprecedented challenges to health care systems. In head and neck procedures, health care staff are at a higher risk of contracting the virus as most examinations and procedures within the respiratory tract. Understanding how to mitigate the risks is critical. The British Otolaryngology Society and the American Society of Gastrointestinal Endoscopy recommended mandatory personal protective equipment (PPE) use, procedures performed in negative-pressure rooms, and thorough decontamination of endoscopes, equipment, and rooms. All non-urgent surgery should be deferred to prevent consumption of emergency equipment and avoid outpatients spread. Airway management strategies should include designating experienced providers, closing circuits, intubating in negative pressure rooms, applying rapid sequence induction techniques, and minimizing bag-mask ventilation. All standard airway equipments should be available including bag-masks with High-Efficiency Particular Air (HEPA) filters, video laryngoscopes with disposable blades, ventilators, and tubes with inline adapter, HEPA filter, and clamp for ETT for application during tube disconnection to avoid aerosolization [57]. On the other hand, awake intubation should be avoided as coughing and bucking may promote aerosolization. THRIVE, jet ventilation, or open-circuit positive pressure ventilation are discouraged. Laser surgery or endonasal and otologic drilling should be avoided as viral particles can spread through plumes [58].

## **9. Conclusion**

Head and neck surgery involves a wide range of procedures from the simple to the complex. Thus, it poses greater challenges to the anesthesiologist; he/she must optimize the patient's comorbidities preoperatively, share the airway, implement different anesthesia and airway techniques specific to each surgery, and manage postoperative airway complications. Head and neck surgery patients often present with difficult airways due to the pathologies which impede the airway anatomy. Therefore, preoperative planning necessitates thorough history and physical examination with particular attention to the airway evaluation. High-risk patients should be identified preoperatively and medically optimized before surgery. A multidisciplinary approach and expertise in H&N anesthesia and advanced airway management should be encouraged as it decreases airway complications and improves surgical outcomes. The preoperative endoscopic airway examination is a useful aide in providing a real-time image of the upper airway and allows adequate preparation. General anesthesia with total intravenous anesthesia (TIVA) is the anesthesia of choice as it offers quick titration of anesthesia, allows immobility, prevents postoperative nausea and vomiting, reduces blood loss by inducing controlled hypotension, and facilitates smooth and rapid emergence. Airway management planning also requires close communication and cooperation with the surgical team. Endotracheal intubation is a general considered in H&N surgery because it offers optimal airway control with adequate oxygenation, ventilation, and protection against aspiration. Video laryngoscopy is recommended in H&N surgery. Different ventilator techniques including jet ventilation should be considered in H&N surgery. Furthermore, multimodal analgesia, PONV prophylaxis, use of steroids to reduce airway edema, and antibiotic prophylaxis are essential components of intraoperative management. Enhanced recovery after surgery (ERAS) guidelines in H&N surgery should be applied. The decision to admit a patient in the critical care unit postoperatively is based on the patient's comorbidities, intraoperative events, complexities

of the surgery, and requirements for airway support. Recent advances in airway management techniques (such as virtual endoscopy) and surgical techniques have been shown to improve the outcome.

### **Conflict of interest**

The authors declare no conflict of interest.

### **Author details**

Muhammad Jaffar Khan\*, Tarek Tageldin, Muhammad Waqas Farooqi, Odai Qasim Khamash, Umair Shahid, Mohamed El-Fatih Abdul-Rahman, Mohamed Elarref and Jazib Hassan  
Department of Anesthesia, Perioperative Medicine and Critical Care,  
Hamad Medical Corporation, Doha, Qatar

\*Address all correspondence to: jafar06khan@gmail.com

### **IntechOpen**

© 2020 The Author(s). Licensee IntechOpen. This chapter is distributed under the terms of the Creative Commons Attribution License (<http://creativecommons.org/licenses/by/3.0>), which permits unrestricted use, distribution, and reproduction in any medium, provided the original work is properly cited. 

## References

- [1] Cook TM, Woodall N, Harper J, Benger J. Major complications of airway management in the UK: Results of the Fourth National Audit Project of the Royal College of Anaesthetists and the Difficult Airway Society. Part 2: Intensive care and emergency departments. *Br J Anaesth*. 2011;
- [2] Patel A, Pearce A P, P. Chapter 18 Head and neck pathology. In: Fourth National Audit Project of the Royal College of Anaesthetists and Difficult Airway Society. 2011. p. 143-154.
- [3] Rosenstock C V., Nørskov AK, Wetterslev J, Lundstrøm LH. Emergency surgical airway management in Denmark: A cohort study of 452 461 patients registered in the Danish Anaesthesia Database. *Br J Anaesth* [Internet]. 2016 Sep 1 [cited 2020 Sep 24];117:i75-82. Available from: <http://bjanaesthesia.org/article/S0007091217337716/fulltext>
- [4] Arné J, Descoins P, Fusciardi J, Ferrier B, Boudigues D, Ariès J. Preoperative assessment for difficult intubation in general and ENT surgery: predictive value of a clinical multivariate risk index †. Vol. 80, *British Journal of Anaesthesia*. 1998.
- [5] Iseli TA, Iseli CE, Golden JB, Jones VL, Boudreaux AM, Boyce JR, et al. Outcomes of intubation in difficult airways due to head and neck pathology. *Ear, Nose Throat J* [Internet]. 2012 Mar 10 [cited 2020 Sep 24];91(3):E1-5. Available from: <http://journals.sagepub.com/doi/10.1177/014556131209100313>
- [6] Heinrich S, Birkholz T, Irouschek A, Ackermann A, Schmidt J. Incidences and predictors of difficult laryngoscopy in adult patients undergoing general anesthesia: A single-center analysis of 102,305 cases. *J Anesth* [Internet]. 2013 Dec 9 [cited 2020 Sep 24];27(6):815-21. Available from: <https://link.springer.com/article/10.1007/s00540-013-1650-4>
- [7] Crosby ET, Cooper RM, Douglas MJ, Doyle DJ, Hung OR, Labrecque P, et al. The unanticipated difficult airway with recommendations for management. *Can J Anaesth* [Internet]. 1998 [cited 2020 Sep 24];45(8):757-76. Available from: <https://link.springer.com/article/10.1007/BF03012147>
- [8] Connelly NR, Ghandour K, Robbins L, Dunn S, Gibson C. Management of unexpected difficult airway at a teaching institution over a 7-year period. *J Clin Anesth*. 2006 May 1;18(3):198-204.
- [9] O'Dell K. Predictors of Difficult Intubation and the Otolaryngology Perioperative Consult [Internet]. Vol. 33, *Anesthesiology Clinics*. W.B. Saunders; 2015 [cited 2020 Sep 24]. p. 279-90. Available from: <http://www.anesthesiology.theclinics.com/article/S1932227515000142/fulltext>
- [10] Cavallone LF, Vannucci A. Extubation of the Difficult Airway and Extubation Failure. *Anesth Analg* [Internet]. 2013 Feb [cited 2020 Sep 24];116(2):368-83. Available from: <http://journals.lww.com/00000539-201302000-00018>
- [11] Lundstrøm LH, Møller AM, Rosenstock C, Astrup G, Gätke MR, Wetterslev J. A documented previous difficult tracheal intubation as a prognostic test for a subsequent difficult tracheal intubation in adults. *Anaesthesia* [Internet]. 2009 Oct 1 [cited 2020 Sep 24];64(10):1081-8. Available from: <http://doi.wiley.com/10.1111/j.1365-2044.2009.06057.x>
- [12] Schaeuble JC, Caldwell JE. Effective Communication of Difficult Airway Management to Subsequent Anesthesia Providers.



Anesth Analg [Internet]. 2009 Aug [cited 2020 Sep 24];109(2):684-6. Available from: <http://journals.lww.com/00000539-200908000-00063>

[13] Brucker JL, Gentry LR. Imaging of Head and Neck Emergencies [Internet]. Vol. 53, Radiologic Clinics of North America. W.B. Saunders; 2015 [cited 2020 Sep 24]. p. 215-52. Available from: <http://www.radiologic.theclinics.com/article/S0033838914001468/fulltext>

[14] Kheterpal S, Martin L, Shanks AM, Tremper KK. Prediction and outcomes of impossible mask ventilation: A review of 50,000 anesthetics. Anesthesiology [Internet]. 2009 Apr 1 [cited 2020 Sep 1];110(4):891-7. Available from: [www.anesthesiology.org](http://www.anesthesiology.org).

[15] Apfelbaum JL, Hagberg CA, Caplan RA, Connis RT, Nickinovich DG, Benumof JL, et al. Practice guidelines for management of the difficult airway: An updated report by the American Society of Anesthesiologists Task Force on Management of the Difficult Airway [Internet]. Vol. 118, Anesthesiology. American Society of Anesthesiologists; 2013 [cited 2020 Sep 24]. p. 251-70. Available from: <http://links.lww.com/ALN/A902>.

[16] Lundstrøm LH, Vester-Andersen M, Møller AM, Charuluxananan S, L'Hermite J, Wetterslev J. Poor prognostic value of the modified Mallampati score: A meta-analysis involving 177 088 patients [Internet]. Vol. 107, British Journal of Anaesthesia. Oxford University Press; 2011 [cited 2020 Sep 24]. p. 659-67. Available from: <http://bjanaesthesia.org/article/S0007091217325990/fulltext>

[17] Kheterpal S, Healy D, Aziz MF, Shanks AM, Freundlich RE, Linton F, et al. Incidence, predictors, and outcome of difficult mask ventilation combined with difficult laryngoscopy: a report from the multicenter perioperative

outcomes group. Anesthesiology [Internet]. 2013 Dec 1 [cited 2020 Sep 24];119(6):1360-9. Available from: [http://pubs.asahq.org/anesthesiology/article-pdf/119/6/1360/263731/20131200\\_0-00022.pdf](http://pubs.asahq.org/anesthesiology/article-pdf/119/6/1360/263731/20131200_0-00022.pdf)

[18] Daodu O, Panda N, Lopushinsky S, Varghese TK, Brindle M. COVID-19 – Considerations and Implications for Surgical Learners. Ann Surg [Internet]. 2020 Jul 1 [cited 2020 Aug 24];272(1):e22-3. Available from: <https://journals.lww.com/10.1097/SLA.00000000000003927>

[19] Coyle MJ, Main B, Hughes C, Craven R, Alexander R, Porter G, et al. Enhanced recovery after surgery (ERAS) for head and neck oncology patients. Clin Otolaryngol [Internet]. 2016 Apr 1 [cited 2020 Sep 24];41(2):118-26. Available from: <http://doi.wiley.com/10.1111/coa.12482>

[20] ASA: American Society of Anesthesiologist. Standards for Basic Anesthetic Monitoring | American Society of Anesthesiologists (ASA) [Internet]. 2015 [cited 2020 Aug 24]. Available from: <https://www.asahq.org/standards-and-guidelines/standards-for-basic-anesthetic-monitoring>

[21] Dort JC, Farwell DG, Findlay M, Huber GF, Kerr P, Shea-Budgell MA, et al. Optimal perioperative care in major head and neck cancer surgery with free flap reconstruction: A consensus review and recommendations from the enhanced recovery after surgery society [Internet]. Vol. 143, JAMA Otolaryngology - Head and Neck Surgery. American Medical Association; 2017 [cited 2020 Sep 24]. p. 292-303. Available from: <https://jamanetwork.com/journals/jamaotolaryngology/fullarticle/2565537>

[22] Eberhart LHJ, Eberspaecher M, Wulf H, Geldner G. Fast-track eligibility, costs and quality of recovery after intravenous anaesthesia with propofol-remifentanyl versus balanced



anaesthesia with isoflurane-alfentanil. Eur J Anaesthesiol [Internet]. 2004 Feb [cited 2020 Sep 24];21(2):107-14. Available from: [/core/journals/european-journal-of-anaesthesiology/article/fasttrack-eligibility-costs-and-quality-of-recovery-after-intravenous-anaesthesia-with-propofolremifentanyl-versus-balanced-anaesthesia-with-isofluranealfentanil/2463B3205297D3F2B8DEF68670E1B135](http://core/journals/european-journal-of-anaesthesiology/article/fasttrack-eligibility-costs-and-quality-of-recovery-after-intravenous-anaesthesia-with-propofolremifentanyl-versus-balanced-anaesthesia-with-isofluranealfentanil/2463B3205297D3F2B8DEF68670E1B135)

[23] Brunner JP, Levy JM, Ada ML, Tipirneni KE, Barham HP, Oakley GM, et al. Total intravenous anesthesia improves intraoperative visualization during surgery for high-grade chronic rhinosinusitis: a double-blind randomized controlled trial. Int Forum Allergy Rhinol [Internet]. 2018 Oct 1 [cited 2020 Sep 5];8(10):1114-22. Available from: <http://doi.wiley.com/10.1002/alr.22173>

[24] Mort TC. Emergency Tracheal Intubation: Complications Associated with Repeated Laryngoscopic Attempts. Anesth Analg [Internet]. 2004 Aug [cited 2020 Sep 1];99(2):607-13. Available from: <http://journals.lww.com/00000539-200408000-00056>

[25] Kelly FE, Cook TM. Seeing is believing: Getting the best out of videolaryngoscopy [Internet]. Vol. 117, British Journal of Anaesthesia. Oxford University Press; 2016 [cited 2020 Sep 1]. p. i9-13. Available from: [https://academic.oup.com/bja/article/117/suppl\\_1/i9/1744017](https://academic.oup.com/bja/article/117/suppl_1/i9/1744017)

[26] Griesdale DEG, Liu D, McKinney J, Choi PT. Glidescope® video-laryngoscopy versus direct laryngoscopy for endotracheal intubation: A systematic review and meta-analysis. Can J Anesth [Internet]. 2012 Jan 1 [cited 2020 Sep 1];59(1):41-52. Available from: <https://link.springer.com/article/10.1007/s12630-011-9620-5>

[27] Aziz MF, Healy D, Kheterpal S, Fu RF, Dillman D, Brambrink AM.

Routine clinical practice effectiveness of the glidescope in difficult airway management: An analysis of 2,004 glidescope intubations, complications, and failures from two institutions. Anesthesiology [Internet]. 2011 Jan 1 [cited 2020 Sep 1];114(1):34-41. Available from: <http://pubs.asahq.org/anesthesiology/article-pdf/114/1/34/252877/0000542-201101000-00017.pdf>

[28] Mason RA, Fielder CP. The obstructed airway in head and neck surgery. Anaesthesia [Internet]. 1999 Jul 1 [cited 2020 Sep 1];54(7):625-8. Available from: <http://doi.wiley.com/10.1046/j.1365-2044.1999.01036.x>

[29] Iseli TA, Iseli CE, Golden JB, Jones VL, Boudreaux AM, Boyce JR, et al. Outcomes of intubation in difficult airways due to head and neck pathology. Ear, Nose Throat J [Internet]. 2012 Mar 10 [cited 2020 Sep 1];91(3):E1-5. Available from: <http://journals.sagepub.com/doi/10.1177/014556131209100313>

[30] MacMillan, M.H. and Davidson, M. (2020) 'Anaesthesia for endoscopic surgery', Anaesthesia and Intensive Care Medicine. Elsevier Ltd, pp. 205-208. doi: 10.1016/j.mpaic.2020.01.006. 2020

[31] Apfelbaum JL, Hagberg CA, Caplan RA, Connis RT, Nickinovich DG, Benumof JL, et al. Practice guidelines for management of the difficult airway: An updated report by the American Society of Anesthesiologists Task Force on Management of the Difficult Airway [Internet]. Vol. 118, Anesthesiology. American Society of Anesthesiologists; 2013 [cited 2020 Sep 1]. p. 251-70. Available from: <http://links.lww.com/ALN/A902>.

[32] Benjamin B, Lindholm CE. Systematic direct laryngoscopy: The Lindholm laryngoscopes. Ann Otol Rhinol Laryngol [Internet]. 2003 Sep 29 [cited 2020 Sep 1];112(9 I):787-97. Available from: <http://journals.sagepub.com/doi/10.1177/000348940311200908>

- [33] Davies R, Balachandran S. Anterior commissure laryngoscope. *Anaesthesia* [Internet]. 2003 Jul 1 [cited 2020 Sep 1];58(7):721-2. Available from: <http://doi.wiley.com/10.1046/j.1365-2044.2003.327713.x>
- [34] Hillel AT, Pandian V, Mark LJ, Clark J, Miller CR, Haut ER, et al. A novel role for otolaryngologists in the multidisciplinary difficult airway response team. *Laryngoscope* [Internet]. 2015 Mar 1 [cited 2020 Sep 1];125(3):640-4. Available from: <http://doi.wiley.com/10.1002/lary.24949>
- [35] Nekhendzy V, Simmonds PK. Rigid Bronchoscope-Assisted Endotracheal Intubation: Yet Another Use of the Gum Elastic Bougie. *Anesth Analg* [Internet]. 2004 Feb [cited 2020 Sep 1];98(2):545-7. Available from: <http://journals.lww.com/00000539-200402000-00051>
- [36] Nowakowski M, Williams S, Gallant J, Ruel M, Robitaille A. Predictors of Difficult Intubation with the Bonfils Rigid Fiberscope. *Anesth Analg* [Internet]. 2016 Jun 1 [cited 2020 Sep 1];122(6):1901-6. Available from: <http://journals.lww.com/00000539-201606000-00028>
- [37] Corbanese U, Morossi M. The Bonfils intubation fibrescope: clinical evaluation and consideration of the learning curve. *Eur J Anaesthesiol* [Internet]. 2009 Jul [cited 2020 Sep 1];26(7):622-4. Available from: <http://journals.lww.com/00003643-200907000-00018>
- [38] Aziz M, Metz S. Clinical evaluation of the Levitan Optical Stylet\*. *Anaesthesia* [Internet]. 2011 Jul 1 [cited 2020 Sep 1];66(7):579-81. Available from: <http://doi.wiley.com/10.1111/j.1365-2044.2011.06708.x>
- [39] Laurie, A., & Macdonald, J. (2018). Equipment for airway management. *Anaesthesia & Intensive Care Medicine*, 19(8), 389-396
- [40] Sharma D, Kim LJ, Ghodke B. Successful airway management with combined use of glidescope® videolaryngoscope and fiberoptic bronchoscope in a patient with cowden syndrome. *Anesthesiology* [Internet]. 2010 Jul 1 [cited 2020 Sep 1];113(1):253-5. Available from: <http://pubs.asahq.org/anesthesiology/article-pdf/113/1/253/250530/0000542-201007000-00035.pdf>
- [41] Gu J, Xu K, Ning J, Yi B, Lu K. GlideScope-assisted fiberoptic bronchoscope intubation in a patient with severe rheumatoid arthritis. *Acta Anaesthesiol Taiwanica*. 2014 Jun 1;52(2):85-7.
- [42] Vieira FO, Rhodes CB, Smith A, Case CRNA S. Videolaryngoscope Assisted Fiberoptic Bronchoscopy for Difficult Intubation in Upper Airway Cancer. *Res Artic*. 2018;14(3).
- [43] Boyce JR, Peters GE, Carroll WR, Magnuson JS, McCrory A, Boudreaux AM. Preemptive vessel dilator cricothyrotomy aids in the management of upper airway obstruction [Internet]. Vol. 52, *Canadian Journal of Anesthesia. Canadian Anaesthetists' Society*; 2005 [cited 2020 Sep 1]. p. 765-9. Available from: <https://link.springer.com/article/10.1007/BF03016567>
- [44] Patel A, Nouraei SAR. Transnasal Humidified Rapid-Insufflation Ventilatory Exchange (THRIVE): a physiological method of increasing apnoea time in patients with difficult airways. *Anaesthesia* [Internet]. 2015 Mar 1 [cited 2020 Sep 5];70(3):323-9. Available from: <http://doi.wiley.com/10.1111/anae.12923>
- [45] Roberts J, Barrass L, Hunningher A. Arndt airway can contribute to the elective management of difficult airway cases [Internet]. Vol. 107, *British Journal of Anaesthesia. Oxford University Press*; 2011 [cited 2020 Sep 5]. p. 470. Available from: <http://bjanaesthesia.org/article/S000709121733088X/fulltext>

- [46] Ogilvie L. Difficult Airway Society guidelines for the management of tracheal extubation. *Anaesthesia* [Internet]. 2012 Nov 1 [cited 2020 Sep 5];67(11):1277-8. Available from: <http://doi.wiley.com/10.1111/anae.12011>
- [47] Apfelbaum JL, Hagberg CA, Caplan RA, Connis RT, Nickinovich DG, Benumof JL, et al. Practice guidelines for management of the difficult airway: An updated report by the American Society of Anesthesiologists Task Force on Management of the Difficult Airway [Internet]. Vol. 118, *Anesthesiology*. American Society of Anesthesiologists; 2013 [cited 2020 Sep 5]. p. 251-70. Available from: <http://links.lww.com/ALN/A902>.
- [48] Varadarajan V V., Arshad H, Dziegielewski PT. Head and neck free flap reconstruction: What is the appropriate post-operative level of care? *Oral Oncol*. 2017 Dec 1;75:61-6.
- [49] Dinsmore JE. Anaesthetic Considerations for Transoral Robotic Surgery (TORS) [Internet]. 2018 [cited 2020 Sep 5]. Available from: [www.wfsahq.org/resources/anaesthesia-tutorial-of-the-week](http://www.wfsahq.org/resources/anaesthesia-tutorial-of-the-week)
- [50] Chi JJ, Mandel JE, Weinstein GS, O'Malley BW. Anesthetic Considerations for Transoral Robotic Surgery [Internet]. Vol. 28, *Anesthesiology Clinics*. Elsevier; 2010 [cited 2020 Sep 5]. p. 411-22. Available from: <http://www.anesthesiology.theclinics.com/article/S193222751000056X/fulltext>
- [51] Apfelbaum JL, Caplan RA, Connis RT, Ehrenwerth J, Nickinovich DG, Pritchard D, et al. Practice advisory for the prevention and management of operating room fires: An updated report by the American Society of Anesthesiologists Task Force on Operating room fires. *Anesthesiology* [Internet]. 2013 Feb 1 [cited 2020 Sep 5];118(2):271-90. Available from: [http://pubs.asahq.org/anesthesiology/article-pdf/118/2/271/261099/20130200\\_0-00013.pdf](http://pubs.asahq.org/anesthesiology/article-pdf/118/2/271/261099/20130200_0-00013.pdf)
- [52] Pereira CMB, Figueiredo MEL, Carvalho R, Catre D, Assunção JP. Anesthesia and Surgical Microvascular Flaps. Vol. 62, *Revista Brasileira de Anestesiologia*. Elsevier; 2012. p. 563-79.
- [53] De Wever W, Vandecaveye V, Lanciotti S, Verschakelen JA. Multidetector CT-generated virtual bronchoscopy: An illustrated review of the potential clinical indications [Internet]. Vol. 23, *European Respiratory Journal*. European Respiratory Society; 2004 [cited 2020 Sep 22]. p. 776-82. Available from: <https://erj.ersjournals.com/content/23/5/776>
- [54] Ahmad I, Keane O, Muldoon S. Enhancing airway assessment of patients with head and neck pathology using virtual endoscopy. *Indian J Anaesth* [Internet]. 2017 Oct 1 [cited 2020 Sep 22];61(10):782. Available from: <http://www.ijaweb.org/text.asp?2017/61/10/782/216676>
- [55] Fried MP, Moharir VM, Lorensen WE, Shinmoto H, Hsu L, Alyassin AM, et al. Virtual laryngoscopy. *Ann Otol Rhinol Laryngol* [Internet]. 1999 Mar 28 [cited 2020 Sep 22];108(3):221-6. Available from: <http://journals.sagepub.com/doi/10.1177/000348949910800301>
- [56] Ahmad I, Millhoff B, John M, Andi K, Oakley R. Virtual endoscopy - A new assessment tool in difficult airway management. *J Clin Anesth*. 2015 Sep 1;27(6):508-13.
- [57] Wax RS, Christian MD. Practical recommendations for critical care and anesthesiology teams caring for novel coronavirus (2019-nCoV) patients [Internet]. Vol. 67, *Canadian Journal of Anesthesia*. Springer;

2020 [cited 2020 Sep 21]. p. 568-76.  
Available from: <https://doi.org/10.1007/s12630-020-01591-x>

[58] Couloigner V, Schmerber S, Nicollas R, Coste A, Barry B, Makeieff M, et al. COVID-19 and ENT Surgery. *Eur Ann Otorhinolaryngol Head Neck Dis.* 2020 May 1;137(3):161-6.