

We are IntechOpen, the world's leading publisher of Open Access books Built by scientists, for scientists

6,900

Open access books available

186,000

International authors and editors

200M

Downloads

Our authors are among the

154

Countries delivered to

TOP 1%

most cited scientists

12.2%

Contributors from top 500 universities



WEB OF SCIENCE™

Selection of our books indexed in the Book Citation Index
in Web of Science™ Core Collection (BKCI)

Interested in publishing with us?
Contact book.department@intechopen.com

Numbers displayed above are based on latest data collected.
For more information visit www.intechopen.com



Nonresectional-Graded Neo Chordal Dynamic Repair of Mitral Valve: Stress Analysis Induced Surgical Innovation

*Pradeep Kumar Radhakrishnan,
Gayathri Ananyajyothi Ambat, Nihaz Nazer
and Nazer Yoosuf Abdul*

Abstract

Drawbacks persist relating to irreversibility of leaflet resection, time-consuming leaflet reconstruction with sliding annuloplasty, monoleaflet function, and systolic anterior motion (SAM) risk. Graded neochordal reconstruction mitigates many of these but has the challenge of precise sizing and possibility of leaving excessive tissue, risking SAM. When this reconstruction is based on stress analysis and shear analysis methods the outcome gives the best results. Short term evaluation has been done with good outcomes.

Keywords: mitral valve repair, neochordal reconstruction, non resectional repair techniques, systolic anterior movement-SAM, MRI-Magnetic resonance Imaging Stress analysis, IVT –interventricular triangle, mitral regurgitation-MR, 3DECHO-3 dimensional echocardiography

1. Introduction

Evolution of repair techniques of mitral valve has taken a concurrent route along with that of cardiac surgery itself. From the concept of replacement to repair and now from respect rather than resect approach to the current non resectional method has been due to a better understanding of the dynamic nature of the valve. Stress pattern studies that have currently received a boost with technological advancements [1]. While “resection” techniques are associated with good results, reparability rates stood at around 60–70% for the last decade. We are presenting a new technique based on latest stress and dynamic updates on the valve, which would facilitate near to 100% reparability rates in future. All current studies support our view of adopting a completely nonresectional method in mitral valve repair – or the dynamic Indian Correction as we call it.

2. Statistics

Mitral valve repair done via non resectional methods from January 2017 to November 2017 is included. Preoperative analysis included cardiac MRI and 3 D echocardiography. 25 patients who underwent non resectional methods during this period and techniques are discussed. Patients who underwent leaflet resection, LVEF less than 45%, reoperative mitral valve repairs, beating heart repairs or who underwent minimally invasive procedures during this period were excluded from the study. Intraop TEE was used in all cases. Approach to the mitral valve was through the superior septal approach with initial assessment done on beating heart. Repair was fashioned on arrested heart. After analysis of the valve artificial chordae were created with CV5 and CV6 e PTFE sutures (Gore-Tex R, WL Gore and associates Flagstaff AZ). Graded reconstruction with suture thickness simulating natural chordal stress patterns were used. The suture was first placed in the fibrous part of the papillary muscle. Pledgets and suture tie was avoided in the papillary muscle to minimize chances of ischemia, by taking a simple U stitch. The apposition points are marked on the anterior or posterior leaflets so that 1/3rd of the anterior leaflet enters the coapting zone (**Figure 1**). Slight billowing of anterior leaflet should be permitted as it reduces the stress. Initial position of neochordae can be fixed with a clip placed lightly 1.5 mm below the annular plane. Suture goes back through the leaflet edge from the atrial to the ventricular side placing knots on the ventricular side. The leaflet was drawn down into the ventricle so that the prolapse was eliminated and area of good zone of coaptation is ensured- usually 1/3rd. Peak height of coaptation point should be only up to the plane of annulus. Use the annular plane as a guide for fixing the neo chordal length. As many neochordae as deemed necessary is created following the natural line of attachment to papillary muscle. Avoid crossing the midline. Strut chordae are never excised. Repair methods are individualized as deemed necessary to shorten leaflet height of anterior leaflet or straightening of posterior leaflet margin. Plication of annulus at P2 and P3 needs to be done in ischemic lesions involving posterior wall. Pulling together of papillary muscles with Gore Tex sutures are done if more than 2 cm apart. Chordal shortening is avoided. In such cases leaflet folding by transferring tissue from atrial to coaptation zone is done. Coaptation zone along neochordae creation allows maximum coaptation at centre and less towards commissures as in the normal valve. Excess leaflet tissue may require plication. Sub commissural fusion has to be released. Chordal splitting

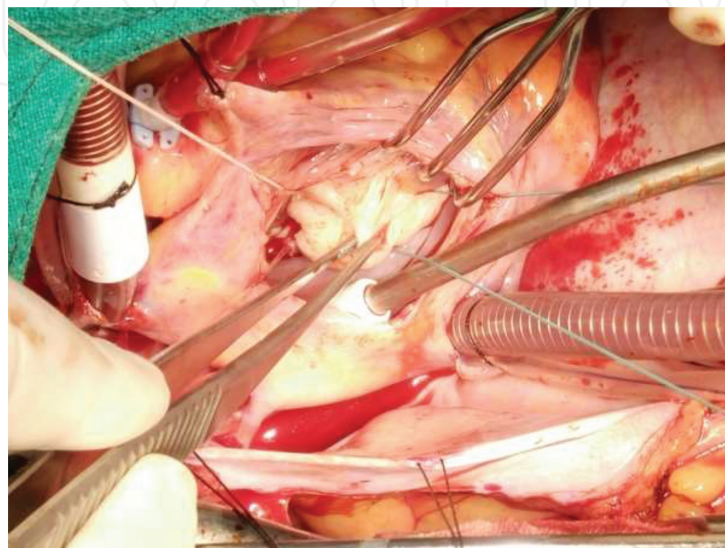


Figure 1.
Mitral valve non resectional graded chordal neoconstruction method.

is done in an individual fashion depending on the pathology. Leaflet thinning and open commissurotomy may be required in rheumatic lesions. Reduction annuloplasty ring is fashioned making allowance for a push up of the ring at the inter-ventricular triangle region of the anterior leaflet to allow for the postero superior movement of the annulus. Keep the posterior leaflet height less than 2 cm. Diastolic and systolic assessment of repair is then done. Post bypass intraop TEE is done to confirm the results. Repair can be assessed in systole in beating heart before atrial septal closure or by simultaneous saline filling of aortic root and left ventricle. No residual mitral regurgitation is accepted. Repair success rate was 100%. No patients underwent mitral valve replacement. All repairs were successful on the first attempt.

3. Methodology

The data was analyzed using SPSS version 13.0 for windows XP. Descriptive statistics for continuous variables are expressed as median or mean as needed while qualitative variables expressed as percentage and $P < 0.05$ being considered significant.

4. Results

Demographic and clinical data was obtained from the hospital records. Mean age was 63 ± 7.7 , 15 were male. All patients were in NYHA class III. 2 patients required tricuspid valve repair and 4 patients needed coronary bypass surgery. Interpapillary distance in patients with inferior wall involvement was 31 ± 3 mm. One patient required LA myxoma removal. Median surgical risk based on Logistic Euroscore was 3.95% (2.38%). Median Total cross clamp time was 74 ± 7 min. Total extracorporeal time being a median of 120 (80 to 146) minutes. 4 neochordae were created in 10, 6 in 12, 2 in 3 patients. 28 sized annuloplasty ring was used in one patient, 30 in 12 patients, 32 in 11 patients and 34 in 1 patient. Mean coaptation height achieved was 8 ± 3 mm. 25 patients had zero MR on post bypass TEE. No patients had SAM. Preoperative annular area was 19.2 ± 4 cm² and post op being 7.7 ± 2 cm² by 3D methods showing a reduction efficiency of 60%. The median ICU stay was 2 days (1–10) days and median total hospital stay was 7 days (5–17) days. One patient had atrial fibrillation which reverted with pharmacological therapy, 1 case of acute renal failure in a patient with chronic renal failure and type 1 neurological dysfunction in one patient. Preop ROA was median 9.10 (6.1–26.4) to post op of 1.10 (0.3–2.1) cm² $P = 0.001$. At follow up of 90 days the median ROA was -0.50 (0.9 cm²) $P = 0.001$. LVEF was median of 63% (30–77) before surgery to 68% (55–80) post op $P = 0.14$. Clinical follow-up was 100%. 25 patients are alive, and all were free of MR signs and symptoms. No patient required reoperation for recurrent MR. Echocardiographic follow-up has been obtained at the discretion of the referring cardiologists. Echocardiograms have been obtained on all patients with a mean follow-up of 1 year. All cause mortality at 30 days, 60 days, 90 days; 1 year after surgery has been zero. No reoperations were needed due to recurrent mitral regurgitation, no new onset atrial fibrillation or embolism or endocarditis was noted. No death, reoperations, heart failure, endocarditis, thromboembolism or pacemaker implantations were needed in any of these patients on follow up until Dec 25th 2017 (median of 9 months). Follow-up was performed till Dec 25 2017 was 100% complete for survival. All patients are currently in NYHA class I.

5. Discussion

Mitral valve has stood the test for evolution and the extreme dynamic nature brings forth a great concept of engineering skills to repair and hold on to this precious tissue. Resection creates extreme stress and should be avoided at all costs. To replace when repair is feasible is a sin with our current understanding and technological evolution. Long term durability and SAM were intriguing concepts which made surgeons adopt technological modifications, but reparability rates remained constant in the last decade in most advanced cardiac centers around the world. The understanding of the intervalvular triangle as an important part of anterior leaflet and the concept of avoiding placing a horizontal stiff ring across it was emphasized by the American correction version of mitral repairs. Mitral valve stress analysis shows at the beginning of systole the marginal chordae carries the maximum stress. Stress increases now on the strut chordae in mid systole with more of leaflet coaptation with entire stress transfer to annulus during late systole with good leaflet coaptation [2, 3]. With annular dilatation stress is evenly distributed to all valvular structures and that is the reason why mitral regurgitation tends to be a progressive disease. Normal valve dynamics ensure optimal diastolic locking, proper zone of coaptation with excellent left ventricular outflow dynamics and smooth leaflet and chordal stress distribution. Of the various geometric, kinetic and structural factors that can lead to SAM, impaired aorto mitral coupling dynamics are most significant. It is important to avoid rigid and undersized rings which not only alter coupling dynamics but reduce the aorto mitral angle [4–7] also that lead to both LV inflow and outflow obstructions. Failures to recognize the interventricular component of anterior leaflet and aortomitral coupling dynamics are important reasons for failure of repair of this segment. Avoid resection and true sized annuloplasty rings that take the interventricular triangle are keys to success. Ischemic mitral regurgitation often with sagging P2 P3 areas require annuloplasty to correct this portion and then bringing the papillary muscles to within 2cm of each other before placing the ring – for which a true sized ring would be most effective. The goals of the Indian method of correction would be explained as follows

1. Eliminate mitral regurgitation
2. Ensure normal leaflet coaptation
3. Restore normal annular dynamics
4. Maintain normal left ventricular outflow dynamics
5. Restore stress ratios to normal thereby enhancing durability of repair.
6. Graded Neochordal reconstruction of the valve chordae for natural stress redistribution

It is an excellent reproducible and safe procedure with 0.2% mortality [8]. Failure with repair techniques is due to leaving behind areas of stress which has to be meticulously avoided by proper assessment and optimal repair [9].

6. Stress analysis

Current state of biomechanical and micro structural characterizations of the chordae tendineae, and shear stress areas are discussed in this with a new Indian

surgical repair technique that takes advantage of this knowledge to repair the valve with better long term outcomes. This almost eliminates chordal failure in repairs making it durable. Customarily, finite element analysis (FEA) is used to predict material stress and strain fields rendered by applying a load on an initially unloaded model. MV leaflets are relatively non deformed during systolic loading. Leaflet strain in vivo is measured using sono micrometry in an ovine model, hybrid models of normal human MVs as constructed using transesophageal real-time 3-D echocardiography (rt-3DE) loaded repeatedly using FEA, and serial rt-3DE images of normal human MVs used to construct models at end diastole and end isovolumic contraction to detect any deformation during isovolumic contraction. Human MV deformed minimally during isovolumic contraction, as measured by the mean absolute difference calculated over the surfaces of both leaflets between serial MV models: 0.53 ± 0.19 mm. FEA modeling of MV models derived from in vivo high-resolution truly 3-D imaging is reasonable and useful for stress prediction in MV pathologies and repairs. Customarily, FEA is used to predict material stress and strain fields rendered by applying a load on an initially unloaded model. In general, the approach has been to use highly idealized and simplistic geometric models to analyze ex vivo or anatomically idealized MVs to assess physiology; to analyze standardized pathological valves to predict stress distribution and, potentially, the integrity and failure behavior of repair techniques; to “evaluate proposed surgical repairs” using idealized computational models, including models that attempt integration of fluid-structure interactions; or to evaluate pathological alterations on the function of idealized computational models. Superimposed tissue formation which is a main determinant of leaflet thickening in MVP, is related to increased stresses over the leaflets.

Chordae can be classified as true or false or as basal, marginal or strut chordae [8–10]. The commissural chordae also is a name that we have added to this as it is slightly thicker and helps to modify the surgical repair technique. Interestingly mitral valve (MV) anterior leaflet chordae are thicker than the MV posterior leaflet chordae [11]. Load or stress bearing is the strut chordae in the normal valve and it shifts to marginal chordae in leaflet prolapse and makes this susceptible to rupture. On an average 25 chordae attached to an atrioventricular valve dissipates off the shear stress of systolic closure. The fact that stress and chordal thickness are linked can be understood by proper analysis of fetal hearts which shows thinner chordae.

Mitral chordae microstructure shows forms of collagen: (i) a mostly straight, dense, collagen fiber core (ii) widely spaced collagen fibers that wrap around the straight collagen fiber core with some angle of alignment on the primary axis. Fiber size and stress are again related. Tricuspid chordae have a greater collagen fiber density and a smaller fiber diameter, as these are subjected only to right heart pressures significantly lower than the right. From out in the arrangement is elastin sheath with fiber orientation at angles to longitudinal axis, straight fibers, undulated collagen fibers with circumferential orientation and a longitudinal structure in the centre. Diseases like myxomatous degeneration affect chordae more than the leaflets increasing its water and glycosaminoglycan contents. Proteoglycans contribute to calcification also. This promotes defective formation of elastin and collagen. In rheumatic involvement the collagen core is affected and fibrosis is an accompaniment.

Chordae even have blood supply and could be vehicles through which nutrient supply also reaches the leaflets. Distinct elastin layer and planar undulated collagen fibers are unique to human species showing some evolutionary advantage even in the micro structural design. Structure and mechanics decide on material properties in nature and emulating them could be the reason for success in surgical approaches to the valve too. Even while studying strut chordae the radial pattern of collagen

fibers is seen for those inserted more anteriorly while circumferential pattern is noted in those inserting closer to annulus. Organized cross networking of collagen is noted at papillary muscle chordal junction also.

The microstructure of artificial chordae should also be looked into. The smooth micro porous structure which reduces thrombogenicity is the cause of calcification and rupture later.

Chordal biomechanics can be evaluated and demonstrated in labs using (i) uniaxial tensile testing; (ii) stress-relaxation testing; (iii) chordae-leaflet insertion region testing; and (iv) in vitro flow loop testing. Chordal ruptured at a strain of 21.4% and a stress of 3.1×10^8 dyne/cm². Tricuspid chordae are less extensible when compared with mitral chordae in uniaxial tensile testing. Aging causes the chordae to become stiffer. Interestingly rupture strains of myxomatous and normal chordae are similar. Here shifting of strain from basal to marginal chordae may be the precipitating factor for chordal rupture.

Strut chordae to have the fastest and greatest relaxation behavior ($49.1 \pm 5.4\%$), followed by the basal chordae ($42.4 \pm 8.3\%$), and then the marginal chordae ($33.2 \pm 4.7\%$). Strut chordae are stiffer than the marginal and basal chordae; (ii) the basal chordae has greater extensibility than the marginal chordae; (iii) the mitral valve chordae were stiffer than their tricuspid valve counterparts; and (iv) the chordae attaching to the tricuspid valve septal leaflet are more extensible than the chordae attaching to the other two tricuspid valve leaflets. Studies using tensile testing devices have shown that marginal chordae ruptures at 68% less load and 28% less strain than the basal chordae. Posterior leaflet chordae of mitral valve ruptures at 43% less load and 22% less strain compared with anterior leaflet chordae. These factors clearly support the graded neochordal reconstruction of the mitral valve retaining the full advantages of the non resectional approach. Marginal chordae have the largest glycosaminoglycan concentrations and the smallest relaxation pattern while the strut chordae had the greatest relaxation pattern, but the lowest glycosaminoglycan content. Biaxial testing shows that the leaflet and papillary muscle insertions have a higher molecular strain than the rest of the chordae. Chordae experienced a strain rate of $75.3 \pm 3.43\%$ during systolic closure and a strain rate of $-54.8 \pm -56.6\%$ during diastolic opening. Constant plateau of the chordal strain between 3.75% and 4.29% during valve closure is also noted in various studies. In this regard the greater compliance of e PTFE chordae could in fact be a surgical advantage [12, 13].

Knowledge is evolving about better understanding and importance of the chordae tendineae of the atrioventricular valves. Morphology and microstructure of the chordae and chordal subsets have been well-defined. There are no standard protocols for investigating chordae mechanics or microstructure as of now, though some investigators like us have ventured out into this area which will help future researchers as time progresses and better evaluation methods are available. Tissue mechanics of MV strut chordae have been well characterized, but future studies are warranted regarding the mechanics of TV chordae. These should be linked to stress analysis and microstructure changes for human chordae. Improved therapy and treatment outcomes with long term effects would result from such studies.

Chordae tendineae are critical to distributing shear stress during systolic movements of leaflets to the papillary muscles, preventing leaflet prolapse and regurgitation. Suboptimal outcomes with repair techniques are due to inability to understand [14–16]. Mechanics and microstructure of the chordae tendineae of these atrioventricular heart valves should be kept in mind and linked to the shear stress analysis on an individual patient basis and surgical repair techniques tailored according to it.

The chordae structures redistribute strain to the papillary muscles during systolic closure and prevent leaflet prolapse. The major stress occurs in the coapting leaflet belly. In the case of chordae failure, such as elongation or chordal rupture with prolapse the shear stress points align along the tips of the leaflets. Uncontrolled regurgitation ends in cardiac failure. Leaflet prolapse secondary to chordal rupture can be triggered by lower ventricular pressures. Major surgical approaches to counter chordal failure include shortening, transposition, and replacement. Shortening has been traditionally described to the superior to transposition in terms of freedom from late significant regurgitation [17]. Vulnerability to rupture is a concern which is overcome with the construction of neochordae. There is still a 13% incidence of recurrent regurgitation with such techniques [18]. Concerns include elongation of the synthetic chordae, rupture of the native chordae, calcification, or recurrent prolapse potentially caused by an elastic modulus higher than that of the native chordae still weigh in the mind of the surgeon [19–22]. Refinement of computational modelling methods and simulation tools may bring forth greater points that could be useful in the modification of surgical techniques and make treatment more individualized [23, 24]. Amalgamation of knowledge of morphology, microstructure and mechanics with material property knowledge of replacement materials will give surgical techniques the much needed support of durability in mitral valve repairs in the years to come [25–27].

7. Conclusion

The Indian Dynamic Correction of mitral valve differs from the French correction that there is no resection of the valve and from American correction in that a complete physio ring is used preserving the aorto mitral dynamics with graded Neochordal reconstruction which would simulate the natural stress redistribution dynamics. This would in future ensure 100% reparability and would increase the percentage of valve repairs in all centres. Stress dynamics enforce the need for proper surgical correction and the fallibility of the developing percutaneous concept in ignoring the aorto mitral dynamics. There is growing evidence showing that the “non-resection” technique has some potential advantages including: (I) preserved leaflet mobility; (II) larger surface of coaptation; (III) no changes in annular geometry; and (IV) implantation of larger prosthetic annuloplasty ring. The leaflet is the most precious part of the valve so preserve it. Mitraclips placed severely damage the valve and placing it has only options of replacing the valve if it fails. Current percutaneous methods fail to relieve the stress ratios and would certainly fail in the long run and surgery would remain the gold standard in future.

This paper was presented at the video Micro-symposium of Indian Association of Cardiothoracic Surgeons Held at Visakhapatnam India from Feb 1-5 -2018.

IntechOpen

Author details

Pradeep Kumar Radhakrishnan^{1*}, Gayathri Ananyajyothi Ambat², Nihaz Nazer³ and Nazer Yoosuf Abdul⁴

1 Chief Division of Cardiothoracic and Vascular Surgery, Programme Coordinator Total Artificial Heart and Mechanical Circulatory Assist, GIMSR GITAM University India, Mentor Biovalley World Innovation Hub, India

2 Medical Student, GIMSR GITAM UNIVERSITY

3 Junior Resident Cardiac Surgery, Travancore Medical College Hospital, Kerala, India

4 Director and Chief Division of Cardiothoracic and Vascular Surgery, Travancore Medical College Hospital, Kerala, India

*Address all correspondence to: rpksai@hotmail.com

IntechOpen

© 2020 The Author(s). Licensee IntechOpen. This chapter is distributed under the terms of the Creative Commons Attribution License (<http://creativecommons.org/licenses/by/3.0>), which permits unrestricted use, distribution, and reproduction in any medium, provided the original work is properly cited. 

References

- [1] Kobayashi J, Sasako Y, Bando K, Minatoya K, Niwaya K, Kitamura S. Ten-year experience of chordal replacement with expanded polytetrafluoroethylene in mitral valve repair. *Circulation*. 2000;**102**(Suppl 3):III30-III34
- [2] Chiappini B, Sanchez A, Noirhomme P, Verhelst R, Rubay J, Poncelet A, et al. Replacement of chordae tendineae with polytetrafluoroethylene (PTFE) sutures in mitral valve repair: early and long-term results. *J Heart Valve Dis*. 2006;**15**:657-663
- [3] Coutinho GF, Carvalho L, Antunes MJ. Acute mitral regurgitation due to ruptured e PTFE neo-chordae. *J Heart Valve Dis*. 2007;**16**:278-281
- [4] Wendy, Tsang Massimiliano, Meineri Rebecca, T. Hahn Federico, Veronesi, Shah Mark, Sandeep Nathan Mark Russo Roberto M. Lang Eric M. Horlick. A three-dimensional Echocardiographic study on aortic-mitral coupling in transcatheter aortic valve replacement. *European Heart Journal - Cardiovascular Imaging*, 2013;10:1: 950-956
- [5] Orszulak, T.A.; Schaff, H.V.; Danielson, G.K.; Piehler, J.M.; Pluth, J.R.; Frye, R.L.; McGoon, D.C.; Elveback, L.R. Mitral regurgitation due to ruptured chordae tendineae: Early and late results of valve repair. *J. Thorac. Cardiovasc. Surg*. 1985, 89, 491-498. [CrossRef]
- [6] Jeresaty, R.M.; Edwards, J.E.; Chawla, S.K. Mitral valve prolapse and ruptured chordae tendineae. *Am. J. Cardiol*. 1985, 55, 138-142. [CrossRef]
- [7] Espino DM, Hukins DW, Shepherd DE, Buchan KG. Mitral valve repair: An in-vitro comparison of the effect of surgical repair on the pressure required to cause mitral valve regurgitation. *J. Heart. Valve Dis*. 2006;**15**:375
- [8] Silver, M.D.; Lam, J.H.C.; Ranganathan, N.; Wigle, E.D. Morphology of the human tricuspid valve. *Circulation* 1971, 43, 333-348. [CrossRef]
- [9] Lomholt M, Nielsen SL, Hansen SB, Andersen NT, Hasenkam JM. Differential tension between secondary and primary mitral chordae in an acute in-vivo porcine model. *J. Heart. Valve Dis*. 2002;**11**:337-345
- [10] Lam, J.H.C.; Ranganathan, N.; Wigle, E.D.; Silver, M.D. Morphology of the human mitral valve: I. Chordae tendineae: A new classification. *Circulation* 1970, 41, 449-458. [CrossRef]
- [11] Zuo, K.; Pham, T.; Li, K.; Martin, C.; He, Z.; Sun, W. Characterization of biomechanical properties of aged human and ovine mitral valve chordae tendineae. *J. Mech. Behav. Biomed. Mater*. 2016, 62, 607-618. [CrossRef]
- [12] Revuelta, J.M.; Garcia-Rinaldi, R.; Gaité, L.; Val, F.; Garijo, F. Generation of chordae tendineae with polytetrafluoroethylene stents: Results of mitral valve chordal replacement in sheep. *J. Thorac. Cardiovasc. Surg*. 1989, 97, 98-103. [CrossRef]
- [13] Gunnal, S.A.; Wabale, R.N.; Farooqui, M.S. Morphological study of chordae tendinae in human cadaveric hearts. *Heart Views* 2015, 16, 1-12. [CrossRef]
- [14] Millington-Sanders, C.; Meir, A.; Lawrence, L.; Stolinski, C. Structure of chordae tendineae in the left ventricle of the human heart. *J. Anat*. 1998, 192, 573-581. [CrossRef] [PubMed]
- [15] De Almeida MTB, Aragao ICSA, Aragao FMSA, Reis FP, Aragao JA. Morphological study on mitral valve chordae tendineae in the hearts of

human fetuses. *Int. J. Anat. Var.* 2019;**12**:17-20

[16] Jett, S.V.; Laurence, D.W.; Kunkel, R.P.; Babu, A.R.; Kramer, K.E.; Baumwart, R.; Towner, R.A.; Wu, Y.; Lee, C.-H. An investigation of the anisotropic mechanical properties and anatomical structure of porcine atrioventricular heart valves. *J. Mech. Behav. Biomed. Mater.* 2018, **87**, 155-171. [CrossRef] [PubMed]

[17] Smedira, N.G.; Selman, R.; Cosgrove, D.M.; McCarthy, P.M.; Lytle, B.W.; Taylor, P.C.; Apperson-Hansen, C.; Stewart, R.W.; Loop, F.D. Repair of anterior leaflet prolapse: Chordal transfer is superior to chordal shortening. *J. Thorac. Cardiovasc. Surg.* 1996, **112**, 287-292. [CrossRef]

[18] Khoiy, K.A.; Asgarian, K.T.; Loth, F.; Amini, R. Dilation of tricuspid valve annulus immediately after rupture of chordae tendineae in ex-vivo porcine hearts. *PLoS ONE* 2018, **13**, e0206744. [CrossRef]

[19] Tabata, M.; Kasegawa, H.; Fukui, T.; Shimizu, A.; Sato, Y.; Takanashi, S. Long-term outcomes of artificial chordal replacement with tourniquet technique in mitral valve repair: A single-center experience of 700 cases. *J. Thorac. Cardiovasc. Surg.* 2014, **148**, 2033-2038.e2031. [CrossRef] [PubMed]

[20] Cochran, R.P.; Kuzelman, K.S. Comparison of viscoelastic properties of suture versus porcine mitral valve chordae tendineae. *J. Card. Surg.* 1991, **6**, 508-513. [CrossRef] [PubMed]

[21] Colli, A.; Manzan, E.; Rucinskas, K.; Janusauskas, V.; Zucchetta, F.; Zakarkaite, D.; Aidietis, A.; Gerosa, G. Acute safety and efficacy of the NeoChord procedure. *Interact. Cardiovasc. Thorac. Surg.* 2015, **20**, 575-581. [CrossRef]

[22] Butany, J.; Collins, M.J.; David, T.E. Ruptured synthetic expanded polytetrafluoroethylene chordae tendinae. *Cardiovasc. Pathol.* 2004, **13**, 182-184. [CrossRef]

[23] Carpentier A, Adams DH, Filsoufi F. Carpentier's Reconstructive Valve Surgery From Valve Analysis to Valve Reconstruction. Philadelphia, PA, USA: Saunders Elsevier Health Sciences; 2011

[24] Phillips, M.R.; Daly, R.C.; Schaff, H.V.; Dearani, J.A.; Mullany, C.J.; Orszulak, T.A. Repair of anterior leaflet mitral valve prolapse: Chordal replacement versus chordal shortening. *Ann. Thorac. Surg.* 2000, **69**, 25-29. [CrossRef]

[25] McQueen, D.M.; Peskin, C.S.; Yellin, E.L. Fluid dynamics of the mitral valve: Physiological aspects of a mathematical model. *Am. J. Physiol. Heart Circ. Physiol.* 1982, **242**, H1095-H1110. [CrossRef]

[26] Lim KH, Yeo JH, Duran C. Three-dimensional asymmetrical modeling of the mitral valve: A finite element study with dynamic boundaries. *J. Heart. Valve Dis.* 2005;**14**:386-392

[27] Wang, Q.; Sun, W. Finite element modeling of mitral valve dynamic deformation using patient-specific multi-slices computed tomography scans.