

# We are IntechOpen, the world's leading publisher of Open Access books Built by scientists, for scientists

6,900

Open access books available

186,000

International authors and editors

200M

Downloads

Our authors are among the

154

Countries delivered to

TOP 1%

most cited scientists

12.2%

Contributors from top 500 universities



WEB OF SCIENCE™

Selection of our books indexed in the Book Citation Index  
in Web of Science™ Core Collection (BKCI)

Interested in publishing with us?  
Contact [book.department@intechopen.com](mailto:book.department@intechopen.com)

Numbers displayed above are based on latest data collected.  
For more information visit [www.intechopen.com](http://www.intechopen.com)



# Congenital Anomalies of the Gastrointestinal Tract

*Richa Verma*

## Abstract

The gastrointestinal system anomalies in the newborn infants are not uncommon and are due to either embryogenesis defects or intrauterine vascular accidents resulting in a compromise of fetal blood circulation to specific system organs. The symptoms generally present within first 1–2 days of life and are mostly referable to intestinal obstruction, manifesting as vomiting, feeding difficulty and distension of abdomen. Other defects may have distinct signs and symptoms and variable time of onset. Some defects may be diagnosed antenatally during prenatal maternal care. The investigations include radiography, magnetic resonance imaging and ultrasound and in a majority of cases clinical presentation and plain radiography may provide adequate diagnostic information. The outcomes of surgical repair are variable and depend upon the original pathological defect. Here, the common anomalies are described with their clinical presentation, surgical repair techniques and outcomes.

**Keywords:** congenital gastrointestinal anomalies, neonates, embryogenesis, surgical repair, intestine, gall bladder, esophagus, colon, liver

## 1. Introduction

Congenital malformations involving the gastrointestinal tract (GIT) can be broadly divided into upper and lower gut abnormalities (**Table 1**). Upper pathology involves the foregut tubes, which are proximal to the ligament of Treitz: the esophagus, stomach, duodenum, pancreas and hepatobiliary tract. Lower GIT anomalies include the mid and hindgut structures: the jejunum and ileum, which constitute the small bowel, the colon and anorectal malformations. Congenital anomalies can further be classified based on whether the defect is structural or functional. Structural anomalies result from either defective embryogenesis or intrauterine complications, such as ischemia. Functional defects have normal anatomy but disrupted flow of GIT contents. In most cases, structural defects adversely impact functional capability. This chapter reviews the clinical presentation, diagnostic work up and surgical management of upper and lower GIT congenital anomalies.

	Anatomic relation	Embryonic source	Blood supply	Viscera
Upper gastrointestinal tract	Proximal to ligament of Treitz	Foregut	Celiac axis	Esophagus Stomach Duodenum Biliary ducts Liver Pancreas
Lower gastrointestinal tract	Distal to ligament of Treitz	Midgut	SMA	Jejunum Ileum Cecum Ascending colon Proximal 2/3 transverse colon
		Hindgut	IMA	Distal 1/3 transverse colon Descending colon Sigmoid colon Rectum Anal canal

*SMA: superior mesenteric artery; IMA: inferior mesenteric artery.*

**Table 1.**  
*Embryologic derivatives of the gastrointestinal tract.*

2. Foregut disorders

2.1 Esophageal atresia (EA) +/- tracheal fistula (TEF)

2.1.1 Embryology

During the fourth week of gestation, the embryonic ventral foregut differentiates into the esophagus and trachea. Muscular and neurovascular development of the esophagus is complete by the end of ninth week of gestation. It is likely that esophageal malformations result from errors during this developmental time period.

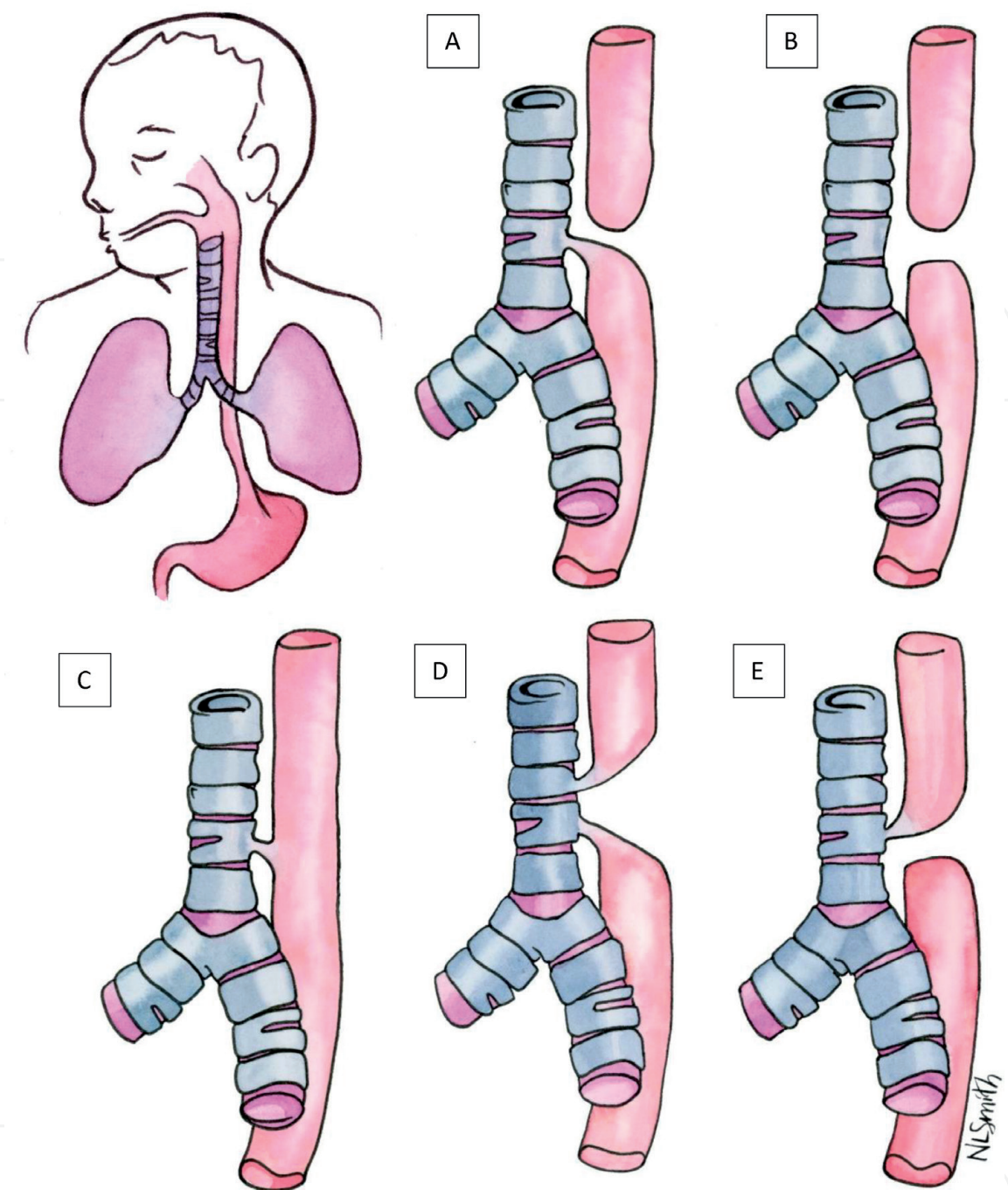
2.1.2 Clinical presentation

EA/TEF is categorized into five types and clinical presentation varies depending on the type of pathology (**Figure 1**). Type A is the most common (90% cases) and consists of proximal EA with a distal TEF. Type B consists solely of proximal EA (no fistula) whereas type C only has a TEF (no atresia). Type D has both a proximal and distal TEF in the setting of atresia. Type E consists of proximal EA with TEF and a distal esophageal pouch. Types D and E are exceedingly rare.

The infant will exhibit drooling and attempts at feeding will result in coughing, choking and regurgitation. Since types B and E have a proximal obstruction without distal fistulization, the infant will have a scaphoid abdomen and gas will not be seen in the bowel distally on radiograph. Type C may present with recurrent aspiration pneumonia and may not be diagnosed until later in life.

2.1.3 Diagnosis

Prenatal ultrasound will demonstrate polyhydramnios and the blind end of the esophageal pouch may be visualized. After birth, unsuccessful attempt at passage



**Figure 1.**  
*Types of tracheoesophageal fistulae depicted as figures A-E.*

of an oro- or nasogastric tube is diagnostic. The tip of the tube will be seen in the esophageal pouch on radiography.

Because of the VACTERL phenomenon (vertebral, anal, cardiac, tracheoesophageal, renal and limb deformities), renal and cardiac ultrasounds as well as plains films of the spine and limbs must be obtained to determine the presence of any other anomalies. An echocardiogram is particularly essential to ensure that the aortic arch is in its normal left-sided anatomic location because this impacts operative planning. Ventricular septal defect is the most common anomaly associated with EA/TEF.

#### *2.1.4 Surgical management*

Ideally, EA/TEF is corrected in a single procedure. Staged procedure, beginning with decompressive gastrostomy and fistula takedown, followed by esophageal

reconstruction at a later date, is reserved for those too unstable to tolerate general anesthesia due to respiratory or cardiac defects. Infants with long gap atresia also undergo delayed repair to allow elongation of the proximal and distal esophageal ends.

In current practice, the minimally invasive approach using video assisted thoracoscopy is preferred to open thoracotomy. If the open approach is employed, a right posterolateral thoracotomy incision is made at the fourth intercostal space, sparing the serratus anterior and latissimus dorsi muscles. Extrapleural dissection is carried until the azygous vein is encountered, which is then divided. In the case of type A, the lower esophageal pouch and its associated fistula are identified. The fistula is resected. The proximal esophageal pouch is then mobilized to establish tension free continuity between the two ends. If a proximal fistula is present, this is ligated prior to mobilization. The esophagus is reconstructed via a single layer end-to-end anastomosis. A chest tube is placed and remains until post-operative esophogram confirms patency of the anastomosis. Anastomotic leaks tend to heal without intervention and are managed by continuation of chest tube and antibiotics.

### *2.1.5 Outcomes*

Thoracoscopic approach has led to improved outcomes and most infants grow to lead fairly normal lives, given the lack of concurrent anomalies such as cardiac defects. Most commonly, gastroesophageal reflux (GER) and esophageal strictures are lifelong issues endured by the patient. GER may be asymptomatic or lead to persistent cough, respiratory problems or esophageal stricturing. Primary management is medical with anti-reflux medications and prokinetics. Surgical correction of GER with fundoplication is last resort. Esophageal strictures may form many years after repair and are best managed by endoscopic dilation. Recurrent or refractory esophageal strictures require surgical resection and re-anastomosis.

## **2.2 Duodenal atresia**

### *2.2.1 Embryology*

It results due to the failure of duodenal recanalization and most commonly occurs in the second portion of the duodenum distal to ampulla of Vater but any segment can be affected.

### *2.2.2 Clinical presentation*

Emesis and feeding intolerance occurs in the first 24–48 h of life. The type of emesis—bilious versus non—depends on the location of atresia relative to the major duodenal papilla. If obstruction is distal to it, infant will exhibit bilious emesis. Obstruction proximal to the ampulla causes non-bilious emesis. Abdomen will not be distended due to proximal nature of obstruction. A palpable mass in the epigastrium may be appreciated on physical exam.

### *2.2.3 Diagnosis*

The “double bubble” on abdominal x-ray indicates air in stomach and duodenum but not in distal small bowel and colon. An UGI series must be obtained to rule out malrotation, which can also present with bilious emesis early in life and is a surgical emergency. UGI may reveal a duodenal web, which is an intraluminal diverticulum that appears as an elongated, conical silhouette resembling a “windsock”. Echocardiogram and renal ultrasound are performed to rule out any other defects as there is an association with trisomy 21 and its related complications.



#### 2.2.4 Surgical management

“The diamond D”, Diamond Duodenoduodenostomy—A transverse incision is made in the proximal widened duodenum and a longitudinal incision in the distal tapered portion of the duodenum (**Figure 2**). The anastomosis is created in a diamond shape to facilitate mucosal abutment between the two incongruent duodenal diameters. During repair, evaluation for duodenal web must be performed because they are not always identified on pre-operative UGI and can cause persistent obstruction if not corrected. If present, a longitudinal duodenotomy is performed over the area of the web and it is excised. Careful attention must be paid to its location relative to the major duodenal papilla so as to not disrupt the integrity of the ampulla of Vater. The duodenotomy is closed in a transverse fashion to avoid narrowing of the lumen.

#### 2.2.5 Outcomes

There tend to be few, if any, long term complications following correction of duodenal atresia. Persistent obstruction may indicate missed duodenal web and requires re-operation. Delayed gastric emptying may occur in the early postoperative period and does not warrant any intervention; most cases resolve with time and enteral feedings can be advanced in small volumes as tolerated.

### 2.3 Pyloric stenosis

#### 2.3.1 Embryology

The exact etiology is unknown. Exposure to erythromycin has been implicated as a risk factor [1].

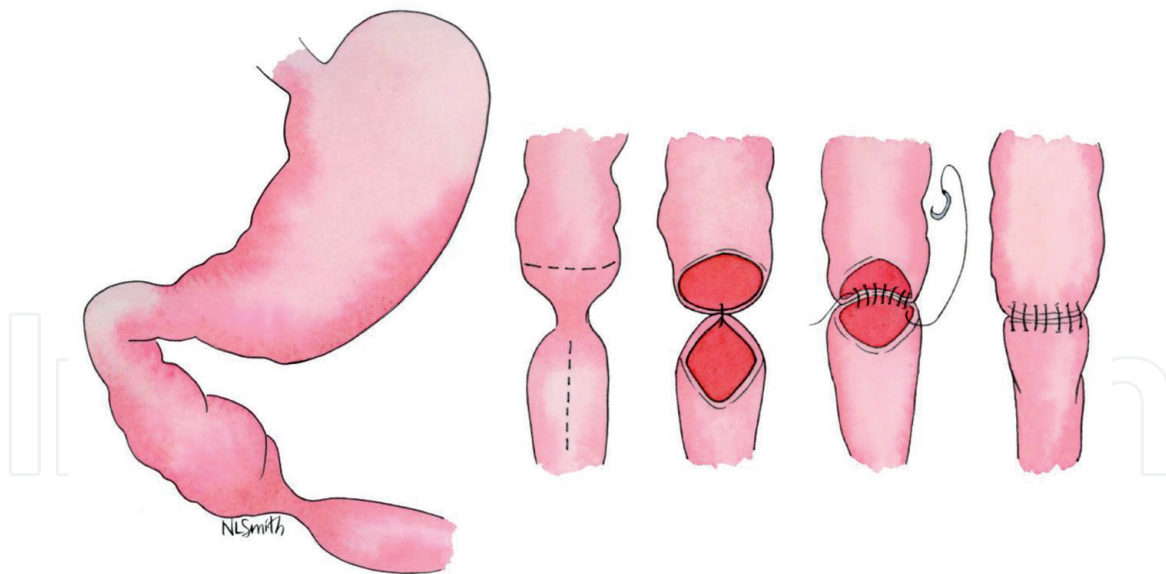
#### 2.3.2 Clinical presentation

It is characterized with feeding intolerance and non-bilious emesis that becomes projectile over time; usually presenting around 2–4 weeks of life, however, may not present up until 6–12 weeks. Emesis is non-bilious because the site of obstruction, the pylorus, is proximal to the ampulla of Vater. It tends to occur in first born Caucasian males.

#### 2.3.3 Diagnosis

On physical exam, may be able to palpate an “olive like” firm, mobile mass in the right upper quadrant or epigastrium, however this is often difficult to appreciate on a restless infant. Abdomen is otherwise soft and non-distended. Ultrasound is diagnostic and demonstrates a pyloric channel length  $\geq 16$  mm, wall  $\geq 4$  mm in thickness.

Repeated vomiting of gastric acid (HCl) leads to hypochloremia, alkalosis and dehydration. Hypovolemia stimulates aldosterone secretion with resultant sodium resorption and potassium secretion. Thus, the infant’s laboratory panel will reveal hypochloremic, hypokalemic metabolic alkalosis. Hydrogen is shifted extracellularly in exchange for potassium to correct the acid–base imbalance, exacerbating hypokalemia. Eventually, worsening hypokalemia stimulates the renal hydrogen-potassium pump to resorb potassium and secrete hydrogen, resulting in acidic urine. This is termed “paradoxical aciduria” because bicarbonate secretion should take precedence in an alkalotic state, but the nephrons prioritize correction of potassium at the expense of hydrogen loss instead.



**Figure 2.**  
*Diamond duodenoduodenostomy for duodenal atresia repair.*

#### *2.3.4 Surgical management*

Pyloric stenosis is not a surgical emergency and operative intervention is deferred until electrolytes have normalized, ideally, chloride  $>95$ , bicarbonate  $<30$ . As the primary metabolic derangements are caused by volume and gastric juice loss, resuscitation should be initiated with 10-20 cc/kg normal saline boluses. Once volume status has been adequately restored and urine output robust, potassium containing fluids (D5 1/2NS + 10 K/L) are administered at maintenance rate.

The Ramstedt pyloromyotomy was historically carried out through a right sub-costal transverse incision however the laparoscopic approach is becoming preferred in current practice. A longitudinal incision along the anterior surface of the pylorus is carried down through the serosa and hypertrophied muscle until the submucosa protrudes, much like slicing the tough outer skin of a grape until the smooth inner flesh is encountered. The length of the myotomy extends from the antrum of the stomach proximally to the pyloric vein of Mayo distally, which designates the junction of the pylorus and proximal duodenum. Oral feeding may be initiated 6–8 h post-operatively and advanced as tolerated.

#### *2.3.5 Outcomes*

Long term results from pyloromyotomy are excellent and few infants, if any, have residual complications. Incomplete myotomy can present with persistent feeding intolerance in the peri-operative period and requires re-operation.

### **2.4 Biliary atresia**

#### *2.4.1 Embryology*

The pathophysiology is unknown. Between 4 and 10 weeks of gestation, the extrahepatic biliary tract develops from the hepatic diverticulum. This occurs normally. In the post-natal period, there appears to be an inflammatory process that causes fibrosis of the extrahepatic biliary ducts [2].

#### *2.4.2 Clinical presentation*

Worsening jaundice unamenable to phototherapy during the first 2 weeks of life, subsequently demonstrating unrelenting direct hyperbilirubinemia are characteristic. Laboratory values are consistent with biliary obstruction and demonstrate direct hyperbilirubinemia and elevated alkaline phosphatase. Signs of cholestasis, dark urine and light or gray colored stools are present.

#### *2.4.3 Diagnosis*

Hepatobiliary technetium-99 iminodiacetic acid scan (99-Tc IDA) has highest sensitivity and specificity [2]. Normally, the radiotracer is taken up by hepatocytes and readily excreted into the intestines via the biliary ducts. In biliary atresia, technetium will be taken up by the liver normally, but obstruction of the extrahepatic ducts prevents outflow of radiotracer into the duodenum. Abdominal ultrasound may reveal a small or obliterated gallbladder. Magnetic resonance cholangiopancreatography (MRCP) is also helpful in ruling out intrahepatic atresia or choledocal cysts.

#### *2.4.4 Surgical management*

Expeditious operative intervention is imperative as liver damage can be attenuated, even reversed, and chance of survival improved with early biliary decompression. Beyond 3–4 months, irreversible liver damage may preclude successful outcome. The Kasai portoenterostomy is the procedure of choice. First, an intraoperative cholangiogram is performed to delineate the anatomy of the biliary tree and confirm the diagnosis. A liver biopsy is obtained to document degree of liver damage. Next, the fibrotic common bile duct is dissected from the hepatoduodenal ligament up to the level of the porta hepatis and excised. An approximately 20 cm limb of jejunum is brought up in a retrocolic fashion and a Roux-en-Y hepaticojejunostomy is created.

#### *2.4.5 Outcomes*

Successful, long term establishment of bile flow correlates with earlier surgical intervention. Infants aged <60 days at time of surgery have best results. Approximately one-third of children undergoing portoenterostomy have a 10-year or greater survival, while the rest will ultimately succumb to liver failure and require transplant. Other indications for liver transplant include presence of intrahepatic atresia, fat soluble vitamin deficiencies causing failure to thrive and variceal bleeding secondary to portal hypertension. 5-year survival following liver transplant ranges from 75 to 95% [2].

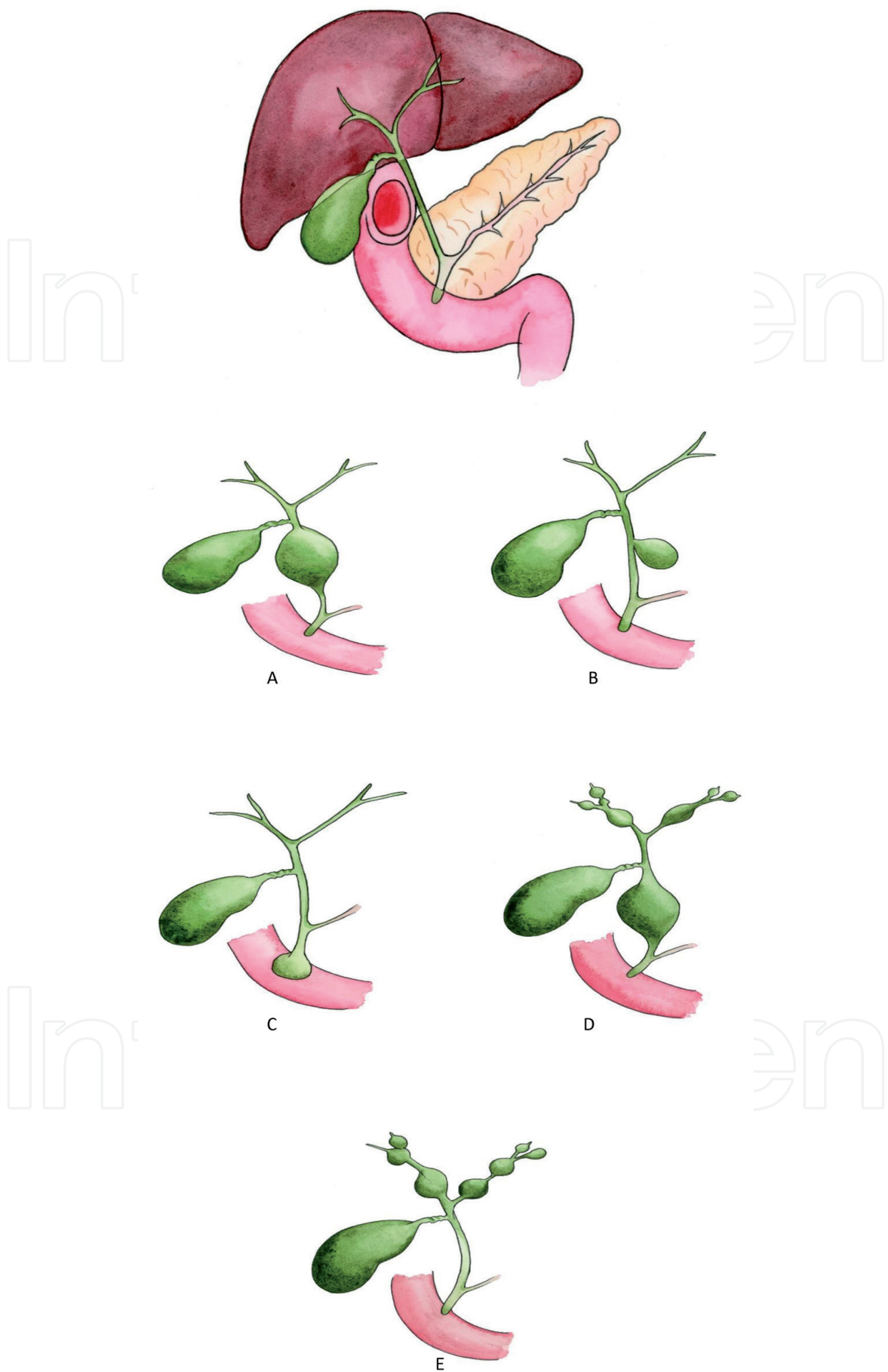
Apart from progressive liver failure, cholangitis is another major post-operative complication occurring in as much as 50% of patients who undergo portoenterostomy [2]. Decreased bile flow indicated by elevated total bilirubin in the setting of fever and leukocytosis is essentially diagnostic of cholangitis until proven otherwise. It is managed with IV antibiotics and fluid resuscitation.

### **2.5 Choledochal cysts**

#### *2.5.1 Embryology*

Etiology is unknown. Aberrant pancreaticobiliary junction near the duodenal wall has been suggested [3].





**Figure 3.** Normal anatomy of the hepatobiliary tree and its relationship to the pancreas and duodenum. (A) Choledocal cyst type 1: fusiform dilation of the extrahepatic duct common bile duct. (B) Choledocal cyst type 2: isolated diverticulum off the common bile duct. (C) Choledocal cyst type 3: supraduodenal choledocoele. (D) Choledocal cyst type 4: cystic dilation of intra- and extra-hepatic bile ducts. (E) Choledocal cyst type 5, dilation of intra-hepatic ducts only.

### 2.5.2 Clinical presentation

Infants present with symptoms of biliary obstruction: progressive jaundice, dark urine, light colored stools. A tender abdominal mass may be palpated in the right upper quadrant. Laboratory values will be consistent with biliary obstruction and demonstrate elevated direct bilirubin and alkaline phosphatase. Patients may also present with cholangitis or pancreatitis.

### 2.5.3 Diagnosis

While abdominal ultrasound and hepatobiliary 99-Tc IDA scan are useful, MRCP best delineates the anatomy of the biliary tree and is the diagnostic test of choice. There are five types (**Figure 3**). Type 1 is the most common and presents as saccular or fusiform dilation of the common bile duct (CBD; **Figure 3A**). Intrahepatic ducts are normal. Type 2 is an isolated CBD diverticulum (**Figure 3B**). Type 3 is a choledochoceles, in which there is cystic dilation of the supra-duodenal CBD, prior to its junction with the pancreatic duct (**Figure 3C**). In type 4 disease, intra- and extra-hepatic bile ducts are dilated whereas in type 5 disease only intra-hepatic ducts are dilated (**Figures 3D, E**).

### 2.5.4 Surgical management

Given the risk of cholangiocarcinoma, highest in types I and IV, surgical intervention is indicated at the time of diagnosis of any type of choledochal cyst. The approach depends on type of lesion. For type 1 cysts, primary cyst excision with cholecystectomy and roux-en-Y hepaticojejunostomy reconstruction is procedure of choice. Type 2 disease is managed by simple diverticulectomy. Type 3 is managed by transduodenal cyst excision or marsupialization and sphincteroplasty. Types 4 and 5 may be treated by anatomic hepatic resection based on the extent and location of disease, however, liver transplantation is ultimately required in most cases.

### 2.5.5 Outcomes

Excision of choledochal cysts result in excellent long-term outcomes with few major complications. Biliary tract malignancy, the most feared complication, may occur with incomplete excision. Cholangitis, stricture formation and choledocolithiasis are lesser significant complications that are managed medically and endoscopically, respectively.

## 3. Midgut disorders

### 3.1 Small intestine atresia

#### 3.1.1 Embryology

Midgut development begins around the fifth week of gestation. The midgut starts as a vertical tube and has two connections: a ventral connection to the yolk sac via the omphalomesenteric (vitelline) duct and a dorsal attachment to the posterior abdominal wall, the mesentery [4–6]. The dorsal mesentery is the conduit for the superior mesenteric artery (SMA), which buds from the aorta, and delivers blood to the midgut. The lengthening gut tube outgrows the confines of the abdominal cavity and consequently herniates into the umbilical cord. As it elongates, it rotates

90° in a clockwise direction relative to the embryo (counterclockwise if visualized from the front). The midgut tube continues to grow extra-abdominally during gestational weeks 6–10. Around week 10, it retracts back into the abdominal cavity, rotating another 180° while doing so. Final intra-abdominal growth and fixation ensue, placing the cecum in the right lower quadrant and the duodeno-jejunal junction to the left of the upper midline, inferior to the SMA. The mesentery broadens, fanning out from its root in the posterior abdominal wall, to support the blood vessels and lymphatics that serve the jejunum, ileum, cecum/appendix, ascending colon and proximal 2/3 of the transverse colon. It is believed that ischemic events during this period cause jejunoileal atresia.

### *3.1.2 Clinical presentation*

Atresia causes a structural obstruction that prevents passage of meconium in the first 24–48 h of life and results in bilious emesis. On physical exam, the abdomen will be distended.

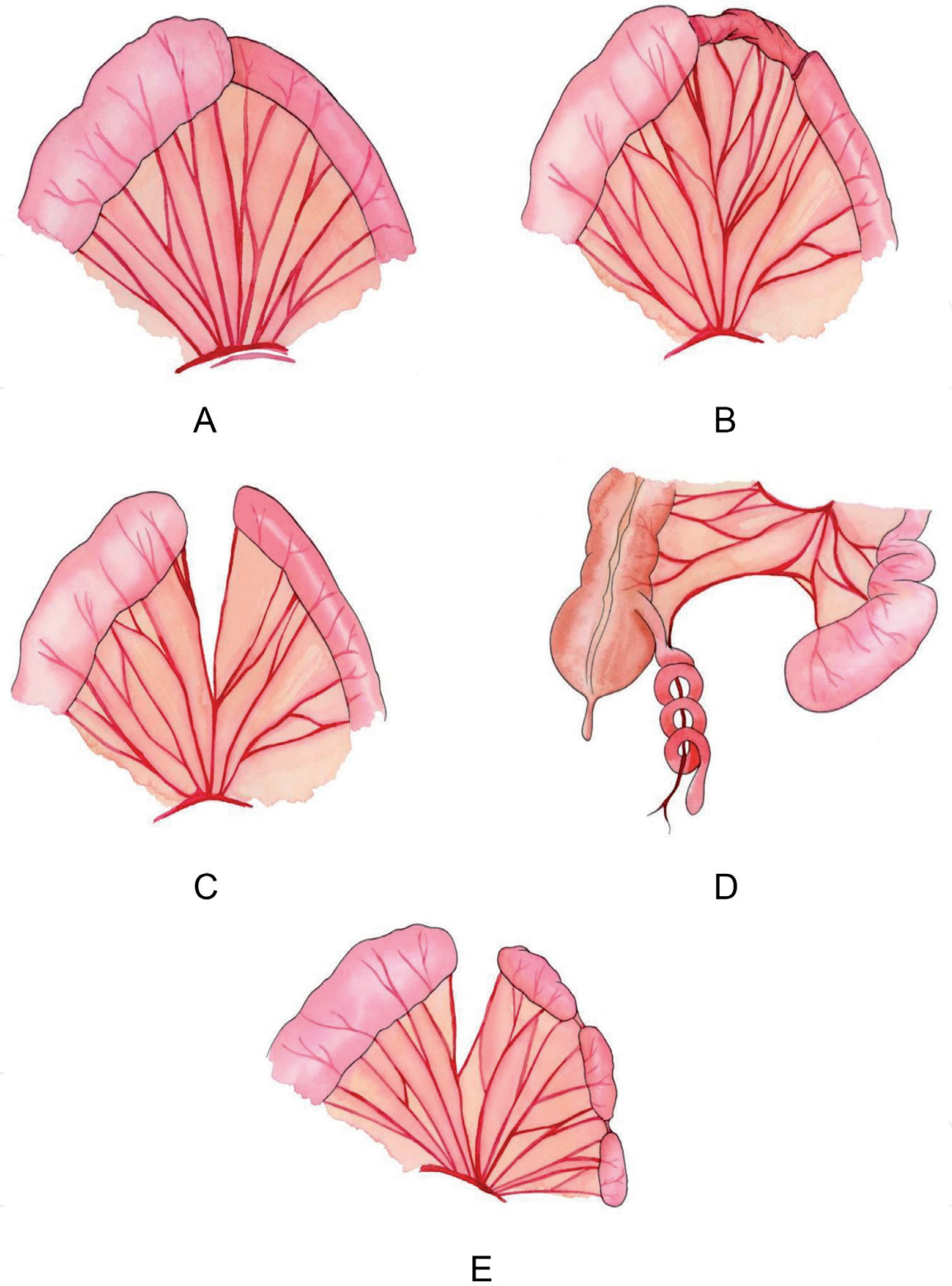
Jejunoileal atresia is classified into four types (**Figures 4A–E**). Type 1 is an intraluminal web with intact mesentery (**Figure 4A**). The seromuscular layers of bowel remain in continuity. Type 2 also has an intact mesentery, but the two ends of bowel are disconnected by a fibrous cord (**Figure 4B**). Type 3a has a small v-shaped mesenteric defect that separates two blind ends of bowel (**Figure 4C**). In type 3b disease, known as an “apple-peel” or “Christmas-tree” deformity, a large mesenteric defect separates the proximal and distal ends of bowel. The proximal pouch is very dilated, and the distal collapsed bowel is supplied by a small vessel around which it repeatedly winds (**Figure 4D**). Type 4 consists of numerous blind ended segments of bowel with discontinuous mesentery, appearing as a “string of sausages” (**Figure 4E**).

### *3.1.3 Diagnosis*

Abdominal x-ray will reveal dilated portions of bowel proximal to the site of obstruction with collapsed loops and paucity of air in the distal bowel. Contrast enema will demonstrate an abrupt transition from the filling to non-filling segments of small bowel and the colon will appear small, <1 cm diameter, due to lack of use. In all cases of bilious emesis, an UGI series is warranted to rule out malrotation, a surgical emergency. UGI will reveal contrast filling in the stomach and proximal bowel, with abrupt cessation of contrast filling at the point of atresia.

### *3.1.4 Surgical management*

Initial management begins with insertion of an oro- or nasogastric tube for bowel decompression and fluid resuscitation. Resection of atretic segments with end-to-end anastomoses is the procedure of choice; however, this can prove quite difficult in cases where ends of bowel are greatly mismatched in diameter. In such circumstances, the anastomosis is created in a fashion similar to duodenoduodenostomy in which the smaller end of bowel is incised longitudinally along its anti-mesenteric border to fit the end of the larger caliber bowel. Prior to completing the anastomosis, the entire length of the bowel must be inspected to ensure there are no intraluminal webs or fenestrations that may cause persistent obstruction. The goal is to resect all defunct bowel segments while maintaining enough length to ensure adequate absorptive capacity. If the ileocecal valve is spared, enteral nutrition can be tolerated with as little as 15–20 cm of small bowel. Otherwise, a length



**Figure 4.** (A) Type 1 jejunoileal atresia. (B) Type 2 jejunoileal atresia. (C) Type 3a jejunoileal atresia. (D) Type 3b jejunoileal atresia. (E) Type 4 jejunoileal atresia.

of approximately 40 cm is required [4]. Mesenteric defects are closed, taking care not to disrupt the feeding blood vessels.

### 3.1.5 Outcomes

Intestinal dysmotility, even in infants that have adequate remaining bowel length, may occur for many weeks following repair. Infants with short bowel



syndrome, those with less than 40 cm, often require long term parenteral nutrition, which itself carries risks of sepsis and liver damage. Nonetheless, overall mortality is low and related to co-morbidities, such as low birth weight and/or cardiac defects.

### **3.2 Malrotation and midgut volvulus**

#### *3.2.1 Embryology*

As described above, normal 270° rotation and fixation of the midgut fails to occur [4–7]. This lack of rotation positions the duodenum and small bowel to the right of the midline and the large bowel to the left. The cecum remains anterior to the duodenum and is tethered to the abdominal wall by lateral peritoneal attachments. These lateral peritoneal attachments, known as Ladd's bands, compress the duodenum, thereby causing obstruction and resultant bilious emesis. The root of the mesentery is narrowed and may potentially act as fulcrum around which the bowel can twist ("volvulize"), thereby kinking the SMA and causing ischemia (**Figure 5**).

#### *3.2.2 Clinical presentation*

Acute malrotation with midgut volvulus presents with feeding intolerance and bilious emesis, usually around the first week of life. Abdominal rigidity, overlying erythema are signs of peritonitis and indicate ischemic bowel. Abdominal distention will not be present given the very proximal nature of pathology. As feeding intolerance and bilious emesis are symptoms of multiple pathologies, a high index of suspicion is required to make this diagnosis.

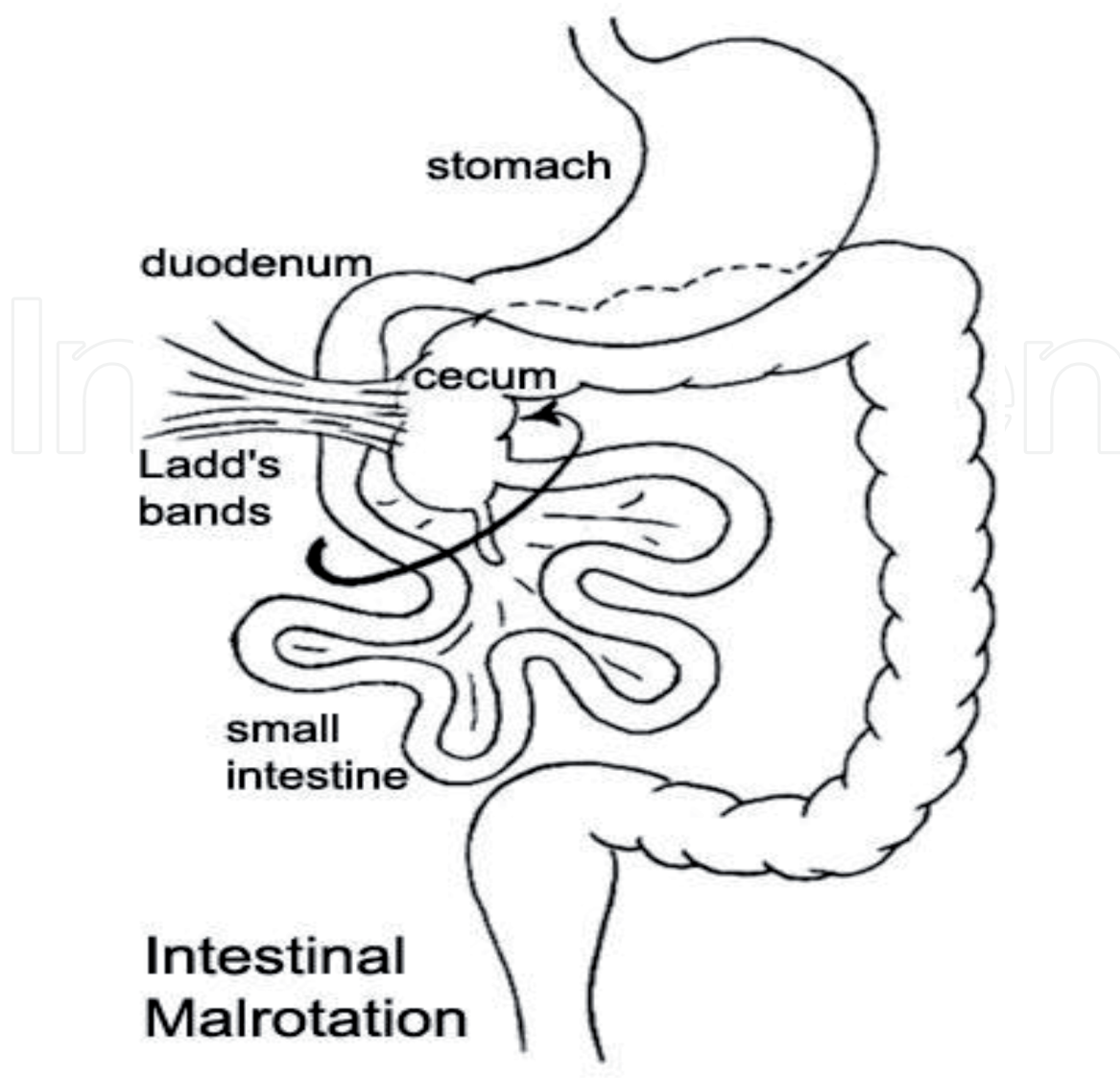
#### *3.2.3 Diagnosis*

An abdominal X-ray is typically first obtained, though rarely helpful in establishing the diagnosis. Any concern for malrotation mandates a prompt UGI. A normal study will reveal contrast exiting the pylorus, descending through the second portion of the duodenum and crossing the midline through the third portion of the duodenum into the small bowel. Thus, a normal "C-loop" will be visualized. An abnormal study will demonstrate contrast exiting the pylorus and descending straight down to the right of the midline into the small bowel.

#### *3.2.4 Surgical management*

Once the diagnosis of acute malrotation is made, the patient is taken emergently to the operating room for detorsion and evaluation of bowel viability. Fluid resuscitation, insertion of oro- or nasogastric tube for decompression and administration of intravenous antibiotics have ideally been implemented prior to surgical intervention. The bowel is eviscerated and detorsed in a counterclockwise direction, fanning out its mesentery. Ladd's bands are incised to release the obstruction. Any frankly necrotic appearing bowel is resected, while dusky bowel can be re-evaluated and usually salvaged in a second look operation 24–48 h later. Ends of healthy, viable bowel can be anastomosed, otherwise stomas are placed. A prophylactic appendectomy is performed to eliminate the possibility of appendicitis in the future. If a second look operation is required, the abdomen is left open and covered with a temporary sterile dressing; if not, it is closed.





**Figure 5.**  
*Intestinal malrotation showing abnormal position of cecum and Ladd's bands*

### 3.2.5 Outcomes

Without significant intestinal necrosis requiring resection, outcomes following correction of malrotation are quite favorable. Infants grow normally and do not have any major adverse sequelae. Rarely, adhesive small bowel obstruction may occur years later, however any operation carries this risk.

## 3.3 Meckel's diverticulum

### 3.3.1 Embryology

This condition occurs as a result of the failure of the omphalomesenteric (vitelline) duct to completely involute between weeks 5–7 of gestation (**Figure 6**).

### 3.3.2 Clinical presentation

Meckel's diverticulum is the most common congenital GIT malformation and the most common cause of painless lower intestinal bleeding in children. It usually presents by the age of 2 years, but presentation can be delayed into the teenage

years. There is a male predominance. The bleeding is typically brisk and bright red. Laboratory values will demonstrate anemia. A fibrous cord connecting the diverticulum to the abdominal wall may be present and can act as a point around which bowel can obstruct, twist or intussuscept. In such cases, the child will present with abdominal pain and distention, inability to pass flatus or move their bowels.

### *3.3.3 Diagnosis*

Technetium-99 pertechnate scintigraphy (“Meckel’s scan”) localizes the bleeding ulcer. The diverticulum is typically found within 2 feet proximal to the ileocecal valve, on the anti-mesenteric side of the ileum and contains heterotopic mucosa, usually that of gastric or pancreatic in origin. Ulceration and bleeding occur secondary to acid secretion from the heterotopic mucosa. It is a true diverticulum involving all four layers of the bowel.

### *3.3.4 Surgical management*

If bleeding is the presenting symptom, ileal resection with primary anastomosis is the procedure of choice. Segmental resection is also indicated in cases complicated by diverticulitis, perforation, obstruction, volvulus or if the base of the diverticulum is very wide. Simple diverticulectomy may be performed if the neck of the diverticulum is narrow, or if diverticulitis does not involve the base.

### *3.3.5 Outcomes*

Resection of Meckel’s diverticulum has an excellent prognosis without major long term post-operative complications.

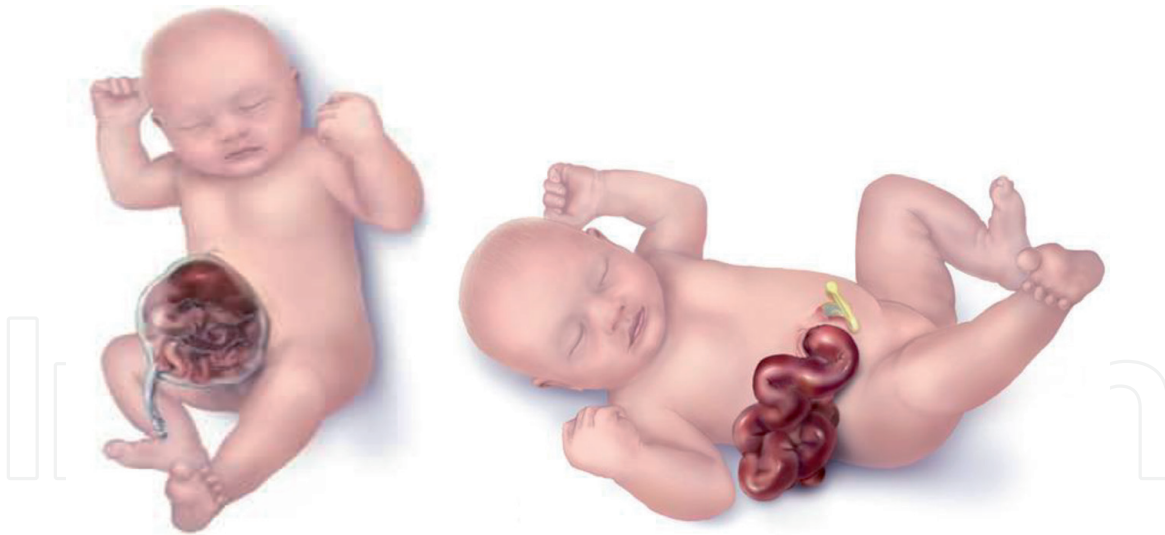## **3.4 Omphalocele and gastroschisis**

### *3.4.1 Embryology*

These are congenital defects of the abdominal wall, not of the gastrointestinal tract itself, but are discussed because they are associated with malrotation (Figure 6).

### *3.4.2 Clinical presentation*

Numerous physical characteristics differentiate omphalocele from gastroschisis. The abdominal wall defect in omphalocele is midline, versus to the right of the umbilicus in gastroschisis. Defects tend to be smaller in gastroschisis, typically  $\leq 3$  cm. In comparison, omphaloceles can vary widely in diameter, ranging in size from 2 to 15 cm. Larger defects allow for herniation of more organs, namely the liver and spleen. This rarely, if at all, occurs in gastroschisis. Herniated contents are covered by an amniotic sac in omphalocele but not in gastroschisis. Exposure of the bowel to amniotic fluid during gestation causes the bowel to become thickened and the mesentery fibrotic whereas bowel is normal in omphalocele since it is protected by the overlying sac. Lastly, omphalocele has a higher association with chromosomal abnormalities and other congenital anomalies compared gastroschisis. Intestinal atresia may be seen in gastroschisis.



**Figure 6.** *Omphalocele (left) and gastroschisis (right). The herniated intestine is covered with a sac with umbilical cord attached to it in omphalocele, while the intestinal loops in gastroschisis herniate through a defect on the right side of umbilicus and are not covered.*

### 3.4.3 Diagnosis

These defects may be appreciated on pre-natal ultrasound and are therefore expected upon delivery. Chest radiography, echocardiogram and renal ultrasound are performed to rule out associated anomalies in the case of omphalocele, as is karyotyping though this may have been performed prenatally.

### 3.4.4 Surgical management

Exposure of intestinal contents to the environment can result in significant insensible losses. Initial management aims to maintain adequate volume status and body temperature. The infant is placed under a warmer, fluid resuscitation commenced, and urinary catheter inserted to strictly monitor volume status. Oro- or naso-gastric tube is placed for bowel decompression. Intestinal contents are wrapped in a moist, sterile plastic dressing to prevent evaporative losses. In the case of omphalocele, care must be taken to prevent rupture of the protective sac. The goals of operation are to return the herniated contents into the abdominal cavity and close the defect. If this is unable to be accomplished either because the infant is too unstable to be taken to the operating room or because there is high risk of abdominal compartment syndrome, a silo can be sutured in place over the herniated viscera and contents gradually reduced. Daily manual reduction can be performed bedside, gently as tolerated, with complete reduction usually achieved over 3–7 days. The resultant ventral hernia is repaired once all viscera have been reduced and the infant deemed fit to tolerate general anesthesia.

### 3.4.5 Outcomes

Given the protective nature of the overlying sac in omphalocele, infants typically have normal bowel function following reduction and abdominal wall repair. Long term complications are related to concomitant congenital defects. In contrast, patients with gastroschisis, especially if they also have intestinal atresia, are subject to dysmotility, malabsorption and are at increased risk of developing

necrotizing enterocolitis. These infants often require long term parenteral nutrition following surgical correction.

## **4. Hindgut disorders**

### **4.1 Hirschprung's disease**

#### *4.1.1 Embryology*

Aganglionosis of the myenteric plexus due to failure of neural crest cell migration during weeks 6–12 of embryonic development. Most often occurs in the rectum though any portion and, rarely, the entire bowel can be affected. The myenteric plexus lies in between the outer longitudinal and inner circular muscle layers of the colon and is responsible for peristalsis.

#### *4.1.2 Clinical presentation*

Aganglionosis results in a functional obstruction manifesting as failure to pass meconium within first 24 h of life. Abdominal distention may be present. Rectal stimulation causes explosive passage of air and stool. Because disease is distal, infant will likely be able to tolerate oral intake though may have intermittent episodes of bilious emesis. Less severe disease may not manifest until later in childhood, up to 2–3 years of age, with chronic constipation. There is an association with trisomy 21. Therefore, work up includes echocardiogram to rule out concomitant cardiac defects.

#### *4.1.3 Diagnosis*

Gold standard is suction rectal biopsy, which demonstrates aganglionosis of the myenteric plexus. Biopsy should be obtained 1–1.5 cm proximal from the dentate line to ensure rectal specimen is obtained. Pathology will reveal unmyelinated nerve fibers with hypertrophied endings that stain darkly with acetylcholinesterase. Abdominal X-ray shows dilated proximal bowel with collapsed distal colon. Contrast enema is helpful in distinguishing transition zone between affected and normal colon however, gross anatomic distinction does not always correlate with histopathology [8].

#### *4.1.4 Surgical management*

Although various operative methods have been described, the fundamental principle of each procedure is the same: to establish continuity between the normal, ganglionic segments of bowel. In the past, multi-stage operations beginning with decompressive colostomy followed by definitive repair was common. Nowadays, single-stage laparoscopic approach is preferred. Regardless of procedure, however, intra-operative frozen section must be performed to confirm the presence of normal ganglionic colon prior to anastomosis, otherwise dysfunction will continue post-operatively.

##### *4.1.4.1 Swenson-original procedure*

The rectum/aganglionic segment is dissected circumferentially, everted through the anus and resected. Normal colon is pulled down and a low end-to-end colorectal anastomosis is created.



#### *4.1.4.2 Duhamel procedure*

The aganglionic portion of bowel is bypassed and a posterior end to side anastomosis is created between the innervated segments of colon and distal rectum. The rectum is stapled at the proximal margin of disease. An incision is made in the distal posterior wall of the rectal stump approximately 1 cm superior to the dentate line. The innervated colon is pulled down through the presacral space and then anastomosed in an end-to-side fashion to the distal posterior rectal wall. The defunct rectal stump is left in place.

#### *4.1.4.3 Soave procedure*

Circumferential endorectal dissection of rectal mucosa and submucosa, followed by evagination of these layers through the anus for resection. A rectal muscular channel remains, and innervated colon is intussuscepted through the remaining rectal muscular channel. A colorectal anastomosis is performed at the distal end of the muscular channel [9].

#### *4.1.5 Outcomes*

No single procedure has been shown to be superior to other in terms of long-term outcomes, and up to 90% patients will have relatively normal bowel function following repair. Although results tend to be quite favorable, one significant cause of significant morbidity and mortality is Hirschsprung's enterocolitis. While the exact etiology of this entity is unknown, bacterial overgrowth and translocation appear to be implicated. Patients present with fever, abdominal distention and diarrhea. Management consists of fluid resuscitation, IV antibiotics and rectal irrigation. Refractory cases require surgical decompression with a proximal ostomy. Other complications such as anastomotic leak, stricture, abscess, wound infection and obstruction occur in up to 10% cases [1].

### **4.2 Anorectal malformation/imperforate anus**

#### *4.2.1 Embryology*

During the 5th week of gestation, the midline urorectal septum descends in a caudal direction toward the cloaca and divides into ventral and dorsal portions. The ventral bud becomes the urogenital sinus, which develops into the urethra and bladder. The dorsal bud becomes the rectum and anal membrane. The anal membrane involutes around week 8, thereby forming the anus. Dysgenesis can occur at any time point, allowing for variability in clinical presentation.

An anatomical distinction based on the pathology's relation to the levator ani muscle complex was first described by Pena. The levator ani complex supports the pelvic floor and is composed of three striated muscles: the puborectalis, the pubococcygeus and the iliococcygeus. The puborectalis encircles the base of the rectum, helps to form the external anal sphincter and thereby plays an integral role in regulating defecation. Anorectal dysgenesis above the levator ani muscles is considered a "high" lesion. Conversely, lesions inferior to the levator ani complex are termed "low" malformations. Generally speaking, higher malformations tend to cause more severe issues with controlling defecation as the neuromuscular development between the levator ani complex and growing recto-anus is compromised to a greater degree.



#### *4.2.2 Clinical presentation*

Failure to pass meconium in the first 24–48 h of life. Physical exam will reveal abdominal distention and absence of anus. A subtle opening in the perineum through which small amounts of meconium pass may be present and indicates an anoperineal fistula in the setting of a low imperforate anus. This is the most common pathology seen. In females, low lesions may also be associated with a rectovestibular fistula, and meconium may be expressed through the vagina. Elimination of meconium during urination indicates rectourethral or rectovesicular fistula and a high rectal pouch.

#### *4.2.3 Diagnosis*

Diagnosis is made upon physical examination of the perineum. Historically, an invertogram was performed to evaluate the length of atresia. In this study, a radiopaque marker is placed on the infant's bottom, where the anus would normally be located, and the infant is placed in a head down position to allow air to ascend at the most inferior point in the rectum. Lateral films of the pelvis are then obtained. The distance between the marker and distal rectum indicate the level of pathology—high vs. low. Now, ultrasound is preferred.

Anorectal malformations are part of the VACTERL syndrome and most commonly associated with concomitant genitourinary defects. In addition to a renal ultrasound, a voiding cystourethrogram should be obtained, especially if a rectourethral/rectovesicular fistula is suspected as this can help delineate the tract. Plains films of the chest, limbs and spine as well as an echocardiogram help identify the presence of other anomalies. Any other life-threatening co-morbidities take precedence, and a temporary diverting ostomy can be placed until definitive repair can be safely performed, usually between 8 and 12 months of age.

#### *4.2.4 Surgical management*

Posterior sagittal anorectoplasty (PSARP) is the surgical procedure performed. The infant is placed in a prone jack-knife position. If a perineal fistula is present, an incision is made around the fistula and carried posteriorly toward the coccyx. If no perineal fistula is present, the incision starts inferior to the coccyx and is carried down to the perineum. It is imperative to remain midline. This is ensured by visualizing striated muscle fibers, which run perpendicular to the incision. If fat is encountered during the dissection, this indicates that the operator has deviated from midline and entered the lateral ischioanal/ischiorectal space. The rectum is identified by its overlying glistening fascia and then freed circumferentially, beginning posteriorly and advancing anteriorly until the fistula is encountered. The fistula is resected. After the fistula is taken down, the anterior rectal wall is freed from its surrounding structures. In females, the anterior rectum lies in close proximity to the posterior vaginal wall and in males, the prostate and bladder. The anterior rectal wall is gently dissected off these structures up to the peritoneal reflection. Complete, circumferential dissection of the rectum will allow for tension-free pull down and anastomosis. The rectum is situated in its anatomic position in the muscle complex. The muscle complex is repaired around the properly positioned rectum and the neoanus is created by suturing mucosa to the perineum.

#### *4.2.5 Outcomes*

Long terms outcomes are dependent on the level of pathology—high versus low anorectal dysgenesis—and the extent of neuromuscular development of the levator

ani complex and rectum. Almost all children will require some degree of lifestyle modifications to manage fecal incontinence or, conversely, chronic constipation. This is achieved by strict bowel regimens with enemas or cathartics. In more severe cases, a cecostomy or appendicostomy may be required to allow for daily antegrade enemas. Worst case scenarios may necessitate a diverting ostomy.

## Acknowledgements


The contribution of Natalia Louise Smith is greatly appreciated for drawing the figures numbered as 1-to-6.

## Author details

Richa Verma  
Piedmont Healthcare, Statesville, NC, USA

\*Address all correspondence to: [rverma1024@gmail.com](mailto:rverma1024@gmail.com)

## IntechOpen

© 2020 The Author(s). Licensee IntechOpen. This chapter is distributed under the terms of the Creative Commons Attribution License (<http://creativecommons.org/licenses/by/3.0>), which permits unrestricted use, distribution, and reproduction in any medium, provided the original work is properly cited. 

## References

[1] Abdellatif M, Ghazy S, Kamel MG, et al. Association between exposure to macrolides and the development of infantile hypertrophic pyloric stenosis: A systematic review and meta-analysis. *European Journal of Pediatrics*. 2019;**178**:301-314. DOI: 10.1007/s00431-018-3287-7

[2] Greenfield Lazar J, Mulholland Michael W, editors. *Greenfield's Surgery: Scientific Principles and Practice*. 5th ed. Philadelphia: Wolters Kluwer Health/Lippincott Williams & Wilkins; 2011

[3] Soares KC, Goldstein SD, Ghaseb MA, et al. *Pediatric Surgery International*. 2017;**33**:637. DOI: 10.1007/s00383-017-4083-6

[4] Fiser SM. *The ABSITE Review: Practice Questions*. 2nd ed. Richmond, VA: Hancock Surgical Consultants; 2015

[5] Dimick JB, Upchurch JR, Sonnenday CJ, editors. *Clinical Scenarios in Surgery: Decision Making and Operative Technique*. Philadelphia: Wolters Kluwer Health/Lippincott Williams & Wilkins; 2012

[6] <http://www.embryology.ch/anglais/sdigestive/mitteldarm01.html>

[7] <https://discovery.lifemapsc.com/library/review-of-medical-embryology/chapter-84-development-of-the-midgut-general-introduction> [https://www.pedsurglibrary.com/apsa/view/Pediatric-Surgery-NaT/829186/all/Posterior\\_Sagittal\\_Anorectoplasty#0](https://www.pedsurglibrary.com/apsa/view/Pediatric-Surgery-NaT/829186/all/Posterior_Sagittal_Anorectoplasty#0)

[8] <https://coloproctol.org/journal/view.php?number=1558>

[9] Morris G, Kennedy A, Cochran W. *Current Gastroenterology Reports*. 2016;**18**:16. DOI: 10.1007/s11894-016-0490-4