

We are IntechOpen, the world's leading publisher of Open Access books Built by scientists, for scientists

6,900

Open access books available

186,000

International authors and editors

200M

Downloads

Our authors are among the

154

Countries delivered to

TOP 1%

most cited scientists

12.2%

Contributors from top 500 universities



WEB OF SCIENCE™

Selection of our books indexed in the Book Citation Index
in Web of Science™ Core Collection (BKCI)

Interested in publishing with us?
Contact book.department@intechopen.com

Numbers displayed above are based on latest data collected.
For more information visit www.intechopen.com



Tear Film – Physiology and Disturbances in Various Diseases and Disorders

*Dorota Kopacz, Łucja Niezgoda, Ewa Fudalej,
Anna Nowak and Piotr Maciejewicz*

Abstract

The tear film is a thin fluid layer covering the ocular surface. It is responsible for ocular surface comfort, mechanical, environmental and immune protection, epithelial health and it forms smooth refractive surface for vision. The traditional description of the tear film divides it into three layers: lipid, aqueous and mucin. The role of each layer depends on the composition of it. Tear production, evaporation, absorption and drainage concur to dynamic balance of the tear film and leads to its integrity and stability. Nonetheless, this stability can be disturbed in tear film layers deficiencies, defective spreading of the tear film, in some general diseases and during application of some general and/or topical medications. Dry eye disease is the result of it. In this review not only physiology of the tear film is presented. Moreover, we would like to discuss the influence of various diseases and conditions on the tear film and contrarily, spotlight tear film disorders as a manifestation of those diseases.

Keywords: tear film, dry eye, mucins, lipid layer, aqueous layer, ocular surface

1. Introduction

The tear film is a thin fluid layer covering the ocular surface; it is the interface of the ocular surface with the environment. It is responsible for ocular surface comfort, mechanical, environmental and immune protection, epithelial (both corneal and conjunctival) health and it forms smooth, refracting surface for vision [1, 2]. Tear production (about 1,2 microliters per minute, total volume 6 microliters, 16% turn-over per minute), evaporation, absorption and drainage are responsible for dynamic balance of the preocular tear film [1, 3–5]. Homeostatic balance leads to stability of the tear film, that makes possible to realize its functions as lubrication, nutrition and protection of ocular surface [3, 6]. Nonetheless, this stability can be disturbed in tear film layers deficiencies, defective spreading of the tear film, in some general diseases and during application of some systemic and/or topical medications and dry eye disease evolves as a consequence of it. These review focused on physiology of the tear film, it's meaning for the ocular surface stability and analyzed influence of various diseases and conditions on it.

2. Tear film structure and function

The traditional description of the tear film is three-layered structure: superficial-oily, middle - aqueous and mucous layer at the base [1–3]. A more recently proposed model consists of two layers: superficial – lipids and mucin/aqueous glycocalyx gel with decreasing mucin concentration from epithelium to lipid layer [1, 3, 7, 8]. Some authors says, that the tear film is a single unit that acts like a fluid shell [9] (**Table 1** and **Figure 1**).

Tear film layer	Function
Lipid layer (meibum)	<ul style="list-style-type: none">• Form the outer layer of the tear film.• Minimize the evaporation of water from the eye surface• Isolate ocular surface from the environment• Improve the stability of tear film• Provide smooth refracting surface• Limit contamination of ocular surface from particles(dust) and microorganisms• Prevent tear contamination by skin lipids• Limit aqueous layer surface tension• Counteract tears overflowing onto the skin
Aqueous phase	<ul style="list-style-type: none">• Constitutes roughly 90% of the tear film volume• Lubricate the ocular surface• Wash away foreign bodies and contaminations• Nourish the avascular cornea (oxygen, proteins, inorganic salts)• Include proteins (lysozyme, lactoferrin, lipocain), immunoglobulins, defensins and glycoproteins responsible for anti-microbial activity• Include growth factors, vitamins and electrolytes necessary for ocular surface health and epithelial integrity• Realign corneal microirregularities (refractive properties)
Mucous layer	<ul style="list-style-type: none">• Form a glycocalyx over the ocular epithelium that prevents pathogen adhesion• Bind water to hydrate and lubricate the ocular surface.• Reduce friction during blinking• Clear the surface of pathogens and debris• Contribute to tear stability• Take part in regulation of epithelial growth• Might be involved in cellular signaling

Table 1.
The function of tear film layers.

2.1 Lipids

The lipid layer is secreted by Meibomian glands, located within tarsal plates of upper and lower eyelids with some small contribution by Moll (modified apocrine, sudoriferous) and Zeiss (modified subciliary) glands, located within superior and lower eyelids (connected with hair follicles) and possibly epithelial cells. The posterior, aqueous interface consists of polar lipids: ceramides, cerebroside and phospholipids. The lipid-air interface is formed with nonpolar lipids: cholesterol esters, triglycerides and free fatty acids [1, 3, 7, 8, 10].

The main function of the lipid layer is to reduce evaporation of tears and improve the stability of them. Moreover, the lipid layer provides smooth refracting surface, limits contamination of ocular surface from particles (dust) and microorganisms, prevents tear contamination by skin lipids, limits aqueous layer surface tension and counteracts tears overflowing onto the skin. [1, 3, 7–14].

Regulation of lipid secretion supervenes through modulation of lipid synthesis or cell maturation. The Meibomian gland secretion is a subject of neuronal, hormonal

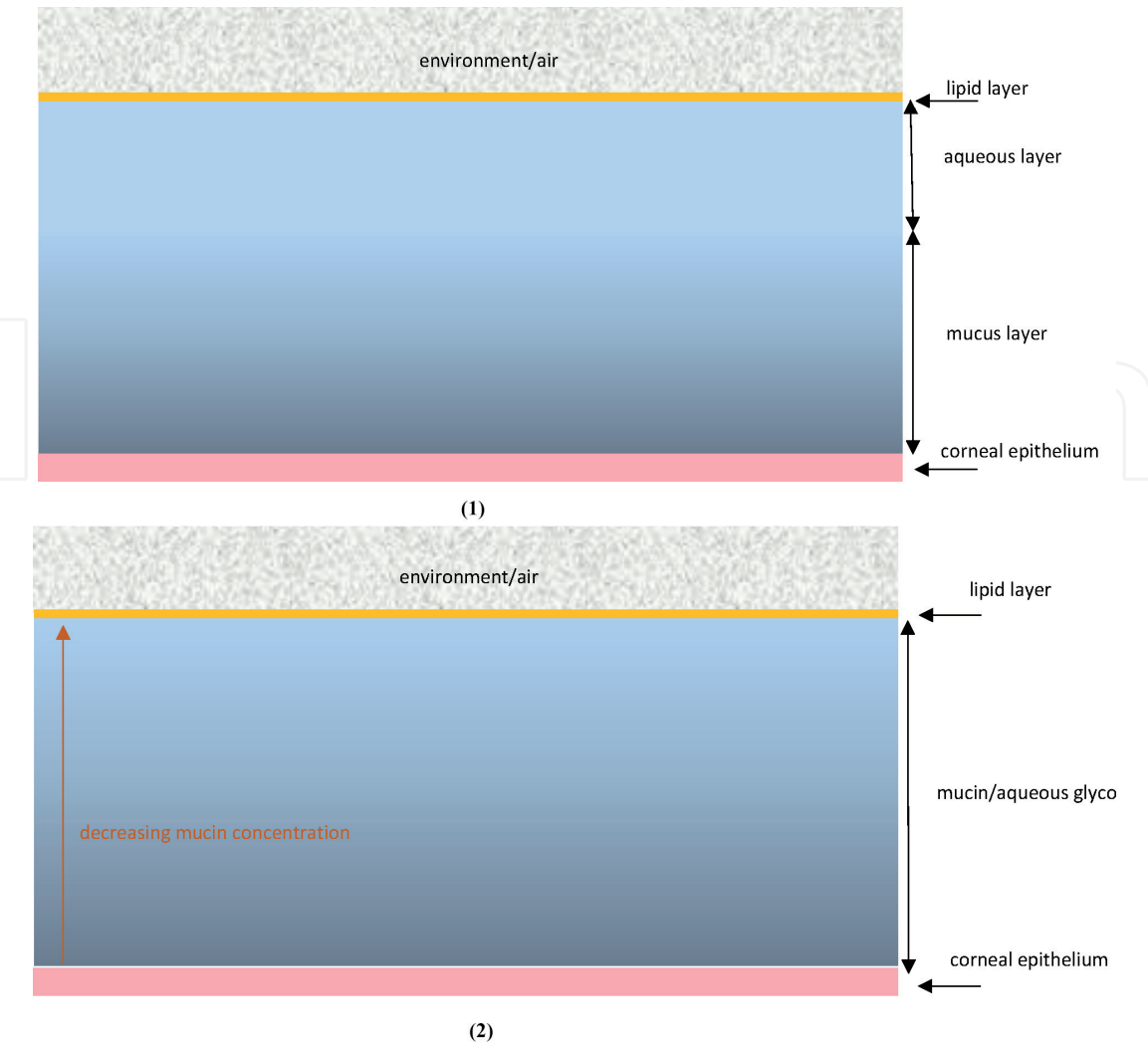


Figure 1.
Structure of the tear film: 1. Three layer conception. 2. Two layer conception.

and vascular influences. Androgen, estrogen and progesterone receptors have been identified in adult male and female rats, rabbits and humans. It is suggested that androgens stimulate and estrogens reduce Meibomian secretion [14–17]. Moreover, Meibomian gland function may be under direct neuronal (predominant parasympathetic, also sympathetic and sensory sources) or indirect vascular (vasoactive intestinal polypeptide VIP) influence to control lipid synthesis and/or excretion [2, 14, 15].

2.2 Aqueous component

The main non-reflex production of aqueous part of mucin/aqueous gel is from the Krauze and Wolfring glands (accessory lacrimal glands) located in the conjunctiva of superior eye lid and superior conjunctival fornix. The main lacrimal gland is responsible for aqueous tears production secondary to deleterious stimulation and plays important, though not entirely clear role in non-reflecting tearing (dry eye syndrome is noted in patients with damaged main lacrimal gland) [1, 7, 8, 11, 18]. The aqueous layer consists of water, electrolytes, proteins, cytokines, vitamins, immunoglobulins and peptide growth factors. Moreover, amino acids, bicarbonate, calcium, urea and magnesium were detected in tear film [15, 19].

The aqueous portion of the tear film is responsible for ocular surface lubrication, washing away foreign bodies or contaminations and nourishing avascular cornea (oxygen, inorganic salts, proteins, glucose) [3, 16, 20]. The soluble mucins decrease the surface tension, impact coherence of the aqueous layer, contribute to tear film

viscosity [14, 19]. Almost 500 different proteins have been extracted from the tear film [3, 21]. Lactoferrin, lysozyme, lipocalin, secretory immunoglobulin A(sIgA), immunoglobulin G(IgG), immunoglobulin M (IgM), albumin, transferrin, ceruloplasmin, defensins, tear specific prealbumin and glycoproteins participate in the ocular surface antimicrobial activity and defense [3, 15, 22]. Growth factors, vitamins, electrolytes, neuropeptides and protease inhibitors are necessary for retaining ocular surface health and epithelial integrity [1, 3, 23]. Retinol, secreted by the lacrimal gland, is necessary for maintenance of goblet cells and regulates corneal epithelium desquamation, keratinization and metaplasia [15, 24–26].

The lacrimal gland is affected by both nervous system and various hormones [1, 2, 7, 11, 15, 18, 23, 27]. The gland innervation comes from the first brunch of trigeminal nerve, the facial nerve and sympathetic fibers from the superior cervical ganglion [1, 11, 15, 28]. Stimulation of the ocular surface is the beginning of the main lacrimal gland production (reflexing tearing). The emotional tearing is also connected with this reflex loop (**Figure 2**). The meaning of the sympathetic part of innervation is thought to stimulate basal tearing but is still not completely understood. The accessory lacrimal glands are heavily innervated, but there is lack of parasympathetic part and most of the innervation is undefined [8, 15, 29].

Androgens and estrogens influence lacrimal gland production. Androgens lack is responsible for reversible degenerative changes of lacrimal gland, decreased volume of the tears, decreased level of proteins in tears. Estrogens remain controversial: some studies described estrogen deficiency linked to keratoconjunctivitis sicca (KCS) and lacrimal gland degeneration, other works have shown no changes in the lacrimal gland and tear film with decreased level of estrogens [15, 17, 30, 31]. Thyroid stimulating hormone (TSH) receptors (present in lacrimal gland) as well as thyroid

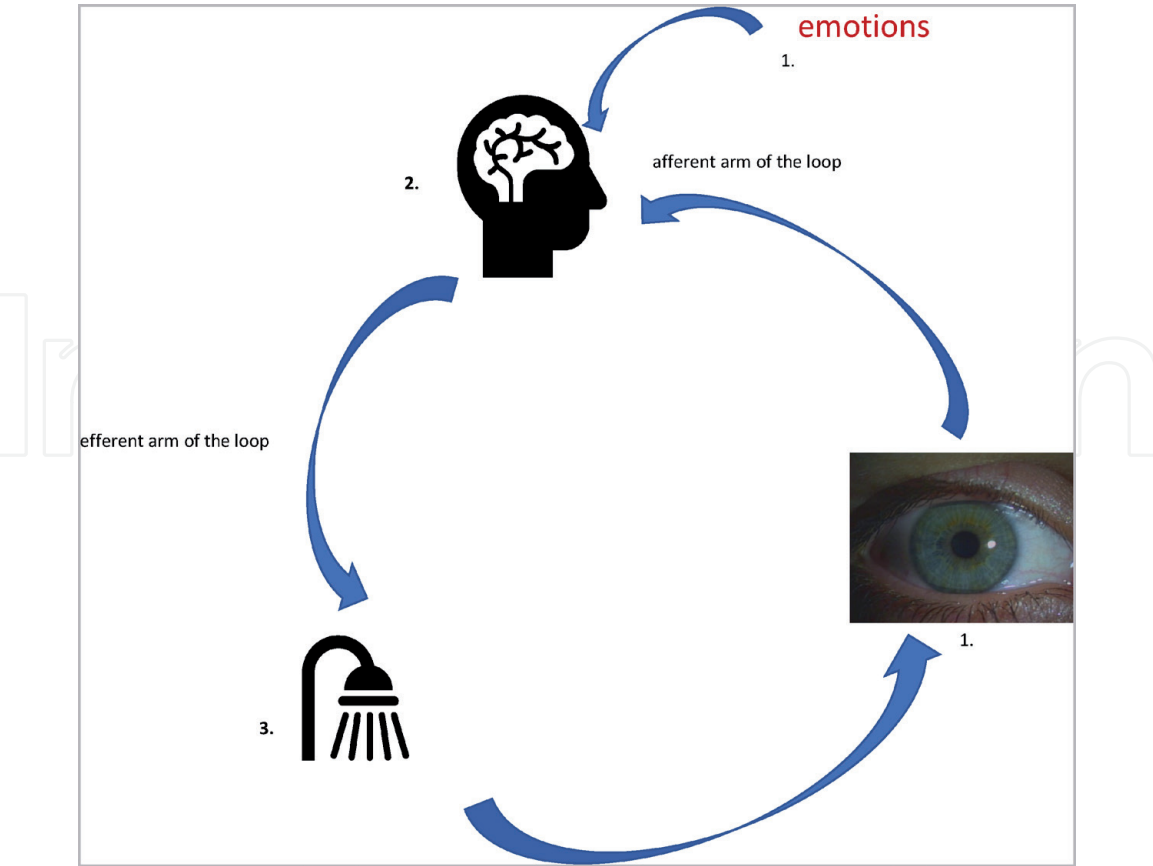


Figure 2. Reflex loop of tearing: 1. Stimulants: - ocular surface and nasal mucosa - afferent arm of the loop (first branch of the fifth cranial nerve)- emotions, 2. brain - efferent arm of the loop (parasympathetic part of the seventh nerve), 3. lacrimal glands.

hormone and tissue interaction are necessary for lacrimal gland secretion. Adequate insulin level is important for lacrimal gland and ocular surface stability and function, because it is necessary for acinar cell and cornea epithelial cell proliferation [32].

2.3 Mucins

The mucous layer of the tear film is produced by both corneal and conjunctival epithelium and the lacrimal gland and conjunctival goblet cells [1, 3, 7, 11, 15, 33]. It is composed of secreted and transmembrane mucins, immunoglobulins, salts, urea, glucose, leukocytes, cellular debris and enzymes [1, 3, 15, 33–35].

Traditional description of the mucins role limits to secreted gel-forming mucins working as lubricating agents and clearing molecules. Current data indicate its role also as a barrier for corneal and conjunctival epithelium. We can find two kinds of the mucins: cell surface-associated and secreted [36].

Cell surface-associated mucins form a thick cell surface glycocalyx, providing through their O-glucans a disadhesive character to the apical surface of the corneal epithelium. That is why they assure boundary lubrication and prevent adhesion of corneal epithelium and tarsal conjunctiva during blinking and sleeping [36, 37]. Moreover, membrane-bound mucins take part in the maintenance of the mucosal barrier integrity to prevent the penetration of molecules onto ocular surface epithelia [36, 38]. Some recent studies have weighed up membrane-bound mucins as osmosensors in eukaryotic cells [36, 39, 40].

Secreted mucins have a capability to trap contaminations (e.g. allergens, debris, pathogens) in order to clearance them from mucosal surface. Gel-forming mucins retaining water, form highly hydrated gel to lubricate ocular surface and reduce shear stress during blinking or rubbing. Moreover, MUC 7 (detected in lacrimal gland), has potent antifungal and antimicrobial activity [34, 35, 37, 41–43].

Goblet cells may be stimulated for mucin secretion by histamine, antigen, immune complex, mechanical action (i.e. blinking), direct (muscarinic and α -adrenergic receptors on immature goblet cells) and indirect (sensory, sympathetic and parasympathetic innervation of conjunctiva surrounding goblet cells) neural control [15, 16, 44–46].

2.4 Tear film dynamics

Balanced tear film production and elimination is crucial for its integrity, stability and right osmolality [3]. Tear film production is a complex process, controlled by the various factors: main and accessory lacrimal glands, ocular surface structures (cornea, conjunctiva, eyelids with Meibomian gland) and interconnecting nerves (both sensory and motor) [3, 47, 48]. Ryc.1. Tears elimination proceeds as evaporation, drainage and absorption. Tear film interfaces with the environment; that is the reason of evaporation (about $1,4\text{--}39,3 \times 10^{-7} \text{ g/cm}^2/\text{s}$) [5, 49]. Some environmental factors like humidity, temperature and air movements impact the rate of tear evaporation from the ocular surface [50]. Higher evaporation is the reason of tear film thinning and, because of that, instability and hyperosmolality [51]. Regardless of the recent data on evaporation, tears outflow through the lacrimal drainage system remains the main way of its elimination. With each blink, tears with contaminations (like cellular debris, toxins, inflammatory cells and other waste products) are moved towards the lacrimal puncta and next - due to the negative pressure created in lacrimal drainage system - to the lacrimal drainage tract [3, 52]. Some studies noted reduction of tears production in patients with impaired drainage that highlights the importance of this process in the model of tear dynamics [53–55]. At least absorption: process necessary for proper tear film dynamics, connected with cornea, conjunctiva and - mainly - nasolacrimal duct epithelium [56]. The equilibrium in

the tear film production, retention and elimination acts the crucial role in its proper functioning, thereby ocular surface health [3].

3. The influence of various diseases and conditions on the tear film

Tear film stability can be disturb in tear film layers deficiencies, defective spreading of the tear film, in some general diseases and during application of some general and/or topical medications. In the wake of it dry eye disease evolves [11, 36, 57] (Tables 2 and 3).

3.1 Lipid layer alteration

Deficiency of this layer is the reason of more rapid evaporation and in the absence of increased tear production activates evaporative form of dry eye disease [58].

The most common reason of lipid layer deficiency is obstruction of the Meibomian glands. Meibomian gland dysfunction (MGD) may be provoked by various local and systemic conditions, e.g. atopic keratoconjunctivitis, chronic blepharitis [59, 60], generalized dysfunction of sebaceous glands (rosacea, seborrheic dermatitis), chemical agents such as turpentine, present in the sick building environment [36, 61]. Tobacco smokers are prone to development of MGD [62], the more severe course of MGD was observed in type 2 diabetes mellitus [63].

Dry eye	
Aqueous deficient dry eye (ADDE)	Evaporative dry eye (EDE)
Sjögren syndrome dry eye (SSDE) Primary Secondary	Endogenous Meibomian gland dysfunction (MGD) Disorders of lids and lid aperture Low blinking Systemic medicines
Non- Sjögren Syndrome dry eye Lacrimal deficiency Lacrimal gland duct obstruction Reflex block Systemic medicines	Exogenous Contact lens wear Ocular surface diseases Topical medicines Vitamin A deficiency

Table 2.
Dry eye classification [7, 23, 64–74].

Dry eye disease	
Signs	Symptoms
<ul style="list-style-type: none">Discomfort: itching, stinging, burning, “foreign body sensation” occasionally pain, photophobiaVisual fluctuations (especially during reading- blinking recover vision)Tear film instability (potential damage of ocular surface)	<ul style="list-style-type: none">Eyelids: blepharitis posterior, Meibomian gland dysfunction, trichiasis, symblepharonConjunctiva: hyperemia, keratonization, persistent inflammation, dyeing with the lissamine green(rose bengal)Tear film: debris, reduced meniscus, instability(reduced break-up time), elevated osmolarity and level of inflammatory mediatorsCornea: epithelial defect (dyeing with the fluorescein), filaments, mucus clumpingPotential complications: persistent epithelial defect, keratomalacia, corneal perforation, corneal ulcer

Table 3.
Signs and symptoms of dry eye disease [1, 7, 23, 64].

Furthermore, the insufficient protein intake in bariatric patients negatively influences tear film lipids [75]. Also androgen deficiency (e.g. aging, anti-androgen therapy, congenital impairment or absence of the androgen receptor) hinders lipid production [76]. Incomplete blinking has been reported as the reason for lipid layer instability, because of inadequate lipid distribution [9, 77]. Some studies have revealed influence of medicines on the lipid layer: e.g. isotretinoin decreases Meibomian gland secretory ability [78], and on the contrary, botulinum neurotoxin A injections seem to increase lipid layer thickness [79].

3.2 Aqueous layer disturbances

Aqueous layer deficiency is the most common reason of dry eye and is classified into two groups: Sjögren Syndrome dry eye and non-Sjögren Syndrome dry eye [64, 65].

Sjögren's syndrome (SS) is a rheumatic autoimmune disease in which exocrine glands (salivary and lacrimal glands) are involved that results in clinical symptoms of dry mouth and dry eye. SS can be primary-pSS (without any other accompanying symptoms) or secondary-sSS (with other autoimmune diseases: systemic lupus erythematosus (SLE), rheumatoid arthritis (RA), polyarteritis nodosa, systemic sclerosis, granulomatosis with polyangiitis (GPA), primary biliary cholangitis (PBC), mixed connective tissue disease, occult thyroid eye disease) [64, 66]. Some studies demonstrated coincidence of dry eye disease (DED) and SS in 46.7% cases [64, 67].

In non-SS dry eye reduced tear secretion is a result of senile hyposecretion, lacrimal excision, lacrimal duct obstruction, immune lacrimal gland damage in sarcoidosis or lymphoma, sensory or motor reflex block, scarring conditions of the conjunctiva (pemphigoid, chemical burns, trachoma, chronic ocular Graft-versus-Host Disease) [11, 57, 64, 68, 69]. Corneal hypoesthesia and due to it dry eye can be result of corneal refraction surgery [70], contact lens wearing [71], herpetic keratitis or as a side effect after surgical trigeminal neuralgia management [72].

Increased electrolyte concentration, loss of growth factors, presence of proinflammatory cytokines result in changes in composition of the aqueous part of the tear film. Such a disturbances in connection with slow tear turnover are secondary to ocular surface damage [8, 47].

There are some medicines reported to exacerbate tear secretion, e.g. thiazide diuretics, tricyclic and tetracyclic antidepressants, β -blockers, anticholinergics, benzodiazepines, antihistamines, antihypertensives and anti-Parkinson's drugs [8, 57, 73, 74].

3.3 Mucin layer deficiency

Disturbances of the mucin layer are connected with the goblet cell deficiency, which is observed in majority forms of dry eye [8, 80]. The leading reason of xerophthalmia connected with mucins the insufficiency of vitamin A is [8, 57, 81, 82]. The lack of vitamin A is usually connected with various forms of malnutrition or chronic malabsorption. Gastroenterological diseases (e.g. coeliac disease) impair vitamin A absorption [83–85]. Conditions affecting liver impair fat metabolism and decreases absorption of this fat-soluble vitamin [86, 87]. Pancreas insufficiency (e.g. cystic fibrosis) hinders vitamin A intake by its influence on fat digestion pathway [88, 89]. Alcoholism, restrictive diets (both in eating disorders and selective, like poor balanced vegans') and low-quality food consumption are the most common reasons of malnutrition and because of that vitamin A insufficiency [90–94].

There are some problems responsible for impairment of goblet cells function. Mucous membrane pemphigoid and its subtype – ocular cicatricial pemphigoid

via recurrent inflammation destroy goblet cells and promote subepithelial fibrosis, resulting in changes ranging from xerophthalmia to conjunctival keratinization and blindness [95–99]. Stevens-Johnson Syndrome, trachoma and severe burns (both thermal and chemical) impair mucin production by decreasing the number of active goblet cells [8, 100–103].

Moreover, some medications (e.g. mucolytics, antihistamines) and preservatives influence the ocular surface and modify mucous layer [8, 57, 104].

3.4 Multilayer disturbances

Although three layers of the tear film are investigated, all of them remain in strict dependence of each other and many conditions cause disturbances of the tear film as a whole. The most common problem impairing ocular surface is progression with age; decreased tear production, tear film problems, hormonal changes, medications and other diseases affect tear production, its' ingredients and spreading over the ocular surface [8, 57, 105, 106]. Tantalizing dry eye seems to be one of the most important conditions influencing all three layers: eyelid incongruity (entropion, ectropion, lid margin irregularities, exophthalmos), epitheliopathy (e.g. corneal scars) and evaporation are the reason of tear loss. Neurological problems (both afferent and efferent part of the reflex loop) directly affect tear secretion [8, 57, 105].

Hormonal changes (androgens, estrogens, prolactin, thyroid hormone, insulin resistance/deprivation, ACTH resistance, adrenal insufficiency, multiple endocrine deficiency) influence tear stability as well [105, 106]. Meanwhile, the newest meta-analysis revealed no correlation between hormonal replacement therapy or oral contraceptives and tear film – it seems to be speculative [107, 108]. Dry eye disease due to hormonal disorders often connect both aqueous tear deficient and evaporative mechanism. Thyroid associated diseases result usually in autoimmune condition (impaired thyroid hormone activity, autoantibodies against THS receptors present in lacrimal glands, autoantibodies against thyroid hormone and/or their receptors) but the final effect of dry eye is connected also with ocular surface disturbances due to enhanced environment exposure, lid mechanical impairment (reduced lipid secretion, eyelid retraction, eye globe proptosis, impaired blinking) and therapy (thyroid hormone replacement, iodine suppression, immunomodulators specific for orbit and ocular disease, local radiotherapy and surgical procedures) [106]. In patients with diabetes mellitus the frequency of dryness varies from 15.4 to 82%. The mechanism of dry eye disease in diabetic patients is multifactorial: insulin resistance or deprivation is responsible for lacrimal gland size reduction, histological and molecular changes of it, polyneuropathy and nerve-conduction abnormalities that reduce secretion. Peripheral microvascular disease and insulin reduced input in target tissues are the other reasons of lacrimal gland and ocular surface disorders. Tear film instability and higher osmolarity are probably the result of higher glucose and protein levels in the tears and changes in the protein profile [106, 109].

In literature there are examples of dry eye disease secondary to other hormonal imbalance (e.g. ACTH-triple A syndrome, multiple endocrine deficiency) [106, 110].

Some environmental factors (e.g. pollutions, visual display terminals, temperature, humidity) promotes dry eye disease, however the pathomechanism is still discussed [111, 112]. Contact lenses wear influences lipid layer, changes the dynamics of the whole tear film and is the reason of dry eye symptoms [113–115].

There are a lot of data on the influence of medications (both topical and systemic) on the tear film. Some samples: β -blockers used for glaucoma therapy reduce test Shirmer I and break-up time values, long term general anesthesia decrease basal tear production, antihistamines block both goblet cells and lacrimal glands, topical glaucoma therapy reduces LLT, oral mucolytics modify mucous layer, systemic

Causes of disturbances	
Lipid layer	MGD: atopic local changes, chronic blepharitis, generalized dysfunction of the sebaceous glands, chemical agents, tobacco smokers, diabetes mellitus Insufficient protein intake (bariatric patients) Androgen deficiency: aging, anti-androgen therapy, congenital impairment or absence of the androgen receptor Incomplete blinking (inadequate lipid distribution) Medicines
Aqueous layer	<ul style="list-style-type: none">• Sjögren syndrome dry eye (SSDE) (primary, without other accompanying symptoms and secondary, with other autoimmune diseases)• Non- Sjögren syndrome dry eye (nSSDE) (senile hyposecretion, lacrimal excision, lacrimal duct obstruction, immune lacrimal gland damage, sensor or motor reflex block, scarring condition of the conjunctiva, corneal hypoesthesia as a result of CL wearing, heretical keratitis or surgical procedures)• Medicines
Mucus layer	<ul style="list-style-type: none">• Insufficiency of vitamin A: malnutrition or malabsorption (gastroenterological diseases, condition affecting liver, pancreas insufficiency, alcoholism, restrictive diets, low quality food)• Destruction of the goblet cells (cicatricial conjunctival changes: e.g. pemphigoid, Stevens-Johnson syndrome, trachoma, GVHD, severe thermal and chemical burns)• Medicines
Multilayer	<ul style="list-style-type: none">• Aging: decreased tear production, tantalic problems (eyelid incongruency as entropion, ectropion, eyelid irregularities, exophthalmos, epitheliopathy; e.g. corneal scars)• Hormonal changes (androgens, estrogens, prolactin, ACTH, thyroid hormone)• Neurological problems (both afferent and efferent part of the reflex loop)• Environment (pollutions, ambient temperature, humidity)• Visual display terminals• Medicines (both topical and systemic)• Preservatives

Table 4.
The main causes of tear film deficiency [7, 58–125].

antidepressants, anticholinergics or antihypertensives increase risk of dry eye problems [56, 103, 116–122]. A comprehensive review of this problem with the list of medicines and herbs has been prepared by Askeroglu et al. [123]. Analyzing influence of medicines on the ocular surface and dry eye disease we have to remember that topical used multidose artificial tears and lubricants contain preservatives. The most common Benzalkonium chloride – BAK disrupts tear stability, causes corneal and conjunctival epithelium damage and induces inflammatory changes that depends on dose and time of use. Alternative preservatives (e.g. Polyquaternium-I: Polyquad®, Polyhexamethylene biguanide: PHMB, Sodium perborate: GenAqua®, Dequest®, stabilized Oxychlorocomplex SOC: Purite®, OcuPure®, ionic-buffered solution containing zinc chloride, borate, propylate glucol and sorbitol:Sofzia) are used in some artificial tears, lubricants or glaucoma drops. Published data on the ocular performance of them generally show they induce significantly less disturbances of the ocular surface than BAK [124, 125] (**Table 4**).

4. Conclusions

The ocular surface contacts with the environment by the tear film as interface. Thus, tear production, composition, dynamics and function is so important to prevent it healthy. There are many diseases and conditions (both systemic and

local) that may affect each layer of the tear film separately or all of them together. Moreover, tear film disorders can manifest systemic diseases and, sometimes, be necessary or even be the only clue to diagnosis. The commonness of tear film problems and wide spectrum of its different background seem to require to be considered in everyday medical, not only ophthalmological, practice. Those problems should be analyzed to plan and undertake proper therapy, especially in patients with eye dryness symptoms.

Author details

Dorota Kopacz^{1,2*}, Łucja Niezgoda¹, Ewa Fudalej¹, Anna Nowak¹ and Piotr Maciejewicz^{1,2}

1 Medical University of Warsaw, Warsaw, Poland

2 Department of Ophthalmology, Infant Jesus Teaching Hospital, Warsaw, Poland

*Address all correspondence to: dr.dk@wp.pl

IntechOpen

© 2020 The Author(s). Licensee IntechOpen. This chapter is distributed under the terms of the Creative Commons Attribution License (<http://creativecommons.org/licenses/by/3.0>), which permits unrestricted use, distribution, and reproduction in any medium, provided the original work is properly cited. 

References

- [1] Holland EJ, Mannis MJ, Lee WB: Ocular Surface Diseases, Elseviere Inc, 2013
- [2] Dartt DA, Willcox MDP; Complexity of the tear film: importance in homeostasis and dysfunction during disease. *Exp Eye Res* 2013, December,117:1-3
- [3] Stahl U, Willcox M, Stapleton F; Osmolality and tear film dynamics. *Clin Exp Optom* 2012, 95(1):3-11
- [4] de Paiva CS, Pflugfelder SC; Tera clearance implications for ocular surface health. *Ex Eye Res* 2004, 78:395-397
- [5] Mathers W; Evaporation from the ocular surface. *Exp Eye Res* 2004, 78:389-394
- [6] Tiffany JM. The normal tear film. *Dev Ophthalmol* 2008, 41:1-20
- [7] Willcox MDP, Argüeso P, Georgiev GA, Holopainen JM, Laurie GW, Millar TJ, Papas EB, Rolland JP, Schmidt TA, Stahl U, Suarez T, Subbaraman LN, Uçakhan OO, MDk, Jones L; TFOS DEWS II Tear Film Report. *Ocul Surf.* 2017 July ; 15(3): 366-403. doi:10.1016/j.jtos.2017.03.006.
- [8] Rolando M, Zierhut M; The ocular surface and tear film and their dysfunction in dry eye disease. *Surv Ophthalmol* 2001, 45(supl2):S203-210
- [9] Yokoi, N., A.J. Bron, and G.A. Georgiev, The precorneal tear film as a fluid shell: the effect of blinking and saccades on tear film distribution and dynamics. *Ocul Surf* 2014, 12(4):252-266.
- [10] McCulley JP, Shine WA; A compositional based model for the tear film lipid layer. *Trans Am Ophthalmol Soc* 1997. 95:79-88
- [11] Daily PM. Structure and function of the tear film. *Adv Exp Med Biol* 1994, 350:239-247
- [12] Bron A, Tiffany JM, Gouveia S, Yokoi N, Voon L; Functional aspects of the tear film lipid layer. *Exp Eye Res* 2004, 78:347-360
- [13] Foulks GN; The correlation between the tear film lipid layer and dry eye disease. *Surv Ophthalmol* 2007, 52(4):369-374
- [14] McCulley JP, Shine WE; The lipid layer of tears: dependent on Meibomian gland function. *Exp Eye Res* 2004, 78:361-365
- [15] Davidson HJ, Kuonen VJ; The tear film and ocular mucins. *Vet Ophthalmology* 2004, 7(2):71-77
- [16] Dartt DA; Regulation of tear secretion. *Adv Exp Med Biol* 1994, 350:1-10
- [17] Sullivan DA, Sullivan BD, Ulman MD, Rocha EM, Krenzer KL, Cermak JM, Toda I, Doane MG, Evans JE, Wickham LA.: Androgen influence of the Meibomian gland. *Invest Ophthalmol Vis Sci* 2000, 41(12): 3732-3742
- [18] Conardy CD, Joos ZP, Patel BCK; Review: The lacrimal gland and its role in dry eye. *J Ophthalmol* 2016, 2016:7542929, doi: 10.1155/2016/7542929. Epub 2016 Mar 2.
- [19] Iwata S; Chemical composition of the aqueous phase. *Int Ophthalmol Clin Spring* 1973;13(1):29-46.doi: 10.1097/00004397-197301310-00005.
- [20] Kaura R, Tiffany JM; The role of mucous glykoproteins in the tear film. in: Holly FJ: The preocular tear film in health, disease and contact lens wear.

Dry Eye Institute Inc, Lubbock,
1986:728-731

[21] de Souza GA, Godoy LM, Mann M; Identification of 491 proteins in the tear film proteome reveals a large number of proteases protease inhibitors. *Genome Biol* 2006, 7:R72

[22] Huang LC, Jean D, Proske RJ, Reins RY, McDermott AM; Ocular surface expression and in vitro activity of antimicrobial peptides. *Curr Eye Res* 2007, 32:595-609

[23] Lemp MA, Beuerman RW; Tear film. in Krachmer JH, Mannis MJ, Holland EJ: *Cornea*. Elsevier Inc, 2011:33-39

[24] Ubels JL, Foley KM, Rismondo V. Retinol secretion by the lacrimal gland. *Invest Ophthalmol Vis Sci*. 1986 Aug;27(8):1261-8.

[25] Ubels JL, Rismondo V, Osgood TB; The Relationship Between Secretion of Retinol and Protein by the Lacrimal Gland. *Invest Ophthalmol Vis Sci* 1989, 30(5):952-960

[26] Pfister RR, Renner ME; The corneal and conjunctival surface in vitamin A deficiency: a scanning electron microscopy study. *Invest Ophthalmol Vis Sci* 1978, 17(9): 874-883

[27] Obata H; Anatomy and histopathology of the human lacrimal gland. *Cornea* 2006, 25 (10) (Supl.1):S82-S89

[28] American Academy of Ophthalmology; Orbit, eyelids and lacrimal system. In *Basic and Clinical Science Course* 1998-1999

[29] Riley CM, Day RC, Greeley DM, Langford WS; Central automatic dysfunction with defective lacrimation; report of five cases. *Pediatrics* 1949, 3(4):468-478

[30] Sullivan DA, Kelleher RS, Vaerman JP, Hann LE; Androgen regulation of secretory component synthesis by lacrimal gland acinar cells in vitro. *J Immunol* 1990, 145:4238-4244

[31] Sullivan DA, Wickham LA, Rocha EM, Kelleher RS, da Silveira LA, Toda I; Influence of gender, sex steroid hormones and the hypothalamic-pituitary axis on the structure and function of the lacrimal gland. *Adv Exp Med Biol* 1998, 438:11-42

[32] Rocha EM, Mantelli F, Nominato LF, Bonini S; Hormones and dry eye syndrome:an update on what we do and don't know. *Curr Opin Ophthalmol* 2013, 24:348-355Gipson IK, 33. Inatomi T; Cellular origin of mucins of ocular surface tear film. *Adv Exp Med Biol* 1998, 4(38):221-227

[33] Gipson IK, Argueso P; Role of mucins in the function of the corneal and conjunctival epithelia. *Int Rev Cytol* 2003, 231:1-46

[34] Gipson IK; Distribution of mucins at the ocular surface. *Exp Eye Res* 2004, 78:379-388

[35] Nichols BA, Chiappino ML, Dawson CR. Demonstration of the mucous layer of the tear film by electron microscopy. *Invest Ophthalmol Vis Sci* 1985, 26:464-473

[36] Mantelli F, Argueso P; Functions of ocular surface mucins in health and disease. *Curr Opin Allergy Clin Immunol* 2008, 8(5):477-483

[37] Sumiyoshi M, Ricciuto J Tisdale A, Gipson IA, Mantelli F, Argueso P; Antiadhesive character of mucin O-glycans confer an surface of the corneal epithelial cells. *Invest Ophthalmol Vis Sci* 2008,49:197-203

[38] Argueso P, Tisdale A, Spurr-Michaud S, Sumiyoshi M, Gipson IK; Mucin characteristics of human

corneal-limbal epithelial cell that exclude the rose Bengal anionic dye. Invest Ophthalmol Vis Sci 2006, 47:113-119

[39] Tatebayashi K, Tanaka K, Yang HY, Yamamoto K, Matsushita Y, Tomida T, Imai M, Saito H; Transmembrane mucins Hrk1 and Msb 2 are putative osmosensors in the SHO 1 branch of yeast HOG pathway. EMBO J 2007;26:3521-3533

[40] De Nadal E, Real FX, Posas F; Mucins , osmosensors in eukaryotic cells? Trends Cell Biol 2007, 17:571-574

[41] McKenzie RW, Jumblatt JE, Jumblatt MM; Quantification of MUC2 and MUC5AC transcripts in human conjunctiva. Invest Ophthalmol Vis Sci 2000, 41:703-708

[42] Dilly PN; Conjunctival cells, subsurface vesicles and tear film mucus. in: Holly FJ: The preocular tear film in health, disease and contact lens wear. Dry Eye Institute Inc, Lubbock, 1986:677-687

[43] Chandler JW, Gillette TE; Immunologic defense mechanisms of the ocular surface. Ophthalmol 1983, 90:585-591

[44] Bobek LA, Situ H; MUC7 20-mer: investigation of microbial activity, secondary structure and possible mechanism of antifungal action. Antimicrob Agents Chemomater 2003;47:643-652

[45] Dartt DA, McCarthy DM, Mercer HJ, Kessler TL, Chung EH, Zieske JD; Localization of nerves adjacent to goblet cells in rat conjunctiva. Curr Eye Res 1995, 14:993-1000

[46] Rios JD, Forde K, Diebold Y, Lightman J, Zieske JD, Dartt DA; Development of conjunctival goblet cells and their neuroreceptor subtype

expression. Invest Ophthalmol Med Sci 2000, 41:2127-2137

[47] Stern MF, Bauerman RW, Fox RI, Gao J, Mircheff AK, Pflugfelder SC; the pathology of dry eye :the interaction between the ocular surface and lacrimal glands. Cornea 1998, 17:584-589

[48] Stern ME, Gao J, Siemasko KF, Bauerman RW, Pflugfelder SC; The role of the lacrimal functional unit in the pathology of dry eye. Exp Eye Res 2004, 78:409-416

[49] Tomlinson A; inputs and outputs of the lacrimal system: review of production and evaporative loss. Ocul Surf 2009;7:186-198

[50] Borchman D, Foulks GN, Yappert MC, Mathews J, Leake K, Bell J; Factors affecting evaporation rates of the tear film components measured in vitro. Eye Contac Lens 2009, 35:32-37

[51] King-Smith PE, Nichols JJ, Nichols KK, Fink BA, Braun RJ; Contributions of evaporation and other mechanisms to tear film thinning and break-up. Optom Vis Sci 2008, 85:623-630

[52] Lemp MA, Weiler HH; How do tears exit? Invest Ophthalmol Vis Sci 1983, 24:619-622

[53] Francois J, Neetens A; Tear flow in man. Am J Ophthalmol 1973, 76:351-358

[54] Yen MT, Pflugfelder SC, Feuer WJ; The effect of punctal occlusion on tear production, tear clearance and ocular surface sensation in normal subjects. Am J Ophthalmol 2001, 131:314-323

[55] Stahl U, Francis IC, Stapleton F; Prospective controlled study of vapor pressure tear osmolality and tear meniscus height in nasolacrimal duct obstruction. Am J Ophthalmol 2006, 141:1051-1056

- [56] Tomlinson A, Khanal S; Assessment of Tear Film Dynamics: Quantification Approach. *Ocul Surf* 2005 Apr;3(2):81-95.
- [57] Niezgoda Ł, Fudalej E, Nowak A, Kopacz D; Tear film disorders as a manifestation of various diseases and conditions. *Klinika Oczna* 2020, article in press.
- [58] Rolando M, Refojo MF, Kenyon KR; Tear water evaporation and eye surface diseases. *Ophthalmologica* 1985, 190:147-149
- [59] Mathers WD, Lane JA; Meibomian gland lipids, evaporation and tear film stability. *Adv Exp Med Biol* 1998, 438:349-360
- [60] Shine WE, McCulley JP; Meibomian gland triglyceride fatty acid differences in chronic blepharitis patients. *Cornea* 1996, 15(4):340-346
- [61] Franck C, Bach E, Skov P. Prevalence of objective eye manifestations in people working in office buildings with different prevalences of the sick building syndrome compared with the general population. *Int Arch Occup Environ Health*. 1993;65(1):65-69
- [62] Altınors DD, Akça S, Akova YA, Bilezikçi B, Goto E, Dogru M, Tsubota K; Smoking associated with damage to the lipid layer of the ocular surface. *Am J Ophthalmol*. 2006 Jun;141(6):1016-1021.
- [63] Sandra Johanna GP, Antonio LA, Andrés GS. Correlation between type 2 diabetes, dry eye and Meibomian glands dysfunction. *J Optom*. 2019;12(4):256-262.
- [64] Kopacz D, Maciejewicz P; Sjögren's Syndrome as an Ocular Problem: Signs and Symptoms, Diagnosis, Treatment. In: Maślińska M; *Chronic Autoimmune Epithelitis – Sjogren's Syndrome and other Autoimmune Diseases of the Exocrine Glands*. IntechOpen 2019
- [65] Lin H, Yiu SC; Dry eye disease: A review of diagnostic approaches and treatment. *Saudi J Ophthalmol* 2014, 28(3):173-181
- [66] Voulgarelis M, Tzioufas AG. Current Aspects of Pathogenesis in Sjögren's Syndrome. *Ther Adv Musculoskelet Dis*. 2010,2(6):325-334
- [67] Ken E, Demirag MD, Beyazyildiz E. Presence of Sjogren's syndrome in dry eye patients. *Rheumatology (Sunnyvale)* 2014,4(2):137
- [68] Craig JP, Nichols KK, Akpek EK, Caffery B, Dua HS, Joo CK, et al. TFOS DEWS II Definition and Classification Report. *Ocul Surf*. 2017;15(3):276-8
- [69] Kopacz D, Maciejewicz P; Objawy okulistyczne w przebiegu choroby „przeszczep przeciwko gospodarzowi” po allogenicznym przeszczepie komórek macierzystych szpiku/ Ocular Manifestation of Graft-Versus-Host Disease Following Allogenic Hematopoietic Stem Cells Transplantation. *Okulistyka* 2/2016:35-37
- [70] Bragheeth MA, Dua HS. Corneal sensation after myopic and hyperopic LASIK: clinical and confocal microscopic study. *Br J Ophthalmol*. 2005;89(5):580-585
- [71] Murphy PJ, Patel S, Marshall J. The effect of long-term, daily contact lens wear on corneal sensitivity. *Cornea*. 2001;20(3):264-269
- [72] Semeraro F, Forbice E, Romano V, et al. Neurotrophic keratitis. *Ophthalmologica*. 2014;231(4):191-197
- [73] Koçer E, Koçer A, Özsütçü M, Dursun AE, Krpınar İ. Dry Eye Related to Commonly Used New Antidepressants. *J Clin Psychopharmacol*. 2015;35(4):411-413
- [74] Bergmann MT, Newman BL, Johnson NC, Jr. The effect of a

diuretic (hydrochlorothiazide) on tear production in humans. *Am J Ophthalmol.* 1985;99(4):473-475

[75] Sánchez-Sánchez AS, Rodríguez-Murguía N, Martínez-Cordero C, Chávez-Cerda S. Protein Diet in Bariatric Patients Could Modify Tear Film. *Obes Surg.* 2020;30(5):2053-2055.

[76] Krenzer KL, Dana MR, Ullman MD, et al. Effect of androgen deficiency on the human meibomian gland and ocular surface. *J Clin Endocrinol Metab.* 2000;85(12):4874-4882

[77] Wang MTM, Tien L, Han A, et al. Impact of blinking on ocular surface and tear film parameters. *Ocul Surf.* 2018;16(4):424-429

[78] Moy A, McNamara, LinMC; Effect of isotretinoin on meibomian glands. *Optom Vis Sci* 2015, 92(9):925-930

[79] Ho RW, Fang PC, Chao TL, Chien CC, Kuo MT. Increase lipid tear thickness after botulinum neurotoxin A injection in patients with blepharospasm and hemifacial spasm. *Sci Rep.* 2018;8(1):8367

[80] Sommer A, Emran N; Tear production in vitamin A-responsive xerophthalmia. *Am J Ophthalmol* 1982, 93:84-87

[81] Wiseman EM, Bar-El Dadon S, Reifen R. The vicious cycle of vitamin a deficiency: A review. *Crit Rev Food Sci Nutr.* 2017, 57(17):3703-3714.

[82] Whatham A, Bartlett H, Eperjesi F, Blumenthal C, Allen J, Suttle C, Gaskin K; Vitamin and mineral deficiencies in the developed world and their effect on the eye and vision. *Ophthalmic Physiol Opt.* 2008, 28(1):1-12

[83] Chiu M, Dillon A, Watson S. Vitamin A deficiency and xerophthalmia in children of a

developed country. *J Paediatr Child Health.* 2016, 52(7):699-703.

[84] da Cruz SP, Matos A, Pereira S, Saboya C, da Cruz SP, Ramalho A. Roux-en-Y; Gastric Bypass Aggravates Vitamin A Deficiency in the Mother-Child Group. *Obes Surg.* 2018, 28(1):114-121.

[85] Cheshire J, Kolli ; Vitamin A deficiency due to chronic malabsorption: an ophthalmic manifestation of a systemic condition. *BMJ Case Rep.* 2017;2017, doi: 10.1136/bcr-2017-220024corr1

[86] Kemp CM, Jacobson SG, Faulkner DJ, Walt RW; Visual function and rhodopsin levels in humans with vitamin A deficiency. *Exp Eye Res.* 1988, 46(2):185-197.

[87] Prasad D, Bharguvanshi A; Ocular manifestations of liver disease in children: Clinical aspects and implications. *Ann Hepatol.* 2019. S1665-2681(19)32293-8. doi:10.1016/j.aohep.2019.11.009

[88] Morkeberg JC, Edmund C, Prause JU, Lanng S, Koch C, Michaelsen KF; Ocular findings in cystic fibrosis patients receiving vitamin A supplementation. *Graefes Arch Clin Exp Ophthalmol.* 1995, 233(11):709-13.

[89] Norsa L, Zazzeron L, Cuomo M, Claut L, Bulfamante AMC, Biffi A, Colombo C; Night Blindness in Cystic Fibrosis: The Key Role of Vitamin A in the Digestive System. *Nutrients.* 2019;11(8) :1876. doi:10.3390/nu11081876

[90] Roncone DP; Xerophthalmia secondary to alcohol-induced malnutrition. *Optometry.* 2006, 77(3):124-133.

[91] Kopecky A, Benda F, Nemcansky J; Xerosis in Patient with Vitamin A

Deficiency - a Case Report. *Cesk Slov Oftalmol.* 2018, 73(5-6):222-224.

[92] Martini S, Rizzello A, Corsini I, Romanin B, Fiorentino M, Grandi S, Bergamashi S; Vitamin A Deficiency Due to Selective Eating as a Cause of Blindness in a High-Income Setting. *Pediatrics.* 2018, 141(Suppl 5):S439-S444.

[93] Jaworowski S, Drabkin E, Rozenman Y; Xerophthalmia and undiagnosed eating disorder. *Psychosomatics.* 2002, 43(6):506-507.

[94] Kirby M, Danner E; Nutritional deficiencies in children on restricted diets. *Pediatr Clin North Am.* 2009, 56(5):1085-1103.

[95] Chan LS; Ocular and oral mucous membrane pemphigoid (cicatricial pemphigoid). *Clin Dermatol.* 2012, 30(1):34-37.

[96] Saw VP, Dart JK; Ocular mucous membrane pemphigoid: diagnosis and management strategies. *Ocul Surf.* 2008, 6(3):128-142.

[97] Ahmed M, Zein G, Khawaja F, Foster CS; Ocular cicatricial pemphigoid: pathogenesis, diagnosis and treatment. *Prog Retin Eye Res.* 2004, 23(6):579-592.

[98] Queisi MM, Zein M, Lamba N, Meese H, Foster CS; Update on ocular cicatricial pemphigoid and emerging treatments. *Surv Ophthalmol.* 2016, 61(3):314-317.

[99] Kopacz D, Maciejewicz P, Kęcik D; Postać oczna pemfigoidu bliznowaciejącego – patogeneza i leczenie/ Ocular Mucous Membrane Pemphigoid – Pathogenesis and Treatment. *Okulistyka* 2/2016:7-9

[100] Arstikaitis MJ; Ocular aftermath of Stevens-Johnson syndrome. *Arch Ophthalmol.* 1973;90(5):376-379.

[101] Ralph RA; Conjunctival goblet cell density in normal subjects and in dry eye syndromes. *Invest Ophthalmol.* 1975, 14(4):299-302.

[102] Wright P, Collin JR; The ocular complications of erythema multiforme (Stevens Johnson syndrome) and their management. *Trans Ophthalmol Soc U K.* 1983, 103(Pt 3):338-341.

[103] Lin A, Patel N, Yoo D, DeMartelaere S, Bouchard C; Management of ocular conditions in the burn unit: thermal and chemical burns and Stevens-Johnson syndrome/toxic epidermal necrolysis. *J Burn Care Res.* 2011, 32(5):547-560.

[104] Kim D, Kim HJ, Hyon JY, Wee WR, Shin YJ. Effects of oral mucolytics on tear film and ocular surface. *Cornea.* 2013, 32(7):933-938.

[105] Murube J, Nemeth J, Hoh H, Kaynak-Hekimhan P, Horwath-Winter J, Agarwal A, Baudouin C, Benítez del Castillo JM, Cervenka S, ChenZhuo L, Ducasse A, Durán J, Holly F, Javate R, Nepp J, Paulsen F, Rahimi A, Raus P, Shalaby O, Sieg P, Soriano H, Spinelli D, Ugurbas SH, Van Setten G; The triple classification of dry eye for practical clinical use. *Eur J Ophthalmol.* 2005, 15(6):660-667.

[106] Truong S, Cole N, Stapleton F, Golebiowski B. Sex hormones and the dry eye; *Clin Exp Optom.* 2014, 97(4):324-336.

[107] Dang A, Nayeni M, Mather R, Malvankar-Mehta MS; Hormone replacement therapy for dry eye disease patients: systematic review and meta-analysis. *Can J Ophthalmol.* 2020, 55(1):3-11.

[108] Moschos MM, Nitoda E.; The impact of combined oral contraceptives on ocular tissues: a review of ocular effects. *Int J Ophthalmol.* 2017, 10(10):1604-1610.

- [109] Modulo CM, Jorge AG, Dias AC; Influence of insulin treatment on the lacrimal gland and ocular surface of diabetic rats. *Endocrine* 2009, 36:161-168
- [110] Alves M, Dias AC, Rocha EM; Dry eye in childhood: epidemiological and clinical aspects. *Ocul Surf* 2008, 6:44-51
- [111] Courtin R, Pereira B, Naughton G, Chamoux A, Chiambaretta F, Lanhers C, Dutheil F; Prevalence of dry eye disease in visual display terminal workers: a systematic review and meta-analysis. *BMJ Open*. 2016, 6(1):e009675.
- [112] Hanyuda A, Sawada N, Uchino M, Kawashima M, Yuki K, Tsubota K, Yamagishi K, Iso H, Yasuda N, Saito I, Kato T, Abe Y, Arima K, Tanno K, Sakata K, Shimazu T, Yamaji T, Goto A, Inoue M, Iwasaki M, Tsugan S; Physical inactivity, prolonged sedentary behaviors, and use of visual display terminals as potential risk factors for dry eye disease: JPHC-NEXT study. *Ocul Surf*. 2020, 18(1):56-63.
- [113] Mann A, Tighe B. Contact lens interactions with the tear film; *Exp Eye Res*. 2013, 117:88-98.
- [114] Lim CHL, Stapleton F, Mehta JS.; Review of Contact Lens-Related Complications. *Eye Contact Lens*. 2018, 44 Suppl 2:S1-S10.
- [115] Alipour F, Khaheshi S, Soleimanzadeh M, Heidarzadeh S, Heydarzadeh S; Contact Lens-related Complications: A Review. *J Ophthalmic Vis Res*. 2017, 12(2):193-204.
- [116] Ohtsuki M, Yokoi N, Mori K, Matsumoto Y, Adachi W, Ishibashi K, Sato M, Kinoshita S; [Adverse effects of beta-blocker eye drops on the ocular surface]. *Nippon Ganka Gakkai Zasshi*. 2001, 105(3):149-154.
- [117] Nielsen NV, Eriksen JS; Timolol transitory manifestations of dry eyes in long term treatment. *Acta Ophthalmol (Copenh)*. 1979, 57(3):418-424.
- [118] Lee SM, Lee JE, Kim SI, Jung JH, Shin J; Effect of topical glaucoma medication on tear lipid layer thickness in patients with unilateral glaucoma. *Indian J Ophthalmol*. 2019, 67(8):1297-302.
- [119] Zernii EY, Golovastova MO, Baksheeva VE, Kabanova EI, Ishutina IE, Gancharova OS, Gusev AE, Savchenko MS, Loboda AP, Sotnikova LA, Zamyatnin Jr AA, Philippov PP, Senin II; Alterations in Tear Biochemistry Associated with Postanesthetic Chronic Dry Eye Syndrome. *Biochemistry (Mosc)*. 2016, 81(12):1549-57.
- [120] Bielory L; Ocular toxicity of systemic asthma and allergy treatments. *Curr Allergy Asthma Rep*. 2006, 6(4):299-305.
- [121] Norn M; The effect of drugs on tear flow. *Trans Ophthalmol SOc UK* 1985, 104:410-414.
- [122] Sraux F, Martin P, Morax S, Offert H; Hyposecretion lacrimale et medicaments psychotropes. *Ann Ocl* 1976, 209:193-197
- [123] Askeroglu U, Alleyne B, Guyuron B; Pharmaceutical and herbal products that may contribute to dry eyes. *Plast Reconstr Surg*. 2013, 131(1):159-167
- [124] Maciejewicz P, Kopacz D; Substancje pomocnicze zawarte w kroplach do oczu/The Pharmaceutical Excipients Commonly Used in Eye Drops. *Okulistyka* 2016, 1:33-36
- [125] Walsh K, Jones L. The use of preservatives in dry eye drops. *Clin Ophthalmol*. 2019;13:1409-1425.