

We are IntechOpen, the world's leading publisher of Open Access books Built by scientists, for scientists

6,900

Open access books available

186,000

International authors and editors

200M

Downloads

Our authors are among the

154

Countries delivered to

TOP 1%

most cited scientists

12.2%

Contributors from top 500 universities



WEB OF SCIENCE™

Selection of our books indexed in the Book Citation Index
in Web of Science™ Core Collection (BKCI)

Interested in publishing with us?
Contact book.department@intechopen.com

Numbers displayed above are based on latest data collected.
For more information visit www.intechopen.com



Imaging and Diagnosis for Planning the Surgical Procedure

Ferdinand Bauer

Abstract

The preoperative imaging diagnosis of rectal cancer lies at the heart of oncological staging and has a crucial influence on patient management and therapy planning. Rectal cancer is common, and accurate preoperative staging of tumors using high-resolution magnetic resonance imaging (MRI) is a crucial part of modern multidisciplinary team management (MDT). Indeed, rectal MRI has the ability to accurately evaluate a number of important findings that may impact patient management, including distance of the tumor to the mesorectal fascia, presence of lymph nodes, presence of extramural vascular invasion (EMVI), and involvement of the anterior peritoneal reflection/peritoneum and the sphincter complex. Many of these findings are difficult to assess in non-expert hands. In this chapter, we present currently used staging modalities with focus on MRI, including optimization of imaging techniques, tumor staging, interpretation help as well as essentials for reporting.

Keywords: rectal cancer, staging, MRI, protocol, reporting, 3D imaging

1. Introduction

The preoperative imaging diagnosis of rectal cancer lies at the heart of oncological staging and has a crucial influence on patient management and therapy planning. Computer tomography (CT) with intravenous contrast medium is the standard method to exclude metastases in the liver and lungs. However, the current state-of-the-art modality for local staging of the tumor is magnetic resonance imaging (MRI). Its new development, 3D MRI, seems to bring additional valuable possibilities for the surgery planning of rectal cancer.

1.1 Multidisciplinary management team (MDT) in rectal MRI

Due to the multitude of treatment options available today for the treatment of rectal cancer, it became an international standard (e.g. in [1]) that a multidisciplinary team (MDT) discusses each patient situation pre-therapeutically in a tumor conference. This procedure ensures that all therapeutic options are considered as necessary for the patient's benefit. The basis for these discussions and decisions of the MDT is in most cases the imaging findings. Magnetic resonance imaging (MRI) of the pelvis has become of central importance in recent years, as it can best depict the relationship of the tumor to the mesorectal fascia and the other structures of the pelvis.

In order to make good therapeutic decisions, an MRI must not only be carried out in a technically adequate manner, but must also be interpreted and presented accordingly. Moreover, the radiologist should also have a basic understanding of the various available therapy options. In particular, it is important to understand the surgery relevant aspects in order to have a target-oriented interdisciplinary discussion. Similarly, the treatment partners should also have basic knowledge of the findings and interpretation of MRI in order to be able to understand the findings of the radiologist.

2. Magnetic resonance imaging (MRI) basics

2.1 Useful MRI sequences

T1 weighted sequences (T1w) are highly sensitive to fat, marrow and gadolinium contrast media, which are able to detect a high intensity signal, so they appear light in T1w images. On the other hand, water retrieves a low intensity signal, so it appears dark. Therefore, you recognize T1w images by the dark gray representation of water, e.g. urine in the bladder, and by the almost white representation of fat, like in the bone marrow. T1w sequences are important particularly for the examination of the pelvic lymph nodes and the bone marrow.

T2 weighted sequences (T2w) are the most important sequences for MRI pelvic imaging. They provide high-resolution anatomical images that allow an accurate representation of the rectal carcinoma and its relationship to surrounding structures. It depicts the mesorectal fascia (CRM) as a thin line of low T2-signal intensity. You may easily recognize the T2w-images by their parameters: the signal-rich representation of water, e.g. urine in the bladder, and the signal-rich representation of fat. T2-weighted (T2w) sequences are water-sensitive, so water is signal-rich (light), whereas fibrotic tissue with low water content is signal-poor (dark). Paradoxically, fat also appears signal-rich (light) in T2w-images, which makes it difficult to distinguish from water in individual cases. A specific suppression of the fat signal might help here. However, since fat suppression techniques (FS) all lead to a loss of signal and thus either to increased image noise or to limited spatial resolution, they are not recommended for pelvic imaging - only after intravenous administration of gadolinium chelates contrast agent. In addition, FS techniques reduce the contrast between the low-signal rectal carcinoma in the T2 weighting and the signal-rich mesorectal fat tissue, which has a negative impact on the exact spread of the disease.

Diffusion weighted imaging (DWI) is achieved using diffusion-sensitive gradients in fast T2w sequences. DWI, in contrast to T1 and T2 measurement (excellent for morphological properties) is an **in vivo measurement** and shows the mobility of water molecules in different tissues (normal, tumorous, or fibrotic tissue). The limited diffusion in malignant tissue leads to a higher signal (bright) on the DW images. Tumors therefore usually appear bright on DWI images, while their lower diffusivity then leads to a low signal on ADC maps. DW sequences have the lowest spatial resolution of all sequences used in routine clinical protocols due to limitations in the signal-to-noise ratio, and they are susceptible to artifacts and distortion. These distortions are particularly pronounced at air-tissue boundaries (e.g. intestine) and OP clips. Moreover, the DWI technique necessarily requires fat saturation, so that fat presents itself with little or no signal. For spatial orientation, we always take corresponding anatomical images using T2w sequences.

Diffusion-weighted sequences are optional for the primary staging of rectal carcinoma, but we strongly recommend including them into the standard MRI protocol, as they can significantly facilitate the localization of the tumor and lymph

nodes, and later restaging. MRI examinations for restaging of the rectal carcinoma after neoadjuvant therapy should contain a DWI sequence in order to be able to detect or exclude vital tumor remnants.

2.2 Patient preparation

2.2.1 Bad diagnosis always begins with bad patient preparation

Contrary to what is still being claimed, preparation of the bowel by means of enema (clyster or micro clyster) immediately prior to the examination is extremely important. We want to perform a high-precision examination similar to colonoscopy in a clean medium and not in a contaminated organ. The patient will always be informed in detail about the exact procedure of the examination, and this ensures active cooperation in most cases. This way, we minimize restlessness and movement artifacts. After flushing with Microlax Rectal Solution, the rectum is filled with warm tap water. Water is an excellent contrast medium without risking distension of the intestinal wall. In our department, we only use ultrasound gel for MRI defaecography, but not for tumor diagnosis, as the expansion of the rectum due to compression may restrict the assessment of the mesorectal space. Water as contrast medium allows an exact detection of even small flat lesions, which may be the case after RCT. Another advantage is the elimination of air besides stool residues. This procedure also creates perfect conditions for high quality DWI, which plays a particularly important role in restaging. Air is an enemy and real falsificator of DWI measurements! Last but not least, we prepare an infusion for administration of butylscopolamine to reduce intestinal motility, and for administration of contrast agent, if necessary.

Having this done, specially trained medical-technical staff accompanied by doctors trained in rectal MRI perform the actual MRI examination. They always follow a standardized protocol with particular attention to angulation. The main axial layers must always be orthogonal to the tumor. Only in this way can the MRI results correspond with histology in terms of local tumor staging, and measurement of infiltration depth and distance to the mesorectal fascia. Furthermore, it is important to ensure that the restaging examination is always performed with the same equipment as the primary staging examination was done. Our experience has shown that different devices (e.g. Siemens vs. Phillips) deliver different DWI, which can make precise restaging difficult. These organizational challenges can only be overcome if we are all aware of them.

2.3 Examination protocol

Rectal MRI can be performed routinely on a 1.5 T or 3 T system and takes about 25 minutes. However, our surgery department prefers 3 T systems because of their clearly higher resolution, shorter examination time, and the possibility of performing 3D imaging. A limited FOV ("field of view") is recommended, as it allows both accurate local tumor diagnosis, and excellent imaging of the mesorectum and adjacent organs.

We begin with a sagittal T2-weighted turbo spin echo (TSE) sequence, which serves as the planning sequence for the second axial thin-layer (3 mm) T2 TSE sequence and is the decisive sequence of the rectal protocol. Axial in this context always means perpendicular to the carcinoma, so that depending on the extent and location of the tumor, paraaxial, axial or paracoronary layers result!

The mandatory and most important measurements, done in mm, such as tumor infiltration depth into the mesorectum and the tumor distance to the mesorectal fascia, are performed based on these paraaxial images. If the radiological department performs accurately, then the measured values and the tumor staging correspond to

the histological results. Radiologists achieve this performance only after a relatively long learning curve. We always correlate our results with the pathology results during the tumor board.

Tips for the high resolution T2 axial sequence

- Must be angled perpendicular to the tumor. The invasive center (the part of the tumor extending the most within the mesorectal fat) of the tumor must be detected on the sagittal plane. It is at this level where the sequence must be angled perpendicularly to the tumor.
- Sometimes, it may be necessary to obtain more than one sequence angulation for optimal assessment in bulky tumor masses.
- A slice thickness of 3 mm or less is recommended.

As mentioned above, in deep carcinomas (lower third of the rectum) a **coro-nary** T2w TSE sequence is obligatory in order to detect or exclude infiltration of the muscle levator ani (T4 stage) or to diagnose infiltration of the anal canal. For deep carcinomas, we recommend to perform a Gd-enhanced T1 weighted axial and

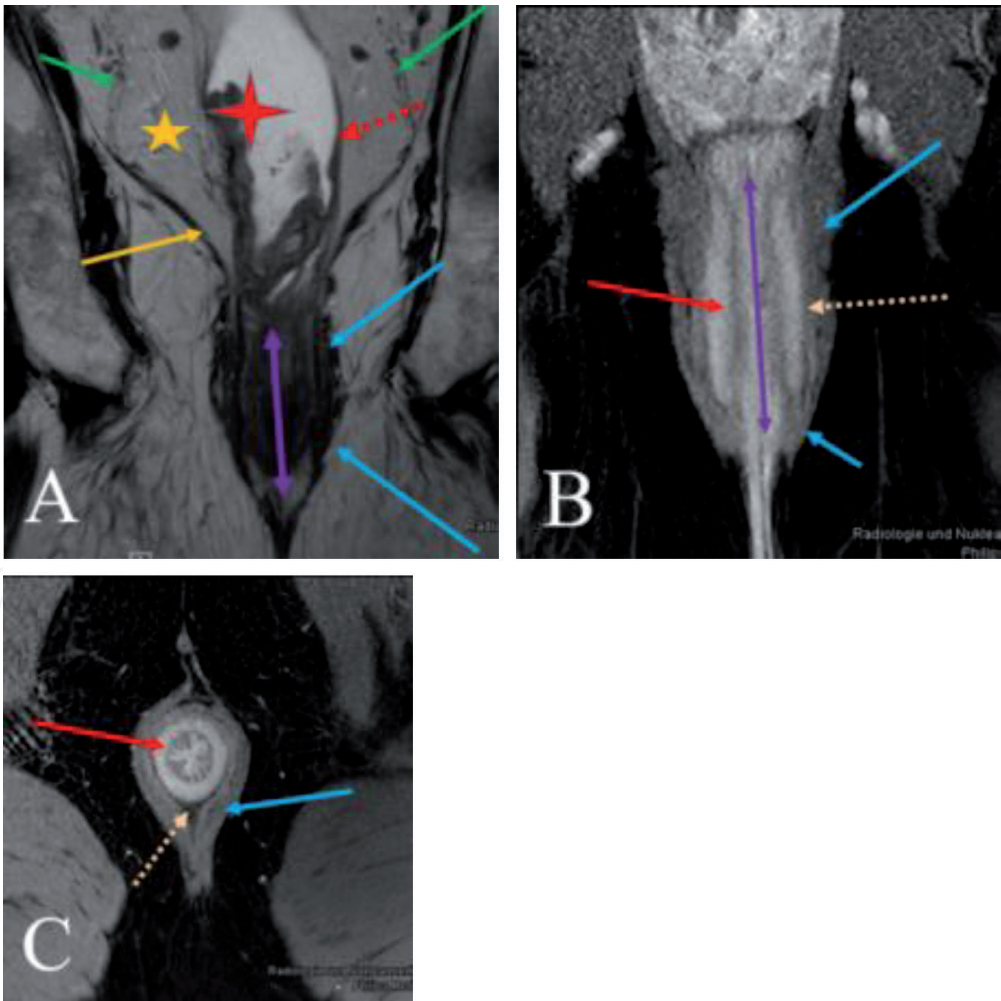


Figure 1.
A. Paracoronar T2WI, no enhancement, shows a lower rectal T2 stage tumor without infiltration of the mesorectum, levator ani or anal canal. B. Gd enhanced paracoronar T1FS, anal canal. C. Gd-enhanced axial T1 FS. Markings: Yellow arrow: Levator ani; Yellow star: end of mesorectum; Green arrow: FMR = CRM; Red star: tumor; Red dashed arrow: muscularis propria; Red plain arrow: internal anal sphincter (IAS); Blue plain arrow: external anal sphincter (EAS); Purple double arrow: anal canal; and Yellow dashed arrow: intersphincteric plane (ISP). Source: F. Bauer, Radiology Kaufbeuren.

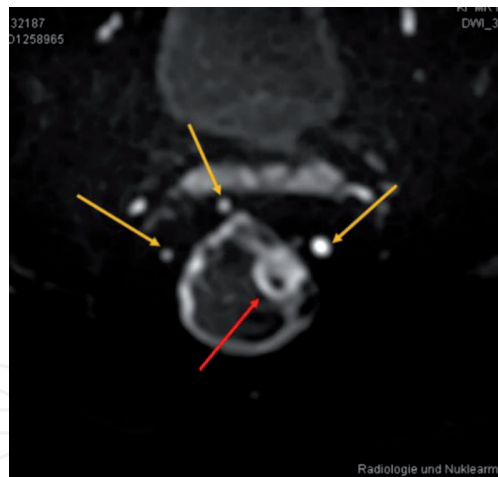


Figure 2.
 Axial DWI-T2W image of a rectal cancer. Note the good demarcation of the tumor (red arrow) and of some irregular intramesorectal lymph nodes (yellow arrows) with the same signal intensity as the tumor. DWI is good in nodal detection, but has no value in assessing nodal malignancy. Source: F. Bauer, Radiology Kaufbeuren.

coronal gradient echo sequence with fat saturation (GRE fs) as standard. These sequences depict the infiltration of the anal canal more accurately than with the native T2 sequence alone, **Figure 1A and B**.

Another important part of the MRI rectal protocol is the preparation of diffusion-weighted sequences (DWI-MRI) including the quantitative measurement of ADC values (*apparent diffusion coefficient*), which in particular provides valuable additional information for the evaluation of therapy response after neoadjuvant radiochemotherapy. DWI is also very helpful for detection of lymph nodes (**Figure 2**), but it is not suitable for determining their benignity or malignancy, because in both cases the lymph nodes have a high cellularity [2].

Since about 12 months, we included the 3D volume measurement into the standard protocol, when using modern 3 T systems with newest hardware and software. This supplementary measurement takes about 5 minutes.

2.4 Clinically relevant embryology of rectum and anal canal

Rectum and anal canal emerge from the part of the endodermal intestinal tract known as the hindgut. At the ventrocaudal end (approx. 5th week of development) this has a sack-shaped dilatation, cloaca, which is closed to the outside by the cloacal membrane. The cloaca lined with endoderm provides not only the epithelial lining for the rectum and anal canal, but also for the bladder and urethra. Through growth or proliferation of the urorectal septum in the direction of the cloacal membrane (approx. 7th week of development), the cloaca is divided into the ventrally located urogenital sinus and the dorsally located anorectum. The cloacal membrane, which consists of epithelial cell clusters, disappears by apoptosis (rupture of the cloacal membrane), so that the urethral and anal canals are each open to the outside. The tip of the urorectal septum has now reached the body surface and forms the future perineum. Through the use of refined methods it has been disproved for decades that the cloacal membrane is the place where the endoderm and ectoderm meet.

Proliferating epithelial cell clusters, so-called anal membrane, temporarily displace the anal opening. This lies at the level of the linea pectinata, which can already be detected at this point by the different immunohistochemical behavior of the surface epithelia. The epithelial closure disappears in the 8th week of development. In the following 9th week of development, the different epithelia proliferate and differentiate and the columnae and sinus anales are formed, thus not only the linea dentata is clearly

marked, but the epithelial border between high-prismatic (cubic) epithelium and squamous epithelium becomes clear. In the mesenchyme around the anorectum, the smooth inner ring muscle layer differentiated, reaching with a thickened end in the 8th week of development to the level of the Linea pectinata. The outer longitudinal muscle layer differentiates with a time delay in craniocaudal direction [3].

Conclusion: Only the rectum part above the linia anorectalis emerges from the endoderm, similarly to the colon. The anal canal emerges from the ectoderm, and for this reason, some authors do not consider it as belonging to the rectum.

3. Normal anorectal anatomy in MRI and the fasciae

In MRI, we can divide the rectum into three sections based on its three lateral curvatures (in analogy to the Houston valves inside).

The upper two thirds are surrounded anterolaterally (upper third) and anteriorly (middle third) by the visceral peritoneum. This forms the anterior peritoneal fold approximately at the level of the middle curve (in the area of the so-called Kohlrausch's fold) and thus delimits the upper two thirds of the rectum from the extraperitoneally located wide lumen rectal ampulla.

The anterior peritoneal fold has a specific shape in axial stratification, which resembles the appearance of a seagull, hence the name "seagull sign" (**Figure 3C**).

As mentioned in 2.3, T2-weighted sequences optimally depict the individual wall layers of the rectum:

1. Submucosa, represented as an inner layer of high intensity. Appropriate examination parameters (see below), allow even to differentiate between mucosa and submucosa. In this case, the mucosa stands out as a fine low intensity line against both the positively contrasted intestinal lumen and the high intensity submucosa;
2. Muscularis propria, represented as a further adjacent layer of intermediate to low signal intensity.
3. Mesorectal fat, the natural barrier to tumor spread, represented as an outer layer of high intensity.

The mesorectal fascia (MRF) represents an important boundary structure for the description of the tumor extension and is well recognizable in T2-weighted sequences as a thin linear structure of low signal intensity.

The mesorectal fascia encases the perirectal (so-called mesorectal) fat including lymph nodes and vessels and represents an important natural barrier to tumor spread [4]. It corresponds to the so-called circumferential resection margin (CRM), which determines the extent of surgical resection in the context of total mesorectal excision (TME) [5], as seen in **Figure 3A** and **B**. At the level of the anterior peritoneal fold, the MRF fuses with the peritoneum. From this point on, the proportion of mesorectal fat decreases continuously until neither fat nor fascia are visible in imaging at the level of the anorectal transition. Inferiorly, the rectum fuses with the anal sphincter complex (Sphincter ani externus and internus).

The external sphincter consists of striated muscles, can be defined as a hypointense structure in all sequences in the MRI and only slightly accumulates contrast medium after gadolinium administration (a typical feature of striated muscles).

The boundary between the rectum and the anal canal can be easily recognized in MRI by the complex of the muscle levator ani at the upper end of the anal canal, which

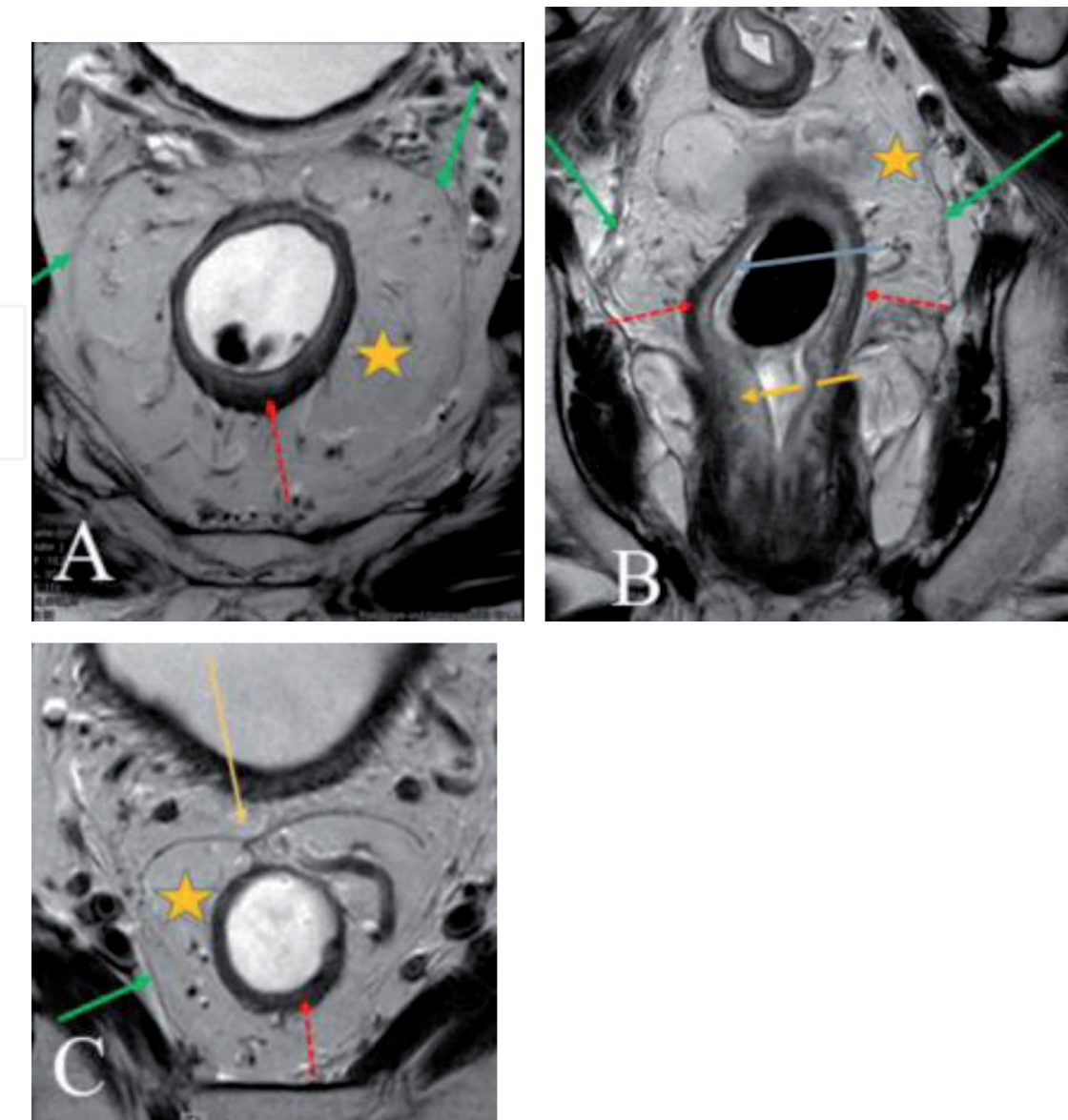


Figure 3.
Normal rectal wall in high-resolution MRI. A. Paraaxial T2WI depicts well layers of the rectal wall around the high-intensity intestinal lumen (filled with water): low intensity muscularis propria (red arrow) and high intensity mesorectal fat (yellow star) including lymph nodes and vessels. MRF (green arrow) is shown as a very thin line of low intensity surrounding the mesorectum. This line is crucial for surgery planning, as it represents the CRM (MRF=CRM). B. Paracoronal T2WI depicts additionally the low intensity mucosa (blue arrow), followed by the high intensity submucosa (yellow arrow) followed by again a low intensity structure, the muscularis propria. C. Paraaxial T2WI depicts the anterior peritoneal fold “Seagull sign” (yellow arrow). Source: F. Bauer, Radiology Kaufbeuren.

fuses with the muscle layer of the inferior rectum [5]. The internal sphincter represents a sort of expansion of the circular muscle layer of the Muscularis propria of the rectum and consists of smooth muscle. In both T1-weighted and T2-weighted sequences it has an intermediate signal intensity. We use Gd-enhanced MRI with i.v. administration of the contrast agent to highlight the internal sphincter, **Figure 1B** and **C**.

4. Tumor morphology with MRI

By far the most common rectal adenocarcinoma, up to 90%, in MRI may appear as solid, polypoid or flat lesions within the intestinal wall, whereas the aspect of an annular or semiannular mass and growing with varying degrees of stenosis is the most frequent image.

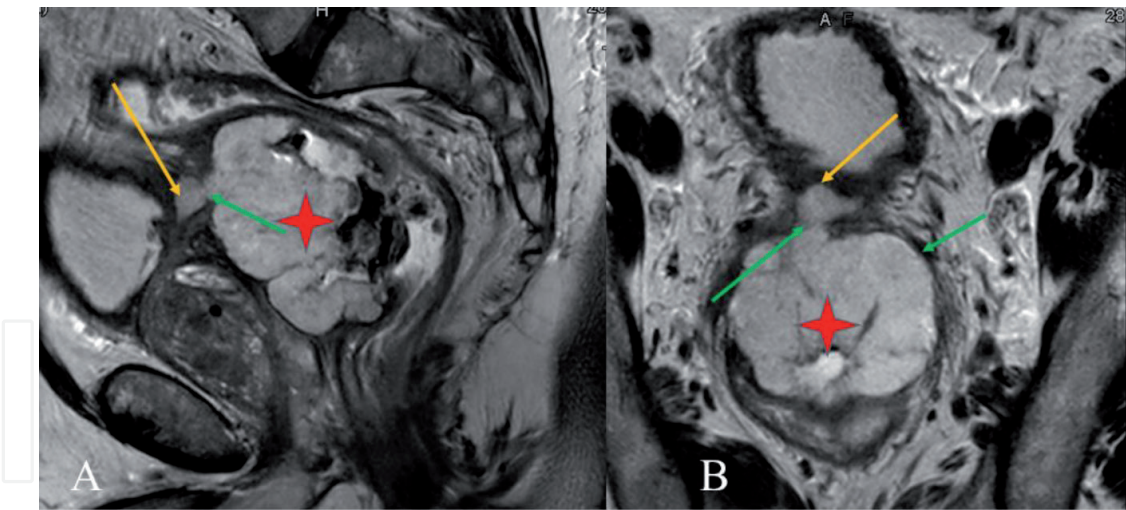


Figure 4.
A. Axial T2w image shows a low-lying mucinous tumor of high signal (red star) disrupting the mesorectal fascia (green arrows) and extending into the dorsal bladder wall (yellow arrow). B. The very large mucinos adenocarcinoma (signet-ring) with a central scar situated in the middle third of the rectum with complete infiltration of the mesorectum, and of the dorsal bladder wall at 12 o'clock. Stage: T4, CRM+, No, EMVI. Histology confirmed this result. Source: F. Bauer, Radiology Kaufbeuren.

Less rectal tumors, up to 10%, may contain mucin, and mucinous tumors have a poor prognosis and a high risk of spillage during surgery [6]. MRI depicts these tumors well on T2w as well delimited high intensity masses, **Figure 4**.

As described above, T2-weighted sequences under optimal conditions can differentiate the wall layers of the rectum. The vast majority of carcinomas have a higher signal than the hypointense (not always controllable) mucosa, but a lower signal than the clearly hyperintense submucosa. Exceptions to this are, on the one hand, mucinous carcinoma and on the other hand, sigmoid ring cell carcinoma [7].

After administration of contrast medium, the entire rectal wall is clearly hyperintense and the individual wall layers can no longer be differentiated from each other. Therefore, the native T2-weighted sequences should be used for the primary diagnosis of the T category.

5. Local staging with MRI

The assessment of the findings obtained with MRI should be based on the TNM system. However, the MRI also provides other essential information, such as the distance of the tumor to the circumferential resection margin (CRM), and the tumoral invasion of the venous structures beyond the muscularis propria (EMVI). This additional information must be included in the report as well.

Multiple studies have proved the added value of structured reporting in rectal cancer [8–10], and resulted in many proforma available online. The diagnosis is ideally carried out using a structured report (SR) like our Structured Report (see Appendix at end of this chapter) for Primary Staging of Rectal Carcinoma at our Imaging Center (www.radiologie-kaufbeuren.de).

The report should include both the appearance of the tumor (e.g. ulcerative growth), as well as its minimum distance from anus. In addition, the craniocaudal tumor extent and the positional relationship of the tumor to the peritoneal fold should be reported. Furthermore, the radius of the carcinoma in the intestinal wall according to lithotomy position (SSL), whether the muscularis propria is infiltrated or whether extramural growth is already present should be reported.

5.1 T-staging

Rectal cancer staging is based on the TNM (tumor, nodes, and metastases) system. In this context, a **stage T1** disease passes through the mucosa and submucosa but does not infiltrate the muscularis propria.

A **stage T2** (**Figure 5A**) disease infiltrates additionally the muscularis propria.

The more advanced **stage T3** (**Figures 5B, 6, and 7**) disease infiltrates the muscularis propria and goes beyond into the mesorectum. This stage T3 has been further split into substages **a, b, c, and d** to categorize the depth of extramural invasion, as follows: < 1 mm = T3a; 1–5 mm = T3b; > 5–15 mm = T3c, and > 15 mm = T3d (**Figures 6 and 7**).

The last stage, **T4**, also divides into two subclasses, **a**, and **b**. Substage **T4a** is diagnosed when the tumor involves visceral peritoneum or anterior peritoneal reflection, while **T4b** is diagnosed when the tumor invades at least one adjacent organ, see **Figure 8**.

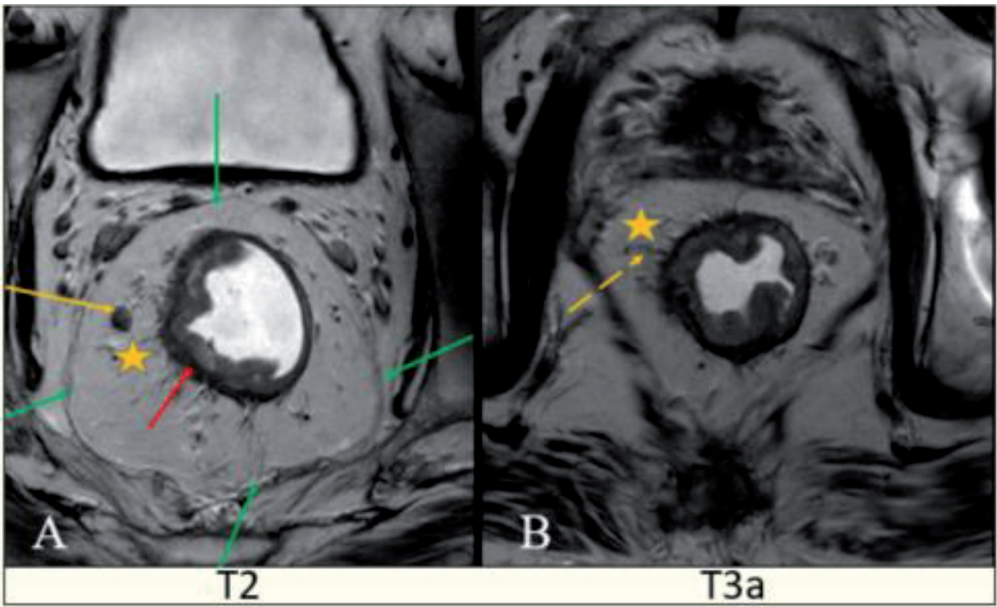


Figure 5.
A. Paraaxial T2w image shows a rectal tumor which invades the muscularis propria (red arrow) but does not penetrate its external margin. Note the fine spiculations towards the mesorectum (yellow star), and the irregular heterogeneous nodes of same signal intensity as the tumor, indicating potential nodal involvement (yellow arrow). Diagnosis: T2, N1, CRM-, EMVI-, which was confirmed by histology (T2 with “desmoplastic reaction” and nodal metastasis). B. Rectal tumor stage T3a. Note the similarity to A: tumor extensions (yellow arrow) into the mesorectal fat (yellow star). Source: F. Bauer, Radiology Kaufbeuren.

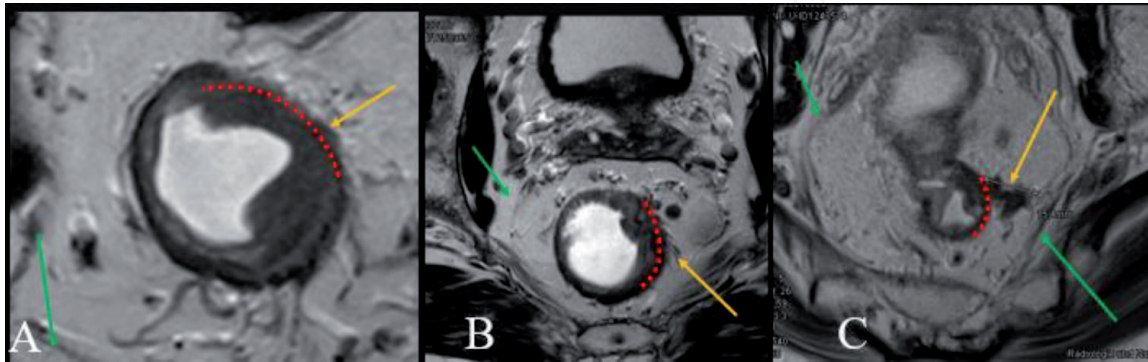


Figure 6.
Short axis axial high-spatial-resolution T2w images of different sub-classifications of T3 tumors with extramural spread (arrow): A. T3a (<1 mm), B. T3b (1–5 mm), C. T3c (>5–15 mm). Markings: mesorectal involvement (yellow arrow), muscularis propria (red dashed line), and CRM = FMR (green arrow). Source: F. Bauer, Radiology Kaufbeuren.

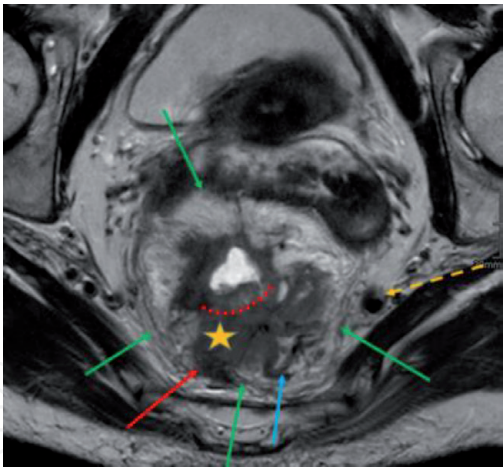


Figure 7. Axial T2wi shows a rectal tumor (yellow star) staged: T3d (>15 mm), CRM+, EMVI+, N1). The extramural spread is measured from the level of the supposed muscularis propria (red dashed line) to the maximal point of mesorectal involvement (red arrow). Notice also the invasion of the venous structures (EMVI, blue arrow) and the extramesorectal metastatic node (yellow arrow). This node group will not be removed in a regular TME! CRM = FMR (green arrow). Source: F. Bauer, Radiology Kaufbeuren.

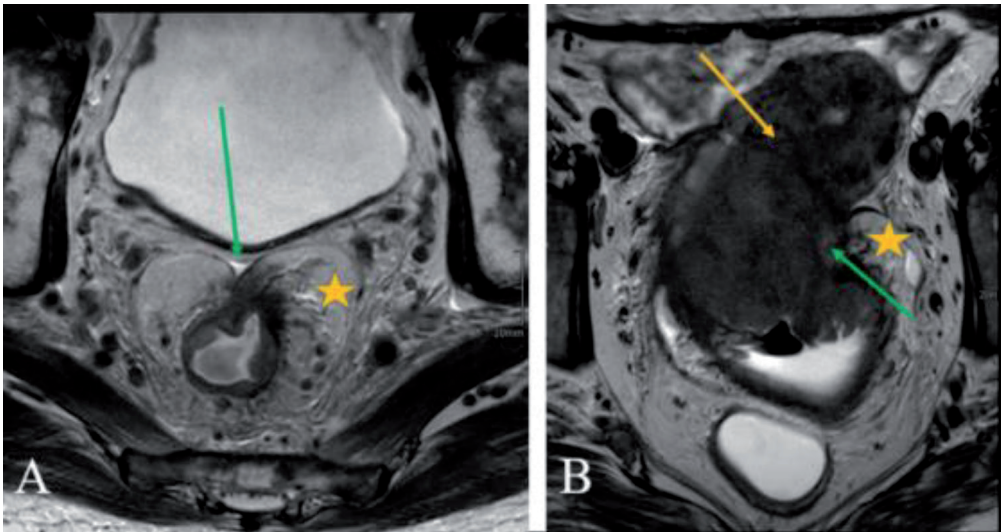


Figure 8. A. Stage T4a tumor involves visceral peritoneum or anterior peritoneal reflection (green arrow). B. Stage T4b tumor involves an adjacent organ, uterus (yellow arrow), and the mesorectum (yellow star). Source: F. Bauer, Radiology Kaufbeuren.

Several histopathologic studies have shown that T3 tumors with more than 5 mm mesorectal invasion have a cancer-specific 5-year survival rate of approximately 54% [11]. On the other hand, for tumors of 5 mm or less in diameter, the cancer-specific survival exceeds 85% [12, 13]. Therefore, it is crucial to report the depth of extramural spread in detail, with the precise substage **T3a, b, c** or **d**. The overall reported accuracy for T staging using a pelvic phased-array coil ranges from 59% to 95% [12, 13]. Differences in T2 signal intensity between the tumor, submucosa, muscular layer, and mesorectum play the main role while detecting and staging rectal cancers using MRI.

T stage must be assessed on planes strictly perpendicular to the tumor. Incorrect prescription of the acquisition plane leads to blurring of the muscularis propria and may lead to overstaging. When the tumor is not visible on sagittal T2 WI: obtaining high-resolution images of the entire length of the rectum and adding DWI may help localize the mass. The depth of extramural spread must be measured in millimeters beyond the outer edge of the longitudinal muscular layer [13], as depicted in **Figures 5, 6** and **7**.

Al-Sukhni et al. [9] published a meta-analysis (21 studies between 2000 and 2011) on the diagnostic accuracy of MRI and found a high overall accuracy in the assessment of the T-stage with a sensitivity of 87% and a specificity of 75%.

5.1.1 Challenges for T-staging

Differentiation between T2 and borderline T3 lesions is still challenging today. The main issue is to distinguish true mesorectal tumor invasion from desmoplastic reactions [14]. In this case, the inflammatory accompanying reaction in the adjacent mesorectal fat masks the actual tumor spread. In particular, fine spicular extensions in the mesorectum should be evaluated carefully - if these are mistakenly interpreted as a tumor (T3 instead of T2), overstaging and thus overtherapy may occur.

One often error source is the use of thicker sections and lower resolution techniques. Therefore, using fine sections in T2WI should help clarifying such cases. Indeed, desmoplasia associated with ulcerating tumors at the invasive border is typically seen as fine low-signal-intensity spicules on T2WI. These spicules do not show restricted diffusion. Tumor extension into the mesorectum, on the other hand, forms thicker, intermediate signal- intensity nodular bands with restricted diffusion and disruption of muscularis propria [15].

From the therapeutic point of view, the differentiation between T2 and T3a, b stages is not important since the treatment of these lesions is identical: TME alone or short term RCT followed by TME.

5.1.2 Specific issues related to low-lying tumors

Low-rectal tumors are associated with higher rates of positive resection margins, higher local recurrence rates, and poorer survival [16]. This is largely due to anatomic considerations and the fact that the mesorectal envelope tapers and narrows at this level. These rates can be improved by using CRT in locally advanced low-rectal tumors. The results show a good response with higher sphincter preservation rates and disease-free survival [15]. In consequence, a tumor that would have previously required an abdominoperineal excision may instead be treated with ultralow resection and coloanal anastomosis.

Our experience has shown that, particularly in the case of low-lying tumors, the primary surgical concept changed relatively often after CRT and restaging. Consequently, tumors that had required abdominoperineal excision before CRT only needed ultralow resection and coloanal anastomosis after CRT.

All these require a very good quality MRI beforehand, to define the location of the tumor relative to the sphincter complex precisely, so that we select correctly the patients who will profit from preoperative CRT.

For the assessment of the anal canal, T1w lipid-saturated T1FS sequences with contrast medium are superior to T2w-sequences, since m. levator ani and m. sphincter ani externus are reliably separated from m. sphincter ani internus due to their signal and contrast medium behavior.

Rectal carcinoma usually shows low signal intensity compared to the normal intestinal wall and sphincters. **Stage T3** implies the infiltration of the external sphincter. At **stage T4**, the tumor infiltrates also of the m. levator ani. As a matter of fact, as soon as a rectal carcinoma crosses the mesorectal fascia and infiltrates the visceral peritoneum, the diagnosis is T4. Here, it must be differentiated whether adjacent organs (vagina, uterus, ovaries, prostate, seminal vesicles, bladder and ureter) are reached by the tumor (T4b) or whether only the visceral peritoneum (T4a) is infiltrated (**Figure 8A and B**). The contact of the tumor with surrounding

organs (without a preserved fat layer adjacent to the organ) automatically requires classification as T4 in the findings report, even if the adhesion later turns out histopathologically to be a peritumorous inflammation.

Tips for T-staging of low-lying tumors with MRI

- Protocol of choice: High-spatial-resolution T2W and T1 FS coronal imaging after i.v. administration of Gd, because it depicts optimally the tumor relationship with the levator and puborectal muscles, sphincter complex, and intersphincteric plane, as depicted in **Figure 1A**, and **B**.
- First focus on the location of the lower edge of the tumor in relation to the puborectalis sling:
 - a. If tumor is located above the puborectalis sling: sphincter involvement can be easily excluded.
 - b. If the tumor extends below the puborectalis sling, 3 areas have to be evaluated and reported on, **Figure 1B**, and **C** (see Appendix on structured reporting).
 1. The internal sphincter (IAS)
 2. The intersphincteric plane (ISP)
 3. The external sphincter (EAS)
- In case of stage T4: Levator and puborectalis muscles or external sphincter are involved.

5.2 Mesorectal fascia (MRF) = Circumferential resection margin (CRM)

A central component of preoperative local staging is the assessment of the distance of the tumor from the mesorectal fascia (MRF) and thus from to the circumferential resection margin (CRM). CRM infestation is an important prognostic indicator for the occurrence of local recurrences [5].

In the case of MRI-based surgery of the rectum, we deliberately equated fascia mesorectalis (MRF) with Circumferential Resection Margin (CRM) in the MDT conference, which naturally led to a need for clarification at the beginning of the discussions. In the meantime, this discussion has been clarified, if one considers the following anatomical and surgical conditions.

The CRM is the non-peritoneal surgical resection plane that is prepared during surgery and has no direct anatomical correlate in the MRI, as it is de facto only determined by the surgeon during the procedure. In practice, however, the surgeon orients himself or herself on the MRF, so that the MRF serves as the most important anatomical landmark in preoperative staging and is practically equated with the surgical resection plane. Accordingly, the visceral peritoneum or peritoneal flap are not part of the CRM, as they cannot be influenced by the surgeon. Consequently, the CRM is only “circumferential” in the lower third of the rectum and thus strongly dependent on the height of the respective rectal section, since in the middle third, the rectum is already covered anteriorly by peritoneum, and the CRM accordingly only exists laterally and posteriorly. In the upper third of the rectum, the CRM is only present on the dorsal side, since the rectum is predominantly peritoneal at this height. The distance between the rectal carcinoma and the circumferential resection

margin (CRM) is the most important risk factor for a local tumor recurrence, therefore special importance must be attached to the CRM.

The CRM is considered positive (MRI predicted “cut edge positivity”) if the distance between the rectal carcinoma and the mesorectal fascia is 1 mm or less (= CRM positivity), see **Figure 7**.

Therefore, we need to document the minimum distance to the MRF in millimeters in the findings. There is no general consensus regarding the evaluation of the lymphatic or extramural vascular infiltration if these are closer to the MRF than the primary tumor. In our clinic, we consider clear lymph node metastases and clear extramural vascular infiltration a CRM positive criteria, when the shortest distance to the MRF is lower than or equals 1 mm.

The lower third of the rectum poses a particular challenge for the assessment of CRM due to its anatomical situation. Therefore, the best possible image quality is essential here, including the exact angulation of the layers with respect to the anal canal. The mesorectal fascia fuses in the lower third of the rectum on the levator ani and ends at the upper edge of the sphincter complex. CRM positivity here depends in particular on the surgical procedure. In this context, the intersphincterian fat lamella is an important anatomical guiding structure in addition to the m. levator ani. If the m. sphincter ani internus is infiltrated, but there is a distance between the tumor and the intersphincterian fat lamella or m. levator ani of more than 1 mm, the CRM for an intersphincterian resection is negative. If, on the other hand, the intersphincterian fat lamella or the m. levator ani is infiltrated, an extended resection must be performed, otherwise CRM positivity would be present.

5.3 Extramural venous invasion (EMVI)

EMVI is defined as tumoral invasion of large vessels, typically veins, in close proximity to the muscularis propria. It represents an important criterion for the individual prognosis, as positive EMVI leads significantly more often to local tumor recurrence and metastases (both local and distant). The probability of metastasis increases with the caliber of the infiltrated vessel, whereas larger vessels with a caliber of ≥ 3 mm greatly increase the probability of metastasis. On the other hand, smaller vessels are difficult to differentiate from lymph vessels, which have a somewhat better prognosis. This distinction is difficult even for histopathology, where it may be achieved using special staining. EMVI indicates at least stage T3, since EMVI expands per continuitatem and represents a tumor infiltration through the muscularis propria.

MRI has shown an increasing sensitivity for the detection of EMVI with the increasing use of 3 T systems. The infiltration can be detected much easier using a higher resolution, where it is shown as an intravascular substrate having an identical T2w signal intensity as the primary tumor. At the same time, no flow signal can be detected inside the vessel (**Figure 7**).

The MRI-EMVI point score system recommended by Smith and Brown in 2008 was not practical for us, and with the increasing use of 3 T equipment, we are now increasingly successful in directly detecting vascular infiltration.

5.4 Lymph node staging

All radiological imaging procedures, including MRI, have limited sensitivity and specificity in assessing lymph node metastasis, but we can significantly improve this result by consistently applying the DLC system, as depicted in **Figure 9** [2]:

D – Detection using axial DWI (number of lymph nodes), see also **Table 1**;

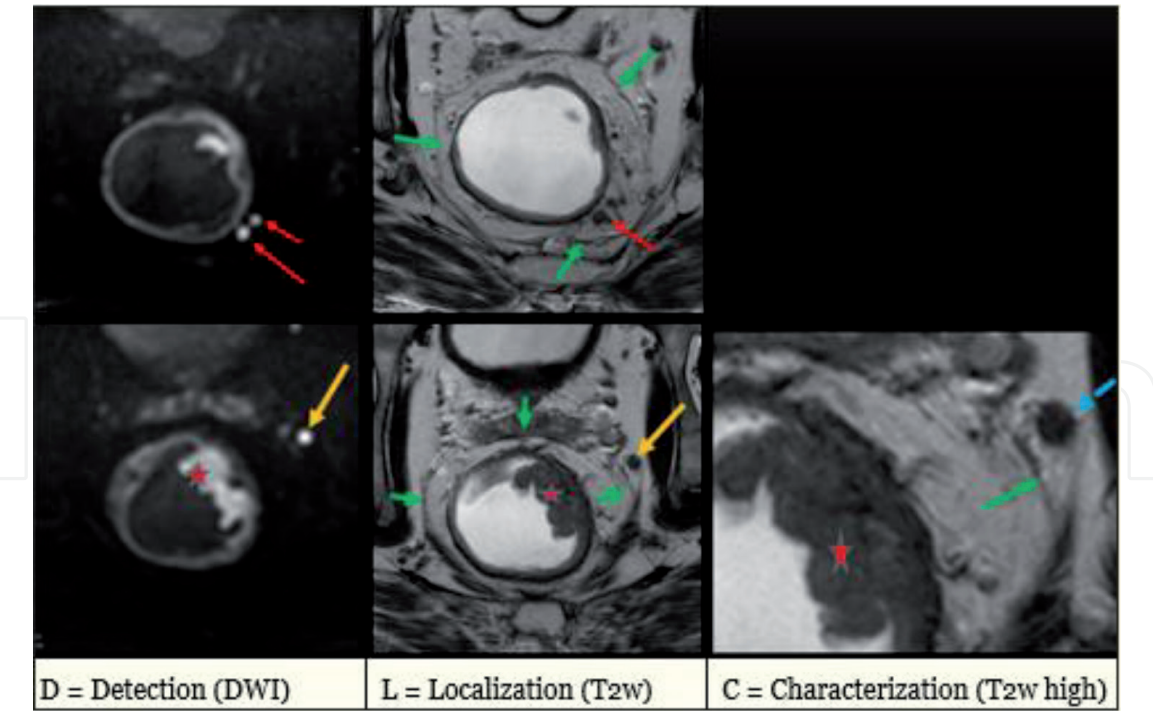


Figure 9. Nodal staging using the DLC system. D = Detection using DWI, L = Localization using T2w, and C = Characterization using high resolution systems with 3 T. Red arrow: intramesorectal nodes. Yellow arrow: extramesorectal nodes. Green arrow: fascia mesorectalis (CRM). Blue dashed arrow: characterization (inhomogeneity, round-oval with spiculae). Red star: tumor. Source: F. Bauer, Radiology Kaufbeuren.

| Class | Interpretation |
|-------|---|
| Nx | Regional lymph nodes cannot be assessed |
| N0 | No involved regional lymph nodes |
| N1 | |
| a | 1 involved regional lymph node |
| b | 2-3 regional lymph nodes involved |
| c | No involved regional lymph nodes, but tumor deposits in subserosa, mesentery or non-peritonealized pericolic or perirectal/mesorectal tissues |
| N2 | |
| a | 4-6 regional lymph nodes involved |
| b | > = 7 lymph nodes involved |

Table 1. Extended N-classification for rectal cancer.

L – Localization of lymph nodes (no. of intra and extra mesorectal) using T2w high resolution multiplanar imaging using a 3 T system (axial, coronal, and sagittal planes);

C – Characterization using T2w high resolution imaging using a 3 T system: tumor size in mm and morphological criteria like inhomogeneity, round-oval with spiculae, etc.

We can answer all therapeutically relevant questions using this scheme. In addition, the increase use of 3 T devices has significantly improved the resolution. Our experience shows that many lymph nodes previously considered round and smooth show distinct spiculae in high resolution images, which is a clear criterion for malignancy. We have also previously seen this correlation between focal findings

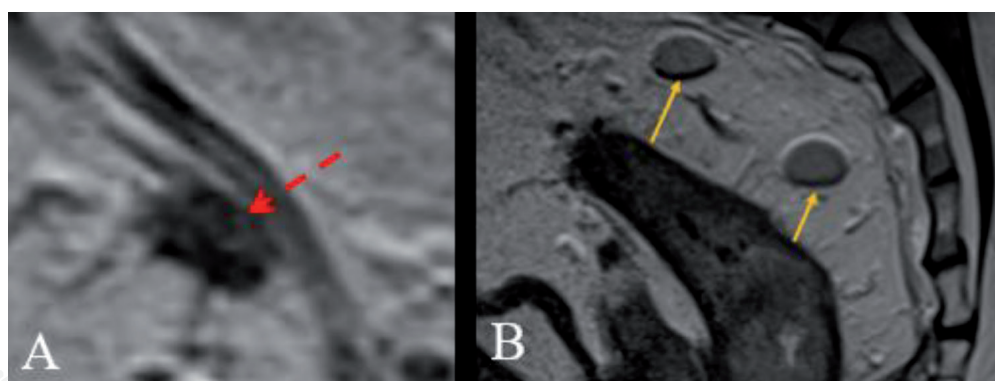


Figure 10.
 Lymph nodes of same size (4 mm) but with totally different morphology in MRI. A. Lymph node metastasis in a patient with rectal cancer. Note the typical aspect of malign lymph nodes: inhomogeneous signal; irregular border with spikes (red arrow). B. Benign (reactive) nodes (arrows), characterized by homogeneous signal and well-defined borders on the background of anal fistula (no cancer!). Source: F. Bauer; Radiology Kaufbeuren.

and resolution in mammography. A good resolution is the key to a correct morphological assessment of the lymph nodes. Currently, the morphology of lymph nodes is becoming more important than their size!

The mesorectal fatty tissue offers a unique and excellent opportunity for a very clear demarcation of lymph nodes. In signal-rich fatty tissue (light), the signal-poor lymph nodes (dark) can be excellently demarcated and characterized (see **Figure 10**). Unfortunately, we do not have this unique situation everywhere in the abdomen!

In general, we have no problems with the assessment of the larger lymph nodes over 5 mm near the tumor or proximal to the primarius, which are usually always positive. We only have problems with smaller lymph nodes below 4 mm, which as we know can contain micrometastases. Here, morphology with good resolution and powerful 3 T devices provides a valuable help, as shown in **Figure 10**.

In our tumor conference, we focus on the localization of lymph nodes, because it is crucial to assess the presence of potentially malignant extramesorectal lymph nodes. While intramesorectal lymph nodes are standardly removed in TME, extramesorectal/obturator lymph nodes are usually left out. If the latter ones present malignancy aspects in MRI, the surgical procedure may change to a D3 lymphadenectomy removing extramesorectal lymph nodes (depending on the surgical strategy).

We recommend the consistent use of structured reporting (see template in Appendix) for primary MRI staging of rectal cancer. This report includes all therapeutically and diagnostically important points.

Nodal metastases must be detected and characterized preoperatively, as they are critical for surgical planning, prognosis, and the decision to administer adjuvant/neoadjuvant chemoradiation.

6. MRI and the newer 3D technology

As in all areas of life, knowledge and experience are also the key to success in dealing with technology. One of these new technologies that deserves application and experience is “high resolution 3D imaging”. Perhaps, it will even change the way we scan in MRI in the future.

3D imaging does not mean, as the term might suggest, image representation in spatial form, but rather the generation of images by means of 3-dimensional data sets.

3D imaging provides numerous benefits for experienced surgeons, from the facilitated planning of complex operations to the use of realistic models. The latter

provides effective solutions for one of the greatest challenges in any academic surgical department: training young surgeons in practical techniques without the negative impact of the learning curve on the patient.

Since 2019, radiologists working in MRI have been using extremely fast, high-resolution 3D data sets. These make even the smallest lesions visible and allow viewing from a variety of perspectives. The “isotropic resolution” (less than 1 mm) ensures excellent display of the tumor’s characteristics and its relation to the surroundings and neighboring organs – and in the shortest possible time. A relevant surgical area can often be measured in only 5 minutes, which saves time and reduces movement artifacts. The “3D high-resolution compressed SENSE pelvic program” converts layered 2D measurements into a single 3D volume scan (**Figure 11**), plane by plane. It allows easily reformatting of isotropic 3D volume data in the range below 0.5 mm in any plane, without gaps, and with the same resolution as the “native” plane. The SNR-rich, ultra-thin 3D volume allows visualization of even subtle lesions without the partial volume averaging effect. Moreover, tissue structures that are best seen in oblique view can be viewed easily.

The new, self-calibrating technique with parallel imaging and compressed scanning significantly speeds up the MRI examination. As a result, scanning times can be reduced by up to 50% compared with those of conventional examination without “compressed SENSE” – all while providing exquisite tissue contrast.

The advantage of 3D imaging in surgical and radiotherapy planning is obvious: multiplanar images with excellent soft tissue contrast. This allows exact delineation of the tumor and healthy tissue, which is of decisive importance for RCT planning.

Furthermore, during follow-up, e.g. after RCT, changes in anatomy and tumor biology can be better visualized, thus permitting improved adaptation of treatment plans.

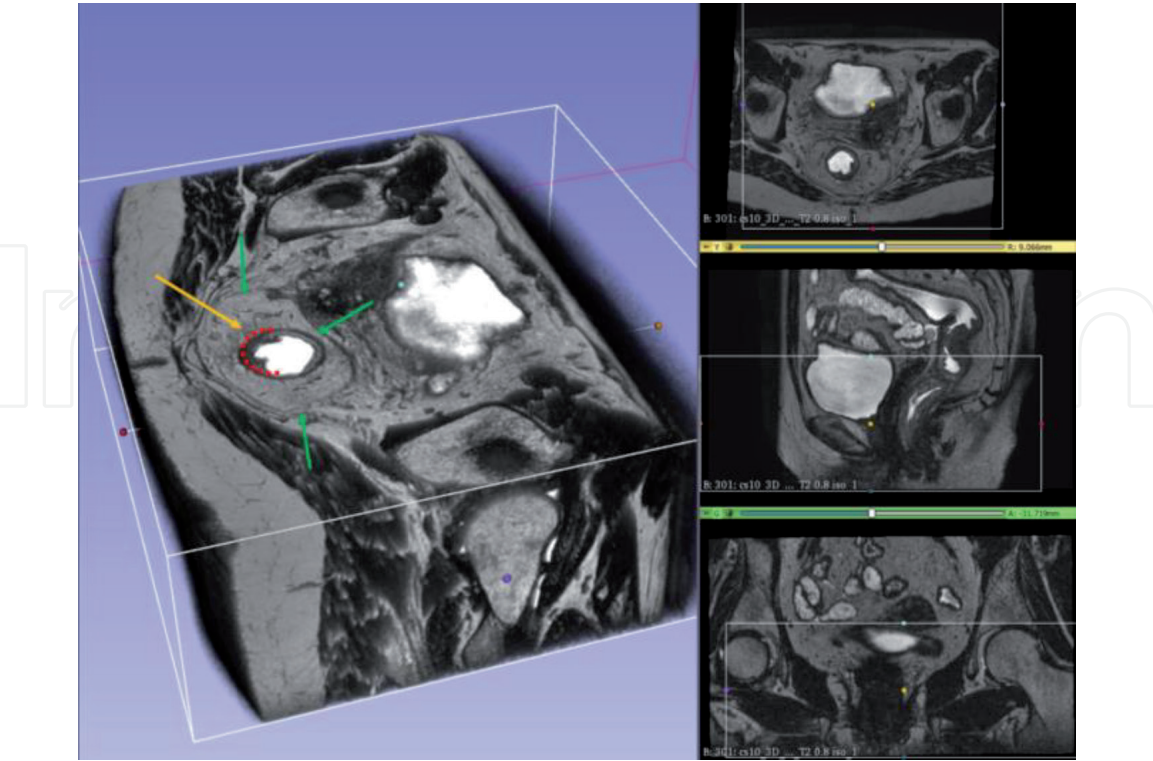


Figure 11.
A 3D volume of pelvis acquires contiguous, sub-millimeter, isotropic 3D data sets that can be easily reformatted into any plane, without losing its resolution. The SNR-rich, ultra-thin slices can provide help to visualize even small and subtle lesions without partial volume averaging effect. This will change the way we scan in the future. Muscularis propria with rectal tumor (red dashed line), mesorectum (yellow arrow), FMR = CRM (green arrow). Source: F. Bauer, Radiology, Kaufbeuren.

Our own experience shows that high resolution in 3D has clear advantages with regard to the assessment of the mesorectal fascia. 3D volume scans allow very clear and seamless visualization of the MRF/CRM at any desired level — even in critical areas, such as ventrally or around the junctional zone, where there is very little to no fat tissue.

Another advantage we see is in the use of arbitrary angulation (adapted to the tumor level) in real time, which permits any possibly unfavorable 2D angulation to be checked quickly and, if necessary, to be corrected accordingly.

Our current results contradict our own older experience as well as the common opinion in the literature regarding the reliability of 3D MRI. The new technology is very stable and can be implemented quickly if given the prerequisite of using 3 T systems with the latest hardware and software technology. **Localization** certainly plays an important role here. In the small pelvis we have no respiratory or pulsation artifacts and the intestinal peristalsis can be exposed very effectively with Buscopan. Of course, we do not have all these unique local conditions in the area of the parenchymatous upper abdominal organs. I can only encourage every user to include this 3D measurement of the pelvis (if 3 T devices are available) in the standard protocol of the rectal examination.

The surgical department has particularly appreciated this 3-dimensional, high quality, multiplanar real-time imaging. We, radiologists, we are especially pleased that the correct orthogonal planning to the tumor can be done very accurately and now in real time, but retrospectively. In the past, incorrect angulation has often produced incorrect readings, resulting in over or underestimation to the distance to the mesorectal fascia. If our measurements are to agree with the histological result, this evaluation must be extremely precise. We see a further advantage in tumors with a strong curvature or in double carcinomas, where multiple angulation is required for precise axial layers. We can now perform all these transformations from one acquired 3D data set. We see no real argument against this 3D volume measurement of the pelvis, which supplements the current standard protocol with an additional 5-minute measurement.

7. Other imaging modalities

7.1 MRI vs. CT

CT cannot be recommended for the local staging of rectal cancer.

The decisive advantage of MRI over CT is that it displays much better the morphology of the tumor and its topographical relationship to the border lamella of the mesorectum and to neighboring structures (prostate, seminal vesicle, vagina, uterus, os sacrum and os coccygeum as well as bladder and sphincter apparatus). As we have shown above, the relationship of the tumor to the neighboring structures is just as important as the TNM classification scheme [17, 18]. In addition, the lymph node prediction accuracy of CT is lower than with MRI.

For the detection of distant metastases, however, contrast-enhanced CT (CECT) is currently the method of choice due to its high availability and supported by current guidelines [19]. In most cases, it consists of a combined examination of the thorax and abdomen, which is a routine protocol both preoperatively for staging and in follow-up.

7.2 MRI vs. PET-CT

We do not routinely use PET-CT in our center for primary staging, nor for restaging after CRT, as complete remission can be evaluated much better with MRI.

In fact, although PET-CT can address the question of tumor response, it cannot determine the presence of complete remission.

However, we do apply PET-CT in particular cases for metastasis detection and evaluation on the background of high CEA values.

7.3 MRI vs. EUS

For the detection, characterization and staging of rectal tumors, MRI is being considered the imaging modality of choice alongside endoscopic ultrasound (EUS), which offers particular advantages for early tumor stages T1 and T2. Without radiation exposure, it enables excellent soft tissue imaging and offers the possibility of multiplanar image acquisition and reconstruction, which is the current standard for the preoperative imaging of rectal tumors [20].

Currently, MRI increasingly being replacing EUS in the local staging for rectal cancer. Both modalities are equivalent for assessment of tumor spread beyond the muscularis propria (i.e., T2 versus T3 status). However, MRI holds several advantages over EUS in case of locally advanced rectal cancers (LARC), because it allows to better characterize lesion size, morphology, tumor margin and other helpful details for surgical planning. In addition, this modality offers a precise characterization of important aspects that may impact therapeutic decisions, such as proximity of the tumor to the mesorectal fascia, presence of extramural vascular invasion (EMVI), presence of extramesorectal pelvic lymph nodes, and involvement of the peritoneum/anterior peritoneal reflection, as well as the assessment of the R0 resectability.

Many of these findings are either difficult to assess, or are beyond the scope of EUS. Because of these advantages, MRI has become the preferred modality in the initial staging of rectal cancer, particularly as part of an interdisciplinary approach [15].

7.4 Endorectal sonography (ERUS) and its evaluation in the MDT tumor conference

At our clinic, our colleagues from gastroenterology apply ERUS routinely for the preoperative local diagnosis of rectal carcinoma and for restaging. The obtained images are then loaded together with colonoscopy images into PACS, so that the obtained information is available to all involved personnel, including radiologists. The examination protocol is well defined and observed: clinical examination at first, followed by colonoscopy with biopsy, and then by ERUS. After this series of examination, and after delivery of the histological finding, we do MRI. At the end, we discuss the results together with all involved departments in the MDT tumor conference.

ERUS is particularly well suited for the preoperative diagnosis of small tumors T1, T2, T3a, and b. However, ERUS has difficulties with large tumors, especially if they are high-set or stenosing carcinomas; likewise, the limited FOV (field of view) of large T3 and T4 tumors can push ERUS to its limits - MRI is superior here. Most of the misdiagnoses in MRI occur during differentiation between T1 and T2 tumors, mostly because of an inadequate representation of the submucosa. In conclusion, ERUS is slightly better suited for the preoperative diagnosis of small low-lying tumors than MRI.

The assessment of the mesorectal fascia (MRF) remains a domain of MRI; especially after neoadjuvant radiochemotherapy, endosonography can neither assess the distance of the tumor to the potential circumferential resection margin (CRM), nor does it offer sufficient sensitivity/specificity to assess the primaries.

ERUS and MRI should not be considered as competing procedures, but rather as complementary imaging modalities. Additionally, we must consider that, especially for endorectal ultrasound, there is a steep learning curve, which possibly also contributes to the lower overall accuracy of ERUS in large multi-center studies. In the hands of an experienced investigator, however, ERUS has proven to be a cost-effective and reliable method for the preoperative diagnosis of rectal cancer.

8. Imaging modalities for restaging

At our Imaging Center we evaluated in the past 5 years (2015-2020) 135 patients with rectal carcinoma using MRI (4 devices of 1.5 T, 2 devices of 3 T).

In the first 2 years, we almost exclusively performed primary diagnoses, the question of restaging being very low. On the one hand, this was due to our surgeons, who did not want to reconsider their original operation planning after completing CRT; on the other hand, it was due to us, because we were still very busy delivering high quality MRI diagnoses. When our image diagnostic results matched the histology, we finally got an adequate appreciation. This required a long learning curve. Today, restaging is as obligatory in our institute as preoperative MRI diagnostics. Restaging is a very demanding examination and can only work if the primary staging is performed with constant high quality. At this point, at the latest, the standardized examination protocol with DWI pays off.

While restaging, MRI imager after nCRT are correlated with MRI images before nCRT in all elements evaluated in primary staging. This requires post therapeutic image acquisition under nearly identical protocol parameters and levels. Essential points at this stage are position, extent and signal intensity of the tumor. These features are compared in the MRI images before and after nCRT. Care is also taken to ensure that restaging or follow up is always performed with the same device, because of the decisive diffusion-weighted images. As already mentioned, different devices (e.g. Siemens vs. Philips) provide different diffusion values, which are not always comparable.

Restaging is not for beginners and requires a long learning curve, similar to MRI of the mamma or MRI of the prostate. A minimum of 50 histologically confirmed cases/examinations are necessary to achieve a good performance.

The difficulties of restaging are obvious: Neoadjuvant therapy leads to profound changes in tumor tissue and surrounding structures, such as excessive fibrosis, deep stoma aging, wall thickening, characteristic muscle remodeling, tumor necrosis, calcification and inflammatory infiltration. As a result, the diagnostic accuracy of the imaging procedures decreases significantly with respect to restaging. Accordingly, the local tumor extent can be over- or underestimated.

These challenges can best handled using MRI with diffusion images. The accuracy of clinical examinations using endorectal ultrasound (EUS), computed tomography (CT) and 18F-FDG protrusion emission tomography with CT (18F-FDG-PET/CT), is very low both for the assessment of mesorectal invasion and for the evaluation of lymph node metastases and is therefore not used at our clinic for restaging as the sole examination.

Our restaging strategy includes digital rectal examination, endoscopy/EUS, and finally MRT (DWI). Care is always taken to ensure that this examination sequence is followed. This is where the multidisciplinary team meeting between surgeons, gastroenterologists and radiologists plays a special role (**Figure 12**). The decisive images are introduced into the PACS system and are available to everyone. When

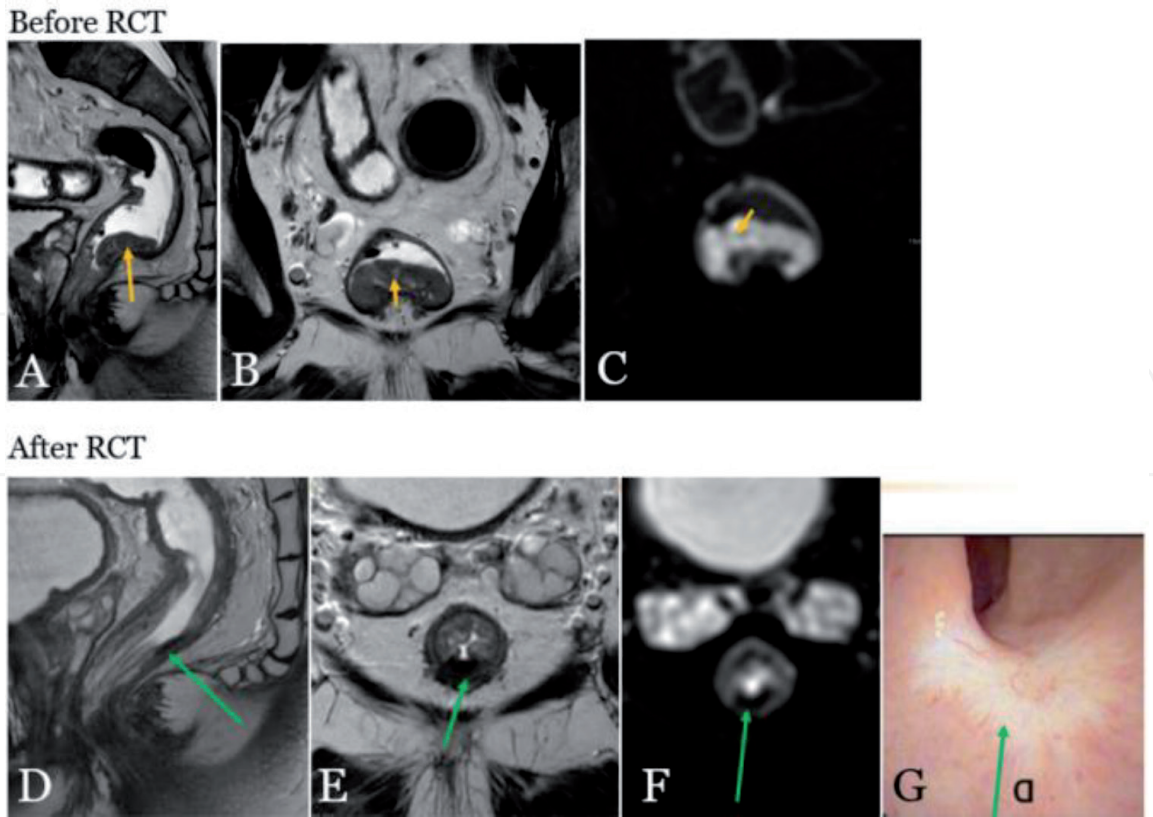


Figure 12.
Response assessment with MRI T2w, DWI, and EUS. Pre RCT imaging shows a rectal cancer stage T2 (yellow arrow) with low to moderate signal in T2w (A, B) and high signal in DWI, C. Reporting: T2, No, EMVI-, CRM-. Post RCT imaging shows complete remission, stage mrTRG-1. Note the tumor has completely regressed and was replaced by fibrosis (green arrows show fibrotic wall thickening with no evidence of tumor remnants) D, E, F. There is no focal high signal in DWI anymore, no diffusion restriction F. G T2wi shows a typical endoluminal white scar. Reporting: ypTo, ypNo, ypEMVI-, CRM-. Therapy strategy: wait-and-see with no tumor recurrence within the following 2.8 years. Source: F. Bauer, Radiology Kaufbeuren.

the radiologist starts restaging, these important staging examinations are already available to everyone.

Almost 90% of our patients have received the internationally recommended standard of care for adenocarcinoma of the lower to middle third of the rectum with a tumor stage T3/4 and/or cN+ and neoadjuvant radiochemotherapy (nRCT).

In addition to the generally known findings such as reduction of the local recurrence rate and improvement of the tumor-free interval, we try to identify the group of patients who would benefit from a non-surgical treatment strategy. The surgical community was initially very reticent towards the watch-and-wait strategy. In fact, it requires a high accuracy MRI examination to identify patients with full remission (CR: ypToN0). Own experience, good interdisciplinary cooperation and evaluation of all diagnostic tests are the prerequisite for reliable diagnostics.

The reference standard for CRT was histopathology or the recurrent free interval of >12 months in watch-and-wait approaches. After a long learning curve, our diagnostic accuracy has improved steadily. In about 24% (33 patients) of the cases we could show a full response, here interestingly also in some patients where chemotherapy had to be discontinued due to cardiac side effects. In almost all CRT cases, the initial stage was a T2 and/or T 3a, b, or c tumor stage. During a follow-up period of 2 years, we could see that almost always a small fibrosis limited to the intestinal wall took place and that this fibrosis was almost always unchanged in the course of the treatment. If a complete remission (CRT) occurred after radiotherapy, a high percentage of patients remained tumor-free.

Restaging remains particularly difficult for initially advanced tumor stages, like T3d with CRM+ or T4. Here, the strong hypointense mass fibrosis of the tumor bed and irregular fibrotic mass or wall thickening with irregular margins and/or spicules makes reliable diagnosis very difficult. In these cases, surgical resection, mostly TME, has always been recommended and performed. In case of low rectal tumors, the anal canal must be assessed.

In fact, our standardized protocol must answer the following questions for surgery:

- Are there vital tumor remnants inside the fibrosis?
- Is the tumor limited to the rectal wall?
- Is the mesorectal fascia (CRM) tumor-free?
- Are there still metastatic lymph nodes?
- Has the tumor withdraws from the anal canal?

In some cases, we have seen that the tumor has actually retreated from the anal canal, thus opening the way for sphincter-preserving surgery and a life without an artificial exit.

The restaging of the lymph nodes often turned out to be surprisingly simple. In the vast majority of cases, where there was a very good or good response to radio-chemotherapy, the mesorectum showed complete remission of the lymph nodes. In some cases, the morphological assessment with regard to spicules and inhomogeneity is particularly difficult due to the extensive fibrosis within the lymph nodes. In such cases, we use the significant reduction in size of the lymph nodes for assessment. Consequently, we consider negative small, star-shaped lymph nodes below 3 mm. However, these lymph nodes must be monitored particularly closely during follow-up.

The time interval to restaging was about 6-8 weeks after the end of CRT. In uncertain cases, where we suspected an almost complete remission, a follow-up examination in about 4 weeks was recommended, because persistent inflammatory reactions and/or a short-term reduction in tumor metabolism can cause an inaccurate result.

The key to success in MR diagnostics and especially in restaging is the unique combination of morphological T2 imaging with in vivo functional (diffusion weighted measurements, DWI) imaging. High-resolution T2 imaging can detect very accurately the extent of fibrosis and mucoid degeneration within fibrosis. Only diffusion-weighted images can assess whether vital tumor tissue is still present within the fibrosis and only MRI is able to combine morphology and functional imaging uniformly within one examination in only 25 minutes (**Figure 12**). Perhaps the mnemonic can help: MRI with DW is a kind of “PET- CT” of the poor man. There is another functional MRI imaging and that is DCE-MRI (Dynamic Contrast Enhanced), which we know very well from prostate diagnostics. We are also experimenting with these sequences. Although we apply here our experience from prostate diagnostics, we currently cannot recommend this examination for routine practice.

Recording the size of the tumor must be paid attention to during restaging and in cases of poor response. A reduction in tumor size can be effectively measured by 3-dimensional MR volumetry and shows a good correlation with the ypT stage after neoadjuvant therapy [21].

| Grade | Response | MRI Finding |
|---------|-------------------|---|
| mrTRG-1 | Complete response | No tumor signal, nor evidence of relapse. |
| mrTRG-2 | Good response | Dense fibrosis, no detectable tumor signal. |
| mrTRG-3 | Moderate response | >50% fibrosis or mucin lakes; detectable tumor signal. |
| mrTRG-4 | Poor response | Predominance of tumor signal over fibrosis and mucin lakes. |
| mrTRG-5 | No response | No change in tumor signal after therapy. |

Table 2.
MRI based tumor regression grading.

Good tumor regression rate in the pathological examination correlates with a tumor volume reduction of more than 70% after nCRT [21, 22] and a higher disease-free survival [21]. Moreover, a volume reduction of more than 75% is significantly associated with pCR [21, 23]. mrTRG can be used to effectively assess the response of rectal carcinomas to CRT. This classification is easy, effective and practice-oriented. According to our experience, a good agreement in histology can be achieved even with minimal training. Again, the focus should be on facilitating the identification of good responders (see **Table 2** for tumor regression stages).

9. Conclusion

Magnetic resonance imaging plays a key role in planning rectal cancer treatment, as it not only accurately depicts the local extent of the cancer and its anatomical positional relationship to the key structures, but can also generate relevant information for prognoses and thus can directly influence the choice of the optimal therapeutic procedure for each individual patient.

To exploit the full potential of MRI, the following must also be reported in addition to the T-stage, including the respective T3 sub-classifications:

- the distance to the circumferential resection margin (CRM),
- presence of extramural vascular infiltration (EMVI), and
- the lymph node status, under consideration of the methodological limitations of MRI.

Endosonography (EUS) is a very important complementary method, especially for determining tumor stage T1 versus T2. A CT thorax/abdomen is routinely used to assess the M status. A PET-CT does not play a significant role in local primary diagnosis and restaging. In this context, the expertise of the radiologist plays an important role, especially in more difficult restaging. We expressly encourage everyone to include 3D volumetry in the standard protocol, because this new technique is already playing an increasingly important role in precise, preoperative surgery planning.

Due to the multitude of therapeutic options available for the treatment of rectal cancer today, it has become an international standard to discuss each patient’s findings pre-therapeutically in a tumor board comprising a multidisciplinary team (MDTmeetings). This procedure ensures that all therapeutic options are considered for the benefit of the patient, according to need.

IntechOpen

IntechOpen

Author details

Ferdinand Bauer
KLF Radiologie und Nuklearmedizin, Kaufbeuren, Germany

*Address all correspondence to: ferdinand.bauer@radiologie-kaufbeuren.de

IntechOpen

© 2020 The Author(s). Licensee IntechOpen. This chapter is distributed under the terms of the Creative Commons Attribution License (<http://creativecommons.org/licenses/by/3.0>), which permits unrestricted use, distribution, and reproduction in any medium, provided the original work is properly cited. 

References

- [1] NAPRC (2020) Commision on Cancer. National Accreditation Program for Rectal Cancer. Optimal Resources for Rectal Cancer Care. 2020 Standards Am Coll Surg pp. 1-60. <https://www.facs.org/quality-programs/cancer/naprc/standards/2020>
- [2] Bauer F (2016) The Importance of Preoperative Staging of Rectal Cancer Using ultiparametric MRI Part II: TNM Cancer Staging. *Chirurgia* Vol. 111(6): 463-475
- [3] Fritsch H, Lienemann A, Brenner E et al (2004) Clinical anatomy of the pelvic floor. *Adv Anat Embryol Cell Biol* 175:1-64
- [4] Laghi A, Iafrate F, Paolantonio P et al (2002) Magnetic resonance imaging of the anal canal using high resolution sequences and phased array coil: visualization of anal sphincter complex. *Radiol Med* 103:353-9
- [5] Iafrate F, Laghi A, Paolantonio P et al (2006) Pre-operative staging of rectal cancer with MR imaging: correlation with surgical and histopathologic findings. *Radiographics* 26:701-714
- [6] McCawley N, Clancy C, O'Neill BD, Deasy J, McNamara DA, Burke JP (2016) Mucinous Rectal Adenocarcinoma Is Associated with a Poor Response to Neoadjuvant Chemoradiotherapy: A Systematic Review and Meta-analysis. *Dis Colon Rectum* 59: 1200-1208
- [7] Schäfer AO, Langer M, Baumann T (2012) Bedeutung der Schnittbildverfahren für das Staging des Rektumkarzinoms [The role of cross-sectional imaging in staging of rectal cancer]. *Chirurg*. 83(5):439-447
- [8] Taylor FG, Quirke P, Heald RJ et al (2011) MERCURY study group. One millimetre is the safe cut-off for magnetic resonance imaging prediction of surgical margin status in rectal cancer. *Br J Surg* 98(6):872-879
- [9] Al-Sukhni E, Milot L, Fruitman M et al. (2012) Diagnostic accuracy of MRI for assessment of T category, lymph node metastases, and circumferential resection margin involvement in patients with rectal cancer: a systematic review and meta-analysis. *Ann Surg Oncol* 19(7):2212-2223
- [10] Beets Tan RG, Lambregts DM, Maas M et al (2018) Magnetic resonance imaging for clinical management of rectal cancer: Updated recommendations from the 2016 European Society of Gastrointestinal and Abdominal Radiology (ESGAR) consensus meeting, *Eur Radiol* 28(4): 1465-1475.
- [11] Rao SX, Zeng MS, Xu JM et al (2007) Assessment of T staging and mesorectal fascia status using high-resolution MRI in rectal cancer with rectal distention. *World J Gastroenterol* 13:4141-4146
- [12] Maas M, Lambregts DM, Lahaye MJ et al (2012) T-staging of rectal cancer: accuracy of 3.0 Tesla MRI compared with 1.5 Tesla. *Abdom Imaging* 37:475-481
- [13] Smith N, Brown G (2008) Preoperative staging of rectal cancer. *Acta Oncol* 47: 20-31
- [14] Lambregts DM, Beets-Tan RG. Optimal imaging staging of rectal cancer. *EJC Suppl.* 2013;11(2):38-44. DOI: 10.1016/j.ejcsup.2013.07.031
- [15] Nougaret S, Jhaveri K, Kassam Z, Lall C, Kim DH (2019) Rectal cancer MR staging: pearls and pitfalls at baseline examination. *Abdom Radiol* 44:3536-3548

- [16] Shihab OC, Brown G, Daniels IR, Heald RJ, Quirke P, Moran BJ (2010) Patients with low rectal cancer treated by abdominoperineal excision have worse tumors and higher involved margin rates compared with patients treated by anterior resection. *Dis Colon Rectum* 53:53-56
- [17] Bernini A, Deen KI, Madoff RD et al (1996) Preoperative adjuvant radiation with chemotherapy for rectal cancer: its impact on stage of disease and the role of endorectal ultrasound. *Ann Surg Oncol* 3(2):131-135
- [18] Gerard JP, Ayzac L, Coquard R et al (1996) Endocavitary irradiation for early rectal carcinomas T1 (T2). A series of 101 patients treated with the Papillon's technique. *Int J Radiat Oncol Biol Phys* 34(4):775-783
- [19] S3 Guideline colorectal cancer version 1.0 - June 2013 AWMF registry number: 021/0070L. http://www.awmf.org/uploads/tx_szleitlinien/021_007OLI_S3_KRK_14062013.pdf.
- [20] Raghunathan G, Morteale KJ (2009) MR imaging of anorectal neoplasms. *Clin Gastroenterol Hepatol* 7(4):379-388
- [21] Nougaret S, Reinhold C, Mikhael HW et al (2013) The use of MR imaging in treatment planning for patients with rectal carcinoma: have you checked the "DISTANCE"? *Radiology* 268(2):330-344
- [22] Barbaro B, Fiorucci C, Tebala C et al (2009) Locally advanced rectal cancer: MR imaging in prediction of response after preoperative chemotherapy and radiation therapy. *Radiology* 250(3):730-739
- [23] Kang JH, Kim YC, Kim H et al (2010) Tumor volume changes assessed by three-dimensional magnetic resonance volumetry in rectal cancer patients after preoperative chemoradiation: the impact of the volume reduction ratio on the prediction of pathologic complete response. *Int J Radiat Oncol Biol Phys* 76(4):1018-1025