

# We are IntechOpen, the world's leading publisher of Open Access books Built by scientists, for scientists

6,900

Open access books available

186,000

International authors and editors

200M

Downloads

Our authors are among the

154

Countries delivered to

TOP 1%

most cited scientists

12.2%

Contributors from top 500 universities



WEB OF SCIENCE™

Selection of our books indexed in the Book Citation Index  
in Web of Science™ Core Collection (BKCI)

Interested in publishing with us?  
Contact [book.department@intechopen.com](mailto:book.department@intechopen.com)

Numbers displayed above are based on latest data collected.  
For more information visit [www.intechopen.com](http://www.intechopen.com)



# Ocular Manifestations in Epstein Barr Virus Infection

*Andi Arus Victor*

## Abstract

The Epstein-Barr Virus (EBV), a member of the Herpesvirus family, occurs commonly and infects more than 90% of people worldwide. Most of systemic EBV infections throughout childhood and adulthood are typically asymptomatic or paucisymptomatic. Even though ocular involvements in EBV infections are infrequently reported, an increasing number of ocular manifestations have been previously reported. Ocular manifestation caused by EBV infection involved all segments of the eye, including oculoglandular syndrome, dry eye syndrome, dacryoadenitis, conjunctivitis, episcleritis, keratitis, uveitis, choroiditis, retinitis, retinal vasculitis, and papillitis. Previous reports found neurologic complications such as papilledema, optic neuritis, ophthalmoplegia, impaired accommodation, and facial nerve palsy. Any atypical ocular inflammatory process should be considered EBV infection in the differential diagnosis. The ocular manifestations of systemic EBV infection are varied and have not been emphasized. And the role of EBV infection in ocular manifestations should be fully described.

**Keywords:** Epstein-Barr virus, oculoglandular syndrome, dry eye syndrome, dacryoadenitis, conjunctivitis, episcleritis, keratitis, uveitis, choroiditis, retinitis, retinal vasculitis, papillitis, papilledema, optic neuritis, ophthalmoplegia, impaired accommodation, facial nerve palsy

## 1. Introduction

The Epstein-Barr Virus (EBV) was first introduced in 1964 by Epstein, Anchong, and Barr [1–3], from a tissue sample of Burkitt's lymphoma and was observed with an electron microscope. EBV has the same characteristic as herpes viruses in tissue cultures from specimens of Burkitt's lymphoma. EBV is included in the family of *Herpesviridae*, which has a characteristic of the viral genome covered inside a nucleocapsid bounded by the viral envelope. In 1968, 4 years right after its first discovery, EBV was found to be the causal agent of the infectious mononucleosis (also called glandular fever). On other studies that conducted after, EBV was also found on tissue samples of nasopharyngeal carcinoma [3, 4], non-Hodgkin's lymphoma, T-cell lymphoma, as well as oral hairy leukoplakia that associated with Acquired Immunodeficiency Syndrome (AIDS) [4, 5].

EBV DNA has a nature of double-strand and consists of guanosine and cytosine as much as 58%. Due to the nature of the receptors on B-cell surfaces, EBV shows a great permissivity toward B lymphocytes. When B lymphocytes are infected by EBV, they will be "transformed" into lymphoblasts in vitro, this process known as immortalization. EBV occurs commonly and infects approximately 90% of human [1–3].

EBV-specific antibodies are found in about 95% of adults and 50–85% of the children [4, 5]. EBV infections are typically asymptomatic or have a subclinical infection, but once infected, it can lead to a viral carrier state for a lifetime. In some cases, primary EBV infection occurring during early adulthood could show clinical significance that is known as glandular fever or infectious mononucleosis [2, 5, 6]. Fortunately, most patients with infectious mononucleosis show a short recovery period since both cellular and humoral immune responses play a prominent role during the infection.

Ocular manifestations caused by EBV infection have been previously described. Previous studies showed that specific antibodies were detectable in 65% of tear and 87.5% of serum samples from 40 normal subjects [4]. EBV infection manifested in the eye may involve all segments of the eye, including oculoglandular syndrome, dry eye syndrome, dacryoadenitis, conjunctivitis, episcleritis, keratitis, uveitis, choroiditis, retinitis, retinal vasculitis, and papillitis [3]. Follicular conjunctivitis is the most common ocular disease during acute EBV infection. It is observed in 1–38% of cases and is usually unilateral. Bilateral stromal keratitis with coin-shaped lesions noted on tapering of systemic steroid therapy has been reported [6]. Uveitis occurred in 0.5% of patients with EBV infection [6].

The ocular manifestations of systemic EBV infection are numerous and have not been emphasized. Therefore, the role of EBV infection in ocular manifestation should be fully understood.

## 2. Pathophysiology infection of EBV

Usually, the first introduction to EBV in the period of childhood will cause subclinical infection, however if this primary event happens during adolescence, most of the time would trigger infectious mononucleosis. This syndrome consists in an acute and self-limiting lymphoproliferation of infected B cells and, at the same time, the development of virus-specific T cells that are triggered in order to tackle viral dissemination.

EBV transmission occurs by the sharing of saliva and then cause infection of mucosal surfaces and lymphoid tissues [3]. Almost most of seropositive individuals shed virus in their saliva. It was proposed earlier that initial replication of the virus happened also in the epithelial cells of the oropharynx, which causes the B cell infection by the previously infected epithelial cells. However, newer studies suggest that B cells located in the oropharynx could be infected first and act as the primary site.

During the latent stage of the infection, the site in which EBV persists within the body is the resting memory B cells. The viral replication in the oropharynx is partially suppressed in patients taking acyclovir, in the other hand, the amount of B cell EBV infected in the circulation remains the same.

Typical symptoms and signs are fever, pharyngitis, lymphadenopathy, and splenomegaly. The basic lesion is a perivascular infiltration of both normal and abnormal lymphocytes in all the tissues except bone marrow [7].

These cells are metaplastic noninvasive and to be formed *in situ* from other cells of the reticuloendothelial system. This lesion distributed throughout the body, and in any individual patient may be most marked in the central nervous system, liver, lungs, and other organs or systems.

Before the entry process into B cell, gp350, a major envelope glycoprotein, fixes to the receptor of the virus, CD21 molecule, which is located on the surface of the B cell. There are other factors besides CD21 that play a significant role, such as major histocompatibility complex (MHC) class II molecules that acts as a cofactor during B cells infection. EBV genome linear DNA molecules encode 100 viral proteins.

These proteins are significant in the process of construction of virion as well as carrying forward immune responses of the host.

EBV infection in vivo of the epithelial cells consequences in active replication while simultaneously with lysis of the cells as well as production of virus. Meanwhile, EBV infected B cells in vitro will become immortalized and causes latent infection. Only a small portion of cases that viral replication is triggered immediately after the infection of B cells.

Both cellular and humoral immunity plays an important role in the infection of EBV in humans. Even though the presentation of antibodies designed against viral structural proteins is critical, cellular immunity plays a higher role on the controller of EBV infection. The control of proliferation of EBV infected B cells in the primary infection is carried forward by CD4+, CD8+, and natural killer cells. During the period of infectious mononucleosis, a proportion of 40% of CD8+ T cells are focused on single replicative EBV protein sequence, meanwhile only 2% are focused to single latent EBV protein sequence.

During acute infection, first IgM and then IgG antibodies to viral capsid antigens (VCA) appear. Anti-VCA IgG may lead to virus carrier state and persist for a lifetime [3, 7]. Antibodies to early antigens rise during the acute phases of the disease and subsequently decrease to low or undetectable.

EBV can exist regardless of competent responses from the healthy immune system that are targeted toward it. It would most probably suggest that EBV has developed some tactics to evade the response from the immune system. EBV encrypts a cytokine as well as cytokine receptors that have a crucial role in moderating capable immune system therefore this allows tenacious infection. The 70% of amino acid sequence of EBV BCRF1 has the same characteristics as interleukin-10.

The protein of BCRF1 imitates the behavior of interleukin-10 of inhibits interferon- $\gamma$  synthesis by in vitro human peripheral-blood mononuclear. In addition to that, EBV BARF1 protein acts as a soluble receptor for colony-stimulating factor 1. It is known that colony-stimulating factor 1 usually upregulates the expression of interferon- $\alpha$  of monocytes, therefore BARF1 protein able to operate as a decoy receptor to halt the action of cytokine. Since inhibition of the outgrowth of EBV infected cells in vitro is done by interferon- $\gamma$  and interferon- $\alpha$ , BARF1 and BCRF1 proteins could aid the EBV to avoid the immune system of the host in the period of both acute as well as latent infection. EBV also codes more than two proteins that cause apoptosis inhibition. Protein of the EBV BHFR1 is similar to the protein of human bcl-2 protein, this protein has the same function on blocking apoptosis. In addition, EBV LMP-1 increases several cellular protein expressions that hinders the process of apoptosis, i.e. bcl-2.

Antibodies to EBV nuclear antigens appear weeks to months later, providing serologic evidence of past infection. Lesions of the special sense organs are somewhat rare, but there are few reports of eye lesions or manifestations [7].

Ocular manifestations have been reported to affect all segments of the eye and most commonly associated with acute mononucleosis [3]. Manifestations in the ocular may be the cause of direct involvement of the eye and its adnexa through inflammatory syndrome similar to that of infectious mononucleosis, and those affecting vision and the neuro-ophthalmologic apparatus owing to a more remote occurrence of the lesion, most commonly involving the central nervous system [7].

### 3. Clinical manifestation

Ocular manifestations of acute EBV infection may affect the central nervous system to the extent of disturbance in the visual or oculomotor pathways, in



addition it could as well cause a disorder in the eye and adnexa of the eye [4, 8]. Further manifestations were observed due to the advancement of diagnostic tools that could give much more sensitive and specific results [8].

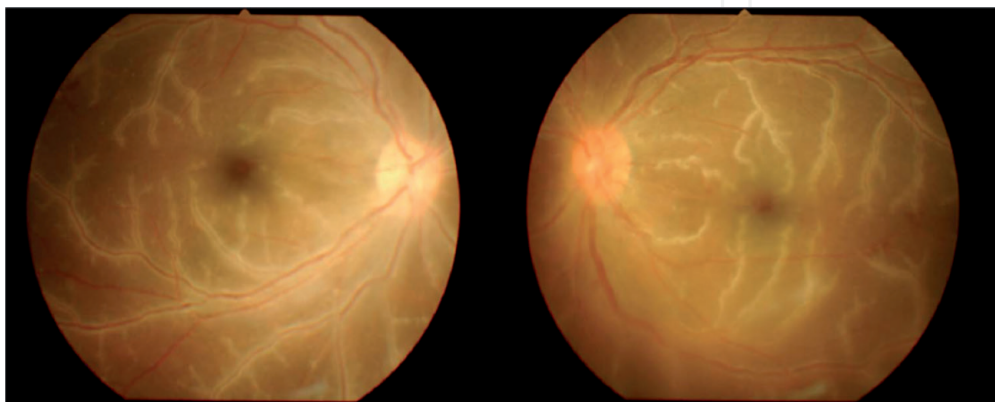
Neurologic abnormalities caused by EBV could disturb the host vision. Disorders that have been reported previously consisted of papilledema, convergence deficiency, nerve palsies, retinal necrosis, central nervous system vasculitis, retinochoroiditis, necrotizing retinitis with extensive hemorrhage that were co-infected with human immunodeficiency virus and cytomegalovirus and optic neuritis [9].

The appearance of yellowish, coalescing lesion in the macula as well as edematous optic disk were seen in a patient with EBV infection by Kim et al. [10]. From our previous case-report, it was examined from funduscopy a peculiar finding of prominent presentation of white sheathing retinal phlebitis covering all four retinal quadrants (**Figure 1**). Other reports had described this finding as frosted branch angiitis. It was also well known that frosted branch angiitis has been seen regularly in numerous disorders such as Crohn disease, Behcet disease, and systemic lupus erythematosus. However, from our previous case, the patient did not show any typical symptoms of Crohn disease, Behcet disease, and systemic lupus erythematosus, also, PCR was done on the patient's serum and was positive for EBV.

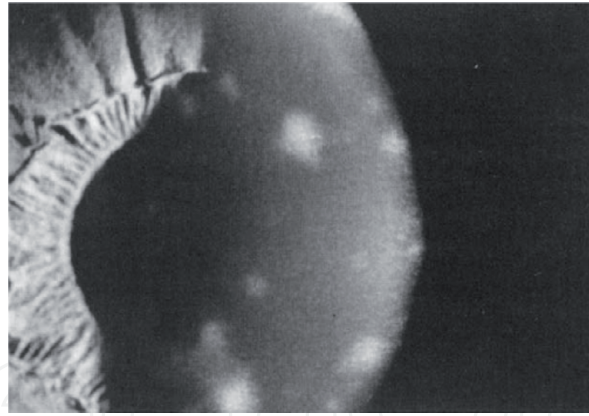
EBV infects lymphoid tissues and also mucosal surfaces. In the cellular level, EBV infects B cell and conforming virus-specific T cells, which will lead to symptoms such as lymphadenopathy and pharyngitis. Based on seroepidemiologic data, it was reported that EBV infects all parts of the eye, though the most common abnormality includes follicular conjunctivitis. After the availability of serologic virus-specific tests, other disorders of the anterior segment that is associated with EBV were detected more frequently, which includes keratitis, iritis, episcleritis, as well as dacryoadenitis.

It was found by Plugfelder et al., [11], that some cases of primary Sjogren's syndrome developed right after infectious mononucleosis. These authors [11] gathered patients that have aqueous tear deficiency and evaluated them for a serologic finding of EBV infection. A significant correlation was found between elevated early antigen EBV titers and severe aqueous tear deficiency once the results were placed in multivariate analysis. This suggests that EBV infection could be a risk factor in developing aqueous tear deficiency [11, 12].

Inflammation of the conjunctiva has been seen and linked with keratitis, that variate from mild hyperemia to mild follicular reaction in the inferior and superior



**Figure 1.** Bilateral fundus photographs showing white sheathing of retinal veins in four retinal quadrants (frosted branch-like appearance) with macular edema. Reprinted from [1]. Copyright 2016 by Retinal Cases & Brief Reports.



**Figure 2.**  
*Subepithelial infiltrates resembling adenoviral infection-associated keratitis in a patient with recent primary EBV infection. Reprinted from [2]. Copyright 1990 by Surv Ophthalmol.*

tarsal conjunctiva. A study by Matoba [4] has found stromal keratitis related to EBV infection to infect all layers of stroma. Matoba [4] has also reported there were two forms of EBV-related keratitis, the first type was a granular, multiple, well-defined, ring, or circular-shaped opacities which was distributed all over the anterior as well as mid-stroma. Another form is nonsuppurative, multifocal keratitis including deep layers or full thickness of peripheral cornea and also related to various grades of vascularization [4]. In another study by Chodosh J, stromal keratitis associated with EBV infection presented three principal forms (**Figure 2**) [7].

Type I: multifocal subepithelial infiltrates that resemble adenoviral keratitis.

Type II: multifocal, blotchy, pleomorphic infiltrates with active inflammation or granular ring-shaped opacities (inactive form) in anterior to midstroma.

Type III: multifocal deep or full thickness peripheral infiltrates, with or without vascularization.

Matoba et al. [4] proposed a hypothesis about the pathophysiology of EBV related keratitis onset being carried forward by infectious and immunologic processes. Due to the quick response to the introduction of topical corticosteroid and seeming resolution of the inflammation without involving the use of antiviral therapy, it is more likely that immunologic processes were involved rather than viral replication. If this is true, the cornea was affected could be due to native keratocyte share a similar antigen with EBV, or it might be caused by EBV antigen develops located within the tissue [4].

Other common symptoms affecting the ocular include periorbital edema, pain when rotating the eyes, deep orbital pain, photophobia, as well as headache. It was spotted by Tanner [8] that episcleritis, as well as uveitis as part of the ocular manifestation of EBV infection. Tanner [8] reported nongranulomatous uveitis taking place at the end stage of clinical manifestation of infectious mononucleosis had been noted in four cases. One specific exhibition is the disorder of the oculomotor apparatus. Fledelius et al. [8] observed an exclusive inferior rectus paresis. Motto and Ashworth [8] were the first to notice a bilateral papilledema case of infectious mononucleosis with the nonappearance clinical manifestation of encephalitis nor meningitis. Other studies observed ptosis, nystagmus, as well as diplopia in their patients [8].

#### **4. A diagnostic approach for detecting ocular disease by EBV infection**

Most of the ocular manifestations linked to the EBV infection have been based mostly on seroepidemiologic data. This claimed is supported by the fact that

numerous patients with EBV infection that showed ocular manifestations have been confirmed from in-situ hybridization of EBV genome from the biopsy of suspected tissue specimens.

The diagnosis of EBV infection by serologically for quite sometimes has been hinge on heterophile antibodies detection [4]. Heterophile antibodies are classified in the IgM group and would typically reach its highest levels around the second to third week since the first onset of the sickness and would exist and visible till 1 year [4]. They are detectable in up to 90% of adults who suffered from primary EBV infection [4].

Monospot test is a test that could be used in detecting EBV infection. This test is a quick slide agglutination test for specific heterophile antibodies produced by the human immune system in response to EBV infection. The sample will clump when it exposes to equine erythrocytes if these specific antibodies present in the patient's blood specimen. The Monospot test is considered to be a very specific test. However, its sensitivity falls in the range of 70–90% [13]. Patients with atypical clinical features and patients and with suspected of chronic infection are better evaluated with EBV specific serologic test that measure antibody levels against VCA, EBNA, and EA [4].

## **5. Management**

The overall goal of EBV treatment is mainly supportive since the disease is usually self- limited [4]. Antiviral drugs have been used to inhibit the replication cycle of the virus. The action of antiviral agents can be divided into: (1) disrupting with cellular process which the virus uses for its replication; (2) inhibits the function of the virus by bind to the nucleic acid; (3) modifies the viral envelope which is resulting in preventing the virus infecting new cells; (4) inhibits the formation of new progeny by interfering with viral assembly; (5) interferes with the viral enzyme and inhibits their function; (6) prevents the processing of viral precursor polypeptide. The effect of some of the antiviral agents used in EBV infection is uncertain, but some studies have reported good results of treating EBV infection with systemic antiviral [4, 12].

Several antiviral drugs have been used to treat EBV infection and can be grouped into three as nucleoside analogs such as ganciclovir, valganciclovir, acyclovir, valaciclovir, acyclic nucleotide analog such as cidofovir and adefovir, and pyrophosphate analog such as foscarnet [12]. Acyclovir is recommended as the first-line drug for treating EBV infection. Therefore, it has become the most commonly prescribed antiviral regimen [14–16]. Anderson et al. [14] have found a significant reduction of EBV-infected B-lymphocytes after acyclovir treatment. Accordingly, systemic acyclovir therapy showed a good result of treating EBV-associated ocular involvement and Acute retinal necrosis [15].

Acyclovir triphosphate inhibits viral replication by acting as a competitive substrate for viral DNA polymerase, and its subsequent incorporation into the viral DNA chain results in obligate chain termination. The recommended regime is intravenous acyclovir 10 mg/kg every 8 hours (or 1500 mg/m<sup>2</sup>) per day for 5–10 days, followed by oral acyclovir 400–800 mg 5 times daily for an additional 6–12 weeks. Second eye involvement may occur within the first 6 weeks after EBV infection; thus, the minimum duration of subsequent oral therapy was 6 weeks. Even though some ophthalmic centers are switching to oral therapy alone, few studies found a higher level of intravitreal acyclovir when given intravenously [15–17]. From the limited data available, one may conclude that acyclovir given intravenously and orally is the recommended regime [16, 17].

The effectiveness of steroid along with antiviral drug in treating ocular manifestations of EBV infection remains unclear. Some studies described that ophthalmic steroids relieve the symptoms of ocular inflammation in the anterior segment of the eye, including keratitis, anterior uveitis, and ocular allergies or injuries, yet its effect on the posterior part is still not clear [2, 4, 17].

## 6. Conclusion

It can be concluded that distinctive characteristic pathologic clinical manifestation, as well as lesions of infectious mononucleosis, exists in the ocular area. The ocular manifestations of systemic EBV infection are wide-ranging and have not been highlighted. EBV infection is best diagnosed using heterophile antibody tests to detect primary EBV infections and serology tests for asymptomatic patients. Despite of the self-limiting nature of the disease, acyclovir still becomes the first line of treatment with its attribute to reduce the viral replication. EBV infection should be included in the differential diagnosis of most unusual inflammatory course of the eye.

## Conflict of interest

There are no conflicts of interest in this chapter.

## Author details

Andi Arus Victor  
Department of Ophthalmology, Faculty of Medicine, Cipto Mangunkusumo  
National General Hospital, Universitas Indonesia, Jakarta, Indonesia

\*Address all correspondence to: [arvimadao@yahoo.com](mailto:arvimadao@yahoo.com)

## IntechOpen

© 2020 The Author(s). Licensee IntechOpen. This chapter is distributed under the terms of the Creative Commons Attribution License (<http://creativecommons.org/licenses/by/3.0>), which permits unrestricted use, distribution, and reproduction in any medium, provided the original work is properly cited. 



## References

- [1] Cohen JL. Epstein-Barr virus infection. *The New England Journal of Medicine*. 2000;**343**:481-492
- [2] Victor AA, Sukmana N. Retinal vasculitis associated with Epstein-Barr virus infection, a case report. *Retinal Cases & Brief Reports*. 2016;1-4
- [3] Slobod KS. Molecular evidence of ocular Epstein-Barr virus infection. *Clinical Infectious Diseases*. 2000;**31**:184-188
- [4] Matoba AY. Ocular disease associated with Epstein-Barr virus infection. *Survey of Ophthalmology*. 1990;**35**:145-150
- [5] Kramer S, Brumer C, Zierhut M. Epstein-Barr virus associated acute retinal necrosis. *The British Journal of Ophthalmology*. 2001;**85**:110-120
- [6] Wong KW, D'Amico DJ, Hedges TR III, et al. Ocular involvement associated with chronic Epstein-Barr virus disease. *Archives of Ophthalmology*. 1987;**105**:788-792
- [7] Chodosh J. Epstein-Barr virus stromal keratitis. *Ophthalmology Clinics of North America*. 1994;**7**(4):549-556
- [8] Tanner OR. Ocular manifestations of infectious mononucleosis. In: Presented at the 36th Annual Meeting of the Pacific Coast Oto-Ophthalmological Society, 1st May 1952, Salt Lake City; 1952
- [9] Andi AV. Ocular Manifestations in Epstein Barr Virus Infection [Online First]. *IntechOpen*; October 5th 2020.
- [10] Kim SJ, Baranano DE, Grossniklaus HE, Martin DF. Epstein-Barr infection of the retina: Case report and review of the literature. *Retinal Cases and Brief Reports*. 2011;**5**:1-5
- [11] Pfugfelder SC, Tseng SCG, Pepose JS, et al. Epstein-Barr virus infection and immunologic dysfunction in patients with aqueous tear deficiency. *Ophthalmology*. 1990;**97**:313-323
- [12] Yaro A. Epstein-Barr infection: Current treatment options. *Annals of Tropical Medicine and Public Health*. 2013;**6**(1):10-13
- [13] Stuempfig ND, Seroy J. Monospot test. [Updated 2019 Mar 10]. In: StatPearls [Internet]. Treasure Island (FL): StatPearls Publishing; 2020. p. 1
- [14] Keorochana N. A case report of Epstein-Barr virus associated retinal vasculitis: Successful treatment using only acyclovir therapy. *International Medical Case Reports Journal*. 2016;**9**:213-218
- [15] Rafailidis PI, Mavros MN, Kapaskelis A, Falagas ME. Antiviral treatment for severe EBV infections in apparently immunocompetent patients. *Journal of Clinical Virology*. 2010;**49**(3):151-157
- [16] Patrick MK, Claire YH, Susan L. Antiviral selection in the management of acute retinal necrosis. *Clinical Ophthalmology*. 2010;**4**:11-20
- [17] Lee FF, Foster CS. Pharmacotherapy of uveitis. *Expert Opinion on Pharmacotherapy*. 2010;**11**:1135-1146