

We are IntechOpen, the world's leading publisher of Open Access books Built by scientists, for scientists

6,900

Open access books available

186,000

International authors and editors

200M

Downloads

Our authors are among the

154

Countries delivered to

TOP 1%

most cited scientists

12.2%

Contributors from top 500 universities



WEB OF SCIENCE™

Selection of our books indexed in the Book Citation Index
in Web of Science™ Core Collection (BKCI)

Interested in publishing with us?
Contact book.department@intechopen.com

Numbers displayed above are based on latest data collected.
For more information visit www.intechopen.com



An Approach to the Airway Management in Children with Craniofacial Anomalies

*Brahim Boudjenah, Al Moataz Billah Adham,
Surendra M. Chinnappa, Omed Assaf
and Mashaël Al-Khelaifi*

Abstract

Managing the airways during anesthesia in pediatric patients with craniofacial abnormalities is a challenging and stressful situation for even experienced anesthesiologists. The prerequisites for a good management are a thorough understanding of the normal anatomy of the upper airway, its normal changes with growth, and the key features of congenital craniofacial abnormalities and their impact on the airways resulting in management difficulties. This chapter aims to provide an overview of various craniofacial anomalies and their airway management specificities. These include cleft lip and palate with or without Pierre Robin syndrome, craniofacial dysostosis (including Crouzon, Pfeiffer, and Apert syndromes), mandibulofacial dysostosis/Treacher Collins syndrome, hemifacial microsomia, Down's syndrome, and other anomalies.

Keywords: congenital syndrome, craniofacial anomalies, difficult airways, anesthesia, mandibulofacial dysostosis

1. Introduction

The incidence of difficult airway is higher in children with craniofacial syndromes than normal children, hence a thorough airway evaluation is crucial in order to anticipate difficult airway and to formulate a safe plan. Common challenges encountered upon examination of a child's airway include an uncooperative child and the unreliability of the Mallampati scoring for prediction of the difficult airway in children [1]. Airway assessment must focus on the general clinical systematic evaluation as well as the more specific airway issues of each syndrome and other associated organs involvement. The approach should include history taking, physical examination, and diagnostic tests.

2. Pediatric difficult airway evaluation

2.1 General airway assessment

General clinical history should focus on the presence of any problem affecting the airway or the respiratory system including history of snoring or apneas, upper

respiratory tract infection (URTI), croup, stridor, voice hoarseness, recurrent aspirations, asthma, parental smoking, and most importantly a history of previous difficult airway management [2].

The general airway examination must include: a baseline oxygen saturation on room air, respiratory rate, preferred body position (prone position must be red-flagged as upper airway obstruction), mouth breathing, existence of any obstruction manifested by intercostal/suprasternal retractions, oral examination of the mouth opening, teeth, tongue size and Mallampati score, shape and position of the mandible, hyo-mental distance, and neck length/mobility.

Nevertheless, the airway examination in children may be difficult to perform in detail especially with an uncooperative child, thus it may be restricted to the general observation of the face, mandible, and breathing pattern in such situations.

The most critical step in airway examination of children pertains at taking a lateral “profile” look of the mandible which could spot a micrognathia or a retracted mandible that might be masked with the frontal look.

General diagnostic tests: they are seldom required especially when further details of the airway are needed. An X-ray of the head and neck can show the place and the level of upper airway obstruction; however, a CT scan/MRI can provide further details (especially in tumors and vascular malformations of the airway). CT virtual endoscopy (VE) is an excellent tool used to obtain an anatomically similar representation of the intraluminal geography of the airway, including supraglottic, glottic, and subglottic structures without the risk of exposure to ionizing radiation. Compared to conventional 3-D reconstructions, the images obtained through virtual endoscopy create the impression of a true endoscopic image allowing for a tailored approach toward the airway management. A flexible fiberoptic endoscopy maybe required in children with airway pathology especially children with an unexplained hoarse voice, suprasternal/intercostal retractions, and chronic aspirations.

2.2 Focused airway evaluation

The clinical evaluation should focus on risk factors which may potentially contribute to difficult airway management including (**Table 1**) [3]:

1. An extremely short thyro-mental distance with an overbite, with micro/retrognathia such as seen in Pierre Robin sequence and Treacher-Collins syndrome;
2. A fixed neck such as in Klippel-Feil syndrome;
3. A small oral opening and large tongue such as seen in Beckwith-Wiedemann syndrome;
4. Obstructive sleep apnea +/- secondary pulmonary hypertension;
5. Stiff subcutaneous tissues as seen in Mucopolysaccharidosis (high risk of difficult ventilation);
6. Midface hypoplasia as seen in Apert and Crouzon syndromes;
7. Obstruction of the airway when in supine position and the need to continuously maintain in prone positioning;

Anatomical malformation	Syndrome
Overbite	Pierre Robin-Treacher Collins-Goldenhar
Mandibular prognathism	Apert
Small mouth	Pierre-Robin, Treacher-Collins, Goldenhar, Down's syndrome
Large mouth	Mucopolysaccharidosis, Beckwith-Wiedemann
Palate (high arched)	Down, Crouzon, Apert, Pierre Robin, Treacher Collins, Mucopolysaccharidosis
Cleft Palate	Pierre Robin, Treacher Collins, Goldenhar, Down's, Apert, Crouzon
Tongue abnormality (Large or Glossoptosis)	Beckwith-Wiedemann, Mucopolysaccharidosis, Pierre Robin.
Short thyromental distance (less than 3 finger breadths used by the own child's fingers)	Pierre Robin, Treacher Collins, Goldenhar,
Subglottic narrowing	Down's syndrome
Tracheal abnormality (tortuosity)	Mucopolysaccharidosis
Cervical spine abnormalities	Down's syndrome, Klippel-Feil, Mucopolysaccharidosis, Goldenhar

Table 1.
Anatomical malformations related to difficult airway in craniofacial syndromes.

- 8. History of a previous failed airway;
- 9. Soft tissue tumors and vascular malformations with significant obstruction of the airway.

3. General airway management in patients with craniofacial syndromes

The airway management plan of the infants and children with difficult airway has many proposed algorithms but not unified as in the American Society of Anaesthesiologists (ASA) adult difficult airway algorithm [4–7]. The awake intubation is no more a popular option in pediatric intubations except for some emergency situations where the patient is in severe distress and obstruction, as it carries its own disadvantages (increase in intracranial pressure ICP and intracere-bral hemorrhage ICH, gagging, uncooperative kid), hence induction of anesthesia with preservation of spontaneous breathing is the cornerstone for a safe airway management in patients with craniofacial syndromes with suspected difficult airway.

The airway provider should set a structured strategy for the management of the airway. Common practice is to have a “Plan A” as an initial approach with subse-quent plan B and C in case of failure of the former.

An otolaryngologist attendance for emergency backup surgical access (Bronchoscopy/Tracheostomy) is recommended during the management of the potential difficult airway.

A secured peripheral IV line prior to induction is recommended in patients with cranio-facial anomalies.

Presence of two airway experts (pediatric anesthesiologists) during induction is advisable.

Plan A: Preserve spontaneous ventilation:

- Induction using IV sedative medication: propofol infusion or boluses (also dexmedetomidine, ketamine)

Or

- Inhalation induction with Sevoflurane

While patient is spontaneously breathing, a careful insertion of the laryngoscope blade may be attempted provided that the patient tolerates without bucking or coughing.

A wide range of airway tools and techniques have been described for the intubation. However, it is crucial that the airway operator sticks with the tool that he is mostly familiar with. It is noteworthy to keep in mind that an airway tool is not a plan.

Techniques used for intubation of syndromic children with difficult airway include:

1. **Direct laryngoscopy:** a regular laryngoscope blade (a Macintosh curved or a Miller straight blade).

The paraglossal approach with a straight blade is a well-described technique for intubation in children with difficult airway where conventional laryngoscopy technique fails. Using this technique may allow the operator to avoid the large tongue commonly encountered in cranio-facial syndromes via inserting the laryngoscope's straight blade through the trench between the tonsils and the base of the tongue. This technique allows a better exposure of an anterior larynx; however, it does not provide an adequate space for tube manipulation, hence it requires a high level of skills by the operator.

Intubation with direct laryngoscopy may be facilitated with gum elastic bougie or a stylet.

2. **Video laryngoscopy:** video laryngoscopes such as the Storz video laryngoscope or the Glidescope have been successfully used for intubation in syndromic children with difficult airway. Despite the fact that the Glidescope provides an easy view, the intubation may be challenging due to the small "working" space and the curvature of the airway, especially in the smaller patients group.

3. **Fiberoptic bronchoscope intubation:** F.O.B intubation is a popular option as "first attempt" technique or as an alternative to a failed direct laryngoscopy and other techniques. It can be performed nasally, orally or through an LMA. However, its main disadvantage is that it might not be an option for neonates and smaller infants who require smaller endotracheal tubes that may barely accommodate the smallest F.O.B.

It is also challenging to perform F.O.B intubation in neonates who have a small airway as the field of vision in the distal lens is very narrow and might get easily obstructed whenever touching any obstacle, hence it requires a high-level skill set and expertise.

4. **Fiber-optic bronchoscope intubation through LMA:** F.O.B intubation through LMA is a popular technique of intubation for children with difficult airway. The LMA can serve for ventilation/oxygenation during the process

of intubation which is a very favorable advantage especially in children with difficult bag-mask ventilation.

However, the removal of the LMA might get complicated with accidental ETT extubation, thus many techniques have been described for the removal; however, the safest strategy remains keeping both the LMA and the ETT in place after intubation and removing them together at extubation.

5. Fiberoptic bronchoscope + GlideScope: The fiberoptic bronchoscope can be used as a guiding bougie for intubation, while the view is provided by the Glidescope. This technique will require two personnel: with one handling the Glidescope while the other manipulating the F.O.B. It is called the video-assisted fiberoptic intubation (VAFI) technique.

Plan B: If Plan A fails and ventilation becomes problematic at any step of the airway management, then an LMA should be immediately inserted. If manual bag-mask ventilation gets possible after LMA insertion, then the operator has a choice whether to keep it if appropriate for the procedure, to proceed with F.O.B intubation through the LMA or to use other techniques for intubation.

If “Cannot ventilate” through LMA, then the operator should immediately move to plan C.

Plan C: If attempts at ventilating via “Bag-Mask” and LMA fail, one attempt at direct laryngoscopy can be performed aiming at intubating if possible.

If all the previous attempts fail, then an emergency surgical airway must immediately be resorted to by the otolaryngologist with either an emergent rigid bronchoscopy placement or an emergency tracheostomy.

Extubation and post-extubation strategies: Extubation of patients with craniofacial anomalies directly at the end of the procedure should only be performed in the following conditions:

1. An atraumatic intubation with minimal airway edema
2. A minor short surgery not involving the airway (excluding adenotonsillectomies)
3. Absence of a history of severe obstructive apnea

The extubation should be performed when the patient is fully awake with vigorous spontaneous breathing and resumption of airway reflexes. The anesthesiologist must be ready for a re-intubation with all the airway tools set up should the extubation trial fail.

Patients at risk of post-operative airway obstruction such as obstructive sleep apnea must be monitored overnight in a high dependency unit (Apnea monitoring).

Patients with significant obstructive apneas undergoing major airway surgeries (such as mandibular distraction osteogenesis surgery) in which intubation might have been difficult or traumatic should not be extubated at the end of the procedure as they are at high risk of obstruction post-op which may necessitate an intubation that would likely be extremely difficult as exacerbated by the airway edema. Such patients should be kept intubated, properly sedated, and transferred to the ICU for post-monitoring. Intravenous steroids regimen should be given to minimize airway edema.

4. Craniofacial anomalies and airway management

4.1 Down's syndrome

Overview: Down's syndrome is the leading chromosomal disorder associated with intellectual disability worldwide. It is characterized by a bundle of multi-systemic morphologic features including cardiovascular, pulmonary, gastrointestinal, neurological, musculoskeletal, hematological, immunological, endocrine, ophthalmic, and hearing abnormalities. It was firstly described and published in the London Hospital Reports by a British doctor John Langdon Down in 1866 who called it "Mongolian type."

Genetics: Down's syndrome is a congenital autosomal disorder caused by the existence of a third copy, full or partial, of the chromosome 21 (HSA21), usually by nondisjunction [8].

Incidence: its average incidence is estimated to be about 1 in 800 live births and tends to increase with advanced maternal age.

Pathophysiology: This syndrome is caused by the existence of a third copy (either full or partial) of the chromosome 21 (HSA21) [8].

Clinical considerations: Down's syndrome is a multisystem disease associated with generalized growth retardation and varying degrees of mental impairment. Its clinical hallmarks encompass generalized neuromuscular hypotonia, atlantoaxial instability often associated with congenital cardiac anomalies (in particular an atrioventricular septal defect, a patent ductus arteriosus, or a tetralogy of Fallot) and gastrointestinal malformations (duodenal atresia and Hirschsprung disease) [4, 5, 9]. In addition, children with DS compared to healthy ones are more prone to multiple health issues, including obstructive sleep apnea, recurrent infections, hypothyroidism, epilepsy, audiovestibular and visual impairment, hematopoietic disorders (including leukemia), anxiety disorders, and early-onset Alzheimer disease. The physical appearance is pathognomonic with a chunky stature and a small round dysmorphic face.

In 1866, Dr. John Langdon Down, with few simple words, well described the main craniofacial features related to this disorder: a flat and broad face, narrow palpebral fissures, small nose, and long and thick tongue. These anomalies include a microcephaly, brachycephaly, a flattened occiput, a sloping forehead, midfacial hypoplasia, depressed nasal bridge, slanting eyes with epicanthic folds, hypotelorism, strabismus, and small ears with flat or absent helix. A cleft lip and/or palate may be present.

Airway and anesthetic implications: airway obstruction is common in children with Down's syndrome. A midface hypoplasia, narrow nasopharynx, choanal stenosis, high arched palate, pharyngeal muscle hypotonia, relative macroglossia, lingual tonsils, glossoptosis, adenotonsillar hypertrophy, micrognathia, short broad neck, and obesity, all these anatomical conditions combined together contribute to upper airway narrowing [6, 10]. In addition, various other structural airway anomalies may be present and diminish further the airway volume. They may be found isolated or combined together such as: laryngomalacia, subglottic stenosis, congenital tracheal, and bronchial anomalies [11]. They are highly suspected in children with Down's syndrome who have recurrent respiratory symptoms. Laryngomalacia and obstructive sleep apnea syndrome are the most common cause of upper airway obstruction below and above the age of 2 years old, respectively. Obstructive sleep apnea syndrome is reported with an incidence of approximately 30–55% of children with Down's syndrome and may be a potential indication of an adenotonsillectomy and/or home continuous positive airways pressure ventilation (BiPAP).

Collecting a detailed and accurate history from the parents is the first step in assessing the airways. Symptoms related to obstructive sleep apnea (snoring, choking, mouth breathing, sleep disturbances/restless sleep, diurnal drowsiness or fatigue) and a recent episode of upper respiratory tract infection should be noted. Any recent or active upper respiratory infection should prompt the physician to postpone any non-urgent surgery because of the high rate of postoperative respiratory complications. Examination of the oropharynx and head-neck is of utmost importance looking for any predictor of a difficult airway. A careful pulmonary examination is a must, and preoperative chest X-ray is not routinely required. An echocardiography is sometimes indicated to rule out any congenital heart defect or pulmonary hypertension [12].

The risk of upper airway obstruction at the induction of anesthesia for children with Down's syndrome is always present, hence a difficult airway management scenario must be anticipated. A difficult mask ventilation may necessitate insertion of an oropharyngeal or a nasopharyngeal airway. Tracheal intubation in children with Down's syndrome deserves special attention. The trachea is narrow and smaller than in healthy children, not only at the subglottic area but over its entire length and may be the site of numerous anatomical anomalies. When endotracheal intubation is indicated, a tracheal tube of 0.5 or 1 mm smaller than the expected one may be required due to the high risk of post-extubation stridor. It is recommended to monitor the ETT cuff pressure and keep it below 18 cm H₂O in order to lower the risk of post-extubation stridor, whereas a smooth and non-traumatic tracheal intubation should be the rule with cuffed ETT [1].

Cranio cervical instability is reported to be common in children with DS with an incidence of about 15% of the cases, mostly secondary to a hyperlaxity of the transverse ligament. Nonetheless, a malformation of the craniovertebral junction bones may be associated. Atlanto-occipital and atlanto-axial joints are at high risk of subluxation during airway manipulation which may result in compression of the underlying spinal cord [13]. Thus, a gentle and cautious manipulation of the neck and the head is required during the airway management of children with DS especially those with potential risk of cervical spine instability causing neurological deficit or at risk of worsening while under anesthesia. A cervical spine manual in-line immobilization approach must always be provided by an assistant during mask ventilation and intubation.

After surgery, a "no touch technique" awake extubation with the child kept in lateral position is preferred. Down's syndrome children with a history of obstructive sleep apnea are hypersensitive to opioid effects and need to be admitted for post-operative apnea monitoring (with continuous SPO₂ monitoring and a dedicated nurse) due to the high incidence of postoperative airway obstruction and hypoventilation. The use of non-invasive positive pressure support may be required for DS patients with severe OSA.

4.2 Pierre Robin sequence (PRS)

Overview: it is one of the congenital defects associated with abnormal anatomy of the airway imposing great challenges in its perioperative management. It was initially described by a French oral surgeon "Pierre-Robin" in 1923 as a clinical triad of: micrognathia (small mandible), glossoptosis (backward retraction of the tongue), and a subsequent airway obstruction [14]. The triad may be associated with a cleft palate in 50% of cases. PRS is classified as a sequence rather than a syndrome as it is representing succession of malformation events due to a sole cause, which is the failure in fetal mandibular development [15] (**Figure 1**).

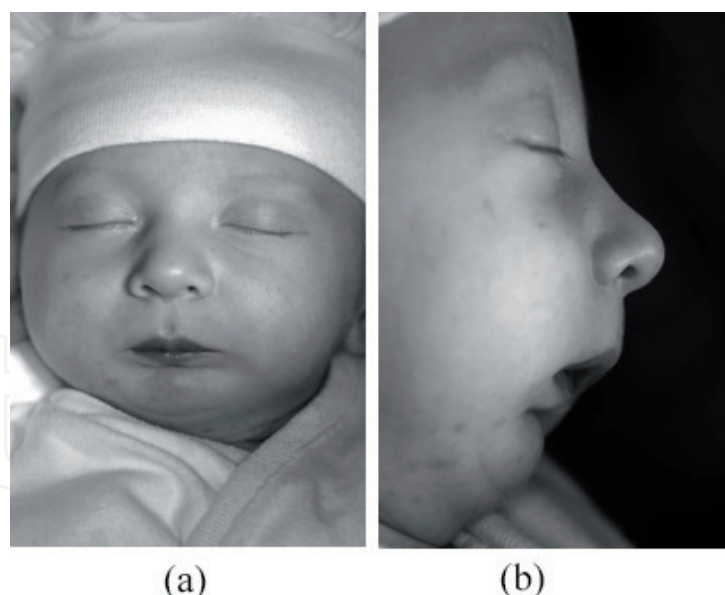


Figure 1.
Pierre Robin sequence frontal (A) and lateral (B) facial [16].

Infants may present with airway obstruction (stridor) and respiratory distress and may require multiple surgeries (tongue adhesion, mandibular distraction osteogenesis, or tracheostomy).

The major challenge to the anesthesiologist is managing the airway of such patients who are infamous to be difficult to bag-mask-ventilate and extremely difficult to intubate.

Incidence: isolated PRS prevalence can range from 1/8500 to 1/14,000 of births [15]; however, around 40–60% of the PRS cases are associated with other facial syndromes including Stickler, Treacher Collins, Velocardial, and fetal alcohol syndromes [14].

Genetics: the genetic etiology of isolated PRS is still debatable as some authors attribute it to “in utero” compression secondary to oligohydramnios, and others suggest its association with SOX9 and KCNJ2 dysregulation on chromosome 17. However, syndromic PRS is associated with genetic mutations such as the 22q, 11.2 microdeletion in the Velocardial syndrome and the COL2A1 COL9A1 COL11A1 mutations associated with the Stickler syndrome.

Pathophysiology: in all cases, PRS is the consequence of primary failure of the development of the mandible, which leads to the backward and downward displacement of the tongue (the normal tongue has no place to be accommodated in the extremely small submandibular space), consequently resulting in airway obstruction. In 50% of cases, a superiorly displaced tongue may prevent the fusion of the palatal arches leading to a cleft palate. The resulting chronic airway obstruction leads to repeated episodes of hypoxemia and hypercapnia culminating in sleep apnea, pulmonary hypertension, poor feeding, gastroesophageal reflux, and failure to thrive and chronic ear diseases.

Preoperative considerations and airway evaluation: multiple procedures might be needed for the child with PRS such as tongue/lip adhesion, mandibular distraction osteogenesis, tracheostomy, bronchoscopies, MRI/CT imaging, gastrostomy tube insertion, and Nissen fundoplication.

The preoperative evaluation should focus on risk factors which may contribute to difficult airway management including:

1. An extremely short hyo-mental distance of less than 1 cm (or a maxillary to mandibular discrepancy of more than 1 cm)

2. Obstruction of the airway when in supine position and the need to continuously maintain in prone positioning
3. Frequent desaturations and the need to provide supplementary oxygenation
4. Presence of OSA (may indicate severe airway obstruction)
5. Presence of pulmonary hypertension
6. History of a previous failed airway
7. Co-existing pulmonary disease (secondary to reflux/recurrent aspirations, laryngo-tracheo-broncho malacia, chronic lung disease...)
8. Presence of reflux and feeding difficulties (nasogastric-tube dependent) [17]

The airway examination must focus on taking a lateral “profile” look of the mandible, assessing for the mandibulo-maxillary discrepancy and the degree of micrognathia. As well as examining the oral cavity for the degree of glossoptosis (size and position of the tongue) and for the presence of a co-existing “cleft palate.”

The presence of any associated syndrome (Stickler, Velocardial, Treacher-Collins) or any heart murmur upon physical exam should prompt a request of a preoperative echocardiography as congenital heart anomalies are not uncommon in such patients.

Airway management in patients with PRS: the airway management plan of the infants and children with Pierre-Robin sequence must address the difficulties in bag-mask ventilation (BMV) and tracheal intubation [18]. The small chin may render the face mask difficult to provide a fit to seal the airway for BMV. With anesthetic induction, the backwardly placed tongue may adjoin the palate and subsequently completely block the airway rendering BMV more problematic. Insertion of a “Guedel” oropharyngeal airway (to overcome the obstruction) may not properly fit the patient because of the distorted airway anatomy, which adds further challenges to the BMV.

The glossoptosis and the micrognathia make the glottic opening more angled and further anteriorly displaced leading to a more anterior view with the laryngoscope. Also, the nearly absent submental space makes it impossible to accommodate the tongue during laryngoscopy which renders the view obstructed by the tongue as well as the difficulty to align the oro-pharyngo-laryngeal axes. The presence of a cleft palate may prevent proper position of the laryngoscope blade in the oropharynx hence further complicating the view.

Despite the subglottic anatomy is usually being normal in PRS, it should be remembered that the cricothyroid space is extremely small in infants which makes emergency crico-thyroidotomy an impractical option in case of the need of an emergency airway access, thus the presence of an ENT surgeon as a backup for emergency tracheotomy is recommended as an integral part of the airway management in children with PRS.

The main aim during anesthetic induction is to preserve spontaneous ventilation by avoiding muscle relaxants as not to “burn your bridges.” This could be achieved via a careful titration of IV propofol (infusion/boluses) or through inhalation induction.

Should the scenario of “Cannot Ventilate” occur at any moment of the airway management in children with PRS, a backup plan of alternative ventilation/oxygenation techniques must be imminently applied which includes first a

two-handed ventilation technique with oropharyngeal/nasopharyngeal airway, and if failed, an immediate insertion of an LMA.

In case of failure of the above techniques, a laryngoscopy attempt may be tried once as to relieve the obstruction done by the tongue and resumption of spontaneous breathing, or to possibly intubate. Should it fail, a prompt decision to establish an emergent surgical airway access (tracheostomy) by the otolaryngologist must be taken immediately.

If intubation was difficult and traumatic, then extubation should not be attempted at the end of the procedure, but rather the patient should be appropriately sedated/paralyzed and transferred to the ICU for post-operative care where extubation should be delayed until the patient is fully awake and has a positive leak test, along with the appropriate set up for a re-intubation in case of airway obstruction/respiratory distress.

4.3 Craniofacial dysostosis

4.3.1 Apert syndrome

Overview: also known as acrocephalosyndactyly Type I, this syndrome encompasses the following characteristics: premature closure of the cranial sutures, syndactyly of hands and feet, mid-facial hypoplasia, and midline calvarial defects from the glabella to the posterior fontanelle. Cervical spine fusion mainly at the level of C5-C6 is commonly involved, in addition to congenital cardiac defects. It was initially described by Eugene Charles Apert, a French pediatrician, in 1906 [4] (**Figure 2**).

Genetics: the genetic inheritance is of autosomal dominant nature, but mainly occurs through sporadic gene mutations of the FGFR-2 gene, mapped to 10q26.

Incidence: 1:65,000 to 1:160,000 of births. Males and females are equally affected. This syndrome represents 5% of all craniosynostoses.

Pathophysiology: Apert syndrome entails abnormal osseous development. The cranium and the extremities are most commonly implicated.

Clinical considerations: Characteristically, these patients have high forehead and flat facies, resulting mainly from coronal suture involvement. Abnormal facies have also been characterized by spheno-ethmoid-maxillary hypoplasia, a bulbous-tipped nose, a sunken nasal bridge, and a high arched palate and cleft. Frequently

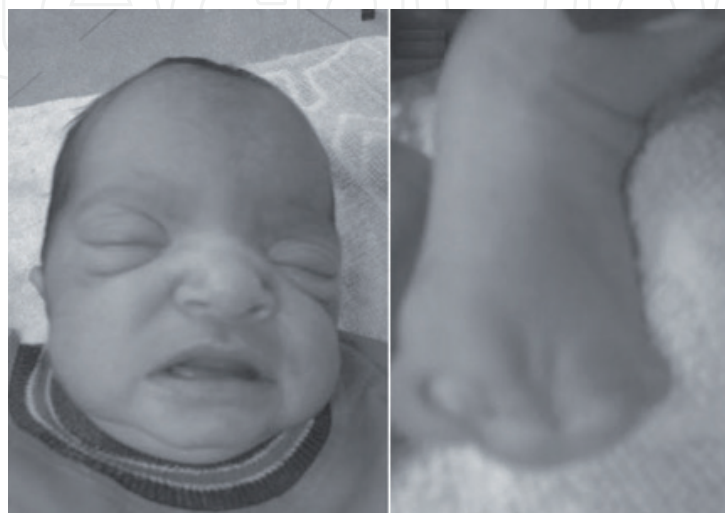

Figure 2.

Apert syndrome: prominent forehead, hypertelorism, proptosis, low set ears, open mouth, and feet with extensive syndactyly [19].

involved is choanal stenosis/atresia. In the context of the central nervous system, agenesis of the corpus callosum, hydrocephalus, an abnormal limbic system, and pyramidal tract have been portrayed. Early neurosurgical correction does not abate mental retardation in these patients. Seventy percent of these patients present with fusion of – more commonly – C5-C6 cervical vertebrae, although other levels may be involved. If limbs are involved, they often present with symmetric syndactyly (commonly the second, third, and fourth digits). Various joints (shoulders and hips) may be ankylotic or even aplastic. In the cardiac context, in 10% of the time, these anomalies involve patent ductus arteriosus (PDA), atrial septal defect (ASD), ventricular septal defect (VSD), Tetralogy of Fallot (TOF), pulmonary stenosis, or coarctation of the aorta. In the urologic context, 10% of these patients can present with polycystic kidneys, vaginal atresia, bicornuate uterus, hydronephrosis, and bladder neck stenosis. Airway/GI anomalies may occur in up to 2% of patients, including esophageal atresia, tracheoesophageal fistula, vertically fused tracheal rings, imperforate anus, biliary atresia, and pyloric stenosis [4, 7, 17].

Airway and anesthetic implications: thorough airway and head and neck evaluation is warranted prior to anesthesia administration in this condition. It would be important to ascertain whether there is any cervical spine fusion, abnormalities of the nasopharynx, palate, and/or trachea. Echocardiography is necessary to rule out congenital cardiac involvement. A chest radiograph may be indicated as many of these infants suffer respiratory complications during anesthesia. During anesthesia induction, one should prepare for likely difficult airway management. Maintenance of spontaneous ventilation until airway is secured is of vital importance. Alternate airway management techniques should be planned (video laryngoscope, fiberoptic intubation, and laryngeal mask airway). Depending on the type of the surgery, intravenous access and blood transfusion considerations are warranted accordingly [1, 20, 21].

4.3.2 Crouzon syndrome

Overview: this craniofacial dysostosis condition is very similar to Apert syndrome but does not necessarily involve extensive syndactyly. Crouzon syndrome is also known as acrocephalosyndactyly Type II. Clinical characters include hypertelorism (increased distance between the two orbits), exophthalmos, maxillary hypoplasia, and macrognathia. Initially designated by Octave Crouzon, a French neurologist, in 1912.

Genetics: autosomal dominant, but sporadic mutations occur in up to 50% of the cases. Genetically mapped to 10q26, encoding for the FGFR-2.

Incidence: 1:25,000 of births, with both males and females being equally affected, accounting for 4.5% of all cases of craniosynostoses.

Pathophysiology: the genetic mutation in this condition leads to accelerated maturation of osteoblastic cells, such that during fetal development, there is premature ossification of the calvaria leading to craniosynostosis (mainly involving the coronal, sagittal and at times the lambdoidal sutures).

Clinical considerations: maxillary hypoplasia associated with mandibular prognathism is commonly seen. Hypertelorism and proptosis are common ophthalmologic findings. It is common to find a high arched palate with a cleft and a bifid uvula. Choanal atresia has been demonstrated in Crouzon syndrome. Central nervous system findings include mental retardation, progressive hydrocephalus with associated intracranial hypertension, and very commonly an associated chronic herniation of the cerebellar tonsils. Twenty five percent of these patients present with cervical spine fusion most commonly at the level of C2-C3. Syndactyly is considered much less severe as compared to Apert syndrome [6, 7, 17].

Airway and anesthetic implications: Serious airway examination is necessary in this condition. Maxillary hypoplasia may lead to poor mask fit, and visualization of the vocal cords can be difficult with standard laryngoscopy. Choanal atresia must be assessed prior to anesthesia induction. Cervical spine fusion must be evaluated pre-operatively, as it can lead to difficulty with neck extension. One must also be mindful of intracranial pressure in the setting of progressive hydrocephalus and chronic tonsillar herniation. Depending on the degree of mental retardation, separation from family may pose a challenge. Difficult airway management is to be expected. Maintenance of spontaneous ventilation and oxygenation is necessary until the airway is secured. Alternate airway management techniques must be planned and pre-arranged (video laryngoscope, fiberoptic intubation, and laryngeal mask airway). A pre-operative echocardiograph is necessary, along with certain intraoperative management measures depending on the cardiac anomaly involved. Special consideration must include eyes protection in the setting of proptosis. Large bore intravenous access must be considered for major surgeries. In case of cranial vault reconstruction for craniosynostosis repair, the anesthesiologist must be mindful of the possibility of venous air embolism [1, 21, 22].

4.3.3 Pfeiffer syndrome

Overview: also known as acrocephalosyndactyly Type V, Pfeiffer syndrome involves sagittal craniosynostosis, maxillary retrusion of variable degrees, and soft tissue syndactyly. Mental retardation and congenital heart disease are commonly associated (**Figure 3**).

Genetics: it is autosomal recessive, with some cases presenting as de novo/sporadic mutations.

Incidence: extremely rare.

Pathophysiology: the genetic mutation involves the FGFR-1 and FGFR-1 genes involved in fetal mesenchymal integrity of the tissue that forms the bones, resulting in premature bony maturation and closure of the sutures, along with accelerated ossification of the calvaria.

Clinical considerations: much like Crouzon syndrome, Pfeiffer syndrome is commonly characterized by maxillary hypoplasia and flat facies, along with proptosis and hypertelorism. Strabismus is commonly present. This condition is linked to mild craniosynostosis and mainly involving the coronal and sagittal sutures. Limb findings are associated with broad thumb, great toe, and polysyndactyly. These

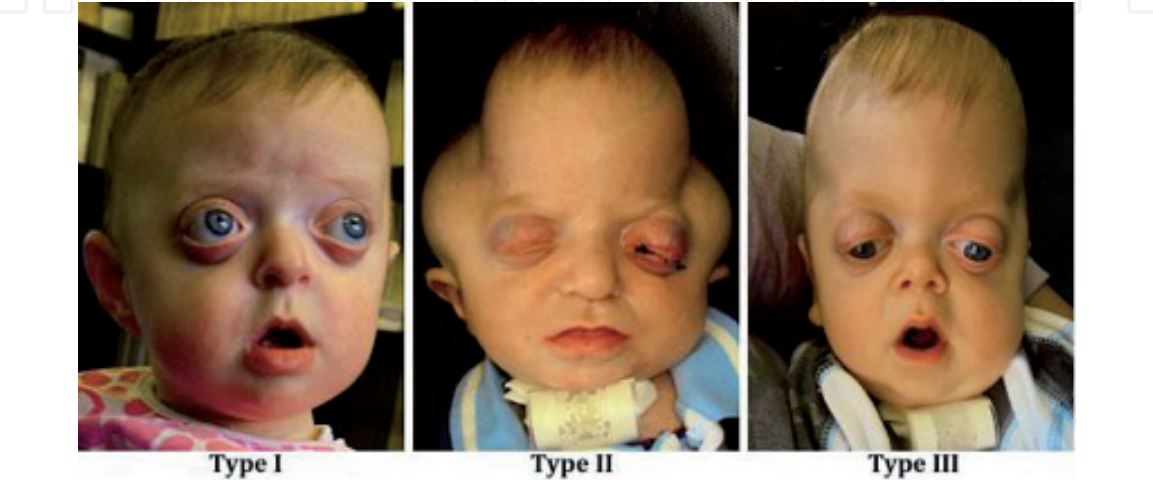

Figure 3.
Images of children with type 1,2,3 Pfeiffer syndrome [23].

patients also present with unpredictable degrees of hearing loss, mainly moderate to severe in most patients. Also, common findings are choanal atresia and cleft palate. Occasional associations include laryngomalacia, tracheomalacia, and bronchomalacia, along with fused cervical spine at varying levels in 30% of Pfeiffer syndrome patients. Other less common associations include Arnold-Chiari malformation, imperforate anus, and congenital heart disease [6, 7, 17].

Airway and anesthetic implications: the degree of mental retardation will dictate the difficulty of parental separation when shifting the patient to the operating room. Special consideration must include protecting the eyes in the presence of proptosis. Difficulty in airway management is to be expected and anticipated. Maintenance of spontaneous ventilation and oxygenation until the airway is secured is of vital importance. Alternate airway management techniques must be prepared and available (video laryngoscope, fiberoptic intubation, and laryngeal mask airway). Depending on the degree of congenital cardiac anomalies present, special considerations are to be undertaken. A large bore intravenous or central venous access is to be considered for more involved procedures, along with readiness for blood transfusion. In the setting of increased intracranial pressure, special consideration includes the maintenance of cerebral perfusion pressure intraoperatively, with a keen eye on mean arterial blood pressure [1, 24, 25].

4.4 Treacher Collins syndrome (TCS)

Overview: also known as mandibulofacial dysostosis or Franceschetti-Zwahlen-Klein syndrome, Treacher Collins syndrome (TCS) is recognized as being one of the most severe craniofacial malformation disorders and one of the most challenging airways encountered by an anesthesiologist [26]. Hallmark features include malar and mandibular hypoplasia, bilateral anotia or microtia often associated with bilateral conductive hearing loss, antimongoloid slanting of the eyelid fissures and lower lid colobomas. Although this syndrome was firstly described in 1846 by Thompson, and reported as a congenital disease with coloboma of the lower eyelids by George Andreas berry in 1889, its name is associated to a British ophthalmologist Edward Treacher Collins, who, in 1990 published a case report of two patients with these ocular and periorbital sequelae (**Figure 4**).

Genetics: known to be a very rare genetic disease, TCS results from a mutation on the TCOF1 gene in most individuals but rare cases were reported secondary to mutation of the POLR1C or POLR1D gene. It is an autosomal dominant inherited disorder. Only about 1% of cases are inherited in an autosomal recessive pattern [28].

Incidence: it has a prevalence of about 1 in 50,000 live births, without predisposition for sex or race.

Pathophysiology: this is a defect of the neural crest formation which affects the first and second branchial arches, grooves, and pouches during the second month of intrauterine life resulting in an oto-mandibular dysplasia associated with other craniofacial anomalies [28].

Clinical considerations: the clinical features associated with Treacher Collins syndrome involve the head and neck and appear to be bilateral with relatively symmetrical distribution. They are variable in severity, mainly including zygomatic, mandibular and maxillary hypoplasia, micrognathia, external ear malformations, hearing loss, high arched palate, antimongoloid slanting of the eyelid fissures, colobomas, total or partial absence of lower eyelashes, and midface bones hypoplasia resulting in a pathognomonic bird-like face appearance with a protruded nose and small rounded face. It may also impact the oral cavity with dental malocclusion and anterior open bite. The hypoplasia of the mandible is more severe at the condyle than at the ramus and the body, which could be potentially responsible for temporomandibular joint

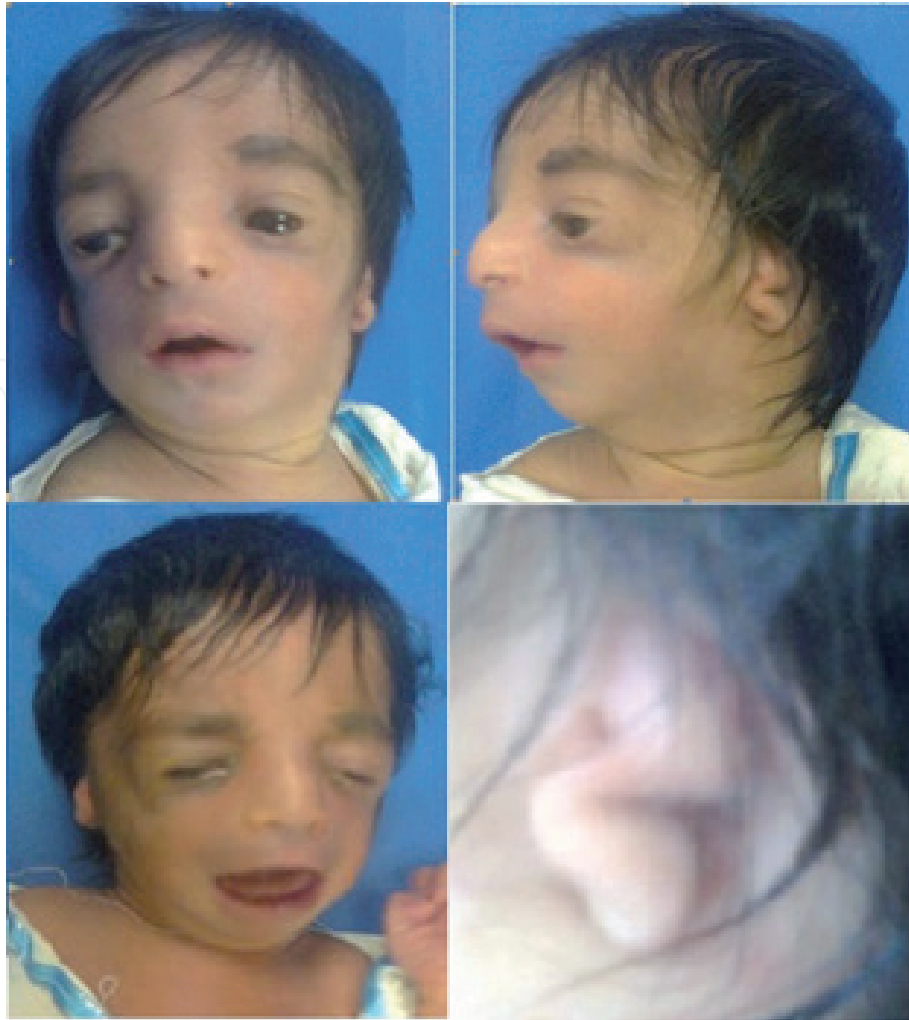

Figure 4. Treacher Collins syndrome with characteristic facial features including downward and laterally slanting palpebral fissures, paucity of lashes and lack of naso-frontal angle, bird like appearance, micrognathia, microtia (deformed pinna), macrostomia, and large tongue [27].

dysfunction and mouth opening limitation. TCS is associated with Cleft Palate in 30% of the cases, and pharyngeal hypoplasia is commonly associated as well. All these anomalies can disrupt several functions like breathing, swallowing, chewing, and speech. Systemic manifestations, namely cardiac, renal, and skeletal, especially cervical vertebral defects, may also be observed [1, 4, 6, 7, 17].

Airway and anesthetic implications: Treacher Collins syndrome (TCS) was firstly reported as a hazard for general anesthesia in 1963 by Edward Ross due to the difficulty in maintaining a free and adequate airway. Several associated mechanisms are the cause, namely mandibular hypoplasia, micrognathia, retrognathia, posterior displacement of the bulky tongue, and the pharyngeal hypoplasia, resulting in a small and narrow retromandibular space [29, 30]. The presence of a temporomandibular joint abnormality or a small mouth aperture may further worsen the case. Thus, upper airway obstruction is common at induction of anesthesia and may require an airway manual maneuver (a two-hand mask ventilation, chin lift, and jaw thrust) and insertion of an oropharyngeal/nasopharyngeal airway. If unsuccessful, insertion of a supraglottic airway device such as a laryngeal mask airway before intubation is indicated. In addition, the failure rate of direct intubation is extremely high owing to the difficulty in alignment of the three axes (oral, pharyngeal, and laryngeal axes), which complicates further the visualization of the glottis. The degree of severity worsens with increasing age mainly because of the decreased mandibular growth.

A rigorous and warily planned algorithm is the success key in the management of the airways in children with Treacher Collins syndrome. Consultation of previous anesthesia records is of valuable aid, and a meticulous airway reassessment is required. A preoperative 3D tomographic images help assess anatomical features of the upper airway and guide the choice of the best airway management plan.

A laryngeal mask airway (LMA) is indicated for short and superficial procedures. But, whenever tracheal intubation is required, the spontaneous ventilation during anesthetic induction must be maintained until securing the airways. Fiberoptic intubation represents the preferred technique. It is facilitated by application of traction on the tongue, and a jaw thrust with a backward-upward-rightward pressure ("BURP") maneuver. Awake fiberoptic intubation is challenging in the pediatric population owing to the lack of cooperation. Other several techniques have been successfully used for tracheal intubation, namely fiberoptic intubation through LMA, fiberoptic-assisted laryngoscopy, blind nasal intubation, retrograde intubation, Shikani Optical Stylet (SOS), indirect videolaryngoscopy with GlideScope Ranger, Airtraq optical laryngoscope, Airway Scope or C-MAC videolaryngoscope with D-Blade, and tracheostomy as the last option. The use of TruView EVO2 laryngoscope for reintubation after accidental extubation in a neonate with TCS was also reported [26, 31].

TCS patients undergoing major surgical procedures involving the airway should be kept intubated and sedated in the intensive care unit (PICU) until subsidization of the edema. For short surgical superficial procedures not involving the airway, extubation may be attempted based on the clinical judgment of the anesthesiologist and the hospital set up. Before extubation, a nasopharyngeal airway must be inserted and maintained during the postoperative period in order to prevent upper airway obstruction.

4.5 Goldenhar's syndrome (GS)

Overview: Goldenhar's syndrome, also called Facio-auriculo-vertebral syndrome or Oculo-Auriculo-Vertebral syndrome, is a variant of hemifacial microsomia disorders that affect the eye, ear, nose, lip, soft palate, and mandible, and often associated with vertebral and cardiac anomalies. It was initially reported in 1952 by a Belgian-American ophthalmologist Maurice Goldenhar. In 1963, Gorlin introduced the term "Oculo-Auriculo-Vertebral syndrome" due to the presence of associated vertebral anomalies (**Figure 5**).

Genetics: the exact etiology remains unclear. Most cases are sporadic, but some rare familial cases were reported suggesting autosomal dominant or recessive inheritance [33].

Incidence: Goldenhar's syndrome occurs in about 1 in 3000 to 1 in 5000 live births, affecting males predominantly. Male to female ratio is 2:1.

Pathophysiology: this hemifacial microsomia is caused by the underdevelopment of the first and second branchial arches during the 4th week of gestation resulting in craniofacial anomalies, ocular anomalies, vertebral anomalies, and cardiac defects.

Clinical considerations: Goldenhar's syndrome (GS) is a multisystem syndrome with a wide spectrum of clinical features. Craniofacial anomalies are unilateral in 90% of the cases and include mandibular hypoplasia, hypoplastic zygomatic arch, micrognathia, macrostomia, external and middle ear malformations (microtia, preauricular appendages, and atresia) often with sensorineural hearing loss, and eye anomalies (epibulbar dermoids, lipodermoids, microphthalmos, and coloboma). Nevertheless, in 10% of cases both facial sides may be affected with one side typically more affected than the other. Oral cavity anomalies like palate anomalies

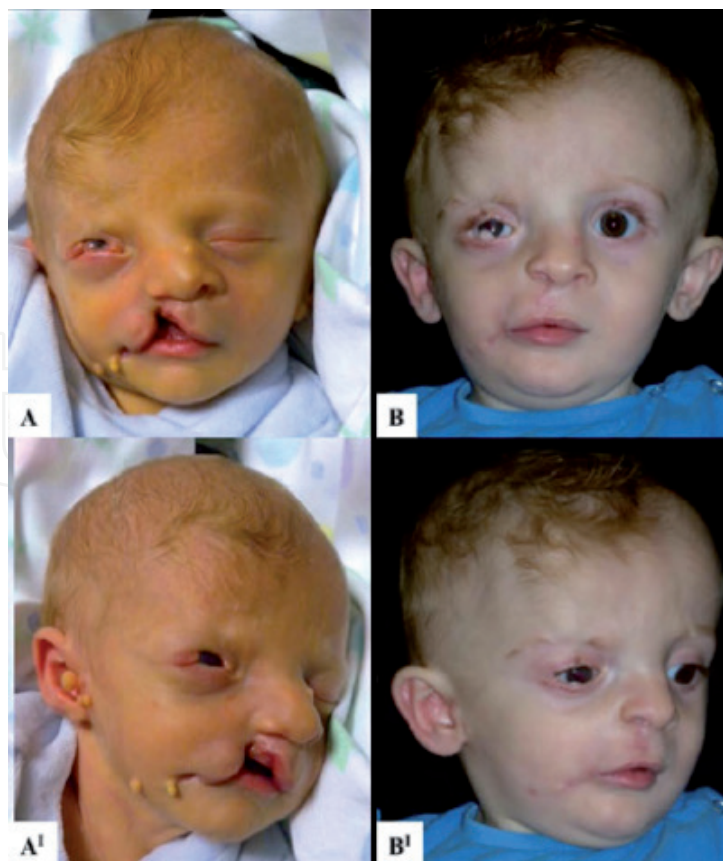


Figure 5. Goldenhar's syndrome before and after surgical procedure for lip and palatoplasty, correction of macrostomia and nasal septum deformity, excision of pre-auricular tags: (A) preoperative; (B) postoperative [32].

(high arch or cleft) and tongue anomalies are often associated. Additionally, almost 50% of children with Goldenhar's syndrome may have vertebral defects, especially at the cervical level, such as hemivertebrae or hypoplasia, along with a potential risk of subluxation at the atlanto-occipital joint. Neck movements are limited during flexion and extension, increasing the rate of difficult or failed tracheal intubation procedure. Congenital cardiac structural malformations (Tetralogy of Fallot and septal defects) are present in about one third of the cases. In rare cases, some degrees of mental retardation and other systemic anomalies, mainly genitourinary, pulmonary, and vascular are reported [4, 6, 7, 17].

Airway and anesthetic implications: anesthesia or sedation may be provided for children with Goldenhar's syndrome for various procedures (ear reconstruction, distraction osteogenesis, soft tissue reconstruction, skin graft, cardiac, etc.).

The anesthetic management is risky because of the difficult airway. The degree of difficulties depends directly on the severity of craniofacial anomalies and associated vertebral defects and tends to worsen progressively with increasing age. Detecting patients at risk in the preoperative setting may anticipate challenging airway situations. Consultation of previous anesthesia records is of a valuable help; however, the airway must be reassessed before any new airway manipulation. The degree of severity of mandibular hypoplasia correlates with difficult tracheal intubation. Virtual imaging using 3D CT or cone-beam computed tomography may be indicated for selected patients to assess the airway anatomy looking for anomalies [34].

Facemask ventilation is challenging in children with Goldenhar's syndrome due to a poor mask seal, often requiring the use of a gauze with self-adhesive tape to provide an adequate seal. The reason for this poor mask fit is the facial asymmetry and the presence of a soft tissue slit extended from the side of the mouth to the middle of the cheek on the abnormal hemi-face.

Tracheal intubation is usually more difficult to achieve than maintaining airway patency, especially in the case right-sided hemifacial microsomia. Several combined conditions may contribute to difficult intubation, including retrognathia, micrognathia, asymmetrical hypoplasia of the mandible, limited mouth opening, palatal anomalies, potentially associated vertebral defects, and limited neck motion. The hypoplastic mandible reduces the retromandibular space. The relatively bulky tongue is displaced posteriorly overhanging the larynx, thus making visualization of the vocal inlets difficult, even nearly impossible during conventional laryngoscopy.

Although fiberoptic intubation (FOB) technique is one of the popular options for securing difficult airways of patients with GS, various strategies can be adopted successfully to perform tracheal intubation; however, it is recommended that the airway operator sticks with the tool and technique that is the most familiar to his practice. These include: FOB through LMA (video-assisted fiberoptic intubation (VAFI)), GlideScope, Air-Q, Airtraq, C-MAC D-blade or C-MAC Miller-blade videolaryngoscopy, Pentax-AWS Airwayscope with tracheal introducer, Laryngeal Mask Airway helped by Pediatric Boussignac Bougie or retrograde tracheal intubation. The Truview PCD® laryngoscopy has proven its effectiveness and offers the advantage of continuously supplying oxygen via its oxygenation side port during the procedure. When the intubation is not required, LMA or nasopharyngeal airway constitutes a possible alternative [1, 35, 36].

4.6 Klippel-Feil syndrome (KFS)

Overview: it was initially described by Klippel and Feil in 1912 as a clinical triad of an extremely short “compressed” neck, a low hairline at the rear end of the skull, and a limited mobility of the neck caused by fusion of two or more cervical vertebrae. Despite being discovered as a triad, it is not uncommon for patients with KFS to meet just one clinical criterion of the above. It may be associated with other anomalies (**Figure 6**).

Genetics: Klippel-Feil syndrome is an inherited autosomal dominant condition. It is the result of an anomalous partition of the cervical somites during embryogenesis between the third and eighth week of gestation.

Incidence: KFS has a prevalence of 1:40000 to 1:42000 of live births.

Clinical considerations: KFS is classified into three classes according to the level and severity of the spine fusion, with type 1 representing a considerable fusion of numerous cervical vertebrae, type 2 representing fusions of one or two cervical vertebrae, and type 3 representing cervical vertebrae fusions combined with thoracic and/or lumbar vertebral fusions.

KFS may be related to other anomalies such as cranio-facial deformities including craniosynostosis, cleft lip, micrognathia, and laryngeal defects. Thoracic deformities such as scoliosis may be present in addition to other skeletal deformities like scapular elevation (Sprengel's). Uro-genital malformations are commonly present as well as congenital heart defects most commonly the VSD.

Neurological deficits with hyperlaxed cervical spines and neuro-degeneration with fused spines are commonly associated with KFS [17].

Airway and anesthetic implications: KFS is often associated with difficult intubation, evidently because of the fixed neck which does not allow proper extension of the atlanto-axial joint during laryngoscopy and the subsequent advanced Cormack-Lehane view. Many reports describe a grade 4 view with a conventional laryngoscope.

Screening patients at risk for cervical spine instability is a crucial step before airway management in order to avoid spinal injury, especially those with

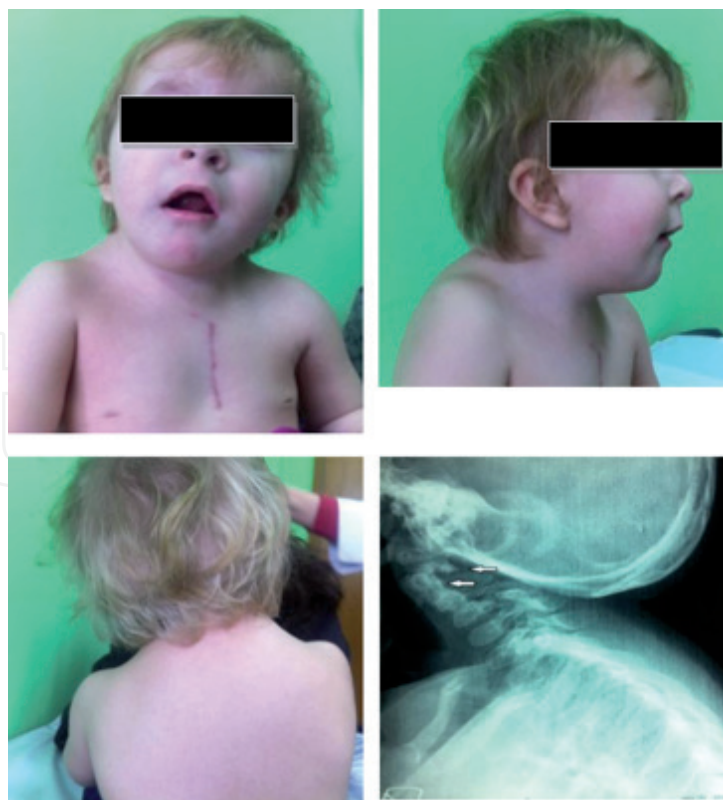

Figure 6. Child with Klippel-Feil syndrome and anomaly of the Occipito-cervical junction. The images show an elevated left shoulder due to a Sprengel anomaly, a short, webbed neck, and a low hairline (scar on the thorax after surgical repair of nonrestrictive atrial septal defect) [37].

hyperlaxed spines who may require C-spine precautions with in-line-stabilization during intubation. This is performed via a lateral neck X-ray in flexion and extension positions [1, 4–7].

Obstructive sleep apnea (OSA) is not uncommonly encountered in patients with KFS, hence a preoperative sleep study may be indicated along with postoperative apnea monitor. A preoperative echocardiography must be considered especially in patients with pulmonary hypertension secondary to OSA and scoliosis.

A history of previous smooth intubation in KFS patient does not implicate a future favorable outcome due to the progressive nature of the disease. Hence, a careful preoperative assessment and planning is critical for safe airway management.

Bag-mask ventilation is likely difficult in those patients as well as direct laryngoscopy owing to the fixed neck or the in-line neck stabilization.

Should the older child be cooperative enough to sustain an awake fiberoptic intubation (with light sedation) that would be the approach of choice avoiding both the risks of difficult ventilation and neck injury secondary to airway manipulation.

Otherwise, a plan to preserve spontaneous ventilation during anesthetic induction should be performed with either total intravenous anesthesia (TIVA) or inhaled Sevoflurane (IV Dexmedetomidine and IV Ketamine can be used as well) avoiding the use of neuro-muscular blockers.

A trial of manual bag-mask to assess for ventilation is used by some practitioners before airway manipulation. The various arrays of airway tools including video-scopes (Glidescope/C-MAC etc.) as well as the fiberoptic bronchoscope have been used successfully for intubation in patients with KFS. They are preferred as first line intubation technique due to the lower incidence of cervical spine mobilization when used.

It is important to keep in mind that the option of an emergency surgical airway such as cricothyrotomy/tracheostomy is very limited in patients with KFS due to the extremely short neck, thus the airway approach must be very carefully planned.

Extubation must only be attempted when the patient is fully awake and in the presence of protective airway reflexes. An opioid-sparing anesthetic technique is recommended (regional anesthesia whenever possible) as the presence of OSA may increase narcotic-sensitivity. KFS patients should preferably be monitored in the post-operative setting in a high dependency unit or an intensive care unit according to the severity of their cardio-pulmonary and airway pathology.

If the patient is on a home BIPAP, it will be required after extubation.

4.7 Beckwith-Wiedemann syndrome

Overview: it was initially reported by J Bruce Beckwith and Hans-Rudolf Wiedemann. It is one of the syndromes associated with a huge tongue that may impose challenges to airway management (**Figure 7**).

Genetics: it is caused by genetic alterations on chromosome 11p15 region.

Incidence: 1 per 13,700–15,000 of live births.

Clinical considerations: Beckwith-Wiedemann syndrome is characterized by a clinical tetrad of macroglossia (Most common), omphalocele, umbilical hernia, and neonatal hypoglycemia.

These children are associated with exomphalos, macroglossia, gigantism, macrosomia, visceromegaly, horizontal earlobe creases, renal medullary dysplasia, cardiac malformations, hypoglycemia, hypothyroidism, hyperlipidemia, polycythemia, hypercalciuria, and embryonal tumors. The presence of three features out of the above will confirm the clinical diagnosis of BWS after ruling out the clinical features of overgrowth syndromes. The risk for embryonal tumor development especially hepatoblastoma, neuroblastoma, rhabdomyosarcoma, gonadoblastoma, and adrenal carcinoma has been observed [6, 7, 17].

Airway and anesthetic implications: the main anesthetic considerations in BWS are abnormal airway anatomy, hypoglycemia, and cardiac anomalies (cardiomegaly and other cardiac structural defects). A detailed pre-operative assessment of the airway, the cardiac, and the urinary system is mandatory. Visceromegaly may shift the diaphragm upward reducing functional residual capacity. Associated congenital malformations, prematurity, and interventions early in life may complicate anesthetic management. These children frequently require corrective surgical

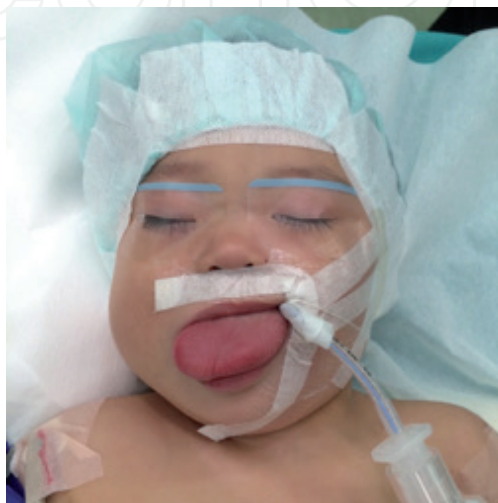

Figure 7.
Macroglossia in the patient with Beckwith-Wiedemann syndrome after intubation [38].

interventions in infancy such as tongue reduction surgeries, hernia repair, exomphalos repair or hepatectomy.

Preoperative assessment should include a careful evaluation of the airway focusing on the mouth opening, tongue size, and preoperative head and neck imaging if required. It should focus also on other systems involvement such as the heart, hence an echocardiography is recommended. The genito-urinary system and the liver must be evaluated in addition to the preoperative glucose homeostasis.

The major challenge during airway management of a patient with Beckwith-Wiedemann syndrome pertains to the huge tongue which might completely obstruct the airway with anesthetic induction rendering the bag-mask ventilation and intubation difficult to perform [39, 40].

Hence a careful plan A, with a backup plan B and a plan C must be organized beforehand. An intravenous line is recommended to be secured before induction. Keeping spontaneous ventilation is considered to be the safest approach to the airway that can be achieved with intravenous anesthetics or inhalational Sevoflurane and by avoiding non-depolarizing neuro-muscular blockers. Some practices may use muscle relaxants after making sure of the ability to ventilate by a trial of ventilation after induction. Sugammadex muscle (rocuronium antidote) has allowed more confidence for anesthesiologists to give muscle relaxants in order to facilitate intubation.

A variety of tools can be used for intubation ranging from the direct laryngoscopes aided by a Gum elastic Bougie or a stylet, to the Videoscopes including the C-MAC and the Glidescope, to the fiberoptic bronchoscope.

A plan B consists of inserting a laryngeal mask airway should ventilation become problematic, and in case of the latter's failure, a plan C with a surgical airway must be immediately implemented.

Extubation must only occur when patient is fully awake and may be helped with a nasopharyngeal airway "in-situ" to help overcoming the tongue's obstruction in the immediate post-operative period. Patients with BWS must have a post-operative monitoring after surgery in the high dependency area or the intensive care unit.

4.8 Mucopolysaccharidosis (MPS)

Overview: the mucopolysaccharidoses (MPS) are a set of storage diseases caused by a disordered or absent lysosomal hydroxylase enzyme leading to the build-up of muco-polysaccharides (glycosaminoglycans (GAG)) in the connective tissues, the musculo-skeletal system and the visceral organs. They are classified as seven syndromes with each involving a mix of 11 enzymatic disorders [41]. Mucopolysaccharidoses patients are associated with a high incidence of difficult bag-mask ventilation which represents the "nightmare" for the anesthesiologist or the airway operator.

Incidence: as a rare set of conditions, MPS accounts for less than 0.1% of all genetic but have been reported throughout the world in various forms. Region and ethnic background may affect the phenotype of MPS.

Genetic: inheritance autosomal recessive.

Pathophysiology: the mutation in lysosomal hydroxylase enzyme leads to an impaired metabolism of mucopolysaccharides (GAG) which will accumulate in multiple body tissues leading to macroglossia, adenotonsillar hypertrophy, and laryngeal/tracheal tissue distortion and narrowing.

Some types of MPS (Type1: Hurler, Type 4: Morquio, and Type 6: Maroteaux-Lamy) may be associated with atlantoaxial subluxation and odontoid hypoplasia which may lead to spinal cord compression with subsequent neurological deficit. Accumulation in the cervical spines may lead to a short and fixed neck. The

temporo-mandibular joint may get affected with restricted mobility. Deposition of mucopolysaccharides in the heart and vascular tissues may lead to cardiomyopathies, arrhythmias, and pulmonary hypertension [5].

Clinical considerations and airway management: difficult ventilation and intubation are common concerns in patients with mucopolysaccharidoses as the thick and uncompliant infiltrated tissues (skin, tongue, and mucous membranes of the airway, bones, and joints) may render the natural airway narrow and not distensible by the positive pressure ventilation applied by the bag-mask. Laryngoscopy is often challenging due to difficult manipulation of the laryngoscope as a result of the stiff and thick tissues. The large tongue, the hypertrophied tonsils, and the limited mouth opening are caused by the immobile temporo-mandibular joints [40]. This effect is compounded if there is a subluxation of the atlanto-axial joint or cervical-spine affection which mandates an in-line-stabilization during airway management.

A narrow/distorted trachea may prevent an appropriately sized endotracheal tube from passing throughout the vocal cords.

Fortunately, the enzymatic replacement therapy may hinder the progression of the disease, hence an adequately treated mucopolysaccharidosis patient may have a lesser risk of difficult airway than the untreated patient.

Preoperatively, the MPS patient must be well assessed for the extent of the disease as well as a focused airway assessment including the mouth opening, tongue and tonsillar size, presence of obstructive sleep apnea (which is very common in MPS), and pulmonary hypertension. A preoperative echocardiography is essential to rule out any associated cardiomyopathy. Patients with MPS type 1 (Hurler), 4 (Morquio), and 6 must be checked for any cervical spine or atlanto-axial instability [42].

Intravenous cannulation in MPS patients may be challenging due to the thick infiltrated skin, hence a preoperatively inserted intravenous line before anesthetic induction is preferable.

Spontaneous ventilation must be maintained during induction of anesthesia due to the high risk of difficult ventilation in case of apnea. This could be achieved with either intravenous or inhalational induction agents and by avoiding neuro-muscular blockers.

An LMA must be used as a second plan whenever encountering difficulties in ventilation; it can also be used to facilitate fiberoptic intubation.

Video-laryngoscopies are other favorable options for intubation in MPS patients especially those with unstable cervical spine owing to the lesser risk of neck mobilization when used. Establishment of a surgical airway access such as tracheostomy may be difficult due to the thick tissues and the associated tracheal deformities.

5. Craniofacial vascular malformations (VMs)

Vascular anomalies are disorders of abnormal vasculogenesis or lymphogenesis. They can involve any part of body and can present in any phase of development. They include different types according to histopathology and anatomical site.

VMs may be with other syndromic malformations such as Parkes-Weber, Sturge-Weber, Klippel-Trenaunay Servelle-Martorell, PHACE and LUMBAR syndromes.

5.1 Subglottic hemangiomas

Overview: infantile hemangioma (IH) is the most prevalent vascular anomaly of the head and neck. It may cause a life-threatening airway obstruction if located in the glottic/subglottic area.

Incidence: its prevalence is approximately 4–5% mainly in fair-skinned kids. It is more common in girls and commonly associated with cutaneous hemangiomas.

Pathophysiology: the infantile hemangioma is a benign proliferative disorder of the vascular endothelial-like cells. It is believed to be due to a dysregulated angiogenesis resulting in neovascularization caused by the disordered differentiation of the embryonic mesenchymal cells. It has two phases, a proliferative one which starts as early as the first few weeks of life and continues progression and growth in size until late childhood, and an involution phase where the tumor begins shrinking in size until complete disappearance which is eventually due to the replacement of the endothelial cells with fibroblasts and fat cells. IH may occur at any place in the head and neck, starting as a small lump and then enlarging in size. Patients with IH are usually asymptomatic unless the tumor is present in the airway and reaches considerable size to cause obstructive symptoms. Hemangiomas of the airway may cause snoring, hemoptysis, hoarseness, stridor, and respiratory distress, which requires early intervention. Propranolol therapy plays a great role in its shrinkage [43].

Airway evaluation and management: history, imaging (MRI), and endoscopic studies are essential in the preoperative evaluation. Patients with glottic/subglottic lesions may easily get airway obstruction upon anesthetic induction. An LMA/supraglottic for rescue ventilation may not be an option if the obstruction is infraglottic. Laryngoscopy and intubation may be complicated by bleeding if the tumor is traumatized which may completely impede the view and render airway management more challenging. Preserving spontaneous breathing with either inhalational or intravenous anesthetic and avoiding muscle relaxants is a safe approach until the airway is secured. Postoperative extubation should not be attempted until resolution of the airway edema. Intensive care (PICU) and postoperative steroids are indicated after major airway lesions endoscopic excision.

5.2 Lymphatic/lymphaticovenous malformations (cystic hygroma)

Overview: also called cavernous hemangioma. It is a multi-loculated benign congenital tumor affecting preferably the head and neck. It can present as a neck mass on prenatal ultrasound [5]. Airway compromise can be the sequelae of direct compression from the mass and/or bony changes following mandibulomaxillary hypertrophy (**Figure 8**).

Incidence: approximately 1 in 6000 live births, 70–80% occur in the neck, usually in the post cervical triangle.

Pathophysiology: it is a combination of lymphatic and venous cells. They may present at different sizes and progress in growth after birth. It might get complicated with bleeding or infection which may considerably increase their size. The clinical presentations are related to its size and the anatomy involved.

Clinical evaluation and airway management: large masses involving the airway can cause potential airway compromise according to the location and the size of the tumor. Tracheal compressions can be present with neck and mediastinal lesions. Tongue, pharyngeal or laryngeal involvement may present with significant airway obstruction. The treatment is often LASER or surgical excision and always requires a pre-inserted tracheostomy or an “in place” endotracheal tube prior to the procedure. Imaging is required in all cases, and tumors located in the mediastinum require further investigation. Sedatives should be used with caution because of their potential to aggravate the airway obstruction. Maintaining spontaneous ventilation via inhalational or intravenous induction is the cornerstone of a safe anesthetic approach when managing the airway of patients with CH. In case of complex and high-risk lesions, a tracheostomy under local anesthesia may be indicated prior to the procedure. Aspirating the cyst to shrink its size prior to

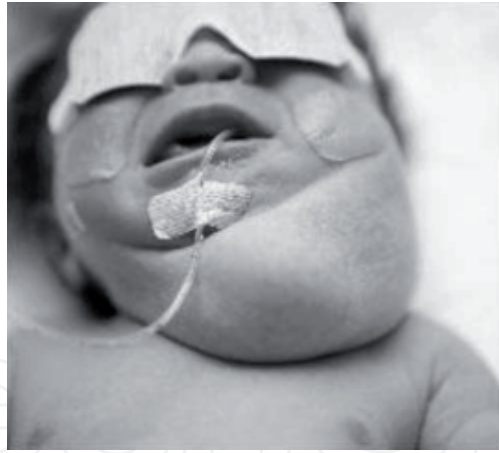

Figure 8.
Huge movable mass is found out on the left neck [44].

facilitate intubation has been reported but at the expense of complicating further the surgery. Post-operative intensive care (PICU) monitoring is indicated for high-risk lesions [45, 46].

5.3 Arterio-venous malformations

Arterio-venous malformations (AVM) involving the face and the airway are rare to occur. The main issue with airway management is the risk of massive bleeding that can occur if the AVM has been traumatized when managing the airway.

Clinical evaluation and airway management of children with vascular malformations involving the airway: a thorough preoperative history and physical exam are of utmost importance in anticipating a potentially difficult airway in children with vascular malformations. Clinical imaging (CT, MRI and 3-D reconstruction) and endoscopic evaluation may be necessary to establish the diagnosis and identify the size and location of the pathology. Even with a meticulous airway evaluation, an unanticipated difficult airway can still occur, hence an effective preparation before airway evaluation is crucial. An airway management strategy should be tailored according to each patient's airway pathology including a back-up approach should the initial one fails and an emergency rescue plan [47].

General anesthesia with an inhaled agent such as Sevoflurane or an intravenous agent (such as propofol, ketamine or dexmedetomidine) while maintaining spontaneous ventilation is the technique of choice. Video laryngoscopy, FOB-guided endotracheal intubation, and endotracheal intubation through an LMA are the most popular strategies for intubation.

A pre-procedure tracheostomy inserted under local anesthesia may be indicated for high risk malformations with severe airway obstruction [48].

6. Conclusion

The airway management of children with craniofacial abnormalities imposes great challenges owing to the difficulties in ventilation and intubation potentially encountered in most of the syndromes as well as the other systems involvement. A careful anticipation, preparation, and planning are key elements for a safe and successful airway management. The approach to each patient should be tailored according to the extent of the relevant abnormalities following a strategy of a simple clear plan A with a backup plan B and C. Preserving spontaneous breathing is one

of the safe practices when patients are at risk of difficult ventilation. The use of the most familiar airway tools is pivotal in achieving favorable results. Extubation is an integral part of the airway management and should only be performed when the child meets its criteria and in a controlled environment. Post-extubation monitoring in a critical care or an observation area must be carried out for patients at risk of airway obstruction.

Acknowledgements

Special thanks for Dr. Habib El Bechouti, senior anesthesia consultant in Sidra Medicine, Qatar and Dr. Yasser Hammad, senior anesthesia consultant in Hamad Medical Corporation, Qatar for their valuable comments, chapter editing, and reviewing.

Conflict of interest

The authors declare no conflict of interest.

Author details

Brahim Boudjenah^{1*}, Al Moataz Billah Adham², Surendra M. Chinnappa¹, Omed Assaf¹ and Mashaal Al-Khelaifi¹

1 Hamad Medical Corporation, Doha, Qatar

2 Sidra Medicine, Doha, Qatar

*Address all correspondence to: bboudjenah@hamad.qa

IntechOpen

© 2020 The Author(s). Licensee IntechOpen. This chapter is distributed under the terms of the Creative Commons Attribution License (<http://creativecommons.org/licenses/by/3.0>), which permits unrestricted use, distribution, and reproduction in any medium, provided the original work is properly cited. 

References

- [1] Raj D, Luginbuehl I. Managing the difficult airway in the syndromic child. *Continuing Education in Anaesthesia, Critical Care & Pain*. 2015;**15**(1):7-13. DOI: 10.1093/bjaceaccp/mku004
- [2] Waisel DB, Truog RD, Todres ID. Ethical issues in pediatric anesthesiology. In: Cote CJ, Lerman J, Todres ID, editors. *The Pediatric Airway*. 4th ed. Vol. 8. Philadelphia, PA: Saunders Elsevier; 2009. pp. 71-87
- [3] Krishna SG, Bryant JF, Tobias JD. Management of the difficult airway in the pediatric patient. *Journal of Pediatric Intensive Care*. 2018;**7**(3): 115-125. DOI: 10.1055/s-0038-1624576
- [4] Mann D, Garcia PJ, Andropoulos DB. Anesthesia for the patient with a genetic syndrome. In: Andropoulos DB, Gregory GA, editors. *Gregory's Pediatric Anesthesia*. 6th ed. Wiley-Blackwell; 2020. pp. 1085-1105. DOI: 10.1002/9781444345186.ch38
- [5] Oliveira CRD. Pediatric syndromes with noncraniofacial anomalies impacting the airways. *Paediatric Anaesthesia*. 2020;**30**(3):304-310. DOI: 10.1111/pan.13810
- [6] Garcia-Marcinkiewicz AG, Stricker PA. Craniofacial surgery and specific airway problems. *Pediatric Anesthesia*. 2020;**30**:296-303. DOI: 10.1111/pan.13790
- [7] Nargozian C. The airway in patients with craniofacial abnormalities. *Paediatric Anaesthesia*. 2004;**14**(1):53-59. DOI: 10.1046/j.1460-9592.2003.01200.x
- [8] Antonarakis SE, Skotko BG, Rafii MS, et al. Down syndrome. *Nature Reviews. Disease Primers*. 2020;**6**(1):9. DOI: 10.1038/s41572-019-0143-7
- [9] Stoll C, Dott B, Alembik Y, Roth MP. Associated congenital anomalies among cases with Down syndrome. *European Journal of Medical Genetics*. 2015;**58**(12):674-680. DOI: 10.1016/j.ejmg.2015.11.003
- [10] Korayem M, Nuha MA, Waleed B, Eman A, Wafa A, Reem A. Craniofacial manifestations of Down syndrome: A review of literature. *Academia Journal of Scientific Research*. 2019;**7**(3):176-181
- [11] De Lausnay M, Verhulst S, Boel L, Wojciechowski M, Boudewyns A, Van Hoorenbeeck K. The prevalence of lower airway anomalies in children with Down syndrome compared to controls. *Pediatric Pulmonology*. 2020;**55**(5):1259-1263. DOI: 10.1002/ppul.24741
- [12] Lewanda AF, Matisoff A, Revenis M, et al. Preoperative evaluation and comprehensive risk assessment for children with Down syndrome. *Paediatric Anaesthesia*. 2016;**26**(4): 356-362. DOI: 10.1111/pan.12841
- [13] Rodrigues M, Nunes J, Figueiredo S. Neuroimaging assessment in Down syndrome: A pictorial review. *Insights into Imaging*. 2019;**10**:52. DOI: 10.1186/s13244-019-0729-3
- [14] Cladis F, Kumar A, Grunwaldt L, Otteson T, Ford M, Losee JE. Pierre Robin sequence: A perioperative review. *Anesthesia and Analgesia*. 2014;**119**(2):400-412. DOI: 10.1213/ANE.0000000000000301
- [15] Izumi K, Konczal LL, Mitchell AL, Jones MC. Underlying genetic diagnosis of Pierre Robin sequence: Retrospective chart review at two children's hospitals and a systematic literature review. *The Journal of Pediatrics*. 2012;**160**(4):645-650.e2. DOI: 10.1016/j.jpeds.2011.09.021
- [16] Kılıç SC, Kılıç N, Oktay H, Kiki A. Pierre Robin sequence from orthodontic and surgical perspective. *World Journal*

of Stomatology. 2014;**3**(4):30-37. DOI: 10.5321/wjs.v3.i4.30

[17] Bissonnette B, Luginbuehl I, Marciniak B, Dalens B. Syndromes: Rapid Recognition and Perioperative Implications. New York: McGraw-Hill Education; 2006. Available from: <https://accessanesthesiology.mhmedical.com/book.aspx?bookid=852>

[18] Elmatite W, Haykal N, Upadhyay S, Pizzuto M, Watt S. Airway management in neonates with Pierre Robin syndrome along with Mobius syndrome and platoglossal fusion. *Journal of Anesthesia and Clinical Research*. 2017;**8**:1000757. DOI: 10.4172/2155-6148.1000757

[19] Panigrahi I. Craniosynostosis genetics: The mystery unfolds. *Indian Journal of Human Genetics*. 2011;**17**(2):48-53. DOI: 10.4103/0971-6866.86171

[20] Nargozian C. Apert syndrome. Anesthetic management. *Clinics in Plastic Surgery*. 1991;**18**:227

[21] Cinalli G, Renier D, Sebag G, et al. Chronic tonsillar herniation in Crouzon's and Apert's syndromes: The role of premature synostosis of the lamboid sutures. *Journal of Neurosurgery*. 1995;**83**:575

[22] Sculerati N, Gottlieb MD, Zimble MS. Airway management in children with major craniofacial anomalies. *Laryngoscope*. 1998;**108**:1806

[23] Amjadi H. The role of genetic mutations in genes FGFR1 & FGFR2 in Pfeiffer syndrome. *Journal of Pediatrics and Neonatal Medicine*. 2019;**1**(2):110

[24] Digilio MC, Marino B, Borzaga U, Giannotti A, Dallapiccola B. Intrafamilial variability of Pfeiffer-type cardiocranial syndrome. *American Journal of Medical Genetics*. 1997;**73**:480

[25] Meyer P, Renier D, Blanot S, Orliaguet G, Arnaud E, Lajeunie E. Anesthesia and intensive care of craniostenosis and craniofacial dysmorphism in children. *Ann Fr Anesth Reanim*. 1997;**16**:152

[26] Hosking J, Zoanetti D, Carlyle A, Anderson P, Costi D. Anesthesia for Treacher Collins syndrome: A review of airway management in 240 pediatric cases. *Pediatric Anesthesia*. 2012;**22**:752-758

[27] Al-Mosawi AJ. Genetic and hereditary disorders in Iraqi children. *Annals of Medical & Surgical Case Reports: AMSCR-1000011*; 2019

[28] Duque C, Lopes Cardoso I. Treacher Collins syndrome and implications in the oral cavity. *Clinical Research and Trials*. 2019;**5**:1-5. DOI: 10.15761/CRT.1000278

[29] Ribeiro A d A, Smith FJ, Nary Filho H, Trindade IEK, Tonello C, Trindade-Suedam IK. Three-dimensional upper airway assessment in Treacher Collins syndrome. *The Cleft Palate-Craniofacial Journal*. 2020;**57**(3):371-377. DOI: 10.1177/1055665619885555

[30] Ma X, Forte AJ, Berlin NL, Alonso N, Persing JA, Steinbacher DM. Reduced three-dimensional nasal airway volume in Treacher Collins syndrome and its association with craniofacial morphology. *Plastic and Reconstructive Surgery*. 2015;**135**(5):885e-894e. DOI: 10.1097/PRS.0000000000001160

[31] Ratnamma V, Navaratnarajah J. 141 Treacher Collins syndrome – Retrospective review of airway management techniques. *Archives of Disease in Childhood*. 2018;**103**:A56-A57. DOI: 10.1136/goshabs.141

[32] Villani R, Michelina VV, Fabbri E, Zarabini AG, Morselli PG. Goldenhar

syndrome: Surgical planning in a severe case with cleft lip and palate, coloboma and macrostomia. *JSM Head and Face Medicine*. 2017;**2**(1):1003

[33] Bogusiak K, Puch A, Arkuszewski P. Goldenhar syndrome: Current perspectives. *World Journal of Pediatrics*. 2017;**13**(5):405-415. DOI: 10.1007/s12519-017-0048-z

[34] Molins G, Valls A, Guijarro R, Hernández-Alfaro F. Mandibular hypoplasia and narrow airway in Goldenhar syndrome: Anticipation of difficult intubation with cone-beam computed tomography. *Journal of Clinical Anesthesia*. 2016;**34**:1-2. DOI: 10.1016/j.jclinane.2016.03.031

[35] Orozco ST, Latorre JLR, Saldarriaga CA. Infant with Goldenhar syndrome: Failed intubation and rescue using fiberoptic and i-gel laryngeal mask. *Trends in Anaesthesia and Critical Care*. 2020;**30**:e30. DOI: 10.1016/j.tacc.2019.12.077

[36] Sinha R, Pangasa N, Nethaji R, Maitra S. Successful use of C-MAC Miller blade in neonate with Goldenhar syndrome and cleft lip with cleft palate: A case report. *Acta Anaesthesiologica Belgica*. 2019;**70**:39-41

[37] Bejiqi R, Retkoceri R, Maluku A, Bejiqi R, Mustafa A, et al. How often is Klippel-Feil syndrome associated with congenital heart disease presentation of five cases and a review of the literature. *Journal of Cardiology and Cardiovascular Medicine*. 2019;**4**:110-116. DOI: 10.29328/journal.jccm.1001050

[38] Tsukamoto M, Hitosugi T, Yokoyama T. Perioperative airway management of a patient with Beckwith-Wiedemann syndrome. *Journal of Dental Anesthesia and Pain Medicine*. 2016;**16**, 4:313-316. DOI: 10.17245/jdapm.2016.16.4.313

[39] Batra M, Valecha UK. Anesthetic management of tongue reduction in a case of Beckwith-Wiedemann syndrome. *Journal of Anaesthesiology Clinical Pharmacology*. 2014;**30**:562-564

[40] Channabasapa SM, Pradeep SH, Dharmapa S, Sarji D. Anesthetic management of a neonate with Beckwith-Wiedemann syndrome posted for repair of exomphalos. *Saudi Journal of Anaesthesia*. 2016;**10**:249-250

[41] Kloesel B, Holzman RS. Anesthetic management of patients with inborn errors of metabolism. *Anesthesia and Analgesia*. 2017;**125**:822-836

[42] Walker R, Belani KG, Braunlin EA, Bruce IA, Hack H, Harmatz PR, et al. Anaesthesia and airway management in mucopolysaccharidosis. *Journal of Inherited Metabolic Disease*. 2013;**36**:211-219

[43] Shayan YR, Prendiville JS, Goldman RD. Use of propranolol in treating hemangiomas. *Canadian Family Physician*. 2011;**57**(3):302-303

[44] Hyunzu K, Hyuk-Soo K, Jung-Tak O, Jeong RL. Anesthetic management for neonate with giant cystic hygroma involved upper airway – A case report. *Korean Journal of Anesthesiology*. 2011;**60**(3):209-213. DOI: 10.4097/kjae.2011.60.3.209

[45] Rao KS, Shenoy T. Anesthetic management of a large cystic hygroma in a newborn. *Anesthesia, Essays and Researches*. 2015;**9**(2):270-272

[46] Braga AFA, Frias JAF, Braga FSS, et al. Anestesia para tratamento intraparto extra-útero em feto com diagnóstico pré-natal de higroma na região cervical. *Revista Brasileira de Anestesiologia*. 2006;**56**(3):278-286

[47] Clarke C, Lee EI, Edmonds J Jr. Vascular anomalies and airway concerns. *Seminars in Plastic*

Surgery. 2014;**28**(2):104-110. DOI:
10.1055/s-0034-1376265

[48] Jacobs IN, Cahill AM. Special
considerations in vascular anomalies:
Airway management. Clinics in Plastic
Surgery. 2011;**38**(1):121-131. DOI:
10.1016/j.cps.2010.08.008

IntechOpen

IntechOpen