

# We are IntechOpen, the world's leading publisher of Open Access books Built by scientists, for scientists

6,900

Open access books available

186,000

International authors and editors

200M

Downloads

Our authors are among the

154

Countries delivered to

TOP 1%

most cited scientists

12.2%

Contributors from top 500 universities



WEB OF SCIENCE™

Selection of our books indexed in the Book Citation Index  
in Web of Science™ Core Collection (BKCI)

Interested in publishing with us?  
Contact [book.department@intechopen.com](mailto:book.department@intechopen.com)

Numbers displayed above are based on latest data collected.  
For more information visit [www.intechopen.com](http://www.intechopen.com)



# Novel Application of Immunomodulatory Mushroom Polysaccharide ( $\beta$ -Glucan) and Triterpenes for Diabetic Wound Care

*Shiu-Nan Chen, Yu-Sheng Wu, Sherwin Chen,  
Ya-Chin Chang and Chung-Lun Lu*

## Abstract

$\beta$ -Glucan and triterpenes are two important derivative compounds from traditional medicinal mushroom, such as *Ganoderma lucidum* and *Antrodia cinnamomea*.  $\beta$ -glucan and triterpenes are considered to have immunoregulatory properties in disease treatment for long years. The immunoregulatory effects are usually activated through some transcription of pro-inflammatory genes and possess immunomodulatory activity. Difficulty in healing wound now is a common condition that occurred in diabetic patients, and the physiological hyperglycemic status of diabetic patients resulting in the wounds continue to produce an inflammatory response. Thus, we hope to use  $\beta$ -glucan and triterpenes for difficult wound healing that possess immunomodulatory activity on the wound micro-environment and stimulate the positive effects on healing. In this chapter, these two important derivative compounds from traditional medicinal mushroom were examined by diabetic mammal's wound healing models. In these models, the skin wounds' microenvironment is expected close to diabetic foot, suffering in hyperglycemic and inflammatory status. The results are clearly presented, with the immunomodulatory effects from mushroom  $\beta$ -glucan and triterpenes that involved in modulating the cell-mediated immune system to cause cellular proliferation and further to introduce healing performance of the chronic inflammation wounds.

**Keywords:** mushroom polysaccharide,  $\beta$ -glucans, triterpenes, immunomodulatory, diabetic, wound healing

## 1. Introduction

Diabetes is a metabolic disease characterized by hyperglycemia resulting from defects in insulin secretion or function, and is associated with the long-term damage, dysfunction, and failure of various organs, especially the eyes, kidneys, nerves, heart, and blood vessels [1]. One of the main consequences of diabetes is the impairment of self-repairing abilities [2]. Various studies have indicated that diets high

in saturated fat and cholesterol contribute to hypercholesterolemia and metabolic disturbances, which may cause hyperglycemic condition in humans and animals [3]. Hyperglycemia can rapidly become severe hyperglycemia and/or ketoacidosis in the presence of infection or other types of stress. The inducing stress can result from the presence of excessive counter regulatory hormones (glucagon, growth hormone, catecholamine, and glucocorticoid; either endogenous or exogenous) and high circulating or tissue levels of inflammatory cytokine [1, 4]. As many reports have shown, a wound healing is an intricate regulation mechanism, which involves many cell populations and molecular mediators, and is one of the key mechanisms that ensures the barrier functions of the skin and the maintenance of body homeostasis. The efficiency of this process is largely determined by the balance of proinflammatory and proregenerative signals, which are mediated by cytokines [5, 6]. But in patients who suffer from diabetes mellitus, chronic wounds occur often due to the impairment of wound healing; major complications of diabetes lead to inflammation and oxidative stress, delayed wound healing, and persistent ulcers. The impaired healing in diabetes is the result of a complex pathophysiology involving vascular, neuropathic, immune, and biochemical components. Hyperglycemia correlates with stiffer blood vessels, which cause slower circulation and microvascular dysfunction, causing reduced tissue oxygenation. Blood vessel alterations observed in diabetic patients also account for reduced leukocyte migration into the wound, which becomes more vulnerable to infections. The hyperglycemic environment itself can compromise leucocyte function. In addition, peripheral neuropathy can lead to numbness of the area and reduced ability to feel pain, which can lead to chronicization of wounds that are not immediately noticed and properly treated [7].

In this chapter, two immunomodulatory extracts ( $\beta$ -glucan and triterpenes) from popular medicinal mushroom were assessed by scientific experiments to examine the functions for treating poorly healing wounds. These immunomodulatory extracts have been studied for its biological effects in mammals widely, and reported to possess antitumor and immunomodulating activities with anti-inflammatory effects and the ability to control tissue cytokines [8–10]. Here, the scientific experiment results of wound healing were consolidated and the novel application of derivative compounds from traditional medicinal mushroom can be used for treatment of diabetic foot in the future.

## 2. $\beta$ -Glucan from mushroom and its diabetic wound caring

### 2.1 Mushroom $\beta$ -glucan functions for wound caring

Glucan is a polysaccharide structure which is constructed by D-glucose, linked by glycosidic bonds. It is now a common product usually obtained by extracting its components from fungi [11] (such as mushrooms) or yeast cell walls and it has been known in recent studies to effectively stimulate immune cells; it not only can enhance specific immune responses of the organism, but also enhance the nonspecific immune response, and is a good immune regulator. One group of the glucan, the beta-glucans ( $\beta$ -glucans), is a heterogeneous group of glucose polymers consisting of  $\beta$ -(1,3)-linked  $\beta$ -d-glucopyranosyl units with a  $\beta$ -(1,6)-linked side chain of varying distribution and lengths. These polysaccharides are of different chemical compositions, with most belonging to the group of  $\beta$ -glucans; these have  $\beta$ -(1  $\rightarrow$  3) linkages in the primary chain of the glucan and additional  $\beta$ -(1  $\rightarrow$  6) branch points that are needed for their bioactive response [12, 13]. Many species of mushroom can produce glucan, such as *Ganoderma lucidum*, *Grifola frondosa*, *Pleurotus ostreatus*, *Lentinula edodes*, *Cordyceps militaris*, and so on [14].

Research on  $\beta$ -glucans application has indicated that this bioactive immunomodulating substance not only enhances the organism's ability to resist infection by bacteria, fungi, viruses, and parasites, but even has the effect of inhibiting tumor growth [15]. This novel immunomodulating substance is thought to mediate effects through activation of various immune system components including macrophages, neutrophils, natural killer (NK) cells, and lymphocytes. Moreover, they are demonstrated to possess immunostimulatory activity and enhance wound healing especially by increasing macrophage infiltration into the injury sites and stimulating tissue regeneration [16].


In the field of wound healing, it has been pointed out by many related studies that by activating macrophages,  $\beta$ -glucan can stimulate the regeneration of collagen and help wound healing [17]. In 2001, Kougias and others found that in addition to the receptors on immune cells, (1-3)- $\beta$ -D-glucans receptors were also found on human dermal fibroblasts. Making fibroblasts directly receive messages from glucans represents a factor that promotes wound healing not only by activating macrophages, but also by stimulating fibroblasts [18]. In study of the mechanism between fibroblasts and wound healing, we can find that after being stimulated by  $\beta$ -glucan, fibroblasts activate two translation factors (transcription factors)-AP-1 (activator protein-1), SP1 (specific protein-1), and two signaling pathways-NF- $\kappa$ B (nuclear factor- $\kappa$ B), NF-1 (nuclear factor-1), can strengthen the immune response at the wound site and promote the hyperplasia and the expression of collagen precursor genes (procollagen genes), thereby generating collagen, to achieve the effect of wound healing [18, 19]. The results from a reference illustrated that mushroom polysaccharides derived from *Schizophyllum* (1-3), (1-6)- $\beta$ -D-glucans, were mixed with gelatin to make artificial skin, either by in vitro cell culture or transplanted into mice, which led to the observation of the growth of new tissues and finding that they all have the effect of promoting epidermal cellization [20]. Mushroom  $\beta$ -glucan's (MBG) role has also been confirmed in tests on the recovery of liver cuts in fish and skin wounds in rats. By stimulating the mechanism of Wnt/ $\beta$  catenin signaling signal transmission, liver cell hyperplasia, and cellular activity, it promotes wound healing [13]. In the application of  $\beta$ -D-glucans in wound healing, it has a reduced chance of infection after surgery [21]; the synthesis of polysaccharides and collagen matrix can promote the recovery of local deep scald skin also has a medical effect for the relief of patients' pain [22].

## 2.2 Mushroom $\beta$ -glucan (MBG) applied in advanced dressing to promote diabetic wound healing (mammal testing model)

In 2018, we carried out a study on mushroom  $\beta$ -glucan (MBG) from *G. lucidum* for testing wound healing in animals. The purified  $\beta$ -glucan of *G. lucidum* was mixed with carboxymethyl cellulose fiber and water, and then through Poly-charge/ion exchange for compounding, and the composite fiber solution is prepared into a fiber sponge substrate by a freeze-drying process, that patented technology from Taiwan Textile Research Institute, to form a sponge dressing contain mushroom  $\beta$ -glucan (**Figure 1(a)**). Carboxymethyl cellulose fibers and  $\beta$ -glucan form the structure of a sponge, and the mushroom  $\beta$ -glucan-containing particles are evenly dispersed in the fiber sponge (**Figure 1(b)**). The swelling ratio of the fiber sponge substrate sample is about 22–32 times. It has the effect of absorbing fluid, which means that it can provide the effect of absorbing too much exudate if it is used on wounds with a lot of exudate, and maintain the proper moisture of the wound to promote wound healing.

The prepared fiber sponge substrate has a high magnification of moisture absorption and swelling ratio and an appropriate structural stability that causes the

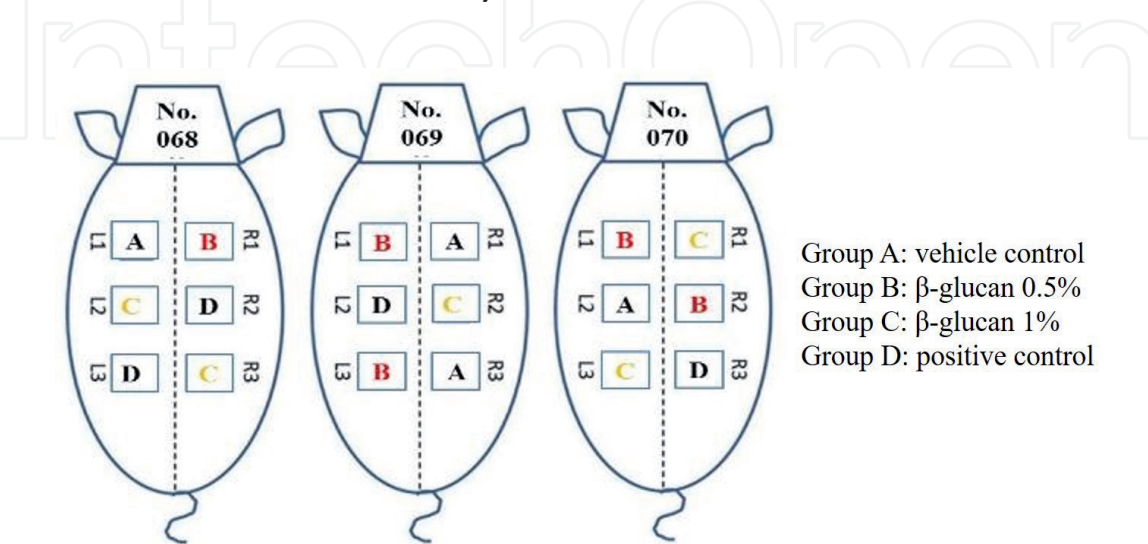




**Figure 1.** Mushroom  $\beta$ -glucan-containing bio-fiber sponge dressing. (a) Appearance of mushroom  $\beta$ -glucan-containing bio-fiber sponge dressing; (b) mushroom  $\beta$ -glucan-containing particles dispersed in the fiber sponge structure (1000 $\times$ ).

release of mushroom  $\beta$ -glucan (MBG) in the substrate slowly. It is expected that it will have an extended-release ability to produce immunostimulatory polysaccharides, which can improve the shortcomings of commercially available sponge dressing products.

In an experiment using three diabetic model pigs, we explored whether mushroom  $\beta$ -glucan (MBG) sponge dressing can accelerate wound healing rate when applied to man-cut wounds. For the present study, all the mammal experiments were performed in accordance with protocol by the Institutional Animal Care and Use Committee (IACUC) of Agricultural Technology Research Institute (ATRI, in Taiwan). Type I diabetes pigs were manual Streptozotocin-induced (to generate chronic wound healing), housed, and surgery was operated in SPF animal room facilities by ATRI Animal Technology Laboratories. Six square wounds ( $2 \pm 0.5 \text{ cm} \times 2 \pm 0.5 \text{ cm}$ ) with full skin layer on the back of one pig were formed by manual operation, three on each side, L1, L2, L3 on the left; R1, R2, R3 on the right (schematic diagram in **Figure 2**), and randomly apply the test mushroom  $\beta$ -glucan (MBG) sponge dressing or control dressing to the wound in the above. Then, the wound healing of each test substance was continuously observed, and the effect of the test substance

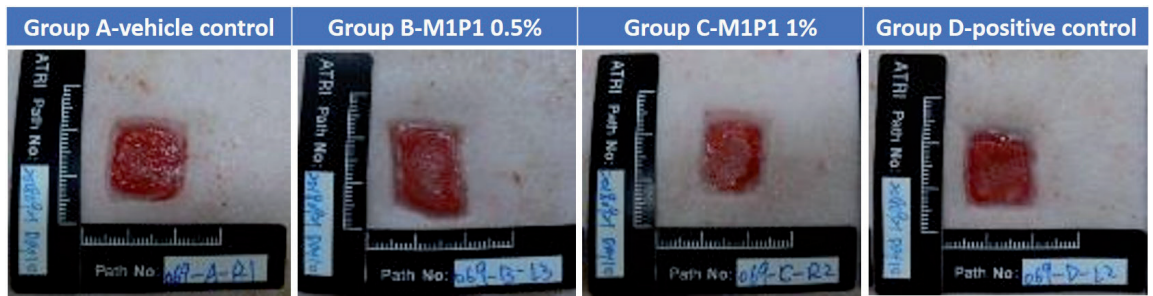


**Figure 2.** Wounds with full skin layer on the diabetic pig. Six square wounds ( $2 \pm 0.5 \text{ cm} \times 2 \pm 0.5 \text{ cm}$ ) with full skin layer on pigs were formed by manual operation, randomly apply the test mushroom  $\beta$ -glucan (MBG) sponge dressing or control dressing to the wound in the above (three pigs, each test dressing  $N = 4$  or  $5$ ).

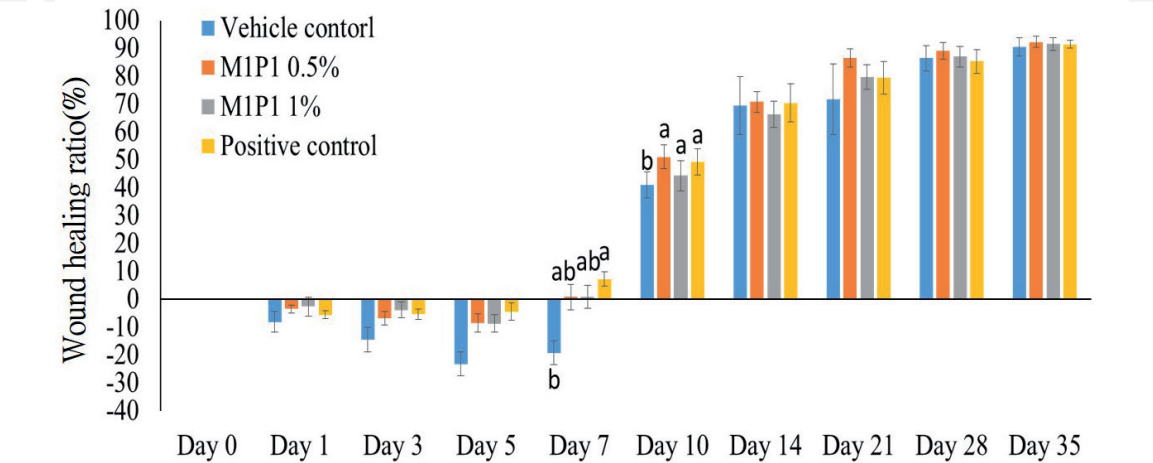
on wound healing was explored based on pathological interpretation. During the test period, the test substances in each group did not affect the growth of the pigs and also did not cause death.

In data calculation, the average value (mean) and standard error of the mean (SEM) of each test group were calculated by Microsoft Excel, and finally presented in the report as mean  $\pm$  SEM. In statistical analysis, one-way ANOVA was performed with IBM SPSS Statistics 20 analysis software, and the Scheffe's post-mortem analysis method was used. The lowercase letter labels in figures mean that there is a significant difference between those who do not have the same letter at the observation time point ( $p < 0.05$ ). In the experimental results, on the 10th day of the experiment, the secretion of tissue fluid of each test group decreased, and it was observed that the granulation tissue had grown to fill the entire wound, forming a bright red and smooth appearance, and the neonatal epithelial tissue could be observed at the edge of the wound, the wound area was significantly reduced, for example in **Figure 3**. The degree of wound healing speed was group B: 51.1% > group D: 49.2% > group C: 44.3% > group A: 41.0%. In statistical analysis results: group A and group B, group A and group C, group A and group D reach statistical significance  $p < 0.05$ . The statistical significance of group B and C was not more than  $p > 0.05$ , and the statistical significance of group B and D was not more than  $p > 0.05$ . Group C and D did not reach statistical significance  $p > 0.05$ . The test mushroom  $\beta$ -glucan (MBG) sponge dressing showed better wound healing performance than vehicle control (**Figure 4**).

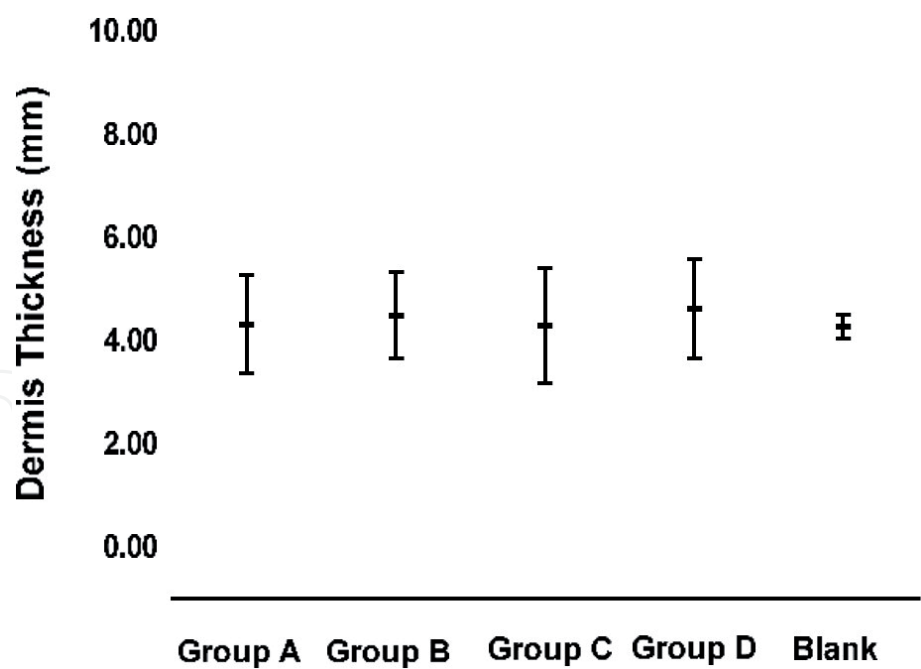
In the histopathological examination result, the thickness of the skin dermal layer and epidermal layer were measured to evaluate the wound healing. In the



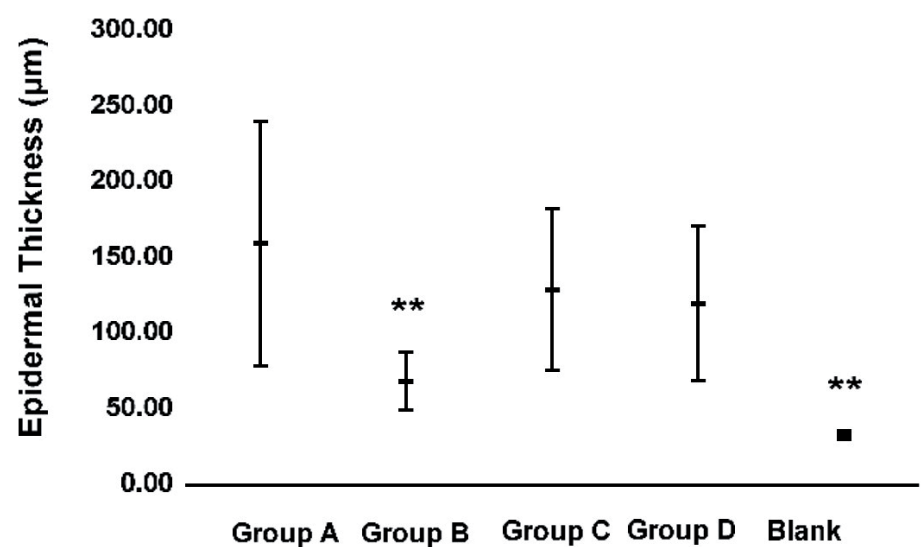
**Figure 3.**  
*Ten days' observation result at the edge of the wound. The performance of wound healing appearance at 10th day, the granulation tissue had grown to fill the entire wound, forming a bright red and smooth appearance, and the neonatal epithelial tissue could be observed at the edge of the wound.*



**Figure 4.**  
*Wound healing ratio.*



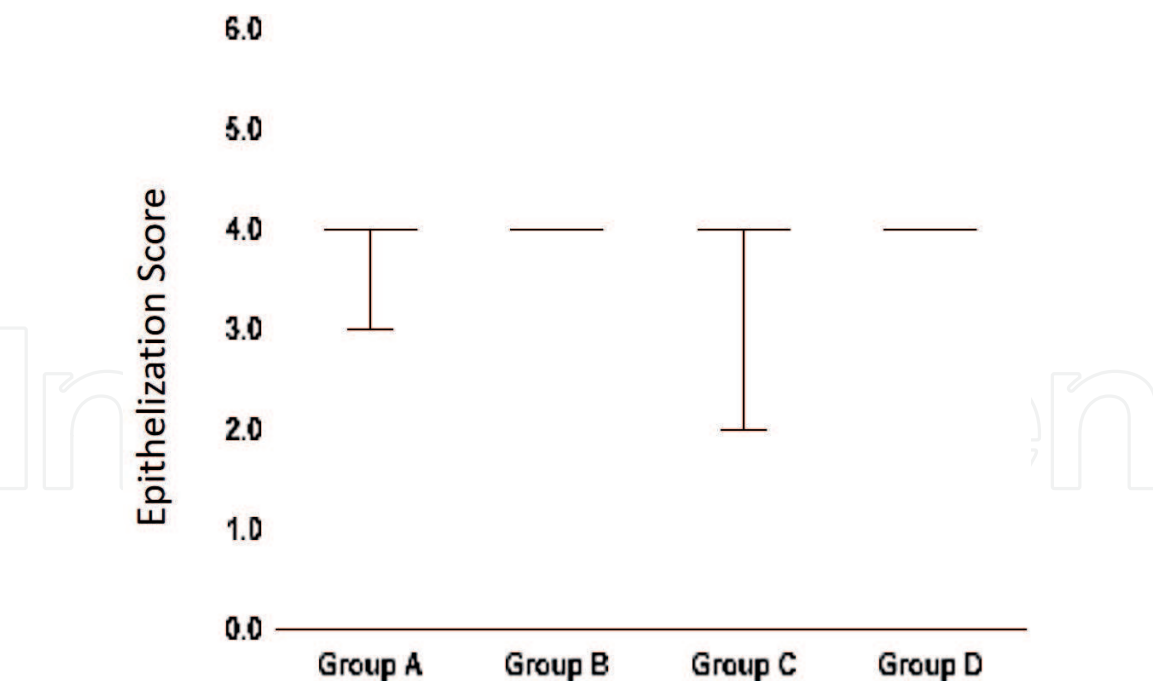
**Figure 5.**  
The thickness of the skin dermal layer of the animals in each test group.



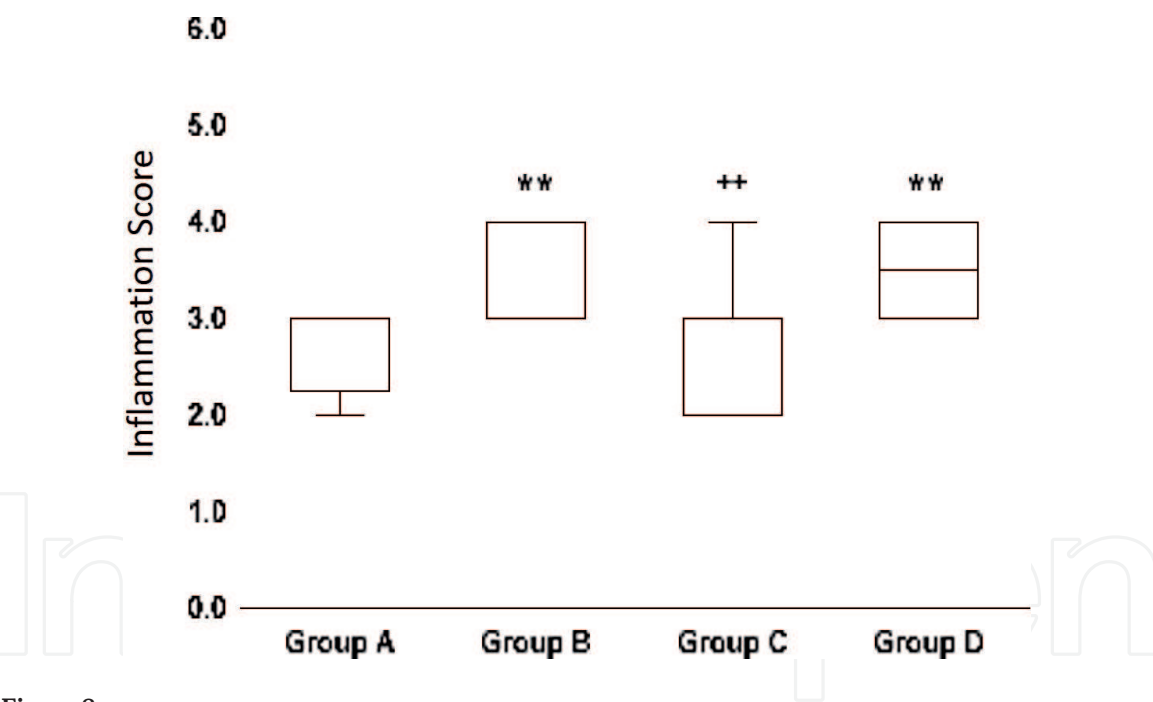
**Figure 6.**  
The thickness of the epidermal layer of the animals in each test group.

diabetic pig model, the thickness of the skin dermal layer of the animals in each test group was not different from each other (**Figure 5**). The analysis of the thickness of the epidermal layer showed that the thickness of the test group A is significantly higher than that of mushroom  $\beta$ -glucan (MBG) sponge dressing (test group B) ( $p < 0.01$ ) (**Figure 6**). Epidermal cell layer tissue formation (epithelization) showed that the wound healing of each group of animals in the diabetic pig model was good, and there was no statistical difference between the test groups in the evaluation of epithelial cell formation response (**Figure 7**).

The results of wound healing tissue react evaluation showed that the inflammatory reaction of animal skin in test group B and test group D was significantly higher than that in control group (test group A) with statistical difference ( $p < 0.01$ ). In addition, the degree of inflammatory response stimulation in test group C was significantly slowed down compared with the positive control group (test group D), indicating that test group B and test group D stimulated local skin inflammation and



**Figure 7.**  
*The evaluation of epithelial cell formation response of the animals in each test group.*

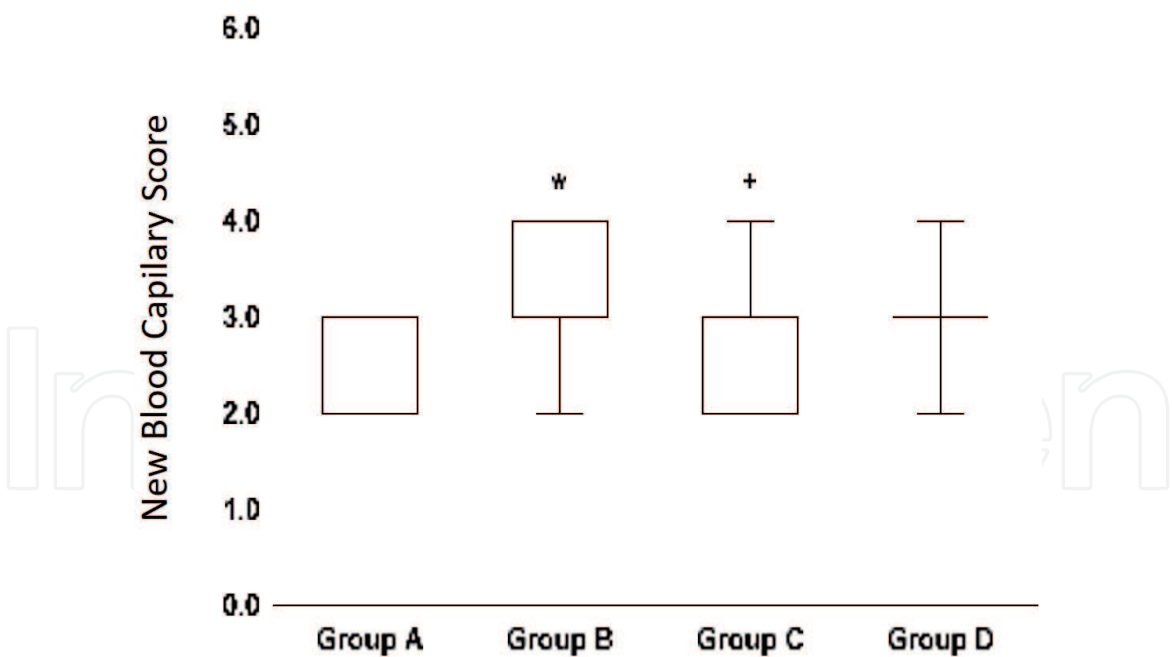


**Figure 8.**  
*The degree of inflammatory response stimulation of the animals in each test group.*

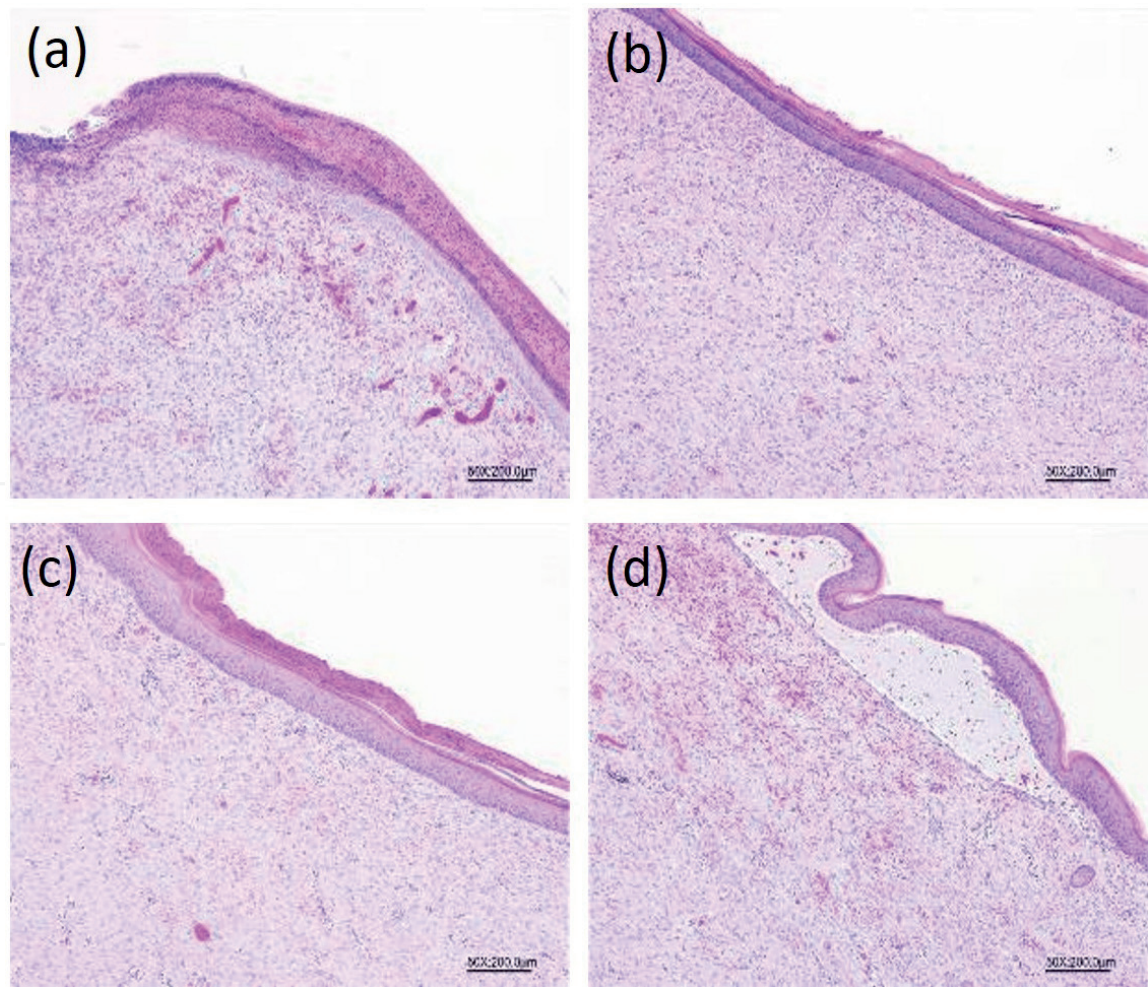
accelerated skin wound healing, but significantly slowed down in the experimental group C (**Figure 8**). After assay of the degree of skin blood capillary, the experimental group B (M1P1 0.5%) can be observed that the response is statistically different from the control group (test group A), showing that the new blood capillary of test substance is more effective than the control group (test group A) in wound healing (**Figure 9**). Moreover, section slices of recovered wound indicated that mushroom  $\beta$ -glucan (MBG) sponge dressing treatment revealed better wound tissue flatness effects than untreated group and positive control (**Figure 10(a)-(d)**).

In conclusion, based on the results of epidermal layer, dermal layer thickness and the local tissue reaction of wound healing, the mushroom  $\beta$ -glucan (MBG) sponge dressing M1P1 0.5% treatment group (test group B) is more effective in wound





**Figure 9.**  
The degree of skin new blood capillary in each test group.



**Figure 10.**  
Section slices of recovered wound in each test group. (a) Animal ID: 068-L1 H&E staining, 50×. Group A; (b) animal ID: 069-L3 H&E staining, 50×. Group B; (c) animal ID: 070-R1 H&E staining, 50×. Group C; (d) animal ID: 069-L2 H&E staining, 50×. Group D. Mushroom  $\beta$ -glucan (MBG) sponge dressing treatment (b and c) reveals better wound tissue flatness effects than untreated group and positive control.

healing than the test substance treatment group C (M1P1 1%) and the positive control group (test group D). When the mushroom  $\beta$ -glucan was applied on diabetic pigs wound, we expected the bioactive immunomodulation from mushroom  $\beta$ -glucan (MBG) occurred in chronic wound microenvironment, and promote wound healing.

### 3. Triterpenes from *Antrodia cinnamomea* in wound caring

#### 3.1 *Antrodia cinnamomea* triterpenes for wound caring

Since antiquity, mushrooms have been valued by humankind as a culinary wonder and folk medicine in Oriental practice. In recent years, mushrooms have emerged as a source of dietary supplements, antioxidants, anticancer, prebiotic, immunomodulating, anti-inflammatory, cardiovascular, antimicrobial, and antidiabetic functions [23]. Among the different types of mushrooms, *A. cinnamomea* is a special fungal parasite that grows on the inner cavity of the endemic species of *Cinnamomum kanehirae* (Bull camphor tree) in Taiwan [24]. This mushroom is considered as a highly valued mushroom due to its rare occurrence, cultivation difficulties of fruit bodies and its common uses as a traditional herb for the treatment of several ailments such as diarrhea, abdominal pain, hypertension, itchy skin, etc. [24, 25]. In Asia, *A. cinnamomea* dried mycelia powder is officially recognized as a rare dietary supplement. Given its popularity, in recent years, fermentation techniques have been employed in the mass production of *A. cinnamomea* and its products have been marketed as functional foods for over 10 years. Among the several bioactive or functional compounds such as polysaccharides, polysaccharides-peptides, nucleosides, and triterpenes that are reported to possess therapeutic effects from *A. cinnamomea*, bioactive *A. cinnamomea* triterpenes were reported with the activity to possess antitumor and immunomodulating activities with anti-inflammatory effects [8], and apoptotic effects in the leukemia HL-60 cells, which suggest that the triterpenes extract may possess protective antioxidants and anticancer properties for biophysiology [26].

Several plant derivatives, such as secondary metabolites, are capable of promoting wound healing in various animal models. A group of secondary metabolites attracting much attention is the pentacyclic triterpenes [27, 28]. Triterpenes, a large and structurally diverse group of natural products derived from squalene or related acyclic 30-carbon precursors, are uniquely abundant with well-characterized biological activities of modulation on the immune cells [29]. In surgical wounds, the triterpenes induced a reduction in time to closure, and this effect was reported in virtually all wound types. In references, triterpenes also modulate the production of ROS in the wound microenvironment, accelerating the process of tissue repair through inducing cell migration, cell proliferation, and collagen deposition [27].

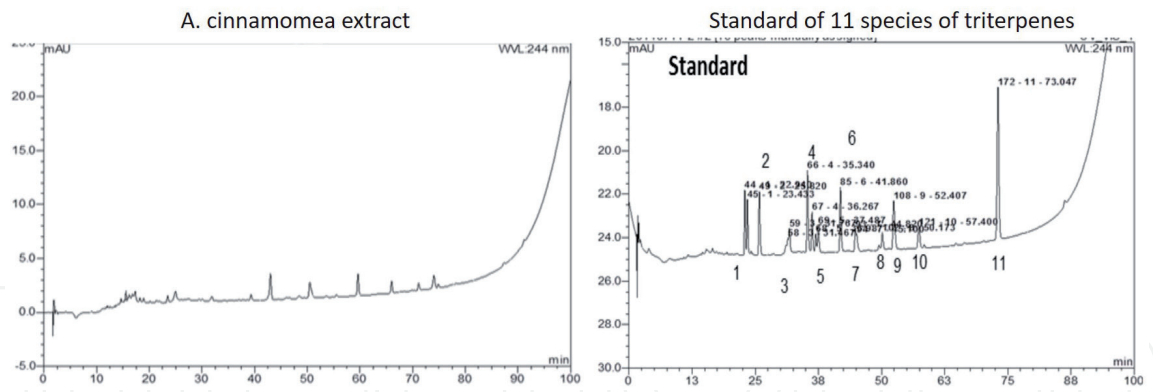
According to these findings and hypotheses, we used triterpenes extracted from *A. cinnamomea* mycelium to examine anti-inflammatory responses in STZ-induced hyperglycemic mice by oral treatment and observed the effect of triterpenes on wound healing model in the mice, and the complete results were published in paper in 2016 [30].

#### 3.2 *Antrodia cinnamomea* triterpenes promote wound healing in hyperglycemic diabetic mice model

The *A. cinnamomea* BCRC36401 was purchased from the Bioresources Collection and Research Center (BCRC), Food Industry Research and Development

Institute, Hsinchu, Taiwan. In laboratory culture system, the *A. cinnamomea* was subcultured into oats containing 5% glucose (16301, RDH) and 1% yeast extract (09182, SIGMA) within the vent plug-glass bottles at 22°C with 12 h of light for 30 days. After the mycelium was observed to overlap on the cultured oats, the mycelia were separated from fermented broth and washed with distilled water. Finally, the mycelia were freeze-dried to powders. The freeze-dried powder was initiated into the 80°C hot water for 6 h (powder:hot water = 1:100) to separate the water-soluble materials. After removal of water-soluble materials, the extraction of triterpenes was performed using 99.8% water-free ethanol (SIGMA) (the removed water-soluble powder:water-free ethanol = 1:50) in 1.5 h three times, and then lyophilized. The extracted compound was used in testing and analysis of triterpenes species by HPLC (**Figure 11**). The *A. cinnamomea* extract analyzed by HPLC was compared to the 11 species of triterpenes and the results was indicated that it was including of Antcin H, Dehydrosulphurenic acid, Eburicoic acid, Methyl antcinate B and Dehydroeburicoic acid (**Table 1**). The recovery rate was measured from different weight of the powder and the presented recovery rate about 7–10%.

Diabetes mouse skin wound healing examination was carried out following the wound healing model assay procedure [13, 31]. All study procedures were performed in accordance with protocol approved by the National Taiwan University Animal and Use Committee (NTUAUC). We used 15 of 6-week-old male ICR (N = 3, purchased from Laboratory Animal Center, National Taiwan University College of Medicine) for this experiment, and animals were housed in the Animal Housing Facility of National Taiwan University, College of Life Science. At the beginning, manual incision wound (one of 1.5 × 0.5 cm<sup>2</sup> full thickness) was made on mice skin. Each wound was cleaned by the 3 M Cavilon™ No Rinse-Skin



**Figure 11.** HPLC identification of *A. cinnamomea* extracted triterpenes. (Left) HPLC result of *A. cinnamomea* extract; (right) standard of the 11 species of triterpenes.

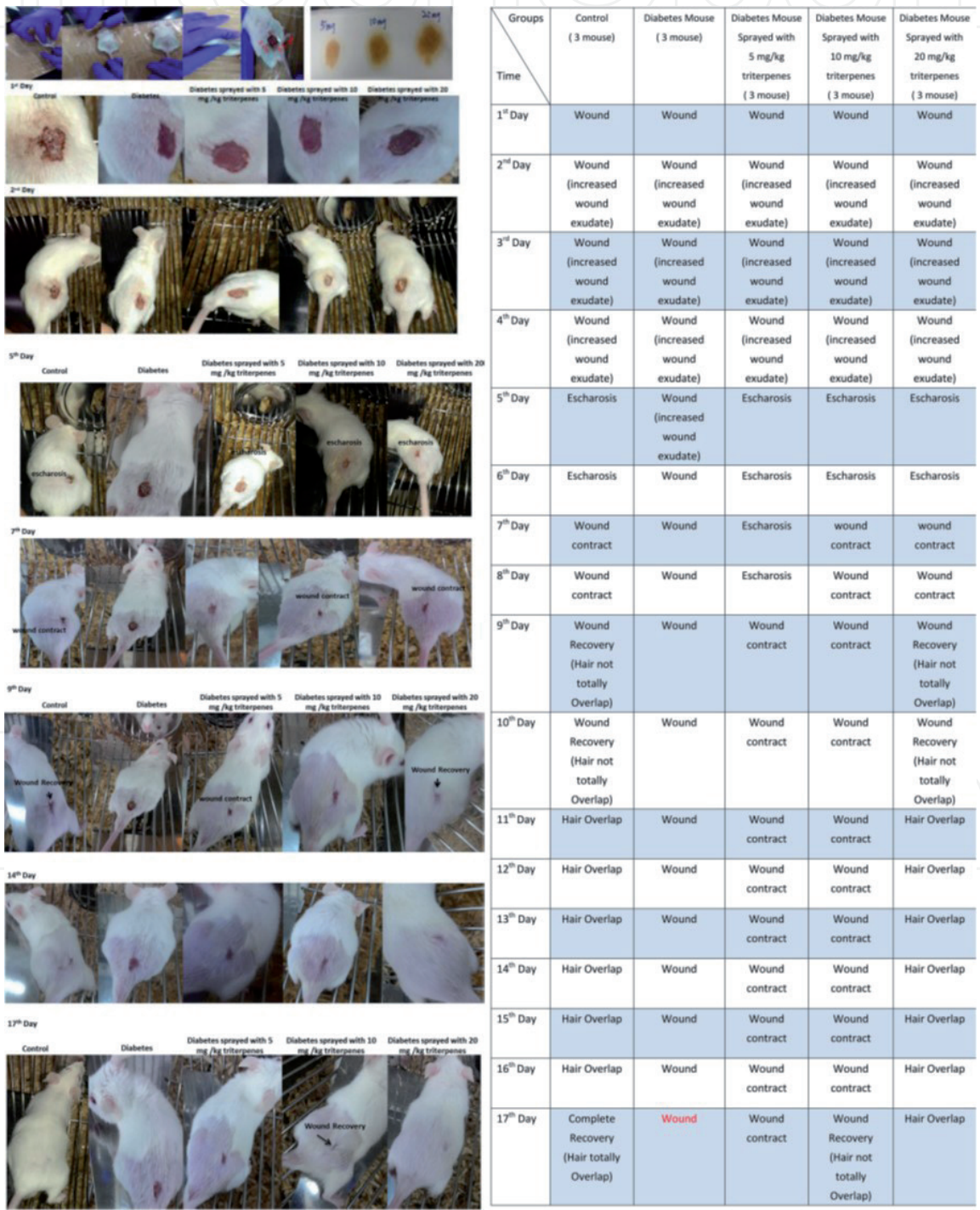
Retention time	Predicted triterpenes species	Height (mAU)	Area (mAU × min)
38.59	Antcin H	0.06	0.01
43.01	Dehydrosulphurenic acid,	2.41	0.95
50.50	Eburicoic acid	1.44	0.73
59.65	Methyl antcinate B	2.01	0.65
74.07	Dehydroeburicoic acid	1.22	0.53

**Table 1.** HPLC analyzed results of *A. cinnamomea* extract in comparison to the purified triterpene standard.



Cleanser and then sprayed with 3 M Cavilon™ No Sting Barrier Film solution with or without *A. cinnamomea* triterpenes.

Five experiment groups, including: 1. control mice, sprayed with 3 M Cavilon™ No Sting Barrier Film, 2. diabetic mice, sprayed with 3 M Cavilon™ No Sting Barrier Film, 3. diabetes mice, sprayed with 5 mg/kg triterpenes with 3 M Cavilon™ No Sting Barrier Film, 4. diabetic mice sprayed with 10 mg/kg triterpenes with 3M Cavilon™ No Sting Barrier Film, and 5. diabetic mice sprayed with 20 mg/kg triterpenes with 3M Cavilon™ No Sting Barrier Film. The wound recovery assay was observed by area change of wound healing appearance. The surgical wound area observation of the five groups was as shown in **Figure 12** (on the left).

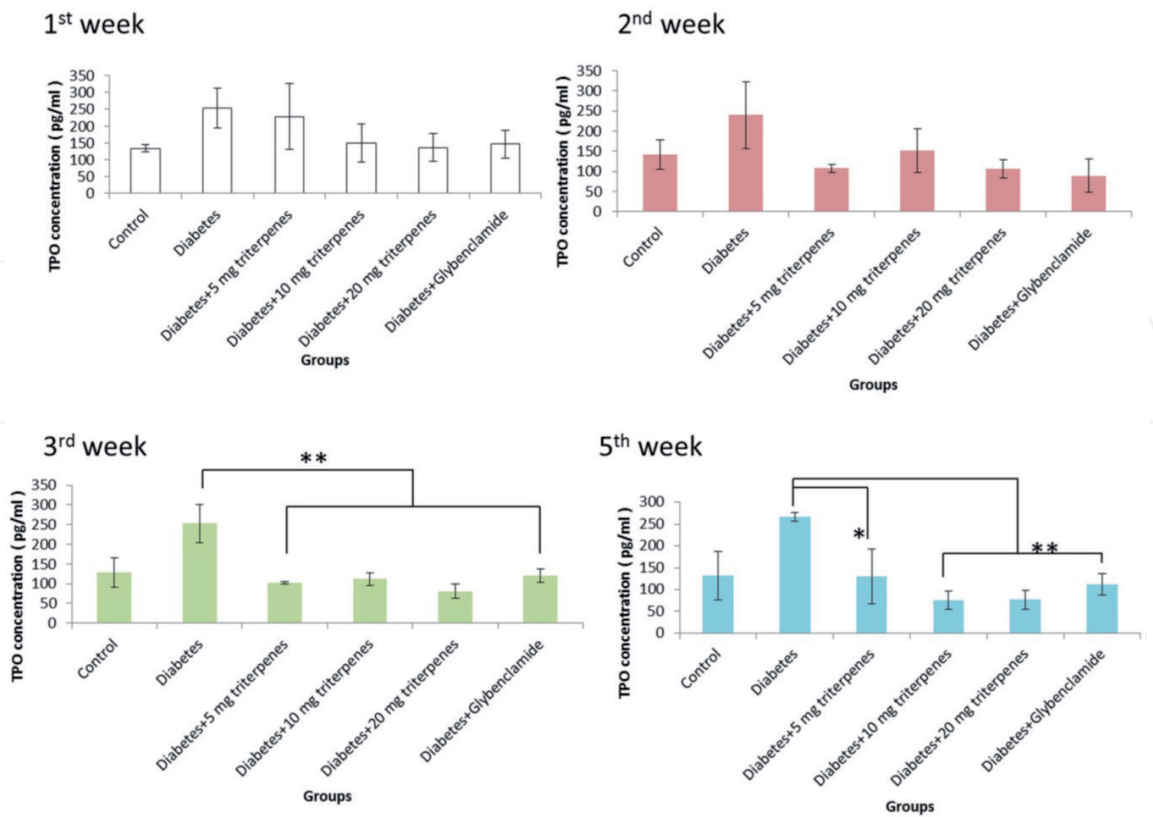


**Figure 12.** Long-term observation of the wound healing process. (Left) The performance of wound healing appearance on mice; (Right) recovery effectiveness compared to the diabetes group.



The presented result as shown in the control group (without diabetes), respectively, comparing with the diabetes mice, sprayed with 5, 10, and 20 mg/kg triterpenes is significantly different in the Days 1–17 after the surgery. In the observation of Day 1 to the Day 5, the presented data has shown that the recovery of the wounded area is markedly in the control and sprayed with 20 mg/kg triterpenes group but not in the diabetes and other treatment groups. In the control group, the recovery process is significantly observed in the Day 5 followed the surgery but the diabetes group has not shown the wound recovery situation in the Day 5. In the Day 7 observation, the wound was initiated to be contacted in the control and 20 mg/kg triterpenes group, other treatment groups were not significant presented with recovery especially the diabetes group. The long-term observation of the wound healing process can be found that the control group completely healing in the Day 17. The 20 mg/kg triterpenes group was not completely wound healing (criteria was presented as hair totally overlapped on the wound) however, the wound exactly has been gradually recovery compared to the diabetes group **Figure 12** (right).

In this study, serum biological analysis was also carried out in the five groups. After administration of different concentrations of *A. cinnamomea* triterpenes orally, concentrations of serum thrombopoietin (TPO) and CCL1 were measured by ELISA. The result showed that diabetes caused an increase in circulating thrombopoietin (TPO), but it was found that daily oral administration with various concentrations of triterpenes was exactly able to reduce the concentration of serum TPO. TPO concentration reduced especially in the oral administration with 10 mg/bw-kg, 20 mg/bw-kg groups and positive control compared to the diabetes group from the 3rd week to the end of investigation ( $p < 0.01$ ) (**Figure 13**). Although, the effect of triterpenes on the reducing CCL1 expression

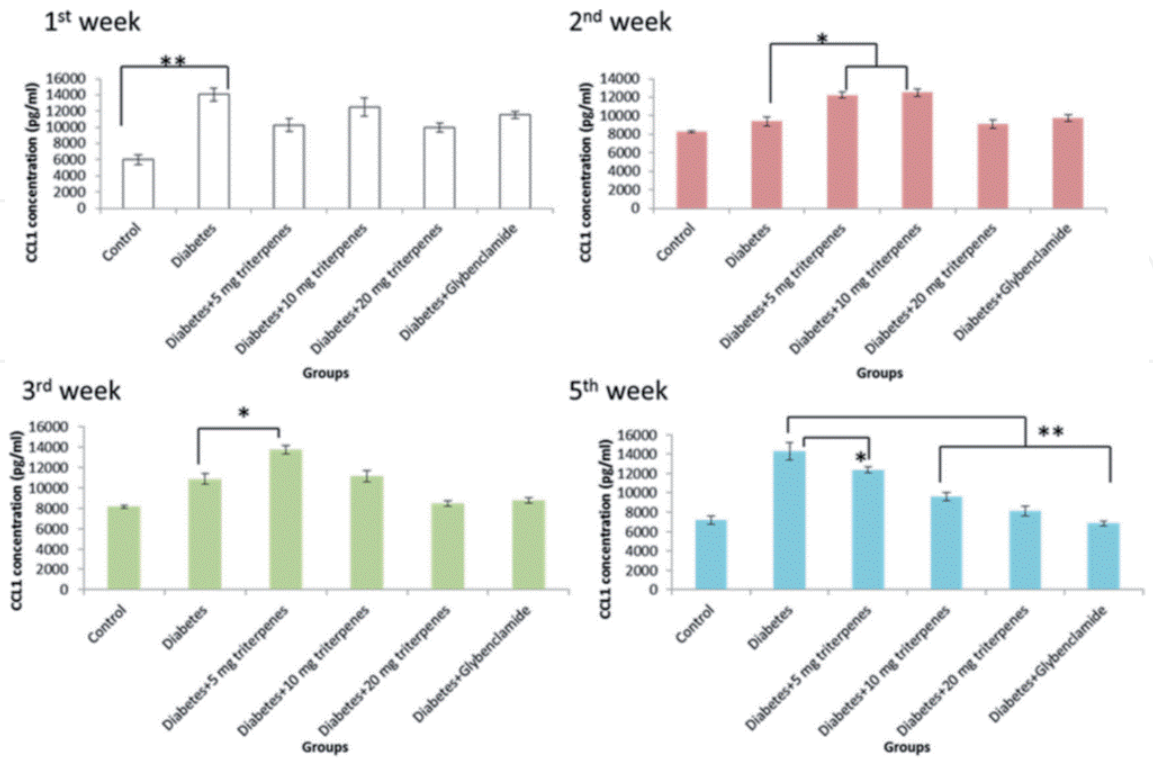


**Figure 13.** Serum circulating thrombopoietin (TPO) after administration of different concentrations of *A. cinnamomea* triterpenes orally in diabetic mice.

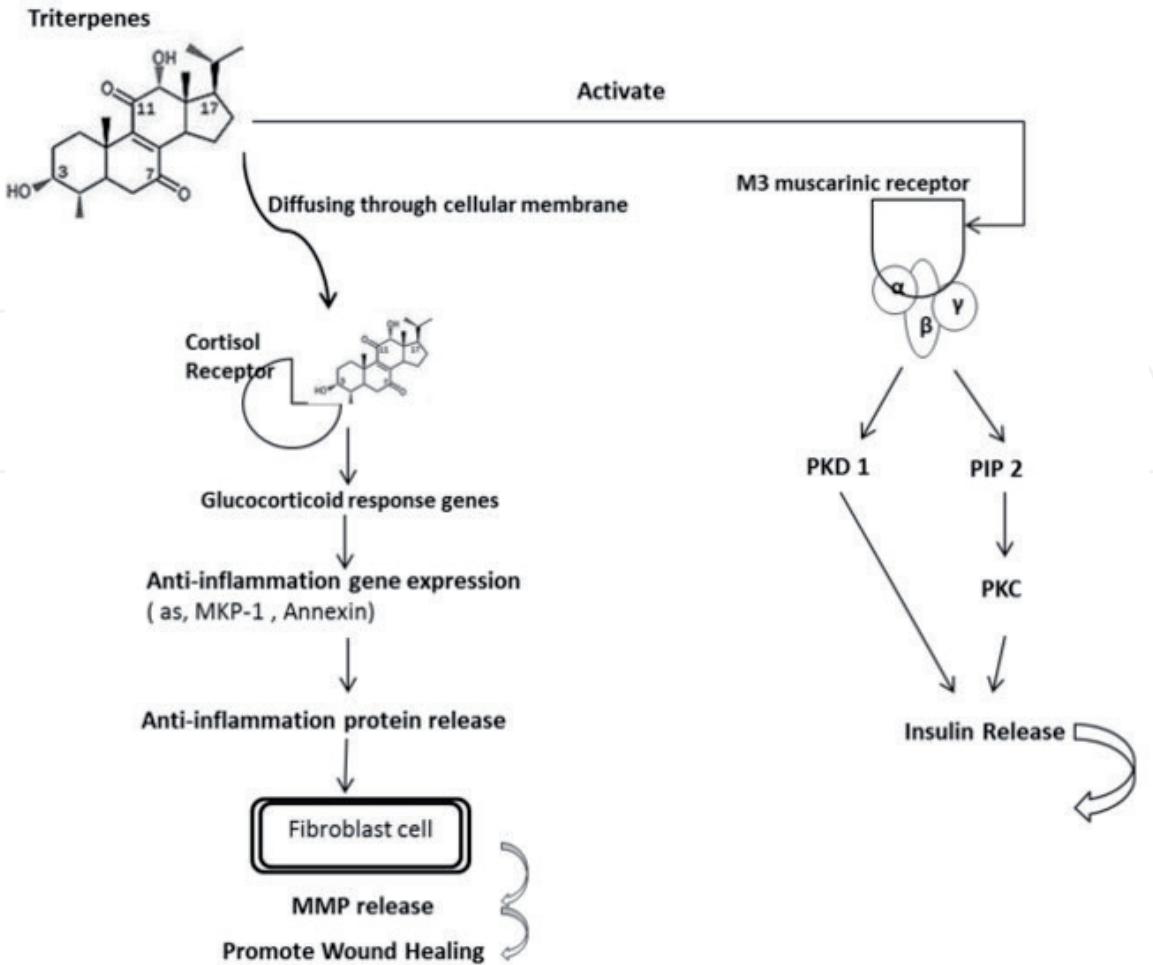
was not significant in early observations, on continuous oral administration with various concentrations of triterpenes (10 mg/bw-kg, 20 mg/bw-kg and positive control), this effect was shown to reduce the serum CCL1 concentration in the 5th week ( $p < 0.01$ ) (**Figure 14**).

As the result, the diabetic mice with skin wound examination, the detection of inflammatory factors such as CCL1 and TPO expression were found to induce than control mice, the hyperglycemia does cause an inflammatory response. Moreover, to the best of our knowledge, hyperglycemia impairs the tissue healing associated with an increased and prolonged inflammatory response. An investigation of the anti-inflammatory response in wound healing as affected by the triterpenes verified the promotion of wound recovery.

As the microenvironment of inflammation related to cellular transdifferentiation, migration, proliferation, survival, and extracellular matrix formation. And many factors are clearly involved in maintaining the balance between appropriate fibroblast activation and the fibrosis resulting from their continued activation for wound healing. We suggest the mechanism that the extracted triterpenes may bind to the glucocorticoid responsive elements (GREs) of target genes to regulate gene expression by mechanisms such as suppressing the expression of proinflammatory proteins and enhancing the expression of anti-inflammatory proteins. Furthermore, oleanolic acid is a triterpene that can increase insulin secretion by activating muscarinic M3 receptors in pancreatic  $\beta$ -cells through the Ach released from cholinergic nerve terminals. According to these findings, we suggest that the extracted triterpenes from *A. cinnamomea* may directly permeate the cell to bind with the GRE or indirectly combine with the M3 receptor, resulting in an anti-inflammatory effect and thereby promoting wound healing in the diabetic mice (**Figure 15**).



**Figure 14.**  
Serum CCL1 after administration of different concentration *A. cinnamomea* triterpenes orally in diabetic mice.



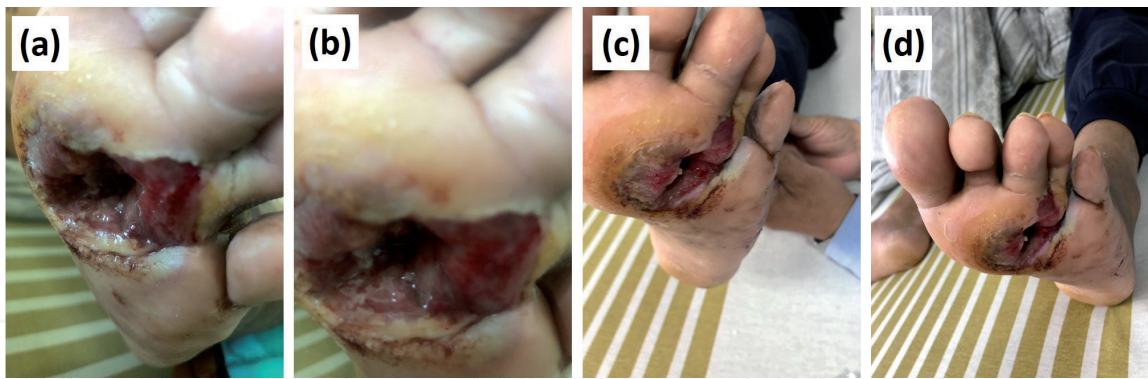
**Figure 15.**  
The proposed mechanism of triterpenes is involved in the diabetic mice with anti-inflammation. Figure description: The mechanism of triterpenes was speculated as binding to the glucocorticoid responsive elements (GREs) of target genes to regulate gene expression such as by suppressing the expression of proinflammatory proteins and enhancing the expression of anti-inflammatory proteins. Furthermore, oleanolic acid is a triterpene that can increase insulin secretion by activating muscarinic M3 receptors in pancreatic  $\beta$ -cells through the Ach released from cholinergic nerve terminals. According to these findings, we suggest that the extracted triterpenes could directly permeate the cell to bind with the GRE or indirectly combine with the M3 receptor, resulting in an anti-inflammatory effect and thereby inducing wound healing in the diabetic mice.

#### 4. A case study of the wound dressing containing mushroom $\beta$ -glucan (MBG) in a type II diabetes mellitus (T2DM) patient with peripheral neuropathy

Frequent and uncontrolled hyperglycemic state from type II diabetes mellitus (T2DM) can result in peripheral neuropathy in later stages of the disease. Patients who suffer from peripheral neuropathy will often suffer from a diabetic foot that results directly from peripheral arterial disease (PAD) and/or sensory neuropathy. It is a chronic complication of T2DM. If control measures such as infections and blood glucose controls are not properly implemented, a diabetic foot can often lead to ulcers or gangrene, which eventually result in amputations.

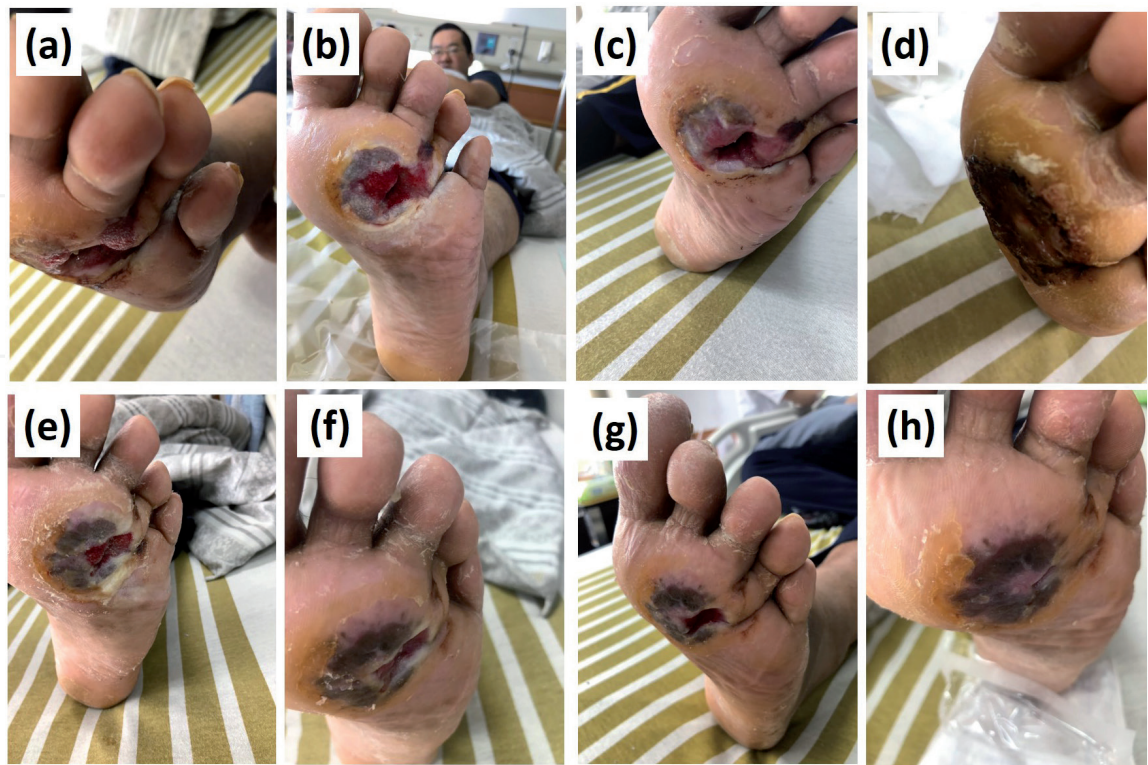
In 2018, a patient who suffered from T2DM volunteered to be included in this case study. During the study, as shown in **Figure 16a** and **b**, the patient suffered from advanced stage of PAD, which resulted in ulcers and gangrenes on the foot's lateral and anterior sides. While the patient followed the primary physician's instructions for lifestyle alteration, routine blood glucose management as well as performing a graft surgery for the affected area, under the physician's discretion,





**Figure 16.**  
The severe ulcers on diabetic patient's feet and treated with  $\beta$ -glucan (MBG) and triterpenes. (a, b) Gangrene resulted from peripheral arterial disease and infections. (c, d) After the test article containing *G. lucidum* (Reishi)  $\beta$ -glucan (MBG) and triterpenes purified from *A. cinnamomea* applied on affected area for 2 weeks.

a topical test article containing  $\beta$ -glucan isolated from *Ganoderma lucidum* (MBG) and triterpenes purified from *A. cinnamomea* was applied to the affected site three times a day (TID) as a palliative treatment to stimulate wound healing. The healing progress was recorded weekly and photographs were taken. As results show, 2 weeks after the test treatment was applied, the wounds showed a significant improvement (**Figure 16c** and **d**). From week 3 to week 10, the wounds showed even more significant improvements and the affected regions were significantly reduced (**Figure 17**). The preliminary results have demonstrated the efficacy of a powerful combination of the beta glucan and triterpenes to promote topical wound healing, that can inspire further scientific researches and applications of such in the future.



**Figure 17.**  
A progress for diabetic patient's feet wound healing. (a–h) The healing progress of gangrenes on a T2DM patient's feet, treated by test article containing *G. lucidum* (Reishi)  $\beta$ -glucan (MBG) and triterpenes purified from *A. cinnamomea*.



## Acknowledgements

The authors thank the technical services provided by the ATRI Animal Technology Laboratories to carry out wound repairing efficacy experiments on large mammals (ordinary or diabetic pigs) and the Council of Agriculture, Taiwan for funding support.

## Conflict of interest

The authors declare no conflict of interest.

## Author details

Shiu-Nan Chen<sup>1</sup>, Yu-Sheng Wu<sup>2</sup>, Sherwin Chen<sup>1</sup>, Ya-Chin Chang<sup>1</sup> and Chung-Lun Lu<sup>3\*</sup>

1 College of Life Science, National Taiwan University, Taipei, Taiwan ROC

2 Department of Aquaculture, National Pingtung University of Science and Technology, Neipu, Pingtung, Taiwan ROC

3 Aquatic Technology Laboratories, Agricultural Technology Research Institute, Hsinchu, Taiwan ROC

\*Address all correspondence to: hydrocoles@msn.com

## IntechOpen

© 2020 The Author(s). Licensee IntechOpen. This chapter is distributed under the terms of the Creative Commons Attribution License (<http://creativecommons.org/licenses/by/3.0>), which permits unrestricted use, distribution, and reproduction in any medium, provided the original work is properly cited. 

## References

- [1] Diabetes Mellitus. Diagnosis and classification of diabetes mellitus. *Diabetes Care*. 2005;**28**:37
- [2] Dinh T, Elder S, Veves A. Delayed wound healing in diabetes: Considering future treatments. *Diabetes Management*. 2011;**1**:509-519
- [3] Kuller LH. Nutrition, lipids, and cardiovascular disease. *Nutrition Reviews*. 2006;**64**:15-26
- [4] McCowen KC, Malhotra A, Bistrian BR. Stress-induced hyperglycemia. *Critical Care Clinics*. 2001;**17**:107-124
- [5] Nosenko MA, Ambaryan SG, Drutskaya MS. Proinflammatory cytokines and skin wound healing in mice. *Molekuliarnaia Biologiya*. 2019;**53**:741-754
- [6] Nosenko MA, Atretkhany KN, Mokhonov VV, Vasilenko EA, Kruglov AA, Tillib SV, et al. Modulation of bioavailability of proinflammatory cytokines produced by myeloid cells. *Seminars in Arthritis and Rheumatism*. 2019;**49**:39-42
- [7] Greenhalgh DG. Tissue repair in models of diabetes mellitus. A review. *Methods in Molecular Medicine*. 2003;**78**:181-189
- [8] Cheng JJ, Huang NK, Chang TT, Wang DL, Lu MK. Study for anti-angiogenic activities of polysaccharides isolated from *Antrodia cinnamomea* in endothelial cells. *Life Sciences*. 2005;**76**:3029-3042
- [9] Sen G, Khan AQ, Chen Q, Snapper CM. In vivo humoral immune responses to isolated pneumococcal polysaccharides are dependent on the presence of associated TLR ligands. *Journal of Immunology*. 2005;**175**:3084-3091
- [10] Murphy EA, Davis JM, Carmichael MD. Immune modulating effects of beta-glucan. *Current Opinion in Clinical Nutrition and Metabolic Care*. 2010;**13**:656-661
- [11] Lieu CW, Lee SS, Wang SY. The effect of *Ganoderma lucidum* on induction of differentiation in leukemic U937 cells. *Anticancer Research*. 1992;**12**:1211-1215
- [12] Woo YI, Park BJ, Kim HL, Lee MH, Kim J, Yang YI, et al. The biological activities of (1,3)-(1,6)-beta-d-glucan and porous electrospun PLGA membranes containing beta-glucan in human dermal fibroblasts and adipose tissue-derived stem cells. *Biomedical Materials*. 2010;**5**. DOI: 10.1088/1748-6041/5/4/044109
- [13] Hsiao CM, Wu YS, Nan FH, Huang SL, Chen L, Chen SN. Immunomodulator 'mushroom beta glucan' induces Wnt/beta catenin signalling and improves wound recovery in tilapia and rat skin: A histopathological study. *International Wound Journal*. 2016;**13**:1116-1128
- [14] Smiderle FR, Baggio CH, Borato DG, Santana-Filho AP, Sassaki GL, Iacomini M, et al. Anti-inflammatory properties of the medicinal mushroom *Cordyceps militaris* might be related to its linear (1 $\rightarrow$ 3)-beta-D-glucan. *PLoS One*. 2014;**9**. DOI: 10.1371/journal.pone.0110266
- [15] Suzuki Hashimoto IK, Ohno N, Tanaka H, Yadomae T. Immunomodulation by orally administered beta-glucan in mice. *International Journal of Immunopharmacology*. 1989;**11**:761-769
- [16] Minutti CM, Knipper JA, Allen JE, Zaiss DM. Tissue-specific contribution of macrophages to wound healing. *Seminars in Cell & Developmental Biology*. 2017;**61**:3-11

- [17] Portera CA, Love EJ, Memore L, Zhang L, Muller A, Browder W, et al. Effect of macrophage stimulation on collagen biosynthesis in the healing wound. *The American Surgeon*. 1997;**63**:125-131
- [18] Kougias P, Wei D, Rice PJ, Ensley HE, Kalbfleisch J, Williams DL, et al. Normal human fibroblasts express pattern recognition receptors for fungal (1→3)-beta-D-glucans. *Infection and Immunity*. 2001;**69**:3933-3938
- [19] Lowe EP, Wei D, Rice PJ, Li Kalbfleisch CJ, Browder IW, Williams DL. Human vascular endothelial cells express pattern recognition receptors for fungal glucans which stimulates nuclear factor kappaB activation and interleukin 8 production. Winner of the Best Paper Award from the Gold Medal Forum. *The American Surgeon*. 2002;**68**:508-517
- [20] Lee SB, Jeon HW, Lee YW, Lee YM, Song KW, Park MH, et al. Bio-artificial skin composed of gelatin and (1→3), (1→6)-beta-glucan. *Biomaterials*. 2003;**24**:2503-2511
- [21] Czop JK, Valiante NM, Janusz MJ. Phagocytosis of particulate activators of the human alternative complement pathway through monocyte beta-glucan receptors. *Progress in Clinical and Biological Research*. 1987;**297**:287-296
- [22] Delatte SJ, Evans J, Hebra A, Adamson W, Othersen HB, Tagge EP. Effectiveness of beta-glucan collagen for treatment of partial-thickness burns in children. *Journal of Pediatric Surgery*. 2011;**36**:113-118
- [23] Patel S, Goyal A. Recent developments in mushrooms as anti-cancer therapeutics: A review. *3 Biotech*. 2012;**2**:1-15
- [24] Chen TI, Chen CC, Lin TW, Tsai YT, Nam MK. A 90-day subchronic toxicological assessment of *Antrodia cinnamomea* in Sprague-Dawley rats. *Food and Chemical Toxicology*. 2011;**49**:429-433
- [25] Geethangili M, Tzeng YM. Review of pharmacological effects of *Antrodia camphorata* and its bioactive compounds, Evidence-based complementary and alternative medicine. *eCAM*. 2011. DOI: 10.1093/ecam/nep108
- [26] Hsu JH, Wu YC, Liu IM, Cheng JT. Release of acetylcholine to raise insulin secretion in Wistar rats by oleanolic acid, one of the active principles contained in *Cornus officinalis*. *Neuroscience Letters*. 2006;**404**:112-116
- [27] Agra LC, Ferro JN, Barbosa FT, Barreto E. Triterpenes with healing activity: A systematic review. *The Journal of Dermatological Treatment*. 2015;**26**:465-470
- [28] Byun-McKay A, Godard KA, Toudefallah M, Martin DM, Alfaro R, King J, et al. Wound-induced terpene synthase gene expression in Sitka spruce that exhibit resistance or susceptibility to attack by the white pine weevil. *Plant Physiology*. 2006;**140**:1009-1021
- [29] Minns LA, Buzoni-Gatel D, Ely KH, Rachinel N, Luangsay S, Kasper LH. A novel triterpenoid induces transforming growth factor beta production by intraepithelial lymphocytes to prevent ileitis. *Gastroenterology*. 2004;**127**:119-126
- [30] Wu YS, Chen SN. Extracted triterpenes from *Antrodia cinnamomea* reduce the inflammation to promote the wound healing via the STZ inducing Hyperglycemia-diabetes mice model. *Frontiers in Pharmacology*. 2016;**7**. DOI: 10.3389/fphar.2016.00154
- [31] Peter G, Kilk R, Mokry M, Vidinsky B, Vasilenko T, Mozes S, et al. Simple method of open skin wound healing model in corticosteroid-treated and diabetic rats: Standardization of semi-quantitative and quantitative histological assessments. *Veterinarni Medicina*. 2008;**53**:652-659