

We are IntechOpen, the world's leading publisher of Open Access books Built by scientists, for scientists

6,900

Open access books available

186,000

International authors and editors

200M

Downloads

Our authors are among the

154

Countries delivered to

TOP 1%

most cited scientists

12.2%

Contributors from top 500 universities



WEB OF SCIENCE™

Selection of our books indexed in the Book Citation Index
in Web of Science™ Core Collection (BKCI)

Interested in publishing with us?
Contact book.department@intechopen.com

Numbers displayed above are based on latest data collected.
For more information visit www.intechopen.com



A Review of Maxillofacial Rehabilitation Using Osseointegrated Implants in Oncological Patients: Buttress Implant Concept

*Leandro Díez-Suárez, Vicente González-Cardín,
Antonio Gómez-Pedraza and Martín Granados-García*

Abstract

Cancer leaves important consequences in the shape, function and esthetics of the patient, especially when it is cancer of the oral cavity or upper aero-digestive tract. Although reconstruction with local and microvascular flaps is sometimes a viable option, maxillofacial rehabilitation with osseointegrated implants is a well-reported treatment alternative with a high success rate. The main advantages in this modality of rehabilitation are the decrease in biological and economic costs, simplifying the management of these defects by reducing surgical intervention, hospitalization time, postoperative morbidity and treatment time. There are several classification systems; however, there is no classification system that has accurately described the maxillofacial defect under a surgical, prosthetic and reconstructive approach with osseointegrated implants. The purpose of this study is to guide professionals in decision-making for maxillofacial rehabilitation using osseointegrated implants located in the anatomical buttresses of the maxillofacial region.

Keywords: dental implants, anatomical buttress, maxillectomy defects, maxillofacial rehabilitation, prosthodontic reconstruction

1. Introduction

In 2018, The Global Cancer Statistics reported just over 18 million new cases worldwide. Lip and oral cavity cancer is ranked 18th with 354,864 new cases (2.0%) and 177,384 deaths (1.9%). However, if we analyze the main cancers that affect the upper digestive tract (salivary glands, hypopharynx, oropharynx, nasopharynx, larynx, lip, and oral cavity), we obtain approximately 887,659 new cases (4.9%) of cancers that could leave important sequelae in the maxillofacial region [1].

Maxillectomy is defined as the partial or total surgical removal of the maxilla and was designed as a surgical treatment for tumors that affect the middle third of the face. During oncological ablative surgery complex maxillofacial defects result that involve the loss of anatomical structures such as dental elements, facial cavities, sense organs, bone tissue and facial soft tissue. Although reconstruction

with local and microvascular flaps is sometimes a viable alternative, maxillofacial rehabilitation with osseointegrated implants has been a well-reported treatment with a high success rate [2].

Various techniques and anatomical locations have been described in the facial region for the placement of osseointegrated implants and its reason is based on the bone buttress where a skeletal anchorage is possible to support the functional load of the implants. In general, maxillofacial rehabilitation with osseointegrated implants uses anchors in the zygomatic, pterygoid, nasomaxillary and alveolar zones [3–5].

2. Buttress implant concept and classification

Based on the anatomical zones of the bony buttresses of the facial middle third, we designed a classification system that allows determining the therapeutic options where the placement and functional loading of osseointegrated implants is feasible: zone I or alveolar, zone II or nasomaxillary, zone III or zygomatic, zone IV or pterygoid (**Figure 1**).

2.1 Zone I/maxillary alveolar buttress

2.1.1 Tilted and axially positioned implants

The use of endosseous osseointegrated implants was introduced to North America in 1982. At that conference, Branemark presented the data from 15 years of work, which was highly evidence-based with long-term clinical follow-up findings setting the guidelines for contemporary implantology [6].

Currently implantology has improved considerably; dental implants have incorporated advances in their anatomy, surface and types of connections, achieving a higher success rate and predictable results [7, 8].

Implants angled between 30 and 45° were described as an alternative surgical technique in order to avoid nearby anatomical structures or to achieve an adjacent bone position. Thus, we avoid advanced bone regeneration procedures and minimize the cantilever of prosthetic rehabilitation [9].

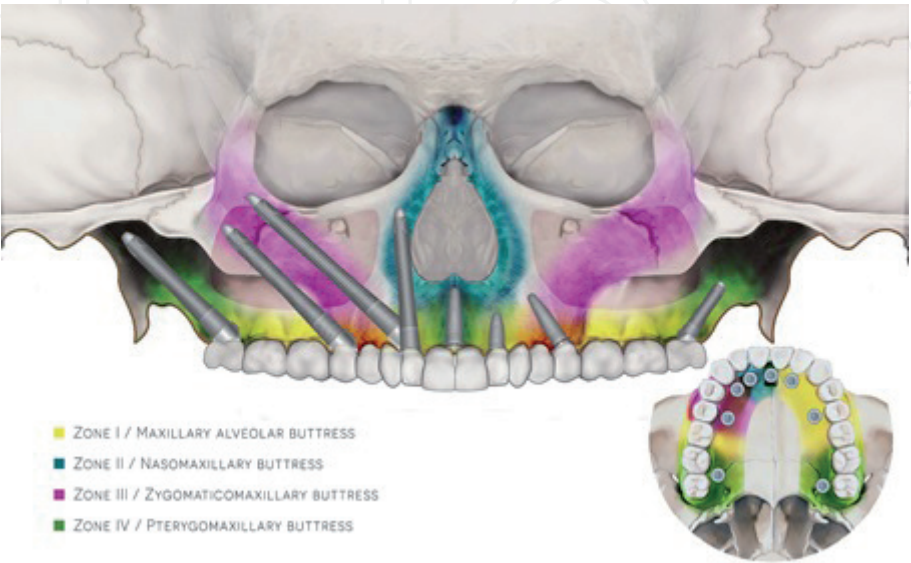


Figure 1.
Anatomical zones of the bony buttresses of the facial middle third and placement of osseointegrated implants with their positions in the prosthetic arch.

2.1.2 Nasopalatine implants

In 1994 Scher. describes the use of the nasopalatine canal as a receptor site for a dental implant, since then controlled studies have been carried out that confirm its viability for the functional load of osseointegrated implants [10].

Peñarrocha et al. treated 13 patients with 78 osseointegrated implants in the rehabilitation of the atrophic maxilla. Of 78 implants, 13 were implanted in the nasopalatine canal, 6 patients had reversible sensory alteration, and 2 implants failed in healthy patients, yielding a success rate of 84.6% [11].

Occasionally, when performing a partial maxillectomy, bone is available throughout the Maxillary alveolar buttress. In these cases, it is possible to use conventional dental implants anchored even in contralateral anatomical structures.

2.2 Zone II/nasomaxillary buttress

2.2.1 Nasomaxillary implants

Although the term “Nasomaxillary implant” has not been defined in the Glossary of Oral and Maxillofacial Implants (GOMI) [12]. We define it as “Implant placement through the alveolar process and into the nasomaxillary buttress”.

The nasomaxillary buttress has been well described in facial trauma as it is a key anatomic zone in the reconstruction of fractures of the middle third. This area offers a cortical bone suitable for the anchorage and functional load of osseointegrated implants. However, there are few implant-oriented anatomical studies and some are anthropometric studies [13–16].

Some authors have described the placement of posterior tilted implants between 30 and 45° that reach an apical anchorage in the nasomaxillary buttress [9, 17, 18]. However, this type of implant is not frankly a nasomaxillary implant because they are retained from an apical portion and are not strictly into the buttress as in the case of a long implant with an axial orientation.

Nasomaxillary implants can be used as an anchorage point in a location anterior to the prosthetic arch. With this, we achieve anterior stability and the reduction of work forces in posterior implants.

2.3 Zone III/zygomaticomaxillary buttress

2.3.1 Zygomatic implants

In 1998 Dr. P. I Branemark described zygomatic implants as a bone anchorage alternative with a design between 30 and 52.5 mm long that are inserted into the body of the malar bone [19]. Since then, Branemark and other authors have described various surgical techniques and approaches for zygomatic implant placement that could be used to rehabilitate atrophic jaws or in patients with partial or total maxillectomy [20–22].

Scott et al. rehabilitated 28 patients after undergoing rhinectomy for malignant pathological processes, a total of 56 zygomatic implants were used as retainers of maxillofacial prostheses, 1 failed after radiotherapy having a success rate of 98% in 15 years [4].

In general, most authors agree that zygomatic implants are more than 95% successful [23] and in radiated patients the success rate of implants is highly variable with a range between 72 and 98% [2].

Zygomatic implants offer adequate bone quality and quantity. Sometimes when the maxillectomy is extensive, it compromises the malar bone. Performing regenerative procedures with autografts or xenografts are a viable option to improve site conditions.

2.4 Zone IV/pterygomaxillary buttress

2.4.1 Pterygomaxillary implants

Tulasne and Tessier in 1989 were the first to describe the technique for the placement of pterygoid implants [24]. This technique wanted to resolve the difficulties caused by the presence of the maxillary sinus and the poor characteristics of the bone in the maxillary tuberosity.

Pterygoid implants are implants between 15 and 20 mm long that allow a bone anchorage of up to 9 mm in the pterygoid process [25]. However, in the maxilectomized patient this length may vary because the posterior segment of the maxilla is not found.

Araujo et al. in 2019 performed a systematic review from January 1995 to January 2018. A total of 634 patients received 1893 pterygoid implants, with a 10-year survival rate of 94.85%.

Pterygoid implants are a viable option and if their main advantage is to decrease the prosthetic distal cantilever [26].

3. Buttress implant concept: advantages and disadvantages

Maxillofacial reconstruction with osseointegrated implants placed in bony buttresses is indicated in patients who have suffered loss of mid-facial anatomical structures due to benign and malignant pathological processes, trauma, and severe maxillary atrophy.

There are few contraindications to the use of osseointegrated implants and they are mostly relative. Their reason is that they decrease the success rate compared to implantation in healthy patients. The most important contraindications suggest bone healing disorders such as bisphosphonate treatment, radiotherapy, chemotherapy and active infection. However, for each situation there are protocols that help maintain a high success rate and some of them are discussed in this chapter [20, 23, 27].

The main advantages in this type of rehabilitation are the decrease in the number of reconstructive surgeries, avoiding the use of donor sites and a shorter hospital stay. By performing a single-phase reconstruction, the patient recovers the phonation, swallowing and chewing lost due to the oncological defect. In addition, the patients present a timely and less morbid treatment compared to local and microvascular grafts. To achieve these results, prosthetically guided reconstruction is key [28].

4. Virtual prosthetic and surgical planning

Three-dimensional (3D) planning in oral and maxillofacial surgery has become a standard in the treatment of multiple conditions of the facial region. Multiple Programs have been designed to perform 3D virtual planning and surgery in the reconstruction with osseointegrated implants (DTX Studio Implant®, SIMPLANT®, DDS-pro®, 3Shape Dental System®). Most of them are equipped with numerous software complements that allow the preparation of surgical guides and prosthetic reconstructions with different attachments through CAD/CAM [29].

Some of the multiple advantages offered by 3D virtual surgery are: simulating different approaches and types of procedures, avoiding damage to neurovascular and anatomical structures, reducing operating time and improving postoperative recovery, reducing complications and obtaining more predictable results.

For preoperative evaluation and planning, a CT scan of the head and neck is the Gold standard [3, 23]. The planning of the placement of osseointegrated implants must be prosthetically guided. This means that planning must precede the surgical act of implant placement and these must be located where it best suits prosthetic rehabilitation and biomechanical demands. The objective should be a surgical and prosthetic planning with at least four osseointegrated implants with their distributed emergencies in a polygonal manner over the prosthetic arch. In this way, we were able to tripodize and stabilize the prosthetic reconstruction in the face of the functional demands of chewing (**Figure 2**) [28, 30].

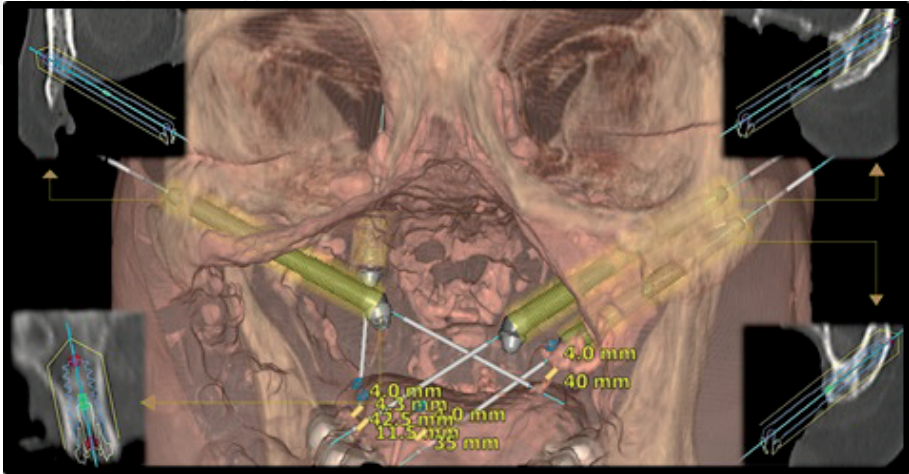


Figure 2.
3-dimensional computed prosthetic and surgical planning and bone availability in the peri-implant anatomical zone.

5. Simulated surgery in stereolithographic biomodels

Stereolithography is a solid three-dimensional prototype obtained through the processing of data obtained from computed tomography or magnetic resonance imaging. In recent years, stereolithographic manufacturing has made great strides in the quality, resolution, and precision of manufactured parts and is becoming increasingly important in medicine and surgery [31].

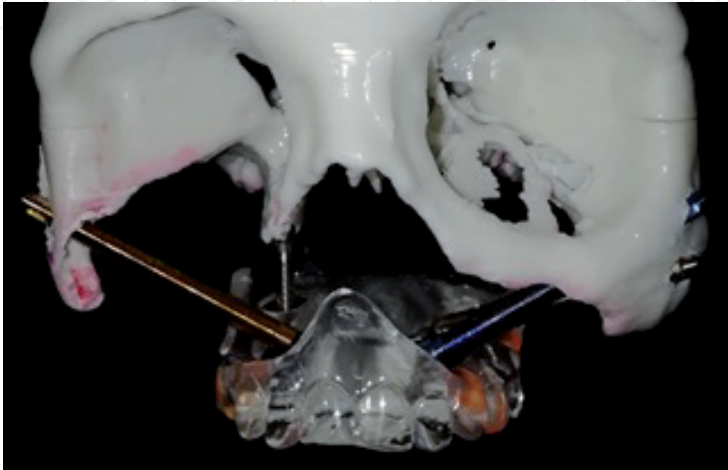


Figure 3.
Simulated surgery in stereolithographic biomodel. Zygomatic and Pterygomaxillary implants placed in the planned positions.

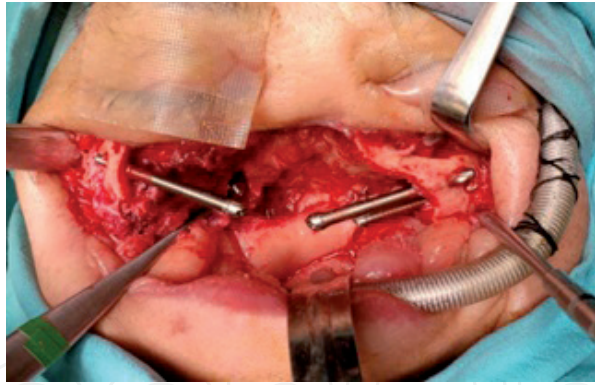


Figure 4.
Photograph of surgical field after placement of zygomatic and Pterygomaxillary implants.

Three-dimensional printing has been used to produce anatomical models, surgical guides and templates, implants, and molds. The main advantages include: the possibility of preoperative planning, the precision of the process used and the time saved in the operating room. However, other studies report inconsistency in precision and additional costs in treatment [32].

The maxillofacial reconstruction with osseointegrated implants simulated in a biomodel, allows to determine the lengths and final positions of the implants, prepare the surgeon for the surgical procedure and minimize the possibilities of errors favoring the results of the treatment (**Figures 3 and 4**).

6. Prosthetic and facial reconstruction

Oral and facial deformity can cause functional and psychological deterioration in oncological patients. The aims of prosthodontic reconstruction are the rehabilitation of the shape, function and esthetics of the lost anatomical structures by means of artificial substitutes. The main facial subunits that require reconstruction due to malignant pathological processes involve the ear, forehead, eyes and brow, nose, cheek, lips and chin [33].

Currently, there are multiple workflows where they combine conventional prosthetic preparation with the use of facial scanners and custom 3D impressions

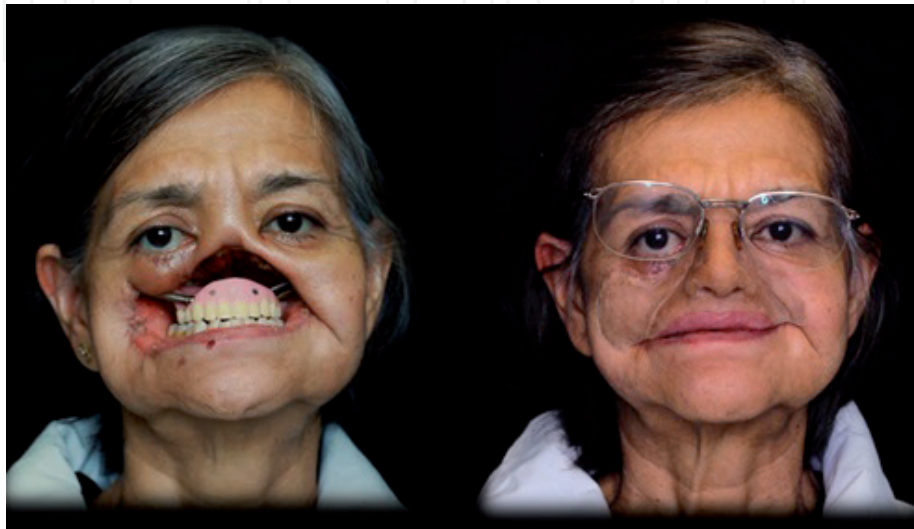

Figure 5.
Photograph showing implant-supported obturator placed and final photograph.

that allow the direct or indirect manufacture of definitive maxillofacial prostheses from conventional silicone [34, 35].

The main advantage with dental prosthodontic reconstruction is the adaptation of a retained implant obturator that allows a posterior palatal seal. With this, most patients successfully recover phonation, swallowing, and chewing function. Artificial facial prostheses allow us to better characterize the demanding anatomy of the face. In most cases, the retention of facial prostheses occurs when copying the anatomical defect, on other occasions magnetized attachments can be used in prosthetic reconstruction or protective glasses that also improve the characterization of the face (**Figure 5**).

7. Radiotherapy treatment and implants

In early clinical stages, surgery is the first decision. However, adjuvant radiotherapy is sometimes indicated in cases of close excision margins (<5 mm), involved (<1 mm), and in suspicion or confirmation of lymph node metastasis with or without extracapsular extension [36]. In general, radiation therapy includes conventional radiation therapy or intensity modulated radiation therapy (IMRT). The latter is more convenient by precisely targeting radiation to a specific area and reducing the dose to nearby anatomical structures such as malar bone, grafts, implants, salivary glands, eyes, and spinal cord [37].

Schiegnitz's study suggests that radiation negatively affects implant survival, but there is no statistically significant difference in survival when implants are inserted 12 months before or after radiation therapy [38]. Other authors have shown favorable results. With implantation at least 6 weeks before radiotherapy since there is a surgical area with less hypoxia, hypovascularity and hypocellularity [27, 39] (**Figure 6**).

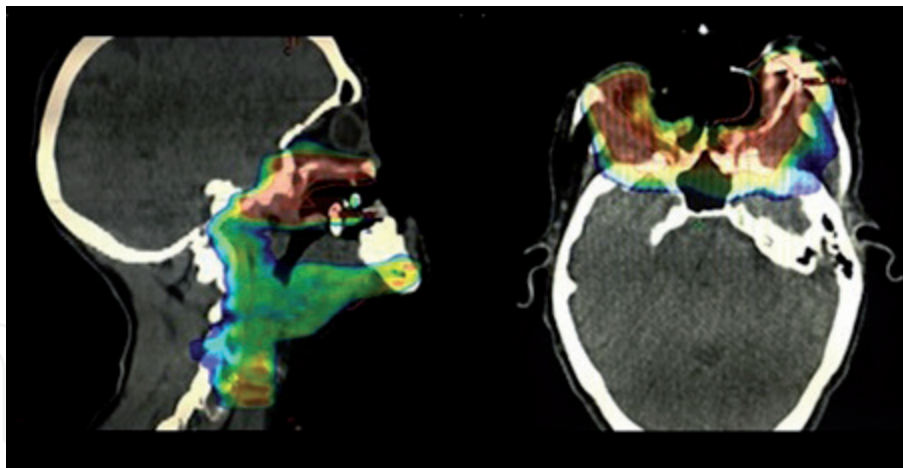


Figure 6.
Histogram showing trajectories, dose and volume used for adjuvant radiotherapy.

8. Chemotherapy treatment and implants

Systemic antineoplastic therapy includes induction, neoadjuvant, adjuvant, and palliative therapy [40]. The survival rate of osseointegrated implants in the patient with antineoplastic and antiangiogenic therapy has not yet been elucidated. Controlled animal studies have shown negative effects on the osseointegration process with chemotherapeutic regimens with cisplatin, bevacizumab and sunitinib [41–43]. However, retrospective studies in humans have reported that chemotherapy has no detrimental effects on the osseointegration and functional stability of dental implants. The success rates reported by these studies were 97.6 and 99.1% [44–46].

9. Conclusion

The placement of osseointegrated implants in anatomical buttresses of the upper jaw is a predictable treatment with a high success rate. By reconstructing the lost anatomical structures with artificial substitutes, a better characterization of the face is achieved and an important esthetic defect is covered with acceptable results.

The main advantages in this modality of reconstruction include the decrease in surgical times, hospital stay and postoperative morbidity. By rehabilitating phonation, swallowing and masticatory function, we improve the quality of life and social reintegration of the oncological patient.

Currently, technological advances point to the development in the design of customized implants; however, controlled studies are required to evaluate the use and behavior of these implants in the different scenarios presented by the oncological patient.

Acknowledgements

To the National Cancer Institute - Mexico City and the head and neck medical department for the comprehensive treatment of oncological patients. To Dr. Víctor Felipe Orduña López for the joint treatment.

Conflict of interest

There are no conflicts of interest to declare.

Ethical approval

Institutional approval was not required.

Author details

Leandro Díez-Suárez^{1,3*}, Vicente González-Cardín², Antonio Gómez-Pedraza³ and Martín Granados-García³

1 Oral and Maxillofacial Surgeon Department, National Autonomous University of Mexico UNAM, Mexico City, Mexico

2 Head and Neck Prosthodontist Department, National Cancer Institute, Mexico City, Mexico

3 Head and Neck Surgery Department, National Cancer Institute, Mexico City, Mexico

*Address all correspondence to: ledisuar@gmail.com

IntechOpen

© 2020 The Author(s). Licensee IntechOpen. This chapter is distributed under the terms of the Creative Commons Attribution License (<http://creativecommons.org/licenses/by/3.0>), which permits unrestricted use, distribution, and reproduction in any medium, provided the original work is properly cited. 

References

- [1] Bray F, Ferlay J, Soerjomataram I, Siegel RL, Torre LA, Jemal A. Global cancer statistics 2018: GLOBOCAN estimates of incidence and mortality worldwide for 36 cancers in 185 countries. *CA: A Cancer Journal for Clinicians*. 2018;**68**(6):394-424
- [2] Gómez-Pedraza A, González-Cardín V, Díez-Suárez L, Herrera-Villalva M. Maxillofacial rehabilitation with zygomatic implants in an oncologic patient: A case report. *Journal of Oral and Maxillofacial Surgery*. 2020;**78**(4):547-556. DOI: 10.1016/j.joms.2019.10.006
- [3] Pellegrino G, Tarsitano A, Basile F, Pizzigallo A, Marchetti C. Computer-aided rehabilitation of maxillary oncological defects using zygomatic implants: A defect-based classification. *Journal of Oral and Maxillofacial Surgery*. 2015;**73**(12):2446.e1-2446.e11. DOI: 10.1016/j.joms.2015.08.020
- [4] Scott N, Kittur MA, Evans PL, Dovgalski L, Hodder SC. The use of zygomatic implants for the retention of nasal prosthesis following rhinectomy: The Morriston experience. *International Journal of Oral & Maxillofacial Surgery*. 2016;**45**(8):1044-1048. DOI: 10.1016/j.ijom.2016.01.020
- [5] Vrielinck L, Politis C, Schepers S, Pauwels M, Naert I. Image-based planning and clinical validation of zygoma and pterygoid implant placement in patients with severe bone atrophy using customized drill guides. Preliminary results from a prospective clinical follow-up study. *International Journal of Oral and Maxillofacial Surgery*. 2003;**32**(1):7-14
- [6] Block MS. Dental implants: The last 100 years. *Journal of Oral and Maxillofacial Surgery*. 2018;**76**(1):11-26
- [7] Ogle OE. Implant surface material, design, and osseointegration. *Dental Clinics of North America*. 2015;**59**(2):505-520. DOI: 10.1016/j.cden.2014.12.003
- [8] Smeets R, Stadlinger B, Schwarz F, Beck-Broichsitter B, Jung O, Precht C, et al. Impact of dental implant surface modifications on osseointegration. *BioMed Research International*. 2016;**2016**:6285620. DOI: 10.1155/2016/6285620
- [9] Soto-Peñaloza D, Zaragoza-Alonso R, Peñarrocha-Diago M, Peñarrocha-Diago M. The all-on-four treatment concept: Systematic review. *Journal of Clinical and Experimental Dentistry*. 2017;**9**(3):e474-e488
- [10] Scher E. Use of the incisive canal as a recipient site for root form implants: Preliminary clinical reports. *Implant Dentistry*. 1994;**3**:38-41
- [11] Peñarrocha D, Candel E, Guirado JL, Canullo LPM. Implants placed in the nasopalatine canal to rehabilitate severely atrophic maxillae: A retrospective study with long follow-up. *The Journal of Oral Implantology*. 2014;**40**(6):699-706
- [12] Laney W. Oral and endorsing organizations. *The International Journal of Oral & Maxillofacial Implants*. 2017;**32**:Gi-G200
- [13] McCollum MA. Nasomaxillary remodeling and facial form in robust australopithecus: A reassessment. *Journal of Human Evolution*. 2008;**54**(1):2-14
- [14] Hwang TS, Song J, Yoon H, Cho BP, Kang HS. Morphometry of the nasal bones and piriform apertures in Koreans. *Annals of Anatomy*. 2005;**187**(4):411-414
- [15] Adnot J, Desbarats C, Joly LM, Trost O. Nasomaxillary fracture:

Retrospective review of 11 consecutive patients and literature review. *Journal of Stomatology, Oral and Maxillofacial Surgery*. 2019;**120**(6):534-539. DOI: 10.1016/j.jormas.2019.03.003

[16] Hsiao S, Cheng J, Tseng Y. ScienceDirect nasomaxillary and mandibular bone growth in primary school girls aged 7 to 12 years. *The Internet Journal of Dental Science*. 2020;**xxxx**:3-8. DOI: 10.1016/j.jds.2020.03.010

[17] Jensen OT. Dental extraction, immediate placement of dental implants, and immediate function. *Oral and Maxillofacial Surgery Clinics of North America*. 2015;**27**(2):273-282. DOI: 10.1016/j.coms.2015.01.008

[18] Jensen OT, Adams MW, Butura C, Galindo DF. Maxillary V-4: Four implant treatment for maxillary atrophy with dental implants fixed apically at the vomer-nasal crest, lateral pyriform rim, and zygoma for immediate function. Report on 44 patients followed from 1 to 3 years. *Journal of Prosthetic Dentistry*. 2015;**114**, 6:810-817. DOI: 10.1016/j.prosdent.2014.11.018

[19] Branemark P. *Surgery Fixture Installation: Zygomaticus Fixture Clinical Procedures*. 1st ed. Gotemburgo, Suecia: Nobel Bio- care, AB; 1998

[20] Salem AA, Shakel EA, Sadakha AA, Kassem EM, El-Segai AA. Evaluation of Zygomatic implant retained obturator in rehabilitation of partial palato-maxillectomy patients. *Tanta Dental Journal*. 2015;**12**(1):35-40. DOI: 10.1016/j.tdj.2014.10.003

[21] Rosenstein J, Dym H. Zygomatic implants: A solution for the atrophic maxilla. *Dental Clinics of North America*. 2020;**64**(2):401-409. DOI: 10.1016/j.cden.2019.12.005

[22] King E, Abbott C, Dovgalski L, Owens J. Orofacial rehabilitation with

zygomatic implants: CAD-CAM bar and magnets for patients with nasal cancer after rhinectomy and partial maxillectomy. *Journal of Prosthetic Dentistry*. 2017;**117**(6):806-810. DOI: 10.1016/j.prosdent.2016.09.029

[23] Aparicio C, Ouazzani W, Hatano N. The use of zygomatic implants for prosthetic rehabilitation of the severely resorbed maxilla. *Periodontology 2000*. 2000;**47**(1):162-171

[24] Tulasne JF. Implant treatment of missing posterior dentition. In: Albrektson T, Zarb G, editors. *The Branemark Osseointegrated Implant*. Chicago: Quintessence; 1989. p. 103-115

[25] Bidra AS, Huynh-Ba G. Implants in the pterygoid region: A systematic review of the literature. *International Journal of Oral and Maxillofacial Surgery*. 2011;**40**(8):773-781. DOI: 10.1016/j.ijom.2011.04.007

[26] Araujo RZ, Santiago Júnior JF, Cardoso CL, Benites Condezo AF, Moreira Júnior R, Curi MM. Clinical outcomes of pterygoid implants: Systematic review and meta-analysis. *Journal of Cranio-Maxillofacial Surgery*. 2019;**47**(4):651-660. DOI: 10.1016/j.jcms.2019.01.030

[27] Schepers RH, Slagter AP, Kaanders JHAM, van den Hoogen FJA, Merks MAW. Effect of postoperative radiotherapy on the functional result of implants placed during ablative surgery for oral cancer. *International Journal of Oral and Maxillofacial Surgery*. 2006;**35**(9):803-808

[28] Okay DJ, Genden E, Buchbinder D, Urken M. Prosthodontic guidelines for surgical reconstruction of the maxilla. *The Journal of Prosthetic Dentistry*. 2001;**86**(4):352-363

[29] Surovas A. A digital workflow for modeling of custom dental implants. 3D

Printing in Medicine. 2019;5(9):01-11.
 DOI: 10.1186/s41205-019-0046-y

[30] Wentaschek S, Lehmann K, Scheller H, Weibrich G, Behneke N. Polygonal area of prosthesis support with straight and tilted dental implants in edentulous maxillae. *The International Journal of Prosthodontics*. 2016;29(3):245-252

[31] Raman R, Bashir R. Stereolithographic 3D bioprinting for biomedical applications. In: *Essentials of 3D Biofabrication and Translation*. Elsevier Inc.; 2015. pp. 89-121. DOI: 10.1016/B978-0-12-800972-7/00006-2

[32] Martelli N, Serrano C, Van Den Brink H, Pineau J, Prognon P, Borget I, et al. Advantages and disadvantages of 3-dimensional printing in surgery: A systematic review. *Surgery*. 2016;159(6):1485-1500

[33] Garritano FG, Fedok F. Facial reconstruction after resection for cutaneous malignancies. *Operative Techniques in Otolaryngology*. 2013;24(1):36-44. DOI: 10.1016/j.otot.2013.03.002

[34] Unkovskiy A, Spintzyk S, Brom J, Huettig F, Keutel C. Direct 3D printing of silicone facial prostheses: A preliminary experience in digital workflow. *Journal of Prosthetic Dentistry*. 2018;120(2):303-308. DOI: 10.1016/j.prosdent.2017.11.007

[35] McHutchion L, Aalto D. Simulation of tissue-prosthesis margin interface by using surface scanning and digital design for auricular prostheses. *Journal of Prosthetic Dentistry*. 2020;1-12. DOI: 10.1016/j.prosdent.2020.01.045

[36] Ellis MA, Graboyes EM, Wahlquist AE, Neskey DM, Kaczmar JM, Schopper HK, et al. Primary surgery vs. radiotherapy for early stage oral cavity cancer. *Otolaryngology–Head and Neck Surgery*. 2018;158(4):649-659

[37] Brennan PA, Bradley KL, Brands M. Intensity-modulated radiotherapy in head and neck cancer — An update for oral and maxillofacial surgeons. *British Journal of Oral and Maxillofacial Surgery*. 2017;55(8):770-774. DOI: 10.1016/j.bjoms.2017.07.019

[38] Schiegnitz E, Al-Nawas B, Kämmerer PW, Grötz KA. Oral rehabilitation with dental implants in irradiated patients: A meta-analysis on implant survival. *Clinical Oral Investigations*. 2014;18(3):687-698

[39] Zen Filho EV, Tolentino EDS, Santos PSS. Viability of dental implants in head and neck irradiated patients: A systematic review. *Head & Neck*. 2016;38:E2229–E2240

[40] Granados M, Arrieta O, Cantú de León D. *Oncología y cirugía*. In: *Bases y principios*. 1a ed. México: Manual Moderno; 2013. p. 768. Available from: <https://books.google.com/books?id=xWTLCQAAQBAJ&pgis=1>

[41] Al-Jandan B, Marei HF, Abuohashish H, Zakaria O, Al-Mahalawy H. Effects of sunitinib targeted chemotherapy on the osseointegration of titanium implants. *Biomedicine & Pharmacotherapy*. 2018;100(January):433-440

[42] Al-Jandan B, Marei HF, Abuohashish H, Zakaria O, Al-Mahalawy H. Effects of cisplatin chemotherapy on the osseointegration of titanium implants. *Biomedicine & Pharmacotherapy*. 2018;100:433-440

[43] Al-Jandan B. Effect of antiangiogenic targeted chemotherapy on the osseointegration of titanium implants in rabbits. *The British Journal of Oral & Maxillofacial Surgery*. 2019;57(2):157-163

[44] Javed F, Al-Hezaimi K, Al-Rasheed A, Almas K, Romanos GE. Implant survival rate after oral cancer therapy: A review. *Oral Oncology*.

2010;**46**(12):854-859. DOI: 10.1016/j.oraloncology.2010.10.004

[45] Kovács AF. Influence of chemotherapy on endosteal implant survival and success in oral cancer patients. *International Journal of Oral and Maxillofacial Surgery*. 2001;**30**(2):144-147

[46] Kovács AF. The fate of osseointegrated implants in patients following oral cancer surgery and mandibular reconstruction. *Head & Neck*. 2000;**22**(2):111-119