

We are IntechOpen, the world's leading publisher of Open Access books Built by scientists, for scientists

6,900

Open access books available

186,000

International authors and editors

200M

Downloads

Our authors are among the

154

Countries delivered to

TOP 1%

most cited scientists

12.2%

Contributors from top 500 universities



WEB OF SCIENCE™

Selection of our books indexed in the Book Citation Index
in Web of Science™ Core Collection (BKCI)

Interested in publishing with us?
Contact book.department@intechopen.com

Numbers displayed above are based on latest data collected.
For more information visit www.intechopen.com



Simultaneous Bilateral Joint Arthroplasties in Treatment of Osteoarthritis

*Aleksandar Radunović, Maja Vulović, Milan Aksić,
Ognjen Radunović and Aleksandar Matic*

Abstract

Osteoarthritis is the most common chronic joint condition, the aetiology of which is still not completely clear. Initial phases of disease are treated conservatively applying physical rehabilitation procedures and medications. Advanced stages need surgical treatment with numerous procedures, depending on the joint affected. Joint arthroplasties are procedure of choice, especially for big joints of the extremities. As osteoarthritis occurs bilaterally very frequently, there are a growing number of patients in need for operation of both joints. Those procedures can be performed under single anaesthesia or staged procedure, with delay between two surgeries. There are many advantages and disadvantages of both approaches cited by different authors. There is consensus of authors in available articles regarding benefits of single-stage procedure: lower cost, shorter hospital stay, single rehabilitation period and better functional results. Authors disagree about safety of a single-stage bilateral procedure as well as incidence of complications and criteria for selection of patients for safe performing of simultaneous procedure.

Keywords: osteoarthritis, hip, knee, bilateral, simultaneous

1. Introduction

Osteoarthritis is the most common joint disease in humans [1]. The American College of Rheumatology defines it as a heterogeneous group of joint affections that lead to occurrence of joint symptoms and signs related to damage of joint cartilage integrity, accompanied by changes in subchondral bone and surrounding soft tissues. Aetiology of osteoarthritis remains only partially known for the time being. It is considered to have multifactorial causes, and its occurrence is a final result of interaction of systemic factors (older age, increased body weight, etc.) as well as local risk factors (mechanical load, injuries, etc.).

Osteoarthritis can be treated both conservatively and surgically. Conservative treatment options can be divided into pharmacological and non-pharmacological. Those two treatment modalities tend to be combined aiming at achieving best possible results.

Pharmacological therapy includes the use of analgesics, NSAID, corticosteroids, oral drugs based on glucosamine and hyaluronic acid as well as intra-articular injections of sodium hyaluronate and corticosteroids. All the abovementioned therapy

modalities have very different results as explained in available reference literature. In the past decade or so, there has been a growing trend of regenerative procedures involving application of platelet-rich plasma (PRP) and stem cell therapy.

Non-pharmacological options include education of patients, reduction of body weight, exercises for muscle strengthening and stretching in order to prevent contractures, application of orthosis as well as different forms of physical rehabilitation.

2. Surgical treatment of osteoarthritis

2.1 Osteotomies of affected joint(s)

With the development of new materials and new surgical techniques, arthroplasties of joints have become a primary solution in surgical treatment of osteoarthritis. However, there are still certain indications for osteotomies, especially for osteoarthritis of lower leg big joints among young adults, aiming to postpone a total joint arthroplasty. Some studies show that at least 40% of patients with performed osteotomies need a total joint arthroplasty only a few years later [2, 3].

2.2 Arthrodesis

Arthrodesis is a surgical fusion of joints. Nowadays it is rarely performed in big joints, mostly as salvage procedure for treating infection after failed arthroplasty. Arthrodesis is more frequently used in treating osteoarthritis of small joints in the foot.

2.3 Joint arthroplasties

At this moment, joint arthroplasties are the most preferred solution for degenerative changes in big joints, especially the knees, hips and shoulders. There are numerous reports of arthroplasties of these three joints in last few decades, showing excellent functional results and patient satisfaction. As about elbows, ankles, and small joints of the hands and feet, reported arthroplasty outcomes are still not comparable with those in the hips, knees and shoulders.

There are many different forms of joint arthroplasties regarding types of fixation, articular surfaces and materials used for fabricating artificial joints, regardless of whether only one or both articular surfaces of the joint are involved in arthroplasty.

3. Simultaneous bilateral joint arthroplasties

When discussing bilateral joint arthroplasties performed as a single procedure, we are exclusively considering hip and knee arthroplasties. A single-stage bilateral arthroplasties of other joints are not routinely performed, and there are only a few articles dealing with patients when both shoulders were operated in a single procedure. In addition to this, a number of patients mentioned in those articles are quite small [4, 5].

3.1 A single-stage bilateral hip and knee arthroplasty

Osteoarthritis of the hip (coxarthrosis) occurs at 4% of the population, and 40–70% percent of patients with coxarthrosis have both hips affected [6, 7] (**Figure 1**). It is considered that 97% of patients with bilateral coxarthrosis will be in need for arthroplasty of the second hip as well [8] (**Figure 2**). With osteoarthritis

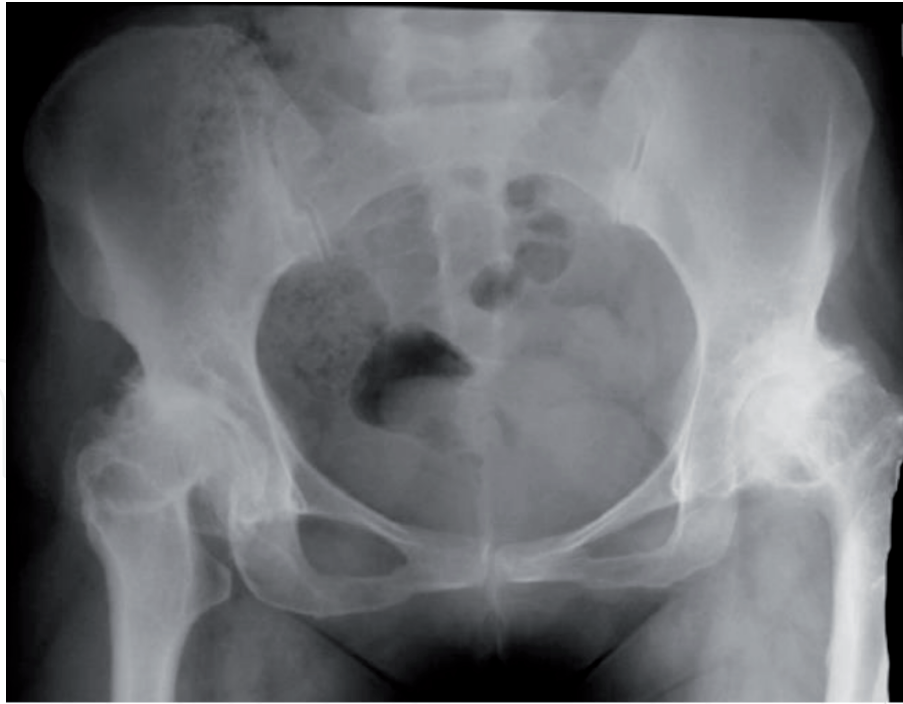


Figure 1.
Bilateral coxarthrosis.

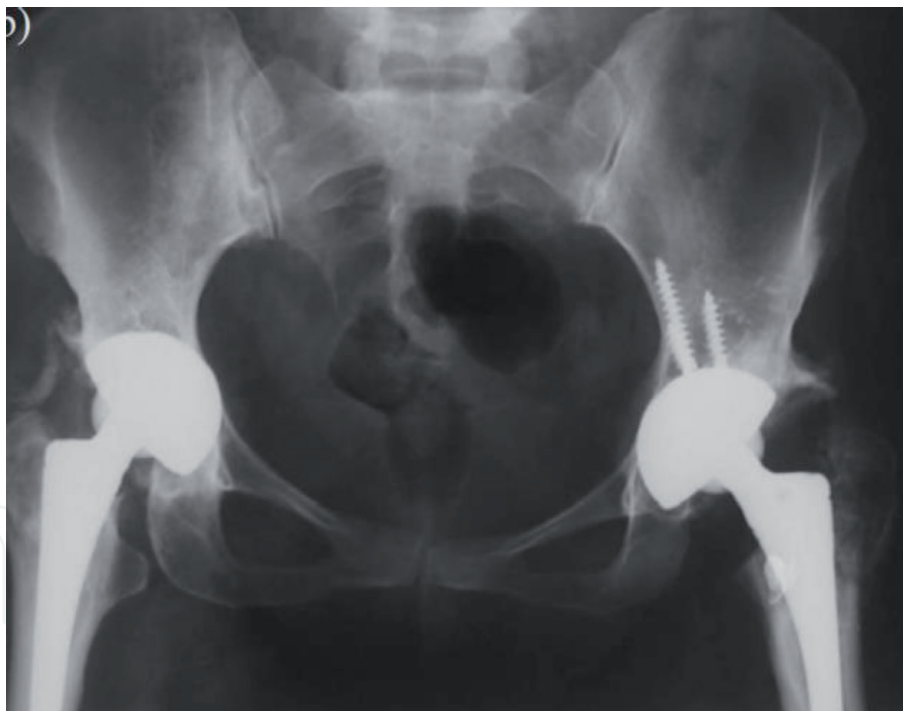


Figure 2.
Simultaneous bilateral total hip arthroplasty.

of the knee (gonarthrosis), it is estimated that 10% of patients older than 55 years have clinical symptoms of gonarthrosis [9], with 30–50% of patients having both knees affected and will be in need of bilateral surgery [10, 11] (**Figures 3 and 4**). Patients with bilateral hip or knee osteoarthritis can be surgically treated in a single procedure, by replacing both hip and knee joints under single anaesthesia, or they could be treated in a two-stage procedure with a break between two procedures. Period between two procedures significantly differs among authors. Having in mind differences among authors when it comes to bilateral hip and knee arthroplasties in a single procedure, we shall analyse them separately.

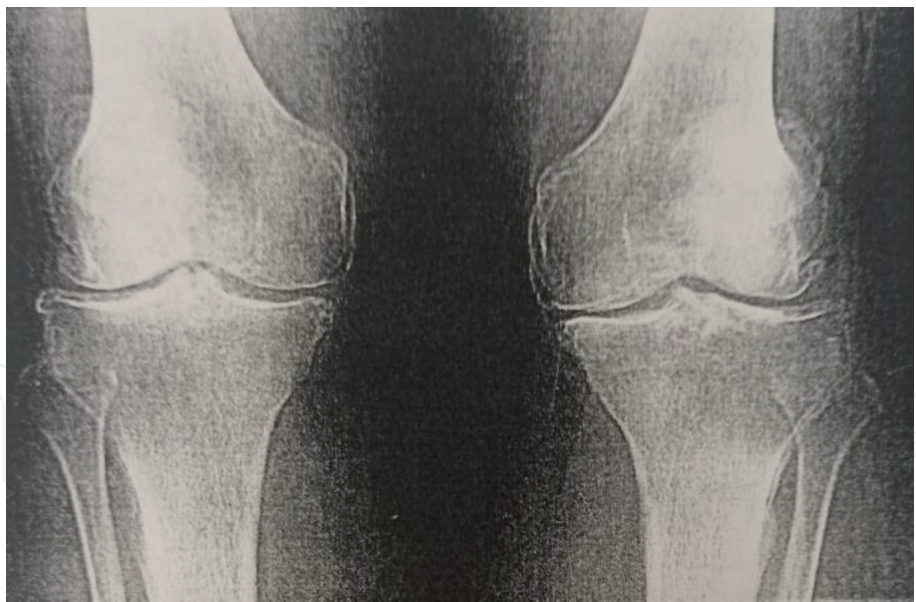


Figure 3.
Bilateral gonarthrosis.

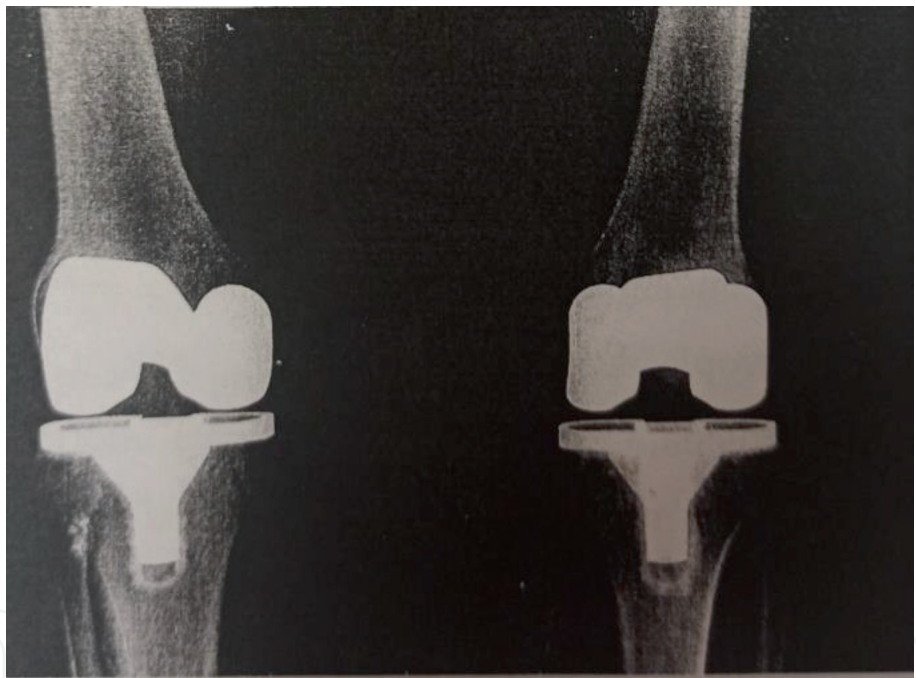


Figure 4.
Simultaneous bilateral knee arthroplasty.

3.2 Simultaneous bilateral total hip arthroplasty

The first simultaneous bilateral total hip arthroplasty was published in 1967 [12]. Jaffe and Charnley published an article in 1971, analysing results of this procedure in 50 patients [13]. Authors found minimally increased risk of complications in a simultaneous group compared to a staged group and noticed advantages of the simultaneous procedure: a single anaesthesia, a single rehabilitation period and shorter hospital days (unlike two hospital slots in a staged procedure). In the succeeding years, multiple authors will have published their results with performing a single-stage bilateral total hip arthroplasty, with lack of consensus regarding safety of procedure, patient selection and frequency of complications. At the same time, authors agreed about benefits of this simultaneous procedure: a significantly

better functional recovery and rehabilitation. Some authors have even claimed that a full functional recovery of patient is possible only after implantation of endoprosthesis in both hips and that functional scores on operated hips are lower if only one hip is operated than in patients with both hips operated in the same procedure [14]. Patients operated in a single procedure achieved better range of movement and better functional satisfaction without significant difference in pain [15]. There are also discrepancies when it comes to the period of time recommended between two surgeries in a staged procedure. Most authors prefer a period ranging from 3 to 6 months between two hip replacements. There was also a strategy of staged surgery during same hospitalization within 7–10 days between two operations. This one has however been abandoned due to significantly increased number of complications reported in majority of studies.

Authors unanimously agree that simultaneous procedure decreases hospital expenses, numbers of hospital days as well as length of rehabilitation [16–22]. It is estimated that hospital costs are reduced by 24–35%. Some authors quote shorter sick leave from work as an additional advantage. There are no studies that have analysed additional expenses (home care services, public services for patient care); hence we may assume that that real savings are even higher.

While discussing financial side effects of the procedure itself, it is interesting to mention that some authors fail to recommend performing a single-stage procedure due to lower income for the surgeon and hospital [23, 24].

Authors' opinions differ regarding selection of patients as well as the type and frequency of complications. Comorbidity is the most important factor when deciding about a safe performance of a bilateral single-stage procedure. Some authors use general determinants such as patients without significant comorbidity, with good general health and who are younger and healthier [17, 25–27].

While analysing articles that tried to objectivize selection of patients, it is noticeable that American Society of Anesthesiologists (ASA) scoring system is almost exclusively used (see below).

- **ASA 1:** A normal healthy patient.
- **ASA 2:** A patient with a mild systemic disease.
- **ASA 3:** A patient with a severe systemic disease that is not life-threatening.
- **ASA 4:** A patient with a severe systemic disease that is a constant threat to life.
- **ASA 5:** A moribund patient who is not expected to survive without the operation.
- **ASA 6:** A declared brain-dead patient whose organs are being removed for donor purposes.

Authors' opinions about groups of ASA scoring systems eligible for safe performance of bilateral single-stage surgery differ as well. Some recommend performing a simultaneous procedure with ASA 1 and 2 [28–30], others suggest this surgery on patients from ASA 1–4 groups [31], some of them say those are patients in ASA 1 and 2 and probably ASA 3 and 4, while certain authors find no differences in complications with patients belonging to ASA 1–3 [32].

One of the major issues with bilateral simultaneous procedure was a theoretical possibility of a higher incidence of thromboembolic complications caused by a prolonged surgical procedure as one of the best-known triggers for this kind of

complication [27, 33]. Earlier publications dealing with simultaneous bilateral hip arthroplasty reported a higher rate of pulmonary embolism and a slightly higher mortality rate while performing this procedure [33–35]. Improvements in surgical technique, anaesthesiology (introduction of hypotensive anaesthesia), anticoagulant therapy and early mobilisation showed decrease in numbers of reported complications of this type. Berend and Glait [36, 37] found increased incidence rate of pulmonary thromboembolism, while majority of other authors did not mention similar findings [20, 38–41]. Some of the authors who failed to find any thromboembolic complications in their series of simultaneous procedures explain this as a better adaptation of a patient to mobilisation protocols when both hips are operated.

Majority of authors reported higher need for transfusion in a simultaneous group [20, 24, 29, 32, 38, 42, 43]. Bhan found lower estimated blood loss in simultaneous group but higher number of transfusions [19]. He explained that in a staged group, blood loss is a sum of losses in two surgeries that are separated long enough for organism to compensate loss from first surgery. Some authors did not discover any increased blood loss in a simultaneous group [17, 25, 37, 44]. Glait pointed out that an increased need for transfusion can be expected if a simultaneous procedure is performed by a less experienced surgeon [37].

3.3 Simultaneous bilateral total knee replacement

While history of bilateral total hip replacement is very well documented, there are almost no papers of a single-stage total knee replacement background. There is a trend of growing number of performed TKA. In the period from 1990 to 2004, number of bilateral total knee replacements doubled and even tripled in female population [45].

Similar to bilateral simultaneous hip arthroplasties, there are certain differences among authors regarding safety of the procedure, potential complications and consensus over its benefits. Overall savings from simultaneous procedure are estimated to be 20–58% with the following contributing factors: fewer hospital days, single medical consultations, single anaesthesia and single rehabilitation period [18, 46]. It is also found by majority of authors that patients in a single-stage group experience equal or better functional result and satisfaction [47, 48]. In one study, 95% of patients would rather choose a single-stage procedure all over again, demonstrating high level of satisfaction [46]. Differences among authors apply to potential increased risk of systemic and local complications, as well as to mortality rate following the procedure itself. Some register studies (the USA and Sweden) found increased morbidity and mortality rate [49, 50], while data from New Zealand arthroplasty registry show no differences between two procedures in same terms [51]. Many authors have discovered with their series of patients an increased risk in systemic complications in a single-stage group [52–55], while a few found no difference in the incidence of complications [47, 56–58]. As per selection of patients, there are only several articles recommending application of the scoring system (ASA, see above). Hadley et al. recommend performing the procedure only in ASA 1 and 2 groups [58], while several authors say this procedure is safe with ASA 1–3 groups as well [59–61]. All authors agree there is an increased blood loss in a simultaneous group [52, 58, 62].

4. Conclusion

While planning and selecting patients with bilateral osteoarthritis of big joints, it is essential to balance between medical and economic efficiency of

simultaneous bilateral procedures and safety of patients. As majority of patients in need of bilateral surgery have significant comorbidity, it is of crucial importance to standardise perioperative protocols for selection and follow-up of patients. Multidisciplinary approach in a patient perception is of utmost importance; hence it is recommended this procedure is performed in facilities enabling this and by highly trained and experienced surgeons.

Author details

Aleksandar Radunović^{1*}, Maja Vulović², Milan Aksić³, Ognjen Radunović⁴
and Aleksandar Matic⁵

1 Clinic for Orthopedic Surgery and Traumatology, Military Medical Academy, Belgrade, Serbia

2 Department of Anatomy, Faculty of Medical Sciences, University of Kragujevac, Serbia

3 Institute of Anatomy “Niko Miljanić”, Serbia

4 Medical Faculty, University of Belgrade, Serbia

5 Department of Surgery, Faculty of medical sciences, Clinic for Orthopedic Surgery and Traumatology, Kragujevac, Serbia

*Address all correspondence to: aradunovic@yahoo.com

IntechOpen

© 2020 The Author(s). Licensee IntechOpen. This chapter is distributed under the terms of the Creative Commons Attribution License (<http://creativecommons.org/licenses/by/3.0>), which permits unrestricted use, distribution, and reproduction in any medium, provided the original work is properly cited. 

References

- [1] Hochberg MC, Silman AJ, Smolen JS, Weinblatt ME, Weisman MH, editors. Rheumatology. 3rd ed. London: Elsevier Limited; 2003
- [2] Schramm M, Hohmann D, Radespiel-Troger M, Pitto RP. Treatment of the dysplastic acetabulum with Wagner spherical osteotomy: A study of patients followed for a minimum of twenty years. The Journal of Bone and Joint Surgery. American Volume. 2003;**85A**:808-814
- [3] Steppacher SD, Tannast M, Ganz R, Siebenrock KA. Mean 20-year follow-up of Bernese peri-acetabular osteotomy. Clinical Orthopaedics and Related Research. 2008;**466**:1633-1644
- [4] Gerber C, Lingenfelter EJ, Reischl N, Sukthankar A. Single-stage bilateral total shoulder arthroplasty. Journal of Bone and Joint Surgery (British). 2006;**88-B**:751-755
- [5] Ferrousis JC, Papaspiliopoulos A, Kitsios E, Asprogenidis T, Kiriakos A, Tzoras N. Single stage bilateral total shoulder arthroplasty. Orthopaedic Proceedings; Published Online: 21 February 2018;**92-B**(Suppl IV):574
- [6] Allen K, Golightly Y. Epidemiology of osteoarthritis: State of the evidence. Current Opinion in Rheumatology. 2015;**27**(3):276-283
- [7] Chitnavis J, Sinsheimer JS, Suchard MA, Clipsham K, Carr AJ. End-stage coxarthrosis and gonarthrosis: Aetiology, clinical patterns and radiological features of idiopathic osteoarthritis. Rheumatology. 2000;**39**:612-619
- [8] Sayeed SA, Johnson AJ, Jaffe DE, Mont MA. Incidence of contralateral THA after index THA for osteoarthritis. Clinical Orthopaedics and Related Research. 2012;**470**(2):535-540
- [9] Peat G, McCarney R, Croft P. Knee pain and osteoarthritis in older adults: A review of community burden and current use of health care. Annals of the Rheumatic Diseases. 2001;**60**:91-97
- [10] Liu TK, Chen SH. Simultaneous bilateral total knee arthroplasty in a single procedure. International Orthopaedics. 1998;**22**(6):390-393
- [11] Hussain N, Chien T, Hussain F, Bookwala A, Simunovic N, Shetty V, et al. Simultaneous vs staged bilateral total knee arthroplasty. HSS Journal. 2013;**9**(1):50-59
- [12] Lazansky M. A Study of Bilateral Low Friction Arthroplasty. Internal Publication No. 3. Centre for Hip Surgery, Wrightington Hospital: Appley Bridge, UK; 1967
- [13] Jaffe WL, Charnley J. Bilateral Charnley low-friction arthroplasty as a single operative procedure: A report of fifty cases. Bulletin of the Hospital for Joint Diseases. 1971;**32**:198
- [14] Wykman A, Olsson E. Walking ability after total hip arthroplasty: A comparison of gait analysis in unilateral and bilateral cases. Journal of Bone and Joint Surgery. British Volume (London). 1992;**74**:53
- [15] Yoshii T, Jinno T, Morita S, Koga D, Matsubara M, Okawa A, et al. Postoperative hip motion and functional recovery after simultaneous bilateral total hip arthroplasty for bilateral osteoarthritis. Journal of Orthopaedic Science. 2009;**14**:161-166
- [16] Alfaro-Adrián J, Bayona F, Rech JA, Murray W. One- or two-stage bilateral total hip replacement. The Journal of Arthroplasty. 1999;**14**:439-445
- [17] Parvizi J, Tarity TD, Ednan Sheikh E, Sharkey PF, Hozack WJ,

- Rothman RH. Bilateral total hip arthroplasty. One-stage versus two-stage procedures. *Clinical Orthopaedics and Related Research*. 2006;**453**:137-141
- [18] Reuben JD, Meyers SJ, Cox DD, et al. Cost comparison between bilateral simultaneous, staged, and unilateral total joint arthroplasty. *The Journal of Arthroplasty*. 1998;**13**:172
- [19] Bhan S, Pankaj A, Malhotra R. One- or two-stage bilateral total hip arthroplasty: A prospective, randomised, controlled study in an Asian population. *Journal of Bone and Joint Surgery. British Volume (London)*. 2006;**88-B**:298-303
- [20] Tsiridis E, Pavlou G, Charity J, Tsiridis E, Gie G, West R. The safety and efficacy of bilateral simultaneous total hip replacement an analysis of 2063 cases. *Journal of Bone and Joint Surgery. British Volume (London)*. 2008;**90-B**:1005-1012
- [21] Seol JH, Park KS, Yoon TR. Postoperative complications and cost-effectiveness of simultaneous and staged bilateral total hip arthroplasty using a modified minimally invasive two- incision technique. *Hip & Pelvis*. 2015;**27**(2):77-82
- [22] Rolfson O, Digas G, Herberts P, Karrholm J, Borgstrom F, et al. One-stage bilateral total hip replacement is cost-saving. *Journal of Orthopedics and Muscular System*. 2014;**3**:175
- [23] Trojani C, Chaumet-Lagrange V-A, Hovorka E, Carles M, Boileau P. Simultaneous bilateral total hip arthroplasty: Literature review and preliminary results. *Revue de Chirurgie Orthopédique et Réparatrice de l'Appareil Moteur*. 2006;**92**(8):760-767
- [24] Berend KR, Lombardi AV Jr, Adams JB. Simultaneous vs staged cementless bilateral total hip arthroplasty: Perioperative risk comparison. *The Journal of Arthroplasty*. 2007;**22**(6):111-115
- [25] Aghayev E, Beck A, Staub L, Dietrich D, Melloh M, Orljanski W, et al. Simultaneous bilateral hip replacement reveals superior outcome and fewer complications than two-stage procedures: A prospective study including 1819 patients and 5801 follow-ups from a total joint replacement registry. *BMC Musculoskeletal Disorders*. 2010;**11**:245-255
- [26] Popović Z, Rajović J, Radunović A. Total bilateral hip arthroplasty in one surgical procedure. *Vojnosanitetski Pregled (Military Medical Review in English)*. 2007;**64**(10):697-700
- [27] Macaulay W, Salvati EA, Sculco TP, Pellicci PM. Single-stage bilateral total hip arthroplasty. *The Journal of the American Academy of Orthopaedic Surgeons*. 2002;**10**(3):217-221
- [28] Trojani C, Ollone T, Saragaglia D, Vielpeau C, Carles M, Prudhon L. One stage bilateral total hip arthroplasty: Functional outcome and complications in 112 patients. *Orthopaedics & Traumatology, Surgery & Research*. 2012;**98**(6):120-123
- [29] Lamo-Espinosa J, Troncoso S, Valentí-Azcarate A, Diaz de Rada P, Valentí JR. Clinical and radiological short-term complications after single stage bilateral uncemented total hip arthroplasty. *Musculoskeletal Surgery*. 2015;**99**(1):67-73
- [30] Romagnoli S, Zacchetti S, Perazzo P, Verde F, Banfi G, Vigano M. Simultaneous bilateral total hip arthroplasties do not lead to higher complication or allogeneic transfusion rates compared to unilateral procedures. *International Orthopaedics*. 2013;**37**(11):2125-2130
- [31] Garland A, Rolfson O, Garellick G, Kärrholm J, Hailer N. Early postoperative

- mortality after simultaneous or staged bilateral primary total hip arthroplasty: An observational register study from the Swedish hip arthroplasty register. *BMC Musculoskeletal Disorders*. 2015;**16**(1):263-272
- [32] Radunovic A. Clinical safety of single stage bilateral cementless hip arthroplasty [PhD thesis]. Serbia: Medical Faculty, University of Kragujevac; 2018
- [33] Ritter MA, Campbell ED. Direct comparison between bilaterally implanted cemented and uncemented total hip replacements in six patients. *Clinical Orthopaedics*. 1986;**207**:77-82
- [34] Ritter MA, Stringer EA. Bilateral total hip arthroplasty: A single procedure. *Clinical Orthopaedics*. 1980;**149**:185
- [35] Ritter MA, Randolph JC. Bilateral total hip arthroplasty: A simultaneous procedure. *Acta Odontologica Scandinavica*. 1976;**47**(2):203-208
- [36] Berend ME, Ritter MA, Harty LD, et al. Simultaneous bilateral versus unilateral total hip arthroplasty an outcome analysis. *The Journal of Arthroplasty*. 2005;**20**:421-426
- [37] Glait S, Khatib O, Bansal A, Hochfelder J, Slover J. Comparing the incidence and clinical data for simultaneous bilateral versus unilateral total hip arthroplasty in New York state between 1990 and 2010. *The Journal of Arthroplasty*. 2015;**30**(11):1887-1891
- [38] Kim YH, Kwon OR, Kim JS. Is one-stage bilateral sequential total hip replacement as safe as unilateral total hip replacement? *Journal of Bone and Joint Surgery (British)*. 2009;**91-B**:316-320
- [39] Eggl S, Huckell CB, Ganz R. Bilateral total hip arthroplasty: One stage versus two-stage procedure. *Clinical Orthopaedics*. 1996;**328**:108-118
- [40] Lorenze M, Huo MH, Zatorski LE, Keggi KJ. A comparison of the cost effectiveness of one- stage versus two-stage bilateral total hip replacement. *Orthopaedics*. 1998;**21**:1249-1252
- [41] Cammisa FPOBS Jr, Salvati EA, Sculco TP, Wilson PD Jr, Ranawat CS, Pellicci PM, et al. One-stage bilateral total hip arthroplasty. A prospective study of perioperative morbidity. *The Orthopedic Clinics of North America*. 1988;**19**(3):657-668
- [42] Parvizi J, Pour AE, Peak L, Sharkey P, Hozack W, Rothman R. One-stage bilateral total hip arthroplasty compared with unilateral total hip arthroplasty. *The Journal of Arthroplasty*. 2006;**21**(6 Suppl 2):26-31
- [43] Schäfer M, Elke R, Young JR, Gancs P, Kindler CH. Safety of one-stage bilateral hip and knee arthroplasties under regional anaesthesia and routine anaesthetic monitoring. *Journal of Bone and Joint Surgery (British)*. 2005;**87-B**:1134-1139
- [44] Diwanji SR, Park KS, Yoon TR, Seo HY, Wie JS. Bilateral simultaneous two-incision mini mal invasive total hip arthroplasty. *Journal of Orthopaedic Science*. 2009;**14**:517-524
- [45] Memtsoudis SG, Besculides MC, Reid S, Gaber-Baylis LK, González Della Valle A. Trends in bilateral total knee arthroplasties: 153,259 discharges between 1990 and 2004. *Clinical Orthopaedics and Related Research*. 2009;**467**(6):1568-1576
- [46] Leonard L, Williamson DM, Ivory JP, Jennison C. An evaluation of the safety and efficacy of simultaneous bilateral total knee arthroplasty. *The Journal of Arthroplasty*. 2003;**18**(8):972-978
- [47] Kim YH, Choi YW, Kim JS. Simultaneous bilateral sequential total knee replacement is as safe as unilateral total knee replacement. *Journal of*

Bone and Joint Surgery. British Volume (London). 2009;**91**(1):64-68

[48] March LM, Cross M, Tribe KL, et al. Two knees or not two knees? Patient costs and outcomes following bilateral and unilateral total knee joint replacement surgery for OA. *Osteoarthritis and Cartilage*. 2004;**12**(5):400-408

[49] Bolognesi MP, Watters TS, Attarian DE, Wellman SS, Setoguchi S. Simultaneous vs staged bilateral total knee arthroplasty among medicare beneficiaries, 2000-2009. *The Journal of Arthroplasty*. 2013;**28**:87-91

[50] Stefansdottir A, Lidgren L, Robertsson O. Higher early mortality with simultaneous rather than staged bilateral TKAs: Results from the Swedish knee arthroplasty register. *Clinical Orthopaedics and Related Research*. 2008;**466**:3066-3070

[51] Hooper GJ, Hooper NM, Rothwell AG, Hobbs T. Bilateral total joint arthroplasty: The early results from the New Zealand National Joint Registry. *The Journal of Arthroplasty*. 2009;**24**:1174-1177

[52] Memtsoudis SG, Ma Y, González Della Valle A, et al. Perioperative outcomes after unilateral and bilateral total knee arthroplasty. *Anesthesiology*. 2009;**111**(6):1206-1216

[53] Ritter MA, Harty LD, Davis KE, Meding JB, Berend M. Simultaneous bilateral, staged bilateral, and unilateral total knee arthroplasty. A survival analysis. *The Journal of Bone and Joint Surgery. American Volume*. 2003;**85-A**(8):1532-1537

[54] Hutchinson JR, Parish EN, Cross MJ. A comparison of bilateral uncemented total knee arthroplasty: Simultaneous or staged? *Journal of Bone and Joint Surgery. British Volume (London)*. 2006;**88**(1):40-43

[55] Luscombe JC, Theivendran K, Abudu A, Carter SR. The relative safety of one-stage bilateral total knee arthroplasty. *International Orthopaedics*. 2009;**33**(1):101-104

[56] Bini SA, Khatod M, Inacio MC, Paxton EW. Same-day versus staged bilateral total knee arthroplasty poses no increase in complications in 6,672 primary procedures. *The Journal of Arthroplasty*. 2014;**29**(4):694-697

[57] Shin YH, Kim MH, Ko JS, Park JA. The safety of simultaneous bilateral versus unilateral total knee arthroplasty: The experience in a Korean hospital. *Singapore Medical Journal*. 2010;**51**:44-49

[58] Hadley S, Day M, Schwarzkopf R, Smith A, Slover J, Zuckerman J. Is simultaneous bilateral total knee arthroplasty (BTKA) as safe as staged BTKA? *American Journal of Orthopedics (Belle Mead, N.J.)*. 2017;**46**(4):E224-E229

[59] Memtsoudis SG, Ma Y, Chiu YL, Poultides L, Gonzalez Della Valle A, Mazumdar M. Bilateral total knee arthroplasty: Risk factors for major morbidity and mortality. *Anesthesia and Analgesia*. 2011;**113**(4):784-790

[60] Noble J, Goodall JR, Noble DJ. Simultaneous bilateral total knee replacement: A persistent controversy. *The Knee*. 2009;**16**(6):420-426

[61] Yoon HS, Han CD, Yang IH. Comparison of simultaneous bilateral and staged bilateral total knee arthroplasty in terms of perioperative complications. *The Journal of Arthroplasty*. 2010;**25**(2):179-185

[62] Breakwell LM, Getty CJ, Dobson P. The efficacy of autologous blood transfusion in bilateral total knee arthroplasty. *The Knee*. 2000;**7**(3):145-147