

# We are IntechOpen, the world's leading publisher of Open Access books Built by scientists, for scientists

6,900

Open access books available

186,000

International authors and editors

200M

Downloads

Our authors are among the

154

Countries delivered to

TOP 1%

most cited scientists

12.2%

Contributors from top 500 universities



WEB OF SCIENCE™

Selection of our books indexed in the Book Citation Index  
in Web of Science™ Core Collection (BKCI)

Interested in publishing with us?  
Contact [book.department@intechopen.com](mailto:book.department@intechopen.com)

Numbers displayed above are based on latest data collected.  
For more information visit [www.intechopen.com](http://www.intechopen.com)



# Guillain-Barre Syndrome and Miller Fisher Variant in Zika Virus Disease

*Raafat Hammad Seroor Jadah*

## Abstract

Guillain-Barre syndrome (GBS) is a serious neurological disorder associated with a rapid progressive ascending muscle paralysis, and it is the most common neurological autoimmune disorder that affects the peripheral nervous system, which is usually triggered by viral or bacterial infection. GBS is rare in children and characterized by rapid progressive onset ascending muscle weakness associated with pain and sensory dysfunction. Miller Fisher syndrome (MFS), a variant of GBS, is rare in pediatric population which is typically manifested by ataxic gait, ophthalmoplegia, and areflexia since it is rare in children. It is vitally important to early diagnose this condition and to initiate early treatment to prevent further complications and long-term morbidity. Since the outbreak of Zika virus, the incidence of GBS has been increased. Zika virus associated with autoimmune anti-ganglioside antibodies trigger which lead to GBS development. Zika virus infection should be strongly considered in patients who present with classical signs of Miller Fisher syndrome, especially travelers and residents from endemic areas.

**Keywords:** Guillain-Barre, Miller Fisher, autoimmune, Zika, outbreak, ataxia

## 1. Introduction

### 1.1 History

In 1916, two French Neurologists Georges Charles Guillain and Jean Alexandre Barre and French Physiologist Andre Strohl reported an original paper encountered new syndrome in two soldiers with muscle weakness, absence of deep tendon reflexes and sensory impairment and described the key diagnosis of albuminocytologic disassociation in the cerebrospinal fluid along with changes in electromyography and nerve conduction studies. Both patients were managed with massage therapy and Strychnine injection and showed clinical recovery after few months [1].

GBS is rare but the commonest cause for acute ascending paralytic polyneuropathy. GBS is considered to be an acute immune-mediated disorder that causes peripheral polyneuropathy. Most cases of GBS are preceded by either viral or bacterial infection, which triggers the immune system affecting the peripheral nervous system causing a rapid progressive demyelinating polyneuropathy [2, 3].

The incidence of GBS has been increased since the outbreak of certain infections such as Zika virus epidemic in Latin America in 2015. GBS is the most leading cause of acute ascending muscle paralysis with an annual incidence of 1–2 per 100,000 persons per year worldwide. GBS is more common in males than females [2, 3].

GBS is a rapid demyelinating peripheral neuropathy that typically manifest as ascending muscle weakness that is symmetric in nature associated with reduced or absent deep tendon reflexes. GBS has been also associated with pain along with sensory impairment [4].

GBS is an acute immune-mediated demyelinating polyneuropathy and it is the commonest cause of acute muscle paralysis in pediatric age group patients [5, 6].

MFS is a rare neurological disorder which was initially recognized in 1932 by James Collier as a classical triad of ophthalmoplegia, ataxia and absent deep tendon reflexes. Later in 1956 Charles Miller Fisher a Canadian Neurologist described and reported details isolated clinical entity of three patients who presented with ophthalmoplegia, ataxia and areflexia [7].

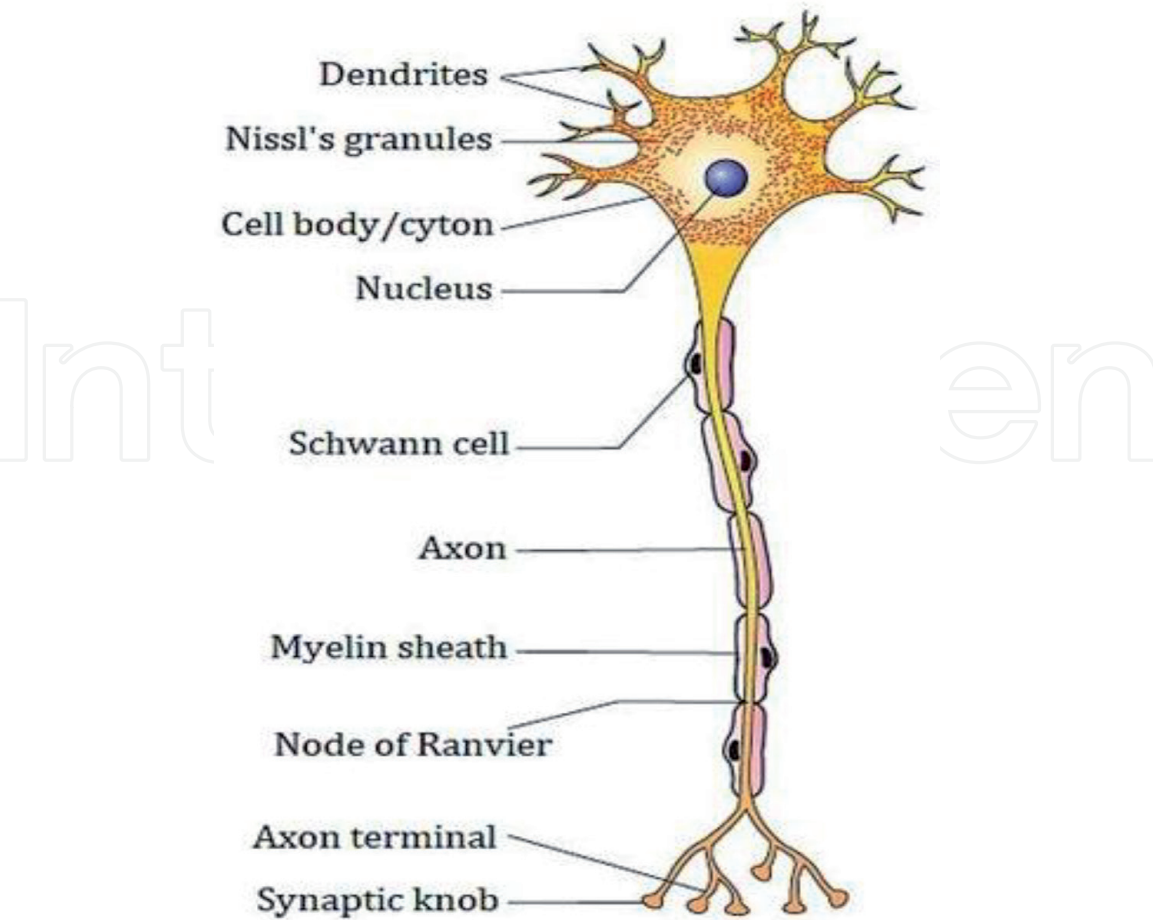
MFS has an annual incidence of 0.9 per 1000,000 populations and affect males more than females at ratio of 2:1 and commonly affect Asian population especially at their fourth decade of life [7].

MFS most commonly preceded by *Campylobacter jejuni* infection and has strong association with positive anti-GQ1b antibodies [7].

Zika virus infection has been associated with different neurological disorders such as microcephaly and since the initial outbreak of Zika virus infection the number of GBS cases has been increased in endemic countries [8].

## 2. Pathophysiology and immunopathology

The neurological symptoms and signs of GBS usually take place 4 weeks after the initial respiratory or gastrointestinal infection which account for about



**Figure 1.**  
Basic structure of motor neuron [10].

two-third of GBS cases in adult population. The immune system will be stimulated secondary to infectious antigen with *Campylobacter jejuni* (*C. jejuni*) being the most common infectious pathogenic agent which account for 25–50% of adult GBS cases [9]. These infectious antigens cause stimulation of both cellular and hormonal systems leading to axonal damage and demyelination of the peripheral nerve and nerve roots (**Figure 1**) [11].

Monocytes, T-cells, especially CD4+ T-helper cells and B-cells in order of frequency, have been commonly implicated in the immunopathology of GBS cases especially in the acute inflammatory demyelinating polyradiculoneuropathy (AIDP) [11].

More than 80% of the patients with Miller Fisher syndrome have anti-GQ1b IgG antibodies which mainly activate the compliment system especially at the presynaptic nerve ending and perisynaptic Schwann cells which has been implicated in the pathogenesis of MFS [11, 12].

### 3. Clinical features

GBS is a rapid inflammatory ascending symmetric muscle weakness associated with reduced or complete absent of deep tendon reflexes. The most common symptom is inability to walk. The frequent findings on the clinical examination include hyperesthesia, autonomic dysfunction, sensory loss, ataxia, bilateral facial nerve palsy and third cranial nerve palsy [4, 13].

#### 3.1 Clinical subtypes of Guillain-Barre syndrome (GBS)

A number of clinical subtypes of Guillain-Barre Syndrome (GBS) are identified.

Acute inflammatory demyelinating polyradiculoneuropathy (AIDP) is considered to be the most common subtype and account for approximately of 90 percent of GBS patients in the United States. Patients with this subtype typically present with progressive ascending symmetric muscle weakness and areflexia associated with severe pain and autonomic dysfunction such as fluctuation in blood pressure, urinary incontinence or syncope. This clinical subtype typically shows a slow nerve conduction velocity with no clear anti-ganglioside antibodies association [14].

Other subtype of GBS is the acute motor axonal neuropathy (AMAN) that accounts for 5% of Guillain-Barre syndrome (GBS) patients in United States. This subtype purely presents with motor weakness without sensory symptoms. Nerve conduction study shows axonal polyneuropathy with normal sensory nerve action potential. Patients with acute motor axonal motor neuropathy have strong association with *Campylobacter jejuni* (*C. jejuni*) infection with positive antibodies against gangliosides GM1, GD1a, GaINac-GD1a and GD1b [14].

The acute motor-sensory axonal neuropathy (AMSAN) is a rare and severe variant of GBS [15], which has similar clinical features to acute motor axonal neuropathy but with predominantly sensory loss and positive antibodies against GM1 and GD1a. Nerve conduction study showed axonal polyneuropathy with reduced or absent sensory nerve action potential [14].

The pharyngeal-cervical brachial syndrome (PCB) is another rare subtype of GBS [16]. Patient with PCB syndrome typically present with rapid and progressive oropharyngeal and shoulder muscle weakness associated with absent deep tendon reflexes in the upper limbs. The nerve conduction study in patients with PCB syndrome is generally normal but sometimes showed axonal neuropathy in the arms. PCB syndrome associated with positive IgG anti-GT1a antibodies [17].

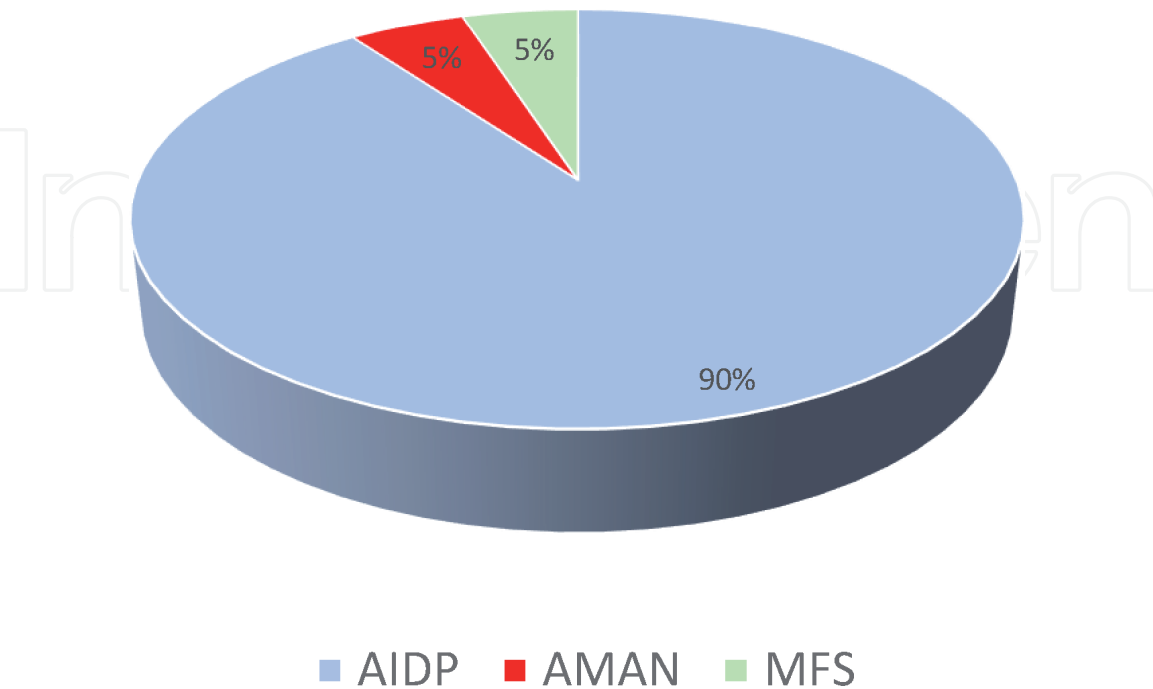
Miller Fisher syndrome is one of the GBS variant. It is an uncommon neurological disorder which account of about 5% of GBS cases. Patients with Miller Fisher syndrome typically present with clinical trial of ophthalmoplegia which is bilateral symmetric in most patients, ataxia and absent deep tendon reflexes. The commonest initial presenting symptoms in patients with Miller Fisher syndrome is diplopia (double vision) which is due to acute onset-ophthalmoplegia. Other less frequent signs and symptoms of MFS include headache, difficulty swallowing and photophobia (**Table 1**). MFS is an immune-mediated neurological disorder and more than 80% of patients with MFS showed positive IgG anti-GQ1b antibodies. Electrophysiological findings in patients with MFS commonly showed reduced sensory nerve action potentials and absent H reflexes (**Figure 2** and **Table 2**) [7, 12, 18].

Bickerstaff brainstem encephalitis currently considered to be another variant of Fisher syndrome associated with central nervous system involvement. Patients with Bickerstaff brainstem encephalitis typically present with ophthalmoplegia, ataxia, hyperreflexia and altered sensorium [19].

Bickerstaff brainstem encephalitis is an immune-mediated neurological disorder usually preceded by infection and associated with positive anti-GQ1b antibodies [19].

• Double vision (diplopia): most common
• Abnormal gait (ataxia)
• <b>Less frequent symptoms</b>
• Headache
• Difficulty swallowing (dysphagia)
• Light intolerance (photophobia)

**Table 1.**  
*Clinical symptoms associated with MFS.*



**Figure 2.**  
*Percentage of different subtypes of GBS [14, 18].*



Type	Clinical symptoms	Electrophysiological findings	Serological tests
Acute inflammatory demyelinating polyradiculoneuropathy	Muscle weakness with sensory and autonomic dysfunction	Slow nerve conduction velocity	No clear anti-ganglioside antibodies association
Acute motor axonal neuropathy	Muscle weakness with no sensory impairment	Axonal polyneuropathy with normal sensory nerve action potential	Positive anti-ganglioside antibodies GM1, GD1a, GaINac-GD1a, and GD1b
Acute motor-sensory axonal neuropathy	Muscle weakness with sensory involvement	Axonal polyneuropathy with absent or reduced sensory nerve action potential	Positive antibodies against GM1 and GD1a
Pharyngeal-cervical brachial variant	Oropharyngeal and shoulder muscle weakness	Generally normal, occasional axonal neuropathy in the arms	Positive IgG anti-GT1a antibodies
Miller Fisher syndrome	Ophthalmoplegia, ataxia and areflexia	Reduced sensory nerve action potential and absent H-reflexes	Positive IgG anti-GQ1b antibodies

**Table 2.**  
*Summary of the clinical subtypes of Guillain-Barre syndrome.*

Zika virus belongs to the virus family Flaviviridae. This virus was first isolated in 1947 from a monkey in the Zika forest of Uganda. Zika virus spread mainly by Aedes mosquitos as well as by intrauterine transmission, blood and sexual intercourse [20]. Most cases of Zika virus infection are associated with mild symptoms such as fever, headache, maculopapular skin rash, red eyes (conjunctivitis) and joint or muscle pain [21–23].

The outbreak of Zika virus infection in Brazil in 2015 has been associated with a more serious neurological complication such as Guillain-Barre syndrome [24]. This outbreak has been also resulted in increase in the incidence of babies with microcephaly [25, 26].

During Zika outbreak in Brazil, patients who developed Guillain-Barre syndrome secondary to Zika virus infection were found to have a higher level of anti-ganglioside antibodies of both IgM and IgG isotypes as compared to other patients with Zika infection in the absence of GBS [27].

Since Zika virus associated with serious devastating neurological complications such as Guillain-Barre syndrome and congenital anomalies in the newborn babies, several methods have been developed in order to detect the virus in early course of infection. Nonstructural protein 1 (NS1) is considered to be an essential biomarker for early detection and diagnosis of Zika virus. The development of double-antibody sandwich ELISA (DAS-ELISA) has been also used for early and rapid detection of ZIKA-NS1 protein in patients who newly infected with Zika virus [28].

At the present time, there is no antiviral treatment or specific vaccines approved for patients infected with Zika virus. Supportive care remains the main modality of managing these patients, yet the challenge remains to prevent congenital Zika syndrome in pregnant women [29].

#### **4. Diagnosis of Guillain-Barre syndrome and Miller Fisher variant**

The diagnosis of GBS and Miller Fisher variant is often made clinically based on the symptoms and clinical signs of the patients [30]. A more detail and supporting investigational studies such cerebrospinal fluid (CSF) analysis, electrophysiological tests such as nerve conduction studies, ultrasonographic and MRI imaging along with serologic testing can be carried out to confirm the diagnosis of GBS and other variants such as MFS [31].

Electrophysiological findings in patients with GBS suggestive of demyelination process in the form of reduce motor conduction velocity (MCV), prolonged motor distal latency and increase F wave latency. The findings of conduction block with absent H-reflex are considered to be the commonest and early sign in GBS [32].

Patients with Fisher-Bickerstaff syndrome (FBS) typically showed sensory axonal neuropathy in the form of reduced sensory nerve action potential (SNAP) amplitude in the absence of demyelination parameters [33].

The use of imaging studies such as peripheral nerve ultrasound and MRI are helpful diagnostic tools to diagnose inflammatory peripheral nerve roots [34].

The findings of MRI findings in patients with Miller-Fisher syndrome can range from cranial nerve involvement especially the optic nerve to severe cerebral white matter lesions [35, 36].

Another important biomarker which help confirming the diagnosis of GBS is the cerebrospinal fluid (CSF) analysis which typically show albuminocytologic dissociation (elevated protein level with normal cell count in cerebrospinal fluid) which has been also seen in patients with MFS and Bickerstaff brainstem encephalitis [37].

Although the diagnosis of MFS is based mainly on the classical triad of ophthalmoplegia, areflexia and ataxia which developed approximately within 1 week to 10 days after the initial infection, serologic tests can be used to confirm the diagnosis. The presence of anti-GQ1b antibodies, which was first described in 1992, provides a strong diagnostic marker for MFS [38].

The yield of this serological marker is high if the test done within 4 weeks after initial clinical onset [39].

#### **5. Treatment practice of Guillain-Barre syndrome and Miller Fisher variant**

Since GBS is a demyelinating polyneuropathy that cause rapid ascending muscle paralysis it is vitally important to admit patients with GBS to the intensive care unit for close monitoring and observation as over 30% of GBS patients can develop respiratory failure [40].

Currently plasmapheresis and intravenous immunoglobulin (IVIG) are the only effective therapies for GBS [41].

The timing of plasmapheresis has a significant impact on the clinical outcome if it is done within 2 weeks from the initial clinical onset as it reduces the time needed for ventilator support and improves motor function and walking without any help. The use of IVIG also shown to yield a good response in patients with GBS, however the use of plasmapheresis and IVIG were equally effective in GBS patients and combined therapy showed no significant difference in the final patients' clinical outcomes as compared to a single therapy. There is no role of corticosteroids therapy in the management of GBS even if it is used in high dose in the initial phase of GBS [40].

In patients with MFS IVIG have shown to speed the recovery of ophthalmoplegia and ataxia. However, IVIG and plasmapheresis have no significant impact on the overall outcome in patients with Miller Fisher syndrome [42].

6. Prognosis of Guillain-Barre syndrome and Miller Fisher variant

The overall prognosis of GBS is positive. Not all patients with GBS show complete recovery; however, most of these patients have a good outcome on one year follow up [43].

However, factors that indicate poor prognosis in GBS patients include old age and severe neurological deficit with cranial nerve injury at clinical onset, the need for mechanical ventilation and axonal damage in the nerve conduction study (Table 3) [44].

MFS has an overall a good prognosis [45], and despite the fact it has self-limiting course in most cases, Miller Fisher rarely progressive to respiratory failure [46].

The early diagnosis of MFS and early treatment with plasma exchange or intravenous immunoglobulins can reduce the severity of the disease and hasten the recovery in patients with MFS [46].

The ataxia and ophthalmoplegia usually recover within 1 to 3 months after initial clinical onset with almost complete resolution within 6 months. The loss of deep tendon reflexes may persist however does not interfere with daily functional activities [47].

1. Elderly patients
2. Severe focal neurological deficit at the initial presentation
3. Mechanical ventilation
4. Axonal demyelination in nerve conduction study

Table 3.  
*Poor prognostic factors in GBS [44].*

7. Conclusion

Guillain-Barre syndrome is a serious neurological disorder associated with a rapid progressive ascending muscle paralysis. It is essential to provide maximum supportive medical care and start early therapy to prevent further deterioration and improve the future outcome of the patients.

Miller Fisher is a variant of Guillain-Barre syndrome is rare in pediatric population with an overall good prognosis. Early recognition and management of such uncommon neurological disorder will help in preventing further complications and long-term morbidity.

Conflict of interest

The author declares no conflict of interest.

Abbreviations

GBS	Guillain-Barre syndrome
MFS	Miller Fisher syndrome
PCB	pharyngeal-cervical brachial
MRI	magnetic resonance imaging
IVIG	intravenous immunoglobulin
ELISA	enzyme-linked immunosorbent assay



IntechOpen

IntechOpen

### **Author details**

Raafat Hammad Seroor Jadah  
Department of Pediatrics, Bahrain Defence Force Hospital, Royal Medical Services,  
Kingdom of Bahrain

\*Address all correspondence to: [nader212@hotmail.com](mailto:nader212@hotmail.com)

### **IntechOpen**

© 2020 The Author(s). Licensee IntechOpen. This chapter is distributed under the terms of the Creative Commons Attribution License (<http://creativecommons.org/licenses/by/3.0>), which permits unrestricted use, distribution, and reproduction in any medium, provided the original work is properly cited. 

## References

- [1] Freitas MRG, Vidal CM, Orsini M. Guillain-Barre syndrome: Celebrating a century. *Arquivos de Neuro-Psiquiatria*. 2017;**75**(8):600-603. DOI: 10.1590/0004-282X20170093
- [2] Leonhard SE, Mandarakas MR, Gondim FAA, Bateman K, Ferreira MLB, Cornblath DR. Diagnosis and management of Guillain-Barre syndrome in ten steps. *Nature Reviews. Neurology*. 2019;**15**(11):671-683. DOI: 10.1038/s41582-019-0250-9
- [3] Willison HJ, Jacobs BC, Van Doorn PA. Guillain-Barre syndrome. *Lancet*. 2016;**388**(10045):717-727. DOI: 10.1016/S0140-6736(16)00339-1
- [4] Estridge R, Iskander M. Understanding Guillain-Barre syndrome. *JAAPA*. 2015;**28**(7):19-22. DOI: 10.1097/01.JAA.000466585.10595.f5
- [5] Ramirez-Zamora M, Burgos-Ganuza CR, Alas-Valle DA, Vergara-Galan PE, Orteiz-Gonzalez CI. Guillain-Barre syndrome in pediatric age: Epidemiological, clinical and therapeutic profile in a hospital in El Salvador. *Revista de Neurologia*. 2009;**48**(6):292-296. DOI: 10.33588/rn.4806.2008560
- [6] Ryan MM. Pediatric Guillain-Barre syndrome. *Current Opinion in Pediatrics*. 2013;**25**(6):689-693. DOI: 10.1097/MOP.0b013e328365ad3f
- [7] Bandeira LP, Palaoro LG, Degenszajn J. Miller Fisher syndrome: A rare variant of Guillain-Barre syndrome. *Autopsy & Case Reports*. 2012;**2**(3):57-61. DOI: 10.4322/acr.2012.027
- [8] Koike H. Zika virus and Guillain-Barre syndrome. *Brain and Nerve*. 2018;**70**(2):113-120. DOI: 10.11477/mf.1416200963
- [9] Rodrigues-Morales AJ, Failoc-Rojas VE, Diaz-Velez C. Gastrointestinal, respiratory and/or arboviral infections? What is the cause of the Guillain-Barre syndrome epidemics in Peru? *Current status—2019. Travel Medicine and Infectious Disease*. 2019;**30**:114-116. DOI: 10.1016/j.tmaid.2019.06.015
- [10] Rodriguez Y, Rojas M, Pacheco Y, Acosta-Ampudia Y, Ramirez-Santana C, Monsalve DM, et al. Guillain-Barré syndrome, transverse myelitis and infectious disease. *Cellular & Molecular Immunology*. 2018;**15**(6):547-562. DOI: 10.1038/cmi.2017.142
- [11] Liu S, Dong C, Ubogu EE. Immunotherapy of Guillain-Barre syndrome. *Human Vaccines & Immunotherapeutics*. 2018;**14**(11):2568-2579. DOI: 10.1080/21645515.2018.1493415
- [12] Dagklis IE, Papaglannopoulos S, Theodoridou V, Kazis D, Argyropoulou O, Bostantjopoulou S. Miller-Fisher syndrome: Are anti-GAD antibodies implicated in its pathophysiology? *Case Reports in Neurological Medicine*. 2016;**2016**:3431849. DOI: 10.1155/2016/3431849
- [13] Kilic B, Gungor S, Ozgor B. Clinical, electrophysiological findings and evaluation of prognosis of patients with Guillain-Barre syndrome. *The Turkish Journal of Pediatrics*. 2019;**61**(2):200-208. DOI: 10.24953/turkjp.2019.02.008
- [14] Walling AD, Dickson G. Guillain-Barre syndrome. *American Family Physician*. 2013;**87**(3):191-197. Available from: <https://www.ncbi.nlm.nih.gov/pubmed/23418763>
- [15] Liu DY, Hollenbacj JR, Gregorin JA, Wynbrandt JH. A case of acute motor sensory axonal neuropathy: A variant of Gillian-Barre syndrome, with possible syndrome of irreversible

- lithium-effectuated neurotoxicity. Case Reports in Medicine. 2020;**2020**:4683507. DOI: 10.1155/2020/4683507
- [16] Pradhan RR, Yadav SK, Yadav SK Sr. Pharyngeal-cervical-branchial variant of Guillain-Barre syndrome in children. Cureus. 2020 Feb;**12**(2):e6983. DOI: 10.7759/cureus.6983
- [17] Wakerley BR, Yuki N. Pharyngeal-cervical-branchial variant of Guillain-Barre syndrome. Journal of Neurology, Neurosurgery, and Psychiatry. 2014;**85**(3):339-344. DOI: 10.1136/jnnp-2013-305397
- [18] Aranyi Z, Kovacs T, Sipos I, Bereczki D. Miller Fisher syndrome: Brief overview and update with a focus on electrophysiological findings. European Journal of Neurology. 2012;**19**(1):15-20. DOI: 10.1111/j.1468-1331.2011.03445.x
- [19] Kuwabara S. Fisher syndrome and Bickerstaff brainstem encephalitis. Brain and Nerve. 2015;**67**(11):1371-1376. DOI: 10.11477/mf.1416200308
- [20] Karam E, Giraldo J, Rodrigues F, Hernandez-Pereira CE, Rodrigues-Morales AJ, Blohm GM, et al. Ocular flutter following zika virus infection. Journal of Neurovirology. 2017;**23**(6):932-934. DOI: 10.1007/s13365-017-0585-1
- [21] Wikan N, Smith DR. Zika virus: History of a newly emerging arbovirus. The Lancet Infectious Diseases. 2016;**16**(7):e119-e126. DOI: 10.1016/S1473-3099(16)30010-X
- [22] Guillier A, Amazan E, Aoun A, Baubion E, Derancourt C. Zika virus infection: A review. Annales de Dermatologie et de Vénéréologie. 2017;**144**(8-9):518-524. DOI: 10.1016/j.annder.2017.05.013
- [23] Zombrano LI, Fuentes-Barahona IC, Soto-Fernandez RJ, Zuniga C, de Silva JC, Rodrigues-Morales AJ. Guillain-Barre syndrome associated with zika virus infection in Honduras, 2016-2017. International Journal of Infectious Diseases. 2019;**84**:136-137. DOI: 10.1016/j.ijid.2019.05.008
- [24] Koppolu V, Shantha RT. Zika virus outbreak: A review of neurological complications, diagnosis, and treatment options. Journal of Neurovirology. 2018;**24**(3):255-272. DOI: 10.1007/s13365-018-0614-8
- [25] Pastrana A, Albarracin M, Hoffmann M, Delturco G, Lopez R, Gil R, et al. Congenital zika syndrome in Argentina: Case series study. Archivos Argentinos de Pediatría. 2019;**117**(6):e635-e639. DOI: 10.5546/aap.2019.e635
- [26] Villamil-Gomez WE, Sanchez-Herrera AR, Hernandez H, Hernandez-Iriarte J, Diaz-Ricardo K, Castellanos J, et al. Guillain-Barre syndrome during the zika virus outbreak in Sucre, Columbia, 2016. Travel Medicine and Infectious Disease. 2017;**16**:62-63. DOI: 10.1016/j.tmaid-2017.03.012
- [27] Rivera-Correa J, de Siqueira IC, Mota S, do Rosario MS, Pereira de Jesus PA, LCJ A, et al. Anti-ganglioside antibodies in patients with zika virus infection-associated Guillain-Barre syndrome in Brazil. PLoS Neglected Tropical Diseases. 2019;**13**(9):e0007695. DOI: 10.1371/journal.pntd.0007695
- [28] Zhang L, Du X, Chen C, Chen Z, Zhang L, Han Q, et al. Development and characterization of double-antibody sandwich ELISA for detection of Zika virus infection. Viruses. 2018;**10**(11):634. DOI: 10.3390/v10110634
- [29] Ferraris P, Yssel H, Misse D. Zika virus infection: An update. Microbes and Infection. 2019;**21**(8-9):353-360. DOI: 10.1016/j.micinf.2019.04.005

- [30] Villamil-Gomez W, Silvera LA, Paez-Castellanos J, Rodriguez-Morales AJ. Guillain-Barre syndrome after Chikungunya infection: A case in Columbia. *Enfermedades Infecciosas y Microbiología Clínica*. 2016;**34**(2):140-141. DOI: 10.1016/j.eimc.2015.05.012
- [31] Al Othman B, Raabe J, Kini A, Lee AG. Update: The Miller Fisher variants of Guillain-Barre syndrome. *Current Opinion in Ophthalmology*. 2019;**30**(6):462-466. DOI: 10.1097/ICU.0000000000000611
- [32] Sudulgunta SR, Sodalgunta MB, Sepehrar M, Khorram H, Bangalore Raja SK, Kothandapani S, et al. Guillain-Barre syndrome: Clinical profile and management. *German Medical Science*. 2015;**13**(16):1-15. DOI: 10.3205/000220.eCollection 2015
- [33] Alberti MA, Povedano M, Montero J, Casasnovas C. Early electrophysiological findings in Fisher-Bickerstaff syndrome. *Neurología*. 2017. pii:S0213-4853(17)30241-4. DOI: 10.1016/j.nrl.2017.05.012
- [34] Doets AY, Jacobs BC, Van Doorn PA. Advances in management of Guillain-Barre syndrome. *Current Opinion in Neurology*. 2018;**31**(5):541-550. DOI: 10.1097/WCO.0000000000000602
- [35] Malhotra A, Zhang M, Wu X, Jindal S, Durand D, Makhani N. MRI findings of optic pathway involvement in Miller Fisher syndrome in 3 pediatric patients and a review of the literature. *Journal of Clinical Neuroscience*. 2017;**39**:63-67. DOI: 10.1016/j.jocn.2016.12.049
- [36] Xu Y, Liu L. Miller-Fisher syndrome associated with unilateral cerebral white matter lesions. *Neurologia i Neurochirurgia Polska*. 2015;**49**(5):344-347. DOI: 10.1016/j.pjnns.2015.07.008
- [37] Illes Z, Blaabjerg M. Cerebrospinal fluid findings in Guillain-Barre syndrome and chronic inflammatory demyelinating polyneuropathies. *Handbook of Clinical Neurology*. 2017;**146**:125-138. DOI: 10.1016/B978-0-12-804279-3.00009-5
- [38] Yepishin IV, Allison RZ, Kaminskas DA, Zagorski NM, Liow KK. Miller Fisher syndrome: A case report highlighting heterogeneity of clinical features and focused differential diagnosis. *Hawaii Journal of Medicine & Public Health*. 2016;**75**(7):196-199. Available from: <https://www.ncbi.nlm.nih.gov/pubmed/27437164>
- [39] Rojas-Garcia R, Gallardo E, Serrano-Munuera C, de Luna N, Ortiz E, Roig C, et al. Anti-GQ1b antibodies: Usefulness of its detection for the diagnosis of Miller-Fisher syndrome. *Medicina Clínica (Barcelona)*. 2001;**116**(20):761-764. DOI: 10.1016/s0025-7753(01)71980-x
- [40] Dimachkie MM, Barohn RJ. Guillain-Barre syndrome and variants. *Neurologic Clinics*. 2013;**31**(2):491-510. DOI: 10.1016/j.ncl.2013.01.005
- [41] Verboon C, Doets AY, Galassi G, Davidson A, Waheed W, Pereon Y, et al. Current treatment practice of Guillain-Barre syndrome. *Neurology*. 2019;**93**(1):e59-e76. DOI: 10.1212/WNL.00000000000007719
- [42] Van Doorn PA. Diagnosis, treatment and prognosis of Guillain-Barre syndrome (GBS). *Presse Médicale*. 2013;**42**(6 Pt 2):e193-e201. DOI: 10.1016/j.lpm.2013.02.328
- [43] Wang Y, Lang W, Zhang Y, Ma X, Zhou C, Zhang HL. Long-term prognosis of Guillain-Barre syndrome not determined by treatment options? *Oncotarget*. 2017;**8**(45):79991-80001. DOI: 10.18632/oncotarget.20620
- [44] Gonzalez-Suarez I, Sanz-Gallego I, Rodriguez de Rivera FJ, Arpa J. Guillain-Barre syndrome: Natural history

and prognostic factors: A retrospective review of 106 cases. BMC Neurology. 2013;**13**:95. DOI: 10.1186/1471-2377-13-95

[45] Teener JW. Miller Fisher's syndrome. Seminars in Neurology. 2012;**32**(5):512-516. DOI: 10.1055/s-0033-1334470

[46] Mwansa H, Obiekezie O, Kaneria S. A case of Miller Fisher syndrome. The American Journal of Medicine. 2019;**132**(6):e591-e592. DOI: 10.1016/j.amjmed.2019.01.014

[47] Bukhari S, Taboada J. A case of Miller Fisher syndrome and literature review. Cureus. 2017;**9**(2):e1048. DOI: 10.7759/cureus.1048