

We are IntechOpen, the world's leading publisher of Open Access books Built by scientists, for scientists

6,900

Open access books available

186,000

International authors and editors

200M

Downloads

Our authors are among the

154

Countries delivered to

TOP 1%

most cited scientists

12.2%

Contributors from top 500 universities



WEB OF SCIENCE™

Selection of our books indexed in the Book Citation Index
in Web of Science™ Core Collection (BKCI)

Interested in publishing with us?
Contact book.department@intechopen.com

Numbers displayed above are based on latest data collected.
For more information visit www.intechopen.com



Low-Vision Rehabilitation in Maculopathy

Giovanni Sato and Roberta Rizzo

Abstract

Maculopathy can have many causes: congenital, hereditary and acquired. The response of a maculopathy is the formation of a scotoma that can be relative or absolute with difficulty or impossibility to read, write and see the normal activities of daily life. The visually impaired person therefore has an insufficient level of visual ability to perform daily activities, work or leisure activities that are usual for individuals of the same age, sex and sociocultural status. A more or less serious low vision and a visual disability are thus created. The visually impaired person is able to use the eccentric visual residue in the preferential retinal network. With visual rehabilitation, a visual capacity lost by the patient is gained, developing eccentric fixation, giving the patient the awareness of his own possibilities to see and use the use of optical and electronic aids.

Keywords: maculopathy, low vision, rehabilitation, preferential retinal locus, neurovision training

1. Introduction

The most frequent maculopathy are age-related macular degeneration, myopic macular degeneration, diabetic edematous and exudative maculopathy, and hereditary macular dystrophy followed in order of frequency by Stargardt Disease, cone dystrophy, cone-rod dystrophy and Best disease. The ability requested from low-vision patients are in the first place to read again (90%) and then recognizing faces, writing, hand working, TV, theater and cinema watching, driving a car, inability to perform the standard daily working activity or hobby and relaxation, inability in the spatial orientation and mobility. The damage induced by AMD leads to a central absolute or relative scotoma of different shape and extension, with subsequent loss or reduction of the fine visual abilities like the reading process.

2. Low-vision rehabilitation in maculopathy: preferential retinal locus (PRL)

The low-vision patient with maculopathy of various origins can recover the visual ability with the presence of a little part of healthy retina called preferential retinal locus (PRL).

PRL is distant in varying degrees from the nonfunctioning fovea.

How to find and locate the PRL? In the presence of an absolute scotoma, the site and the extension of the scotoma must be precisely detected, and it has to be the preferential retinal locus (PRL) [1].

In 1982, Timberlake [1] used the scanning laser ophthalmoscopy (SLO) to do direct retinal perimetry. With SLO, he obtained a map with which the retinal locus was directly observable on a video of the fundus in patients with macular disease.

About the localization of PRL, Guez, Le Gargasson, Rigaudiere and O'Reagan (1993) reported that the PRL was located in 60% of the cases to the left of the visual field scotoma; Sunness et al. [2], Cummings and Rubin [3] in 63%; and Fletcher and Schuchard [4] in 34%. Trauzettel-Klosinski [5] found that in 50% of patients with Stargardt's juvenile maculopathy the eccentric fixation was located above the retinal lesion (below the visual scotoma).

Nilsson et al. [6, 7] studied 20 patients with age-related macular degeneration, an absolute central scotoma and a mean visual acuity of 0.04 (20/475) using scanning laser ophthalmoscopy (SLO) (**Figure 1**) that was used for microperimetry and determination of preferred retinal locus, localized in most patients to the left.

Trying to read with a PRL to the left of the retinal lesion with the scotoma located in the direction of reading has been shown to be very disadvantageous. All 20 patients were trained to use a new PRL located above the macular atrophy, which is better for reading (corresponding to a location below the visual field scotoma)-first by reading the text under simultaneous fixation monitoring and instruction in the SLO and then by reading the printed text, using high magnification (mean $14.3\times$). With training (mean 5.2 h), it increased significantly ($p < 0.001$) the reading speed to 68.3 ± 19.4 words per min. Training of eccentric reading has thus proved to be very successful (**Figure 2**).

Nilsson test is a fundamental in low-vision rehabilitation: a large cross generated by the SLO with the center omitted to accommodate a large letter. The patient is asked to fixate on the center of the cross: the letter is invisible to the patient since it is located in the scotoma. The horizontal line is then moved upwards (or downwards) on the SLO screen step by step, and the patient is instructed to follow it until he can clearly identify the letter (**Figures 3 and 4**) [6].

The horizontal bar of the cross on the SLO screen is then elevated step by step, and the patient is told to follow the moving bar so as to fixate on the center of the cross at all times. This means that the projection of the bar on the retina gradually moves downwards together with the lesion until the projection of the letter on the retina finally becomes visible above the retinal lesion (below the visual field scotoma), as demonstrated in the figure. The horizontal bar moves in one direction on the SLO screen, viewed by the patient, and its projection on the retina in the

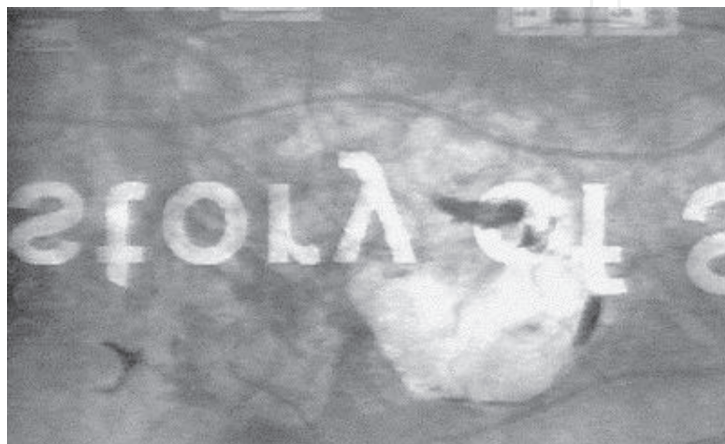


Figure 1.
Scanning laser ophthalmoscopy shows the site of PRL.

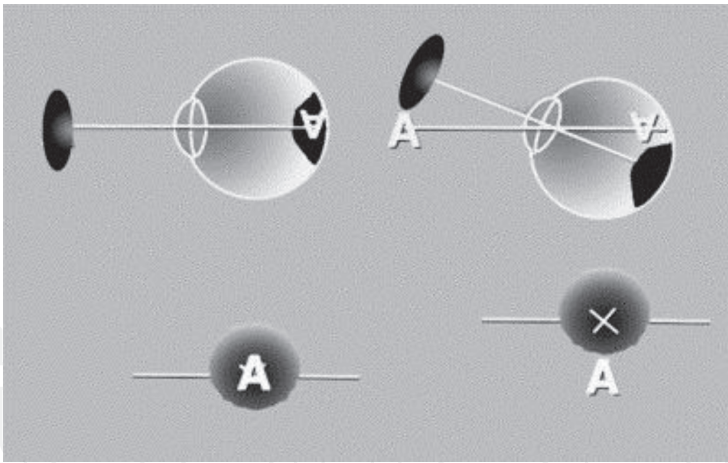


Figure 2.
In AMD with absolute scotoma, the central fixation places a letter in the foveal center, within the macular scar, corresponding to the visual field scotoma (left part of the figure). By looking upwards, moving the retinal lesion downwards and elevating the visual field scotoma, the letter is projected in the healthy retina above the lesion and seen below the scotoma (right part of the figure) [6].

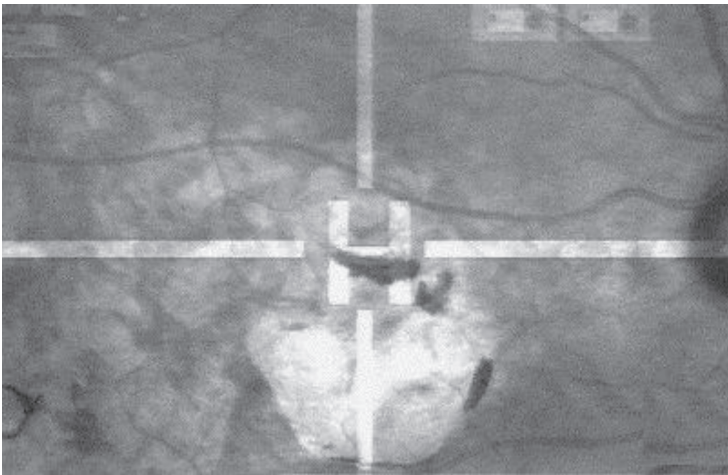


Figure 3.
A large cross is generated in the SLO screen, viewed by the patient: the center of the cross is omitted to accommodate a large-size letter. The patient is told to fixate the center of the cross but the letter placed in the center of the retinal lesion (visual field scotoma) is invisible to the patient.

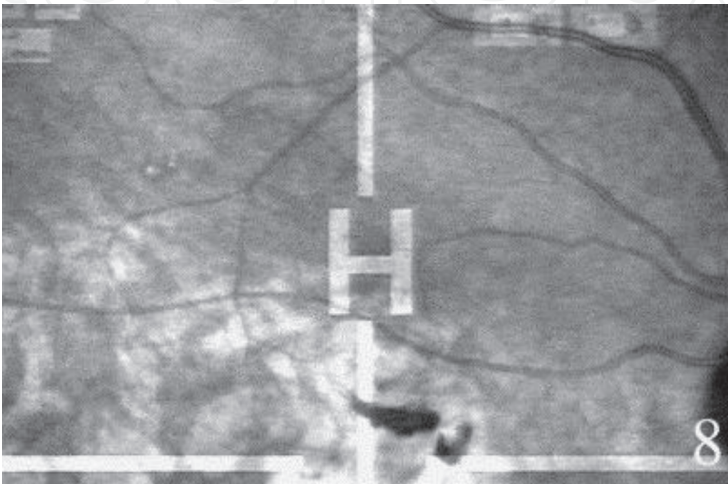


Figure 4.
Nilsson test.

opposite direction. The patient is repeatedly trained to find his new trained retinal locus (TRL).

After the training with SLO [6, 7], reading speed increased in 90% of the patients who accepted and learned eccentric viewing from an average of 9 words/min, which is far from fluent reading, to an average of 68 words/min.

Currently, SLO is not available and the tools to locate the PRL are represented by some type of microperimetry. There are also some low-tech test like Letter Scotometry and California Visual Field Test and Backman procedure [8, 9]. In the Age pre-microperimetry and after the end-age of SLO, the scotoma might be




Figure 5.
Automatic computerized perimetry: absolute scotoma.

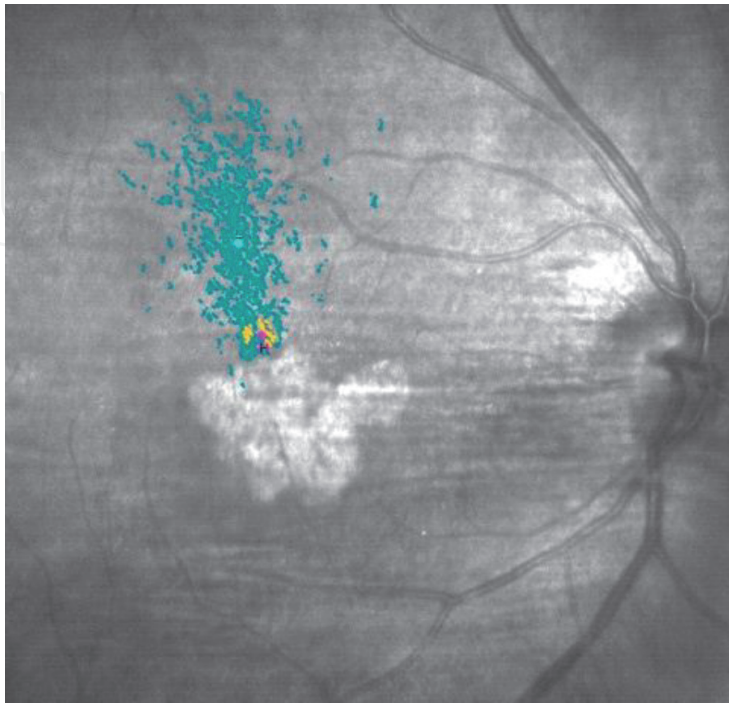


Figure 6.
Superior PRL in patients with loss of central vision in atrophic ARMD.

detected with Visual Field Test (Goldmann and automatic computerized perimetry) (Figure 5).

Microperimetry [10, 11] (MP) or fundus perimetry is a technology that allows the study of retinal sensitivity at different foveal and parafoveal areas as well as eye fixation and provides a direct correlation between anatomical and functional outcomes. Concerning ocular pathology, several studies have confirmed the usefulness of MP for evaluating and analyzing different retinal pathological conditions, such as age-related macular degeneration or glaucoma, and for analyzing the effect of different medical or surgical treatments for these conditions. MP has also been shown to be useful for visual training and rehabilitation using audiobiofeedback [11, 12].

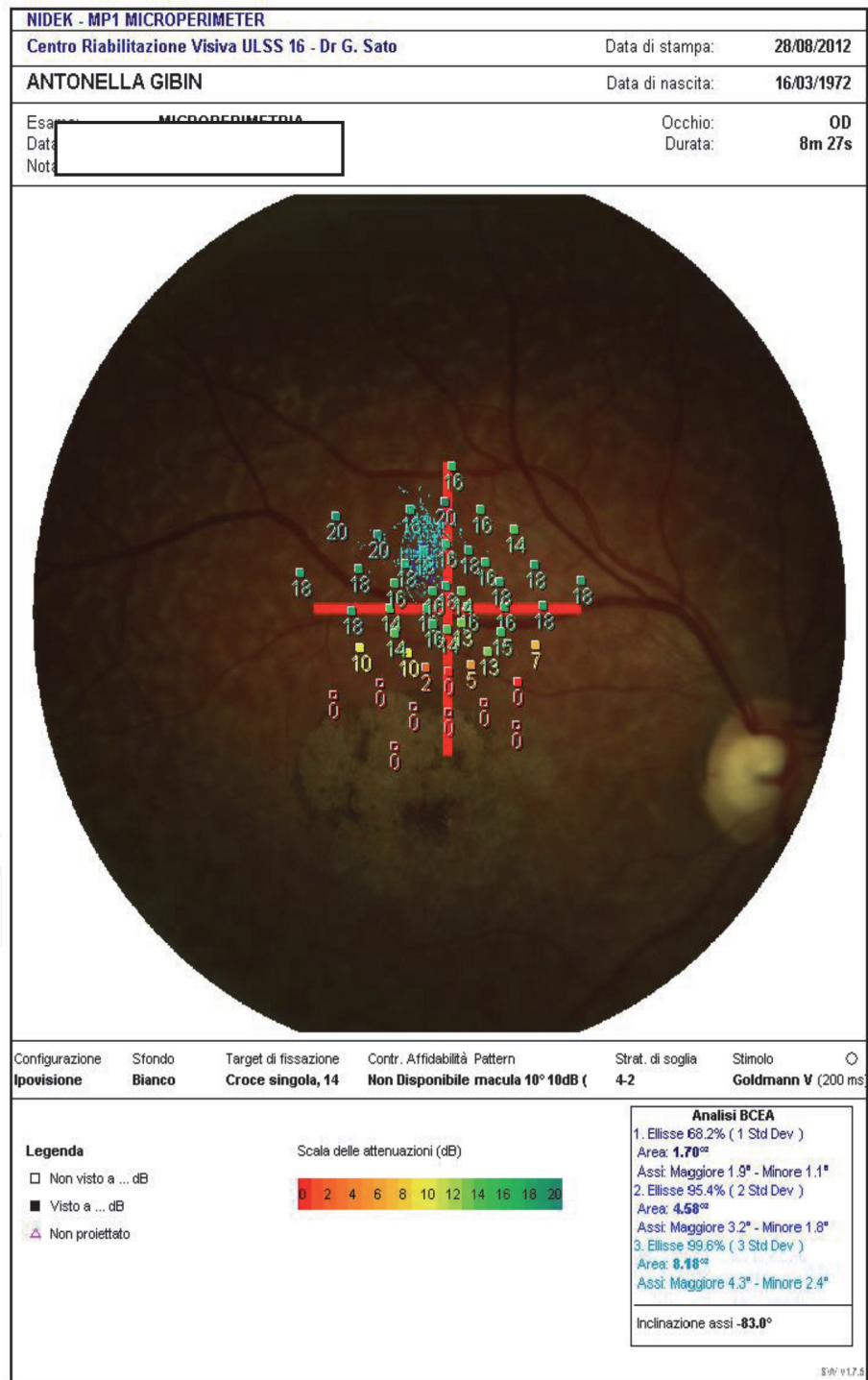


Figure 7.
Superior PRL in Stargardt disease.

MP enables precise assessment of the location and stability of fixation (PRL) in patients with maculopathy and also allows the shifting of PRL in the site of TRL (trained retinal locus) (**Figures 6 and 7**).

The sight deficit area will be more or less extended in correlation to the retinal lesion extension and according to the PRL position (below, left, right and over the lesion) (**Figures 8 and 9**), and the reading difficulties may vary.

The most favorable situation for the reading activities is when the PRL is located over the atrophy.

Visual acuity depends on the site of PRL and from the stability of fixation.

The patient is trained, if he is not able and when the scotoma is more dense, and taught to fixate on the best available portion of the retina, where the PRL is better.

The patient will direct his sight a little above the target object (the words on the book).

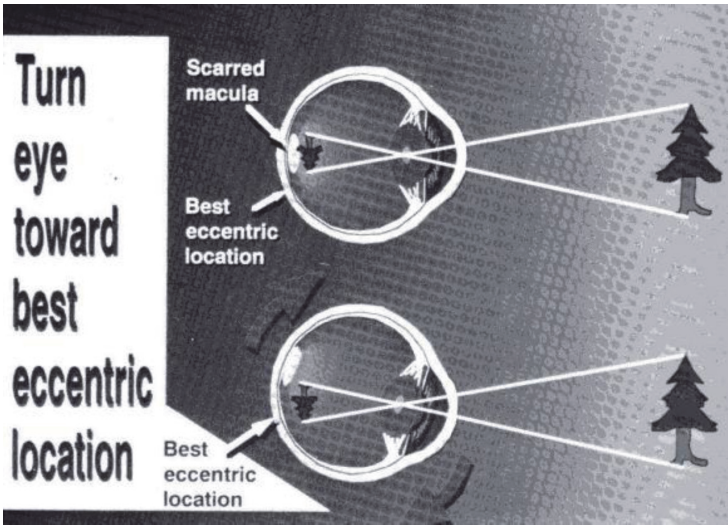


Figure 8.
Best eccentric fixation.

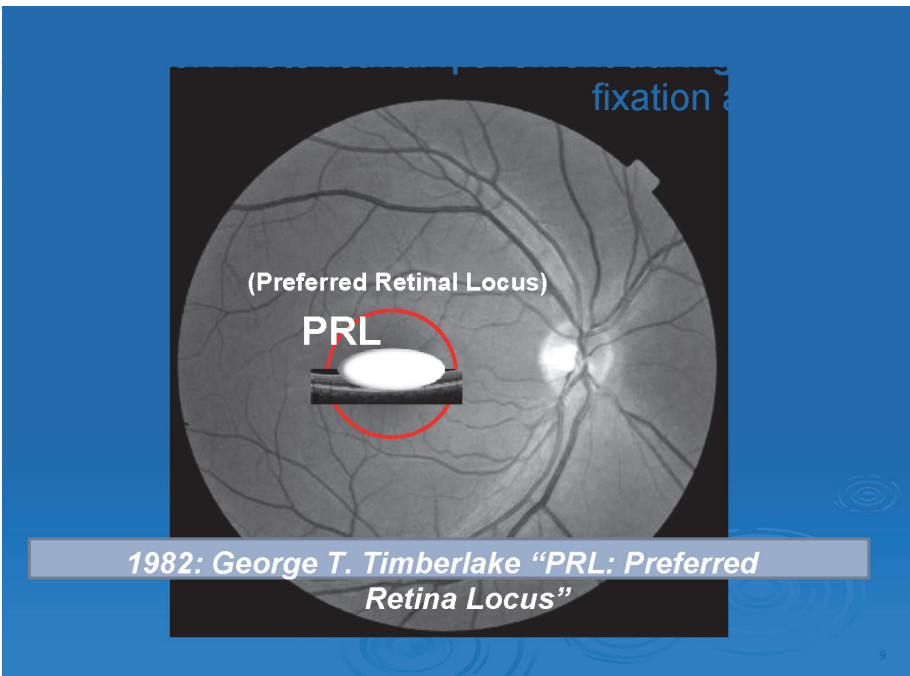
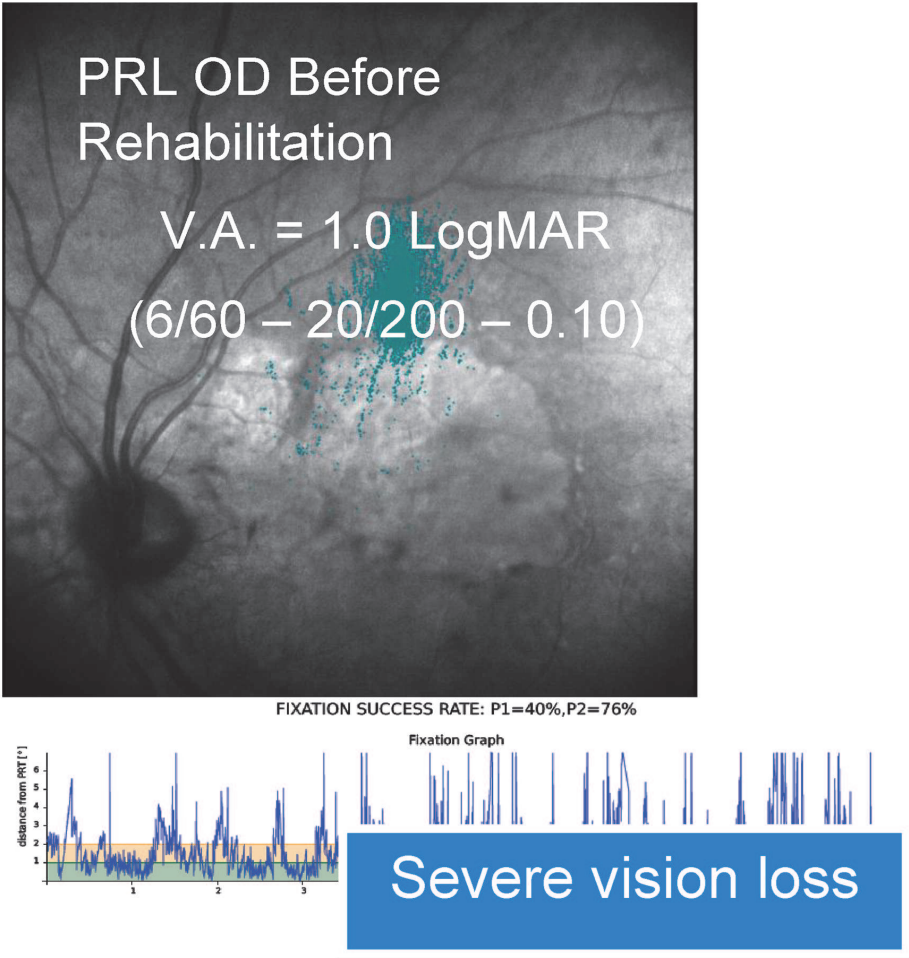
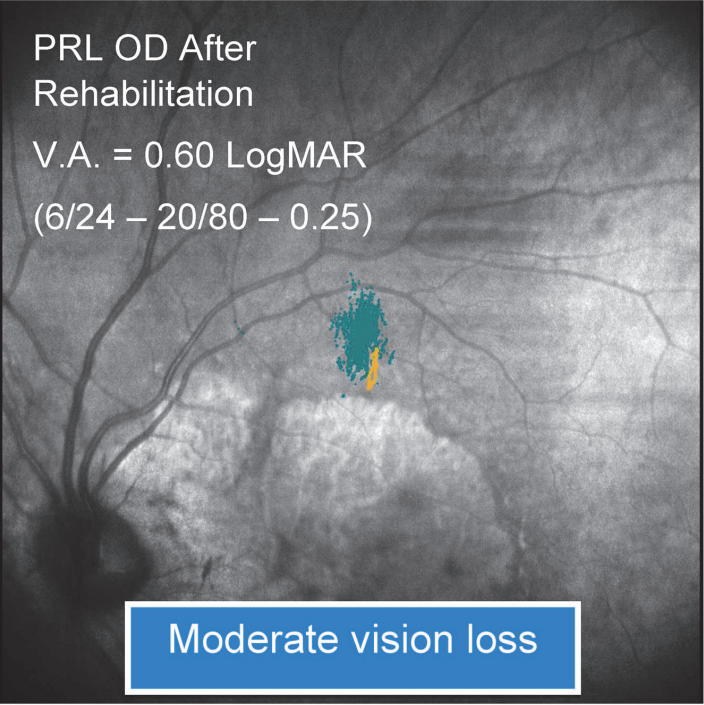


Figure 9.
Preferential retinal locus.



(a)



(b)

Figure 10.
(a) PRL above the retinal atrophy and (b) reduction of the area of ellipse of fixation in °q.

This type of low-vision rehabilitation is usually made with audiobiofeedback with microperimeter (**Figure 10a and b**).

The microperimeter employs an audiobiofeedback to help patients reach a new selected fixation position, with the purpose to increase fixation stability (**Figure 11**).

The examination of the fixation also allows us to assess whether the fixation chosen by the patient is to be strengthened or to be modified per site in order to improve a visual improvement (Retinal Locus Rehabilitated) (**Figure 11**).

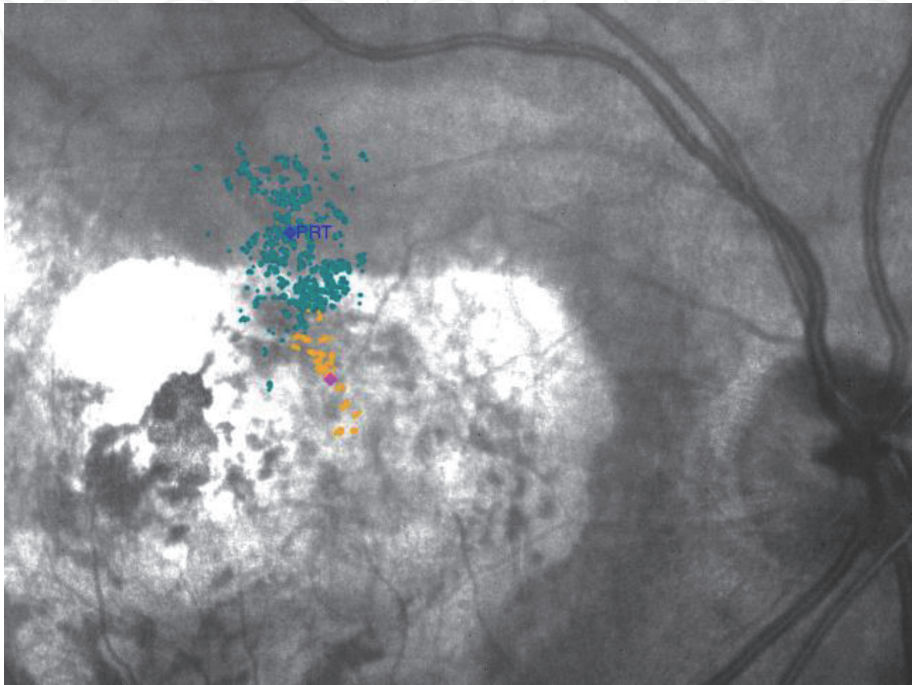


Figure 11.
Stabilization of fixation: a good use of peripheral vision retains a better quality of life.

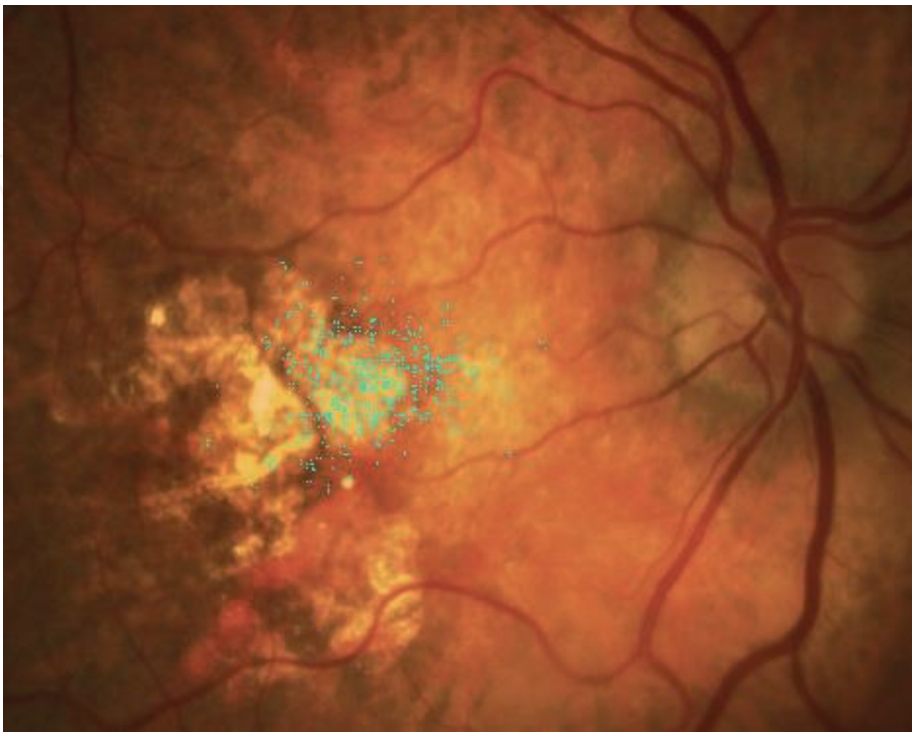


Figure 12.
Unstable eccentric fixation in ARMD.

After the localization of PRL and its level of stability or establishing the necessity to shift the PRL in another side of the nonatrophic retina (**Figure 12**), we must train PRL with reading exercise using the Backmann Formula [9].

Backman formula:

$$\text{TANG } D^{\circ} = X / \text{RD.}$$

$$X = \text{TANG } D^{\circ} \times \text{RD.}$$

where X is the distance on the reading paper between the text and point of fixation decentration; D° is the angle in degrees of the distance between the lesion fovea and the PRL; and RD is the reading distance in centimeters.

According to this formula, customized exercises are printed and the patient will practice with them at the Low Vision Center and then at home (**Figure 13**).

Only after a proper training session can the patient practice reading books or newspapers.

Reading coated paper is more difficult for it has many reflexes, newspapers for the low quality of the paper. The reading position must be ergonomically corrected, with reading stand vertical in front of the patient, with the possibility to put the elbows and with a correct illumination, to avoid dazzling, and to increase the contrast sensitivity, filter lenses may be used.

After the localization of PRL and the stabilization and/or the shifting with MP of the eccentric fixation, we must enhance the visual plasticity using neurovision training [13].

Perceptual learning (PL) paradigms have been successfully employed to treat a series of pathologies affecting central vision. Specifically, training observers for several weeks on basic visual tasks improved their visual abilities, such as visual acuity (VA) and the contrast sensitivity function (CSF) [14, 15]. One of the most efficient approaches consists in a contrast detection task of a low-contrast Gabor patch flanked above and below by high-contrast Gabor patches [15, 16].




Figure 13.
 Reading with aplanatic system.




Figure 14.
Stimulus configuration used in the learning sessions. Only one spatial frequency is shown (i.e., 3 cpd). A central target Gabor is flanked by two high-contrast Gabor patches of the same orientation and spatial frequency. Panels from left to right show the five target-to-flankers distances trained: 2λ , 3λ , 4λ , 6λ and 8λ [13].

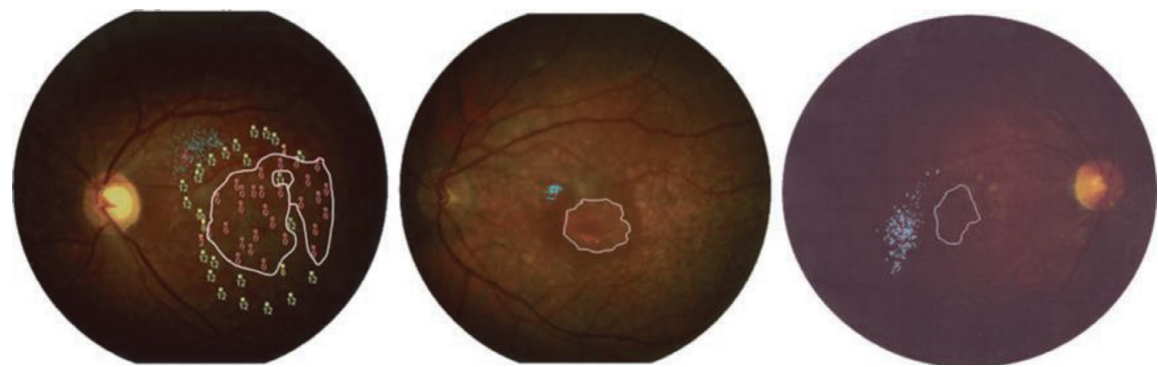


Figure 15.
MP of patients subjected to neurovision training: the blue points represent the dispersion of monocular fixation pattern that indicates the location of PRL, i.e., the part of the retina that is used by the patients during fixation tasks [13].

For foveal stimuli, it has been found that collinear flankers placed at a distance of 3–4 times the wavelength of the target Gabor (λ) enhance target detection, thus producing facilitation (i.e., lower contrast detection thresholds) (**Figure 14**).

Training on lateral interactions is effective in improving the residual visual functions in the periphery of the visual field of patients with maculopathy and eccentric fixation. Perceptual learning procedures produced significant improvements in the trained task and learning transferred to visual acuity and induced a significant improvement of the contrast sensitivity. Perceptual learning effects were retained between 4 and 6 months, suggesting long-term neural plasticity changes in the visual cortex (**Figure 15**).

The successive step in a low-vision rehabilitation patient is the choices of optic and/or visual aids.

3. Reading: physiopathology and rehabilitation of the reading process in low vision

Reading is the technical ability to perceive the words in a sequential way plus text understanding capability. Normal reading is composed of rapid eye movements

(SACCADES), 50 ms; and fixation pauses, 250 ms, saccade (50 ms). In the fixation pauses, there are 50 ms for text comprehension and 200 ms for programming the next saccade.

Normally, the perceptual area or sight field for reading is 3–4 letters to the left and 15 letters to the right of the fixation point. Decoding field or identification area or “VISUAL SPAN”: number of letters of the smallest dimensions that can be recognized during one fixation. The normal sighted have a visual span of 8–12 letters.

The central 10° diameter of the visual field, which accounts for approximately 2% of the total visual field, is mapped onto nearly 50% of the primary visual cortex.

Visual acuity (yellow) decreases rapidly with increasing eccentricity (Figure 16) [5].

A person to have a good reading performance needs a window of visual field of at least:

≥2° to the right of the fixation point.

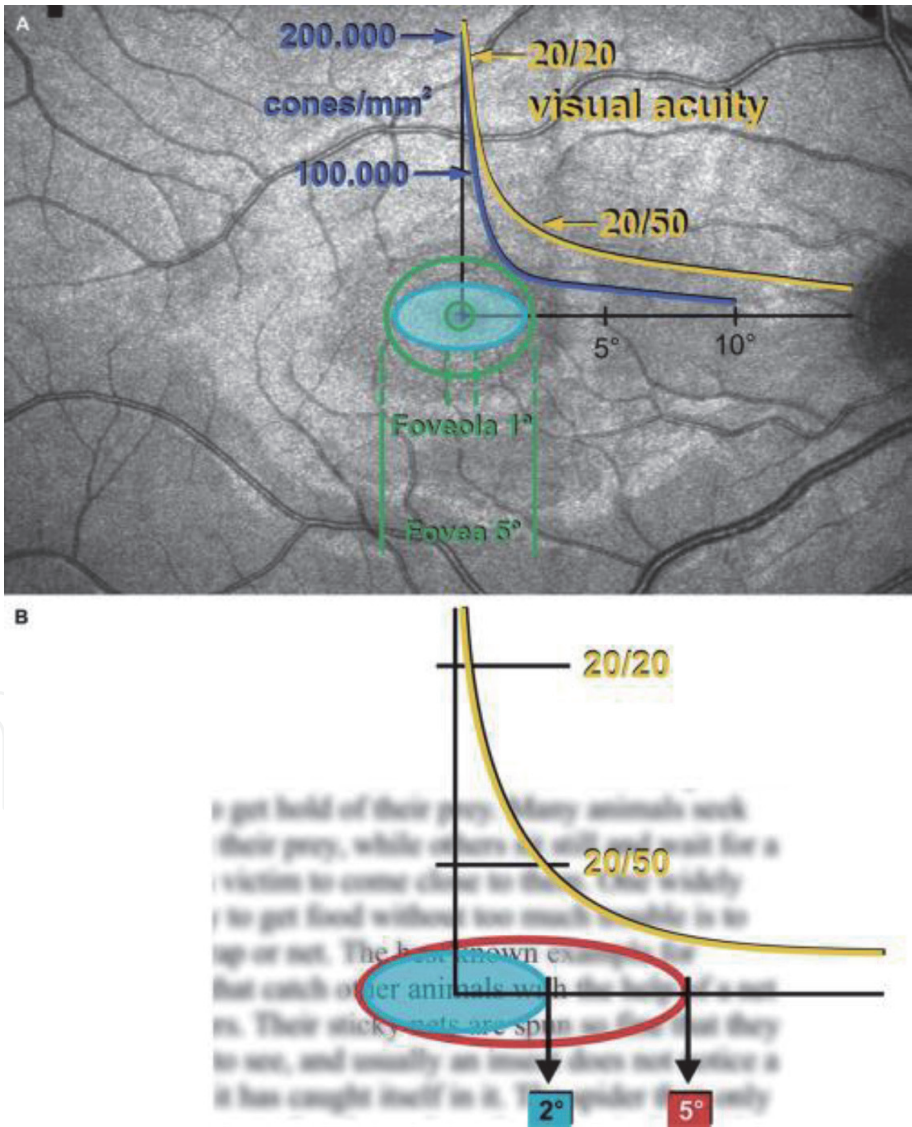


Figure 16. (A) In normal subjects, the visual acuity (yellow) decreases rapidly with increasing eccentricity like the cone density (dark blue). The proportions of the foveola (1°, green circle) and the fovea (5° diameter, green oval) determine the minimum reading visual field (turquoise oval) of 2° to the right and left of fixation and 1° above and below fixation. (B) Because of the visual acuity curve (yellow), only in the minimum reading visual field (turquoise oval) can the text be perceived clearly. The total perceptual span (red oval) is extended up to 5° (or 15 letters) in the reading direction by parafoveal information processing [5].

In a low-vision patient with maculopathy, PRL may be located up, down, in the right or in the left of the macular atrophy.

The more favorable condition to reading is a PRL located above the macular atrophy that coincides with a PRL, seen at the way of visual field it is located below the scotoma. The patient must move the gaze or the eye up, down, right or left with respect to the object to be seen. Scotoma superior to the fixation point (PRL above the retinal lesion) represents the best location for the reading process.

Different conditions of scotoma/PRL location versus reading in low-vision patient are as follows:

1. Dense scotoma to the right of the fixation point: difficulties reading along a line (**Figure 17**).
2. Left of inferior scotomas to the fixation point scotomas: difficulties in finding the next line (**Figures 18 and 19**).

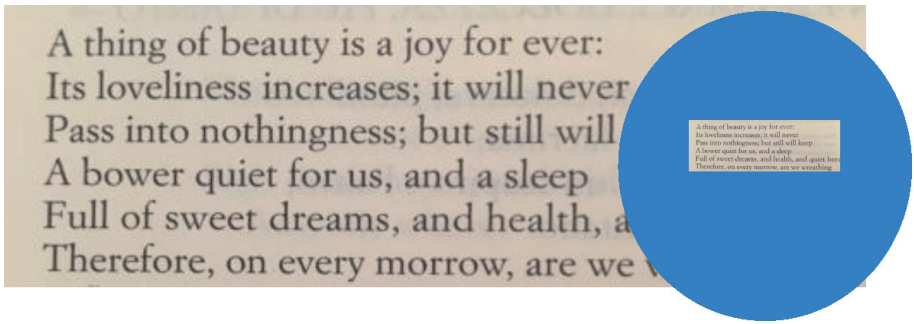


Figure 17.
Dense scotoma to the right of the fixation point: difficulties reading along a Line.

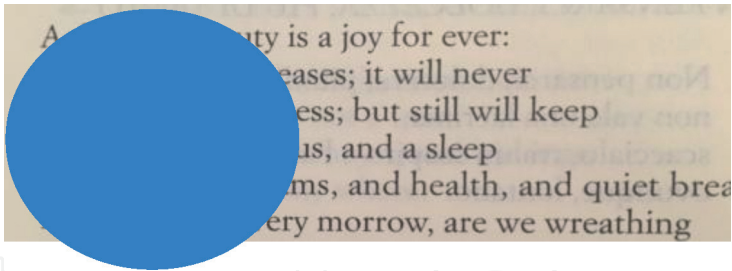


Figure 18.
Left scotomas to the fixation point scotomas: difficulties in finding the next line.

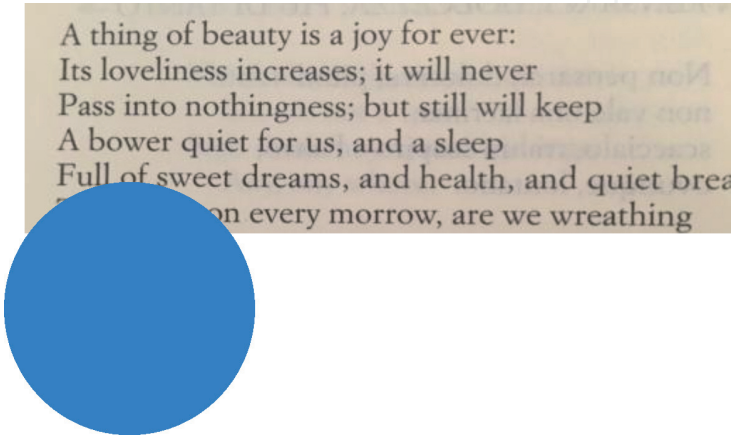


Figure 19.
Inferior scotomas to the fixation point scotomas: difficulties in finding 13 the next line.

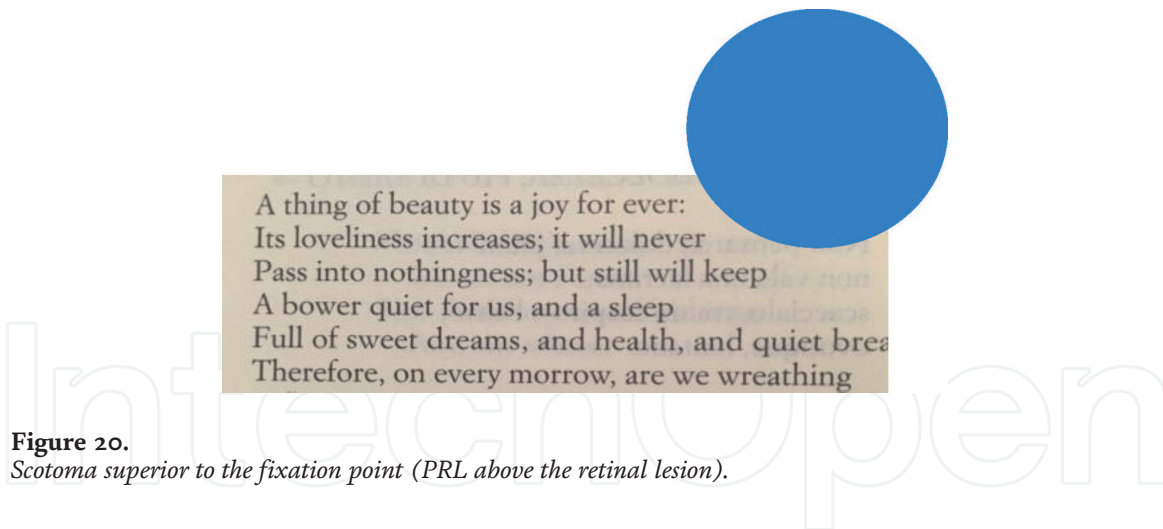


Figure 20.
 Scotoma superior to the fixation point (PRL above the retinal lesion).

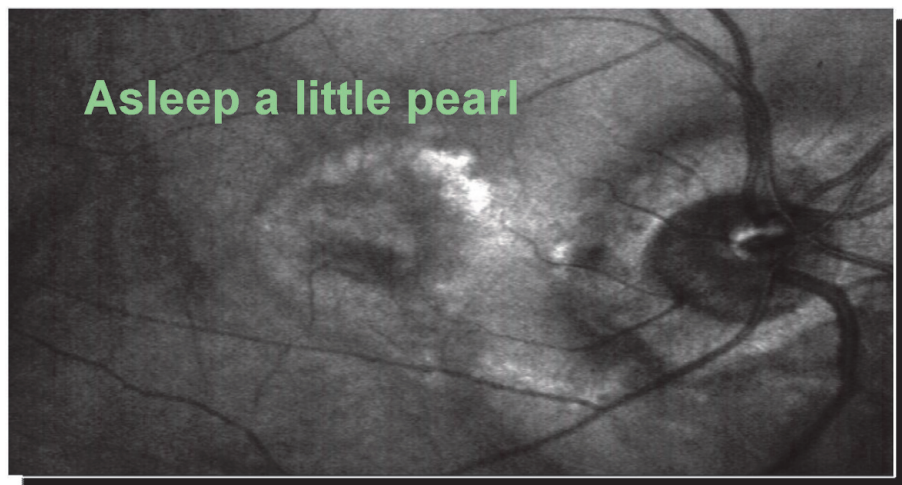


Figure 21.
 PRL above the retinal lesion.

Scotoma superior to the fixation point (PRL above the retinal lesion) represents the best location for the reading process (**Figures 20 and 21**).

4. Optical aids

The purpose of low-vision rehabilitation is to recover the visual skills lost with visual impairment and first of all the possibility to read. After the first phase in which the patient is taught to fix in the PRL and the fixation is stabilized or moved to the best place for vision, we must begin the special training with optical devices [17].

4.1 Microscopic visual aids

Binocular hypercorrective prismatic lenses are used if the residual visual acuity is bilateral. The combination with the prism reduces the convergence effort for the short distance and can be associated with the correction of astigmatism. A filter lens of 450 nm can be used to increase the contrast and reduce the dazzling, and the power arrives to 16 diopters (**Figure 22**).

Monocular hypercorrective aplanatic lens is used if the residual visual acuity is monolateral. It is made of a polycarbonate ring holding two lenses facing each other



Figure 22.
Binocular hypercorrective prismatic lenses.

with the convex curve and the flat side external. In this way, the spherical aberrations are compensated.

The aplanatic monocular lens can have power from 2 up to 10 \times .

It combines an elevated magnifying power with an angle of 48°.

It is made of a polycarbonate ring holding two lenses facing each other with the convex curve and the flat side external.

In this way, the spherical aberrations are compensated (**Figures 23–25**).

When the patient needs to read and write or to use the PC keyboard and other electronic devices, he must use bifocal and trifocal AIDS (**Figure 26**).

An optic aid for intermediate distance is a pin-see (pince-nez) attachable to an eyeglass with a clip-on (**Figure 27**).

We can use also a telemicroscope. Adding a spherical positive lens in front of the Galilean telescope allows the patient to focus in intermediate and near distances, and this helps to work in near distance: reading, writing and other activities (**Figure 28**).

A simple aid may be also a magnifying glass neck-tight (**Figure 29**).

Electronic aids, electronic magnifying device [18–20].



Figure 23.
Monocular hypercorrective aplanatic lens.



Figure 24.
Monocular hypercorrective aplanatic lens.



Figure 25.
Ergonomic table.

4.2 Close Circuit Tele Vision

Close Circuit Tele Vision (CCTV) is used when VA is less than 0.1 and when there is a dense absolute scotoma [21].

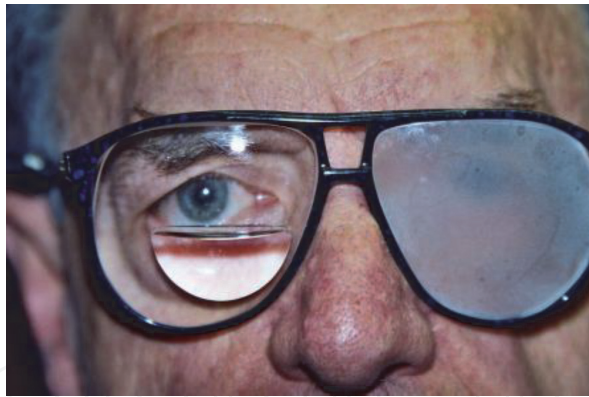

Figure 26.
Bifocal system (writing and reading).



Figure 27.
Pin-see.

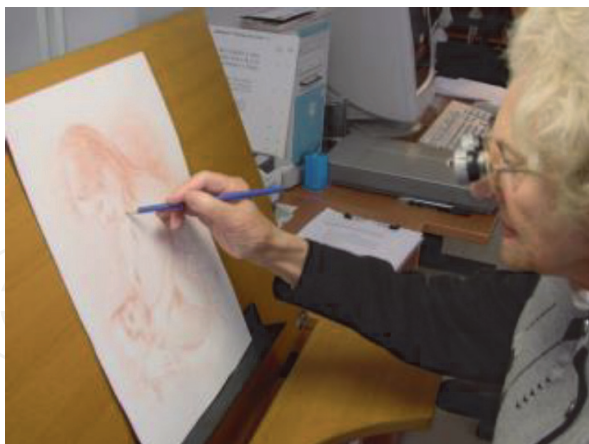

Figure 28.
Telemicroscope.

The use of CCTV restores reading ability and improves quality of life reducing depression in low-vision patients (**Figures 30–33**).

4.3 Aids for far vision: telescopes

4.3.1 Galilean telescope

It is made of a positive lens in the objective and with a negative lens in the eyepiece. It is an afocal optic system with visual field angle of 24° (**Figure 34**).

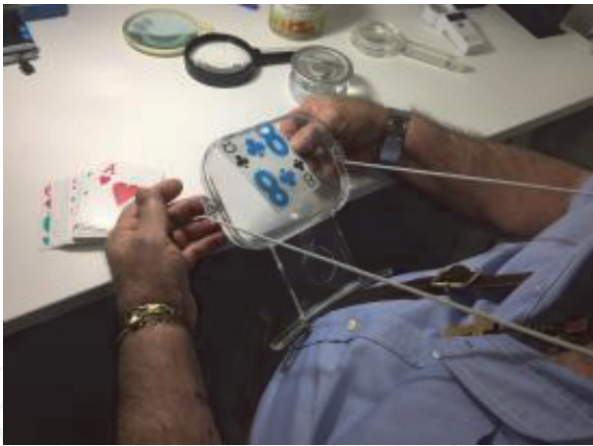

Figure 29.
Magnifying glass neck-tight.

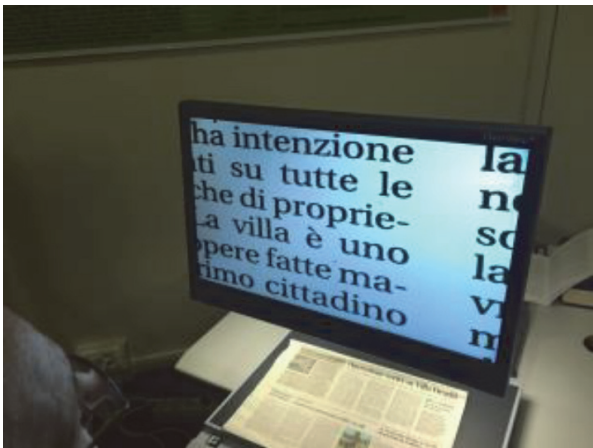


Figure 30.
CCTV.




Figure 31.
Portable CCTV.

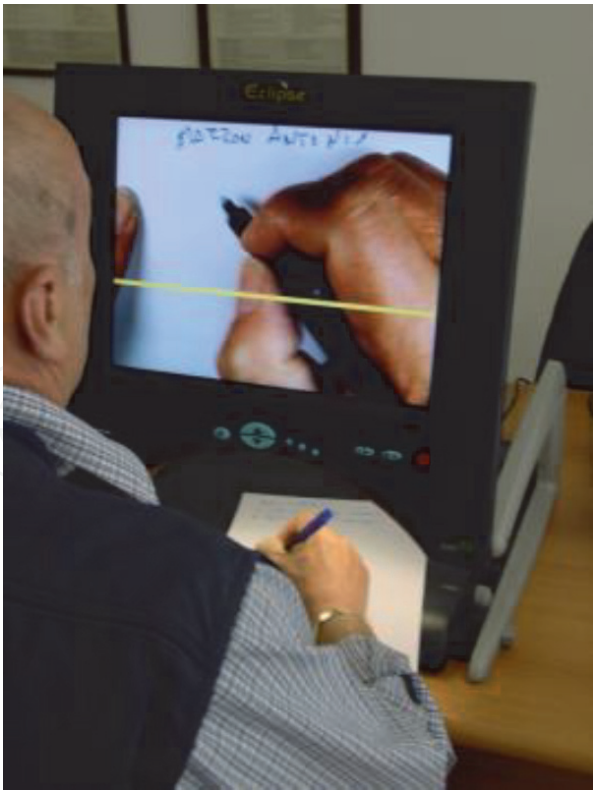

Figure 32.
Writing with CCTV.



Figure 33.
Electronic magnifier with personal computer.



Figure 34.
Galilean telescope.



Figure 35.
Binocular Keplerian telescope.



Figure 36.
Hand Keplerian telescope.

PELLI-ROBSON CONTRAST SENSITIVITY TEST											
0.00	V	R	S	K	D	R	0.15	0.00	V	R	S
0.30	N	H	C	S	O	K	0.45	0.30	N	H	C
0.60	S	C	N	O	Z	V	0.75	0.60	S	C	N
0.90	C	N	H	Z	O	K	1.05	0.90	C	N	H
1.20	N	O	D	V	H	R	1.35	1.20	N	O	D
1.50	C	D	N	Z	S	V	1.65	1.50	C	D	N
1.80	K	C	H	O	D	K	1.95	1.80	K	C	H
2.10	R	S	Z	H	V	R	2.25	2.10	R	S	Z
Right Eye				Binocular				Left Eye			

Figure 37.
Pelli-Robson contrast sensitivity test.

4.3.2 Keplerian telescope

It allows greater far magnification. It is composed of two positive lenses spaced from a distance equal to the sum of the two focal lengths (**Figures 35 and 36**).

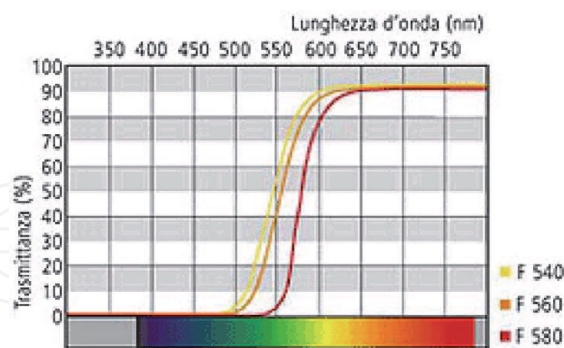


Figure 38.
Transmittance curves of 540–550–580 nm filter lens.



Figure 39.
511-nm filter lenses.



Figure 40.
550-nm filter lenses.



Figure 41.
Filter lenses test.

4.3.3 Filter lens

Low-vision patients in the most part of cases have dazzle, photophobia and a decrease in contrast sensitivity, so it is very important to evaluate the contrast sensitivity with Pelli-Robson test (**Figure 37**) and try out the filter lens starting from 400 nm with different grade of polarization [22–24].

Transmittance is a specific and fundamental feature of a filter lens and refers to the percentage of radiation that can pass through the lens related to the wavelength: a 100% of transmittance means that all the incident radiation on the lens passes through, while a 0% transmittance means that all the radiation is absorbed or reflected (**Figure 38**).

Filter lenses stop some wavelengths and some other get through.

A red-colored lens lets the red wavelength get through. Lenses have the color of the wavelength that passes through them.

For example, a 450-nm yellow lens blocks the wavelengths below 450 nm like the UV (phototoxic) and the Blu Light (diffusion and dazzling) (**Figures 39–41**).

5. Conclusions

Visual rehabilitation of low vision, with its various techniques, being able to recover visual disabilities, is likely to activate neuronal plasticity, which is the ability of neurons to undergo lasting changes in the efficiency of their synaptic transmission, a concept that is owed to Donald Hebb [25] who had the intuition that if two neurons are activated at the same time, the synapses between them are strengthened: “Neurons that fire together wire together.”

In patients with central visual field scotoma, a large part of visual cortex is not adequately stimulated and the low-vision patients must use a new eccentric fixation area on intact peripheral retina: preferred retinal locus (PRL) that functions as a pseudofovea. Functional magnetic resonance imaging (fMRI) has been used to examine whether stimulating this pseudofovea leads to increased activation or altered activation patterns in visual cortex in comparison to stimulating a comparable peripheral area in the opposite hemifield (opposite PRL) [26]. The PRL and OppPRL were stimulated with flickering checkerboard stimuli and object pictures during fMRI measurement and the result shows that stimulation with pictures of everyday objects led to overall larger BOLD (blood oxygen level dependent) responses in V1 visual cortex compared to that evoked by stimulation with

flickering checkerboards. BOLD responses to stimulation of the PRL with object pictures were significantly enhanced in comparison to stimulation of the OppPRL area, and a stable eccentric fixation with the PRL was associated with a higher BOLD signal in visual cortex.

The first step in low-vision rehabilitation in maculopathy is to find the preferential retinal locus (PRL) with microperimetry, stabilize the PRL and, if necessary, shift PRL to a better area useful in reading, using audiobiofeedback. Then, with neurovision training (NVT) and perceptual learning, we can increase the neuronal wire and further improve the visual quality, the contrast sensitivity and the VA.

After these neurovisual rehabilitations, we must consider visual aids for all the visual activity requests from the patient: reading, writing, watching TV, walking, the possibility of orientation and movement, manual work, daily activity like cooking and moving in the house.


The low-vision patient is a person and we must consider all his appearances: visual, physical, psychological and social life [27–30].

Author details

Giovanni Sato* and Roberta Rizzo
Low Vision Rehabilitation Center, Padova, Italy

*Address all correspondence to: giovanni.sato@aopd.veneto.it

IntechOpen

© 2020 The Author(s). Licensee IntechOpen. This chapter is distributed under the terms of the Creative Commons Attribution License (<http://creativecommons.org/licenses/by/3.0>), which permits unrestricted use, distribution, and reproduction in any medium, provided the original work is properly cited. 

References

- [1] Timberlake GT, Mainster MA, Webb RH, Hughes GW, Trempe CL. Retinal localization of scotomata by scanning laser ophthalmoscopy. *Investigative Ophthalmology & Visual Science*. 1982; **22**(1):91-97
- [2] Sunness JS, Applegate CA, Haselwood D, Rubin GS. Fixation patterns and reading rates in eyes with central scotomas from advanced atrophic age-related macular degeneration and Stargardt disease. *Ophthalmology*. 1996;**103**(9):1458-1466
- [3] Cummings RW, Rubin GS. Reading speed and saccadic eye movements with an artificial paracentral scotoma. *Investigative Ophthalmology and Visual Science*. 1992;**33**(Suppl):1418
- [4] Fletcher DC, Schuchard RA. Preferred retinal loci relationship to macular scotomas in a low-vision population. *Ophthalmology*. 1997; **104**(1997):632-638
- [5] Trauzettel-Klosinski S. Rehabilitation for visual disorders. *Journal of Neuro-Ophthalmology*. 2010;**30**(1):73-84
- [6] Nilsson UL, Frennesson C, Nilsson SE. Patients with AMD and a large absolute central scotoma can be trained successfully to use eccentric viewing, as demonstrated in a scanning laser ophthalmoscope. *Vision Research*. 2003 Jul;**43**(16):1777-1787
- [7] Nilsson UL, Nilsson SEG. Rehabilitation of the visually handicapped with advanced macular degeneration. *Documenta Ophthalmologica*. 1986;**62**(1986):345-367
- [8] Bäckman Ö, Inde K. *Low Vision Training*. Malmö, Sweden: Hermods; 1979
- [9] Backman O, Inde K. In: Brogginini M, editor. *Riabilitazione visiva del paziente ipovedente a cura del dott. Fabiano Editore*; 1979
- [10] Cassels NK et al. The use of microperimetry in assessing visual function in age-related macular degeneration. *Survey of Ophthalmology*. 2018
- [11] Molina-Martín A, Pérez-Cambrodí RJ, Piñero DP. Current clinical application of microperimetry: A review. *Seminars in Ophthalmology*. 2018;**33**(5):620-628
- [12] Giacomelli G, Virgili G, Giansanti F, Sato G, Cappello E, Cruciani F, et al. Clinical and microperimetric predictors of reading speed in low vision patients: A structural equation modeling approach. *Investigative Ophthalmology & Visual Science*. 2013;**54**(6): 4403-4408. DOI: 10.1167/iovs.12-10734
- [13] Maniglia M, Pavan A, Sato G, Contemori G, Montemurro S, Battaglini L, et al. Perceptual learning leads to long lasting visual improvement in patients with central vision loss. *Restorative Neurology and Neuroscience*. 2016; **34**(5):697-720
- [14] Polat U, Ma-Naim T, Belkin M, Sagi D. Improving vision in adult amblyopia by perceptual learning. *Proceedings of the National Academy of Sciences of the United States of America*. 2004;**101**(17): 6692-6697
- [15] Polat U, Sagi D. Spatial interactions in human vision: From near to far via experience-dependent cascades of connections. *Proceedings of the National Academy of Sciences of the United States of America*. 1994;**91**(4): 1206-1209
- [16] Casco C, Guzzon D, Moise M, Vecchies A, Testa T, Pavan A. Specificity and generalization of perceptual learning in low myopia.

Restorative Neurology and Neuroscience. 2014;**32**(5):639-653

[17] Virgili G, Acosta R, Bentley SA, Giacomelli G, Allcock C, Evans J. Reading aids for adults with low vision. Cochrane Database of Systematic Reviews. 2018;**4**:CD003303

[18] Morrice E, Johnson AP, Marinier JA, Wittich W. Assessment of the Apple iPad as a low vision reading aid. Eye (London, England). 2017;**31**(6):865-871

[19] Burggraaff MC, van Nispen RM, Knol DL, Ringens PJ, van Rens GH. Randomized controlled trial on the effects of CCTV training on quality of life, depression, and adaptation to vision loss. Investigative Ophthalmology & Visual Science. 2012;**53**(7):3645-3652

[20] Harland S, Legge GE, Luebker A. Psychophysics of reading. XVII. Low-vision performance with four types of electronically magnified text. Optometry and Vision Science. 1998; **75**(3):183-190

[21] Beckmann PJ, Legge GE. Psychophysics of reading—XIV. The page navigation problem in using magnifiers. Vision Research. 1996; **36**(22):3723-3733

[22] Eperjesi F, Fowler CW, Evans BJ. Do tinted lenses or filters improve visual performance in low vision? A review of the literature. Ophthalmic and Physiological Optics. 2002;**22**(1):68-77. Review

[23] Chung ST, Legge GE. Comparing the shape of contrast sensitivity functions for normal and low vision. Investigative Ophthalmology & Visual Science. 2016;**57**(1):198-207

[24] Giacomelli G, Volpe R, Virgili G, Farini A, Arrighi R, Tarli-Barbieri C, et al. Contrast reduction and reading: Assessment and reliability with the reading explorer test. European Journal of Ophthalmology. 2010;**20**(2):389-396

[25] Hebb D. The Organization of Behavior. New York: Wiley & Sons; 1949

[26] Plank T, Frolo J, Brandl-Rühle S, Renner AB, Jägle H, Greenlee MW. fMRI with central vision loss: Effects of fixation locus and stimulus type. Optometry and Vision Science. 2017; **94**(3):297-310

[27] Legge GE, Chung STL. Low vision and plasticity: Implications for rehabilitation. Annual Review of Vision Science. 2016;**2**:321-343

[28] Sagi D. Perceptual learning in vision research. Vision Research. 2011;**51**(13): 1552-1566

[29] Sabel BA, Flammer J, Merabet LB. Residual vision activation and the brain-eye-vascular triad: Dysregulation, plasticity and restoration in low vision and blindness—A review. Restorative Neurology and Neuroscience. 2018; **36**(6):767-791

[30] Colenbrander A, Fletcher DC. Vision rehabilitation. Journal of Neuro-Ophthalmology. 2018;**38**(2):135-137