

We are IntechOpen, the world's leading publisher of Open Access books Built by scientists, for scientists

6,900

Open access books available

186,000

International authors and editors

200M

Downloads

Our authors are among the

154

Countries delivered to

TOP 1%

most cited scientists

12.2%

Contributors from top 500 universities



WEB OF SCIENCE™

Selection of our books indexed in the Book Citation Index
in Web of Science™ Core Collection (BKCI)

Interested in publishing with us?
Contact book.department@intechopen.com

Numbers displayed above are based on latest data collected.
For more information visit www.intechopen.com



Parathyroid Glands and Hyperparathyroidism: A General Overview

Andre Luis Maion Casarim

Abstract

Hyperparathyroidism (HPT) is a clinical condition caused by the increase of parathyroid hormone (PTH) synthesis by the parathyroid glands. PTH has a central and fundamental role in the control of calcium and phosphorus homeostasis. Its action on the kidney, bone, and, indirectly, intestinal cells implies a rapid increase in extracellular calcium flow. This clinical condition may be due to an intrinsic parathyroid disorder or secondary to an imbalance of calcium metabolism in patients with systemic diseases, such as chronic renal failure. The treatment of hyperparathyroidism may be clinical, with the control of calcium, phosphorus, and PTH levels, or surgical, depending on the various forms presented. The purpose of the chapter is to discuss the types of hyperparathyroidism, their relationship with phosphorus and mainly calcium metabolism, as well as the main forms of diagnosis and treatment.

Keywords: hyperparathyroidism, calcium, bone diseases, kidney diseases, parathyroid hormone

1. Introduction

Hyperparathyroidism (HPT) is a pathology caused by the increased synthesis of parathyroid hormone (PTH) by the parathyroid glands. This process can be a consequence of an intrinsic parathyroid disorder or secondary to an imbalance of calcium metabolism in patients with systemic diseases, such as chronic kidney disease (CKD) [1]. PTH plays a central and fundamental role in homeostasis of the control of calcium and phosphorus in the body. Its action on the renal, bone, and, indirectly, intestinal cells implies a rapid increase in the extracellular flow of calcium. This hormone has a short half-life (2–3 min) that quickly mobilizes calcium to the intravascular. It binds to specific membrane receptors on the kidney and bone cells, fibroblasts, chondrocytes, vascular smooth muscle, adipocytes, and placental trophoblasts [2].

2. History

The parathyroid glands were initially discovered in the eighteenth century by Richard Owen, who dissected the parathyroid glands of an approximately 2260 kg

rhino, being reported as “a small, compact yellow glandular body attached to the thyroid at the point where the veins emerge” [3, 4]. However, the definitive discovery of the parathyroid glands in humans was made in 1877 by Swede Ivar Sandström, a medical student at Uppsala University, Sweden, publishing his work in which he wrote: “Almost three years ago I found on the thyroid gland of a dog a small organ, hardly as big as a hemp seed, which was enclosed in the same connective tissue as the thyroid, but could be distinguished therefrom by the light color. Microscopically the examination revealed glandular tissue completely different from that of the thyroid” [4]. After identification in dogs, he finally dissected such structures in human cadavers, calling them *glandulae parathyroidae* (**Figure 1**).

Later, in 1891, Eugene Gley reported symptoms of tetany when these glands were removed during thyroidectomies [5]. At the beginning of the twentieth century, the theory described by Jacob Erdheim emerged, which related hypertrophy of parathyroid tissue as a response to bone disease (osteomalacia and/or cystic fibrous osteitis). This theory was rejected by Felix Mandl in 1925, who performed the first parathyroid surgery in Vienna. Initially, it was believed that bone lesions were a consequence of a parathyroid deficiency, and to prove it, transplantation of cadaveric parathyroid tissues was performed in patients with cystic bone lesions and hypercalciuria. With the procedure unsuccessful, Mandl proceeded with cervical exploration and identified a 21 × 12 × 12 mm parathyroid “tumor,” which was resected, observing the patient’s improvement [6]. Still in 1925, Collip brought a breakthrough in studying the function of PTH, by treating patients with tetany due to parathyroidectomy with relative PTH extract with relative success [4].

The term tertiary HPT came up with Dr. Walter St. Goar, when describing a case report in the New England Journal of Medicine, number 268, in 1963, of a patient with CKD and functional parathyroid autonomy [7]. McPhaul, in 1964, published

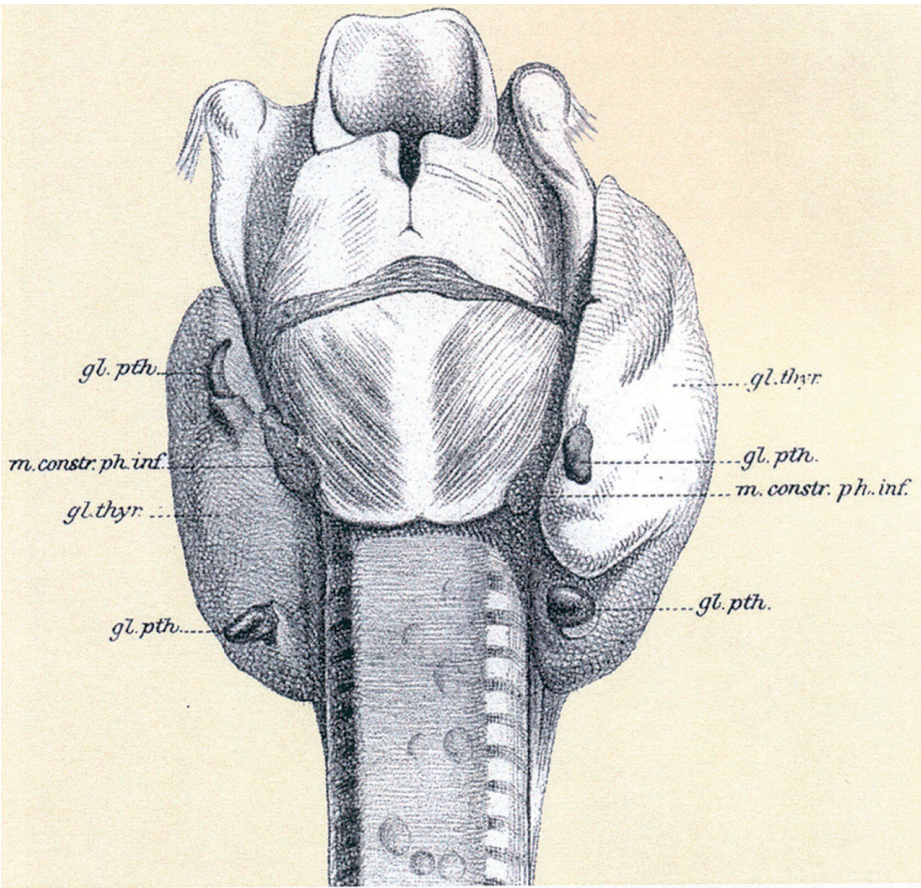


Figure 1.
Original drawing by Ivar Sandström of human parathyroid glandular anatomy [4].

the first surgical success in patients with this clinical condition [8]. Later, in 1968, Davies and colleagues also studied 200 cases of HPT and, of these, obtained 14 cases of tertiary HPT [7].

3. Physiology

PTH plays a central and fundamental role in homeostasis of the control of calcium and phosphorus in the body. It is produced by the parathyroid glands, composed mainly of main cells, and, to a lesser extent, by oxyphil cells [1, 4]. Studies show that, over time, the main cells are replaced by oxyphil cells, which are more sensitive to PTH production, especially in cases of CKD [9, 10]. Its action on renal, bone, and, indirectly, intestinal cells implies a rapid increase in the extracellular flow of calcium (**Figure 2**). This hormone is a peptide with 84 amino acids and a molecular weight of 9500 Da. It has a short half-life (2–3 min) and is broken down into the amino-terminal and carboxy-terminal portions. Only the amino-terminal portion has biological effects on the body, while the carboxy-terminal portion remains inactive. PTH binds to specific membrane receptors in renal and bone cells, fibroblasts, chondrocytes, vascular smooth muscle, adipocytes, and placental trophoblasts [11].

3.1 Effect of PTH on the kidneys

PTH causes an increase in the calcium reabsorption of the glomerular filtrate. This is mainly due to some factors. First, it acts in the loop of Henle, increasing the voltage gradient to allow the passive transport of ionized calcium. Then, it acts on the granular portion of the distal contorted tubules, inducing translocation of preformed calcium channels on the cell surface, increasing the entry of calcium into the vascular lumen. Finally, it also acts on the collecting tubules by changing the activation of the $\text{Na}^+/\text{Ca}^{2+}$ pump [11–13]. In addition, PTH has other effects on kidney cells, such as an increase in phosphate excretion, with increased phosphaturia and decreased serum phosphate; increased bicarbonate clearance with urine

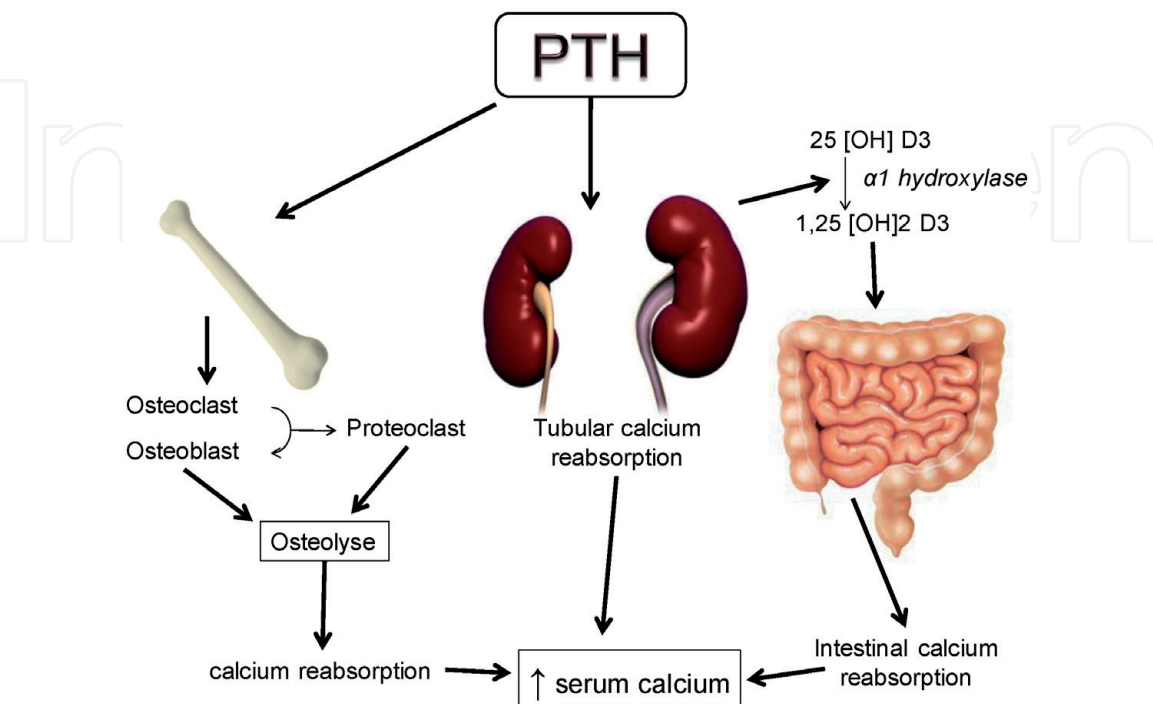


Figure 2.
Mechanisms of action of parathyroid hormone.

alkalinization, resulting from decreased bicarbonate reabsorption in the proximal renal tubules; inhibition of sodium reabsorption in the proximal tubules, with increased clearance of free water and greater urinary flow; and increased activity of vitamin D1 alpha-hydroxylase, with greater production of the active form of vitamin D (calcitriol) [12, 14, 15].

3.2 Effect of PTH on bones

PTH produces both anabolic and catabolic effects, depending on the phases of action. In the early phase, there is a mobilization of calcium from the bones, entering equilibrium with the extracellular fluids. In the late phase, there is an increase in the synthesis of bone enzymes, such as lysosomal enzymes, which promotes bone resorption and remodeling. PTH also inhibits osteoclasts and stimulates bone resorption, leading to an increase in serum alkaline phosphatase and urinary hydroxyproline (markers of osteolysis) [11–13].

3.3 Effect of PTH on the intestine

PTH has no direct action on the intestine. Its effect is due to an increase in the synthesis of calcitriol (activate form of vitamin D) in the kidneys, through the stimulation of the enzyme α 1-hydroxylase. Calcitriol has an effect on increasing serum calcium from the resorption of bowel lumen [11].

4. Embryology and anatomy of the parathyroid glands

Embryologically, the parathyroid glands have an endodermal origin, usually four glands, and rarely may be in number of three, five, or more glands. They develop through the proliferation of the dorsal part of the branchial pharyngeal pouches. Both parathyroid glands migrate to the posterior portion of the thyroid gland, since the lower ones are able to migrate to the thymus or upper mediastinum [4, 12, 16].

4.1 Inferior parathyroid glands

The inferior parathyroid glands originate from the dorsal portion of the third branchial pouch. This branchial pouch differs around the 5th to the 6th week of gestation, when the ventral portion gives rise to the thymus. Around the 7th week of pregnancy, both the thymus and the lower parathyroid loosen the connection with the pharynx, occurring medial and caudal migration of the thymus, bringing together the inferior parathyroid, when, finally, it separates from the thymus. Usually the inferior parathyroid glands are found outside the capsule of the thyroid gland and have a more variable location [17]. Caudal migration close to the thymus explains the lower localization of the inferior parathyroid glands (derived from the third branchial pouch) than the superior parathyroid glands (derived from the fourth branchial pouch). During this process, debris from the parathyroid tissue that can form supernumerary glands may detach. The arterial supply of the inferior parathyroid glands is from the branches of the inferior thyroid artery [17–19].

4.2 Superior parathyroid glands

The superior parathyroid glands originate from the dorsal portion of the fourth branchial pouch. In the 7th week of pregnancy, they lose their relationship with the

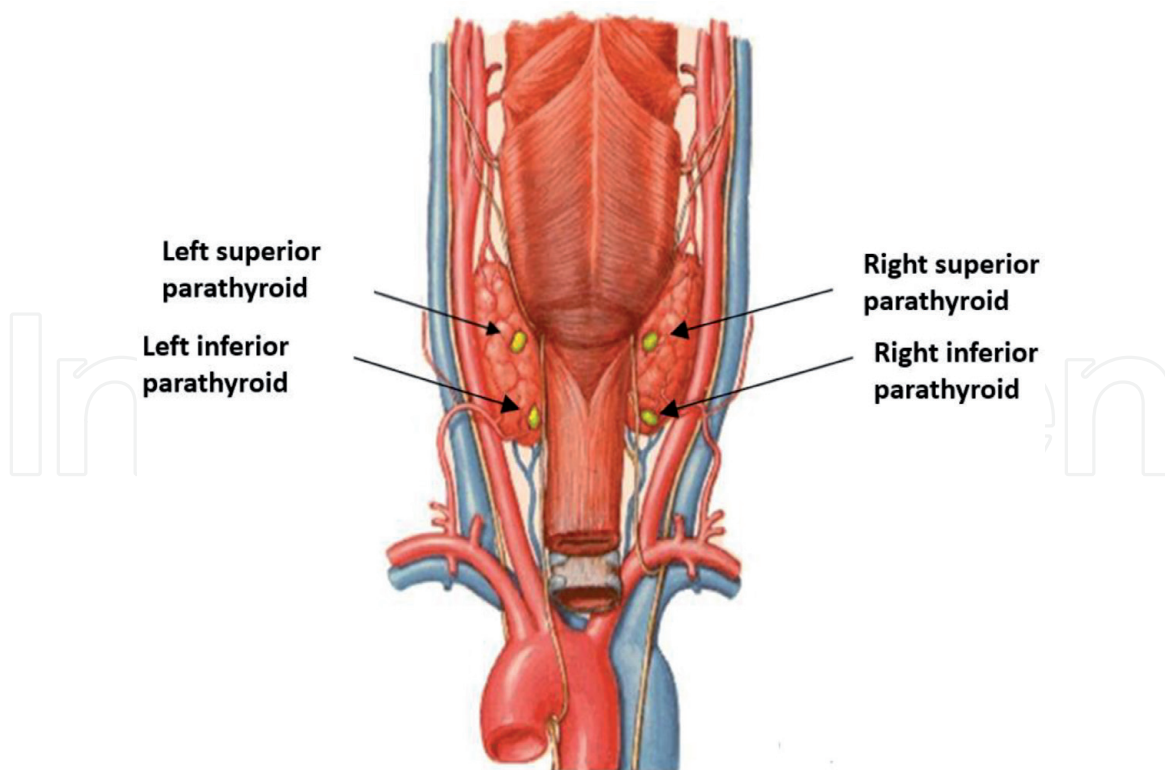


Figure 3.
 Anatomical location of the parathyroid glands, posterior view (modified by F. netter, atlas of human anatomy).

pharynx and adhere to the thyroid gland, which is migrating caudally and medially. This migration occurs to a lesser extent than the migration of the thymus and inferior parathyroid glands, and therefore their locations are more predictable. Superior parathyroid glands are usually located more posteriorly and medially than inferior parathyroid glands, often located on the dorsal surface and outside the thyroid capsule [4, 17–19].

These glands are closely related to the inferior thyroid artery and its intersection with the recurrent laryngeal nerve, although many anatomical variations may occur. The superior parathyroid glands have arterial supply from the branches of the inferior thyroid artery and posterior branches of the superior thyroid artery. The inferior thyroid artery generates branches to supply the parathyroid glands before irrigating the thyroid lobes.

Parathyroid appears in the body as two superior and two inferior glands in approximately 85–90% of the population. In addition, in 10% of the population, they appear as supernumerary, with 5 or more glands, with reports of up to 10 parathyroid glands in a single patient [19].

Figure 3 shows the locations of the parathyroid glands.

5. Clinical presentations

HPT can be divided into primary, secondary, or tertiary.

5.1 Primary HPT

PTH, in these cases, is produced through a stimulus of the parathyroid due to an intrinsic pathology of this gland. In 85% of the cases, a parathyroid adenoma forms, generating an increase in PTH production. However, hyperplasia of the

parathyroid gland (13%) or carcinoma (1%) can occur. Parathyroid adenoma is the most common clinical presentation in primary HPT. It usually presents with only one adenoma, but it can manifest in more than one parathyroid, known as multiple adenomas [20–22]. Structural genetic mutations are associated with the etiology of the adenoma, although it can also occur after exposure to neck irradiation, treatment with lithium, or thiazide diuretics [20, 23]. The consequence is the disorderly overproduction of PTH, increasing osteoclastic activity and therefore raising calcium levels in the body. PTH also stimulates renal calcium reabsorption and acts on the activation of vitamin D, increasing intestinal calcium absorption. Most are asymptomatic; however the patient may develop clinical manifestations. The most frequent consequence of primary HPT is nephrolithiasis that develops in almost 15–20% of cases. Nevertheless, HPT is found in just 5% of patients with nephrolithiasis. Osteoporosis, fibrous osteitis, and peptic disease may be also found in these patients. Neuropsychiatric and neuromuscular disorders such as asthenia, weakness, and mild depression can be found less frequently [24]. In rare presentations, brown tumors may be formed, the etiology of which is associated with the disruption of bone turnover between osteoblastic and osteoclastic activity, resulting in benign bone tumors. Sporadic presentation is more frequent; however, family forms may be associated. The main familial manifestations are multiple endocrine neoplasia (MEN) type I, or Werner's syndrome (HPT, pancreatic tumor and pituitary tumor), and type IIA, or Sipple's syndrome (HPT, medullary thyroid carcinoma and pheochromocytoma), and are associated with the expression of the RET proto-oncogene [24, 25].

Other existing familial forms described are primary neonatal HPT, familial hypocalciuric hypercalcemia, jaw tumor HPT syndrome, and isolated familial HPT [26]. Associated with primary HPT is the parathyroid carcinoma, a rare presentation, less than 1% of cases. It is suspected when there are high levels of serum calcium and PTH and may also have a palpable cervical mass on the thyroid gland topography. HPT in patients, if not treated quickly and efficiently, can progress rapidly to complications secondary to hypercalcemia and may progress to death [20, 26, 27].

5.2 Secondary HPT

Secondary HPT, unlike primary HPT, is a systemic and non-intrinsic pathology of the parathyroid gland, the consequence of which affects the functioning and metabolism of the parathyroid glands. It is the result of a parathyroid response to a tendency of hypocalcemia in order to maintain calcium homeostasis. It occurs due to low calcium absorption and vitamin D deficiency. Hypovitaminosis D is the main cause of secondary HPT in developed countries, in which confinement and low sun exposure occur frequently. As a result, there is a decrease in intestinal calcium absorption and a tendency towards serum hypocalcemia. The feedback mechanism stimulates the parathyroid glands and increases PTH synthesis, mobilizing calcium from the bones to maintain intravascular calcium homeostasis. Another important cause of secondary HPT is CKD, in which the kidney injury generates low calcium reabsorption in the distal renal tubules with consequent hypocalcemia. It is also in the kidney that the conversion of vitamin D (cholecalciferol) to its active form (calcitriol) occurs through the enzyme α 1-hydroxylase. In CKD, this conversion is impaired and shows a consequent decrease in serum calcitriol rates and intestinal calcium absorption. As a result, there is an increase in PTH production and osteoclastic activity to try to normalize serum calcium levels. In advanced cases, there is intense damage to bone health, with osteoporosis, severe bone pain, fibrous osteitis, and even pathological fractures [16, 28, 29]. At the same time, renal injury causes phosphate retention, with an increase in serum inorganic phosphate.

The chronic renal patient with secondary HPT frequently presents with major bone disease, bone pain, itching, cardiovascular disorders, and, in advanced cases, pathological bone fractures [28, 29].

5.3 Tertiary HPT

Tertiary HPT manifests itself through an evolution of secondary HPT. In these cases, the continuous stimulus to the overproduction of PTH leads the autonomy of the parathyroid glands to produce PTH in high amounts. In the case of CKD, many patients undergo kidney transplants, expecting normalization of calcium reabsorption, conversion of vitamin D to its active form (calcitriol), and a consequent drop in PTH levels and normalization of the calcium rates. However, autonomous parathyroid glands maintain PTH overproduction even with renal calcium reabsorption normalized. The main consequence is the increase of the calcium serum levels. Most patients are asymptomatic, although some maintained bone pain and risk of fractures. In these cases, persistent hypercalcemia, chronic renal graft dysfunction, bone disease progression, cardiovascular events, and the risk of developing nephrolithiasis in the transplanted renal graft justify the early treatment of the disease [7, 30].

6. Diagnosis

In HPT, anamnesis and physical examination are of fundamental importance for accurate diagnosis.

Hypercalcemia is the main consequence of the primary HPT. In most cases, the disease is asymptomatic, occupying more than 80% of cases [21, 26, 31]. This condition was introduced after the 1970s, when routine laboratory tests began to be performed in asymptomatic patients [32]. However, they can develop symptoms that usually begin when calcium levels exceed 12 mg/dL and include manifestations in several systems. Neurological disorders manifest with changes in the level of consciousness, confusion, or lack of concentration. Gastrointestinal manifestations, such as nausea, epigastric pain due to peptic disease, or even pancreatitis, can be found. Nephrolithiasis can occur, mainly of repetition, polydipsia or polyuria. Bone pain and pathological fractures are also reported, in addition to brown tumors in the bone skeleton. Cardiovascular manifestations and heart rhythm disorders are also associated with hypercalcemia [33]. We can measure ionized serum calcium or total calcium. The total calcium measurement needs to be adjusted, because much of it is bonded with serum albumin. The formula can be shown in the following: $\text{corrected calcium} = \text{measured total serum calcium in mg/dL} + 0.8 \times (4.0 - \text{patient's serum albumin concentration in g/dL})$ [21]. Vitamin D participates actively in the diagnosis of primary HPT. The Institute of Medicine (IOM) affirms an evidence that the disease is more active when the vitamin D levels are below normal [21, 34]. A variant of primary HPT is the normocalcemic HPT, when presents with levels of PTH above normal and normal levels of serum calcium. The evolution of these cases can be stable, without clinical complications or laboratory alterations, increase the serum calcium concentration, or cause bone, kidney, or cardiovascular impairments [35].

Secondary HPT caused by CKD normally courses with normal or low levels of serum calcium. Thus, the history of CKD, especially dialysis, is fundamental for the diagnostic interpretation. The symptoms are due to bone disease with bone pain that can be of different intensities and pathological fractures with difficulty in movement. The pruritus also is most frequent, especially when the phosphate levels are above the normal.

Laboratory assessment of HPT is essential for diagnosis. Serum measurements of PTH, total serum calcium, ionized fraction of calcium, phosphorus, vitamin D, and alkaline phosphatase should be ordered. PTH will always be increased but to varying degrees. In primary HPT, PTH normally increases from two to four times normal, but it can reach much higher values depending on the severity of the disease. Consequently, serum calcium also rises. Phosphorus levels are normal or low and alkaline phosphatase rises [33]. Very high levels of PTH and calcium raise the hypothesis of parathyroid carcinoma and require a different approach. In secondary HPT there is a high elevation of PTH, commonly reaching the values of 10–20 times higher than normal or above in several cases. Calcium is usually in the normal range or at reduced levels, with hyperphosphatemia occurring in some cases. Due to decreased vitamin D activation in the kidney, there is a decrease in serum calcium due to low intestinal absorption.

In tertiary HPT, the parathyroid glands become autonomous in the production of PTH, despite the improvement in renal function, observed mainly in post-kidney transplant patients [36]. There is not a sufficient decrease in PTH, which remains in the range of 5–10 times greater than normal. Vitamin D levels also tend to normalize, since the absence of kidney damage in the post-transplant patient normalizes the conversion of vitamin D into its active form (calcitriol) and also normalizes the intestinal absorption of calcium. Thus, the mechanisms lead to increased serum calcium concentration [36, 37].

Complementary imaging exams are of great value in therapeutic planning, especially when the surgical approach is programmed [38].

Cervical ultrasonography has an important value, i.e., in trying to locate the enlarged parathyroid glands, although there is difficulty due to the overlying position of the thyroid gland and the fact that it is operator dependent. Also, we need to study the thyroid anatomy and the possibility of thyroid nodules that can be approached at the same time, if surgery is performed [39, 40].

Computed tomography, as well as magnetic resonance imaging of the neck, can also help in locating the altered glands, especially if they are much larger than normal. One of the main exams is parathyroid scintigraphy, as it can functionally reveal parathyroid glands with increased activity through the uptake of ⁹⁹Tc-sestamibi (MIBI) [38, 39]. Even more sensitive and specific than scintigraphy is SPECT/CT with MIBI. This examination has the same physiological foundations as flat scintigraphy; however its fusion with the computed tomography image allows for a much more precise location of the affected parathyroid glands.

Another resource is 4D computed tomography. The mechanism of realization of this exam is based on the arterial supply and venous drainage of the analyzed structure. It helps to differentiate a parathyroid gland from a lymph node or any other structure present in the neck or mediastinal region [38, 40, 41].

7. Treatment

The treatment for HPT may be with clinical management or surgery. However, there are other previous forms of disease control, mainly in primary asymptomatic HPT and secondary HPT in early stages. In asymptomatic cases of primary HPT, clinical follow-up without surgical treatment can be performed in most cases. However, in symptomatic cases with evidence of bone and kidney disease, surgical treatment is preferred [27, 31, 32, 42]. Treatment with bisphosphonates and calcimimetics, such as cinacalcete, is applied in cases of severe hypercalcemia and difficulty in performing surgical treatment in a timely manner [43, 44]. Therapeutic doubt arises in asymptomatic cases, in which initial surgical treatment is often not

indicated. According to the Fourth International Workshop, held in Italy in 2013 [21], surgical indications in asymptomatic patients are reserved for the situations illustrated in **Table 1**.

The surgery performed on primary HPT is, in most cases, resection of the parathyroid affected by the adenoma (85% of cases). The use of intraoperative rapid PTH allows less chance of persistent disease (as in multiple adenomas) or future recurrences [26, 45–47]. In cases of parathyroid hyperplasia in primary HPT, as in multiple endocrine neoplasia, the surgical approach is the subject of much discussion. The possibility of subtotal/partial parathyroidectomy or total parathyroidectomy with autograft of fragments of parathyroid tissue in muscle tissue (forearm, presternal, or deltoid musculature) is described [25, 48]. Although rare, being responsible for less than 1% of cases of primary HPT, parathyroid carcinoma, when clinically suspected, should be treated with special care. Cases of severe hypercalcemia (greater than 14 mg/dL) and high levels of PTH (15–20 times higher than normal) should have parathyroid carcinoma as a diagnostic hypothesis. The recommended treatment is resection of the tumor en bloc with wide safety margins. The complete surgery includes partial thyroidectomy ipsilateral to the affected parathyroid, lymphadenectomy of the central compartment, and thymectomy [49].

In secondary HPT, initial clinical treatment is focused on the control of calcemia and phosphatemia and reduction of factors that stimulate PTH overproduction, as well as avoiding exposure to aluminum. Administration of vitamin D and calcium carbonate is used to try to correct serum calcium levels. Surgical treatment is usually indicated when intact PTH levels exceed 800 pg./mL, or when persistent symptoms such as bone fractures, pain refractory bone, intractable pruritus, brown tumor, and ectopic calcification. The pathology is systemic, and hyperplasia of all parathyroid glands occurs through feedback mechanisms. Therefore, the surgery to be performed can be the total parathyroidectomy with autograft of fragments of parathyroid tissue in the muscle tissue (forearm, presternal, or deltoid musculature) in order to avoid persistent hypoparathyroidism, or subtotal parathyroidectomy, with maintenance of parathyroid tissues to avoid persistent hypoparathyroidism [50–52]. The clinical management of secondary HPT is increasingly available, with acceptable responses, especially in patients who are not candidates for surgical treatment. Calcimimetics, such as cinacalcet, have acceptable results in reducing serum PTH and, mainly, improving the quality of life of chronic renal patients. Tolerability is reasonable, with some side effects, such as nausea, vomiting, and hypocalcemia, which may suspend treatment in some cases [53].

Indication of parathyroidectomy in asymptomatic primary HPT	
1. Serum calcium values	Serum calcium 1.0 mg/dL (0.25 mmol/L) greater than the upper limit of normal
2. Imaging findings	A. Bone mineral density: T-score < –2.5 in the lumbar spine, hip, femur, or distal third of the radius
	B. Vertebral fracture on X-ray, CT, MRI, or bone densitometry
3. Renal factors	A. Creatinine clearance < 60 cc/min
	B. Calciuria 24 h > 400 mg/d (>10 mmol/dL) and increased risk of calculosis by biochemical analysis
	C. Presence of nephrolithiasis or nephrocalcinosis by X-ray, ultrasound, or CT
4. Age	<50 years

Table 1.
Indication of parathyroidectomy in asymptomatic primary HPT [21].

Tertiary HPT occurs in autonomy of parathyroid glands resulting from continuous stimulation of PTH secretion, a consequence of secondary HPT. These cases are better demonstrated after kidney transplantation, when PTH levels are kept high even after treating the cause of secondary HPT, the renal disease. Surgical treatment is indicated due to persistent hypercalcemia, in addition to symptoms that may be associated, such as bone pain, pathological fractures, and intractable pruritus. The surgical approach, as in secondary HPT, can be total parathyroidectomy with autograft of parathyroid fragments in muscle tissue, or subtotal parathyroidectomy [36, 54]. The measurement of intraoperative rapid PTH in cases of secondary and tertiary HPT during surgical treatment is the subject of much current discussion, although it is increasingly accepted in order to avoid new approaches due to recurrent or persistent disease [36, 51, 55, 56].

8. Conclusion

Hyperparathyroidism is an important clinical condition with severe consequences if it is not well diagnosed and treated. Knowledge of calcium metabolism is essential for the correct management of the patient with the disease. Primary hyperparathyroidism, although oligosymptomatic in most patients, should be viewed with magnitude by general practitioners with a basic health approach. The patient with hyperparathyroidism secondary to chronic kidney disease, often with several associated comorbidities, needs the best possible approach, directly influencing his quality of life, improving cardiovascular and osteometabolic status.

Conflict of interest

The author declares no conflict of interest.


Author details

Andre Luis Maion Casarim

School of Medical Sciences, Universidade Estadual de Campinas, Campinas, Brazil

*Address all correspondence to: andre.casarim@yahoo.com.br

IntechOpen

© 2020 The Author(s). Licensee IntechOpen. This chapter is distributed under the terms of the Creative Commons Attribution License (<http://creativecommons.org/licenses/by/3.0>), which permits unrestricted use, distribution, and reproduction in any medium, provided the original work is properly cited. 

References

- [1] Gonçalves MDC, Rodrigues ASS. Cirurgia do hiperparatireoidismo. Revista do Colégio Brasileiro de Cirurgias. 2002;**29**(3):166-176
- [2] Potts J. Chemistry and physiology of parathyroid hormone. Clinical Endocrinology. 1976;**5**:307-315
- [3] Vermeulen AHM. The birth of endocrine pathology: How Erdheim misunderstood parathyroids. Virchows Archiv. 2010;**457**(3):283-290
- [4] Johansson H. The Uppsala anatomist Ivar Sandström and the parathyroid gland. Upsala Journal of Medical Sciences. 2015;**120**(2):72-77
- [5] Sethi N, England JA. Parathyroid surgery: From inception to the modern day. British Journal of Hospital Medicine. 2017;**78**(6):333-337
- [6] Toneto MG, Prill S, Debon LM, Furlan FZ, Steffen N. A história da cirurgia das paratireoides. Revista do Colégio Brasileiro de Cirurgias. 2016;**43**(3):214-222
- [7] Davies DR, Dent CE, Watson L. Tertiary hyperparathyroidism. British Medical Journal. 17 August 1968;**3**(5615):395-399. DOI: 10.1136/bmj.3.5615.395
- [8] McPhaul J, McIntosh D, Hammond W, Park O. Autonomous secondary (renal) parathyroid hyperplasia. The New England Journal of Medicine. 1994;**330**(4):242-248
- [9] Basile C, Lomonte C. The function of the parathyroid oxyphil cells in uremia: Still a mystery? Kidney International [Internet]. 2017;**92**(5):1046-1048. DOI: 10.1016/j.kint.2017.06.024
- [10] Ritter C, Miller B, Coyne DW, Gupta D, Zheng S, Brown AJ, et al. Paricalcitol and cinacalcet have disparate actions on parathyroid oxyphil cell content in patients with chronic kidney disease. Kidney International [Internet]. 2017;**92**(5):1217-1222. DOI: 10.1016/j.kint.2017.05.003
- [11] Mihai R. Parathyroid disease and calcium metabolism. British Journal of Anaesthesia [Internet]. 2000;**85**(1): 29-43. DOI: 10.1093/bja/85.1.29
- [12] Slatopolsky E, Finch J, Denda M, Ritter C, Zhong M, Dusso A, et al. Phosphorus restriction prevents parathyroid gland growth: High phosphorus directly stimulates PTH secretion in vitro. The Journal of Clinical Investigation. 1996;**97**(11):2534-2540
- [13] Lacativa PGS, Patrício Filho PJM, Gonçalves MDC, De FMLF. Indicações de paratireoidectomia no hiperparatireoidismo secundário à insuficiência renal crônica. Arquivos Brasileiros de Endocrinologia e Metabologia. 2003;**47**(6):644-653
- [14] Cozzolino M, Galassi A, Conte F, Mangano M, Di Lullo L, Bellasi A. Treatment of secondary hyperparathyroidism: The clinical utility of etelcalcetide. Therapeutics and Clinical Risk Management [Internet]. 2017;**13**:679-689. DOI: 10.2147/TCRM.S108490. Available from: <http://www.embase.com/search/results?subaction=viewrecord&from=export&id=L616601782%0A>
- [15] Koc H, Hoser H, Akdag Y, Kendir C, Ersoy FF. Treatment of secondary hyperparathyroidism with paricalcitol in patients with end-stage renal disease undergoing hemodialysis in Turkey: An observational study. International Urology and Nephrology [Internet]. 2019;**51**(7):1261-1270. DOI: 10.1007/s11255-019-02175-5
- [16] Pitt SC, Panneerselvam R, Chen H, Sippel RS. Secondary and tertiary

- hyperparathyroidism: The utility of ioPTH monitoring. *World Journal of Surgery*. 2010;**34**(6):1343-1349
- [17] Cordeiro A, Ferraz A. Embriologia e anatomia cirúrgica da glândula tireóide. In: *Tratado de cirurgia de cabeça e pescoço e otorrinolaringologia*. São Paulo: Ateneu; 2001. pp. 543-550
- [18] Kimura E. Embriologia e Histologia das Glândulas Tireoide e Paratireoide. In: *Tratado de Tireoide e Paratireoide*. Rio de Janeiro: Rubio; 2007. pp. 9-25
- [19] Mansberger AR, Wei JP. Surgical embryology and anatomy of the thyroid and parathyroid glands. *The Surgical Clinics of North America* [Internet]. 1993;**73**(4):727-746. DOI: 10.1016/S0039-6109(16)46082-2
- [20] Levine MA. Primary hyperparathyroidism: 7,000 years of progress. *Cleveland Clinic Journal of Medicine*. 2005;**72**(12):1084-1098
- [21] Bilezikian JP, Brandi ML, Eastell R, Silverberg SJ, Udelsman R, Marcocci C, et al. Guidelines for the management of asymptomatic primary hyperparathyroidism: Summary statement from the fourth international workshop. *The Journal of Clinical Endocrinology and Metabolism*. 2014;**99**(10):3561-3569
- [22] Leere JS, Karmisholt J, Robaczynk M, Vestergaard P. Contemporary medical management of primary hyperparathyroidism: A systematic review. *Frontiers in Endocrinology (Lausanne)*. 2017;**8**(APR):1-11
- [23] Cetani F, Saponaro F, Marcocci C. Non-surgical management of primary hyperparathyroidism. *Best Practice & Research. Clinical Endocrinology & Metabolism* [Internet]. 2018;**32**(6):821-835. DOI: 10.1016/j.beem.2018.09.006
- [24] Muñoz-Torres M, García-Martín A. Primary hyperparathyroidism. *Medicina Clínica (Barcelona)*. 2018;**150**(6):226-232
- [25] Guimarães J. Neoplasias endócrinas múltiplas. *Acta Médica Portuguesa*. 2007;**20**(1):65-72
- [26] Walker MD, Silverberg SJ. Primary hyperparathyroidism. *Nature Reviews. Endocrinology* [Internet]. 2018;**14**(2):115-125. DOI: 10.1038/nrendo.2017.104
- [27] Aarum S, Nordenström J, Reihner E, Zedenius J, Jacobsson H, Danielsson R, et al. Operation for primary hyperparathyroidism: The new versus the old order: A randomised controlled trial of preoperative localisation. *Scandinavian Journal of Surgery*. 2007;**96**(1):26-30
- [28] Messa P, Alfieri CM. Secondary and tertiary hyperparathyroidism. *Frontiers of Hormone Research* [Internet]. 2018;**51**:91-108. Available from: <https://www.karger.com/Article/FullText/491041> [Cited: 28 March 2020]
- [29] Pitt SC, Sippel RS, Chen H. Secondary and tertiary hyperparathyroidism, state of the art surgical management. *The Surgical Clinics of North America*. 2009;**89**(5):1227-1239
- [30] Torregrosa JV, Barros X. Manejo de la hipercalcemia tras el trasplante renal. *Nefrología*. 2013;**33**(6):751-757
- [31] Insogna KL. Primary hyperparathyroidism. *The New England Journal of Medicine*. 2018;**379**(11):1050-1059
- [32] Silva BC, Cusano NE, Bilezikian JP. Primary hyperparathyroidism. *Best Practice & Research. Clinical Endocrinology & Metabolism* [Internet]. 2018;**32**(5):593-607. DOI: 10.1016/j.beem.2018.09.004
- [33] Taniegra E. Hyperparathyroidism. *American Family Physician*. 2004;**69**(2):333-339

- [34] Grey A, Lucas J, Horne A, Gamble G, Davidson JS, Reid IR. Brief report: Vitamin D repletion in patients with primary hyperparathyroidism and coexistent vitamin D insufficiency. *The Journal of Clinical Endocrinology and Metabolism*. 2005;**90**(4):2122-2126
- [35] Corbetta S. Normocalcemic hyperparathyroidism. *Frontiers of Hormone Research*. 2018;**51**:23-39
- [36] Casarim ALM, Arcadipane FAMC, Martins AS, Del Negro A, Rodrigues AAN, Tincani AJ, et al. Pattern of intraoperative parathyroid hormone and calcium in the treatment of tertiary hyperparathyroidism. *Otolaryngology–Head and Neck Surgery (United States)*. 2019;**271**(26):1-6
- [37] Yamamoto T, Tominaga Y, Okada M, Hiramitsu T, Tsujita M, Goto N, et al. Characteristics of persistent hyperparathyroidism after renal transplantation. *World Journal of Surgery*. 2016;**40**(3):600-606
- [38] Khan AA, Hanley DA, Rizzoli R, Bollerslev J, Young JEM, Rejnmark L, et al. Primary hyperparathyroidism: Review and recommendations on evaluation, diagnosis, and management. A Canadian and international consensus. *Osteoporosis International* [Internet]. 2017;**28**(1):1-19. DOI: 10.1007/s00198-016-3716-2
- [39] Scattergood S, Marsden M, Kyrimi E, Ishii H, Doddi S, Sinha P. Combined ultrasound and sestamibi scintigraphy provides accurate preoperative localisation for patients with primary hyperparathyroidism. *Annals of the Royal College of Surgeons of England*. 2019;**101**(2):97-102
- [40] Boury S. New methods for parathyroid imaging: Sonography, 4D CT, MRI. *Annales d'Endocrinologie* [Internet]. 2015;**76**(2):148-152. DOI: 10.1016/j.ando.2015.04.001
- [41] Lundstroem AK, Trolle W, Soerensen CH, Myschetzky PS. Preoperative localization of hyperfunctioning parathyroid glands with 4D-CT. *European Archives of Oto-Rhino-Laryngology*. 2016;**273**(5):1253-1259
- [42] Wharry LI, Yip L, Armstrong MJ, Virji MA, Stang MT, Carty SE, et al. The final intraoperative parathyroid hormone level: How low should it go? *World Journal of Surgery*. 2014;**38**(3):558-563
- [43] Marcocci C, Bollerslev J, Khan AA, Shoback DM. Medical management of primary hyperparathyroidism: Proceedings of the fourth international workshop on the management of asymptomatic primary hyperparathyroidism. *The Journal of Clinical Endocrinology and Metabolism*. 2014;**99**(10):3607-3618
- [44] Di Dalmazi G, Giuliani C, Napolitano G. Parathyroid apoplexy following cinacalcet treatment in primary hyperparathyroidism. *Frontiers in Endocrinology (Lausanne)*. 2018;**9**(December):1-6
- [45] Nelson CM, Victor NS. Rapid intraoperative parathyroid hormone assay in the surgical management of hyperparathyroidism. *The Permanente Journal*. 2007;**11**(1):3-6
- [46] Sokoll LJ, Drew H, Udelsman R. Intraoperative parathyroid hormone analysis: A study of 200 consecutive cases. *Clinical Chemistry*. 2000;**46**(10):1662-1668
- [47] Patel KN, Caso R. Intraoperative parathyroid hormone monitoring. Optimal utilization. *Surgical Oncology Clinics of North America* [Internet]. 2016;**25**(1):91-101. DOI: 10.1016/j.soc.2015.08.005
- [48] Balsalobre Salmeron M, Rodriguez Gonzalez JM, Ríos A, Febrero B, Parrilla

Paricio P. Primary hyperparathyroidism associated with MEN 1: Experience in 71 cases. *Cirugía Española*. 2018;**96**(10):627-633

[49] Machado NN, Wilhelm SM. Parathyroid cancer: A review. *Cancers (Basel)*. 2019;**11**(11):1-16

[50] Riss P, Asari R, Scheuba C, Niederle B. Current trends in surgery for renal hyperparathyroidism (RHPT)—An international survey. *Langenbeck's Archives of Surgery*. 2013;**398**(1):121-130

[51] Hiramitsu T, Tominaga Y, Okada M, Yamamoto T, Kobayashi T. A retrospective study of the impact of intraoperative intact parathyroid hormone monitoring during total parathyroidectomy for secondary hyperparathyroidism. *Medicine (United States)*. 2015;**94**(29):1-6

[52] Zhang L, Xing C, Shen C, Zeng M, Yang G, Mao H, et al. Diagnostic accuracy study of intraoperative and perioperative serum intact PTH level for successful parathyroidectomy in 501 secondary hyperparathyroidism patients. *Scientific Reports [Internet]*. 2016;**6**(May):26841. Available from: <http://www.nature.com/articles/srep26841>

[53] Bover J, Ureña P, Ruiz-García C, da Silva A, Lescano P, del Carpio J, et al. Clinical and practical use of calcimimetics in dialysis patients with secondary hyperparathyroidism. *Clinical Journal of the American Society of Nephrology*. 2016;**11**(1):161-174

[54] Dulfer RR, Franssen GJH, Hesselink DA, Hoorn EJ, van Eijck CHJ, van Ginhoven TM. Systematic review of surgical and medical treatment for tertiary hyperparathyroidism. *The British Journal of Surgery*. 2017;**104**(7):804-813

[55] Ohe MN, Santos RO, Kunii IS, Carvalho AB, Abrahão M, das Neves MC, et al. Intraoperative PTH cutoff definition to predict successful parathyroidectomy in secondary and tertiary hyperparathyroidism. *Brazilian Journal of Otorhinolaryngology*. 2013;**79**(4):494-499

[56] Vulpio C, Bossola M, Di Stasio E, Pepe G, Nure E, Magalini S, et al. Intraoperative parathyroid hormone monitoring through central laboratory is accurate in renal secondary hyperparathyroidism. *Clinical Biochemistry [Internet]*. 2016;**49**(7-8):538-543. DOI: 10.1016/j.clinbiochem.2016.01.012