

We are IntechOpen, the world's leading publisher of Open Access books Built by scientists, for scientists

6,900

Open access books available

186,000

International authors and editors

200M

Downloads

Our authors are among the

154

Countries delivered to

TOP 1%

most cited scientists

12.2%

Contributors from top 500 universities



WEB OF SCIENCE™

Selection of our books indexed in the Book Citation Index
in Web of Science™ Core Collection (BKCI)

Interested in publishing with us?
Contact book.department@intechopen.com

Numbers displayed above are based on latest data collected.
For more information visit www.intechopen.com



Facioscapulohumeral Muscular Dystrophy: Genetics and Trials

Robin Warner

Abstract

A complex combination of molecular pathways and cell interactions causes facioscapulohumeral muscular dystrophy (FSHD). Several new therapies pose a promising solution to this disease with no cure. This chapter aims to explain the genetics of facioscapulohumeral muscular dystrophy, and review the current clinical trials for the treatment of FSHD.

Keywords: facioscapulohumeral muscular dystrophy, antisense oligonucleotide, decoy nucleic acid, novel therapies, genetics, trials

1. Introduction

1.1 Epidemiology

Facioscapulohumeral muscular dystrophy (FSHD) is one of the most common muscular dystrophies. Worldwide, its prevalence is up to 6.8 in 100,000 and in the United States, it is about 1 in 20,000. It affects men more than women because estrogens counteract the differentiation impairment of FSHD myoblasts without affecting cell proliferation or survival. Estrogen effects are mediated by estrogen receptor β (ER β), which reduces chromatin occupancy and transcriptional activity of double homeobox 4 (DUX4) [1].

1.2 History

Facioscapulohumeral muscular dystrophy was first described by two French physicians, Louis Landouzy and Joseph Jules Dejerine, in the late 1800s [2]. Their description was based on a family that they had monitored for 11 years. In 1950, Tyler and Stephens described a family from Utah that included 1249 people spanning six generations. All were descendants of an affected individual who had migrated to Utah in 1840. Their findings confirmed the autosomal dominant inheritance pattern of FSHD. Clinical criteria were established by an international consortium in 1991. These criteria were as follows: onset of the disease in the facial or shoulder girdle muscles and sparing of the extraocular, pharyngeal, and lingual muscles and the myocardium, facial muscle weakness in more than 50% of affected family members, autosomal dominant inheritance in familial cases and evidence of myopathic disease from electromyography and muscle biopsy in at least one affected member, without biopsy features specific for alternative diagnoses.

2. Genetics

Facioscapulohumeral muscular dystrophy is caused by the inappropriate expression of an early embryonic transcriptional activator, DUX4, in adult muscle, leading to cell death [3, 4]. The disease is autosomal dominant, although up to one-third of cases involve de novo mutations, so there may not be a family history. About 10% of these sporadic cases are attributed to new mutations and 20% are attributed to mosaicism [2].

The Double Homeobox Protein 4 (DUX4) is the embryonic transcriptional activator responsible for the disease. DUX4 induces changes in the expression of hundreds of genes that impact many interconnected pathways, making a relationship between gene expression and muscle degeneration difficult to discern [2]. Evidence reveals a complex RNA-mediated process that prompts a robust immune attack on myocytes [4]. It is found in embryonic tissues and allows for apoptosis of cells during formation [5–7].

There are two types of FSHD: Type 1 and Type 2. Type 1 results from a contraction of the D4Z4 repeat. Type 2 is due to mutations in silencing proteins. Both cases lead to chromatin relaxation and aberrant expression of the DUX4 gene in skeletal muscle [8]. The entire D4Z4 region is normally hypermethylated (and therefore silenced), but FSHD is characterized by hypomethylation of D4Z4. There are also two polymorphic genes (4qA and 4qB) that are also required to produce the disease. 4qA has the ability to be pathogenic and 4qB does not, so at least one 4qA allele is required to produce FSHD [2].

The 4qA allele contains a promoter region pLAM, which allows for the DUX4 protein to be transcribed. The 4qB allele lacks pLAM, so the protein cannot be produced. Since there are two copies of chromosome 4 in a cell; AA, BB, or AB are possible, but the presence of at least one A allele is required to produce FSHD, regardless of the presence of Type 1 or Type 2 mutations. This makes FSHD a digenic disease, as two mutations are required to produce disease (A-allele plus Type 1 or Type 2 mutations) [8].

2.1 Type 1 FSHD

Type 1 FSHD affects 95% of FSHD patients. It is caused by shortening of the D4Z4 array, which leads to hypomethylation and chromatin relaxation. The D4Z4 array is a 3300 DNA base pair (3.3 kb) long repeat units on the long arm (q) of chromosome 4. Subtelomeric regions of 4q and 10q at both 4q35 and 10q26 contain D4Z4 arrays, but only the locus at 4q35 results in FSHD [8]. There can be 1–100 units of the D4Z4 repeat. FSHD is associated with an array of 1–10 units at 4q35, although cases with 11 or slightly greater have been described. Patients carrying 1–3 units are usually severely affected and often represent new mutations, while patients carrying 4–10 units are typically familial cases [9]. There is an approximate inverse relationship of residual repeat size to the severity of the disease and the age at onset. A high degree of variability of disease expression even in patients with fragments of the same size makes it impossible to predict disease severity and progression in a given individual based on genetics alone.

2.2 Type 2 FSHD

Type 2 FSHD affects 5% of FSHD patients. It is usually caused by a mutation in the epigenetic modifier gene SMCHD1 on chromosome 18, but 20% of FSHD2 patients do not have an identified mutation in the SMCHD1 gene, so the cause of the hypomethylation is unknown. SMCHD1 provides instructions for making

a protein that normally hypermethylates the D4Z4 region. A mutation in this gene leads to haploinsufficiency or dominant negative mutations in SMCHD1 protein, leading to a reduced binding of SMCHD1 protein to the D4Z4 repeat and consequently to a loss of epigenetic marks (methylation) in this region. Some patients with Type 1 mutation can also have a Type 2 mutation, which worsens the disease [10].

3. Clinical manifestations

There is a high degree of variability in phenotype. FSHD1 and FSHD2 are clinically indistinguishable. Patients present most frequently with the inability to lift arms overhead (82%) in the second or third decade of life. About 10% of patients notice facial weakness first, 8% of patients notice ankle dorsiflexion weakness first, and 5% notice pelvic girdle weakness first (these patients are often confused with Limb Girdle Muscular Dystrophy patients). Typically, facial, shoulder, and arm muscles are involved. Facial muscles, including orbicularis oculi and orbicularis oris with asymmetric involvement around the lips can occur. The mechanism of the asymmetry is unknown. Orofacial dysphagia without atrophy of the pharyngeal muscles can also occur. On MRI, tongue atrophy can be seen. The serratus anterior and rhomboids in the shoulder girdle (scapulo-) as well as biceps and triceps in the upper arms (humeral) are commonly involved. There is a lack of contractures around the weak muscles, which is often found in other forms of muscular dystrophy, such as Emery Dreyfus [9].

FSHD typically progresses from the upper to lower extremities. In the lower extremities, it progresses distal (TA, gastrocnemius) to proximal (quadriceps, hamstrings). There is involvement of the core muscles in an asymmetric pattern, including paraspinal muscles and abdominal muscles, leading to lumbar lordosis or camptocormia. The need for wheelchair occurs in 20% of patients in a bimodal distribution. In the severe infantile form with one to three D4Z4 units, the need for a wheelchair occurs in the second decade of life [9]. In other forms, it usually occurs when the patient is over age 50.

A Dutch study of 18% of their FSHD population showed that 74% of patients experienced pain for more than 4 days a month and 58% experienced pain for 4 or more days per week [9]. A French study showed that the cause of pain seemed to be exertion in 91% of patients or faulty posture due to weakness in 74% of patients [9]. Environmental temperature seemed to be a factor in 48% and humidity was a factor in 27% of patients. Pain management techniques, including analgesics, hot baths or showers, and massage provided only temporary relief. About 61% of patients report severe fatigue.

In the infantile form, large deletions resulting in fragments of only one to three D4Z4 repeats occur. Early onset cases are usually sporadic and are occasionally diagnosed as Möbius syndrome. A Japanese study found an association with mental retardation and epilepsy in people with an early onset who are severely affected, although FSHD patients are usually mentally and cognitively normal [11].

3.1 Examination findings

Facial weakness is found in 94% of patients and is demonstrated by decreased brow furrow, inability to close their eyes fully or bury their eyelashes, or the inability to tense their platysma. In the chest wall, examination may reveal pectoral wasting, an exaggerated or inverted axillary crease, and 5% of patients will have

pectus excavatum. Shoulder girdle weakness occurs in 93% of cases and may be demonstrated by flattening of clavicular angle, rounding of shoulders, internal rotation of arms or triple hump sign (**Figure 1**), which is alternating muscle and bony landmarks on arm and shoulder. In the arms, one can see Popeye arm with wasting of biceps and triceps muscles and preservation of distal forearm muscles until late in disease. In the back, there is often lateral winging of the scapula with shoulder abduction or flexion (**Figure 2**). About 67% have ankle dorsiflexion weakness and 50% have pelvic girdle weakness. Patients often have a protuberant abdomen with demonstration of Beevor sign (**Figure 3**), which is asymmetric rise in umbilicus with abdominal tensing [2].

3.2 Cardiorespiratory involvement

About 0–13% of patients have restrictive lung disease due to loss of core strength. One percent of patients in a Dutch study were on nocturnal ventilatory support [12]. Risk factors for respiratory compromise include severe disease with wheelchair confinement, moderate to severe kyphoscoliosis, and presence of pectus excavatum.

Cardiomyopathy is not typical, although preclinical reduction of left ventricular function has been described. Asymptomatic supraventricular arrhythmias occur in ~12% [12]. One study showed one-third of their subjects had right bundle branch block that did not progress over 8 years [12].

3.3 Ocular findings

Orbicularis oculi weakness causes incomplete lid closure (lagophthalmos), can lead to exposure keratitis and corneal scarring [2]. Eye drops, ointments, taping, or patches are not always successful in managing these problems. Peripheral telangiectasias of the retina occur in up to one-fourth of patients. Coats disease is an eye disease that can lead to retinal detachment and blindness. Although it usually occurs in males and is unilateral, in FSHD, it occurs in females and is bilateral. Coats disease affects less than 1% of FSHD patients and more commonly affects those with the smallest number of units (one to three D4Z4 units).

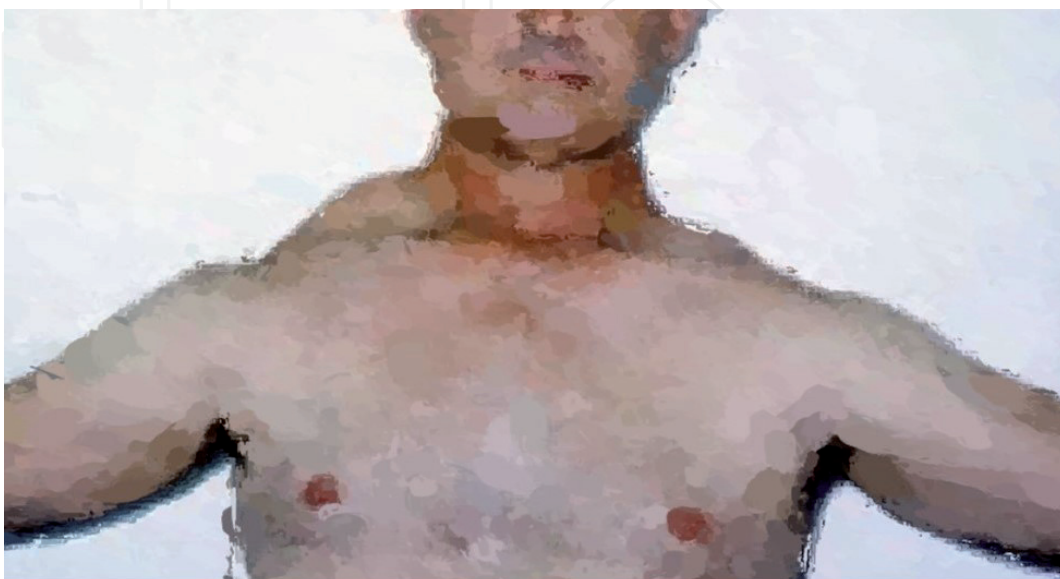


Figure 1.
Triple hump sign: Alternating muscle and bony landmarks of shoulder girdle muscles. Source: Muscular Dystrophy Association.

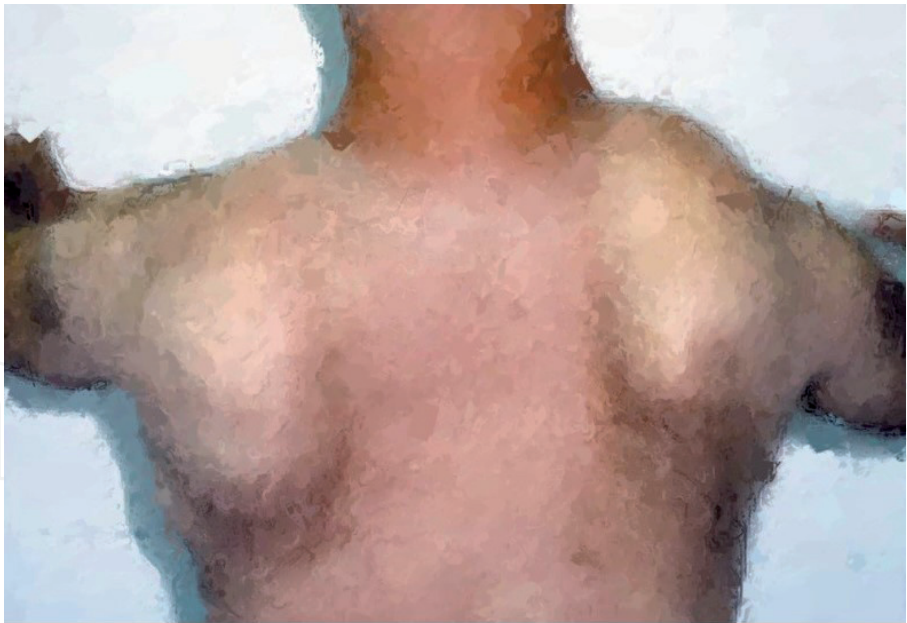


Figure 2.
Winged scapula (right). Source: Muscular Dystrophy Association.

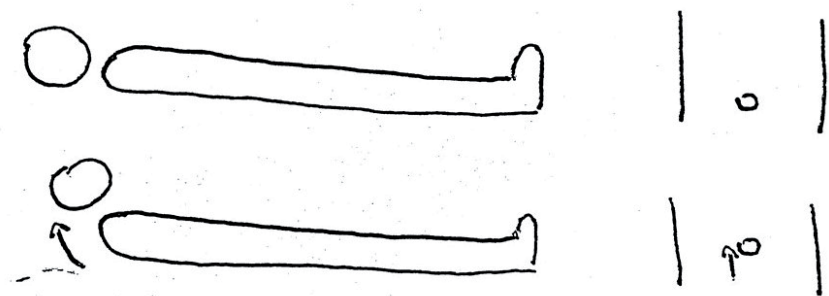


Figure 3.
Beevor sign: When the patients lift their head, their umbilicus displaces up and to the side.

3.4 Ear findings

Asymptomatic loss of high-frequency hearing occurs in up to 65% of patients [2]. Hearing loss, requiring hearing aids affects patients with the smallest number of units (one to four D4Z4 units).

4. Diagnostic testing

Current guidelines call for genetic testing in all patients with clinical FSHD [2]. Labs that perform genetic testing for FSHD first test for D4Z4 contraction using a Southern blot, which has a sensitivity of 93% and specificity of 98%. Normal patients have fragments over 38 kb, but patients with FSHD1 have fragments 10–38 kb, corresponding to 1–10 residual D4Z4 units. If this is negative, then the lab will determine if there is at least one A allele and less than 20% methylation to confirm FSHD2. Genetic testing for SMCHD1 gene is available; however the gene will only be expressed in a low methylation environment [8].

EMG shows small polyphasic motor units (myopathic units) with positive sharp waves or fibrillations. Muscle biopsy shows variation in fiber size, internal myonuclei, degenerating and regenerating myofibers, and increased fibrosis or fatty

replacement of muscle. About 5–30% also show perivascular inflammatory infiltrate, consisting of CD4 or CD8 cells. CK is modestly elevated at less than 10 times the upper limit of normal [2]. An MRI of the thigh shows hamstring involvement more than quadriceps involvement [9].

5. Treatment

Currently, there is no cure for FSHD. Scapulopexy (fascial or synthetic slings are used to improve scapular fixation to the thorax) or scapulodesis (scapula is fixed to the thoracic wall to produce a solid fusion) resulted in significant improvement in function, according to one study. Improvements were measured by ability to abduct the shoulder at 1 year and by patient-perceived improvement in the performance of activities of daily living [13].

Conservative management of FSHD includes referral to speech therapy for compensatory strategies for swallowing, ophthalmology consultation for eye issues, periodic hearing screenings, yearly EKGs, physical therapy, and occupational therapy and bracing. Abdominal supports and binders are useful for truncal weakness. The braces most commonly recommended for foot drop include fixed or hinged ankle-foot orthoses or floor reaction orthoses [9].

A Cochrane review of strength training and aerobic exercise training for muscle disease concluded that moderate-intensity strength training does not produce any benefit or harm in patients with FSHD [14].

5.1 New treatment literature review

5.1.1 Losmapimod

Researchers looked into preventing expression of DUX4 mRNA [15]. Past research showed agonists of the β -2 adrenergic receptor suppress DUX4 expression by activating adenylate cyclase to increase cAMP levels. In vitro experiments demonstrate that clinically advanced p38 inhibitors suppress DUX4 expression in FSHD type 1 and 2 myoblasts. Individual small interfering RNA-mediated knockdown of either p38 α or p38 β suppresses DUX4 expression. p38 inhibitors effectively suppress DUX4 expression in a mouse xenograft model of human FSHD gene regulation. These data support the repurposing of existing clinical p38 inhibitors as potential therapeutics for FSHD.

p38 α and p38 β isoforms each independently contribute to DUX4 expression, so p38 isoform-selective inhibitors may balance efficacy and safety in skeletal muscle.

Losmapimod inhibits enzymes p38 α / β mitogen-activated protein kinases (MAPKs). It has the drawback that p38 kinase inhibition could impair myogenesis by impairing myotube formation. However, GlaxoSmithKline clinical trials showed that losmapimod was generally well tolerated in over 3500 subjects. Two clinical trials of losmapimod for treatment of FSHD are going on at the time this chapter was written. ReDUX4 is evaluating drug efficacy in a randomized controlled phase IIb clinical trial with an estimated study completion date of August 2020. A phase II open-label clinical trial in the Netherlands, with an estimated study completion date of January 2021 is also ongoing at the time this chapter was written.

5.1.2 Resolaris

ATYR1940 (Resolaris) is based on a protein naturally secreted from muscle (resokine) that may act to decrease T-cell activation against muscle [16]. Quality of life and muscle strength of patients treated with Resolaris improved compared

to those on placebo, as assessed by individualized neuromuscular quality of life (INQoL) and manual muscle testing (MMT) scores. The phase 1/2 trial was completed in March of 2017. Results showed no significant trend of worsening in MMT or INQoL assessment scores. However, there was a low sample size of nine with three drop outs. The results of a phase 1b/2 trial of 18 patients with LGMD2B and FSHD showed that Resolaris did not suppress circulating immune cells and muscle function by MMT at 14 weeks improved in 50% of FSHD patients. Participants maintained or increased their MMT and INQoL scores at 24 and 36 weeks.

5.1.3 Decoy nucleic acid

A patented decoy nucleic acid can inhibit DUX4-mediated gene activation by binding to the DNA-binding site of the DUX4 transcription factor protein [17]. AAV vectors carrying in their genome two DUX4-binding sites injected in TA muscles of mice also receiving a DUX4-coding plasmid via electron transfer. In a study, AAV carrying the decoy oligonucleotide (AAV D3) significantly decreases DUX4 target gene (mTm7sf4) expression as compared to a control AAV. They concluded that AAV with a DUX4 decoy can inhibit DUX4 expression, making it a future treatment possibility for FSHD patients. DUX4 mRNAs observed in muscle and stem cells are heterogeneous, which can make targeting difficult.

5.1.4 Antisense oligonucleotides

The use of antisense oligonucleotides (AOs) targeting the DUX4 mRNA may interfere either with transcript cleavage/polyadenylation or intron splicing [18]. DUX4-targeted ASOs suppressed the atrophic FSHD myotube phenotype. The ASOs were not shown to improve the disorganized FSHD myotube phenotype, which could be caused by DUX4c over-expression. Therefore, DUX4c might constitute another therapeutic target in FSHD.

5.1.5 Electrical stimulation

In a French study, electrical stimulation was performed to stimulate weak muscles with the goal of strengthening them [19]. They used an HVPG stimulator (Elettronica Pagani, Performer 982, Class Type BF, S/N:181, 2004, Supplier: Libor Medical Products, Ankara/Turkey, Manufacturer: Medical Expo Paderno Dugnano, Italy), using monophasic wave type (twin peak pulse) via surface electrodes. The pulse frequency of the device was 2–100 Hz, voltage output was 0–500 V, and pulse duration was 200 μ s. They used a pulse frequency of 50 Hz for optimal contraction. Four electrodes were placed around the muscle and current intensity was increased up to significant contraction. Duty cycle was set at 5 seconds on and 10 seconds off, during 10 minutes of stimulation of each muscle. This was applied 3 times a week, for 8 weeks. Electrostimulation was effective in increasing the strengths of the deltoid and quadriceps femoris muscles. Muscle strength of the deltoid was higher in the electrical stimulation group, and the difference between the groups was maintained in the follow-up period ($p < 0.05$). Additionally, the electrical stimulation group presented more obvious overall improvements than the exercise therapy group according to muscle strength, endurance, and timed performance tests.

5.1.6 Ace-083

ACE-083 binds to and inhibits select proteins in the TGF-beta protein superfamily, namely activins and myostatin, which reduce muscle growth [20]. If a person

stops exercising, the muscles gradually reduce in size, due to the function of activins and myostatin, among other factors. Inhibiting the TGF-beta family reduces or slows this muscle breakdown. The researchers looked into whether this can be helpful for patients with Charcot-Marie-Tooth (CMT) or FSHD. However, phase 2 clinical trials showed a lack of efficacy, so Acceleron halted the development of ACE-083 for FSHD. Trials for CMT were not halted.

6. Conclusion

Facioscapulohumeral muscular dystrophy is a disease with no cure; however, current research is promising for a cure in the near future. Technologies in genetic editing show particular promise in the field of muscular dystrophy. Molecular mechanisms of genetic diseases, even those with known mechanisms, are often-times much more complex than initially thought. Discoveries regarding transcription modulators have proven particularly useful in research to find treatments for muscular dystrophies. Given recent advances in these areas, the future appears bright for patients with muscular dystrophy.

Acknowledgements

The author would like to thank the Muscular Dystrophy Association for their support and acknowledge Dr. Dale Lange for inspiring the author's interest in neuromuscular medicine.

My program director, Dr. Dora Leung, was instrumental in defining the path of the author's career. For this, the author is extremely grateful.

Conflict of interest

The author declares no conflict of interest.


Author details

Robin Warner

Department of Neurology, Hospital for Special Surgery, New York, USA

*Address all correspondence to: warnerr@hss.edu

IntechOpen

© 2020 The Author(s). Licensee IntechOpen. This chapter is distributed under the terms of the Creative Commons Attribution License (<http://creativecommons.org/licenses/by/3.0>), which permits unrestricted use, distribution, and reproduction in any medium, provided the original work is properly cited. 

References

- [1] Teveroni E et al. Estrogens enhance myoblast differentiation in facioscapulohumeral muscular dystrophy by antagonizing DUX4 activity. *The Journal of Clinical Investigation*. 2017;**127**(4):1531-1545. DOI: 10.1172/JCI89401
- [2] Stratland JM, Tawil R. Facioscapulohumeral Muscular Dystrophy. *Continuum*. 2016;**22**(6):1917-1931. DOI: 10.1212/CON.0000000000000399
- [3] Tawil R, McDermott MP, Mendell JR, et al. FSHD: Design of natural history study and results of baseline testing. *Neurology*. 1994;**44**:442-446
- [4] Shadle SC et al. DUX4-induced dsRNA and MYC mRNA stabilization activate apoptotic pathways in human cell models of facioscapulohumeral dystrophy. *PLoS Genetics*. 2017;**13**(3):e1006658. DOI: 10.1371/journal.pgen.1006658
- [5] Whiddon JL et al. Conservation and innovation in the DUX4-family gene network. *Nature Genetics*. 2017;**49**(6):935-940. DOI: 10.1038/ng.3846. [Epub: 01 May 2017]
- [6] Hendrickson PG et al. Conserved roles of mouse DUX and human DUX4 in activating cleavage-stage genes and MERV1/HERV1 retrotransposons. *Nature Genetics*. 2017;**49**(6):925-934
- [7] De Iaco A et al. DUX-family transcription factors regulate zygotic genome activation in placental mammals. *Nature Genetics*. 2017;**49**(6):941-945
- [8] Tawil R, Van Der Maarel SM. Facioscapulohumeral muscular dystrophy. *Muscle and Nerve*. 2006;**34**:1-15
- [9] Pandya S, King WM, Tawil R. Facioscapulohumeral dystrophy. *Physical Therapy*. 2008;**88**(1):105-113. DOI: 10.2522/ptj.20070104
- [10] Mason AG et al. SMCHD1 regulates a limited set of gene clusters on autosomal chromosomes. *Skeletal Muscle*. 2017;**7**(1):12. DOI: 10.1186/s13395-017-0129-7
- [11] Funakoshi M, Goto K, Arahata K. Epilepsy and mental retardation in a subset of early onset 4q35-facioscapulohumeral muscular dystrophy. *Neurology*. 1998;**50**(6):1791-1794. DOI: 10.1212/wnl.50.6.1791
- [12] van Dijk GP, van der Kooi E, Begin A, et al. High prevalence of incomplete right bundle branch block in facioscapulohumeral muscular dystrophy without cardiac symptoms. *Functional Neurology*. 2014;**29**(3):159-165
- [13] Orrell RW, Copeland S, Rose MR. Scapular fixation in muscular dystrophy. *Cochrane Database of Systematic Reviews*. 2010;(1). Artical number: CD003278. DOI: 10.1002/14651858.CD003278.pub2
- [14] van der Kooi EL, Lindeman E, Riphagen I. Strength training and aerobic exercise training for muscle disease. *Cochrane Database of Systematic Reviews*. 2005;**1**:CD003907
- [15] Oliva J, Galasinski S, Richey A, Campbell AE, Meyers MJ, Modi N, et al. Clinically advanced p38 inhibitors suppress DUX4 expression in cellular and animal models of facioscapulohumeral muscular dystrophy. *The Journal of Pharmacology and Experimental Therapeutics*. 2019. DOI: 10.1124/jpet.119.259663
- [16] Gershman A, Chiang K, Do M, Abbink E, Harbers V, Audebert C,

et al. A randomized, double-blinded, placebo-controlled, multiple ascending dose study to evaluate the safety, tolerability, pharmacokinetics, immunogenicity, and biological activity of ATYR1940 in adult patients with facioscapulohumeral muscular dystrophy (FSHD). *Neuromuscular Disorders*. 2016;**26**(Supplement 2):S167. DOI: 10.1016/j.nmd.2016.06.293

[17] Dumonceaux J, Voit T, Mariot V. Treatment of Facioscapulohumeral Dystrophy. 2019. Available from: <http://www.freepatentsonline.com/y2018/0016577.html>

[18] Anseau E, Vanderplanck C, Belayew A. Antisense oligonucleotides used to target the DUX4 mRNA as therapeutic approaches in facioscapulohumeral muscular dystrophy (FSHD). *Genes (Basel)*. 2017;**8**(3):93. DOI: 10.3390/genes8030093

[19] Kiliç M, Yildirim SA, Tan E. The effects of electrical stimulation and exercise therapy in patients with limb girdle muscular dystrophy: A controlled clinical trial. *Neurosciences*. 2015;**20**(3):259-266. DOI: 10.17712/nsj.2015.3.201501097

[20] Statland J, Bravver E, Karam C, Elman L, Johnson N, Joyce N, et al. Results for a dose-escalation phase 2 study to evaluate ACE-083, a local muscle therapeutic, in patients with facioscapulohumeral muscular dystrophy. *Neuromuscular Disorders*. 2018;**28**(Supplement 2):S140. DOI: 10.1016/j.nmd.2018.06.413