

We are IntechOpen, the world's leading publisher of Open Access books Built by scientists, for scientists

6,900

Open access books available

185,000

International authors and editors

200M

Downloads

Our authors are among the

154

Countries delivered to

TOP 1%

most cited scientists

12.2%

Contributors from top 500 universities



WEB OF SCIENCE™

Selection of our books indexed in the Book Citation Index
in Web of Science™ Core Collection (BKCI)

Interested in publishing with us?
Contact book.department@intechopen.com

Numbers displayed above are based on latest data collected.
For more information visit www.intechopen.com



Glucagonoma Masquerading as a Mucinous Cancer of the Ovary: Lessons from Cell Biology

Gwo Yaw Ho, Sumitra Ananda, Cassandra J. Vandenberg, Orla McNally, Jeanne Tie, Kylie Gorringer, David Bowtell, Jan Pyman, Matthew J. Wakefield and Clare L. Scott

Abstract

High-grade mucinous ovarian cancer (HGMOC) is often a misnomer as the majority of cases are metastatic disease with a gastro-intestinal origin. The standard platinum-based ovarian cancer (OC) chemotherapy regimens are often ineffective, and there are insufficient data to support the use of colorectal cancer (CRC) chemotherapy regimens due to the rarity of HGMOC. We described a cohort of four consecutive suspected HGMOC cases treated at the Royal Women's Hospital, Melbourne in 2012. Two cases were treated as primary MOC, whereas the other two were considered to be metastatic CRC based on histopathological and clinical evidence. From the RNAseq analysis, we identified two cases of HGMOC whose gene expression profiles were consistent with mucinous epithelial OC, one case that was treated as metastatic CRC with gene expression profile correlated with CRC and one case with neuroendocrine (NET) gene expression features. Interestingly, glucagon was over-expressed in this tumor that was subsequently confirmed by immunohistochemistry. These findings suggest a rare glucagonoma-like NET appendiceal tumor that had metastasized to the surface of ovary and were unresponsive to CRC chemotherapy regimens. In summary, a carefully curated panel of expression markers and selected functional genomics could provide diagnosis and treatment guidance for patients with possible HGMOC.

Keywords: mucinous ovarian cancer, glucagonoma, genomic

1. Introduction

Primary mucinous epithelial ovarian cancer (mEOC) is a rare subset, 2.7–11.9%, of epithelial ovarian cancer. The incidence for high grade mucinous ovarian cancer (HGMOC) is even lower [1]. More than two-thirds of primary HGMOC cases are misdiagnoses, which has huge implications for the outcome of these patients [2]. The overall 5-year survival outcome for localised primary mucinous ovarian cancer is over 95%, whereas the life expectancy of women with metastatic mucinous cancer ranges from months to years depending on the

organ site of the primary tumour. Primary mEOC is a unique subtype of ovarian neoplasm, which tends to occur in younger women, is confined to the ovaries and has a more indolent natural history. Primary mEOC is unlike metastatic mucinous epithelial cancer, which tends to occur in older women with multiple sites of metastasis (often both ovaries involved) and retains the biological behaviour of the primary tumour [3].

The poor outcome of patients with HGMOEC is largely due to two main factors. Firstly, the majority of these patients have incurable advanced stage (stage IV) disease at diagnosis. Secondly, these tumours are largely unresponsive to the ovarian cancer chemotherapy regimen, in particular platinum-based chemotherapy regimen, as first-line and subsequent-line treatment [4]. Historically, mucinous ovarian cancers are treated as a single entity together with epithelial ovarian cancer, as seen in large clinical trials such as ICON3 [5], ICON5 [6] and ICON7 [7].

The distinction between primary and metastatic mucinous adenocarcinoma of the ovary has become a major focus given its importance in predicting outcomes and also to allow appropriate tumour workup and treatment planning. The diagnosis of primary HGMOEC and metastatic mucinous epithelial cancer remains challenging although there is now a better recognition by pathologists in distinguishing both subsets of cancer. Advances in imaging techniques and the involvement of multidisciplinary discussions are aiding in differentiating between primary and metastatic mEOC. In a recent retrospective analysis of patients enrolled into the ICON5 trial, where the patients were screened by a panel of experts and treated as ovarian cancer, 68% of stage III and IV HGMOEC cases were redefined as metastasis to the surface of ovaries [8]. This was reflected in the poor outcomes of these patients because they had received standard ovarian cancer treatment as part of their adjuvant and palliative treatment. In general, patients with advanced mEOC should be treated as a separate entity requiring an alternative therapeutic approach, such as fluorouracil (5FU) based chemotherapy regimen [9]. Despite strong preliminary support for a change in regimen there is still a universal lack of evidence in directing treatment for this subset of cancer due to the rarity of HGMOEC. A recent phase II trial comparing the use of platinum-based chemotherapy versus 5FU-based chemotherapy with or without the use of an anti-angiogenic agent (Bevacizumab) failed due to poor patient accrual. Interestingly, upon specialist pathology review of all cases (n = 36), 52% of mEOC were actually metastatic disease from elsewhere, highlighting again the diagnostic difficulties [10].

The molecular events leading to the development of HGMOEC are largely unknown. Gene and protein expression analyses have been performed on well-curated mucinous ovarian cancers to elucidate the key molecular processes allowing a better understanding of the tumour biology and development of biomarkers [11]. In a study published in 2006 by Heinzelmann-Schwarz et al., the gene expression profile of mEOC was distinct, compared with other subtypes of ovarian cancer, in particular, with serous and endometrioid ovarian cancer. mEOC was shown to express genes associated with mucin production and intestinal cell surface adhesion (e.g. LGALS4), demonstrating molecular similarity to malignant intestinal type epithelial cells but with key differences in gene expression, for example, lack of KRAS activity at the transcriptional level [11]. Perhaps surprisingly given earlier reports [12], mutations in p53 are observed in 64% of true primary mEOC [13]. HGMOEC were distinguished by having more chromosomal copy number events, although still not as extensively genomically unstable as High Grade Serous Ovarian Cancer (HGSOC) [13].

We describe in our mini-series four of nine consecutive cases who were referred to The Royal Women's Hospital, Melbourne in 2012 and initially treated as primary HGMOEC. These cases were annotated with the initial diagnostic work up, surgical procedure and subsequent management, which include follow-up investigations and systemic treatments. We performed RNAseq analysis on fresh frozen tumour samples from four patients who had consented for tumour tissue bio-banking under the Australian Ovarian Cancer Study (AOCS) platform. Within our metastatic HGMOEC cohort, we identified one case with a gene and protein expression profile suggestive of a glucagonoma-like NET gastro-intestinal tumour, which was largely unresponsive to 5FU-based chemotherapy. This report highlights the genomic diversity of HGMOEC that might account for a variable outcome to treatment and also the potential clinical application of functional genomics in curating a panel of mutation and expression markers to improve diagnostic accuracy.

2. Patients and methods

2.1 Patient selection

The study group consisted of patients referred to and assessed for mEOC at the Department of Gynaecology, Royal Women's Hospital (RWH) in Melbourne, between December 2011 and March 2013. For all patients, the diagnosis of mEOC was confirmed histologically and slides were reviewed by the RWH pathologists.

The Australian Ovarian Cancer Study (AOCS) was approved by Human Research Ethics Committees at the Peter MacCallum Cancer Centre, Queensland Institute of Medical Research, University of Melbourne and all participating hospitals. Additional approval was obtained from the Human Research Ethics Committees at the Royal Women's Hospital and the Walter and Eliza Hall Institute.

Case data were obtained via the CONTRO-engined gemma database, Royal Women's Hospital and the following parameters were collected: histology, age, date of diagnosis, stage of disease, grade, primary surgery (and outcomes), tumour markers (CA-125 and carcinoembryonic antigen) before and after chemotherapy, chemotherapy regimen, clinical outcome of patient following treatments (initial and subsequent lines), and date of death or last follow-up.

HGMOEC cases (Grade 2 or 3) were selected for RNAseq analysis based on the availability of fresh frozen tumour sample collected at the time of surgery and patient consent to the AOCS study.

2.2 RNAseq

Fresh frozen tumour tissue was obtained from the bio-bank (AOCS) facility. Total RNA was isolated using the RNeasy kit (Qiagen), and Illumina polyA RNAseq performed according to standard protocols at Australian Genome Research Facility. Libraries were 50 bp single end sequenced in multiplexed pools to an average depth of 50 million reads.

The resulting reads were mapped with Bowtie2 to the human reference genome with local alignment and discarding multi-mapped reads. Reads were summarised to genes using HTSeq and ENSEMBL v69. Differential expression analysis was performed in edgeR [14], comparing the four HGMOEC cases as a group (to identify gene expression common to all cases), and each case individually (to allow for high levels of heterogeneity between cases) to a panel of 16 High Grade Serous Ovarian Cancer (HGSOC) cases.

The resulting list of up-regulated genes present in HGMOOC was filtered for genes that are expressed in less than 10 anatomical systems in the eGenetics expression resource using ENSEMBL biomaRt [15].

3. Results

3.1 Patient characteristics

Nine patients with a histologically confirmed diagnosis of high-grade mucinous ovarian cancer presented at the Gynaecology Department of RWH between December 2011 and March 2013 (**Figure 1**). Three patients declined consent to AOCS and were therefore excluded from this study. Of the six patients who consented to AOCS, one did not have fresh frozen tumour tissue stored during the original surgery and another case was excluded due to subsequent diagnosis of pseudomyxoma peritonei. RNAseq analysis was performed on the remaining four cases using tumour tissue snap frozen at surgery. The patients’ characteristics were summarised as per **Table 1**. Representative histology images are shown in **Figure 2**.

3.2 Case reports

3.2.1 Tumour 1

Patient #32, a 31-year-old woman with no significant family history of malignancy, presented with a short history of increasing right iliac fossa abdominal pain. She previously had a CT scan 1 month earlier, which showed a large 16 cm complex left ovarian mass. This mass was confirmed by her pre-operative pelvic MRI scan with enlarged para-aortic lymph nodes below the renal artery and no other obvious

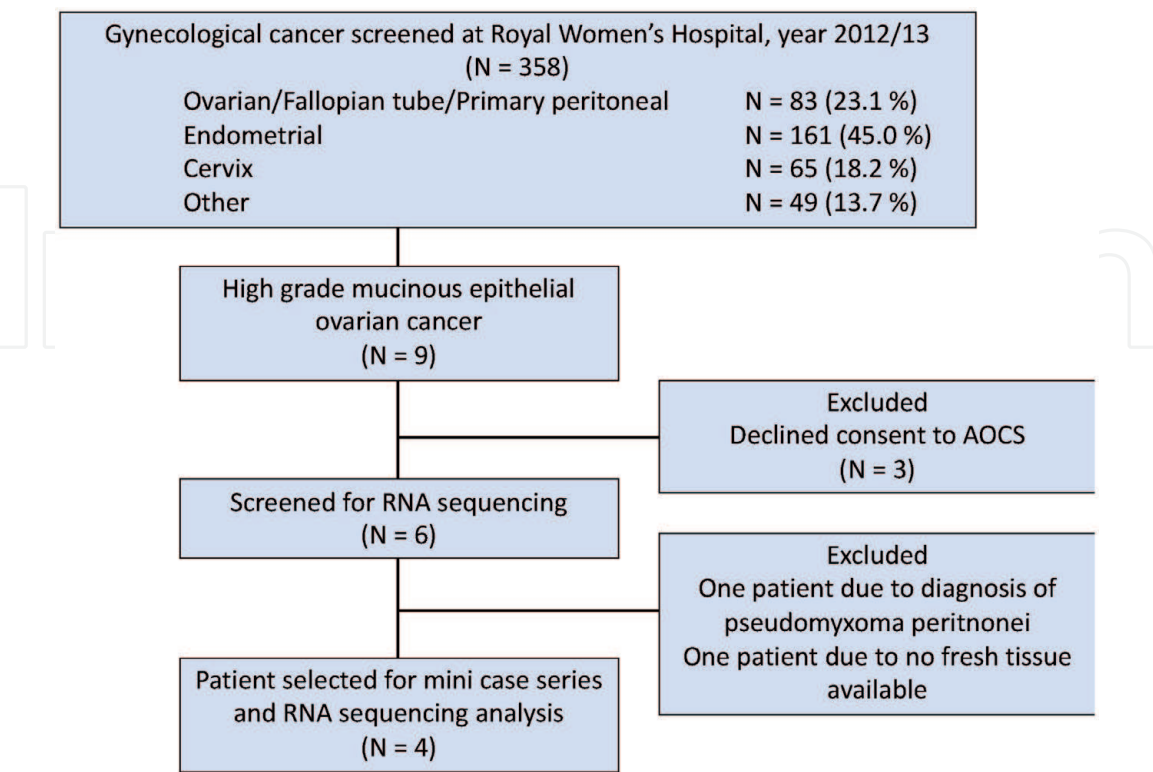


Figure 1. Patients screened at Royal Women’s hospital during 2012/13 being treated as high grade mucinous epithelial ovarian cancer for RNA sequencing analysis.

Patient number	#32	#35	#49	#60
Age (years)	31	34	64	67
Past medical history	Nil	Nil	Non-insulin dependent diabetes mellitus Hypertension Thyroid cyst	Previous metastatic appendix mucinous adenocarcinoma of right ovary (2 years earlier) Oostoarthritis Hypertension
Histopathology				
Histology	Adenocarcinoma with focal intestinal type mucinous differentiation	High-grade adenocarcinoma with focal mucinous differentiation	Mucinous adenocarcinoma with large area of mucin surrounded by signet ring cells - associated with appendiceal tumour with similar histological features	Adenocarcinoma with tumour cells demonstrating focal intracytoplasmic mucin
Immunohistochemistry	CK7, CK19 and CEA diffusely positive, CK20 focally positive	CK7 diffusely strongly positive and CK20 positive in 30-40% of tumour cells, P53 positive in areas of carcinoma	CK20 strongly positive, CK7, WT1 and GCDFP15 negative, Chromogranin and synaptophysin positive	CK20 positive and CK7 negative
Grade	II	III	II	III
Stage	FIGO 1A	FIGO 1C	IV	IV
Laterality	Left	Left	Bilateral	Left
Size	18cm	15cm	7.5cm (right) and 6cm (left)	14cm
Pathologist opinion	May represent primary ovarian carcinoma but need to exclude upper GIT/pancreobiliary tumour	Consistent with primary HGMO	Appendiceal primary mucinous adenocarcinoma with neuroendocrine differentiation	Metastatic from previous appendix mucinous adenocarcinoma with similar histopathology features
Baseline tumour markers				
CA125	20	112	6	584
Surgical outcome	Optimal debulk	Optimal debulk	Optimal debulk	Debulking surgery
Post surgery systemic treatment	Nil	Carboplatin and paclitaxel (completed 6 cycles)	5FU-based chemotherapy Radiotherapy - at progression for symptom control	Standard colorectal treatment
Survival outcome	Alive at 5 year follow-up	Alive at 5 year follow-up	Died 4 years later	Lost to follow-up (discharged back to the colorectal team)

Table 1.
Patient characteristics.

lesion identified. This patient underwent total abdominal hysterectomy (TAH), bilateral salpingo-oophorectomy (BSO) and para-aortic lymph node sampling. At surgery, her bowels and intra-peritoneal cavity looked normal. Her tumour histology was reviewed at a multi-disciplinary meeting and was diagnosed as grade 2 primary mEOC stage IA. She received no further systemic treatment. For completion of her cancer assessment, the patient underwent upper gastro-intestinal endoscopy and colonoscopy, which were both normal and subsequently had a PET/CT scan that showed no evidence of metastatic disease. The patient remained alive and well at 5-year follow-up.

3.2.2 Tumour 2

Patient #35 was a 34-year-old woman with no previous significant background medical history and presented to her general practitioner with 1-month history of intermittent lower abdominal pain. Her initial ultra-sound scan organised by her general practitioner showed a large left ovarian cyst and pre-operative MRI scan confirmed a 18 cm complex mixed cystic lesion with a 5 cm solid component associated with moderate ascites. The patient underwent up-front surgery with TAH and BSO. Her peritoneum, abdominal organs and diaphragm appeared to be normal during surgery. The histopathology result confirmed high-grade mucinous adenocarcinoma of the ovary with no surface spread and negative lymph node

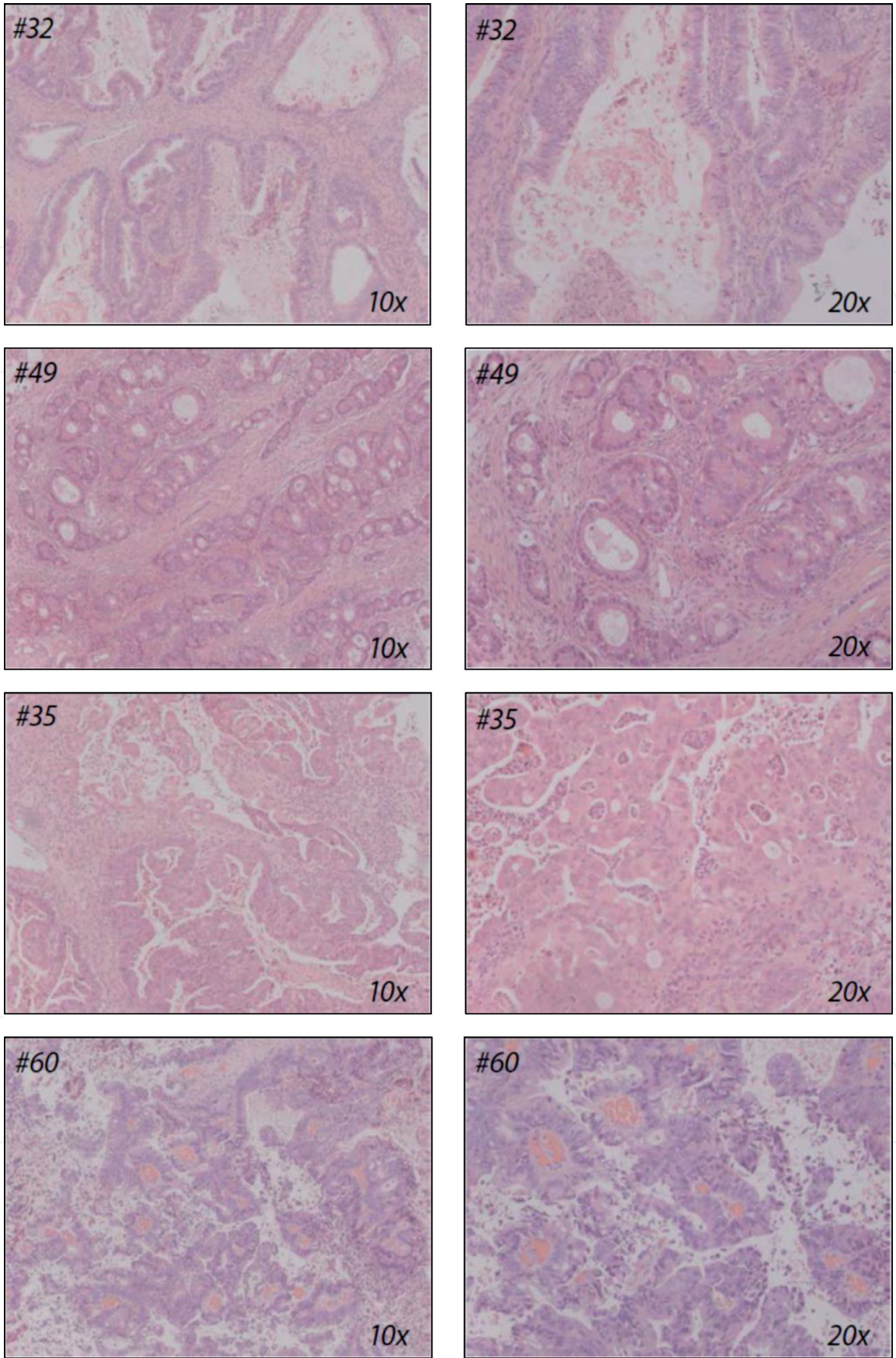


Figure 2.
Histopathology of the four cases: Representative haematoxylin and eosin stained slides presented at 10× and 20× magnification.

involvement. The tumour was stage IC given that the peritoneal washing was positive for malignant cells. Patient received adjuvant ovarian cancer chemotherapy, consisting of carboplatin and paclitaxel, at her local medical oncology centre. She

also underwent upper gastro-intestinal endoscopy and colonoscopy as completion of her tumour assessment, which were normal. She remained well and alive at her last follow-up assessment 5 years later.

3.2.3 Tumour 3

Patient #49 was a 64-year-old woman with known type II diabetes mellitus who presented to her local hospital with increasing abdominal pain, nausea, vomiting, and urinary frequency. Her initial CT scan showed a right ovarian mass associated with peritoneal deposits. This was confirmed by her diagnostic laparoscopy that showed a 14 cm ovarian mass adherent to the left adnexa and pouch of Douglas associated with macroscopic tumour deposits on her anterior abdominal wall and omentum. The original biopsy confirmed adenocarcinoma favouring gastro-intestinal tumour. She underwent TAH, BSO, omentectomy and appendectomy. Bilateral ovarian masses were resected during her surgery together with appendiceal and omental nodules. The histopathology confirmed metastatic mucinous adenocarcinoma on both ovaries with evidence of similar tumour effacement of the appendix suggestive of appendiceal origin. It was noted by the pathologist that there was NET differentiation of her mucinous adenocarcinoma with immunohistochemistry staining for chromogranin and synaptophysin positive. She was discharged from hospital following recovery of her surgery to the care of the gastro-intestinal (GI) team. Her case was discussed at the GI tumour board meeting and the expert opinion was to treat this as advanced stage (Stage IV) colorectal cancer with palliative fluorouracil (5FU) based chemotherapy following her surgical debulking procedure. The patient had minimal residual disease prior to commencing her palliative chemotherapy. Her gastroscopy and colonoscopy performed post-operatively showed significant pathology. She completed 8 cycles of FOLFOX (5FU with oxaliplatin) following by single agent 5FU until late 2014. The patient had an interval PET/CT scan performed a year later that showed minimal metabolic activity in known low volume metastatic peritoneal disease. She subsequently presented in 4–6 months later with incomplete bowel obstruction and radiological evidence of slow peritoneal disease progression. Her bowel obstruction resolved with conservative management and she declined further lines of systemic treatment. She received palliative radiation therapy to her peritoneal metastasis with some relief of abdominal symptom. She had multiple admissions to her local hospital in the following 12 months, with bowel-related complications and subsequently passed away in that year, 4 years following the diagnosis of her cancer having only effectively completed one line of systemic treatment.

3.2.4 Tumour 4

Patient #60 was a 67-year-old woman who was diagnosed with metastatic appendiceal mucinous adenocarcinoma of her right ovary 2 years prior to her re-referral with a left ovarian mass. Her initial cancer was treated with surgical removal of the right ovarian and appendiceal mass. Her surgery was complicated with extensive venous thrombo-embolic (VTE) events. She received no systemic treatment following her initial surgery and represented with a 12 cm mixed cystic/solid mass arising from the left ovary based on initial imaging. She underwent second de-bulking surgery following insertion of an inferior vena cava filter for her VTE. This involved the removal of the dense left pelvic tumour mass that was adherent to her bowel, ureter and bladder requiring cystotomy and colostomy. The histopathology report confirmed evidence of adenocarcinoma with focal

intracytoplasmic mucin consistent with mucinous adenocarcinoma similar with the original diagnosis 2 years ago. The CK20 was strongly positive and associated with negative staining for CK7. The patient was discharged back to her original colorectal team for further management.

3.3 Transcriptome analysis by RNAseq

Due to the high level of heterogeneity in expression within the HGMOEC group, significantly differentially expressed genes were not able to be detected in the group comparison. However, the individual tumour analyses identified a large number of differentially expressed genes. This large number of differentially expressed genes is an expected limitation of this type of analysis, as variance can only be estimated from the control group and there is no suppression of random variability as would be seen in a group of replicates. Because many of these genes were minimally informative, the differentially expressed genes were filtered to identify upregulated genes that are annotated as having organ specific expression and may be informative for the organ of origin. The RNAseq analysis identified 18 genes with a restricted tissue/organ expression pattern that were differentially up regulated in the four tumour samples. These genes were enriched for expression in colon, stomach, pancreas, lung, kidney and skeletal muscle. Only two of the genes, LGALS4 and ERN2, are annotated as expressed in gynaecological tissues and both are also expressed in colonic tissue (**Figure 3**).

3.3.1 *Primary mucinous ovarian epithelial carcinoma exhibits a gene expression profile distinct from metastatic mucinous epithelial carcinoma and high-grade serous ovarian cancer*

The variable genes identified by transcript profiling revealed that the two primary HGMOEC tumours #32 and #35, could be clearly distinguished from the two metastatic mEOC, tumours #49 and #60. A cluster of genes including PGC (encodes a digestive gastric protein), ANAX10 (encodes a calcium- and phospholipid-binding gastric protein), DOUX2 (encodes an oxidase enzyme common in thyroid and GI system) and C12orf36 (non-protein encoding RNA) were up regulated in both tumour #32 and tumour #35. Tumour #49 and tumour #60 had CDH17 (encodes a cadherin superfamily glycoprotein common in gastro-intestinal and pancreatic cells), GUCY2C (encodes for guanylyl cyclase enzyme found in intestinal epithelium) and SCGN (encodes a secretory calcium binding protein in cell cytoplasm) genes up regulated. All four tumours shared in common high expression of seven genes not seen in HGSOEC, in particular LGALS4, an intestinal surface cell adhesion molecule that is over-expressed in intestinal carcinomas [16]. LGALS4 had previously been shown to be specifically expressed in mEOC [11]. However, in our cohort, this gene was universally expressed in all four tumours rendering it as a non-distinguishing gene. Interestingly, the two primary HGMOEC (tumour #32 and tumour #35) retained some expression of PAX8 and WT1 together with KRT7/CK7 expression as also seen in the HGSOEC control panel. The expression of PAX8 in mucinous epithelial ovarian cancer, and the lack of its expression in appendiceal cancers, has been previously described and this further supports the relevance of this gene expression in differentiating the organ of origin of the tumour [17]. With only two mEOC cases this analysis is weakly powered and heavily influenced by the individual cases. Analysis of a larger cohort and validation will be required to identify robust clinical markers.

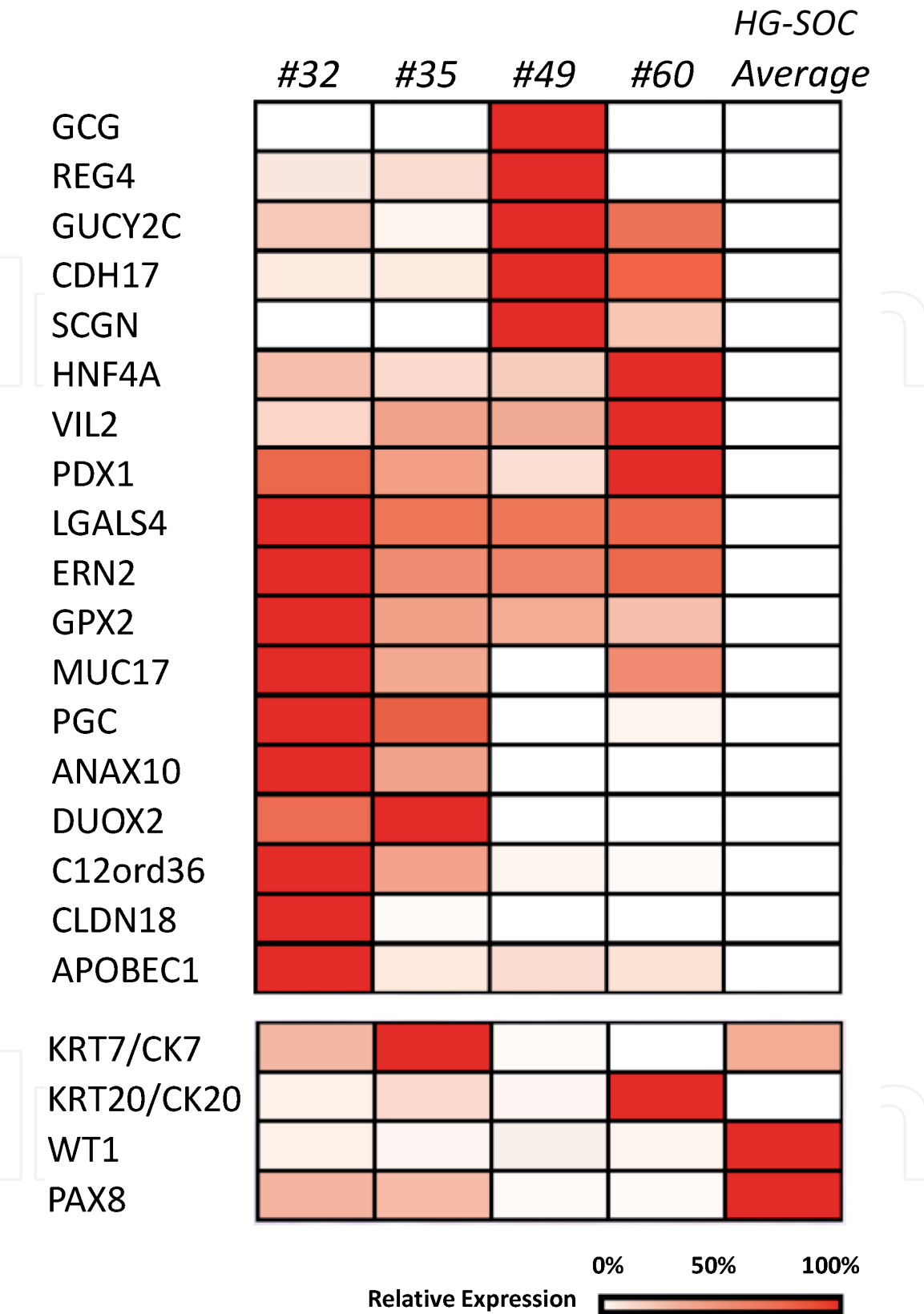


Figure 3.
Heat map of the most differentially expressed genes in the four tumours analysed compared to HGSOC (top panel), and expression comparison of four commonly used markers (lower panel). The tissue specific expression of the listed genes: GCG: pancreas; REGA: GIT (D, Sm, C, R) + appendix; GUCY2C: GIT (D, Sm, C, R); CDH17: GIT (S, D, Sm, C, R) + appendix; SCGN: GIT (S, D, Sm, C, R) + pancreas; HNF4A: GIT (S, D, Sm, C, R) + liver + pancreas + appendix; VIL2: GIT + FGT; PDX1: GIT (D, S) + pancreas; LGALS4: GIT (S, D, S) + gallbladder + appendix; ERN2: GIT (S, D, S, C, R) + appendix; GPX2: GIT + liver + kidney; MUC17: GIT (D, Sm); PGC: S; ANAX10: S; DUOX2: thyroid + stomach; C12ord36: S; CLDN18: S; APOBEC1: Sm; KRT7/CK7: FT. cervix, uterine, liver, gallbladder, pancreas; KRT20/CK20: GIT (D, S, C, R); WT1: FGT; PAX8: FGT. GIT: gastro-intestinal tract; D: duodenum; S: stomach; Sm: small intestine; C: caecum; R: rectum; FGT: female genital tract; FT: fallopian tube.

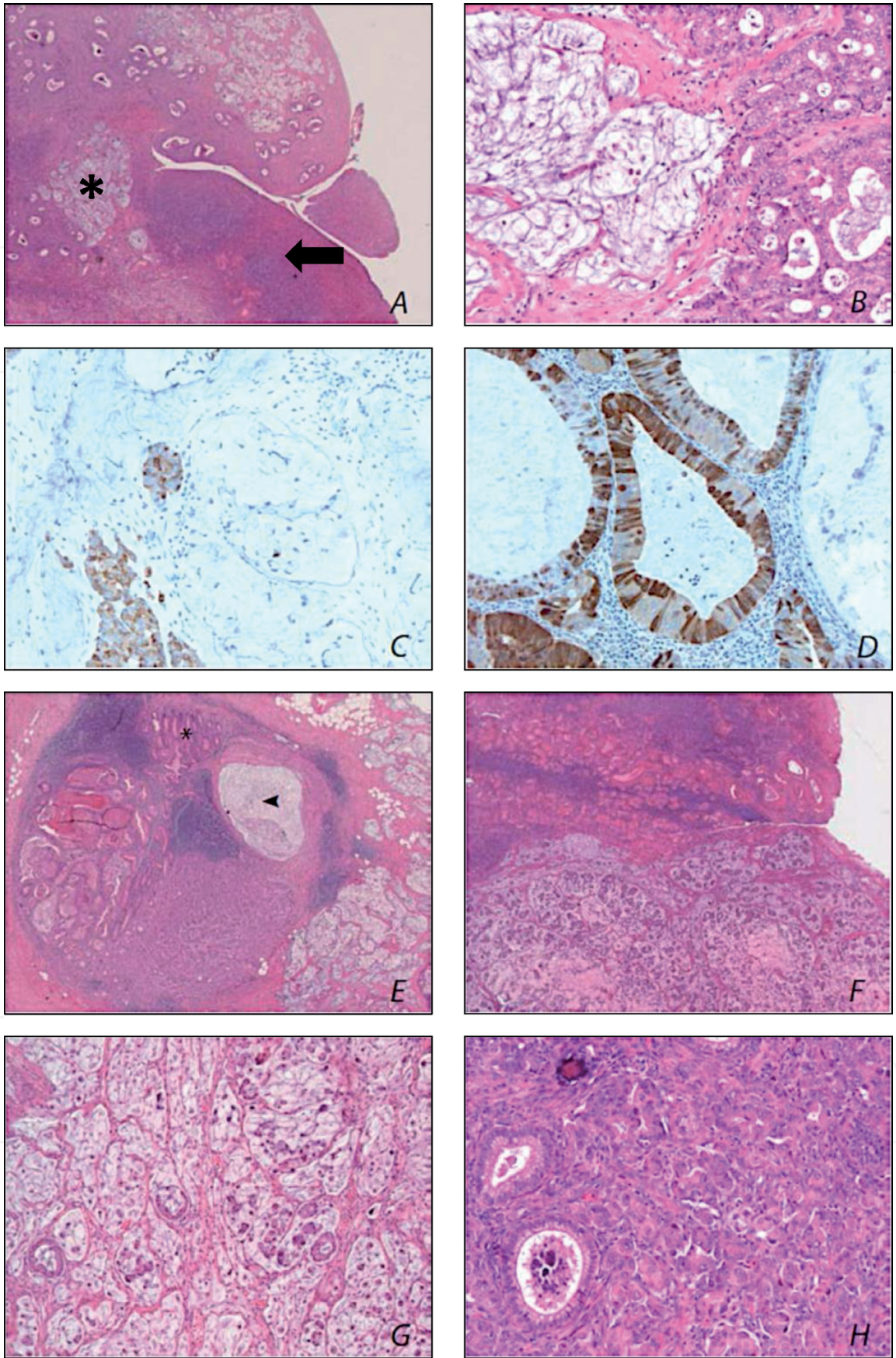


Figure 4.
A. Adenocarcinoma seeding in the ovary; normal ovarian tissue (arrow), mucinous glandular component of adenocarcinoma (*); prominent stromal desmoplasia can be typically seen in tumours that secondarily involve the ovary (5× magnification); B. Adenocarcinoma in the ovary (20× magnification); C. Chromogranin immunohistochemical staining shows strong and diffuse reactivity (20× magnification); D. Glucagon immunohistochemical staining shows strong reactivity in tumour cells (20× magnification); E. Adenocarcinoma infiltrating the appendix (5× magnification); lumen of appendix (arrow); adenocarcinoma (*); F. Adenocarcinoma in the appendix (20× magnification); G. Adenocarcinoma in the appendix (20× magnification); H. Adenocarcinoma in the appendix (20× magnification).

3.3.2 Identification of tumour #49 as a glucagonoma-like neuroendocrine tumour of likely appendiceal origin by transcriptome analysis

The RNAseq analysis identified up regulation of GCG, a gene that encodes for glucagon, in tumour #49. GCG accounted for ~5% of transcriptional output indicating a high level of glucagon expression. The original histopathology report on the resected tumour confirmed evidence of NET differentiation within the mucinous adenocarcinoma, with positive IHC staining for chromogranin and synaptophysin. Our findings were returned to the original pathologist at RWH and further IHC for glucagon protein expression was performed. Strong glucagon staining was seen in the tumour cells by IHC, confirming the RNAseq findings (**Figure 4**). This “glucagonoma”-like tumour may have either a pancreatic origin or may have originated from the appendix as clinically implicated (**Figure 4**).

This patient’s case was discussed at the GI tumour board meeting, and despite the finding of our RNAseq analysis, it was treated as a standard colorectal cancer given the rarity of NET differentiated mucinous adenocarcinoma of the appendix. It was difficult to ascertain the full effect of CRC/5FU-based chemotherapy regimen on this patient given the limited line of treatment received and perceived minimal residual disease post-surgery. Unfortunately, the patient declined further chemotherapy at first progression but survived for a further 2 years receiving only palliative radiation treatment to problematic intra-abdominal lesions.

4. Discussion

True mucinous epithelial ovarian carcinomas are a rare subtype of ovarian cancer. In our limited case cohort, half of the mEOC seen in our institute at a given period of time were re-diagnosed as metastatic mucinous epithelial carcinoma. This posed a challenge for both the pathologists and surgical team to provide an accurate and timely diagnosis of the cancer and enable the delivery of optimal treatment. Clinical and radiological information, such as patient age, laterality of tumour, tumour stage and to some extent tumour marker CA125 can guide diagnosis prior surgery [3]. Ultimately, it is the histology of the resected tumour that allows accurate assessment of tumour origin based on the pattern of protein expression seen by IHC and morphology [8]. However, in patient #60 case, a previous history of appendiceal tumour should have raised the suspicion for metastatic recurrence of the tumour.

Our pilot RNAseq study indicated that tumours initially diagnosed as mEOC can be a diverse collection of disease, and that gene expression analysis has the potential to identify prognostically useful subsets. Categorising based on gene expression and identifying genetic aberrations is likely to greatly assist in selection of the optimal treatment for each individual patient. While RNAseq for each individual patient is an impractical method for tumour identification, the observations from this study contributed to the design of a larger study, GAMuT—Genomic Analysis of Mucinous Tumours, which will compare HGMOc to low grade and borderline cases to identify prognostic and therapeutically useful gene expression signatures (Australian National Health and Medical Research (NH&MRC) Funded Study—APP1045783). This study will allow the selection of a panel of mutation and expression markers to elucidate the tumour organ of origin, thus providing some guidance in treatment selection.

We highlighted the identification of a very rare “glucagonoma-like” NET appendiceal tumour in our series of mEOC to indicate the reliability of functional genomics in identifying rare conditions. This diagnosis is in context with the

patient's clinical findings and also with IHC proving glucagon protein expression only apparent after the RNA sequencing results were available. In hindsight, it is hard to predict if this patient would have benefited from repeated surgical resection of recurrent tumour [18], or to NET based treatment regimens, such as mTOR inhibition (everolimus) [19] or multiple tyrosine kinase inhibitor (sunitinib, pazopanib) [20, 21]. Furthermore, the patient did not exhibit glucagon syndrome and her glucagon serum level was never tested. Nevertheless, clinically tumour #49 behaved like a NET tumour with slow indolent progression and localised complication. Unfortunately, in this case, the problematic tumour caused repeated bowel obstructive symptoms requiring multiple hospital admissions in the months leading up to the patient's death.

The recognition of diversity of tumour subtypes even within a rare tumour population is important especially in designing clinical trials. Given the small number of patients available for accrual, it is vital that we accurately stratify patients into treatment arms and identify robust biomarkers early. A very rare tumour within a rare tumour subtype can pose a challenging issue in terms of being an outlier that would skew the outcome in a clinical trial and also in optimising treatment for this patient based on available evidence (which is lacking). These issues will need to be addressed in any clinical trials pertaining to rare cancer.

Acknowledgements

We thank Margot Osinski (Royal Women's Hospital) for database assistance and AOCS: The Australian Ovarian Cancer Study Group was supported by the U.S. Army Medical Research and Materiel Command under DAMD17-01-1-0729. The AOCS also acknowledges the cooperation of the participating institutions in Australia and acknowledges the contribution of the study nurses, research assistants and all clinical and scientific collaborators to the study. The complete AOCS Study Group can be found at www.aocstudy.org. We would like to thank the women who participated in these research programs.

IntechOpen

Author details

Gwo Yaw Ho^{1,2,3,4,7*}, Sumitra Ananda^{1,3,4,8}, Cassandra J. Vandenberg^{1,4},
Orla McNally⁷, Jeanne Tie^{1,3,4}, Kylie Gorringer^{3,4}, David Bowtell³, Jan Pyman⁷,
Matthew J. Wakefield^{1,4} and Clare L. Scott^{1,3,4,5,6,7}

1 Walter and Eliza Hall Institute, Parkville, Australia

2 Monash University, Melbourne, Australia

3 Peter MacCallum Cancer Centre, Melbourne, Australia

4 The University of Melbourne, Melbourne, Australia

5 Royal Melbourne Hospital, Parkville, Australia

6 Monash Medical Centre, Clayton, Australia

7 Royal Women's Hospital, Parkville, Australia

8 Western Health, Melbourne, Australia

*Address all correspondence to: ho.g@wehi.edu.au

IntechOpen

© 2020 The Author(s). Licensee IntechOpen. This chapter is distributed under the terms of the Creative Commons Attribution License (<http://creativecommons.org/licenses/by/3.0>), which permits unrestricted use, distribution, and reproduction in any medium, provided the original work is properly cited. 

References

- [1] Schiavone MB et al. Natural history and outcome of mucinous carcinoma of the ovary. *American Journal of Obstetrics and Gynecology*. 2011;**205**:480.e1-480.e8
- [2] Perren TJ. Mucinous epithelial ovarian carcinoma. *Annals of Oncology*. 2016;**27**:i53-i57
- [3] Khunamornpong S et al. Primary and metastatic mucinous adenocarcinomas of the ovary: Evaluation of the diagnostic approach using tumor size and laterality. *Gynecologic Oncology*. 2006;**101**:152-157
- [4] Pignata S et al. Activity of chemotherapy in mucinous epithelial ovarian cancer: A retrospective study. *BMC Cancer*. 2008;**8**:252
- [5] Investigators, I.T. Paclitaxel plus carboplatin versus standard chemotherapy with either single-agent carboplatin or cyclophosphamide, doxorubicin, and cisplatin in women with ovarian cancer: The ICON3 randomised trial. *The Lancet*. 2002;**360**:505-515
- [6] Bookman MA. GOG0182-ICON5: 5-arm phase III randomized trial of paclitaxel (P) and carboplatin (C) vs combinations with gemcitabine (G), PEG-liposomal doxorubicin (D), or topotecan (T) in patients (pts) with advanced-stage epithelial ovarian (EOC) or primary peritoneal (PPC) carcinoma. *Journal of Clinical Oncology*. 2006;**24**(18_suppl):5002-5002. DOI: 10.1200/jco.2006.24.18_suppl.5002
- [7] Oza AM et al. Standard chemotherapy with or without bevacizumab for women with newly diagnosed ovarian cancer (ICON7): Overall survival results of a phase 3 randomised trial. *Lancet Oncology*. 2015;**16**:928-936
- [8] Zaino RJ et al. Advanced stage mucinous adenocarcinoma of the ovary is both rare and highly lethal. *Cancer*. 2010;**117**:554-562
- [9] Hess V. Mucinous epithelial ovarian cancer: A separate entity requiring specific treatment. *Journal of Clinical Oncology*. 2004;**22**:1040-1044
- [10] Gore ME et al. Multicentre trial of carboplatin/paclitaxel versus oxaliplatin/capecitabine, each with/without bevacizumab, as first line chemotherapy for patients with mucinous epithelial ovarian cancer (mEOC). *Journal of Clinical Oncology*. 2015. DOI: 10.1200/jco.2015.33.15_suppl.5528
- [11] Heinzelmann-Schwarz VA et al. A distinct molecular profile associated with mucinous epithelial ovarian cancer. 2006:1-10. DOI: 10.1038/sj.bjc.6603003
- [12] Shih I-M, Kurman RJ. Ovarian tumorigenesis. *The American Journal of Pathology*. 2010;**164**:1511-1518
- [13] Cheasley D et al. The molecular origin and taxonomy of mucinous ovarian carcinoma. *Nature Communications*. 2019:1-11. DOI: 10.1038/s41467-019-11862-x
- [14] Robinson MD, McCarthy DJ, Smyth GK. edgeR: A bioconductor package for differential expression analysis of digital gene expression data. *Bioinformatics*. 2009;**26**:139-140
- [15] Magali R et al. Ensembl core software resources: Storage and programmatic access for DNA sequence and genome annotation. *Database*. 2017:1-11. DOI: 10.1093/database
- [16] Grotzinger C et al. LI-cadherin: A marker of gastric metaplasia and neoplasia. *Gut*. 2001;**49**:78-81

[17] Laury A et al. A comprehensive analysis of PAX8 expression in human epithelial tumors. *The American Journal of Pathology*. 2011;**35**:816

[18] Al-Faouri A, Ajarma K, Alghazawi S, Al-Rawabdeh S, Zayadeen A. Case report glucagonoma and glucagonoma syndrome: A case report with review of recent advances in management. *Case Reports in Surgery*. 2016:1-3. DOI: 10.1155/2016/1484089

[19] Yao JC et al. Everolimus for the treatment of advanced, non-functional neuroendocrine tumours of the lung or gastrointestinal tract (RADIANT-4): A randomised, placebo-controlled, phase 3 study. *The Lancet*. 2016;**387**:968-977

[20] Dahan L et al. Sunitinib malate for the treatment of pancreatic neuroendocrine tumors. *New England Journal of Medicine*. 2011;**364**:501-513

[21] Grande E et al. Pazopanib in pretreated advanced neuroendocrine tumors: A phase II, open-label trial of the Spanish task force Group for Neuroendocrine Tumors (GETNE). *Annals of Oncology*. 2015;**26**:1987-1993