

# We are IntechOpen, the world's leading publisher of Open Access books Built by scientists, for scientists

6,900

Open access books available

185,000

International authors and editors

200M

Downloads

Our authors are among the

154

Countries delivered to

TOP 1%

most cited scientists

12.2%

Contributors from top 500 universities



WEB OF SCIENCE™

Selection of our books indexed in the Book Citation Index  
in Web of Science™ Core Collection (BKCI)

Interested in publishing with us?  
Contact [book.department@intechopen.com](mailto:book.department@intechopen.com)

Numbers displayed above are based on latest data collected.  
For more information visit [www.intechopen.com](http://www.intechopen.com)



# Surgical Approaches and Leg Positions for Tibial Plateau Fractures

*Katsimentzas Triantafyllos, Tryfon Ditsios  
and Kostantinos Ditsios*

## Abstract

Tibial plateau fractures are a common orthopedic injury. Epidemiological studies have shown that these injuries appear in younger or older patients with different mechanisms of injury. For better long-term results, it is crucial to achieve successful fracture reduction, thus avoiding the main complication, which is post-traumatic arthritis. Reduction can be achieved by choosing the proper surgical approach. Many approaches that address the fractures of the tibial plateau have been described in international literature. In the past, the direct anterior midline approach was used, which required a large detachment of the soft tissues. Nowadays, the percutaneous approach, the anterolateral approach, the medial approach, the postero-medial approach, the posterolateral approach, and the direct posterior approach are used by orthopedic surgeons to treat these kinds of fractures. In this chapter, we will describe the surgical approaches available for tibial plateau fractures and the possible positions of the affected leg.

**Keywords:** tibial plateau fractures, proximal tibia fractures, surgical approach, surgical incision, patient position, leg position

## 1. Introduction

Tibial plateau fractures constitute 1% of all bone fractures [1]. These intra-articular fractures are rare with an incidence of 10.3/100,000 per year [1]. They occur in young adults as a result of high energy trauma (motor accident, fall) or as low energy fractures in elderly patients with poor bone quality. This type of injury has a variety of fracture patterns. Compared to women, men younger than 50 years of age show a higher incidence for these fractures. Incidence increased markedly in women older than 50 years and decreased in men older than 50 years. For both sexes, the highest frequency was between ages 40 and 60 years [1].

Seventy percent of fractures are isolated to the lateral plateau, with 10–30% bicondylar and less than 10% isolated medial condyle fractures [2]. However, after multifragmentary articular surface destruction, they are often associated with a poor postoperative outcome [1]. With bicondylar fracture involvement, arthritis rates up to 44% have been described. Moreover, the medial plateau fractures with >3 mm displacement and anteromedial or posterolateral column fractures in young patients are associated with higher risk of ACL avulsion fracture [3].

Displaced fractures are treated with open reduction and internal fixation. The goals of treatment include restoration of extremity axial alignment, joint stability, and congruity, allowing early motion and prevention of osteoarthritis. Short-term results of surgical fixation of tibial plateau fractures are good; however, longer-term outcomes have demonstrated a significantly higher risk of end-stage arthritis and necessity for total knee arthroplasty [4].

Nontraumatic management of soft tissue with careful surgical incision is crucial in order to avoid further damage of the tissues around the fractured area. The choice of surgical approach is mainly based on the morphology of the fracture and the condition of the soft tissues, the general condition of the patient and the accompanying injuries. Computed tomography has greatly assisted in assessing the pattern of tibial plateau fractures.

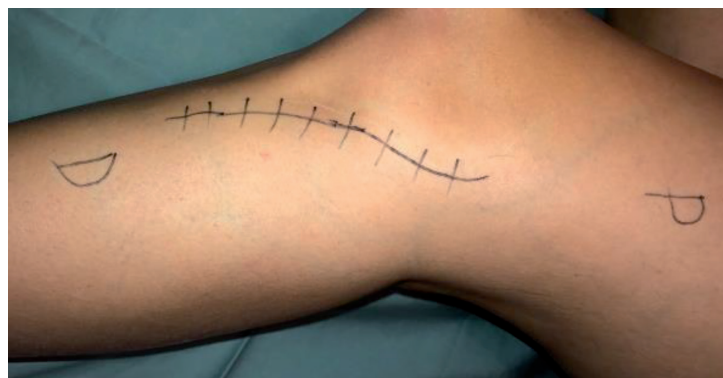It is important to achieve good reduction of the fracture for better long-term results with the proper surgical incision. The ideal surgery approach helps the orthopedic surgeon to evaluate the fracture and place the orthopedic fixation implants successfully.

## **2. Lateral approaches**

### **2.1 Anterolateral approach**

Lateral tibial plateau fractures are very common. Due to this reason, the anterolateral approach is the most frequently used surgical approach for tibial plateau fractures. This surgical incision can be used for simply split lateral tibial fractures with or without compression and also for comminuted bicondylar tibial fractures.

There are quite a few variations in skin incisions for the anterolateral approach. In this chapter, we will describe the two methods most commonly used. For the first one, the incision starts 2–3 cm proximal to the joint line and ends 3 cm inferior of the tibial tubercle, depending on the fracture pattern. This lazy “s” shaped incision begins directly lateral over the iliotibial band (IT), curves over Gerdy’s tubercle, and continues distally lateral to the tibial crest (**Figure 1**) [5]. The ilio-tibial band is detached from its insertion using sharp dissection with a knife and reflected anteriorly and posteriorly (**Figure 2**) [5]. The interval between the IT band and the joint capsule is developed with blunt dissection, and care is taken to keep the capsule intact. As far as deep dissection is concerned, the anterior tibialis muscle is retracted posteriorly revealing the anterolateral part of proximal tibia. Consequently, the joint line is identified, and submeniscal arthrotomy is made [6]. Two or three sutures are placed in the peripheral part of the meniscus, and



**Figure 1.**  
*Skin incision for anterolateral approach lazy “s”.*

retraction is applied to better visualize the articular surface. These sutures are also used to stabilize the lateral meniscus into the tibia or into the K-wire holes of the plate after fracture fixation.

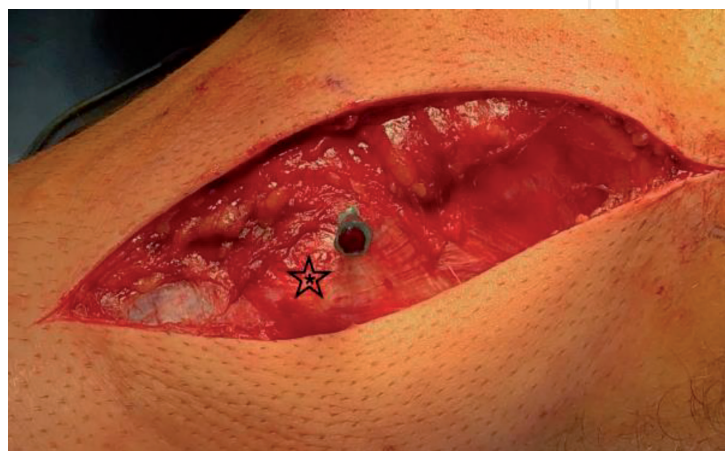
According to the international literature, many orthopedic surgeons use the “straight” incision for the anterolateral approaches of tibial plateau fractures [7]. This is the second method most often used for the anterolateral approach. It consists of an incision that begins proximal to the lateral femoral epicondyle and continues distally behind Gerdy’s tubercle. Depending on the fracture pattern, the skin incision can be either more posterior or anterior. Regarding superficial dissection, extensive subcutaneous soft tissue must be mobilized in order to expose the fascia of the tibialis anterior. The deep dissection that follows is the same as we describe above in “s-shaped” incision, using iliotibial band and fibula head as landmarks.

Typically, the patient is positioned in either supine or lateral decubitus position. Moreover, the patient’s leg can be placed in leg-holter position for better fracture reduction due to permanent ligamentotaxis.

### **Structures in danger**

- Short saphenous vein
- Superficial peroneal nerve
- Anterior tibial artery and deep peroneal nerve

Posterolateral plateau fractures can neither be viewed nor adequately supported with these types of procedures. Posterolateral areas cannot be visualized via the classic anterolateral approach; consequently, other techniques are needed [8]. Several osteotomies have been described for improving exposure via a standard anterolateral approach. These osteotomies help to better visualize the posterolateral part of tibial plateau and manipulate the fragments; however, it is difficult to place the adequate posterior fixation. First, the femoral epicondyle osteotomy has been used for several orthopedic surgeries, such as total knee arthroplasty or meniscal transplantation [9]. In 2015, a case report was described in which the lateral femoral epicondyle was osteotomized for better access to the posterolateral tibial plateau fracture [10]. Second, the fibula resection osteotomy has been described in 2010 and includes resection of the medial and proximal fibula. Third, the digastric fibular osteotomy has been recently described in the literature improving both the



**Figure 2.**  
*Iliotibial band curved over Gerdy's tubercle.*

visualization of the posterolateral articular surface and the ability to manipulate posterolateral fracture fragments.

## **2.2 Posterolateral approach**

The posterolateral approach is ideal for the lateral tibial plateau fractures which have posterior displacement. This approach was initially described by Lobenhoffer et al. [11] in 1997 and was then modified by many surgeons such as Frosch [12] and Solomon [8] either with or without fibular osteotomy.

As Lobenhoffer [11] first described, the head of the fibula and the tibial tuberosity can be used for the orientation of the skin incision. The longitudinal cut runs laterally exactly in the middle of the distance between the tibial tuberosity and the fibula tip and has approximately 10 cm length. The peroneal nerve is identified proximal to the head of the fibula and is looped. The origin of the extensor muscle is then cut away, and the incision is continued tongue-shaped over the fibular neck. If there is a subcapital fibula fracture, this fracture is carefully mobilized. If this is not the case, a fibula osteotomy is performed after careful circumvention of the fibular neck. The origin of the extensor muscles is pushed about 1 cm distally. The meniscotibial ligament is incised, and the lateral meniscus is pulled proximally using holding threads. The fixed ligament of the tibiofibular joint is released, so that the head of the fibula can be pulled upward and back. As a result, the lateral collateral ligament relaxes and enables the lateral joint gap to be opened wide. The posterolateral tibial plateau is brought into the field of the surgeon's vision in flexion and varus as well as internal rotation. If necessary, the posterolateral tibia shaft is exposed. If extensive exposure is required, the iliotibial tract on Gerdy's tubercle can also be detached in one layer with the meniscotibial ligament.

### **Structures in danger**

- Common peroneal nerve
- Popliteal artery
- Popliteal tendon
- Lateral superior genicular artery
- Lateral inferior genicular artery

Nowadays, a modification of the posterolateral approach is used that was described by Frosch et al. [12]. A straight incision, about 8–10 cm, is made from the medial border of the biceps femoris tendon proximally to the posteromedial part of fibula distally. Subsequently, through the skin and subcutaneous tissues, the interval between the biceps femoris tendon and the lateral gastrocnemius muscle is found. In this area, the common peroneal nerve (CPN) can be identified. In particular, it is located medial to the biceps tendon, which gives off the lateral sural cutaneous nerve (LSCN) at this level. The superficial dissection ends at the plane between lateral gastrocnemius muscle with LSCN in the lateral side and biceps femoris tendon with CPN medial. It is important to know that lateral gastrocnemius is the most medial structure in this approach. Distally, the soleus is encountered at its origin on the posterolateral tibia and fibula. Blunt elevation of the soleus will provide exposure of the proximal tibia. Moreover, the anterior tibial artery should



be protected in this area, because it travels to the anterior compartment, and the common peroneal nerve. The popliteus tendon is carefully mobilized, protecting the inferolateral genicular artery from injury. Finally, submeniscus arthrotomy can be performed for better visualization of the articular surface. If more exposure is needed, transverse osteotomy of the fibular neck can be performed.

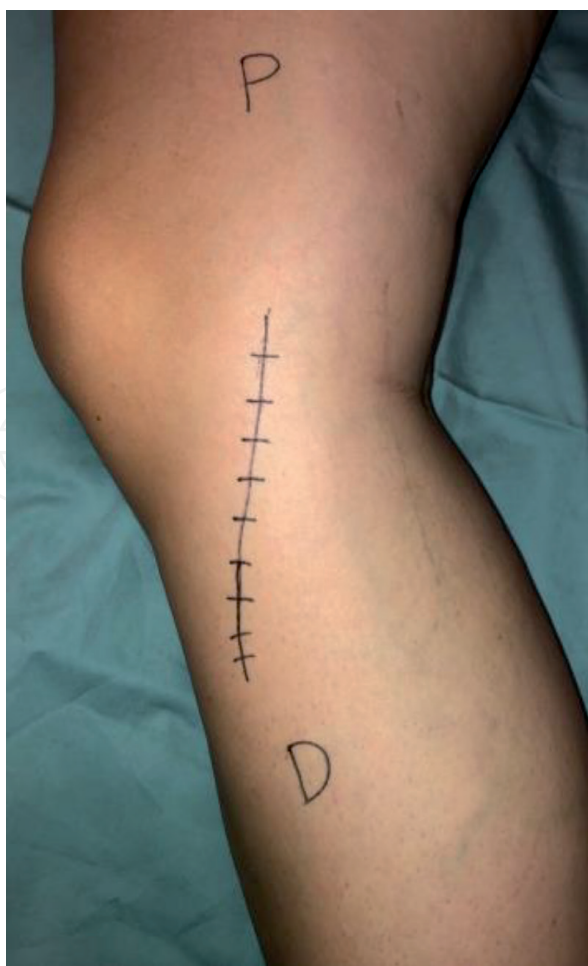A modification of this approach was described by Solomon, with an incision along the anterior border of biceps femoris and an osteotomy of the fibula [8]. This provides the opportunity to retract the fibular head, the lateral collateral ligament, and the biceps femoris upward.

The patient may be placed in the prone, supine, or lateral decubitus position based on the patient's other injuries and the surgeon's preference.

### 2.3 Medial approach

The medial approach is used when an anteromedial fracture pattern of tibial plateau occurs [5]. It is difficult with this approach to obtain a good access of the articular surface without injuring the medial collateral ligament. The adductor tubercle and the medial border of the tibial crest are very important landmarks for this procedure [5].

The skin incision begins from the medial femoral epicondyle, about 2–3 cm over the joint line, and ends 2 cm posterior to the tibial crest, depending on fracture extension. The knee must be flexed about 15°–20° before proceeding with this skin incision (**Figure 3**). The superficial dissection includes the sartorius fascia, which is incised in a straight line similar to the skin. Next, the gracilis and semitendinosus



**Figure 3.**  
*Skin incision for medial approach.*

tendons are identified, which arise posteriorly creating together with the sartorius the pes anserinus in the anteromedial tibia. In regard to the deep dissection, three layers exist in this area [5]. The first is the pes anserinus tendons posterior and proximal, the second is the superficial medial collateral ligament, and the third is the deep medial collateral ligament. The first and second layers can be cut off during this procedure and should be repaired after fracture fixation. The deep medial collateral can be incised by making an arthrotomy for articular surface visualization. In most cases, fracture reduction is carried out without an arthrotomy because it can be subsequently confirmed by fluoroscopic imaging.

#### **Structures in danger**

- Infrapatellar branch of saphenous nerve
- Saphenous vein
- Medial inferior genicular artery
- Popliteal artery

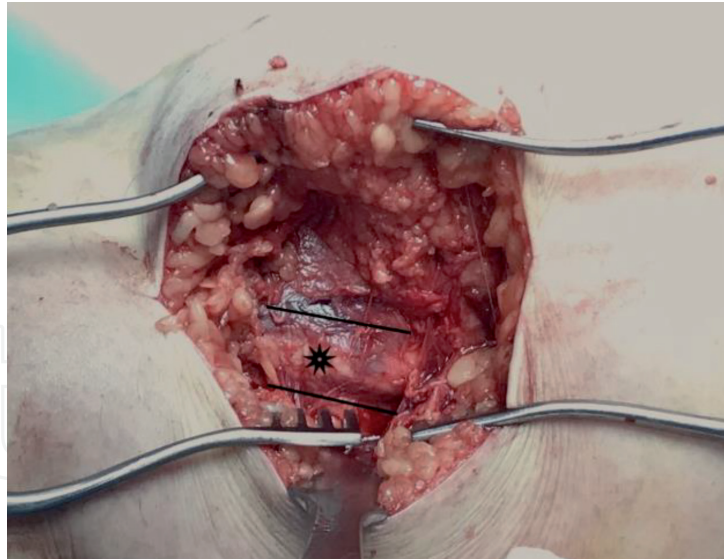
The patient's position is either supine with the knee flexed ( $\sim 50^{\circ}$ – $60^{\circ}$ ), the ipsilateral hip external rotated and abducted or in a "leg-holter" position.

### **2.4 Posteromedial approach**

The posteromedial approach is mainly used for shear or coronal fractures of the medial tibial plateau [13]. It is an ideal approach because it gives the opportunity to place an antglide plate for better fixation of this type of fractures. Moreover, it can be done in either the supine or prone position. The prone position has the main advantage of being more comfortable for the surgeon. This is not recommended in dual approach strategies such as performed for concurrent lateral and medial plateau fractures, because of the need for the patient's repositioning.

In posteromedial approach in supine position [13], the surgeon should stand on the opposite side of the injured leg. The important landmarks for the incision are the medial femoral epicondyle proximal and the posterior tibial border distally. For this approach, it is important to obtain a  $30^{\circ}$  knee flexion and external rotation of the ipsilateral hip for better access of the posteromedial area. Regarding superficial dissection, the skin incision is about 8 cm, and the sartorius fascia is incised between the medial gastrocnemius posteriorly and the pes anserinus anteriorly (**Figure 4**). The saphenous nerve runs just anterior to the great saphenous vein. The medial collateral ligament lies deeper than the pes anserinus and therefore cannot be injured during this approach. The semimembranosus and the popliteus muscle insertion in the posterior tibia can be released off the bone using subperiosteal dissection for better access of the fracture area. Moreover, submeniscal arthrotomy can be done to visualize the joint directly, and sutures may be placed into the meniscus for retraction. Finally, fluoroscopic imaging is necessary to confirm the appropriate reduction of the articular surface [5].

On the other hand, the posteromedial approach in prone position was initially described in 2003 [14]. For this procedure, it is important to place a folded blanket under the ipsilateral femur allowing leg hyperextension for easier fracture reduction as mentioned by Moore. The skin incision is about 2 cm posterior and lateral than in the supine position. Its length is 8–10 cm running along the medial border of the medial gastrocnemius. The medial gastrocnemius is then



**Figure 4.**  
*The asterisk is pes anserinus tendon. Above this structure is the line for the posteromedial access between pes anserinus and medial gastrocnemius.*

retracted laterally developing the interval between the medial gastrocnemius and the semimembranosus. The pes tendons are placed intact anteriorly. The deep dissection continues with the subperiosteal elevation of the popliteus muscle off its insertion in the posterolateral area of tibia. Finally, modifications of this approach exist that provide additional lateral exposure such as the “S-type” procedure [15].

#### **Structures in danger**

- Short saphenous vein
- Peroneal artery and branches
- Posterior tibial artery and nerve

### **2.5 Direct posterior approach**

The direct posterior approach is rarely used for tibial plateau fractures. The fracture pattern treated with this approach is a shear posterior bicondylar plateau's fracture with the main fracture line in coronal plane. This method has an important disadvantage when compared to other surgical incisions, and there is a higher risk for iatrogenic injury of neurovascular structures in the popliteal fossa.

#### **Structures in danger**

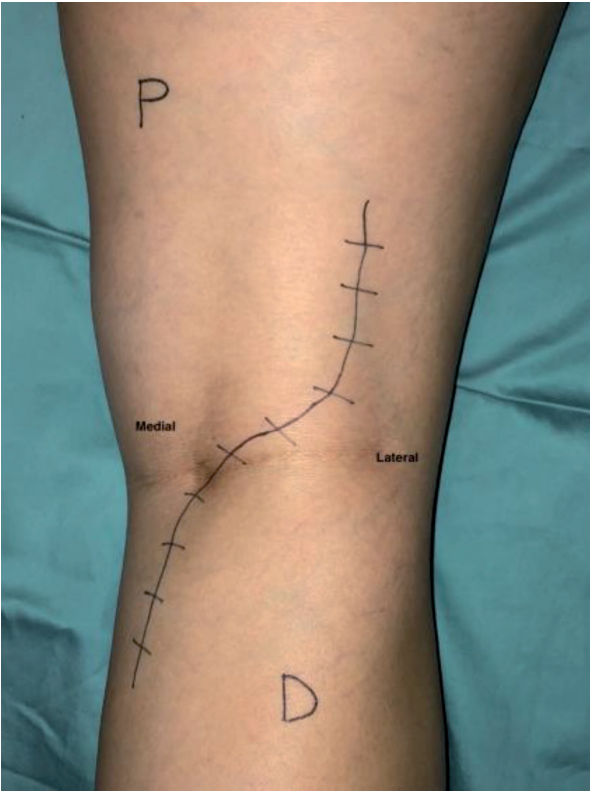
- Popliteal artery
- Tibial nerve
- Sural nerve and short saphenous vein

Posterior approach was first announced in 1945 as a midline incision through popliteal fossa by Abbott and Carpenter. Many variations have been published over

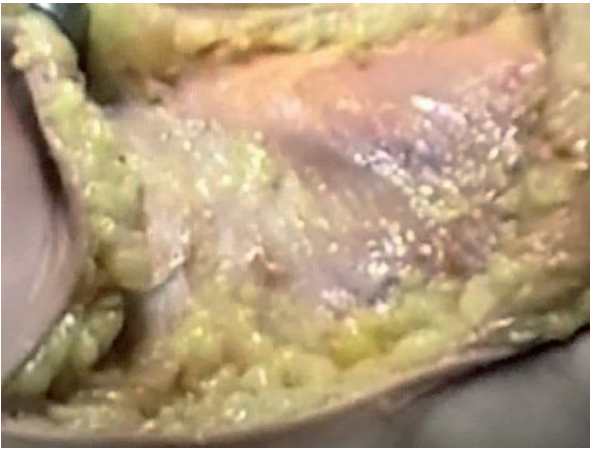


the years of the classic technique as “S – shape” [5], “L – type” incision [16], and lastly the “FCR” approach to the knee [17].

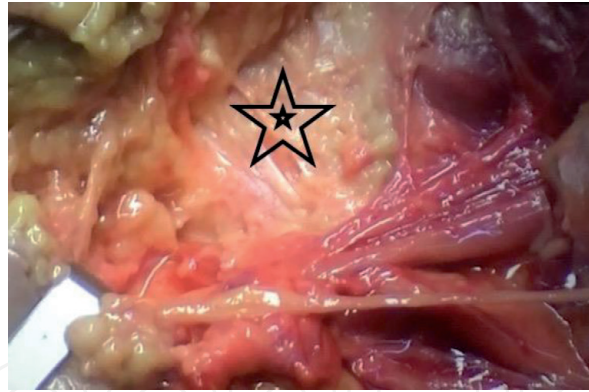
An “S-shape” skin incision is made from proximal-lateral to distal-medial. In this incision, the important landmarks are the Biceps Femoris proximal, the popliteal fossa at the joint line, and the medial head of the gastrocnemius distally (**Figure 5**). We should be attentive in the superficial dissection because underneath the skin lies the lesser saphenous vein and the sural nerve, which rests immediately lateral to the vein (**Figure 6**). The deep fascia is incised, and the sural nerve may be followed proximally helping the surgeon to identify the tibial nerve. The tibial nerve lies superficial and slightly lateral to the popliteal vein and artery. The popliteal fossa is recognized proximally between the medial and lateral heads of the gastrocnemius and distally between the medial border of biceps femoris and the lateral border of semimembranosus. Underneath the biceps femoris is the common peroneal nerve,



**Figure 5.**  
*Skin incision for direct posterior approach.*



**Figure 6.**  
*The skin was mobilized and was identified the lesser saphenous vein and the sural nerve.*



**Figure 7.**  
*The posterior capsule of knee.*

which is separated from the sciatic nerve just proximal to the joint line. Depending on the fracture pattern, the deep dissection may be continued either posteromedial or posterolateral as we described above (**Figure 7**). The landmarks are Biceps femoris, the lateral and the medial gastrocnemius, and the semimembranosus tendon.

An “L-shape” incision starts superiorly and medially at the popliteus space parallel to Langer’s line. A vertical skin incision begins at the medial corner of the popliteal fossa and extends distally. Full-thickness fasciocutaneous flaps are raised protecting the sural nerve and lesser saphenous vein. The medial head of the gastrocnemius should be retracted laterally, protecting the neurovascular structures and exposing the knee capsule. The deep dissection should be done beneath the popliteus muscle in the proximal part from medial to lateral. Subsequently, the popliteus and the soleus origins are mobilized for better visualization of the posterior tibial plateau. In most cases, the entire posterior part of the tibia can be exposed without cutting the medial head of the gastrocnemius [16].

This procedure is performed with the patient in prone position and the knee slightly flexed using a bump under the ankle.

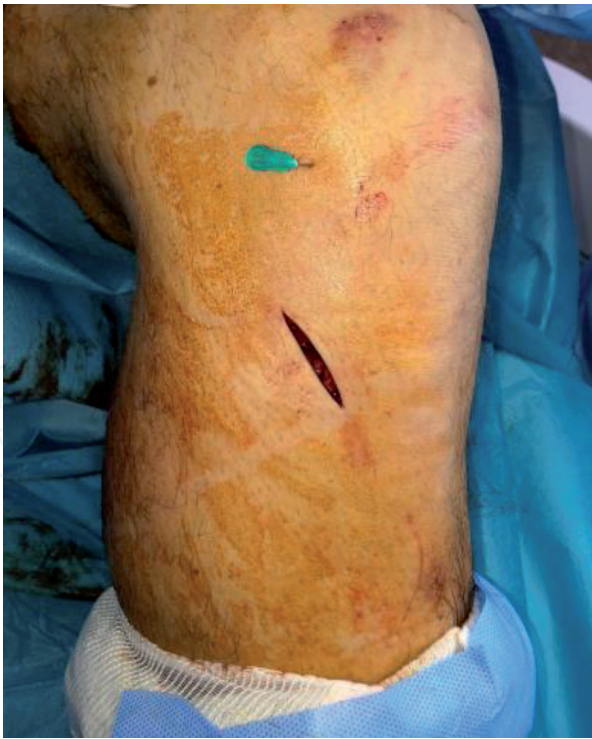## 2.6 Percutaneous approach

The percutaneous approach is applied to tibial fractures with either small split of the articular surface (Schatzker I classification) or a pure depression of the lateral tibial plateau (Schatzker III classification). The incisions are about 1–2 cm in length, and fluoroscopy or arthroscopy imaging is vital for this procedure.

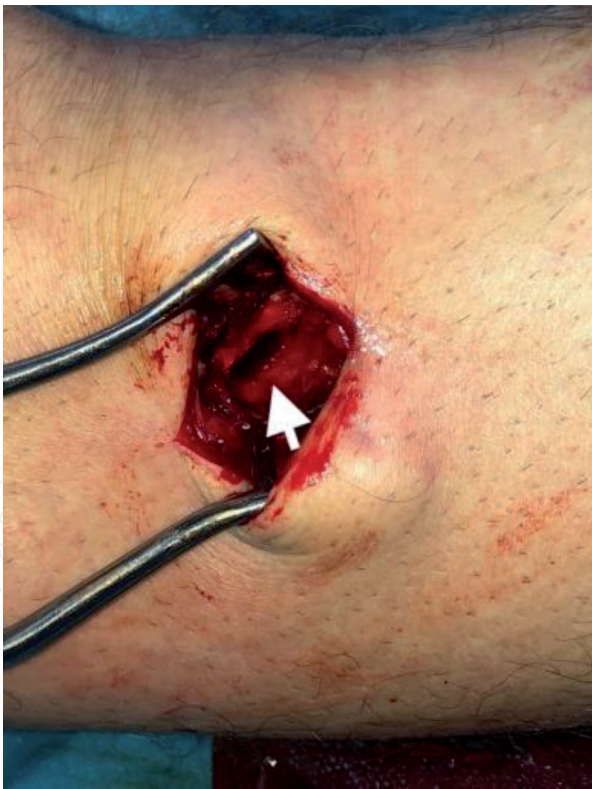Percutaneous reduction should be made with a bone tamp, with percutaneous application of bone-holding forceps, and with the joystick technique and ligamentotaxis [18].

Reduction of tibial plateau fractures with small split is achieved by inserting a clamp with its ends on the lateral and medial sides, approximately 1 or 2 cm below the articular surface. The 6.5–7.3 mm cannulated screws are then placed parallel to the articular line. According to the literature, the minimal number of screws required for this procedure is three [18]. Washers are a good choice for better compressing the fracture line.

The reduction of fractures with a slight depression of the articular surface is performed by the mini-open technique. This consists of a small vertical incision on the skin (2 cm) on the lateral or medial side of the tibial metaphysis (**Figure 8**). Through this incision, a bone window is opened into the cortex, and a bone tamp is pushed for the reduction of the articulated surface (**Figure 9**). The gap that is created can be filled either with bone autografts or allografts or with calcium phosphate bone cement to support the articular surface. It is recommended to overcorrect the fracture.



**Figure 8.**  
*Skin incision for lateral plateau fracture with percutaneous approach.*



**Figure 9.**  
*Bone window in the cortex.*

Radiological imaging or arthroscopic visualization of the articular surface of the tibia may be performed to evaluate adequate reduction. There are a lot of meta-analyses in the international literature, which indicate that arthroscopic fracture reduction rather than open arthrotomy achieves better functional outcomes in patients [19]. More than 10 mm of plateau depression presents an increased risk of lateral meniscus tear [20]. Therefore, slight depressed monocondylar fractures



should be examined with arthroscopy after fracture reduction. It is crucial to acknowledge that knee arthroscopy can cause post-operative compartment syndrome due to fluid escaping into the tibia compartments.

Moreover, fixation plates can be used for fracture fixation, with less bone exposure. In 1989, Mast et al. [21] described the “indirect reduction” technique, thus minimizing the soft tissue damage. Subsequently, in 1997, the minimally invasive plate osteosynthesis was introduced (MIPO) by Wenda [22] and Krettek [23]. An abundance of studies followed in the international literature describes the MIPO technique and compares the advantages and disadvantages of this new method. This procedure includes small skin incisions, the application through these of the fixation plate, and furthermore percutaneous screw placing. Fracture reduction is achieved by distraction using either a distractor, a tension device, or a lamina spreader.

The main advantages of percutaneous approach and MIPO technique are risk reduction of wound complications due to minimal soft tissue damage during surgical dissection and biological fracture healing by preserving the vascularity of the bone [19]. Furthermore, this technique offers paramount benefits such as less blood loss, earlier functional rehabilitation, and shorter hospitalization [19].

### 3. Conclusion

Tibial plateau fractures are very common, and orthopedic surgeons should be familiar with this kind of injury. Classic surgical approaches are the lateral, the posterolateral, the medial, the posteromedial, and the direct posterior. Many variations of these techniques have been developed over the years. Nowadays, percutaneous approaches and MIPO techniques are gaining ground but only after specific indications. Before choosing the appropriate approach, it is necessary to evaluate the fracture pattern either with sufficient X-rays or CT scans.

### Author details

Katsimentzas Triantafyllos<sup>1\*</sup>, Tryfon Ditsios<sup>2\*</sup> and Kostantinos Ditsios<sup>1\*</sup>

<sup>1</sup> 2<sup>nd</sup> Orthopaedic Department Aristotle University of Thessaloniki, G. Gennimatas Hospital, Thessaloniki, Greece

<sup>2</sup> Medical University of Sofia, Sofia, Bulgaria

\*Address all correspondence to: [triantafyllos\\_katsimentzas@hotmail.com](mailto:triantafyllos_katsimentzas@hotmail.com), [tryfonditsios@gmail.com](mailto:tryfonditsios@gmail.com) and [ditsiosk@otenet.gr](mailto:ditsiosk@otenet.gr)

### IntechOpen

© 2020 The Author(s). Licensee IntechOpen. This chapter is distributed under the terms of the Creative Commons Attribution License (<http://creativecommons.org/licenses/by/3.0>), which permits unrestricted use, distribution, and reproduction in any medium, provided the original work is properly cited. 



## References

- [1] Rasmus Elsoe SEO, Larsen P, Nielsen NPH, Swenne J, Rasmussen S. Population-based epidemiology of tibial plateau fractures. *Orthopedics*. 2015;**38**(9):18-22
- [2] Virkus WW, Berkson EM. High-energy tibial plateau fractures. *The Journal of the American Academy of Orthopaedic Surgeons*. 2006;**14**(1):20-31
- [3] Tang HC et al. Correlation of parameters on preoperative CT images with intra-articular soft-tissue injuries in acute tibial plateau fractures: A review of 132 patients receiving ARIF. *Injury*. 2017;**48**(3):745-750
- [4] Wasserstein D, et al. Risk of total knee arthroplasty after operatively. *The Journal of Bone and Joint Surgery American*. 2014;**96**:144-150
- [5] Kandemir U, Maclean J. Surgical approaches for tibial plateau fractures. *The Journal of Knee Surgery*. 2014;**27**(1):21-29
- [6] Padanilam TG, Ebraheim NA, Frogameni A. Meniscal detachment to approach lateral tibial plateau fractures. *Clinical Orthopaedics and Related Research*. 1995;**314**:192-198
- [7] Krause M, Müller G, Frosch KH. Surgical approaches to tibial plateau fractures. *Unfallchirurg*. 2018;**121**(7):569-582
- [8] Solomon LB, Stevenson AW, Lee YC, Baird RPV, Howie DW. Posterolateral and anterolateral approaches to unicondylar posterolateral tibial plateau fractures: A comparative study. *Injury*. 2013;**44**(11):1561-1568
- [9] Bowers AL, Huffman GR. Lateral femoral epicondylar osteotomy: An extensile posterolateral knee approach. *Clinical Orthopaedics and Related Research*. 2008;**466**(7):1671-1677
- [10] Yoon YC, Sim JA, Kim DH, Lee BK. Combined lateral femoral epicondylar osteotomy and a submeniscal approach for the treatment of a tibial plateau fracture involving the posterolateral quadrant. *Injury*. 2015;**46**(2):422-426
- [11] Lobenhoffer P, Gerich T, Bertram T, Lattermann C, Pohlemann T, Tscherne H. Spezielle posteromediale und posterolaterale zugänge zur versorgung von tibiakopffrakturen. *Unfallchirurg*. 1997;**100**(12):957-967
- [12] Frosch KH, Balcerek P, Walde T, Stürmer KM. A new posterolateral approach without fibula osteotomy for the treatment of tibial plateau fractures. *Journal of Orthopaedic Trauma*. 2010;**24**(8):515-520
- [13] Weil YA, Gardner MJ, Boraiah S, Helfet DL, Lorch DG. Posteromedial supine approach for reduction and fixation of medial and bicondylar tibial plateau fractures. *Journal of Orthopaedic Trauma*. 2008;**22**(5):357-362
- [14] Galla M, Lobenhoffer P. Der direkte dorsale zugangsweg zur versorgung posteromedialer luxationsfrakturen des tibiakopfes. *Unfallchirurg*. 2003;**106**(3):241-247
- [15] De Boeck H, Opdecam P. Posteromedial tibial plateau fractures: Operative treatment by posterior approach. *Clinical Orthopaedics and Related Research*. 1995;**320**:125-128
- [16] He X et al. A posterior inverted L-shaped approach for the treatment of posterior bicondylar tibial plateau fractures. *Archives of Orthopaedic and Trauma Surgery*. 2013;**133**(1):23-28
- [17] Berwin JT, Donovan RL, Riddick A, Kelly MB. The 'FCR' approach to the knee for the management of posterior tibial plateau fractures. *Journal of*

Orthopaedic Trauma. 2019 [Ahead of print]

[18] Chang HR, Yu YY, Ju LL, Le Zheng Z, Chen W, Zhang YZ. Percutaneous reduction and internal fixation for monocondylar fractures of tibial plateau: A systematic review. *Orthopaedic Surgery*. 2018;**10**(2):77-83

[19] Wang Y, Wang J, Tang J, Zhou F, Yang L, Wu J. Arthroscopy assisted reduction percutaneous internal fixation versus open reduction internal fixation for low energy tibia plateau fractures. *Scientific Reports*. 2018;**8**(1):1-9

[20] Ringus V, Lemley F, Hubbard D, Wearden S, Jones D. Lateral tibial plateau fracture depression as a predictor of lateral meniscus pathology. *Orthopaedics*. 2010;**33**(2):80-84

[21] Ganz R, Mast J, Jakob R, Planning and Reduction Technique in Fracture Surgery. 1989

[22] Wenda K, Runkel M, Degreif J, Rudig L. Minimally invasive plate fixation in femoral shaft fractures. *Injury*. 1997;**28**(Suppl 1):13-19

[23] Krettek C, Schandelmaier P, Miclau T, Tscherne H. Minimally invasive percutaneous plate osteosynthesis (MIPPO) using the DCS in proximal and distal femoral fracture. *Injury*. 1997;**28**(Suppl 1):20-30