

We are IntechOpen, the world's leading publisher of Open Access books Built by scientists, for scientists

6,900

Open access books available

185,000

International authors and editors

200M

Downloads

Our authors are among the

154

Countries delivered to

TOP 1%

most cited scientists

12.2%

Contributors from top 500 universities



WEB OF SCIENCE™

Selection of our books indexed in the Book Citation Index
in Web of Science™ Core Collection (BKCI)

Interested in publishing with us?
Contact book.department@intechopen.com

Numbers displayed above are based on latest data collected.
For more information visit www.intechopen.com



Combining PDO Threads with Exosomes for Microlifting

Diane Irvine Duncan

Abstract

A recent survey of practicing plastic surgeons showed that regenerative medicine is the current top interest of esthetic consumers worldwide. Patients are frequently requesting correction of small regions, instead of opting for an all-encompassing procedure associated with prolonged recovery time. Thus, the field of “microlifting” has emerged. This is a new approach in which minimally invasive procedures can be utilized to accomplish outcomes formerly reserved for traditional surgery. The combination of polydioxanone (PDO) threads and topical exosomes is a method of treating both underlying soft tissue laxity and the surface of aging skin. The application of exosomes can deliver topical growth factors and targeted peptides to assist in rapid skin surface healing. More than a simple delivery vesicle, exosomes communicate with cells at the recipient site and can induce cellular change. PDO threads can be used subcutaneously as both a suspension device and regenerative biostimulatory device. Usually resorbed at 6 months post-insertion, these threads leave behind a linear network of collagen and elastin fibers that remains long after the polydioxanone is gone. Combination therapies can target several concerns when performed simultaneously. This regenerative method is well accepted by patients due to minimal cost and recovery time.

Keywords: injectable implant, threadlift, exosomes, particulate drug delivery, growth factors, PDO threads, filler threads

1. Introduction

The number of practitioners joining the esthetic field is increasing rapidly. These specialists range in background and training from aestheticians, chiropractors, and acupuncturists to dentists, dermatologists, facial plastic, and plastic surgeons. While more patients are seeking treatment for concerns regarding facial and body region challenges, few desire traditional surgical intervention with the associated risk and recovery time. Regional differences dictate the preferences of the clientele, but many do seek the restoration of their own youthful appearance instead of a drastic change. In years past, the emergence of stem cell therapy has been viewed by many as a magic wand that could restore aging tissues to a youthful state without surgical intervention. Some limitations to treatment with mesenchymal stem cells (MSCs) include a low survival rate, tumorigenicity, poor “take,” and lack of efficacy [1]. It is thought that many of the supposed effects of mesenchymal stem cells are indeed paracrine effects,

mediated by acellular factors that are transmitted with the cells, but not by direct effects of the cells themselves [2]. For several years, filler companies have focused on biostimulatory effects seen after the hyaluronic acid, hydroxyapatite, or other fillers have been metabolized [3, 4]. The injectable poly-L-lactic acid works on this principle. A problem can occur when so much filler has been injected that the response turns from collagen stimulation to fibrosis. Some long-term injectable patients note a “woody” or stiff feeling, difficulty achieving a natural animated expression, and chronic swelling in a treatment region years after the original product was injected. A preferred solution would be induction of an existing tissue response using regenerative options now available and in development. Restoration of dermal thickness, collagen, and elastin and self-repair of the adipose framework upon which the skin rests are concepts that make sense to our esthetic customer base.

2. Background

Exosomes, also known as secretomes [5], are formed within the cell from multivesicular endosomes. Intracellular endosomes contain multiple small vesicles measuring 20–200 nm. These multivesicular bodies fuse with the cellular plasma membrane, and exocytosis releases spherical particulate carriers now identified as exosomes. These acellular bilamellar structures contain miRNA, mRNA, and peptides. Exosomes are identified by biomarkers CD9, CD63, CD81, Alix, Tsg101, and flotillin-1. The production of exosomes in a laboratory involves the use of conditioned media (CM) in a cell culture setting. Usually MSCs are the cells cultured. Exosomes can express characteristics of the cells of origin, so directed wound care exosomes might be harvested from conditioned media used in a co-culture of dermal fibroblasts and adipose-derived stem cells (ADSCs). Cell-to-cell communication currently appears to be more important in achieving a desired effect than in achieving the direct effect of MSCs themselves [6]. An example of this has been seen in a co-culture of dermal fibroblasts and mesenchymal stem cells. The formation of “nanotunnels” from cell to cell is seen, so cell signaling is somewhat direct. The ability to transfer information can also be seen with the endosome/exosome route [7]. Transfection of gene products or small peptides through the lipid bilayer of the exosome to recipient cells can induce those cells to change cellular characteristics [8]. STAT3 is found in exosomes and promotes angiogenesis, improves fibroblast proliferation, and decreases the amount of time needed to heal an injury [9]. In regenerative medicine, it has been noted that paracrine signaling can generate up to 91% of the effects of injected stem cells [10]. Thus, the use of exosomes obtained from conditioned media used in cell culture has rapidly become popular in many specialties including cardiology, orthopedics, oncology, and the esthetic field [11]. Esthetic applications include topical application following nonthermal microneedling, RF microneedling, fractional laser resurfacing, and plasma-driven resurfacing. In these instances, reduction of downtime and improvement in skin tone and texture have been noted [12]. The FDA issued a statement [13] in December 2019 that, as yet, no exosomes have been cleared by the agency; therefore, topical use only is advised. Because the product is acellular, many companies producing these products note that they are exempt from FDA scrutiny or GMP manufacturing processes. However, since the FDA classifies any biological that is intended to penetrate the stratum corneum in order to change the structure or function of any aspect of the human body as a drug, practitioners who inject exosomes are violating FDA guidelines [14].

Polydioxanone (PDO) threads have become popular worldwide over a period of approximately 5 years. These threads can be used in place of fillers for such purposes as dorsal nasal augmentation, improvement of deep dermal or superficial hypodermal defects, and focal depressions. Improvement of skin laxity by using barbed threads as suspension devices is also growing again in popularity. While barbed threads originated more than 20 years ago, the early devices were created by hand cutting existing sutures, creating a weak spot at the base of the cut in the thinnest area of the suture diameter. Early threads were notorious for breakage, extrusion, and “cheese wiring” or cutting through soft tissue to extrude through the skin [15]. The “lunchtime facelift” was performed using percutaneous threads that could create bunching and superficial contour irregularities. Patients noted either little result in many cases or complained about the lack of longevity. The use of permanent sutures resulted in a mixture of good and not so good results. This history parallels that of permanent fillers: an irreversible outcome has no easy solution if a problem arises [16]. Thus, many practitioners are now choosing threads that are resorbable over time.

Because regeneration of the subcutaneous layer is as important as skin rejuvenation, the emphasis on biostimulatory products has increased during recent years. Erosion of the collagen matrix that binds the adipose framework supporting the overlying skin has been well documented (**Figure 1**). Restoration of the collagen and elastin fraction of the fibroseptal network has been noted primarily with radiofrequency-assisted soft tissue stimulation [17]. Poly-L-lactic acid can also stimulate collagen formation over time. Because it is sometimes difficult to get the compound into solution and because it is somewhat expensive to the consumer, widespread adoption of this injectable has lagged behind acceptance of HA and hydroxylapatite fillers. Late granuloma formation is also a deterrent to its use [18]. First popularized in Asia, PDO (polydioxanone) threads [19] have been rapidly accepted in that part of the world. Advantages include longevity similar to that of fillers with a significantly lower product cost. Ease of administration is a plus, and the lack of intravascular accidents due to the mechanics of threads offers a superior safety profile. PDO threads are available in several styles. “Mono” threads are used in the deep dermis or in the superficial hypodermis. They are usually injected in a stacked pattern (nasal dorsum) for filling volume-deficient regions. They can also be placed in a crosshatched “woven” pattern to stimulate soft tissue neocollagenesis in a pattern similar to that of Sculptra. The effect of small diameter threads can be subtle, but these are excellent for use in patients with very thin skin.

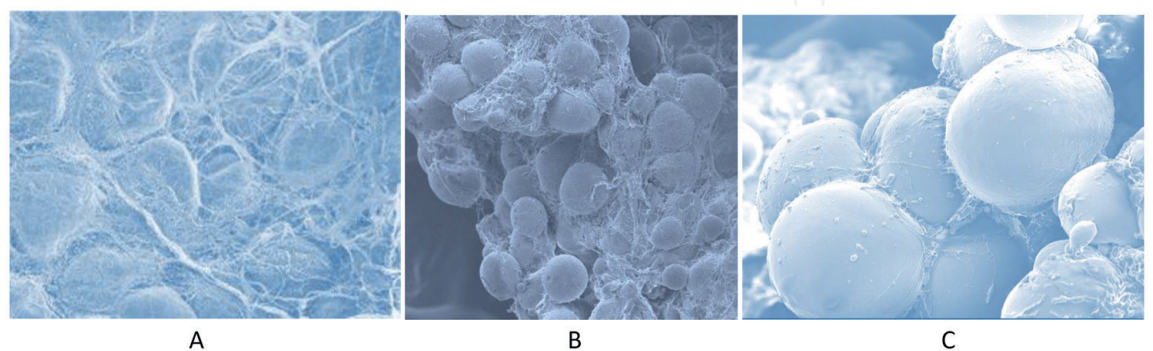


Figure 1. Scanning electron micrographs of aging adipose tissue. (A) A 23-year-old shows a dense three-dimensional “net” of collagenous stroma forming a scaffold that holds adipose cells in a firm and defined shape. (B) In middle age an irregular erosion of this framework is apparent. (C) A 61-year-old patient shows complete loss of the fibroseptal network that shapes and supports the subcutaneous adipose layer.

Early manufacture of barbed threads involved several cuts after manufacturing of the suture, but this can cause weak points as noted, and therefore breakage can be problematic. Molded threads retain their central integrity, so tensile strength is improved. Cogs or cones can be used instead of or in addition to barbs in order to secure tissue attachment. A new double-coated polydioxanone thread combines these two modalities in order to strongly secure soft tissue. These threads have a 2-year effect; when the outer layer erodes and resorbs, the inner thread remains intact.

A new thread type unique to the Miracu (Mission Viejo, CA) company is known as Meshfill TM. These filler threads consist of 16 tiny woven PDO threads formed into a hollow cylinder. They can be used alone or in combination with fat or filler. When filled with the correct amount of complementary filler, the product can be contained in the cylinder's space. Meshfill can be stacked in area needing more volume, such as the cheeks or chin. When used with autologous fat transfer, the volume correction is retained as the fat becomes newly vascularized. Meshfill can be used in difficult-to-treat regions such as the infraorbital region and oral commissures.

3. Materials and methods

Topical exosomes are available in the USA from several commercial producers. Benev (Mission Viejo, CA) currently offers the most cost-effective version. Because the FDA considers any formulation intended to change the structure or function of a human that is administered deeper than the stratum corneum [14], the use of exosomes is now limited to cosmetic use as a topical application. The Benev formulation consists of two vials. One vial contains lyophilized exosomes that are to be reconstituted and are obtained from progenitor cells treated with conditioned media. The second vial of diluent contains hyaluronic acid, which is a strong hydrator, plus multiple growth factors and small peptides. Once mixed, the preparation should be refrigerated. The solution can be applied topically to the skin on label. Exosomes are also used following treatment with microneedling, nitrogen plasma resurfacing, application of radiofrequency energy, fractional laser, and dermaplaning in order to optimize rapid healing. Ideally several serial applications should be made in order to obtain the most benefit.

PDO threads can be added to the skin treatment in order to improve the tone and laxity of the subcutaneous layer. The biostimulatory nature of PDO threads is seen in **Figure 2**. A small collagenous tunnel develops over 1 month, surrounding the thread as it gradually resorbs. This soft tissue support remains after the thread itself disappears. Most esthetic practitioners employ combination treatments in order to optimize outcomes for their aging patients, as a single solution generally does not address all defects. Three areas of subcutaneous improvement can be targeted. Problems addressed include mild to moderate soft tissue atrophy; this type of defect may be best treated with mono threads. Soft tissue laxity and mild to moderate pendulosity of the jowls and nasolabial folds are usually addressed with barbed threads. The longer lasting threads are recommended for use by skilled practitioners as these can be difficult to remove. Focal volumetric defects such as prejowl sulcus, gonial notching, a retrusive chin, drooping oral commissures, infraorbital hollowing, and the depression associated with malar bags all respond well to Meshfill injection. Excellent correction of deep nasolabial folds is also seen with Meshfill.

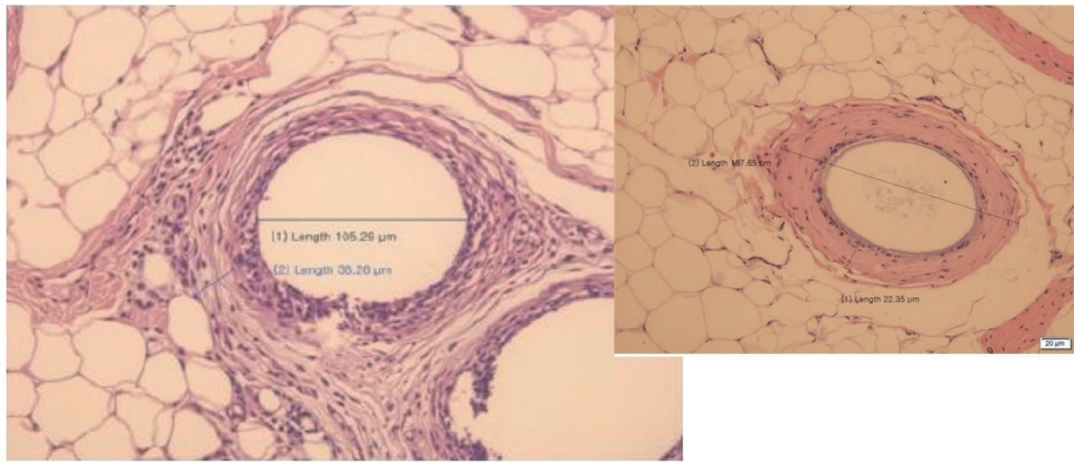


Figure 2.
 Polydioxanone thread hollow and granulation tissue with newly made collagen fibers, 1 month after thread insertion, White Yucatan pig study. Source: Research by Yonsei Clinical Medicine Research Center, Dr. Junghyun Yoon, and Dr. Sangseob Kim with N-Finders Co., Ltd.

The patient should be marked in the upright position prior to thread insertion. Injection can be performed either upright or in a semirecumbent position. However, when tightening barbed threads, this is best done while the patient is upright. Markings are performed with a brow pencil prior to thread insertion. The vector of tightening is calculated. Generally, two or three threads are needed per region for optimal effect. Application of topical anesthesia prior to treatment is routinely performed. Removal of the topical anesthetic along with sterile prep and drape is the standard of care. Hair is contained so that thread contact is minimized. While mono threads are commonly injected without local anesthetic, a small amount of intradermal local anesthesia greatly improves patient comfort. With barbed thread insertion and Meshfill injection, it is recommended to numb both the insertion site and the line or track along which the thread will be placed. Only a small amount of lidocaine is needed per region. The use of 0.5 or 1% lidocaine with epinephrine will minimize bruising if injected in full 3 minutes prior to thread insertion. An insertion point for the cannula is placed approximately 0.5–1 cm proximal to the region to be filled. Thus, the thread should be held in place over the treatment target prior to choosing an access point, in order to be sure the thread length is correct. The importance of this point cannot be overstated. If not injected well beyond the actual treatment target, threads can migrate, and the ends can create a superficial deformity.

4. Results

Combination therapy, especially when performing microlifting, generally produces a more profound improvement than when using a single treatment modality. Triple treatments for face and neck rejuvenation in patients seeking minimal recovery time include light fractional resurfacing or nitrogen plasma resurfacing, application of exosomes to the treatment region for enhanced outcome and rapid healing, and volumization and tissue suspension with PDO threads. In many states, these treatments can be delegated to a licensed supervised provider.

It is recommended that only skilled physicians inject Meshfill or Line threads, as the treating provider should be able to take care of any potential complication that might occur.

Figure 3 illustrates the case of a 56-year-old patient who sought treatment for infraorbital hollowing. She had filler injections as well as autologous fat grafting. Her result following Meshfill injection plus fat introduced into the cylinder shows a dramatic correction in an area that is historically difficult to treat. Meshfill insertion in this region is below the orbicularis muscle at the level of the orbital rim. A 30 mm length was used in order to reduce the risk of thread visibility. In patients with lateral hollowing, the use of two shorter threads per region can yield more accurate placement than a single longer thread in this curved region.

Figure 4 shows a 74-year-old with drooping oral commissures and general volume loss. Meshfill was injected into the oral commissures in an “X” distribution so that the threads were stacked at the point of deepest depression. 30 mm threads were used at this location in combination with 0.2 cc Restylane

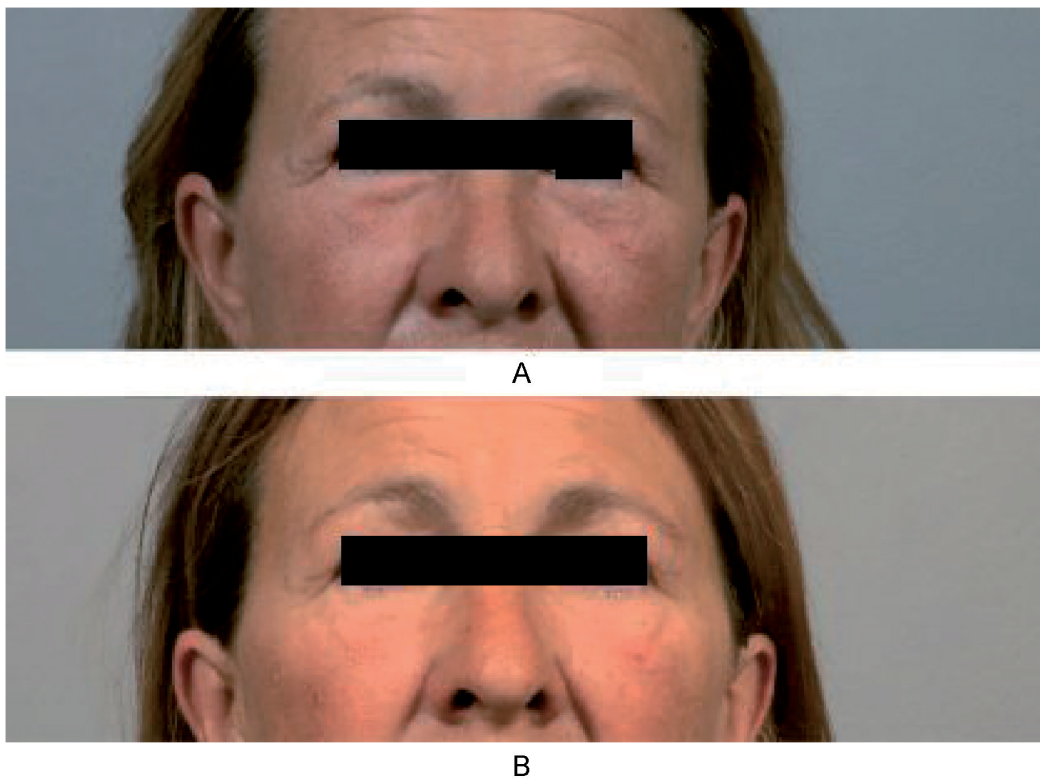


Figure 3.
(A) A 56-year-old patient before treatment. Previous infraorbital treatments included filler and fat grafting.
(B) The same patient 2 weeks postinjection of Meshfill PDO cylinders plus 0.2 cc hyaluronic acid filler per side.

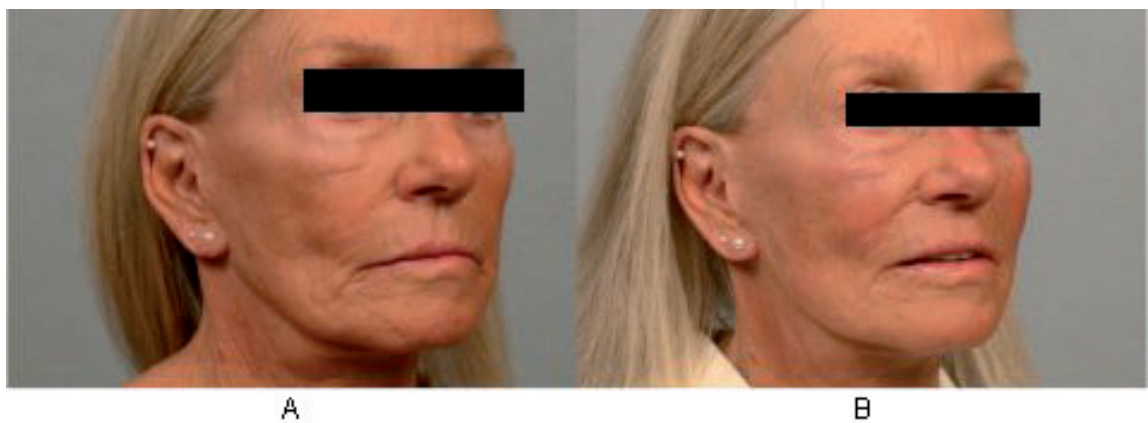

Figure 4.
(A) A 74-year-old patient with age-related soft tissue atrophy. (B) Two-week postinjection of Meshfill plus intraluminal injection of 0.2–0.3 cc HA filler per site: Cheeks, perioral, and infraorbital regions.

per injection site. 40 mm Meshfill was stacked in the malar region in order to achieve volumetric enhancement.

Figure 5 denotes a 53-year-old patient treated with a combination of barbed threads and Meshfill in the brow region. The often flat supraorbital rim can be contoured and lifted using this unique combination (**Figure 6**).

Figure 7 depicts the improvement in rapidity of healing that can be achieved by applying topical exosomes. Normally, fully ablative erbium laser resurfacing takes 7–10 days to fully re-epithelialize. This patient had full skin surface repopulation in 5 days. Application of exosomes, then Aquaphor ointment, was performed twice a day for 2 days.

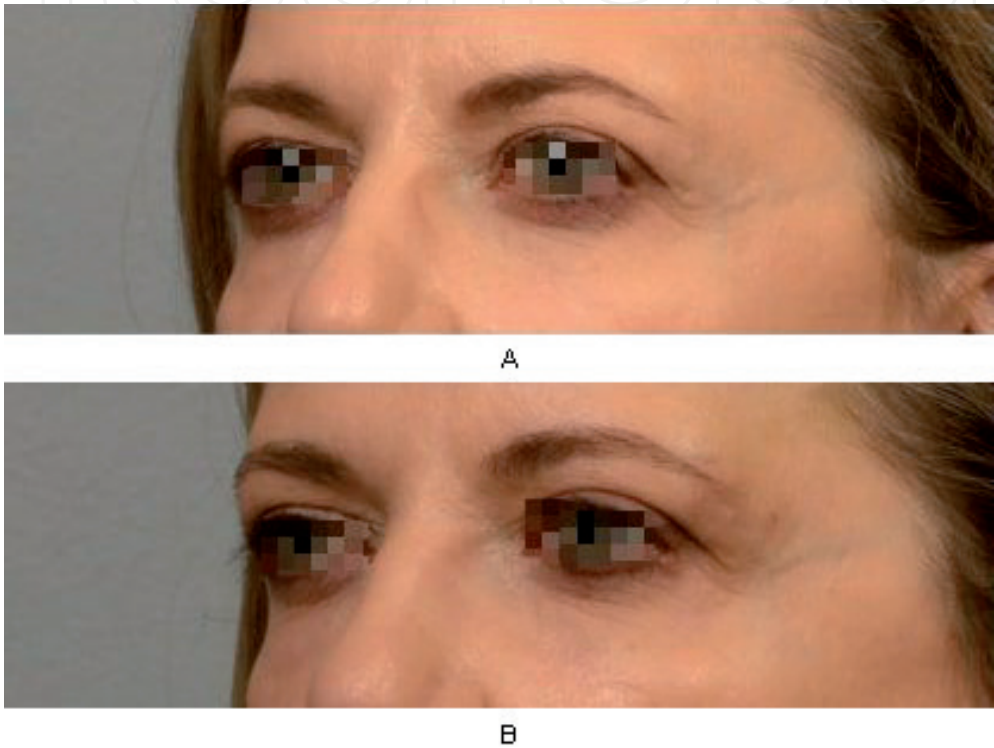


Figure 5.
(A) A 53-year-old patient noting a flattening of the supraorbital rim and loss of brow structure. (B) Two-week post-insertion of two PDO barbed threads per lateral brow plus injection of Meshfill and 0.3 cc HA filler underneath the brow itself.

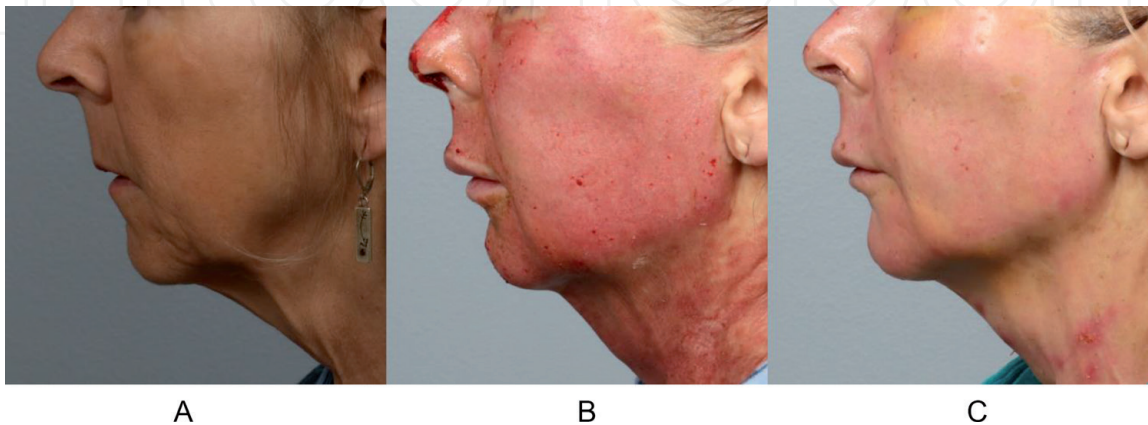


Figure 6.
(A) A 75-year-old before RF needling, laser resurfacing, fat grafting, and exosome application. (B) Two days post-treatment, most areas have re-epithelialized. Usually this process takes 6–8 days. (C) One month post-treatment, the patient's facial contour and jawline has changed dramatically. No surgical facelift was performed.

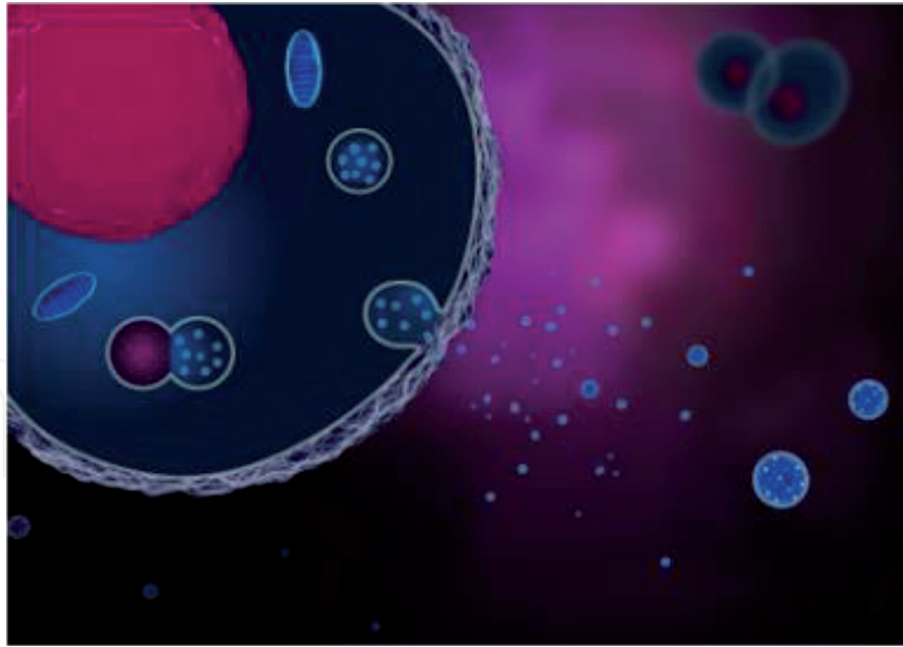


Figure 7.
Diagram of intracellular exosomes.

5. Discussion

Botulinum toxin and fillers have been the standard introductory maintenance treatment for the improvement of age-related lines and volumetric lines for many years. “Filler fatigue” is a growing phenomenon, especially when the cost of treatment is calculated. As with any repeated procedure, the cost is not only monetary. For most patients, time spent recovering from a procedure, which limits their ability to work or enjoy leisure activities, is a real concern. Many tend to choose a lesser procedure based solely on “down” time. The lack of longevity with filler and toxin injections is a common complaint. As patients age, many note that the problem they are experiencing cannot be adequately addressed with these two types of injections. Regenerative options are being sought as an alternative to standard approaches, as restoration of one’s own tissues is preferred to injecting toxins or foreign substances. Microlifting [20], a term coined by Tiryaki, is an approach that generally combines subcutaneous thread placement with other regenerative approaches.

While stem cell therapy is regarded as the highest form of regenerative medicine, recent research disputes that conventional wisdom. Many papers in different specialties note that cell-to-cell signaling has much more of an effect at the treatment target than the progenitor cells themselves do [21]. Exosomes are present in all tissues. They are formed when endosomes, or intracellular multivesicular particles, fuse with the cell’s plasma membrane. Smaller nanoparticulate vesicles “bud out” into the intercellular space (**Figure 8**). Exosomes are able to communicate with other cells without making direct contact. In the early 1980s, exosomes were thought to be a receptacle for intracellular waste. Named in 1987, exosomes [22] were found to be the messengers that transfer behavior instructions to a recipient cell located in the region. The “paracrine effect” is the way that exosomes communicate with target cells (**Figure 7**). These nanoparticles generally measure 20–100 microns and less than 0.1 micron. They reside within endosomes, which are multivesicular organelles located within the cell. After binding with the internal plasma membrane, these nanoparticles are released outside the cell. Able to communicate with multiple cells in the region, exosomes are capable of inducing a change in behavior of a nearby cell without depending on direct cell contact.

They contain messenger RNA, microRNA, proteins, lipids, cytokines, bioactive compounds, and nucleic acids [23]. **Figure 9** shows the formation of exosomes from intracellular endosomes. Exosomes have been shown to promote proliferation of the target cell and more rapid healing than with a PBS buffer or depleted media in vitro [24]. Repair of injury with exosomes was noted to be three times as fast as the injury

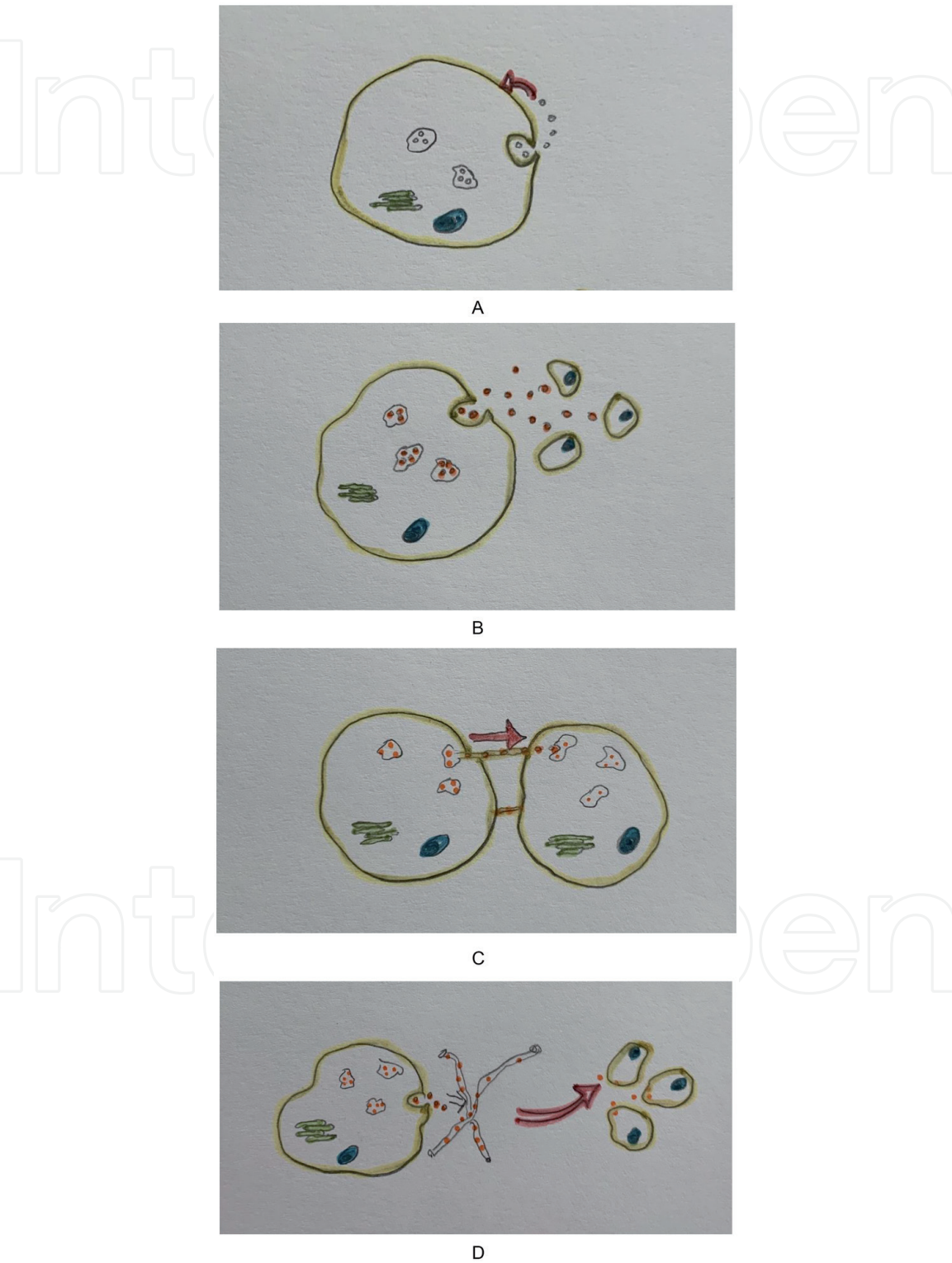


Figure 8.
(A) Autocrine signaling occurs when intracellularly derived particles influence the same cell at the extracellular membrane level. (B) Paracrine signaling occurs when exosomes are released into the extracellular fluid, thus influencing the behavior of cells within the local region. (C) Direct cell to cell communication can occur when adjacent cells build nanotunnels through which intracellular proteins and RNA is shared. (D) Endocrine signaling occurs when a substance such as a hormone enters the nearby bloodstream, influencing cellular behavior in a distant location.

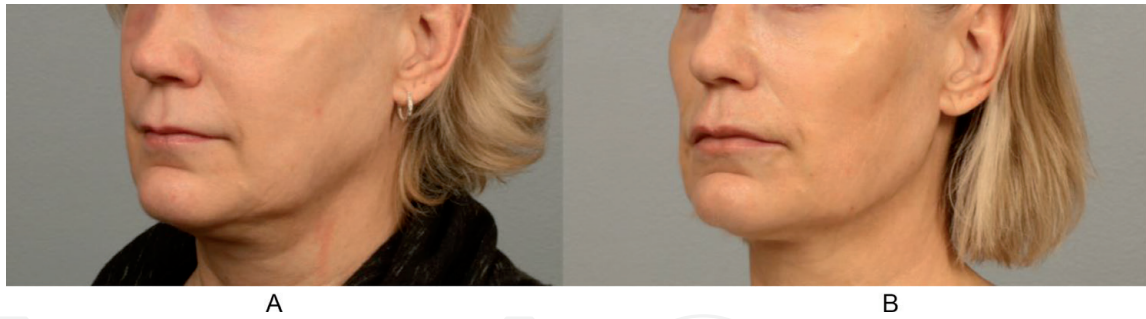


Figure 9. Clinical effect of exosomes. (A) A 62-year-old patient 2 days following ablative erbium laser resurfacing. (B) The same patient on day 5. Usually these patients require 7–10 days of healing in order to achieve re-epithelialization.

treated with buffer alone and two times as fast as the region treated with depleted media. The response was dose related; the dose of 10 mcg/ml seemed optimal in laboratory conditions. Clinical use of topical exosomes is noted to improve healing in patients who undergo fractional resurfacing procedures.

6. PDO threads

Alcarno was the first to use barbed threads and is given credit for his invention in 1964 [25]. These threads were hand cut and barbs were unidirectional. MacKenzie [26] is credited with the development of the bidirectional barbed thread. In the late 1980s, Sulamanidze noted the use of modified polypropylene sutures for subcutaneous facial lifting without skin excision [27]. Aptos threads were developed and became popular for improving soft tissue pendulosity since little downtime was required. While some patients experienced good results, many major complications were reported, including breakage, rippling, facial distortion, extrusion, infection, and cheese wiring of the suture through the skin [28]. Wu [29] developed his own version of a barbed thread and noted that all effects were lost over time; patients needed to repeat the procedure in order to retain benefit. Ruff was awarded a patent for developing a barbed thread in 1994, with his first prototype a weed whacker cord [30]. FDA clearance in the USA was achieved in 2004, when a polypropylene, then later a polydioxanone device, was developed by Quill. Shortly thereafter, the contour thread was withdrawn from the market. At the time, threads had attained some notoriety due to a combination of use by poorly trained individuals and a rash of publicized complications. Threads have made a bit of a comeback, as better training and safer resorbable sutures are being introduced. Currently there are several remaining barbed sutures available in US origin. Stratafix, a permanent barbed suture by Ethicon, has been discontinued in practice due to the intense fibrotic response and patient complaints of inflammation and discomfort in the treatment region. V-lock is resorbable and seems better tolerated, especially in breast surgery. Silhouette is FDA cleared for midface lifting [30] and also claims to be biostimulatory [31]. Since 2015, several companies have applied for FDA clearance of their polydioxanone threads for the approximation of the skin. Miracu threads [32] have received FDA clearance for both the PDO thread and the cannula insertion device.

Many styles of PDO threads are available. Filler threads have no fixation and are intended to supply a small amount of volume as well as hypodermal stimulation. Bidirectional barbed threads can be placed with a needle from the center of the treatment region. An alternative is the placement of these threads from within a cannula which avoids a central puncture mark. “Spring” threads are used in areas where

dynamic motion is prominent and might be restricted with a linear model. The novel Meshfill device (**Figure 10**) is a cylinder made of 16 tiny woven PDO threads that is inserted within a cannula. Prior to cannula withdrawal, 0.2 cc of either filler or fat can be injected into the internal space. The concept of an injectable implant has a great utility. In regions where a firm or defined contour is needed—the chin, cheek, or jawline, for example—these devices can be stacked or lined up to dramatically enhance shape. In regions where a linear depression is noted—the nasolabial fold—dramatic rather than subtle correction can be obtained with a very small amount of additional filler or fat.

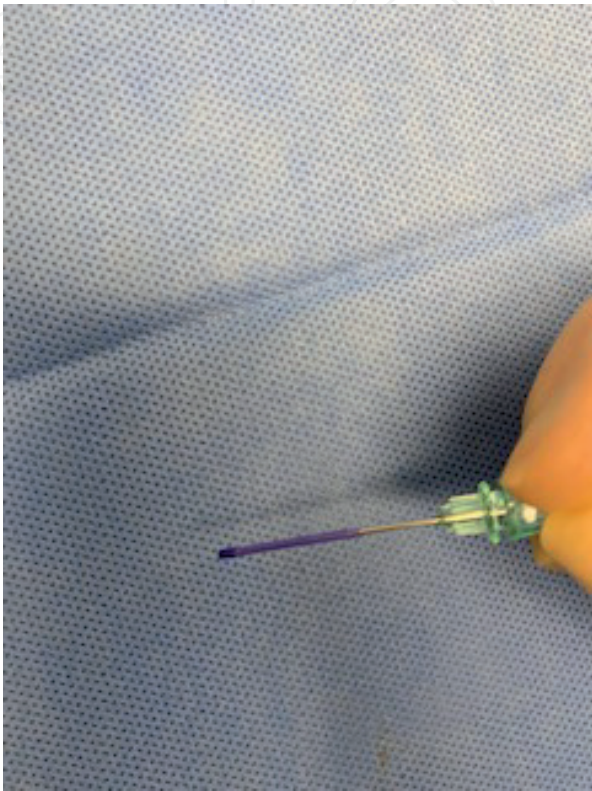


Figure 10.
Diagram of Meshfill construction. Sixteen tiny PDO threads are woven and placed on a 21 gauge cannula. These cylindrical structures can be used as filler threads by themselves or can be filled with fat or fillers to augment the volumetric correction.




Figure 11.
Miracu line thread. This PDO thread employs barbs and cogs in a double-coated structure that lasts up to 2 years.

A new addition to the portfolio is a double-coated PDO thread that combined barbs and cogs. The Miracu Line™ device is molded, not cut, so there is no weak point along the thread (**Figure 11**). The thread called “Line” lasts for 2 years. As the outer coating is resorbed, the inner thread maintains a presence and continues to offer soft tissue support. Because of the semipermanent nature of the Line thread, it is recommended that only skilled physicians use the device, with care taken to place it deep enough so that a contour defect is avoided. Manipulation of these threads should not be overdone as they are difficult to remove.

7. Conclusion

While patient acceptance of injectables has been high, many educated consumers are now seeking regenerative solutions for their esthetic needs. Combination treatment of the skin and subcutaneous stromal scaffold is attractive to both patients and physicians. The use of exosomes to signal cells in the treatment region is a rapidly growing trend. When combined with a light resurfacing protocol, exosomes accelerate the healing process while delivering mRNA, cytokines, chemokines, and growth factors. Restoration of the support system of the skin, the subcutaneous stroma, can be enhanced with PDO resorbable threads that are biostimulatory. Mono threads will generate directional collagen ingrowth in the superficial hypodermis. Barbed suspension threads can support sagging regions. Cylinder configured threads can be used alone or in combination with filler or fat. These injectable implants can replace small surgically introduced facial implants in many cases. Microlifting using suspension threads combined with regenerative techniques is a popular alternative to traditional injectable techniques.

Author details

Diane Irvine Duncan
Private Practice, Fort Collins, Colorado, USA

*Address all correspondence to: momsurg@aol.com

IntechOpen

© 2020 The Author(s). Licensee IntechOpen. This chapter is distributed under the terms of the Creative Commons Attribution License (<http://creativecommons.org/licenses/by/3.0>), which permits unrestricted use, distribution, and reproduction in any medium, provided the original work is properly cited. 

References

- [1] Knoepfler PS. Deconstructing stem cell tumorigenicity: A roadmap to safe regenerative medicine. *Stem Cells*. 2009;27(5):1050-1056. DOI: 10.1002/stem.37. PMCID: PMC2733374
- [2] Gurunathan S et al. Review of the isolation, characterization, biological function, and multifarious therapeutic approaches of exosomes. *Cell*. 2019;8(4):307. DOI: 10.3390/cells8040307. PMCID: PMC6523673
- [3] De Almeida AT, Figuerdo V, et al. Consensus recommendations for the use of hyperdiluted calcium hydroxyapatite (Radiess®) as a face and body biostimulatory agent. *Plastic and Reconstructive Surgery*. Global Open. 2019;7(3):e2160. DOI: 10.1097/GOX.0000000000002160. PMCID: PMC6467620
- [4] Amselem M. Radiess®: A novel rejuvenation treatment for the upper arms. *Clinical, Cosmetic and Investigational Dermatology*. 2016;9: 9-14. DOI: 10.2147/CCID.S93137. PMCID: PMC4699473
- [5] Mitchell R, Mellows B, Sheard J, et al. Secretome of adipose-derived mesenchymal stem cells promotes skeletal muscle regeneration through synergistic action of extracellular vesicle cargo and soluble proteins. *Stem Cell Research & Therapy*. 2019;10:116. DOI: 10.1186/s13287-019-1213-1. PMCID: PMC6451311
- [6] Ferraris V. How do cells talk to each other? Paracrine factors secreted by mesenchymal stromal cells. *The Journal of Thoracic and Cardiovascular Surgery*. 2016;151(3):849-851. DOI: 10.1016/j.jtcvs.2015.11.035. [Epub: 27 November 2015]
- [7] Rustom A, Saffrich R, Markovic I, Walther P, Gerdes HH. Nanotubular highways for intercellular organelle transport. *Science*. 2004;303:1007-1010
- [8] Poe AJ, Knowlton AA. Exosomes as agents of change in the cardiovascular system. *Journal of Molecular and Cellular Cardiology*. 2017;111:40-50. DOI: 10.1016/j.yjmcc.2017.08.002
- [9] Shabbir A, Cox A, et al. Mesenchymal cell exosomes include proliferation and migration of normal and chronic wound fibroblasts, and enhance angiogenesis in vitro. *Stem Cells and Development*. 2015;24(14):1635-1647. DOI: 10.1089/scd.2014.0316. [Epub: 13 April 2015]
- [10] van Balkom BW, de Jong OG, Smits M, Brummelman J, den Ouden K, de Bree PM, et al. Endothelial cells require miR-214 to secrete exosomes that suppress senescence and induce angiogenesis in human and mouse endothelial cells. *Blood*. 2013;121: 3997-4006; S1-S15
- [11] Rashed MH, Bayraktar E, Helal G, et al. Exosomes: From garbage bins to promising therapeutic targets. *International Journal of Molecular Sciences*. 2017;18(3):538. DOI: 10.3390/ijms18030538. PMCID: PMC5372554
- [12] Hu L, Wang J, Zhou X, et al. Exosomes derived from human adipose mesenchymal stem cells accelerates cutaneous wound healing via optimizing the characteristics of fibroblasts. *Scientific Reports*. 2016;6:32993. DOI: 10.1038/srep32993. PMCID: PMC5018733
- [13] <https://www.fda.gov/vaccines-blood-biologics/safety-availability-biologics/public-safety-notification-exosome-products> [Accessed: 20 December 2019]
- [14] <https://www.fda.gov/regulatory-information/search-fda-guidance-documents/regulatory-considerations-microneedling-devices> [Accessed: 21 September 2018]

- [15] Rakesh K. Use of barbed threads in facial rejuvenation. *Indian Journal of Plastic Surgery*. 2008;**41**(Suppl):S93-S100
- [16] Fukaya M. Long-term effect of the insoluble thread-lifting technique. *Clinical, Cosmetic and Investigational Dermatology*. 2017;**10**:483-491. DOI: 10.2147/CCID.S150738. PMCID: PMC5697446
- [17] Duncan DI. Nonexcisional tissue tightening: Creating skin surface area reduction during abdominal liposuction by adding radiofrequency heating. *Aesthetic Surgery Journal*. 2013;**8**:1154-1166
- [18] Storer M, Euwer R, Calame A, Kourosh S. Late-onset granuloma formation after poly-L-lactic acid injection. *JAAD Case Reports*. 2016;**2**(1):54-56. DOI: 10.1016/j.jdcr.2015.11.017. PMCID: PMC4809477
- [19] Tang S, Sun Z, Wu X, Wang YY, Zhang J. An innovative thread-lift technique for facial rejuvenation and complication management: A Case Report. *Medicine (Baltimore)*. 2018;**97**(21):e10547. DOI: 10.1097/MD.00000000000010547
- [20] Tiriyaki T. Micro-shuttle lifting of the neck: A percutaneous loop suspension method using a novel double-ended needle. *Aesthetic Surgery Journal*. 2016;**36**(6):629-638. DOI: 10.1093/asj/swj001. [Epub: 23 February 2006]
- [21] Wang Y, Pennock S, Chen X, Wang Z. Endosomal signaling of epidermal growth factor receptor stimulates signal transduction pathways leading to cell survival. *Molecular and Cellular Biology*. 2002;**22**(20):7279-7290. DOI: 10.1128/MCB.22.20.7279-7290.2002. PMCID: PMC139821
- [22] Johnstone RM, Adam M, Hammond JR, Orr L, Turbide C. Vesicle formation during reticulocyte maturation. Association of plasma membrane activities with released vesicles (exosomes). *The Journal of Biological Chemistry*. 1987;**262**:9412-9420
- [23] Théry C, Amigorena S, Raposo G, Clayton A. Isolation and characterization of exosomes from cell culture supernatants and biological fluids. *Current Protocols in Cell Biology*. 2006;**3**(3):22
- [24] Cui X, He Z, Liang Z, Chen Z, Wang H, Zhang J. Exosomes from adipose-derived mesenchymal stem cells protect the myocardium against ischemia/reperfusion injury through Wnt/ β -catenin signaling pathway. *Journal of Cardiovascular Pharmacology*. 2017;**70**(4):225-231. DOI: 10.1097/FJC.0000000000000507
- [25] Alcamo J. US Patent # 3,123,077; 1964. Available from: <https://patents.google.com/patent/US3123077A/en> [Accessed: 12 October 2019]
- [26] MacKenzie A. An experimental multiple barbed suture for the long flexor tendons of the palms and fingers. *JBJS British Volume*. 1964;**49B**(3):440-447
- [27] Sulamanidze MA, Fournier PF, Paikidze TG, Sulamanidze GM. Removal of facial soft tissue ptosis with special threads. *Dermatologic Surgery*. 2002;**28**(5):367-373
- [28] Bertossi D, Botti G, Gualdi A, et al. Effectiveness, longevity, and complications of facelift by barbed suture insertion. *Aesthetic Surgery Journal*. 2019;**39**(3):241-247
- [29] Wu WTL. Commentary on: Effectiveness, longevity, and complications of facelift by barbed suture insertion. *Aesthetic Surgery Journal*. 2019;**39**(3):248-253. DOI: 10.1093/asj/sjy340. PMCID: PMC6376340

[30] Ruff GL. Inserting device foe a
barbed tissue connector. US Patent No.
5342376; 1994

[31] https://www.accessdata.fda.gov/scripts/cdrh/cfdocs/cfRL/rl.cfm?start_search=1&OwnerOperatorNumber=10032162 [Accessed: 20 December 2019]

[32] Consilgio F, Pizzamiglio R,
et al. Suture with resorbable cones:
Histology and physico-mechanical
features. *Aesthetic Surgery Journal*.
2016;**36**(3):NP122-NP127. DOI: 10.1093/
asj/sjv202. PMCID: PMC5127481