

We are IntechOpen, the world's leading publisher of Open Access books Built by scientists, for scientists

6,900

Open access books available

185,000

International authors and editors

200M

Downloads

Our authors are among the

154

Countries delivered to

TOP 1%

most cited scientists

12.2%

Contributors from top 500 universities



WEB OF SCIENCE™

Selection of our books indexed in the Book Citation Index
in Web of Science™ Core Collection (BKCI)

Interested in publishing with us?
Contact book.department@intechopen.com

Numbers displayed above are based on latest data collected.
For more information visit www.intechopen.com



Basic Principles in Microvascular Anastomosis and Free Tissue Transfer

Ignacio Vila, Iván Couto-González and Beatriz Brea-García

Abstract

Free tissue transfer pursues the best functional and aesthetic results in reconstructive surgery. As these techniques completely maximise the donor tissues' disposability, these treatments have become a first-line option in many situations. When the donor site is taken from the same patient, these surgeries are often referred to as autotransplants. Free tissue transfer sustains in microvascular anastomosis, which are defined by a vessel lumen diameter inferior to 3 mm. Particular attention to some details is important in these techniques, as, for example, to preclude any damage to the vessel walls or any leakage in the microvascular anastomosis. But the success of these techniques does not only depend on an adequate vascular suture, but also on a constellation of details that must be taken into account. These go from the availability of a trained team, to the ergonomics of the surgeon, through the scrupulous cleanliness of the surgical field.

Keywords: free tissue transplantation, microvascular anastomosis, microsurgery, reconstruction

1. Introduction to microsurgery

Microvascular transfer is a reconstructive technique based on raising tissues from healthy areas of the body, where an excess or dispensability exists, in advance to transplant them to other regions where they are lacking, mainly after trauma, oncological surgery or chronic infection. A microsurgical transfer from a strict point of view implies a double vascular anastomosis less than 3 mm between vessels in the transferred tissue to the ones in the recipient area [1]. Super-microsurgery would refer to those situations in which anastomoses have a diameter between 0.3 and 0.8 mm [2]. Rigorously speaking, the recipient vessels are those receiving the blood flow and the donors those from which it emanates. From a historical point of view, the compound of the transferred tissues is named free flaps.

Since its inception, reconstructive techniques have aimed to restore the integrity, form and function of the body [3]. Although plastic surgery is the discipline of medicine that brings together all these techniques, it lacks an anatomical limitation; therefore, its knowledge is widespread according to the diverse body regions through maxillofacial surgery, ophthalmology, hand surgery, etc. For centuries, it was intended to limit the potential damage inflicted to patients by narrowing down the reconstructive options. In this regard, a reconstructive ladder was defined,

where the primary closure of the wounds, the cure by secondary intention or the skin grafts were in the lower steps of this ladder and the flaps in the higher [4, 5].

With the improvement in optical tools, it became easier to perform the vascular anastomoses that allowed free flap transfer and to set up skilled teams. As the tissue transfers became more dynamic and the microsurgery success rates rose, the benefits became more and more evident [5]. It was proven that the transfer of healthy tissues to the hand or head and neck allowed surgeons to achieve faster and better recoveries in areas of high functional demand, also with much more aesthetically acceptable results and lower morbidity. The same happened to breast surgery, where reconstructions with a natural shape and adequate volume could be achieved; the scars were hidden in the distance, and there was no need to use prosthesis. In lower limb osteomyelitis, free muscle flaps became the alternative to amputation. In addition, the advent of perforator flaps, mainly due to the contributions of Song and Koshima [5], thanks to whom it was not necessary to take the underlying muscle to transfer a fasciocutaneous flap, made it possible to further minimise the morbidity of these microsurgical interventions. Finally, a revision of the reconstructive ladder was proposed, the simplicity of the reconstruction would prevail, but pursuing the best aesthetic and functional results. So, a switch to a reconstructive elevator was made. In this way, microsurgical reconstructions became the first-line option for many patients and the technique was extended to a multitude of centres [5, 6].

2. Basic principles in microsurgery

2.1 Ergonomy

Multiple aspects regarding the environment in the operating room and the position are particularly important in microsurgery. It is imperative to have enough field to allow an easy movement. This aspect, which is less substantial in *macro*-surgery, becomes absolutely fundamental in microsurgery. Mention it at the beginning, does nothing but tries to emphasise its relevance.

A two-team approach is usually chosen in reconstructive microsurgery, one will raise the flap and the other will set the recipient site where this is going to be transplanted [7]. Therefore, all the time spent planning disposition is properly invested. This is true both for placing the patient in the proper position, and for the surgeon to adopt a comfortable and durable posture. Since the surgery will be prolonged, we must meticulously paddle all bony prominences of the patient and the areas at risk of neurovascular compression. It must be encouraged to take all the necessary anaesthesia monitoring measures at the beginning, just to avoid emergencies or interruptions during delicate stages of surgery. It is also sensible to foresee how the microscope will be arranged in the room.

The comfort of the surgeon is a must when it comes the time to perform the microvascular anastomosis, primarily regarding the back, scapular and muscular groups. The sutures used usually size about 75–100 μm and the vessel lumen just a few millimetres; therefore, any tremor will greatly hinder the precision and success of the anastomoses. We cannot afford mistakes at any point of the microvascular anastomosis. The surgeon must be perpendicular disposition to the vessels and seated in a self-regulating chair that allows a self-sufficient height adjust. He or she should also be with the feet on a flat surface, the arms supported on a cloth and the hands on some comfortable place of the field to work only with the intrinsic muscles of the hand [1].

Patience is the cornerstone of microsurgery, calm dissection with no external worries or hurry [8]. For this to be the case, it is essential to be in an easy environment without any tensions among the team members. Fatigue will appear mainly at the most complex moments, well in the middle of long interventions. So, if we do not foresee a comfortable environment with all these details, which may seem insignificant at first, as soon as the least complication appears, the reconstruction will be at high risk. In the case of microsurgical reconstructions, comfort is not a luxury but a must.

2.2 General conditions

After having invested enough time planning the operating room configuration, it is time to choose the vessels in the recipient area, since those of the flap are already determined and are assumed to be healthy because of their undamaged origin. It is essential to emphasise that the dissection must be very scrupulous, some groups advocate applying tension to the tissues around the vessel, without any direct pulling or forceps grasping on it, as not to generate any intimal traumas that may cause a thrombotic source [8, 9]. Any injury to the intima of the vessel, unnoticed or not, will expose the subendothelial collagen of the lumen, leading to a thrombotic focus. There are situations where it is impossible not to manipulate the vessel, as it happens in cervical dissections for oncological reasons; in these cases, a high incidence of thrombosis in the recipient vein has been demonstrated [6].

We must choose healthy vessels, without excessive fibrotic or irradiated tissue around them, this will allow us to perform a clean dissection, achieving a blood-less field. If blood accumulates in the field, we should spare no expense in abundantly rinse the area and review haemostasis. Blood has a red light refraction that deteriorates the sight with usual optical tools and releases procoagulant factors inducing vascular thrombosis [10, 11]. In limbs with previous surgeries or trauma, in case of doubt, we must carry out explorations such as angiography or Doppler, to check the availability of adequate vessels [12–15]. We should recruit as much vessel length as necessary to prevent any tension in the anastomosis, since the use of vein grafts, although may be needed, should be avoided due to its higher incidence of complications.

Before sectioning the donor artery to which we are going to transfer our flap, we must ensure that it has a good flow, we should ideally evince pulse [8]. Once sectioned, it will only be valid if we observe the exit of an abundant spurt of pulsatile blood. On the other hand, the vein that receives the blood from the flap in the recipient area must have at least the diameter that the vein of the flap has; otherwise, a bottleneck will form and prevent a good return and a venous congestion may develop in the flap.

Once the vessels in the receiving area are all set, we proceed to review the haemostasis and the perfusion of our previously dissected flap, then we release and transfer it [8, 10]. We should section the artery first and then the vein, as to avoid any congestion. Then we have to adapt the flap in the recipient area, since after anastomosis the flap will become edematized and its fixation in some deep spaces will be complex. This fixation is a mandatory prior step in all free flaps but in those in which the anastomosis lies in a deeper plane. In the head and neck reconstruction, small and intricate spaces make it advisable to do the fixation at first; but in breast reconstruction, we can only secure it with a gauze before microvascular anastomosis [6].

When performing the anastomosis, we prefer to adjust each vessel end in a simple microvascular clamp, tension-less approximate both ends and perform

the microvascular anastomosis sparing as much proximal dissection as possible between the vessels of the flap pedicle and between the ones of the recipient area. On the other hand, we can place the anastomosis vessels end in a double microvascular clamp and approximate them [16]. The anastomosis should be placed on a rubber contrast and this over a wet gauze to avoid pooling and elevate the anastomosis from the surrounding field, full of thrombogenic debris [10] (**Figures 1 and 2**).

It is characteristic of the lumen of vessels to show a diameter smaller than that seen before severing them. This phenomenon is known as vasospasm. To mitigate it, we must perform a mechanical dilatation of the vessel lumen with specific dilator forceps and with agents such as lidocaine 1–2% or papaverine 3%, the latter being our preference [8–11]. Another dilatation technique is to abundantly rinse lumen with heparinised serum (200–300 IU/ml) [11–17]. It is key to remove the adventitia next to the anastomosis; we usually remove 2–3 mm with cutting technique, by pulling the adventitia over the lumen of the vessel and making a section parallel to the light. Aggressive adventitectomies leave the proximity of the anastomosis lacking *vasa vasorum*; this can cause ischemia in the vessel wall and, secondary to this, a failure or a pseudoaneurysm. On the other hand, the adventitia is highly thrombogenic, its entry with a knot into the lumen can be disastrous [18]. No technique completely removes the adventitia, but the sharp dissection seems more respectful with the intima [19]. Before carrying out the anastomosis, we must ensure that there are no intimal lesions in the lumen of the vessel, venous valves or branches, that may cause turbulence or resistance to flow in the vicinity of anastomosis [8].

There is debate about which anastomoses to perform first, whether arterial or venous. If there is no limitation for the position of a vessel deeper than another, as happens in breast reconstruction where the internal mammary vein usually has a more medial position, we can choose any one of them [6, 8]. Many groups choose to start with the arterial anastomosis to minimise ischemia time, taking into account that they do not usually experience added venous congestion. We usually start with the venous anastomosis to avoid any congestion within the flap that can cause a thrombus in its internal circuit. At the time of removing the clamps, once the anastomosis is completed, it is clearly preferable to remove the venous one first.

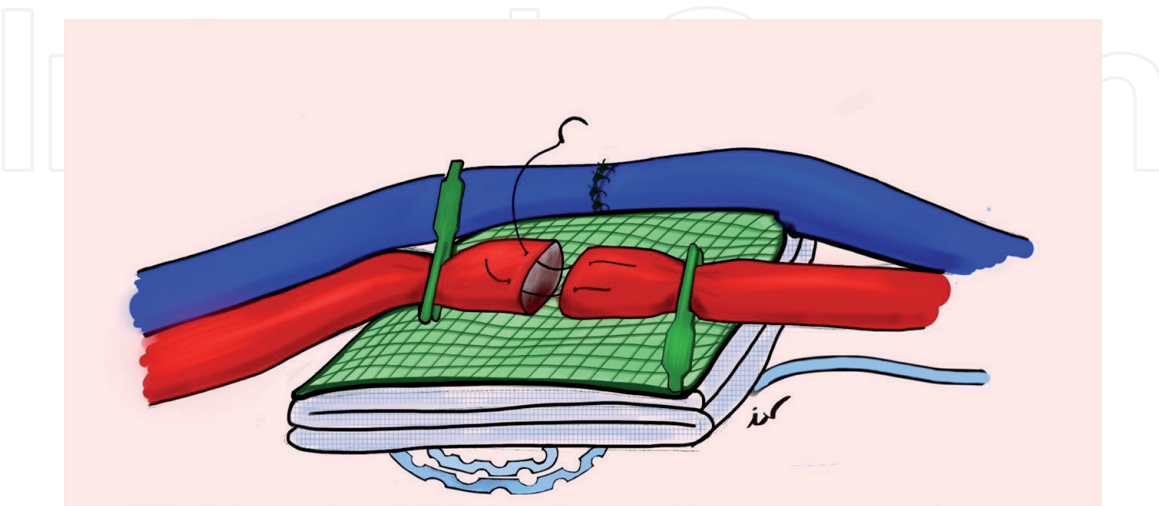


Figure 1.

General overview of a microvascular anastomosis. Artery microvascular anastomosis is performed in a blood-less field after vein anastomosis (in a second plane), in a higher position over a rubber medium contrast and wet gauzes. A protected 5F Redon is usually placed under the anastomosis. Dissection of the vessels in each side of the anastomosis is limited, only simple vascular clamps are employed; this eases the one-side-up technique (see below). In this figure, the first two stitches of the triangulation technique are depicted.

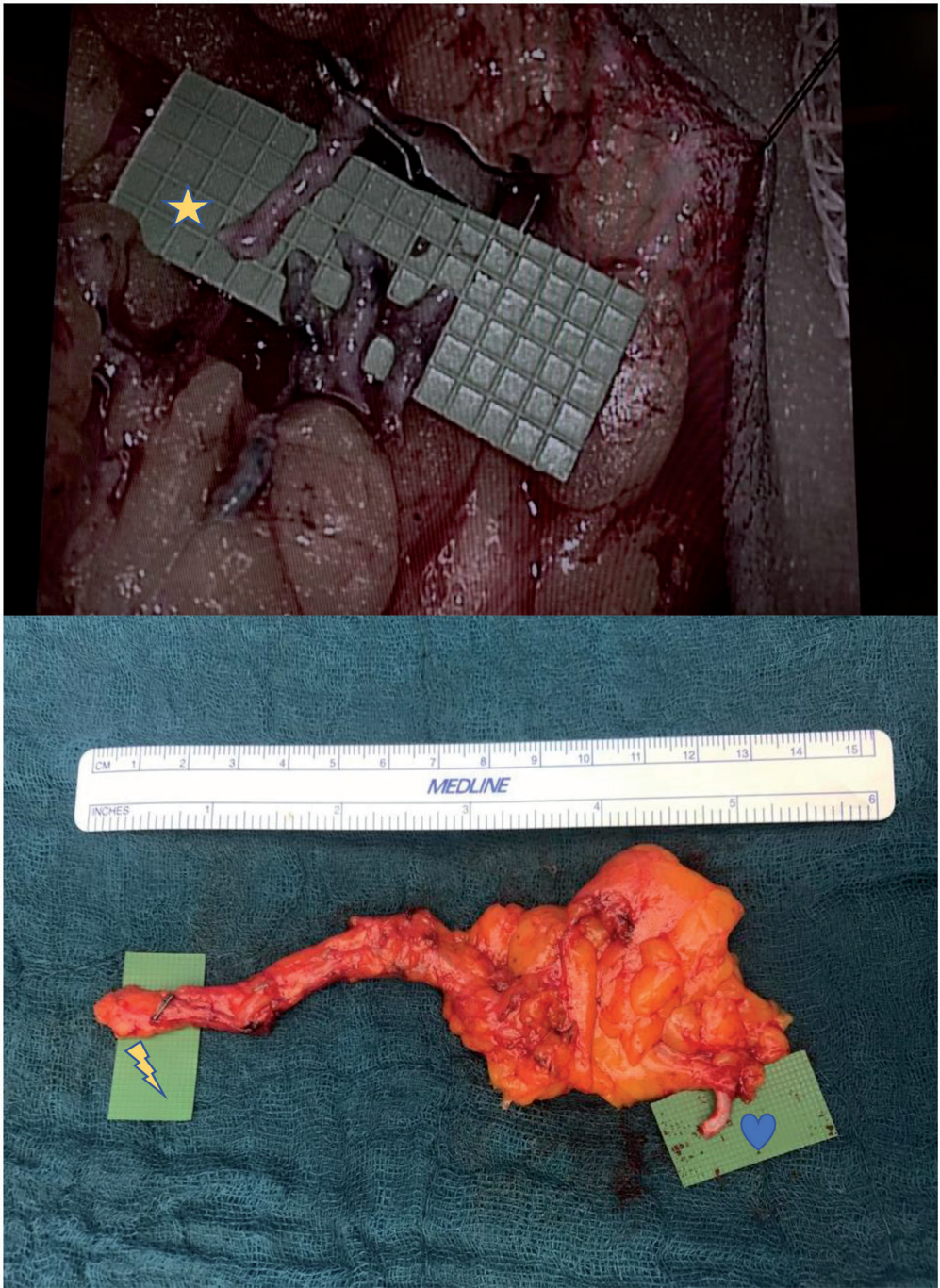


Figure 2.
Examples of the limited pedicle dissection before anastomosis. In the upper picture, we can see a free epigastric flap for an axillary free lymph node transfer. Marked with a star, we see the donor posterior circumflex humeral artery; below it, the inferior epigastric artery of the free flap is shown with both veins at each side. In the lower picture, we see the free flap before the transfer. Marked with a thunder, we see the inferior epigastric pedicle severed before its entrance in the abdominal rectus muscle; the inferior epigastric vein is marked with a heart, it has been cut near its mouth in the circumflex iliac vein and laid prepared for the lymphovenous anastomosis.

2.3 Team

The use of microsurgical techniques is not limited to reference centres with a high availability of resources, although their routine use is almost exclusive of these. This is due to the disposability of a microsurgical team with several surgeons trained in microvascular anastomosis and free flaps management.

In this kind of surgery, each mistake has its consequences. So, if we perform these interventions with a very scarce and inexperienced team, these day-long surgeries can be translated into fatigue, nerve-wrecking and inaccuracies. This

ultimately will generate failures in the microvascular anastomosis and problems in the perfusion of the flap. Therefore, having a team that allows pauses and relays, without stopping the procedure, is a fundamental element. Likewise, this second fresh team will overcome emergencies (more frequent in the first 48–72 h) or can replace a tired first team. It seems sensible to have at least four microsurgeons, two assistants and two experienced scrub nurses [20].

A microsurgical team must function as a unit that critically analyses its results, seeking rates of failure lower than 5% in free flaps. Errors and the morbidity of the interventions must be analysed, minimising both. This constant improvement is hard to achieve if several microsurgeons are not available.

3. Microsurgical tools and instruments

3.1 Tools

Microsurgery results from adapting the visual inaccuracy of our naked eye, to the fine movements of our hands. Here is where magnification arises. This can be done by two optical tools: the microscope and the magnifying loupe. In both, good lighting is essential [21, 22].

Surgical microscopes occupy a large space in the operating room but allow a magnification of up to 40× with greater illumination. In addition, they have pedals to control zoom and focus with the feet. Smaller magnification of 6–12× is usually used for the preparation of the vessels, and then it is increased up to 20× before the microanastomosis. In addition, the microscope gives us a wide range of field and provides the same vision to the surgeon and the assistant, enhancing the collaboration between them [21].

On the other hand, loupes are very cost-effective and easily transportable visual systems. The most common magnification employed in microsurgery is between 2.5× and 4.5×. In skilled hands, microscope has not proved to be superior *versus* loupes in achieving high success rates in free tissue transfers [23].

There are two types of magnifying loupes, on the one hand the compound or Galilean loupes and on the other hand the prismatic. The former consist of two lenses in line, and offer less weight and cost, although their magnification (2.5×) and depth of field are lower. The latter use a prism inside to reach a longer path of light through the lenses, which allows greater magnification and field depth, although they can be darker, heavier, more expensive and fragile [22].

3.2 Basic microsurgery instruments kit

The microsurgical instruments have evolved from ophthalmology or jewellery material to extremely specific and precise tools [7]. The basic kit is not made up of too much surgical material. This material should ideally be antireflective and cylindrical to allow its sliding from the index to the middle fingers and facilitate the passage of the needle through the tissues using only the intrinsic musculature. The size of the material should be about 16 cm to facilitate its support in the first hand commissure. In the case of working in very small fields, as in the case of hand surgery, smaller material, about 8 cm, with flat surface may be useful. Nowadays the self-locking material has lost interest, the mere requisite is just to offer little resistance when grasping to preclude any fatigue of the thenar eminence with prolonged use [24].

The basic kit consists of two scissors, a needle holder and a jeweller forceps. One of the scissors should be curved and round tipped, to be useful to dissect.

Other pair should be straight and pointed to perform the adventitectomy and to cut sutures. These pointed scissors should not be used for tissue dissection, because of the possible vessel trauma that they would generate. The jeweller forceps must have a precise closure, with enough contact between surfaces at the tip, just to handle fine sutures of 75 or 100 μm .

Other instruments that can also be useful are an aspiration system, an irrigation system and a bipolar forceps identical to jeweller forceps but protected. Our preference is to prepare a fixed suction system in the corner of the field, and to avoid introducing traditional aspirators directly over the vessels. Usually we fix a 5F Redon drain in a corner of the field or under the rubber contrast and we keep it connected to soft aspiration, in such way that it rests distant from the area of the anastomosis but does not allow pooling. We also avoid the contact of celluloses or cotton gauzes directly with the lumen of the vessel due to their thrombogenic properties.

For the lumen irrigation, we use a heparin solution with 200–250 IU/ml [11]. Washing the lumen of the vessel directly can hydrodissect the vessel wall, exposing the subintimal collagen. Therefore, we introduce a blunt-tipped lacrimal cannula into the lumen of the vessel before anastomosis to perform a gentle wash [17]. Likewise, we usually do an irrigation of the flap through the artery with 20 or 30 ml of heparin solution, prior to the transfer; this checks the correct flow in the vascular circuit of the flap.

3.3 Instruments care

This delicate material requires little but precise care. First of all, we should avoid falls during surgery or washing, as the tips of the material can be damaged. If this happens, the closure of the material would not be perfect and its functionality would be noticeably reduced. It is also necessary to avoid the tips of the material to be oriented towards the sides in the store box, since movements with the box closed could also damage the tips inadvertently.

The material should preferably be washed by the scrub nurse or the surgeon himself, who is familiar with it and will be more careful with its handling. A final wash should be done with distilled water and dried with an air gun to prevent rust formation.

During surgery, the material must always be clean and moist, so that the sutures do not adhere to its surface. Dirty material and damaged tips will cause problems with the suture technique at key moments of the intervention.

3.4 Sutures

The most common sutures elected are the 9-0 on a 100- μm needle and the 10-0 on a 75- μm needle. Because of the ease of knotting and the low tissue reaction, the most used material in sutures is nylon. Some authors prefer polypropylene due to a lower tissue reaction, but its knots may be less reliable.

4. Microsurgery techniques

There is no stipulated standard on how to perform a microvascular anastomosis, the choice of the specific technique is operator-dependent. However, there are certain issues that we must avoid: a narrowing of the vascular lumen, an irregular distribution of the diameters of the vessels that would generate folds and irregularities, an excessive suture material inside the vascular lumen, and above anything else transmural sutures that bite the posterior wall closing the vascular lumen [24].

4.1 End-to-end anastomosis

By far, the most frequently employed technique is the end-to-end anastomosis. Because of its simplicity in less experienced hands, it has one of the lowest failure rates.

4.1.1 Triangulation

This technique was described by Alexis Carrel in the 1902. His intention was to separate the posterior wall from the anterior, as he realised about the danger of transmural stitches. The technique employed three initial sutures, with 120° separation between each [25]. It was modified with the use of only two initial sutures at 120° or 150° distance, as the posterior side was then longer and also fell away (**Figure 3**). Finally, it was modified again to propose only two initial sutures at 180° . The rest of the anastomosis will be closed with simple sutures between the initial points [24, 26].

4.1.2 Continuous

The continuous suture saves time and corrects discrepancies of 2–3 mm in size between vessels, but it has as an inconvenient: the tobacco bag effect. Some authors propose to distribute at first the two vascular lumens with some simple stitches. This technique is not very popular in venous microvascular anastomosis due to its stenosing tendency [24, 26].

4.1.3 Continuous interrupted

The continuous interrupted technique (also known as open-loop technique) is our technique of choice. It combines the safety of simple sutures with the comfort and speed of the continuous ones. It allows to constantly maintain a perfect visualisation of the vascular lumen and at the same time minimises the necessary manoeuvres. In this technique, a continuous suture with a spiral of very wide loops is made,

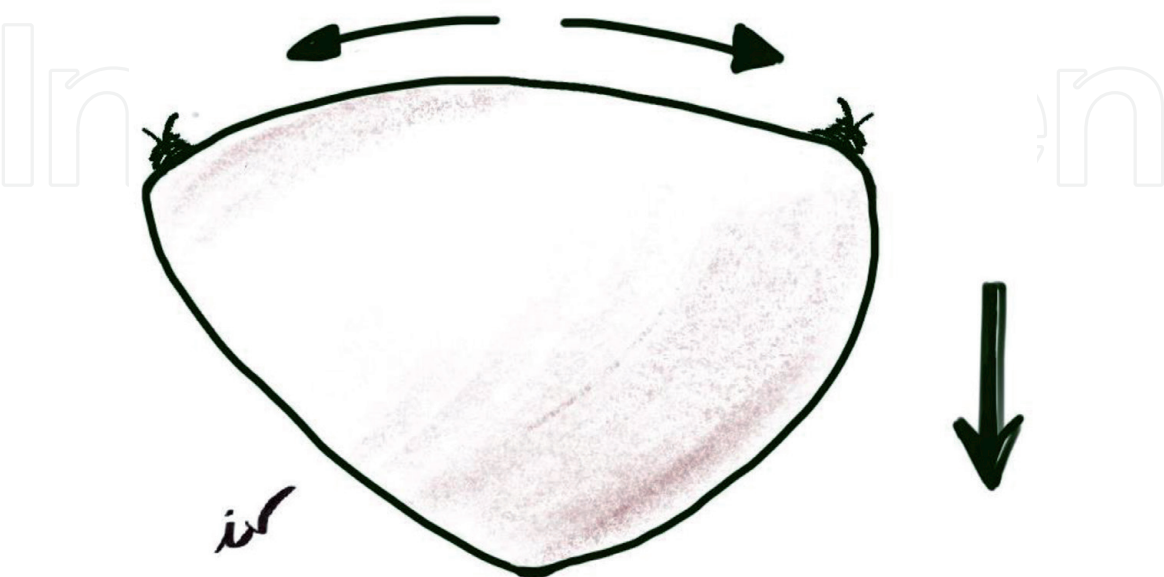


Figure 3. Triangulation technique, after placing tension between the first two stitches, the longer posterior wall of the anastomosis falls down, precluding transmural stitches.

then moved towards a lateral. Finally, each one of the loops is sectioned and knitted separately [24] (**Figure 4**).

4.1.4 One way up

This technique is of first choice when we cannot properly manipulate both the vessels of the microvascular anastomosis, we cannot manage to rotate it in order to carry out the suture of the posterior wall. When performing the one-way-up technique, we begin suturing the posterior side. The needle is introduced from the deep side of the vessel to the intima of the posterior wall and returns through the intima in the lumen of the posterior wall of the opposite vessel. The knots are the same as in simple stitches. After placing three or four stitches in the posterior wall in an inverted fashion, it is easy to perform the remaining stitches in a conventional way. It is important to place the posterior wall stitches close enough to prevent any leakages, as revising the posterior wall is bothering. Lastly, the anterior face is sutured. This technique is one of our preferences as it minimises the incidence of transfixing sutures [24] (**Figure 5**).

4.2 End-to-side anastomosis

This type of suture is very useful when there is a great discrepancy between vascular lumens, or when the flow through a vascular axis must be preserved.

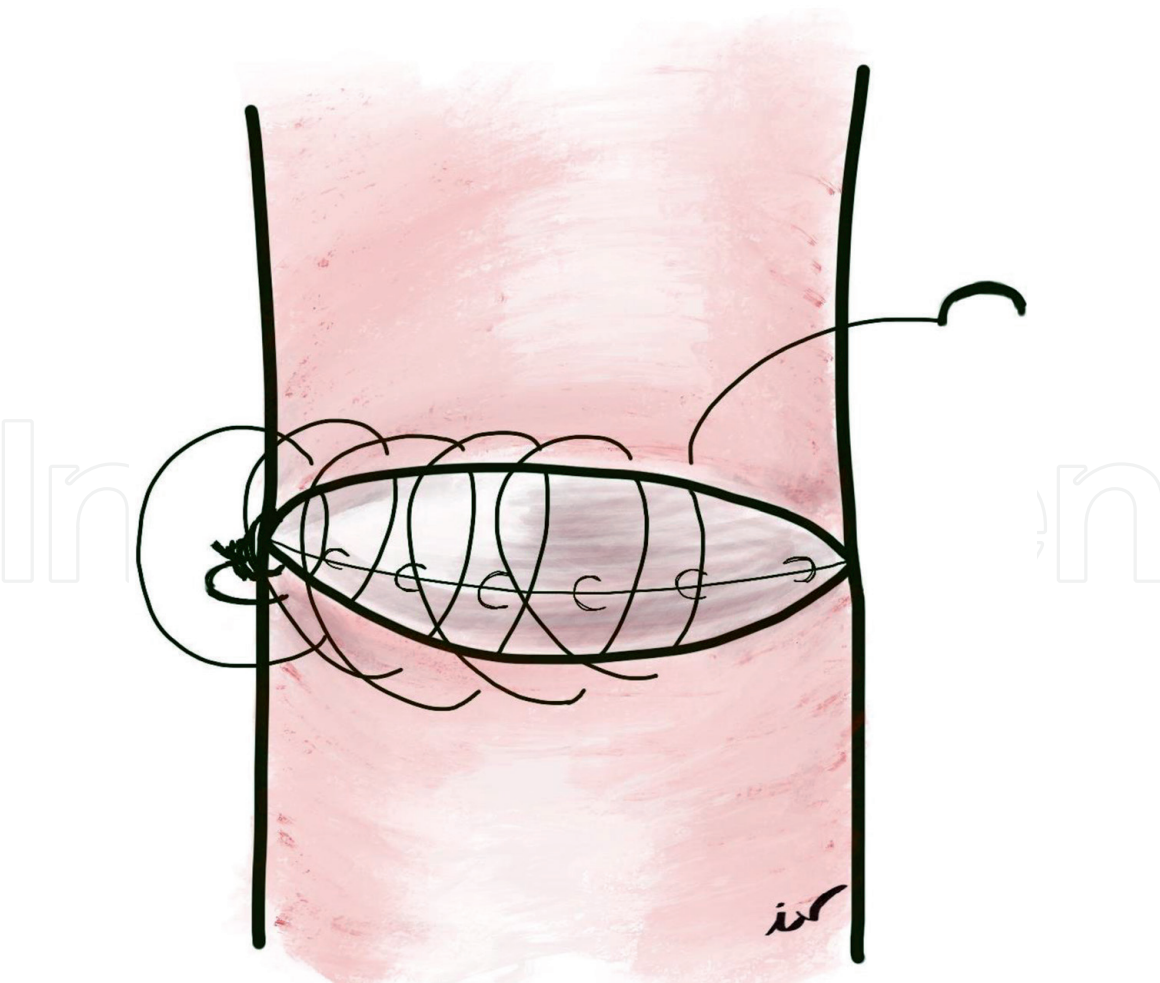


Figure 4.
Open-loop technique. Continuous suture of the upper face of the vessel, with very loose loops. Afterwards these loops are divided, and knotted as simple stitches. The posterior wall is depicted sutured first.

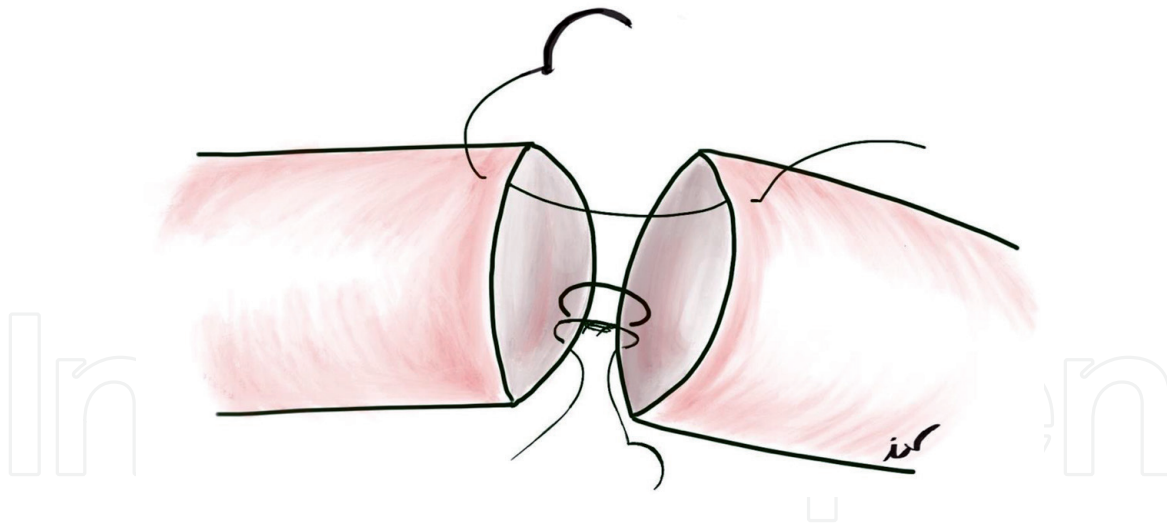


Figure 5.

One-way-up technique. First four to five stitches are placed in the posterior wall in an inverted fashion. It is important to leave only a small gap between the two first knots in this posterior wall, in order to avoid leakages and reviews here. After these first inverted stitches, the rest of them are placed in a conventional simple fashion as depicted in the figure. This technique avoids twisting and injuring the anastomosis.

Therefore, it is very useful in lower limb reconstructions, when one of the vascular axes is damaged or we want to preserve the integrity of all [27]. For example, in head and neck surgery, after a cervical dissection, the high rate of venous thrombosis makes it advisable to choose the internal jugular as recipient vein [6]. In view of the discrepancy between the internal jugular and the vein of any flap, as well as the pertinence of maintaining the flow through the internal jugular, an end-to-side anastomosis is frequently chosen.

To perform this end-to-side anastomosis, we must occlude the flow through the larger vessel that will remain in continuity. Our preference is the use of two rubber loops with a double pass around the vessel. When tensioning these loops, it seems that the damage to the walls of the vessel is inferior than with bulldog or baby Satinsky clamps. Next, by putting traction on the wall of the vessel with a transmural suture, we elongate the wall and make a section with the straight adventitectomy scissors or with a scalpel [27]. The diameter of the hole created must not be greater than the one on the vessel present in the free flap. If possible, the flap is tilted over the anastomosis to suture the posterior face; otherwise, we will use a one-way-up suture technique [28].

4.3 Tips and pearls

- It is important to take within each suture a good amount of intima to adequately evert it and expose smooth intima to the vascular lumen, with scarce subendothelial collagen or suture material.
- The knots should be flat, placed on one side, with the right pressure just to close the anastomosis, since very tight sutures can cause ischemia and failure.
- In case of working with veins of inconsistent walls, to perform an immersion technique, using abundant heparinised serum in the field to open the vascular lumen can be useful.
- We should not allow leaks in the anastomosis; these will cease through the formation of an intraluminal thrombus, which can ultimately endanger the entire anastomosis.

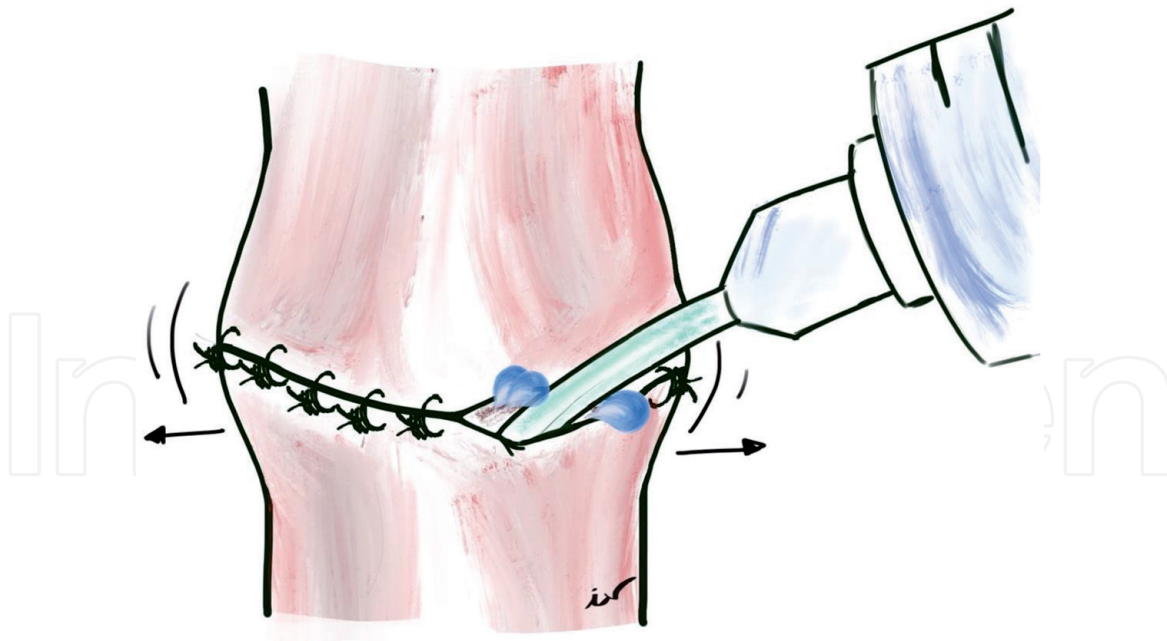


Figure 6.

Patency test with rinsing. A short Abbocath cannula is introduced in the microvascular anastomosis in between the space left by the two late stitches, we pretend to verify an easy dilatation before finishing the suture. The anastomosis is completed full of heparinised serum, until clamps are released.

- At the end of an anastomosis, we must check its permeability, for example by means of a patency test. Other possibility is to make a profuse irrigation through the space left in the microvascular anastomosis before placing the last two stitches, an inflation and slight dilatation of the anastomosis with the heparinised serum evinces the vascular patency (**Figure 6**). The classic patency test can traumatise the intima.
- The learning of these techniques must begin in a laboratory of experimental surgery with animal models [29].
- Dilatation of the lumen with specific dilator forceps allows better visualisation of the interior of the vessel, easily recovering the needle at each stitch.
- Before passing the entire thread through the anastomosis, the former should be in line with the vessels, and not angulated behind the needle. This precaution will avoid tears and friction on the vessel wall with the thread passage.
- Limit the vessel dissection as much as possible (**Figures 1 and 2**).

5. Couple devices

Since the onset of microsurgery, a great interest was drawn towards the development of suture techniques to perform anastomoses more quickly and automatically, in order to buffer inaccuracies [28]. For this purpose, devices in the form of two metal rings that are coupled, known as coupler devices, were developed.

Currently, its use is widespread, mainly for vein anastomoses, although they have also tested a 100% patency in arterial ones. The vessel is introduced through the ring and the edges are fixed inside-out in the pins arranged in the ring, then the same is done with the other vessel and the hinge of the device, that joins both sides, is closed. The eversion of the edges achieves less exposure of the vascular lumen to foreign

material and therefore the rate of thrombogenesis is lower. This eversion of the edges in the case of the arteries is more complex due to the thickness of the vascular wall, which makes its use in arterial anastomosis not so popular [28, 30]. There are coupler devices currently available with built-in systems for flap control, such as Doppler.

Despite their many advantages, they present some drawbacks. Although they have been shown to reduce the time needed to perform the anastomosis, their use involves some complexity and produces some stenosis. On the other hand, they are not recommended in areas with a tendency to infection, with poor vascularisation or to be irradiated.

6. Conclusions

In the search of the best functional and aesthetic results, free tissue transfers have become the gold standard for many of the issues that arise in reconstructive surgery [31, 32]. Clear examples of this are the deep inferior epigastric artery perforator flap in breast reconstruction [7, 8] and the anterolateral thigh flap in head and neck reconstruction [6]. But the success of these techniques does not only depend on an adequate vascular suture, but also on a constellation of details that must be taken into account. These go from the availability of a trained team, to ergonomics, through a scrupulous cleanliness of the surgical field. All this does nothing but stress the importance of patience, good planning, attention to details or even the use of microsurgical check-lists in to prevent any error that, however small, can have catastrophic consequences.

Acknowledgements

The authors would like to give special thanks to their chief Dr. Antonio Taboada-Suárez for his support, constant stimuli and generosity and to Dr. Joaquim Megías Barrera for his guidance.

Conflict of interest

The authors declare no conflict of interest.

Author details

Ignacio Vila*, Iván Couto-González and Beatriz Brea-García
Department of Plastic Surgery, University Hospital Complex of Santiago,
Santiago de Compostela, Spain

*Address all correspondence to: ignacio.vila.garcia@sergas.es

IntechOpen

© 2020 The Author(s). Licensee IntechOpen. This chapter is distributed under the terms of the Creative Commons Attribution License (<http://creativecommons.org/licenses/by/3.0>), which permits unrestricted use, distribution, and reproduction in any medium, provided the original work is properly cited. 

References

- [1] Wei FC, Tay SK. Principles and techniques of microvascular surgery. In: Neligan PC, editor. *Plastic Surgery*. Vol. 1, Principles. 3rd ed. Elsevier; 2013. pp. 587-621.e10
- [2] Masia J, Olivares L, Koshima I, et al. Barcelona consensus on supermicrosurgery. *Journal of Reconstructive Microsurgery*. 2014;**30**:53-58
- [3] Gu YD, Cheng DS, Zhang GM, et al. Long-term results of toe transfer: Retrospective analysis. *Journal of Reconstructive Microsurgery*. 1997;**13**(6):405-408
- [4] Tamai S. History of microsurgery. *Plastic and Reconstructive Surgery*. 2009;**124**:e282-e294
- [5] Eskander A, Kang SY, Teknos TN, et al. Advances in midface reconstruction: Beyond the reconstructive ladder. *Current Opinion in Otolaryngology & Head and Neck Surgery*. 2017;**25**(5):422-430
- [6] Ray E. Head and neck reconstructive surgery. *Cancer Treatment and Research*. 2018;**174**:123-143
- [7] Murphy BD, Farhadi J, Masia J, et al. Indications and controversies for abdominally-based complete autologous tissue breast reconstruction. *Clinics in Plastic Surgery*. Jan 2018;**45**(1):83-91
- [8] Dancey A, Blondeel PN. Technical tips for safe perforator vessel dissection applicable to all perforator flaps. *Clinics in Plastic Surgery*. 2010;**37**(4):593-606
- [9] Khouri RK. Avoiding free flap failure. *Clinics in Plastic Surgery*. 1992;**19**:773-781
- [10] Hyza P, Vesely J, Schwarz D, et al. The effect of blood around a flap pedicle on flap perfusion in an experimental rodent model. *Acta Chirurgiae Plasticae*. 2009;**51**:21-25
- [11] Li X, Cooley BC, Gould JS. Influence of topical heparin on stasis-induced thrombosis of microvascular anastomoses. *Microsurgery*. 1992;**13**:72-75
- [12] International Registry on Hand and Composite Tissue Transplantation–World Exp. 2009. [Accessed: 31 December 2009]
- [13] Lutz BS, Wei FC, Machens HG, et al. Indications and limitations of angiography before free-flap transplantation to the distal lower leg after trauma: Prospective study in 36 patients. *Journal of Reconstructive Microsurgery*. 2000;**16**:187-191
- [14] Masia J, Clavero JA, Larranaga JR, et al. Multidetector–Row computed tomography in the planning of abdominal perforator flaps. *Journal of Plastic, Reconstructive & Aesthetic Surgery*. 2006;**59**:594-599
- [15] Isken T, Alagoz MS, Onyedi M, et al. Preoperative color Doppler assessment in planning of gluteal perforator flaps. *Annals of Plastic Surgery*. 2009;**62**:158-163
- [16] Acland RD. Microvascular anastomosis: A device for holding stay sutures and a new vascular clamp. *Surgery*. Feb 1974;**75**(2):185-187
- [17] Yan JG, Yousif NJ, Dzwierzynski WW, et al. Irrigation pressure and vessel injury during microsurgery: A qualitative study. *Journal of Reconstructive Microsurgery*. 2004;**20**:399-403
- [18] Lohman R, Siemionow M, Rockwell WB, et al. Acute adverse effects of blunt adventitial stripping. *Annals of Plastic Surgery*. 1995;**35**:60-65

- [19] Kemler MA, Kolkman WF, Slootweg PJ, et al. Adventitial stripping does not strip the adventitia. *Plastic and Reconstructive Surgery*. 1997;**99**:1626-1631
- [20] Haddock NT, Kayfan S, Pezeshk RA, et al. Co-surgeons in breast reconstructive microsurgery: What do they bring to the table? *Microsurgery*. 2018;**38**(1):14-20
- [21] Nunley JA. Microscopes and microinstruments. *Hand Clinics*. 1985;**1**:197-204
- [22] Baker JM, Meals RA. A practical guide to surgical loupes. *The Journal of Hand Surgery*. 1997;**22**:967-974
- [23] Shenaq SM, Klebuc MJ, Vargo D. Free-tissue transfer with the aid of loupe magnification: experience with 251 procedures. *Plastic and Reconstructive Surgery*. 1995;**95**:261-269
- [24] Acland RD, Sabapathy SR. *Practice Manual for Microvascular Surgery*. 3rd ed. The Indian Society for Surgery of the Hand (ISSH); 2008
- [25] Carrel A. *La technique opératoire des anastomoses vasculaires et la transplantation des viscères*. Lyon Medical. 1902;**98**:859-863
- [26] Chen YX, Chen LE, Seaber AV, et al. Comparison of continuous and interrupted suture techniques in microvascular anastomosis. *The Journal of Hand Surgery*. 2001;**26**:530-539
- [27] Godina M. Preferential use of end-to-side arterial anastomoses in free flap transfers. *Plastic and Reconstructive Surgery*. 1979;**64**:673-682
- [28] Chernichenko N, Ross DA, Shin J, et al. End-to-side venous anastomosis with an anastomotic coupling device for microvascular free-tissue transfer in head and neck reconstruction. *The Laryngoscope*. 2008;**118**:2146-2150
- [29] Klein I, Steger U, Timmermann W, et al. Microsurgical training course for clinicians and scientists at a German university hospital: A 10-year experience. *Microsurgery*. 2003;**23**:461-465
- [30] Spector JA, Draper LB, Levine JP, et al. Routine use of microvascular coupling device for arterial anastomosis in breast reconstruction. *Annals of Plastic Surgery*. 2006;**56**:365-368
- [31] Parry SW, Toth BA, Elliott LF. Microvascular free-Tissue transfer in children. *Plastic and Reconstructive Surgery*. 1988;**81**:838-840
- [32] Germann G, Bickert B, Steinau HU, et al. Versatility and reliability of combined flaps of the subscapular system. *Plastic and Reconstructive Surgery*. 1999;**103**:1386-1399