

# We are IntechOpen, the world's leading publisher of Open Access books Built by scientists, for scientists

6,900

Open access books available

186,000

International authors and editors

200M

Downloads

Our authors are among the

154

Countries delivered to

TOP 1%

most cited scientists

12.2%

Contributors from top 500 universities



WEB OF SCIENCE™

Selection of our books indexed in the Book Citation Index  
in Web of Science™ Core Collection (BKCI)

Interested in publishing with us?  
Contact [book.department@intechopen.com](mailto:book.department@intechopen.com)

Numbers displayed above are based on latest data collected.  
For more information visit [www.intechopen.com](http://www.intechopen.com)



# The Health and Future of the Six Hare Species in Europe: A Closer Look at the Iberian Hare

Margarida D. Duarte, Carina L. Carvalho,  
Fábio Abade dos Santos, Jéssica Monteiro, Madalena Monteiro,  
Paulo Melo Carvalho, Paula Mendonça,  
Patrícia Tavares Santos and Pedro C. Melo

## Abstract

Although there are around 40 species of hares in the world divided into three different genera (*Lepus*, *Caprolagus*, and *Pronolagus*), only six species inhabit Europe, all belonging to genus *Lepus*. The conservation status of these six species was recently revised in the International Conservation Union (IUCN) Red List of Threatened Species. *Lepus castroviejo* and *L. corsicanus* were attributed the status of “vulnerable”. The other four species, *L. europaeus*, *L. timidus*, *L. capensis*, and *L. granatensis*, were considered of “least concern” although a declining trend was recognized for the last two species’ wild populations. Here we review the major threats to the hare species in Europe, with emphasis on infectious diseases. Furthermore, we present the sanitary data regarding the Iberian hare populations from Portugal, which were severely affected by the emergence of a naturally occurring recombinant myxoma virus (MYXV), first reported in mid-2018. The recent detection in 2019 of a leporid herpesvirus (LeHV-5), which pathogenicity appears to be exacerbated in MYXV-infected hares, brings additional concerns to the health and conservation of the Iberian hare.

**Keywords:** hare species, Iberian hare, *Lepus granatensis*, viral diseases, myxomatosis, myxoma virus, MYXV, rabbit hemorrhagic disease virus, RHDV2, leporid herpesvirus, LeHV-5

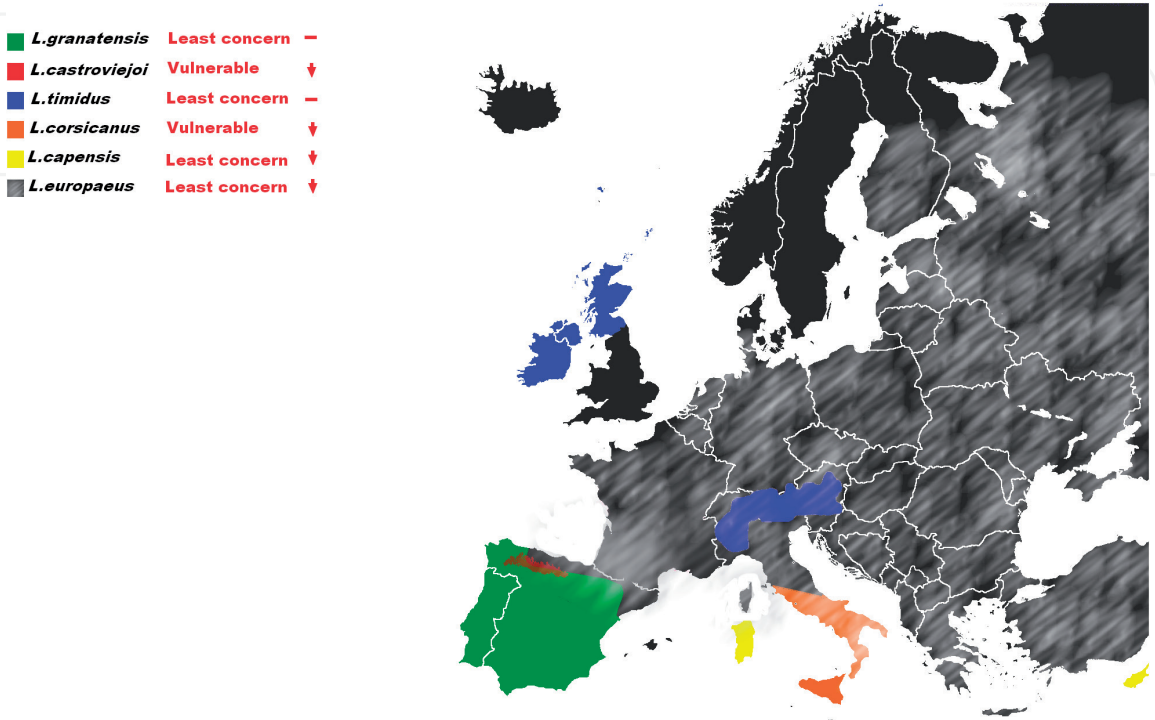
## 1. Introduction

### 1.1 Geographic distribution in Europe


The Lagomorpha order (belonging to the Mammalia class) includes the Ochotonidae family, with one sole genus designated *Ochotona*, and the Leporidae family, with 11 genera, namely, *Pentalagus*, *Bunolagus*, *Nesolagus*, *Romerolagus*, *Brachylagus*, *Sylvilagus*, *Poelagus*, *Pronolagus*, *Caprolagus*, *Oryctolagus*, and *Lepus*.

Like the other hare species in the world, the six hare species found in Europe are small herbivorous mammals belonging to the order Lagomorpha, family Leporidae, and genus *Lepus*.

These hare species, however, have different geographical distributions (Figure 1). The Iberian hare (*Lepus granatensis*) is endemic to the Iberian Peninsula and is found in almost all of the territories in Portugal and in southwest Spain (Figure 2) [1]. Although genetically and morphologically distinct from the Mountain hare (*Lepus timidus*), in evolutionary terms these two species are closely related [2]. However, the Mountain hare is adapted to cold climates, being found in northern continental Europe, Scotland, Ireland, and the Swiss Alps [3], while



**Figure 1.** Geographic distribution, conservation status (International Union for Conservation of Nature, IUCN), and trends of the populations of different hare species found in Europe. The distribution was inferred from the distribution on the IUCN maps, with low precision of the geographic distribution limits. Only distribution in Europe is shown. The distributions resulting from human introductions are not represented. For more information, see the individual page for each species on the website of the International Union for Conservation of Nature (IUCN).



**Figure 2.** Adult male Iberian hare (photograph by Sebastião Miguel, 2019).

the Iberian hare's preferred habitat is composed of undergrowth plains, alternating with small areas of bush or grove for refuge [4]. In Spain, two other species are also present, namely, the Broom hare (*Lepus castroviejo*), limited to the Castroviejo region of northern Spain [5], and the European or Brown hare (*Lepus europaeus*), the species with the widest geographical distribution, also found in the countries of Central and Eastern Europe [6]. The other two species that inhabit Europe are the Italian or Corsican hare (*Lepus corsicanus*), native to the southern coast of Italy and Sicily [7], and the Cape, Arabian, or desert hare (*Lepus capensis*), found in Sardinia. The latter originates from Africa, Asia, and the Middle East and, unlike the other five mentioned species, was introduced into Europe [8]. The six hare species and respective subspecies that inhabit Europe are identified in **Table 1**.

Species	Subspecies		Common names
<i>Lepus europaeus</i>	<i>L. e. europaeus</i>	<i>L. e. caspicus</i>	Brown hare
	<i>L. e. conkori</i>	<i>L. e. creticus</i>	European hare
	<i>L. e. cyprius</i>	<i>L. e. cyrensis</i>	
	<i>L. e. hybridus</i>	<i>L. e. judeae</i>	
	<i>L. e. karpatorum</i>	<i>L. e. medius</i>	
	<i>L. e. occidentalis</i>	<i>L. e. parnassius</i>	
	<i>L. e. ponticus</i>	<i>L. e. rhodius</i>	
	<i>L. e. syriacus</i>	<i>L. e. transsylvanicus</i>	
<i>Lepus timidus</i>	<i>L. t. ainu</i>	<i>L. t. begitschevi</i>	Mountain hare
	<i>L. t. gichiganus</i>	<i>L. t. hibernicus</i>	Blue hare
	<i>L. t. kamtschaticus</i>	<i>L. t. kolymensis</i>	Tundra hare
	<i>L. t. kozhevnikovi</i>	<i>L. t. lugubris</i>	Variable hare
	<i>L. t. mordeni</i>	<i>L. t. orii</i>	White hare
	<i>L. t. scoticus</i>	<i>L. t. sibiricorum</i>	Snow hare
	<i>L.t. sylvaticus</i>	<i>L. t. timidus</i>	Alpine hare
	<i>L. t. transbaicalicus</i>	<i>L. t. varronis</i>	Irish hare
<i>Lepus granatensis</i>	<i>L. g. granatensis</i>		Granada hare
	<i>L. g. gallaecius</i>		Liebre ibérica (Spanish)
	<i>L. g. solisi</i>		Lebre-ibérica (Portuguese)
<i>L.castroviejo</i>	No subspecies		Broom hare
<i>Lepus capensis</i>	<b>South Africa group</b>		Sardinian hare
	<i>L. c. capensis</i>	<i>L. c. aquilo</i>	
	<i>L. c. carpi</i>	<i>L. c. granti</i>	
	<b>East Africa group</b>		
	<i>L. c. aegyptius</i>	<i>L. c. hawkeri</i>	
	<i>L. c. isabellinus</i>	<i>L. c. sinaiticus</i>	
	<b>East Africa group</b>		
	<i>L. c. arabicus</i>		
	<b>North West Africa group</b>		
	<i>L. c. atlanticus</i>	<i>L. c. mediterraneus</i>	
	<i>L. c. schlumbergeri</i>	<i>L. c. whitakeri</i>	
<i>Lepus corsicanus</i>	No subspecies. Recently considered to be a distinct species from <i>L. europaeus</i>		Corsican hare
			Apennine hare
			Italian hare

**Table 1.**  
Scientific and common names of the six hare species found in Europe. The recognizable subspecies for *Lepus europaeus* (16 subspecies), *Lepus timidus* (16 subspecies), *Lepus granatensis* (3 subspecies) and *Lepus capensis* (13 subspecies) are shown.



Southern Europe provides, therefore, suitable habitats for the largest number of hare species. Morphologically, the six species of hare that inhabit Europe are distinguishable and follow the Bergmann rule, which establishes a direct relationship between the adults of medium size and the colder environments, for a given taxonomic group with wide geographical distribution [9].

## 1.2 Favorite habitats

The Iberian hare occupies a wide variety of habitats [2], namely, coastal dunes, wet mountain forests, and dry areas [10]. Like the other species found in Europe, such as the European hare, generally it does not need open water to sustain its metabolism [11]. Besides the open fields, the greater species densities are registered in intensive agricultural areas [12, 13] such as olive tree, sunflower fields, and vineyards [14].

## 1.3 Morphological characteristics

The Iberian hare is smaller than the other sympatric species, namely, the European hare and Broom hare, with mean body weight ranging from 2.0 to 2.6 kg [15]. Females are bigger than the males [10]. The Iberian hare has an extensive white ventral area that extends partially to the forefeet and hindfeet. This species has an evident contrast between the fur color of the back (ochraceous brown/gray-brown) and the belly (white). It has large brown eyes and long ears (with dark extremities) as a heat dissipation mechanism. The tail is also black on the dorsal surface and white on the ventral side (**Figure 3**). The hind limbs are longer than the front ones [9]. These characteristics added to a cleft lip and second pair of incisors in the upper jaw allow for the differentiation of leporids from rodents.



**Figure 3.**  
*Lateral-caudal view of a juvenile male Iberian hare (photograph by Margarida Duarte, 2019).*

## 1.4 Natural behavior

Hares are solitary, as they do not have a social organization nor inhabit burrows [14]. However, they can gather in groups following complex age-dependent patterns, mostly during feeding time, hence reducing predation risk and increasing feeding efficiency [16], or at the time of mating [17]. They do not have a territorial behavior, unlike other lagomorphs such as the wild rabbit [18].

Hares are active primarily during twilight and at night, though in summer they may be observed during the day [19]. During daylight, they seek refuge at the surface, in depressions a few inches deep, dug into the ground or in foxes and marmot's burrows [11].

The Iberian hare is highly specialized in camouflage and when chased by predators is capable of rapid escape, reaching around 70 km/hour [20]. It has a relatively lighter skeleton and larger heart than rabbits, which is only found in the fast-running species [9].

## 1.5 Reproduction

Reproductive parameters and breeding activities depend on the hare species and environmental conditions. A study on the reproductive strategies of genus *Lepus* compared the breeding season and litter size for distinct hare species, showing differences depending on the climatic conditions of the breeding areas. The species that occur in zones of greater latitude usually produce only a litter per year of about 6–7 young, while species in temperate climate zones have a longer reproductive period, with 3–4 litters of 2–5 leverets each. In the regions closer to the equator, there is no interruption in the reproductive period, with an average of 8-litter per year, each with 1–2 young [21].

The European brown hare, best studied due to its extensive geographic distribution, is a polyestrous seasonal breeder [22]. During the breeding peak, in the spring, mating leads to agglomerations of solitary hares, the so-called “March madness”. This species produces an average of 3–5 litter per year [23]. The mean litter size appears to be dependent on the region occupied, ranging between 2.0 and 2.7, with a maximum of 6 [24]. European hares newborns have an average weight of around 100g and are fully furred, born with eyes open, and able to walk. Weaning occurs around 4–5 weeks when juvenile weight reaches around 1 kg. The European hare is fertile at around 4–5 months of age reaching maximum weight at 8 months. When in continental climates, the reproduction in the year of birth is frequent [11]. This species has an age expectancy of 8–12 years [25].

The principal breeding season of Mountain hare occurs from February to September. The gestation period is about 42 days, but this inter-birth interval can be of 36 days in case of superfetation [11]. The species has a mean litter size between 1.9 and 2.1 with a maximum of 5 leverets.

The reproduction period of Iberian hare occurs throughout the year, although there is a certain seasonality in its reproductive activity, peaking in March and April with a minimum in autumn [24]. The onset of sexual activity is not season dependent but rather depends on the size of the animals [10]. The Iberian hare reproductive strategy, of continuous procreation [24], is concordant with smaller litters and longer breeding seasons [26]. Gestation period is also around 42 days. The seasonal trend in the population of young depends on the percentage of pregnant females and litter size. The most frequent gestations involve one or two fetuses; however, litter size may range from one to seven leverets, the largest litter size reported in the wild [11, 27]. The mean annual litter size was estimated in 2.1 leverets per litter [27]. Based on embryo





**Figure 4.**  
*Leveret of Iberian hare approximately one month of age (photograph by Margarida Duarte, 2019).*

counts, the mean litter size was 1.58 (range 1–4). Annual changes in the environment impact on the reproduction of the Iberian hare causing seasonal variations [27]. Newborn Iberian hares are also fully furred, born with eyes open, and able to walk [11] (**Figure 4**). These characteristics differentiate hares from other lagomorphs [28]. The mean weight of newborn leverets in captivity is 128.6 g (range 123–140 g) [11].

## 1.6 Ecological relevance

Hares have an ecological substantial importance as prey of several species like the golden eagle (*Aquila chrysaetos*), the European wildcat (*Felis silvestris*), the red fox (*Vulpes vulpes*), the Eurasian eagle owl (*Bubo bubo*), among others [29]. Due to the decrease in the number of wild rabbits (*Oryctolagus cuniculus*), the Iberian hare also plays an important role as prey for predators such as the *vulnerable* imperial eagle (*Aquila adalberti*) [30–32].

## 1.7 Importance as a small game species

As a game species, the Iberian hare is much appreciated by Portuguese and Spanish hunters (**Figure 5**). In Portugal, hare hunting is permitted from September to February by different modalities, namely, “salto” and “batida” (the name of two hunting processes in the Portuguese territory), and also standing, coursing, and falconry (Article 93, Decree-Law No. 202/2004 of 18 August); the last two are only allowed between January and February. The ability of high-speed endurance running is used in hare coursing (**Figure 6**), a modality that has led to the selection of the greyhound breed.

Although there is no hare population census-supported data from Portugal, the trends from the National Gamebag Census indicate a reduction in the Iberian hare populations in the recent decades that has accompanied the decline in the wild rabbit populations [33]. This decrease resulted from the combined and cumulative effect of several environmental factors that simultaneously affected the wild rabbit and the Iberian hare, along with the emergence of infectious diseases, namely, myxomatosis and rabbit hemorrhagic disease (RHD).





**Figure 5.**  
*Portuguese hunter (Jacinto Amaro, President of the Portuguese Hunting Federation, Fençaça), collecting an Iberian hare from his dog (German Shorthaired Pointer x English Setter), Avis, Alentejo, 21st December 2017 (photograph by Margarida Duarte).*



(A)



(B)

**Figure 6.**  
*Top: João Grave and his team performing field recognition before a race (Herdade da Bala, Évora, Alentejo, 20th February, 2016). Bottom: Greyhound dogs chasing an hare during a coursing race (Alentejo, 20th February, 2016). Photographs by José d' Oliveira e Sousa.*



## **2. The top threats to hares in Europe**

Most hare species have been subjected to a multitude of threats, which consequently have led to the reduction of the wild populations.

The International Union for Conservation of Nature (IUCN) has recognized as threatening factors to hares in Europe, the loss of habitats due to changes in the agriculture practices and development of urban areas, overhunting, poaching, trapping, agriculture pollution, human intrusions, and disturbances due to recreation activities. The impact of invasive non-native or problematic native species with consequent competition and hybridism has also been pointed out as treats to hare species.

The fragility of the hare species is also related to its own idiosyncrasies, such as the biology of its reproduction. The relatively small size of the litter and the characteristics of the shelters constructed above ground expose the juveniles to much higher predation rates than do rabbits.

Juvenile mortality is considered the most critical factor in the population dynamics. The hares' abundance is directly related to female breeding success and to juvenile survival rates [34], both directly dependent on habitat suitability [14]. The Iberian hare population dynamics is also greatly affected by food availability [35]. The highest juvenile mortality is observed after the maximum reproductive intensity period [14]. This mortality is due to, among other factors, agricultural land use, diseases, and predation [11]. Juvenile mortality of the European hare may reach 90% [36]. Data on the Iberian hare suggest that nearly 60% of the young die, corresponding to an increase of 40% in the population numbers [14]. More recently, prenatal mortality was estimated between 18% and 21% [24, 26]. One study refers to a minimum annual survival rate in young of 27.91% [27].

Below we detail some of the main threats to hares in Europe.

### **2.1 Habitat loss**

Many factors have cumulatively led to ecosystem modifications and to the deterioration of the hares' preferential habitats. The changes in agricultural practices, namely, by the cultivation of annual and perennial non-timber crops, have played a major role in habitat reduction. In addition, the expansion of urban and industrial areas as well as of roads and railroads brought limitations and barriers to the natural habitats and movements of wild species [1, 3, 5–8].

A meta-study involving 12 European countries concluded that the primary cause of the European hare decline since 1910 was agricultural intensification [11]. The average density of the European hare in the original habitats was two individual per 100 ha, although densities of 275/100 ha have already been recorded in territories with favourable conditions [11]. The territory range is directly dependent of the agricultural intensity and can be less of 20 ha (well-structured habitat) or up to 300 ha in habitats subject to intensive agriculture [11].

In the case of the Iberian hare, climate changes and reforestation of old cultures with the densification of open scrubland areas have been contributing to lower habitat suitability [1].

### **2.2 Diseases**

#### *2.2.1 Management of wildlife diseases*

Management strategies for wildlife disease encompass the prevention of introduction and spread of new diseases and control or eradication of an existing disease.

However, management of hares' diseases is hampered for several reasons. The high resistance of some pathogens in the environment, where they may persist infectious for long periods, the lack of identification of putative species' reservoirs, and their dissemination via arthropod vectors, such as the European brown hare syndrome virus (EBHSV), RHDV, RHDV2, and MYXV, potentiate new infections and make control very difficult.

Viral dissemination of leporid diseases has often been linked to anthropogenic activities [37, 38]. Changes in human activities, such as the introduction of cleaning and disinfection practices after hunting, the proper disposal of animal by-products, the periodic deworming of dogs, and the restriction of hare translocations to prevent disease spreading, can be easily implemented and impact positively on the recovery of the populations.

Immunization of wild populations, through oral bait vaccines, has been successful in the control of a few diseases such as rabies [39] and Aujeszky disease [40]. However, immunization is best suited for microparasitic exogenous infections with a low reproductive rate and in populations which have a low turnover [41], which is not the case of wild leporids. Several attempts to produce vaccines against RHDV for wild rabbits have been made in the past [42, 43].

Disease surveillance programs of wild animal populations are particularly crucial to obtain data regarding the animal health. The frequent movements of people through territories previously not occupied by man and the recurrent translocation of animals for hunting and conservation purposes increase the contact between wild and domestic animals and humans.

### *2.2.2 Importance of a conclusive diagnosis in decision-making*

Despite its limitations, the implementation of appropriate infection control measures must always be supported by a conclusive diagnosis, for which laboratory testing is essential.

The clinical evaluation of sick animals for diagnosis and research purposes is particularly difficult in wild species, where samples usually reach the laboratories as cadavers or organ samples. In these cases, histopathology provides the only possible bridge to understand the physiopathology of the disease. However, many factors compromise the rigor of the histopathological evaluation, such as an advanced degree of autolysis, which is common in wild species, and the consequences of sample freezing, often done due to transportation and logistic difficulties. Nonetheless, an exhaustive and systematic necropsy is the basis for a successful and complete laboratory diagnosis.

Isolation of pathogens, namely, of viruses by multiplication in sensitive cell lines, facilitates diagnosis and research. However, some pathogens of leporids are not cultivable *in vitro*, such as RHDV [44] and RHDV2 [45].

Molecular methods, in use for many decades, provide the possibility of testing many samples in a few hours with high specificity and sensibility.

Serologic examination of wild species allows the assessment of the previous contact of a population with a particular pathogen (herd immunity).

### *2.2.3 Relevant hare pathogens*

Until recently, unlike rabbits, infectious diseases were not considered a major threat to hares, except for the European brown hare syndrome (EBHS) [46].

Pathogens that infect hares may have an impact at individual or population level. Some are also zoonotic causing disease in humans.

Staphylococcosis (caused by the bacterium *Staphylococcus aureus*) and toxoplasmosis (caused by the protozoan *Toxoplasma gondii*) may affect hares but generally do not have a major impact on their health from a population perspective. Cestodal or tapeworm infections within this group comprise *Paranoplocephala wimerosa*, *Andrya cuniculi*, *Andrya rhopalocephala*, *Cittotaenia denticulata*, *Mosgovoyia pectinata*, and *Mosgovoyia ctenoides*, all causing catarrhal enteritis with malabsorption in severe cases [47].

Examples of diseases that may have an impact at the population level are pasteurellosis, outbreaks of which, despite residing within the upper respiratory tract of most animals, can kill up to 80% of the population. Hares are also particularly vulnerable to coccidial infections. It is believed that *Coccidia* play an important role in leveret's mortality rate but it also affects adults. Several species of *Eimeria* were reported in hares, namely, *E. europea*, *E. hungarica*, *E. robertsoni*, *E. robertsoni*, *E. septentrionalis*, *E. stefanskii* and *E. townsendii*, which can cause severe catarrhal enteritis and gaseous distension of the gut being found within the epithelial lining of the intestines. *E. stiedae* is limited to the liver and is less important in hares than in rabbits [47].

The gastrointestinal nematode, *Graphidium strigosum*, resides within the stomach of up to 40–60% of hares and in massive infections may cause anemia. In addition, *Trichostrongylus retortaeformis*, a nematode that causes catarrhal enteritis, and *Trichuris leporis*, found inside the cecum which produces toxic metabolites responsible for necrotic lesions within the gut wall, may also be present in high percentages in hare populations, namely, 75.8 and 39.8%, respectively [47, 48]. As for lungworm parasitosis, there are reports of 42–60% of *Protostrongylus commutatus* infection within a hare population [47]. In severe cases, animals present dyspnea and seromucosal nasal discharge due to catarrhal pneumonia and pleuritis. Lungworm infections seem to predispose to contact with bacterial disease [47–49]. Kornaś et al. [50] found a higher prevalence of nematode infection among adult hares than in juveniles from Southern Poland.

The typical examples of the zoonotic disease group are tularemia, a bacterial disease caused by *Francisella tularensis* [51], and leishmaniasis, caused by protozoan parasites of the genus *Leishmania* that are transmitted through the bite of female sand flies [52]. *Francisella tularensis* is one of the most virulent microorganisms presently known as few as 10 microorganisms can cause potentially fatal disease in man and animals (reviewed in [51]). The most important pathogenic subspecies are *F. tularensis* subsp. *tularensis* (Type A) that occurs usually in North America and *F. tularensis* subsp. *holarctica* (Type B) that occurs throughout the northern hemisphere (reviewed in [51]) and has been described in Iberia both in wild leporids [53] and humans [54]. Wild lagomorphs are one of the main reservoirs of *F. tularensis* in nature and are considered suitable sentinels for disease surveillance (reviewed in [51]). *Leishmania infantum* is responsible for both visceral and cutaneous zoonotic leishmaniasis in the Mediterranean Basin. Iberian hares were associated with an outbreak of 260 human cases of leishmaniasis affecting metropolitan Madrid, Spain, suggesting that hares may have an unexpected role in the epidemiology of *L. infantum* in Spain [52].

Brucellosis is another important zoonosis that can infect hares. In this species, it is caused by *Brucella suis* biovar 2 which can infect other wild or domestic animals and humans [47, 55]. Additionally, hares can also be infected with the zoonotic important *Echinococcus granulosus* and *Echinococcus multilocularis* [56–58]. Pseudotuberculosis is another typical disease of lagomorphs with zoonotic potential. It is caused by *Yersinia pseudotuberculosis* and is one of the most important lethal infections in hare with population losses of up to 50% [47, 59, 60]. Generally, the zoonotic pathogens do not have a major impact on hares, which act mainly as reservoirs for humans [51, 52, 55].



Some pathogens, such as *Taenia pisiformis* (a cestode parasitosis) [61], and a few viruses, namely, EBHSV [17], rabbit hemorrhagic disease type 2 (RHDV2) [62–67], and the new natural recombinant myxoma virus [68–70], cause potentially devastating diseases in hares, constituting real threats to the preservation of the wild populations. These pathogens are described in more detail below.

### 2.2.3.1 Cysticercosis

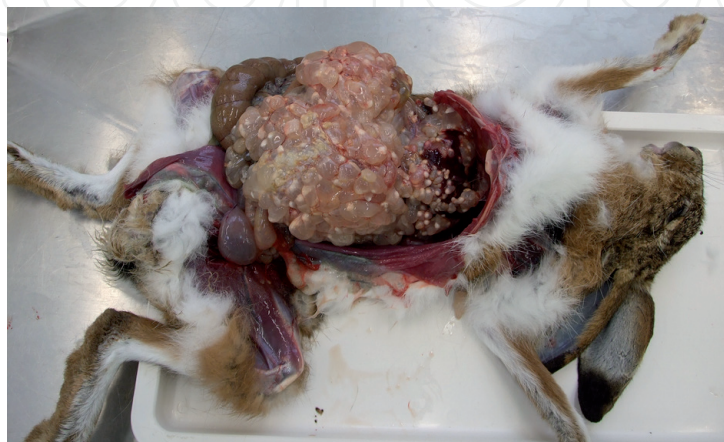*Taenia pisiformis* is known to cause a typical parasitosis of lagomorphs known as cysticercosis [33, 71]. The larval stage of this parasitic cestode is found particularly in rabbits and hares, having been described in the European brown hare [61] and in the Iberian hare [72]. Generally, cysticercosis does not give rise to clinically relevant signs in lagomorphs [61]. Light infections are unapparent, although heavy infections can cause abdominal distension and discomfort [73, 74]. Notwithstanding, a negative relation between cysticercosis and kidney fat index in Iberian hare and loss of prolificacy in New Zealand rabbits has been described [61, 75, 76].

There is little information on the prevalence and species diversity of cestode infections in rabbits because of their low pathogenicity and the limited opportunities available to diagnose infection [74]. In the European brown hare, the prevalence of *T. pisiformis* found in northern Italy was 14.8% (8/54) in 2013 and 3.28% (2/61) in 2015 [61]. In Portugal, cysticercosis has been frequently observed in the Iberian hare in some geographic areas from the south.

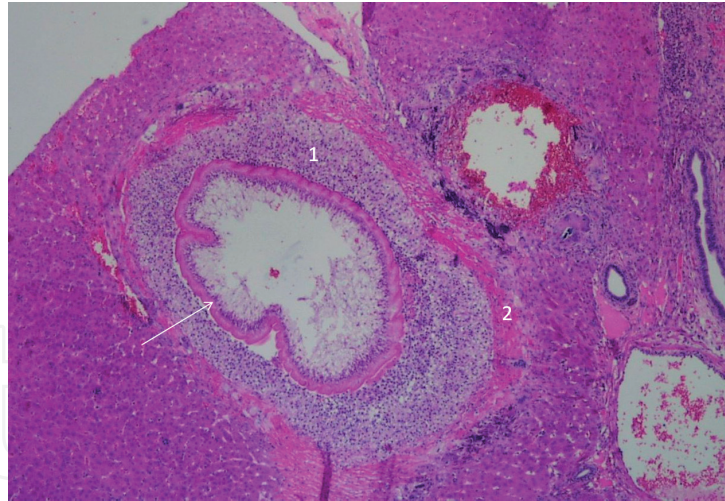
A combination of pathological-, parasitological-, and molecular-based techniques is usually employed for diagnostic purposes [74].

The presence of mature cysticerci within the abdominal cavity, the most common clinical presentation, can be observed during postmortem examination [77–79]. Yellowish-white parasitic cysts (2–18 mm) are observed in diverse locations, namely, in the peritoneum and liver surface. In massive infections, cysts may be found in the thorax, affecting the mediastinal space and pulmonary parenchyma, scrotum, small and large intestine, and renal capsule (**Figure 7**). Moderate to severe hepatomegaly may be observed.

Vesicles are covered by a membrane (thickness about 1 mm) containing clear liquid and an invaginated scolex of white cysticerci [80, 81]. In some cases, the migratory path of the larvae in the liver can be visualized as lighter colored areas. A host reaction to the parasite, with moderate interstitial lymphocytic hepatitis is observed. Liver parenchyma around protoscolex sections of cysts is usually surrounded by a



**Figure 7.** Macroscopic view of the abdomen and thorax cavities of an adult female hare with numerous cysticerci (the larval stage of *Taenia pisiformis*), attached to the serosa of the intestines and to the liver surface (photograph by the INIAV I.P. Pathology team).



**Figure 8.**

Microscopic view of a cysticercus vesicle (arrow), in the liver of an Iberian hare. Inflammatory cell infiltration (1) and peripheral necrosis (2) around the vesicle. HE, 40× (photograph by the INIAV I.P. Pathology team).

fibrous reaction or granulomatous inflammation with multinucleated giant cells, macrophages, plasma cells, and many eosinophils (**Figure 8**). Multifocal to disseminated interstitial chronic hepatitis with diffuse biliary stasis may be observed [74].

At the parasitological examination, cysticerci appear as small, transparent, fluid-filled cysts with a broad anterior and narrow, tail-like posterior. Examination by light microscopy using staining techniques can reveal features consistent with described morphologies of *T. pisiformis* cysticerci, namely, corrugated tegument, apical tegument invagination, and invagination canal [74, 82–85].

The molecular diagnosis of *T. pisiformis* cysticercosis can be performed using a generic pair of primers described by Boubaker et al. [86]. This pair of primers was designed to amplify the *Taeniidae* mitochondrial 16S ribosomal RNA gene and is suitable for amplifying and distinguishing through sequence analysis 13 separate cestode species and theoretically for distinguishing further 10 cestode species, predominantly from the family *Taeniidae* [86].

#### 2.2.3.2 European brown hare syndrome

European brown hare syndrome (EBHS) is caused by a single-stranded RNA non-enveloped virus (EBHSV) belonging to the *Lagovirus* genus, family *Caliciviridae*, which induces a disease in the European brown hare similar to rabbit hemorrhagic disease (RHD) in rabbits, characterized by hemorrhages in several organs and liver necrosis. Despite EBHSV emergence was recognised in the 1980s in the north of Europe [46], Duff et al. [87] reported descriptions of lesions consistent with EBHS in hares since 1976 in England. In addition, Lenghaus et al. [88] revealed that hunters in Scandinavia knew of the disease in the early 1970s. Until now, EBHSV is restricted to Europe having been registered in the European hare in Sweden [46], Italy [89], the United Kingdom [87, 90], France [91], Poland [92], Greece [93], and Slovakia [94].

EBHS causes severe necrotic hepatitis in both wild and captive hares (European brown hares and mountain hares) [46, 93, 95]. The infection has significant similarities to RHD in its epidemiology, symptomatology, and pathology [93, 96], being characterized by rapid progression, mild nervous symptoms (including depression, muscular tremors, and incoordination), presence of sero-haemorrhagic liquid at the nostrils, congestion and extensive haemorrhages on the lungs and on serosa and mucosa, severe necrotic hepatitis, and congestion of the spleen and kidneys [90, 92, 93, 96].

Severe congestion of the trachea may also be present. Splenomegaly and dark red-black discoloration of the spleen, kidney congestion, and hepatomegaly may

also be present. Liver is usually friable and discolored [93, 97]. Death occurs within 3 days after the onset of clinical signs, and mortality rates are extremely high and can reach 100% [90, 92].

Microscopically, necrosis may affect the whole hepatic lobule or be confined to peripheral or periportal areas. Hepatocytes nucleus appear swollen and lytic or may have completely disappeared. Coagulation necrosis can occur. Periportal and mid-zonal hepatocellular necrosis is the most consistent histopathologic finding. Nuclear degradation appears to be rare in EBHS contrary to what happens in RHD. The hepatocytes frequently contain fine iron granules.

Other findings are marked hyperemia irregularly distributed over the hepatic lobule and disruption of sinusoids with hemorrhage. In the necrotic and hemorrhagic areas, neutrophil infiltration and mesenchymal cell proliferation are observed.

Moderate dilatation of segments of the proximal and distal tubules with flattened epithelium and focal hydropic degeneration of the proximal tubules may be present. The tubules can contain pale eosinophilic protein casts of a slightly granular appearance. Congestion of spleen red pulp has been described. White follicles can appear depleted of lymphocytes, with karyorrhexis or pyknosis of B and T cells. Follicular hyperplasia can also occur [93, 97].

As with other lagoviruses, EBHSV cannot be isolated or propagated in rabbit and hare primary cell cultures or in cell lines (RK-13, PK-15, FL) [46, 98, 99]. The virus can be detected usually in the liver, which contains high viral loads, by electron microscopy, which shows 30–35 nm virions indistinguishable from those of RHDV [90, 100]. Other methods for virus detection include the hemagglutination (HA) test, using human type “A” or “O” red blood cells [46, 100], enzyme-linked immunosorbent assay (ELISA)-based methods [46, 90, 96, 98], and RT-PCR. Bascuñana et al. [99] developed two conventional RT-PCR assays for the detection and differentiation of RHDV and EBHSV, both able to detect as few as 10 copies of cloned viral genomic fragments, with no cross-amplification between the two viruses. The system can be used for amplification of VP60 genomic sequences from fresh and fixed tissues. Primers were selected from similar regions of the VP60 genes to amplify a fragment of 316 nucleotides from the genome of RHDV and a region of 265 nucleotides from the genome of EBHSV. In addition, Le Gall-Reculé et al. [101] developed an immunocapture (IC)-RT-PCR for EBHSV diagnosis that can be carried out directly with the liver exudate. Viral particles present in the sample are captured by specific antibodies immobilized on a microtitration plate. After enzymatic disruption of virus-antibody complexes, viral RNA is released and subjected to RT-PCR. The assay combines the rapidity of an ELISA test (because immunocapture and the RT reaction are carried out in the same microtiter plate) and the sensitivity of PCR, being suitable for the processing of large numbers of samples and phylogenetic studies. In 2011, Zexiao et al. [102] also developed a RT-PCR for the detection of EBHSV with good specificity and sensitivity, able to detect about 50 copies of cloned viral genomic fragments (pGM-T-EBHSV), with no amplifications for RHDV.

#### *2.2.3.3 Rabbit hemorrhagic disease*

RHD is caused by two types of lagoviruses, namely, RHDV that emerged in China in 1986 in domestic rabbits [103] and RHDV2 (RHDVb or GI.2), a virus genetically related to but distinct from RHDV, that emerged in France in 2010 in rabbits [104]. RHDV2 quickly replaced the circulating strains of RHDV in most European countries, both in the wild and domestic populations. In the Iberian hare, Lopes et al. [105] reported RHDV only in two animals during a retrospective study. However, in the last decade, several cases of RHDV2 disease have been reported in



the European hare in France (2013) [64], Spain (2014), and Italy (2012) [65], in the United Kingdom (2018 and 2019) [67], in Australia (2015) [106], in Sweden (2016 and 2017) [38], and in the Netherlands (2017) (<https://www.dwhc.nl/en/haas-rhdv-2-nederland/>). RHDV2 was also reported in the Cape hare on the island of Sardinia (2011) [63] and in the Italian hare, in Sicily (2012) [34]. More recently (in 2019), cases of RHDV2 infection have been reported in the Mountain hare in Scotland [107] and Ireland ([https://www.oie.int/wahis\\_2/public/wahid.php/Reviewreport/Review?page\\_refer=MapFullEventReport&reportid=31386](https://www.oie.int/wahis_2/public/wahid.php/Reviewreport/Review?page_refer=MapFullEventReport&reportid=31386)).

However, RHDV2 infections have never been described in the Iberian hare.

The clinical evolution of RHD can be peracute, acute, subacute or chronic. The clinical manifestations are mainly present in the acute form of infection though in the subacute form, similar but milder signs can be observed. In the peracute form, usually there are no clinical signs of disease [108]. Chronic and subacute forms are more frequent in RHDV2 infections [109], which also differ from RHDV in affecting rabbit kits as young as 11 days old that develop disease [104, 109, 110].

The incubation period may vary between 1 and 5 days. Death may occur 12–36 hours after the onset of fever ( $>40^{\circ}\text{C}$ ). The clinical signs observed include prostration, apathy, convulsion, ataxia, paralysis, opisthotonos, paddling, anorexia, dullness, groans and cries, dyspnea, frothy and bloody nasal discharge, and cyanosis of mucous membranes. Subacute cases may present with malaise, mild anorexia, apathy, weight loss, and jaundice [108].

RHDV2-infected hares exhibited clinical signs and lesions similar to those induced by EBHSV [64–66]. Epistaxis and a RHD-like disease was reported in the Italian hare [34] and in the Sardinian Cape hare [63].

The macroscopic findings in hares affected by RHDV2 include extensor rigidity, epistaxis, and hyperemia of the tracheal mucosa, where a foamy bloody mucous can be found. The liver can be pale or congested (light brown to orange-pink) or presenting a reticular enhancement pattern suggestive of zonal vacuolar hepatocellular degeneration and necrosis. Moderated to severe congestion or petechial hemorrhages (or multifocal to coalescing hemorrhage) can also be observed in the lungs and kidneys.

Microscopic lesions may comprise generalized hepatic necrosis, including coagulative necrosis and multifocal areas of lytic necrosis. Acidophilic bodies may be observed in the hepatocytes. Other findings may include fatty degeneration of hepatocytes and periportal mononuclear infiltration. Degeneration and necrosis of kidney proximal tubules cells or acute tubular nephrosis may also be registered. In some cases, it is possible to observe moderated lymphocytolysis in the spleen white pulp, and moderate to severe fibrin deposition and necrosis of the red pulp can be observed [62–64, 66, 67].

Different molecular assays for the detection of RHDV have been described since the late 1990s, including conventional RT-PCR assays [99, 111–113], immunocapture RT-PCR [110], real-time multiplex RT-PCR [114], and more recently, loop-mediated isothermal amplification [115] and SYBR green-based real-time PCR [116]. None is designed to specifically detect RHDV2 strains.

For the amplification of RHDV2, Le Gall-Reculé et al. [109] described specific primers which amplify a 794-bp sequence located in the C-terminal of the gene encoding the VP60 of RHDV2.

Duarte et al. [117] developed a specific real-time TaqMan RT-PCR for the detection of RHDV2. The system was designed to amplify a 127-nucleotide-long RNA region located within the *vp60* gene, being able to detect as few as 9 RNA molecules. The method has proven a valuable tool to diagnose most of RHDV2 circulating strains and useful to monitor viral loads [118], disease progression, and vaccination efficacy [119]. The system figures in the OIE Manual as a

recommended method for nucleic acid detection ([https://www.oie.int/fileadmin/Home/eng/Health\\_standards/tahm/3.06.02\\_RHD.pdf](https://www.oie.int/fileadmin/Home/eng/Health_standards/tahm/3.06.02_RHD.pdf)). Nearly 5 years since it was developed, the method remains suitable for the detection of the circulating field strains [120].

More recently, Dalton et al. [121] developed a diagnostic real-time RT-PCR for the detection of RHDVb strains targeting a 91-bp amplicon within the VP60 protein that covers nucleotides (nts) 6190–6280. The RT-PCR is carried out as a duplex using the endogenous amplification control of the beta-actin gene from a commercial kit (EXOPOL S.L.). The same authors also designed a conventional RT-PCR for the differentiation of RHDV2 strains from RHDV2 recombinants by subsequent sequencing of the amplicon. Primers were designed to cover a 449-nt region from the 3' region of the RHDV polymerase (3D) to the sg promoter region. Degenerate primers were designed to bind at positions 4837–4856 and 5266–5286 in the RHDV2 genome [121].

#### 2.2.3.4 Myxomatosis

Myxomatosis, caused by a double-stranded DNA enveloped virus belonging to the family *Poxviridae*, genus *Poxvirus*, was for a long time considered a disease of rabbits. Only a few sporadic cases were reported in the European brown hare in Spain in 1953 [122], France in 1954 [123], and the United Kingdom in 2014 [124]. However, this scenario changed radically in 2018, when outbreaks of myxomatosis in Iberian hare occurred in Spain [125] and in Portugal [126] [https://www.oie.int/wahis\\_2/public/wahid.php/Reviewreport/Review?page\\_refer=Map+FullEventReport&reportid=28628](https://www.oie.int/wahis_2/public/wahid.php/Reviewreport/Review?page_refer=Map+FullEventReport&reportid=28628), causing an alarming wave of mortality in wild populations [68, 126].

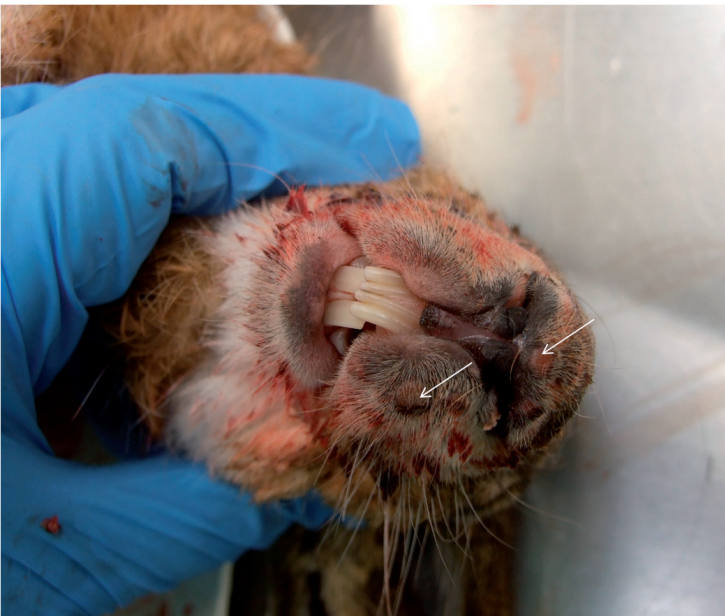The hare myxoma virus (MYXV) is a recombinant with additional genetic material in comparison with the MYXV from rabbits. The inclusion of this supplementary material led to the disruption of one gene and to the duplication of four others. While the origin of this recombinant is not yet completely understood, some authors have suggested that the extra genes originated from a capri- or cervipoxvirus [69, 70], and others propose the translocation of genes from the rabbit myxoma genome itself [70].

In rabbits, when the typical signs and skin lesions develop, the clinical diagnosis is possible. These signs may include blepharitis, blepharoconjunctivitis, anorexia, listlessness, fever, and depression. In the dermatophic form of myxomatosis, disseminated cutaneous and mucocutaneous lesions, accompanied by oedema, are usually present in the eyelids, nose, lips, ears, and genitals (vulva, or scrotum). Emaciation and dyspnea followed by death may occur within a few weeks [127, 128]. However, in peracute forms, sudden death may occur with no clinical signs of disease or unspecific signals such as lethargy, loss of appetite, fever, and eventually swelling of the eyelids [129]. The clinical diagnosis of the atypical amyomatous forms of myxomatosis, characterized by minor cutaneous signs and intense respiratory distress, may be complicated as well [127, 129–131].

In hares, as for rabbits, the clinical diagnosis relies on the observation of the typical skin lesions, namely, small nodules and oedema, usually present in the eyelids, nose, and genitalia. The typical myxomas observed in the ears, eyelid, or other areas of the skin in rabbits are rarely observed in hares (**Figure 9**). Blepharoconjunctivitis and mucopurulent eye discharge are a common feature [68, 69, 126].

MYXV-infected hares can show good body condition, contrary to what is common in rabbits with myxomatosis.

Histopathological findings include epidermal hyperplasia and balonization of the epidermal keratocytes. Eosinophilic cytoplasmic inclusion bodies may be observed in the keratinocytes. In the dermis, an abundant basophilic myxoid matrix

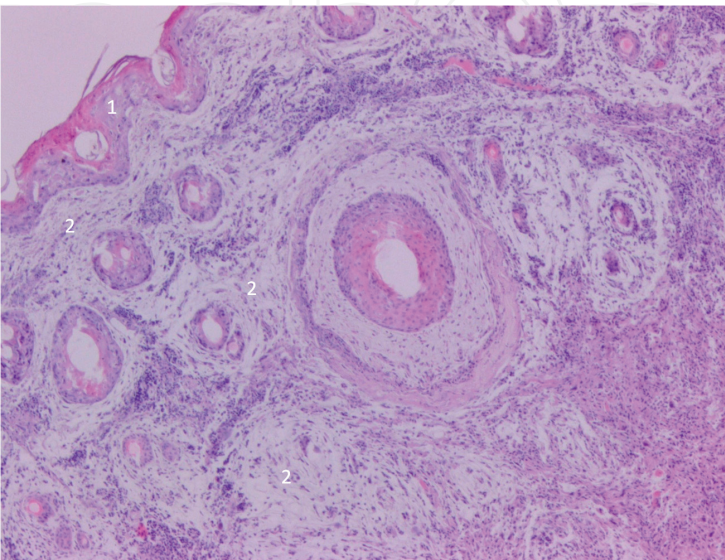


**Figure 9.**  
*Iberian hare positive to myxoma virus, with nodular formations in the lips (arrows) (photograph by the INIAV I.P. Pathology team).*

admixed with oedematous areas with inflammatory infiltrates of macrophages, lymphocytes, and polymorphonuclear cells may also be seen (**Figure 10**). A severe depletion of lymphocytes may be noted in the spleen [68, 132, 133]. As for rabbits, the clinical diagnosis of the atypical form of the disease in hares may be limited.

Molecular methods provide the possibility to detect a reduced number of viral DNA copies in multiple tissue samples such as nasal and conjunctival swabs, skin oedema, myxomas, crusts, lungs, and semen. The highly conserved regions of the MYXV genome are used for primer design for PCR-based assays, allowing for detection of the circulating virus strains. Several conventional [134] and real-time PCR methods [135–137] were described and can be used to detect MYXV.

The conventional PCR system by Cavadini et al. [134] is based on the MYXV genes *M071L*, *M140R*, and *M142R/M144R*. Primers were designed for PCR and PCR-restriction fragment length polymorphism (PCR-RFLP) protocols, enabling



**Figure 10.**  
*Histopathology of the lip of an Iberian hare with myxomatosis showing moderate hyperplasia of the epidermis (1) and myxoid tissue in the dermis (2). HE, 40× (photograph by the INIAV I.P. Pathology team).*



to discriminate vaccinated from naturally infected animals and to detect mixed infections caused by wild-type and vaccine MYXV strains.

Dalton et al. [138] developed a long-range PCR-RFLP method directed towards amplification of genomic MYXV DNA from the left and right terminal inverted repeat regions (TIRs) with subsequent differentiation of virus strains by RFLP. Two sets of primers were designed covering the entire TIRs and flanking sequences (*M009L* gene and genome regions from *M141R* to *M156R*). This method proved to be efficient in the identification of mutations, with potential application in phylogenetics.

Quantitative PCR systems (qPCR) allow the determination of viral copy number in the tested sample. In the PCR-based method developed by Albini et al. [136], primers and probe were designed to amplify a 147-bp fragment of the serpin (*Serp2*) gene, allowing the detection limit of 23 genome copies of MYXV DNA per reaction.

The TaqMan qPCR by Belsham et al. [135] that targets a *M029L* gene of MYXV was designed for detection and confirmation of suspected cases of myxomatosis. The assay detects efficiently as few as 10 copies of MYXV DNA, per reaction, while not producing amplification signals for other poxviruses.

A highly sensitive qPCR assay targeting nucleotide sequences within the MYXV gene *M000.5L/R* was developed by Duarte et al. [137]. This gene has two copies in the MYXV genome, in the right and left TIR, respectively. Hence, when compared to other PCR protocols targeting virus genes present in a single copy, this method shows a significantly higher sensitivity while enabling the detection of 2.6 genome copies of MYXV DNA per reaction. Furthermore, the *M000.5L/R* is a unique gene in the *Leporipoxvirus* genome [139] increasing the specificity of this PCR-based system. The method figures in the OIE Manual as a recommended method for nucleic acid detection ([https://www.oie.int/fileadmin/Home/eng/Health\\_standards/tahm/3.06.01\\_MYXO.pdf](https://www.oie.int/fileadmin/Home/eng/Health_standards/tahm/3.06.01_MYXO.pdf)).

The systems described by Cavadini et al. [134] and Duarte et al. [137] were successfully used to detect the recombinant MYXV obtained from hares (*our results unpublished*).

For many years, the laboratorial diagnosis of myxomatosis was based on the isolation of the virus in cell culture. Isolation of MYXV can be accomplished in primary cultures of rabbit kidney (RK) cells or in cell lines (RK-13, Vero). This method is recommended by the OIE, particularly for the diagnosis of amyxomatous form of the disease. In this case, antemortem diagnosis can be done using nasal and conjunctival swabs [140].

The virus multiplies in the cytoplasm of the infected cells [141, 142]. For the classical MYXV strains from rabbits, a cytopathic effect (CPE) may develop in 24–48 hours or take up to 1 week, depending on the virulence of the strain [143]. CPE is usually characterized by the formation of syncytia and roundup and contraction of the infected cells. Later, when all cells are affected, the cell monolayer detaches completely.

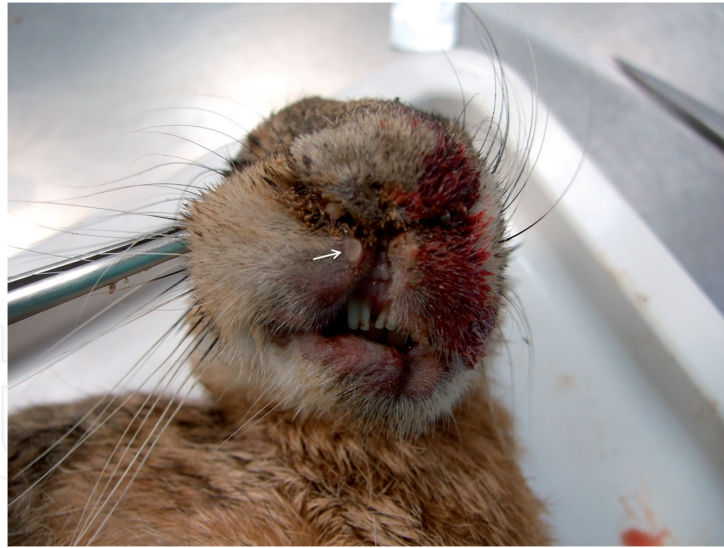Viral isolation of the Iberian hare recombinant MYXV strains is more difficult since CPE is less obvious, differing from the one induced by the rabbit MYXV strains.

#### 2.2.3.5 *Leporid herpesvirus*

Recently a new leporid herpesvirus (LeHV-5) was detected by PCR [144] and electron microscopy in Iberian hares [132].

Herpesvirus DNA was detected in hares with myxomatosis, where, in most cases, herpetic-like skin vesicles were present in the nostrils and lips along with necrosis of the genitalia, most evident in males affecting the penile glans but also observed in females (**Figure 11**) [132].

However, LeHV-5 DNA was also detected in apparently healthy hares, testing negative to MYXV, probably representing the latent stage of infection.

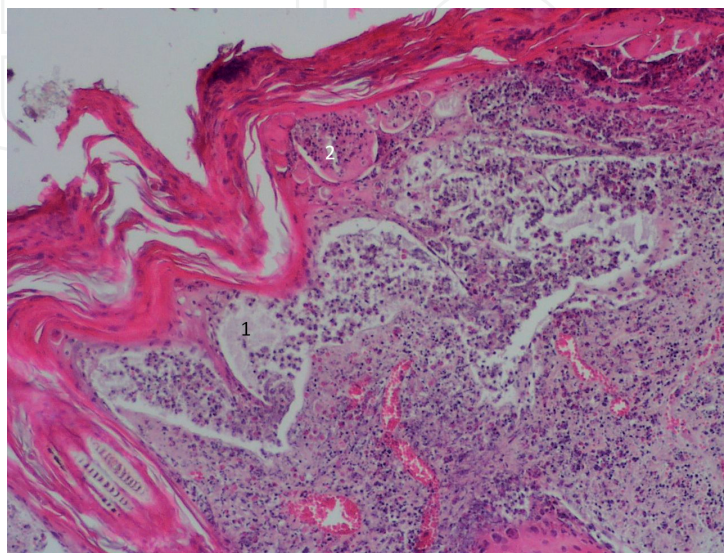


**Figure 11.**  
*Small vesicle in the lips of an Iberian hare positive to herpesvirus (photograph by the INIAV I.P. Pathology team).*

The penile and foreskin epithelia of some LeHV-5 positive hares was mostly necrotic and replaced by a thick band of necrotic cells, heterophils, and red blood cells. Severe heterophilic infiltrations of the stroma, in either a diffuse pattern or multifocal aggregates, are common.

Proliferation of pleomorphic spindle cells is observed, with some nuclei almost completely filled with slightly eosinophilic inclusion bodies, resembling Cowdry nuclear inclusions [132]. Coalescent intraepidermal and subepidermal vesicopustules filled with fibrin and necrotic cell debris and multifocal detachment of the eyelids, lips, and foreskin epidermis were seen (**Figure 12**) [132]. In the dermis, multifocal hemorrhages, intense infiltration by heterophils, and necrotic cells with accumulation of chromatin debris were present [132].

Clinical diagnosis of this disease is difficult and may pass unnoticed. During lytic replication (reactivation phase), small vesicles may be observed in the mucous membranes and skin, which may still be intact, or after erosion, mainly in the lips



**Figure 12.**  
*Subepidermal vesicular-pustular lesion with detachment of the epidermis (1) and intradermal vesicular-pustular lesion (2), from a herpesvirus positive Iberian hare. HE, 100× (photograph by the INIAV I.P. Pathology team).*



and nostrils. Necrosis of the genitalia may not be present. The conclusive diagnosis is achieved by PCR and sequencing or by electron microscopy.

### 2.3 Excessive predation

Predation can have a major impact on hare populations since, unlike the wild rabbit, hares generally do not burrow, except when subjected to high persecution pressure and without alternative escape, and are therefore more exposed to this phenomenon. The hares' natural predators include large birds of prey and wild canids and felids [29]. In fact, the Iberian hare is the preferred prey of some Iberian vertebrate predators, such as the Eurasian eagle owl (*Bubo bubo*) [145].

Some carnivorous bird species that can prey on hares have shown a progressive increase on the Iberian Peninsula. This is the case of the white stork (*Ciconia ciconia*) that between 1984 and 2004 showed a considerable increase in breeding numbers, as exposed by the number of occupied nests which increased about 401% in that period [146]. Furthermore, the number of wintering storks increased from 1187 individuals in 1995 to 14,434 in 2015 [147]. Large flocks of storks are presently found in many areas of mainland Portugal (**Figure 13**). The Eurasian or common magpie (*Pica pica*) is another omnivorous bird that may prey young hares [148].

The wild boar (*Sus scrofa*), a mammalian omnivore and one of the most widespread wildlife species which has entered a stage of continuous growth in Europe and could even be considered a pest species [149], can also have a potentially devastating impact on hare populations due to the easy predation of juvenile hares [150]. An increase in juvenile mortality reduces the recruitment of new individuals to populations, affecting their renewal.

### 2.4 Hunting pressure

Extrinsic factors threatening the conservation of hare populations include reduced size and quality of the habitat, which is particularly critical for hare species whose territories are restricted to very limited geographical areas, such as the northern Castroviejo broom hare, in Spain, and the Italian hare, in Italy. In these small territories, excessive hunting pressure can pose a serious threat to the preservation of these species [5, 7].

In addition, the imbalance of the complex Iberian trophic chains resulting, among other aspects, from the reduction of wild rabbit populations, increases predation on hares by predators that preferentially feed on wild rabbit [31, 32].



**Figure 13.**  
Flock of Skorts, Alentejo, 15th March 2020 (Photograph by Fábio Abade dos Santos).



## 2.5 Other causes

The mechanization of cereal harvesting was recognized as a cause of direct mortality of juvenile hares by their exposure on the soil surface. Also, the effect of pollution resulting from agricultural chemicals, agricultural and forest effluents [1], and road traffic pose additional threats to the species [10].

## 3. Sanitary surveillance of the Iberian hare in Portugal

In Portugal, an action plan to control rabbit viral hemorrhagic disease was set in place in August 2017 by a nine-institution partnership, following the Dispatch 4757/17 of May 31 of the Ministry of Agriculture. This partnership is comprised of the National Institute of Agrarian and Veterinary Research (INIAV. PI), the General Directorate of Food and Veterinary (DGAV), the Institute for Nature Conservation and Forests (ICNF), the Research Centre in Biodiversity and Genetic Resources (CIBIO), the Institute for Experimental Biology and Technology (iBET), the Portuguese first sector hunting organizations (FENCAÇA, ANPC, CNCP), and the National Order of Veterinary Doctors (OMV). Since its implementation from August 2017 to the end of January 2020, 1507 wild leporids originating from almost 50 hunting reserves where sampled and systematically tested for the presence of RHDV, RHDV2, and MYXV to assess the population health during the hunting seasons. Of these, 89.93% (1099/1222) were wild rabbits, and 10.07% (123/1222) were hares. Furthermore, during the same period, 285 animals found dead in the field in mainland Portugal were also screened, of which 77.54% (221/285) corresponded to wild rabbits and 22.46% (64/285) were hares.

Hunting associations are authorized by permits emitted by the National Forest Authority, Institute for Nature Conservation and Forests (ICNF).

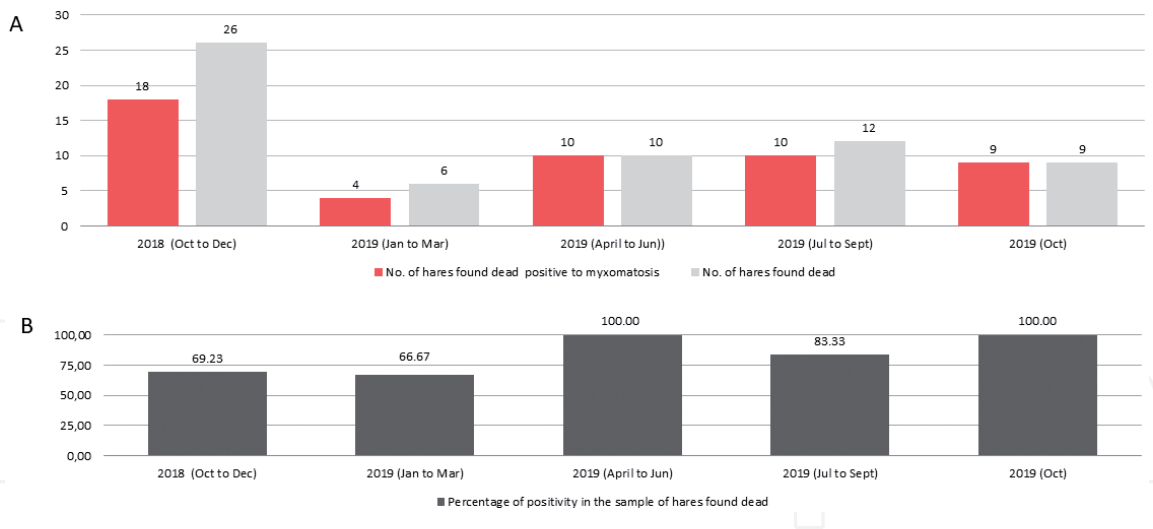Below we present the virological examinations regarding the Iberian hare. Despite RHDV2 being detected in several hare species, none of the 187 hares investigated in Portugal between August 2017 and the end of January 2020 were positive, confirming the lack of susceptibility of Iberian hare to this virus.

As in domestic and wild rabbits, where RHDV has no longer been detected in Portugal since the emergence of RHDV2 in 2012, RHDV-RNA was not detected in Iberian hares [151].

MYXV was first detected in Portugal in October 2018 in an adult hare, found dead in a hunting reserve, located in the district of Évora, Alentejo Region, in the south mainland. The virological diagnosis was made by the National Reference Laboratory for Animal Diseases (INIAV, Oeiras, Portugal) in October 2018.

The first evidence of Iberian hare mortality by myxomatosis was noticed in early summer of 2018, in Spain. The affected hares showed clinical signs compatible with myxomatosis and were found dead or moribund in hunting reserves in the municipalities of Montalbán and La Rambla (Córdoba), in the south. The diagnosis was confirmed by the Central Veterinary Laboratory in Algete, Madrid, Spain in July 2018 (OIE report).

Before the detection of the first MYXV case in the Iberian hare in Portugal, within the scope of the national surveillance action plan as referred above, 91 hares were sampled and screened for the presence of MYXV, between August 2017 and end of October 2018. None of the animals tested positive, suggesting that the virus was not circulating in the populations sampled. After the first case, by the end of October 2018 until the end of January 2020, 107 Iberian hares were tested for MYXV, 58.88% (63/107) of which were found dead or moribund and 41.12% (44/107) were legally hunted. In the first group, 82.54% (52/63) animals were positive for myxomatosis, reflecting the significance of this infection as a cause of death in Iberian hares.



**Figure 14.** Results of the surveillance of myxoma virus in 63 Iberian hares found dead in continental Portugal between October 2018 and October 2019, by trimester (A). Percentage of positivity in the same sample (B).

The percentage of positivity in the sample of hares found dead by trimester showed an increasing trend, suggesting the progressive spread of the disease (**Figure 14**).

In the group of 44 hunted animals, only 4 were positive (9.1%). Most of these samples ( $n = 39$ , 86.4%) were collected during the 2018–2019 hunting season. The small sample gathered during the 2019–2020 hunting season ( $n = 6$ , all collected in October 2019) does not allow to predict the trend of positivity for this group.

Since the non-recombinant rabbit MYXV is endemic in the entire national territory, our results suggest that the Iberian hare is not susceptible to the rabbit strains. However, serological data obtained from Iberian hares shows the presence of antibodies against RHDV2 and myxoma virus indicating the ability of these viruses to induce an immune response [151].

#### 4. Conclusions

The progressive loss of habitat due to the deep changes in land use, excessive predation, and hunting poses serious threats to the conservation of hare species in Europe.

The development of effective strategies that trigger the continuous implementation of good practices is urgent to ensure the preservation of wild populations and to promote their recovery in the most affected areas. Such measures should safeguard the persistence/existence of favorable habitats for the species, particularly threatened in the geographical areas where their natural territories are reduced or in areas where farmers adopted super-intensive production methods.

In Portugal and in Spain, government research institutions, academics and field agents joined efforts through projects +Coelho and MIXolepus, respectively, to evaluate and counteract the effects of this emergent virus in Iberian hare.

At a time when the conservation status of the wild rabbit has recently been revised from “least concern” to “endangered,” it seems inevitable that, in a near future, the status of some hare species, namely, the Iberian hare, will also be revised.

Apprehension on the preservation and sustainability of wild leporid populations in the Iberia is aligned with the concerns of many other wild species. According to the World Wildlife Fund (WWF) “Living Planet Report 2018” report, global wildlife populations have declined by an average of 60% over the past 40 years, demonstrating that the planetary biodiversity is threatened.

Infectious diseases, particularly those of viral etiology, have been gaining importance as disrupting factors for the stability of rabbits and hares. The potential evolution of the viral *hemorrhagic* disease virus (RHDV) to RHDV2 and the recent emergence of a recombinant myxoma virus, able to specifically infect hares, showed that these viruses were capable to alter their initial host specificity, acquiring the ability to infect some hare species, with very expressive morbidity and mortality rates. Furthermore, the recent detection of a new herpesvirus in Iberian hares, associated with genital pathology, raises addition concerns to the future of this species.

## **Acknowledgements**

The authors thank all the hunters who participated in the collection of biological samples, represented by João Carvalho (ANPC), Jacinto Amaro (FENCAÇA), and Fernando Castanheira Pinto (CNCP). Funding was supported by Fundo Florestal Permanente (Government of Portugal) within the scope of the action plan for the control of rabbit viral hemorrhagic disease (+Coelho 2 project nº 2018044300001 - Desenvolvimento e implementação de medidas práticas impulsionadoras da recuperação dos leporídeos silvestres em Portugal - financed by the Fundo Florestal Permanente (FFP), Dispatch nº4757/2017 of 31st May) by the Fundação para a Ciência e Tecnologia (FCT) (grant SFRH/BD/137067/2018) and by the Interdisciplinary Research Centre on Animal Health, Faculty of Veterinary Medicine, University of Lisbon (CIISA, FMV-UL) (Project UID/CVT/00276/2013).

## **Conflict of interest**

The authors declare no conflict of interest.



IntechOpen

## Author details

Margarida D. Duarte<sup>1,2\*</sup>, Carina L. Carvalho<sup>1</sup>, Fábio Abade dos Santos<sup>1,2,3</sup>,  
Jéssica Monteiro<sup>1</sup>, Madalena Monteiro<sup>4</sup>, Paulo Melo Carvalho<sup>4</sup>, Paula Mendonça<sup>4</sup>,  
Patrícia Tavares Santos<sup>5</sup> and Pedro C. Melo<sup>5</sup>

1 National Institute of Agrarian and Veterinarian Research, Virology Laboratory,  
Oeiras, Portugal

2 Interdisciplinary Research Centre on Animal Health, Faculty of Veterinary  
Medicine, University of Lisbon (CIISA, FMV-UL), Portugal

3 Department of Biochemistry and Molecular Biology, University of Oviedo,  
Oviedo, Spain

4 National Institute of Agrarian and Veterinarian Research, Pathology Laboratory,  
Oeiras, Portugal

5 General Directorate of Food and Veterinary, Epidemiology and Animal Health  
Unit, Lisbon, Portugal

\*Address all correspondence to: [margarida.duarte@iniav.pt](mailto:margarida.duarte@iniav.pt)

## IntechOpen

© 2020 The Author(s). Licensee IntechOpen. This chapter is distributed under the terms of the Creative Commons Attribution License (<http://creativecommons.org/licenses/by/3.0>), which permits unrestricted use, distribution, and reproduction in any medium, provided the original work is properly cited. 

## References

- [1] Soriguer R, Carro F. *Lepus granatensis*. The IUCN Red List of Threatened Species 2019: e.T41306A29531952019. DOI: 10.2305/IUCN.UK.20191.RLTS.T41306A2953195.en (downloaded on 24 January 2020)
- [2] Alves PC, Ferrand N, Suchentrunk F, Harris DJ, Ancient introgression of *Lepus timidus* mtDNA into *L. granatensis* and *L. europaeus* in the Iberian Peninsula. Molecular Phylogenetics and Evolution. 2003;27:70-80
- [3] Smith AT, Johnston CH. *Lepus timidus*. The IUCN Red List of Threatened Species 2019: e.T11791A451771982019. DOI: 10.2305/IUCN.UK.2019-1.RLTS.T11791A45177198.en (downloaded on 24 January 2020)
- [4] Paupério J. Ecologia de lebre-ibérica (*Lepus granatensis*) num Ecossistema de Montanha—Distribuição espacial, abundância e dieta de duas populações do Parque Natural da Serra da Estrela [Masters thesis]. Porto, Portugal: Faculdade de Ciências da Universidade do Porto; 2003
- [5] Ballesteros F, Smith AT. *Lepus castroviejoi*. The IUCN Red List of Threatened Species 2019: e.T11797A5039082019. DOI: 10.2305/IUCN.UK.2019-2.RLTS.T11797A503908.en (downloaded on 24 January 2020)
- [6] Hacklander K, Schai-Braun S. *Lepus europaeus*. The IUCN Red List of Threatened Species 2019: e.T41280A451874242019. DOI: 10.2305/IUCN.UK.2019-1.RLTS.T41280A45187424.en (downloaded on 24 January 2020)
- [7] Randi E, Riga F. *Lepus corsicanus*. The IUCN Red List of Threatened Species 2019: e.T41305A29529542019. DOI: 10.2305/IUCN.UK.2019-2.RLTS.T41305A2952954.en (downloaded on 24 January 2020)
- [8] Johnston CH, Robinson TJ, Child MF, Relton C. *Lepus capensis*. The IUCN Red List of Threatened Species 2019: e.T41277A451867502019. DOI: 10.2305/IUCN.UK.2019-1.RLTS.T41277A45186750.en (downloaded on 24 January 2020)
- [9] Chapman JA, Flux JEC. Chapter 1: Introduction and overview of the lagomorphs. In: Chapman JA, Flux JEC, editors. Rabbits, Hares and Pikas. Status Survey and Conservation Action Plan. Gland, Switzerland: International Union for the Conservation of Nature and Natural Resources; 1990. pp. 1-13
- [10] Purroy FJ. Liebre ibérica—*Lepus granatensis*. In: Salvador A, Cassinello J, editors. Enciclopedia Virtual de los Vertebrados Españoles. Madrid: Museo Nacional de Ciencias Naturales; 2011. Available from: <http://www.vertebradosibericos.org/>
- [11] Smith AT, Johnston CH, Alves PC, Hackländer K, editors. Pikas, Rabbits and Hares of the World. Baltimore: Johns Hopkins University Press; 2018. LCCN 2017004268; ISBN: 9781421423401 (hardcover); ISBN: 1421423405 (hardcover); ISBN: 9781421423418 (electronic); ISBN: 1421423413 (electronic)
- [12] de la Calzada E, Martínez FJ. Requerimientos y selección de hábitat de la liebre mediterránea (*Lepus granatensis*) en un paisaje agrícola mesetario. Ecología. 1994;8:381-394
- [13] López JMA, Hernández FJ, Purroy Y, Robles JL. Datos sobre la biología de la reproducción de la liebre Ibérica (*Lepus granatensis*) en agrosistemas cerealistas de la provincia de León (NW de España). Revista Florestal. 1996;9(1):49-60
- [14] Duarte J. Liebre ibérica (*Lepus granatensis* Rosenhauer, 1856). Galemys. 2000;12:3-14

- [15] Palacios F. Biometric and morphologic features of the species of the genus *Lepus* in Spain. *Mammalia*. 1989;**53**:227-263
- [16] Marboutin E, Péroux YR. Some aspects of the spatial distribution of hares (*Lepus europaeus*) at night. *Gibier Faune Sauvage*. 1999;**16**(2):143-158
- [17] Péroux R. Le lièvre d'Europe. *Bulletin Mensuel de l'Office National la Chasse*. 1995;**204**:1-96
- [18] Chapman JA, Flux JEC, editors. Rabbits, Hares and Pikas. Status Survey and Conservation Action Plan. 1990. IUCN/SSC Lagomorph Specialist Group. IUCN/SSC Action Plans for the Conservation of Biological Diversity; Imprint: Gland: IUCN; 1990. ISBN: 2-8317-0019-1
- [19] Holley AJF. The daily activity period of the brown hare (*Lepus europaeus*). *Mammalian Biology*. 2001;**66**:357-364
- [20] Lovegrove B. Fires of Life. Endothermy in Birds and Mammals. New Haven, CT: Yale University Press; 2019
- [21] JEC F. Reproductive strategies in the genus *Lepus*. In: Myers K, MacInnes CD, editors. Proceedings of the World Lagomorph Conference. Guelph, Ontario, Canada: University of Guelph; 1981. pp. 155-174
- [22] Roellig K, Goeritz F, Fickel J, Hermes R, Hofer H, Hildebrandt TB. Superconception in mammalian pregnancy can be detected and increases reproductive output per breeding season. *Nature Communications*. 2010;**1**:78. DOI: 10.1038/ncomms1079
- [23] Holley AJ, Greenwood PJ. The myth of the mad March hare. *Nature (London)*. 1984;**309**:549-550
- [24] Alves PC, Gonçalves H, Santos M, Rocha A. Original investigation reproductive biology of the Iberian hare, *Lepus granatensis*, in Portugal. *Mammalian Biology*. 2002;**67**:358-371. DOI: 10.1078/1616-5047-00051
- [25] Parker SP. Grzimek's Encyclopedia of Mammals. New York: McGraw Hill Publishing Company; 1990
- [26] Fernandez A, Soriguer R, Castien E, Carro F. Reproduction parameters of the Iberian hare *Lepus granatensis* at the edge of its range. *Wildlife Biology*. 2008;**14**:434-443. DOI: 10.2981/0909-6396-14.4.434
- [27] Farfán MA, Vargas JM, Real R, Palomo LJ, Duarte J. Population parameters and reproductive biology of the Iberian hare *Lepus granatensis* in southern Iberia. *Acta Theriologica*. 2004;**49**(3):319-335
- [28] Corbet GB. A review of classification in the family Leporidae. *Acta Zoologica Fennica*. 1983;**174**:11-15
- [29] Taylor M. The Way of Hare. England: Bloomsbury Natural History, Bloomsbury Publishing Plc; 2017. p. 288. ISBN: 9781472909893
- [30] BirdLife International 2019. *Aquila adalberti*. The IUCN Red List of Threatened Species 2019: e.T22696042A152593918. 10.2305/IUCN.UK.2019-3.RLTS.T22696042A152593918.en (downloaded on 12 February 2020)
- [31] Gortazar C, Millán J, Acevedo P, Escudero MA, Marco J, de Luco DF. A large-scale survey of brown hare *Lepus europaeus* and Iberian hare *L. granatensis* populations at the limit of their ranges. *Wildlife Biology*. 2007;**13**:244-250. DOI: 10.2981/0909-6396(2007)13[244:ALSO BH]2.0.CO;2
- [32] Acevedo P, Melo-Ferreira J, Real R, Alves PC. Past, present and future distributions of an Iberian endemic, *Lepus granatensis*: Ecological and evolutionary clues from species distribution models. *PLoS One*.



- 2012;7(12):e51529. DOI: 10.1371/journal.pone.0051529. [Epub: 13 December 2012]
- [33] Francisco CARRO Ramón C. SORIGUER. Long-term patterns in Iberian hare population dynamics in a protected area (Doñana National Park) in the southwestern Iberian Peninsula: Effects of weather conditions and plant cover. Special subsection: Animal Behavior and Ecology. 2016. 10.1111/1749-4877.12212
- [34] Marboutin E, Bray Y, Péroux R, Mauvy B, Lartiges A. Population dynamics in European hare: Breeding parameters and sustainable harvest rates. Journal of Applied Ecology. 2003;40:580-591. DOI: 10.1046/j.1365-2664.2003.00813.x
- [35] Carro F, Beltrán JF, Pérez JM, Márquez FJ, Iborra O, Soriguer YRC. Dinámica Poblacional de la Liebre ibérica (*Lepus granatensis*) en el Parque Nacional de Doñana. Segovia: Resúmenes IV Jornadas SECEM; 1999. p. 20
- [36] Voigt U, Siebert U. Living on the edge—Circadian habitat usage in pre-weaning European hares (*Lepus europaeus*) in an intensively used agricultural area. PLoS One. 2019;14(9):e0222205. DOI: 10.1371/journal.pone.0222205
- [37] Duarte MD, Carvalho CL, Bernardo B, Barros SV, Benevides S, Flor L, et al. Rabbit haemorrhagic disease virus 2 (RHDV2) outbreak in Azores: Disclosure of common genetic markers and phylogenetic segregation within the European strains. Infection, Genetics and Evolution. 2015;35:163-171. DOI: 10.1016/j.meegid.2015.08.005. [Epub: 04 August 2015]
- [38] Carvalho CL, Silva S, Gouveia P, Costa M, Duarte EL, Henriques AM, et al. Emergence of rabbit haemorrhagic disease virus 2 in the archipelago of Madeira, Portugal (2016-2017). Virus Genes. 2017;53(6):922-926. DOI: 10.1007/s11262-017-1483-6. [Epub 21 June 2017]
- [39] Brown LJ, Rosatte RC, Fehlner-Gardiner C, Bachmann P, Ellison JA, Jackson FR, et al. Oral vaccination and protection of red foxes (*Vulpes vulpes*) against rabies using ONRAB, an adenovirus-rabies recombinant vaccine. Vaccine. 2014;32(8):984-989. DOI: 10.1016/j.vaccine.2013.12.015. [Epub: 24 December 2013]
- [40] Maresch C, Lange E, Teifke JP, Fuchs W, Klupp B, Müller T, et al. Oral immunization of wild boar and domestic pigs with attenuated live vaccine protects against Pseudorabies virus infection. Veterinary Microbiology. 2012;161(1-2):20-25. DOI: 10.1016/j.vetmic.2012.07.002. [Epub: 10 July 2012]
- [41] Wobeser G. Disease management strategies for wildlife. Revue Scientifique et Technique. 2002;21(1):159-178
- [42] Bárcena J, Morales M, Vázquez B, Boga JA, Parra F, Lucientes J, et al. Horizontal transmissible protection against myxomatosis and rabbit hemorrhagic disease by using a recombinant myxoma virus. Journal of Virology. 2000;74:1114-1123
- [43] Martín-Alonso JM, Castañón S, Alonso P, Parra F, Ordás R. Oral immunization using tuber extracts from transgenic potato plants expressing rabbit hemorrhagic disease virus capsid protein. Transgenic Research. 2003;12:127-130
- [44] Parra F, Prieto M. Purification and characterization of a calicivirus as the causative agent of a lethal hemorrhagic disease in rabbits. Journal of Virology. 1990;64:4013-4015
- [45] Carvalho CL. The role of wild leporids as reservoirs of infectious agents [PhD thesis]. Portugal: University of Évora; 2017. p. 431.

- [46] Gavier-Widén D, Mörner T. Epidemiology and diagnosis of the European brown hare syndrome in Scandinavian countries. *Revue Scientifique et Technique (International Office of Epizootics)*. 1991;**10**:453-458
- [47] Wibbelt G, Frölich K. Infectious diseases in European Brown hare (*Lepus europaeus*). *Wildlife Biology in Practice*. 2005;**1**(1):86-93
- [48] Lukešová D, Langrová I, Vadlejch J, Jankovská I, Hlava J, Válek P, et al. Endoparasites in European Hares (*Lepus europaeus*) Under Gamekeeping Conditions in the Czech Republic. Košice: Institute of Parasitology, SAS; 2012
- [49] Diakou A, Sokos C, Papadopoulos E. Endoparasites Found in European Brown Hares (*Lepus europaeus*) Hunted in Macedonia, Greece. Research Note. Košice: Institute of Parasitology, SAS; 2014
- [50] Kornaś S, Wierzbowska IA, Wajdzik M, Kowal J, Basiaga M, Nosal P. Endoparasites of European brown hare (*Lepus europaeus*) from southern Poland based on necropsy. *Annals of Animal Science*. 2014;**14**(2):297-305
- [51] Carvalho CL, Zé-Zé L, Lopes de Carvalho I, Duarte EL. Tularaemia: a challenging zoonosis. *Comparative Immunology, Microbiology and Infectious Diseases*. 2014;**37**(2):85-96. DOI: 10.1016/j.cimid.2014.01.002. [Epub: 13 January 2014]
- [52] Ruiz-Fons F, Ferroglio E, Gortázar C. *Leishmania infantum* in free-ranging hares, Spain, 2004-2010. *Eurosurveillance*. 2013;**18**(30):20541
- [53] Lopes de Carvalho I, Toledo A, Carvalho CL, Barandika JF, Respicio-Kingry LB, Garcia-Amil C, et al. *Francisella* species in ticks and animals, Iberian Peninsula. *Ticks Tick Borne Diseases*. 2016;**7**(1):159-165. DOI: 10.1016/j.ttbdis.2015.10.009. [Epub: 19 October 2015]
- [54] Martín C, Gallardo MT, Mateos L, Vián E, García MJ, Ramos J, et al. Outbreak of tularaemia in Castilla y León, Spain. *Eurosurveillance*. 2007;**12**(11):E071108.1. DOI: 10.2807/esw.12.45.03302-en
- [55] Gyuranecz M, Erdélyi K, Makrai L, Fodor L, Szépe B, Mészáros AR, et al. Brucellosis of the European brown hare (*Lepus europaeus*). *Journal of Comparative Pathology*. 2011;**145**(1):1-5. DOI: 10.1016/j.jcpa.2010.11.013
- [56] Schantz PM, Cruz-Reyes A, Colli C, Lord RD. Sylvatic echinococcosis in Argentina. I. On the morphology and biology of strobilar *Echinococcus granulosus* (Batsch, 1786) from domestic and sylvatic animal hosts. *Tropenmedizin und Parasitologie*. 1975;**26**(3):334-344
- [57] Craig P, Mastin A, van Kesteren F, Boufana B. *Echinococcus granulosus*: Epidemiology and state-of-the-art of diagnostics in animals. *Veterinary Parasitology*. 2015;**213**(3-4):132-148. DOI: 10.1016/j.vetpar.2015.07.028
- [58] Chaignat V, Boujon P, Frey CF, Hentrich B, Müller N, Gottstein B. The brown hare (*Lepus europaeus*) as a novel intermediate host for *Echinococcus multilocularis* in Europe. *Parasitology Research*. 2015;**114**(8):3167-3169. DOI: 10.1007/s00436-015-4555-3
- [59] Magistrali CF, Cucco L, Pezzotti G, Farneti S, Cambiotti V, Catania S, et al. Characterisation of *Yersinia pseudotuberculosis* isolated from animals with yersiniosis during 1996-2013 indicates the presence of pathogenic and Far Eastern strains in Italy. *Veterinary Microbiology*. 2015;**180**:161. DOI: 10.1016/j.vetmic.2015.08.020
- [60] Fratini F, Verin R, Ebani VV, Ambrogi C, Bertelloni F, Turchi B, et al. Experimental infection with *Yersinia pseudotuberculosis* in European brown hare (*Lepus europaeus*, Pallas). *Asian Pacific Journal of Tropical Medicine*.

2017;**10**(3):285-291. DOI: 10.1016/j.apjtm.2017.03.008

[61] Stancampiano L, Ravagnan S, Capelli G, Militerno G. Cysticercosis by *Taenia pisiformis* in Brown hare (*Lepus europaeus*) in Northern Italy: Epidemiologic and pathologic features. The International Journal for Parasitology: Parasites and Wildlife. 2019;**9**:139-143. DOI: 10.1016/j.ijppaw.2019.04.004

[62] Camarda A, Pugliese N, Cavadini P, Circella E, Capucci L, Caroli A, et al. Detection of the new emerging rabbit haemorrhagic disease type 2 virus (RHDV2) in Sicily from rabbit (*Oryctolagus cuniculus*) and Italian hare (*Lepus corsicanus*). Research in Veterinary Science. 2014;**97**:642-645. DOI: 10.1016/j.rvsc.2014.10.008

[63] Puggioni G, Cavadini P, Maestrale C, Scivoli R, Botti G, Ligios C, et al. The new French 2010 rabbit hemorrhagic disease virus causes an RHD-like disease in the Sardinian Cape hare (*Lepus capensis mediterraneus*). Veterinary Research. 2013;**44**:96. DOI: 10.1186/1297-9716-44-96

[64] Le Gall-Reculé G, Lemaitre E, Bertagnoli S, Hubert C, Top S, Decors A, et al. Large-scale lagovirus disease outbreaks in European brown hares (*Lepus europaeus*) in France caused by RHDV2 strains spatially shared with rabbits (*Oryctolagus cuniculus*). Veterinary Research. 2017;**48**(1):70. DOI: 10.1186/s13567-017-0473-y

[65] Velarde R, Cavadini P, Neimanis A, Cabezon O, Chiari M, Gaffuri A, et al. Spillover events of infection of brown hares (*Lepus europaeus*) with rabbit haemorrhagic disease type 2 virus (RHDV2) caused sporadic cases of an European Brown Hare Syndrome-like disease in Italy and Spain. Transboundary and Emerging Diseases. 2017;**64**(6): 1750-1761. DOI: 10.1111/tbed.12562

[66] Neimanis AS, Ahola H, Larsson Pettersson U, Lopes AM, Abrantes J, Zohari S, et al. Overcoming species barriers: An outbreak of Lagovirus europaeus GI.2/RHDV2 in an isolated population of mountain hares (*Lepus timidus*). BMC Veterinary Research. 2018;**14**(1):367. DOI: 10.1186/s12917-018-1694-7

[67] Bell DJ, Davis JP, Gardner M, Barlow AM, Rocchi M, Gentil M, Wilson RJ. Rabbit haemorrhagic disease virus type 2 in hares in England. The Veterinary Record. 2019. Jan 26;**184**(4):127-128. DOI: 10.1136/vr.l337.

[68] García-Bocanegra I, Camacho-Sillero L, Risalde MA, Dalton KP, Caballero-Gómez J, Agüero M, et al. First outbreak of myxomatosis in Iberian hares (*Lepus granatensis*). Transboundary and Emerging Diseases. 2019;**66**(6):2204-2208. DOI: 10.1111/tbed.13289

[69] Águeda-Pinto A, Lemos de Matos A, Abrantes M, Kraberger S, Risalde MA, Gortázar C, et al. Genetic characterization of a recombinant myxoma virus in the Iberian hare (*Lepus granatensis*). Viruses. 2019;**11**(6). pii: E530. DOI: 10.3390/v11060530

[70] Dalton KP, Martín JM, Nicieza I, Podadera A, de Llano D, Casais R, et al. Myxoma virus jumps species to the Iberian hare. Transboundary and Emerging Diseases. 2019;**66**(6):2218-2226. DOI: 10.1111/tbed.13296

[71] Jones A, Pybus MJ. Taeniasis and echinococcosis. In: Samuel WM, Pybus MJ, Kocan AA, editors. Parasitic Diseases of Wild Mammals. Ames, USA: Iowa State University Press; 2001. pp. 150-192

[72] Contreiro J. Prevalência de *Taenia pisiformis*/*Cysticercus pisiformis* em três zonas de caça do Baixo Alentejo [MSc thesis]. Universidade Lusófona de Humanidades e Tecnologias Faculdade de Medicina Veterinária Lisboa; 2014



- [73] Helminths SEJL. Helminths, Arthropods and Protozoa of Domestic Animals. Baltimore: Williams and Wilkins; 1968
- [74] Graham-Brown J, Gilmore P, Harcourt-Brown F, Eastham H, Williams D. Veterinary Record Case Reports. 2018. Published Online First. DOI: 10.1136/vetreccr-2018-000634
- [75] Hallal-Calleros C, Morales-Montor J, Orihuela-Trujillo A, Togno-Peirce C, Murcia-Mejía C, Bielli A, et al. *Taenia pisiformis* cysticercosis induces decreased prolificacy and increased progesterone levels in rabbits. *Veterinary Parasitology*. 2016;**229**:50-53. DOI: 10.1016/j.vetpar.2016.09.015
- [76] Alzaga V, Vicente J, Villanua D, Acevedo P, Casas F, Gortazar C. Body condition and parasite intensity correlates with escape capacity in Iberian hares (*Lepus granatensis*). *Behavioral Ecology and Sociobiology*. 2008;**62**:769-775
- [77] Harcourt-Brown FM. Infectious diseases of domestic rabbits. In: *Textbook of Rabbit Medicine*. 1st ed. Oxford: Butterworth-Heinemann; 2001. p. 363
- [78] Saunders RA, Rees-Davies R. Notes on Rabbit Internal Medicine. Oxford: Blackwell; 2005. pp. 146-147
- [79] Varga M. The rabbit-friendly practice. In: Meredith A, Lord B, editors. *BSAVA Manual of Rabbit Medicine*. Gloucester: British Small Animal Veterinary Association; 2014. p. 66
- [80] Manning PJ, Ringler DH, Newcomer CE. *The Biology of the Laboratory Rabbit*. 2nd ed. London: Academic Press Limited. ISBN: 0-12-469235-4
- [81] Van Praag, E. Cysticercosis and Hydatid Echinococcosis, Dangerous Parasitic Larval Forms in Rabbits. 2015
- [82] Shield JM, Heath DD, Smyth JD. Light microscope studies of the early development of *Taenia pisiformis* cysticerci. *International Journal for Parasitology*. 1973;**3**(4):471-480. DOI: 10.1016/0020-7519(73)90042-8
- [83] Khalil A, Noor El Din S, Radwan N, et al. Cysticercus pisiformis: Ultrastructural transformation of the tegument during development from oncosphere to cysticercus. *Parasitologists United Journal*. 2014;**7**:13
- [84] Solomon SG. Some points in the early development of cysticercus pisiformis (Bloch 1780). *Journal of Helminthology*. 1934;**12**:197-204
- [85] Heath DD. The migration of oncospheres of *Taenia pisiformis*, *T. serialis* and *Echinococcus granulosus* within the intermediate host. *International Journal for Parasitology*. 1971;**1**:145-152. DOI: 10.1016/0020-7519(71)90008-7
- [86] Boubaker G, Marinova I, Gori F, Hizem A, Müller N, Casulli A, et al. A dual PCR-based sequencing approach for the identification and discrimination of *Echinococcus* and *Taenia* taxa. *Molecular and Cellular Probes*. 2016;**30**(4):211-217. DOI: 10.1016/j.mcp.2016.05.004
- [87] Duff JP, Whitwell K, Chase D. The emergence and epidemiology of European brown hare syndrome in the UK. In: *Proc, 1st International Symposium on Caliciviruses ESVV*, Reading, UK. 1997. pp. 176-181
- [88] Lenghaus C, Studdert MJ, Gavier-Widden D. Calicivirus infections. In: Williams ES, Barker IK, editors. *Infectious Disease of Wild Mammals*. 3rd ed. Ames, Iowa: Iowa State University Press; 2001. pp. 280-291
- [89] Scicluna MT, Lavazza A, Capucci L. European brown hare syndrome in northern Italy: Results of a virological and serological survey. *Revue Scientifique et Technique*.

1994;**13**(3):893-894. DOI: 10.20506/rst.13.3.801

[90] Chasey D, Lucas M, Westcott D, Williams M. European brown hare syndrome in the UK: A calicivirus related to but distinct from that of viral haemorrhagic disease in rabbits. *Archives of Virology*. 1992;**124**(3-4): 363-370. DOI: 10.1007/bf01309816

[91] Le Gall-Reculé G, Zwingelstein F, Laurent S, Portejoie Y, Rasschaert D. Molecular epidemiology of European brown hare syndrome virus in France between 1989 and 2003. *Archives of Virology*. 2006;**151**(9):1713-1721. DOI: 10.1007/s00705-006-0754-7. [Epub: 07 April 2006]

[92] Frölich K, Meyer HH, Pielowski Z, Ronsholt L, von Seck-Lanzendorf S, Stolte M. European brown hare syndrome in free-ranging hares in Poland. *Journal of Wildlife Diseases*. 1996;**32**(2):280-285. DOI: 10.7589/0090-3558-32.2.280

[93] Billinis C, Knowles NJ, Spyrou V, Sofianidis G, Psychas V, Birtsas PK, et al. Genetic analysis of the first European Brown hare syndrome virus isolates from Greece. *Wildlife Biology in Practice*. 2005;**1**(2):118-127. DOI: 10.2461/wbp.2005.1.14

[94] Frölich K, Fickel J, Ludwig A, Lieckfeldt D, Streich WJ, Jurcik R, et al. New variants of European brown hare syndrome virus strains in free-ranging European brown hares (*Lepus europaeus*) from Slovakia. *Journal of Wildlife Diseases*. 2007;**43**(1):89-96

[95] Syrjälä P, Nylund M, Heinikainen S. European brown hare syndrome in free-living mountain hares (*Lepus timidus*) and European brown hares (*Lepus europaeus*) in Finland 1990-2002. *Journal of Wildlife Diseases*. 2005;**41**(1):42-47. DOI: 10.7589/0090-3558-41.1.42

[96] Capucci L, Scicluna MT, Lavazza A. Diagnosis of viral haemorrhagic disease

of rabbits and the European brown hare syndrome. *Revue Scientifique et Technique*. 1991;**10**:347-370

[97] Fuchs A, Weissenböck H. Comparative histopathological study of rabbit haemorrhagic disease (RHD) and European brown hare syndrome (EBHS). *Journal of Comparative Pathology*. 1992;**107**(1):103-113

[98] Wirblich C, Meyers G, Ohlinger VF, Capucci L, Eskens U, Haas B, et al. European brown hare syndrome virus: Relationship to rabbit hemorrhagic disease virus and other caliciviruses. *Journal of Virology*. 1994;**68**(8):5164-5173

[99] Ros Bascuñana C, Nowotny N, Belák S. Detection and differentiation of rabbit hemorrhagic disease and European brown hare syndrome viruses by amplification of VP60 genomic sequences from fresh and fixed tissue specimens. *Journal of Clinical Microbiology*. 1997;**35**(10):2492-2495

[100] Duff JP, Chasey D, Munro R, Wooldridge M. European brown hare syndrome in England. *The Veterinary Record*. 1994;**134**(26):669-673. DOI: 10.1136/vr.134.26.669

[101] Le Gall-Reculé G, Zwingelstein F, Portejoie Y, Le Gall G. Immunocapture-RT-PCR assay for detection and molecular epidemiology studies of rabbit haemorrhagic disease and European Brown Hare Syndrome viruses. *Journal of Virological Methods*. 2001;**97**(1-2):49-57. DOI: 10.1016/s0166-0934(01)00336-6

[102] Zexiao Y, Lirui L, Yin W, Xueping Y, Xueqing H, Zengqi Y, et al. Development of a RT-PCR for the detection of European brown hare syndrome virus. *Advanced Materials Research*. 2011;**271-273**:410-416

[103] Liu SJ, Xue HP, Pu BQ, Qian NH. A new viral disease of rabbits. *Animal Husbandry & Veterinary Medicine*. 1984;**16**:253-255

- [104] Le Gall-Reculé G, Zwingelstein F, Boucher S, Le Normand B, Plassiart G, Portejoie Y, et al. Detection of a new variant of rabbit haemorrhagic disease virus in France. *The Veterinary Record*. 2011;**168**:137-138. DOI: 10.1136/vr.d697
- [105] Lopes AM, Marques S, Silva E, Magalhães MJ, Pinheiro A, Alves PC, et al. Detection of RHDV strains in the Iberian hare (*Lepus granatensis*): Earliest evidence of rabbit lagovirus cross-species infection. *Veterinary Research*. 2014;**45**:94. DOI: 10.1186/s13567-014-0094-7
- [106] Hall RN, Peacock DE, Kovaliski J, Mahar JE, Mourant R, Piper M, et al. Detection of RHDV2 in European brown hares (*Lepus europaeus*) in Australia. *The Veterinary Record*. 2017;**180**(5):121. DOI: 10.1136/vr.104034
- [107] Rocchi M, Maley M, Dagleish M, Boag B. Rabbit haemorrhagic disease virus type 2 in hares in Scotland. *The Veterinary Record*. 2019;**185**(1):23. DOI: 10.1136/vr.l4481
- [108] World Organisation for Animal Health (OIE) Technical Disease Cards. Rabbit Haemorrhagic Disease. Aetology, Epidemiology, Diagnosis, Prevention and Control References. 2015. Available from: [https://www.oie.int/fileadmin/Home/eng/Animal\\_Health\\_in\\_the\\_World/docs/pdf/Disease\\_cards/RHD.pdf](https://www.oie.int/fileadmin/Home/eng/Animal_Health_in_the_World/docs/pdf/Disease_cards/RHD.pdf)
- [109] Le Gall-Reculé G, Lavazza A, Marchandeau S, Bertagnoli S, Zwingelstein F, Cavadini P, et al. Emergence of a new lagovirus related to rabbit haemorrhagic disease virus. *Veterinary Research*. 2013;**44**:81. DOI: 10.1186/1297-9716-44-81
- [110] Dalton KP, Nicieza I, Balseiro A, Muguerza MA, Rosell JM, Casais R, et al. Variant rabbit hemorrhagic disease virus in young rabbits, Spain. *Emerging Infectious Diseases*. 2012;**18**:2009-2012. DOI: 10.3201/eid1812.120341
- [111] Guittre C, Baginski I, Le Gall G, Prave M, Trepo C, Cova L. Detection of rabbit haemorrhagic disease virus isolates and sequence comparison of the N-terminus of the capsid protein gene by the polymerase chain reaction. *Research in Veterinary Science*. 1995;**58**:128-132. DOI: 10.1016/0034-5288(95)90065-9
- [112] Tham KM, Barnes SM, Hunter SN. Polymerase chain reaction amplification and gene sequence analysis of a calicivirus from a feral rabbit. *Virus Genes*. 1999;**18**(3):235-242. DOI: 10.1023/a:1008020303036
- [113] Yang L, Wang F, Hu B, Xue J, Hu Y, Zhou B, et al. Development of an RT-PCR for rabbit hemorrhagic disease virus (RHDV) and the epidemiology of RHDV in three eastern provinces of China. *Journal of Virological Methods*. 2008;**151**:24-29. DOI: 10.1016/j.jviromet.2008.04.003
- [114] Gall A, Hoffmann B, Teifke JP, Lange B, Schirrmeier H. Persistence of viral RNA in rabbits which overcome an experimental RHDV infection detected by a highly sensitive multiplex real-time RT-PCR. *Veterinary Microbiology*. 2007;**120**(1-2):17-32. DOI: 10.1016/j.vetmic.2006.10.006
- [115] Yuan D, Guo D, Liu J, Si C, Jiang Q, Lin H, et al. Development of a reverse-transcription loop-mediated isothermal amplification method for detection of rabbit hemorrhagic disease virus. *Journal of Virological Methods*. 2013;**187**:274-277. DOI: 10.1016/j.jviromet.2012.11.020
- [116] Niedzwiedzka-Rystwej P, Hukowska-Szematowicz B, Dzialo J, Tokarz-Deptula B, Deptula W. Real time PCR detection of rabbit haemorrhagic disease virus in rabbits infected with different European strains of RHDV. *Polish Journal of Veterinary Sciences*. 2013;**16**:39-43. DOI: 10.2478/pjvs-2013-0006



- [117] Duarte MD, Carvalho CL, Barros SC, Henriques AM, Ramos F, Fagulha T, et al. A real time Taqman RT-PCR for the detection of rabbit hemorrhagic disease virus 2 (RHDV2). *Journal of Virological Methods*. 2015;**219**:90-95. DOI: 10.1016/j.jviromet.2015.03.017
- [118] Carvalho CL, Duarte EL, Monteiro M, Botelho A, Albuquerque T, Fevereiro M, et al. Challenges in the rabbit haemorrhagic disease 2 (RHDV2) molecular diagnosis of vaccinated rabbits. *Veterinary Microbiology*. 2017;**98**:43-50. DOI: 10.1016/j.vetmic.2016.12.006
- [119] Carvalho CL, Duarte EL, Monteiro JM, Afonso C, Pacheco J, Carvalho P, et al. Progression of rabbit haemorrhagic disease virus 2 upon vaccination in an industrial rabbitry: A laboratorial approach. *World Rabbit Science*. 2017;**25**:73-85
- [120] Carvalho CL, Abade dos Santos F, Fagulha T, Duarte MD. The aptitude of the specific RT-qPCR method used for RHDV2 detection: *In silico* analysis. In: Poster. Wildlife Summit—Game Manegement, 28 and 29 of June, 2019. Oeiras, Portugal
- [121] Dalton KP, Arnal JL, Benito AA, Chacón G, Martín Alonso JM, Parra F. Conventional and real time RT-PCR assays for the detection and differentiation of variant rabbit hemorrhagic disease virus (RHDVb) and its recombinants. *Journal of Virological Methods*. January 2018;**251**:118-122. DOI: 10.1016/j.jviromet.2017.10.009
- [122] Lucas A, Bouley G, Quinchon C, Tocas L. La myxomatose du lievre. *Bulletin de l'Office International des Epizooties*. 1953;**39**:770-776
- [123] Jacotot H, Vallee A, Virat B. Sur un cas de myxomatose chez le lievre. *Annales del'Institut Pasteur*. 1954;**86**:105-107
- [124] Barlow A, Lawrence K, Everest D, Dastjerdi A, Finnegan C, Steinbach F. Confirmation of myxomatosis in a European brown hare in Great Britain. *The Veterinary Record*. 2014;**175**(3):75-76. DOI: 10.1136/vr.g4621
- [125] OIE. Myxomatosis. Spain. 2018. Available from: [https://www.oie.int/wahis\\_2/public/wahid.php/Reviewreport/Review/viewsummary?fu pser=&dothis=&reportid=27539](https://www.oie.int/wahis_2/public/wahid.php/Reviewreport/Review/viewsummary?fu pser=&dothis=&reportid=27539)
- [126] Carvalho CL, Abade dos Santos FA, Monteiro M, Carvalho P, Mendonça P, Duarte MD. First cases of myxomatosis in Iberian hares (*Lepus granatensis*) *Veterinary Record Case Reports (Portugal)*. 2020. DOI: 10.1136/vetreccr-2019-001044 [Accessed: 13 April 2020]
- [127] Stanford MM, Werden SJ, McFadden G. Myxoma virus in the European rabbit: Interactions between the virus and its susceptible host. *Veterinary Research*. 2007;**38**(2): 299-318. DOI: 10.1051/vetres:2006054. [Epub: 13 February 2007]
- [128] Kerr PJ, Liu J, Cattadori I, Ghedin E, Read AF, Holmes EC. Myxoma virus and the Leporipox-viruses: An evolutionary paradigm. *Viruses*. 2015;**7**(3):1020-1061. DOI: 10.3390/v7031020
- [129] Bertagnoli S, Marchandean S. Myxomatosis. *Revue Scientifique et Technique (International Office of Epizootics)*. 2015;**34**(2):549-556
- [130] Marlier D, Vindevogel H. Poxless myxomatosis—Isolation of three strains in Belgium. *Annales de Médecine Vétérinaire*. 1996;**140**:343-346
- [131] Marlier D, Mainil J, Linde A, Vindevogel H. Infectious agents associated with rabbit pneumonia: Isolation of amyxomatous myxoma virus strains. *The Veterinary Journal*.

2000;**159**(2):171-178. DOI: 10.1053/tvjl.1999.0413

[132] Abade dos Santos FA, Monteiro M, Pinto A, Carvalho CL, Peleteiro MC, Carvalho P, et al. First description of a herpesvirus infection in genus *Lepus*. *PLoS One*. 2020;**14**:1-20. DOI: 10.1371/journal.pone.0231795

[133] Dinev I. An outbreak of myxomatosis in rabbits in bulgaria clinicomorphological studies. *Trakia Journal of Sciences*. 2012;**10**(1):79-84. Available from: <http://www.uni-sz.bg>

[134] Cavadini P, Botti G, Barbieri I, Lavazza A, Capucci L. Molecular characterization of SG33 and Borghi vaccines used against myxomatosis. *Vaccine*. 2010;**28**:5414-5420. DOI: 10.1016/j.vaccine.2010.06.017

[135] Belsham GJ, Polacek C, Breum SØ, Larsen LE, Bøtner A. Detection of myxoma viruses encoding a defective M135R gene from clinical cases of myxomatosis; possible implications for the role of the M135R protein as a virulence factor. *Virology Journal*. 2010;**7**:7-17. DOI: 10.1186/1743-422X-7-7

[136] Albini S, Sigrist B, Güttinger R, Schelling C, Hoop RK, Vöggtlin A. Development and validation of myxoma virus real-time polymerase chain reaction assay. *Journal of Veterinary Diagnostic Investigation*. 2012;**24**:135-137. DOI: 10.1177/1040638711425946

[137] Duarte MD, Barros SC, Henriques AM, Fagulha MT, Ramos F, Luís T, et al. Development and validation of a real time PCR for the detection of myxoma virus based on the diploid gene M000.5L/R. *The Journal of Virological Methods*. 2014;**196**:219-224. DOI: 10.1016/j.jviromet.2013.11.014

[138] Dalton KP, Ringleb F, Martín Alonso JM, Parra F. Rapid identification of myxoma virus variants

by long-range PCR and restriction fragment length polymorphism analysis. *Journal of Virological Methods*. 2009;**161**:284-288. DOI: 10.1016/j.jviromet.2009.06.026

[139] Willer DO, McFadden G, Evans DH. The complete genome sequence of Shope (rabbit) fibroma virus. *Virology*. 1999;**264**:319-343. DOI: 10.1006/viro.1999.0002

[140] OIE (World Organisation for Animal Health) *Terrestrial Manual* 2018. Chapter 3.6.1. Myxomatosis. Available from: <http://www.oie.int/en/international-standardsetting/terrestrial-manual/access-online/>

[141] Murphy FA, Fauquet CM, Bishop DHL, Ghabrial SA, Jarvis AW, Martelli GP, et al. Virus taxonomy: classification and nomenclature of viruses. In: *Sixth Report of the International Committee for the Taxonomy of Viruses*. Archives of Virology. Vienna: Springer Verlag; 1995 (Supplement 10). pp. 586

[142] Scherrer PR. Morphogenese *et* ultrastructure de virus fibromateux de Shope. *Pathology and Microbiology*. 1968;**3**:129-146

[143] Joubert L. La Myxomatose T.II. Série: Les Maladies Animales à Virus. Paris, France: L'Expansion éditeur; 1973

[144] VanDevanter DR, Warrenner P, Bennett L, et al. Detection and analysis of diverse herpesviral species by consensus primer PCR. *Journal of Clinical Microbiology*. 1996;**34**(7):1666-1671

[145] Lourenço RF. The food habits of Eurasian eagle-owls in Southern Portugal. *The Journal of Raptor Research*. 2006;**40**:297-300

[146] Rosa G, Encarnação V. The white stork in Portugal: Results of the 2004 National Census. Lisbon, Portugal:

NABU-Bundesverband; 2013. Available from: [https://bergenhusen.nabu.de/imperia/md/nabu/images/nabu/einrichtungen/bergenhusen/portugal\\_zensus\\_2004.pdf](https://bergenhusen.nabu.de/imperia/md/nabu/images/nabu/einrichtungen/bergenhusen/portugal_zensus_2004.pdf)

[147] Catry I, Encarnação V, Pacheco C, Catry T, Tenreiro P, da Silva LP, et al. Recent changes on migratory behaviour of the White stork (*Ciconia ciconia*) in Portugal: Towards the end of migration? *Airo*. 2016/2017;24:28-35

[148] Jennings N. RSPB Spotlight Hares. England: Bloomsbury Natural History, Bloomsbury Publishing Plc; 2017. pp. 128. ISBN-10: 1472933648; ISBN-13: 978-1472933645

[149] Veličković N, Ferreira E, Djan M, Ernst M, Obreht Vidaković D, Monaco A, et al. Demographic history, current expansion and future management challenges of wild boar populations in the Balkans and Europe. *Heredity (Edinb)*. 2016;117, 5:348-357. DOI: 10.1038/hdy.2016.53

[150] Schley L, Roper TJ. Diet of wild boar *Sus scrofa* in Western Europe, with particular reference to consumption of agricultural crops. *Mammal Review*. 2003;33(1):43-56 (Printed in Great Britain)

[151] Duarte M, Carvalho CL, Santos FA, Gomes J, Alves PC, Esteves PJ, et al. “+Coelho: Avaliação Ecosanitária das Populações Naturais de Coelho Bravo Visando o Controlo da Doença Hemorrágica Viral”. Relatório de atividades na época venatória 2017-2018. INIAV I.P., DGAV, CIBIO, ANPC, CNCP, FENCAÇA. Fundo Florestal Permanente. ICNF. 2018. pp. 280